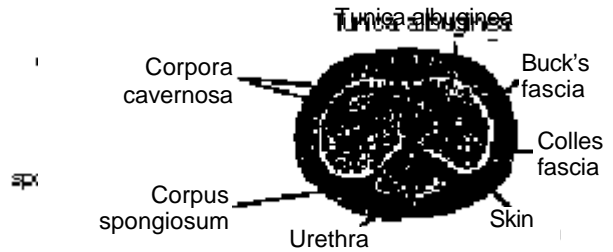
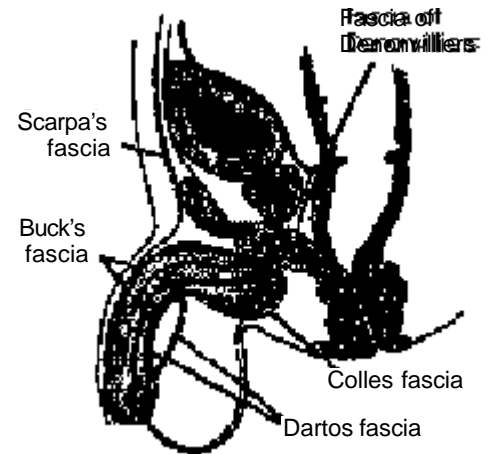
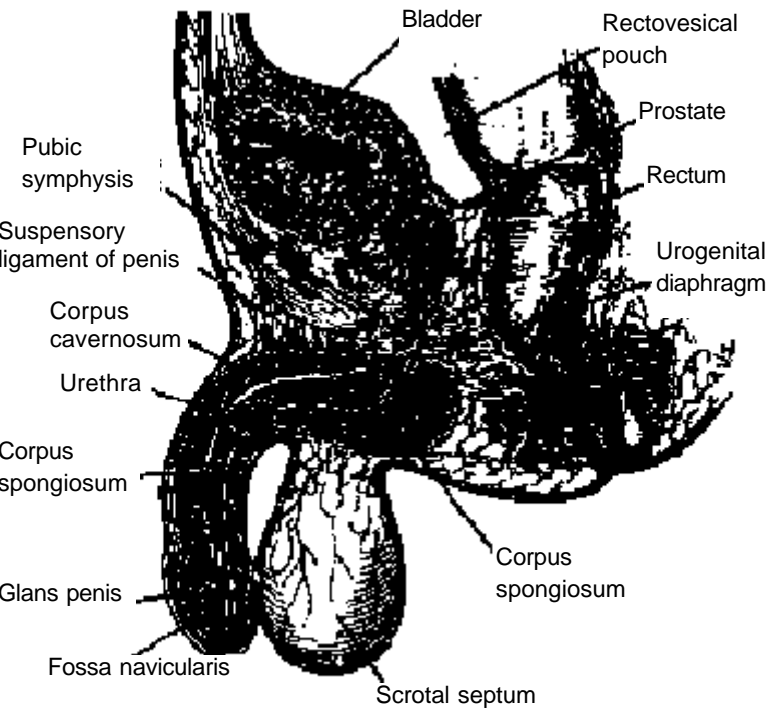


Figure 1. Cross-section Anatomy of the Penis



Used with permission from: Tanagho EA, McAnich JW, eds. *Smith's General Urology*, 15th ed. New York: McGraw-Hill Education;2000:10.