

Figures 2 A-B. Dorsal Slit Procedure as Treatment for Phimosis

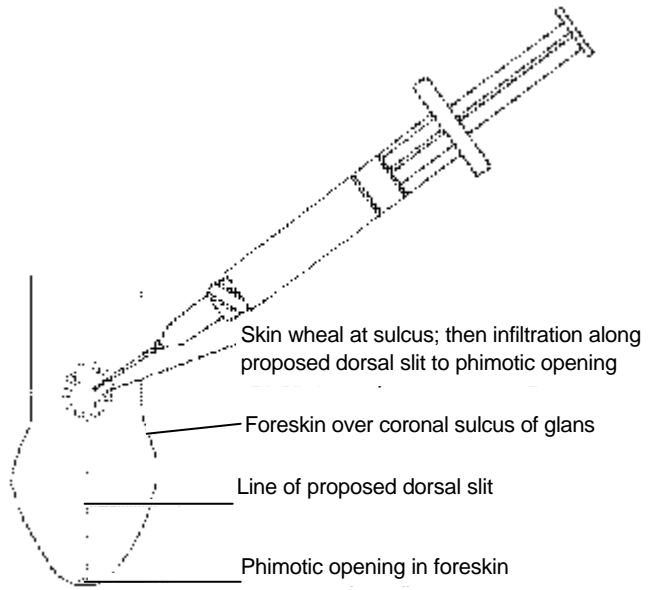


Figure 2A. Technique for anesthetizing the foreskin before performing dorsal slit procedure as treatment for phimosis.

Figures used with permission from: Roberts JR, Hedges JR, eds. *Clinical Procedures in Emergency Medicine*, 3rd ed. Philadelphia: W.B. Saunders Co.; 1998: 948.

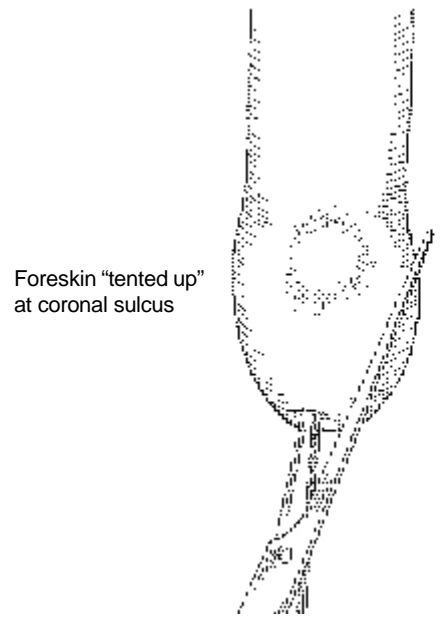


Figure 2B. Placement of hemostats for dorsal slit procedure as treatment for phimosis.