EMERGENCY MEDICINE REPORTS

Practical, Evidence-Based Reviews in Emergency Care

MARCH 1, 2016 VOL. 37, NO. 5

AUTHORS

Dennis Hanlon, MD, Emergency Medicine Attending, Quality Site Director, Allegheny General Hospital, Pittsburgh, PA.

Kirby Black, MD, Emergency Medicine, Allegheny General Hospital, Pittsburgh, PA.

PEER REVIEWER

Howard A. Werman, MD, FACEP, Professor of Emergency Medicine, Vice Chair of Academic Affairs, Medical Director, MedFlight, Ohio State University, Columbus.

STATEMENT OF FINANCIAL DISCLOSURE

To reveal any potential bias in this publication, and in accordance with Accreditation Council for Continuing Medical Education guidelines, we disclose that Dr. Farel (CME question reviewer) owns stock in Johnson & Johnson. Dr. Stapczynski (editor) owns stock in Pfizer, Johnson & Johnson, Walgreens Boots Alliance Inc., GlaxoSmithKline, Bristol Myers Squibb, and AxoGen. Dr. Schneider (editor), Ms. Fessler (nurse planner), Dr. Hanlon (author), Dr. Black (author), Dr. Werman (peer reviewer), Ms. Mark (executive editor), Ms. Leslie Coplin (executive editor), and Mr. Landenberger (editorial and continuing education director) report no financial relationships with companies related to the field of study covered by this CME/CE activity.

AHC Media

Emergency Airway Management: A Targeted Review of Difficult Trauma Situations

Introduction

Airway management is one of the cornerstones of emergency medicine practice and resuscitation. After a brief review of the history of airway management in trauma patients, this article will discuss the literature concerning several difficult clinical scenarios. Although these patients will most often eventually be transferred to a trauma center, a difficult or failed airway initially can present to any emergency department, and can be extremely challenging. An emergency clinician must have a strategy for these situations based on clinical skills, available devices, urgency of the situation, and potential consultants, if any.

History

In the United States, the care of trauma patients has evolved into specialized, regional trauma centers. However, major trauma can occur anywhere, so all emergency departments must be able to provide initial stabilization of the sick trauma patient. The first priority in stabilization starts with assessment and management of the airway. As recently as the mid-1980s, Advanced Trauma Life Support (ATLS) advocated blind nasotracheal intubation as the preferred method of definitively controlling the airway in trauma patients without contraindications because of concern about cervical spine movement. Currently, the recommended trauma airway management is oral endotracheal intubation with in-line cervical stabilization using rapid sequence induction to optimize intubating conditions.[1] The success rate with this strategy is very high, and the necessity of emergent cricothyrotomy has significantly decreased. In fact, the failure rate of rapid sequence intubation in the emergency department is approximately 1%.[2,3] The debate between direct visualization with standard laryngoscopy and video laryngoscopy is ongoing. Despite the high success rate, there are certain circumstances in the management of trauma patients that may require adjustments to this strategy. These scenarios are reviewed below.

Cervical Spine Injury

A standard principle is that all trauma patients have the potential for a cervical spine injury and should be managed as if one is present until proven otherwise. However, even in Level 1 Trauma Centers, only 4% of patients with major trauma have cervical spine fractures.[4] Clinical decision tools, such as the NEXUS Criteria or the Canadian C-Spine Rules, can be used in selected patients to exclude a clinically relevant cervical spine fracture without

EXECUTIVE SUMMARY

- Plan to Maximize for Initial Success: Position, use manual in-line stabilization, and use video-assisted laryngoscopy.
- Apply apnea oxygen as soon as the decision to intubate is made.
- Have supraglottic airways (LMA or ILMA) available as a rescue method.
- Know that RSI drugs are dosed according to different versions of body weight: total body weight, ideal body weight, or lean body weight.

radiographic imaging. Those who cannot be cleared clinically must remain immobilized until their cervical spine can be cleared with diagnostic imaging and further clinical examination. This immobilization impacts the airway management of these patients. Although suspected or known cervical spine injury affects technique, the indications for intubation remain the same. The Eastern Association for the Surgery of Trauma (EAST) has a practice guideline for emergency tracheal intubation immediately following traumatic injury. The Level 1 EAST recommendations are supported strongly by scientific evidence including randomized trials, and Level 3 recommendations are those supported mostly by expert opinion.[1] (*See Tables 1 and 2.*) Notice there are no Level 2 recommendations, which would be those supported by both reasonable scientific evidence and expert opinion.

The decision to intubate involves more than the ability to oxygenate or ventilate. The potential for abrupt deterioration in clinical status is one of the most difficult aspects of airway management in the trauma patient. In fact, a delay in airway management was associated with a substantial increase in mortality of 10% in one study.[5] These delays are considered one of the most important causes of preventable traumatic deaths in both the prehospital and emergency department setting.[6,7] Once the decision is made to intubate, it is important to recognize that immobilizing the neck increases the difficulty of glottis visualization. In fact, neck mobility is a component of the LEMON mnemonic that predicts difficulties with the airway.[8,9] (*See Tables 3 and 4.*)

The Mallampati Classification is a graded observation that correlates visualization of the posterior pharynx with predicted laryngoscopic view of the glottis.[10] (*See Table 4.*)

Table 1. Level 1 Indications for Endotracheal Intubation

- Airway obstruction
- Hypoventilation
- Persistent hypoxemia ($SaO_2 \leq 90\%$) despite supplemental oxygen
- Glasgow Coma Scale (GCS) ≤ 8
- Severe hemorrhagic shock
- Cardiac arrest

Cormack and Lehane developed an objective grading system to describe the view obtained with laryngoscopy.[11] (*See Table 5.*)

Cervical immobilization will prevent optimal positioning and decrease the laryngoscopic view. Poor visualization of the glottis aperture, Cormack-Lehane grades of III or IV, occurs in 15-25% of trauma patients.[12,13] Optimal alignment of the oropharyngeal-laryngeal axis for laryngoscopy and intubation involves extension of the cervical spine, specifically at the occipito-atlantal and antlanto-axial joints more than the lower portions, so this optimal positioning is not permissible in patients who are immobilized in rigid cervical collars.[5] In fresh cadavers with induced C5-C6 instability, it was shown that chin lift and jaw thrust maneuvers caused significant motion of the C-spine that was not fully mitigated by application of a rigid collar.[5] An alternative to a rigid cervical collar is manual inline stabilization of the cervical spine by one provider while another provider performs airway management. Some degree of cervical spine movement still occurs during intubation with manual stabilization, but the amount is considered to be of no clinical significance in almost all cases if head movements are done carefully to avoid hyperextension. Neurologic deterioration following intubation of patients with cervical spine fractures has been reported, but whether it was related to maneuver of the spine during the procedure or from progression of the initial injury continues to be debated.[5,10] Nonetheless, manual cervical spine stabilization is considered safe and has become standard of care.

When managing the airway, manual in-line cervical immobilization is associated with more successful intubations than keeping the patient in the cervical collar due to improved mouth opening.[14] There is no evidence that nasotracheal intubation is accomplished with any less C-spine movement compared to orotracheal intubation with in-line stabilization.[15] A retrospective study of 133 patients with unstable cervical spine fractures demonstrated it was safe to intubate these patients with in-line immobilization. None of the patients in this study developed neurological deficits using nasotracheal or orotracheal techniques.[16] Previously, suspicion for potential cervical spine fracture was cited as the most frequently reported indication for cricothyrotomy.[17]

Studies have shown that video-assisted laryngoscopy may reduce C-spine movement compared to direct laryngoscopy, but others have shown no significant difference.[18,19] Video-assisted laryngoscopy during manual

Table 2. Level 3 Indications for Endotracheal Intubation

- Facial or neck injury with potential for airway obstruction
- GCS 9-12
- Persistent combativeness refractory to pharmacologic agents
- Respiratory distress
- Preoperative management
- Early ETI is indicated in cervical spinal cord injury (SCI) with any evidence of respiratory insufficiency (complete SCI or incomplete injuries C5 and above)

Table 3. LEMON Mnemonic

L	Look externally (facial trauma, large incisors, large tongue, or facial hair)
E	Evaluate 3-2-2 rule (incisor distance < 3 patient finger breadths, hyoid to mental distance < 3 fingers, thyroid to hyoid distance < 2 fingers)
M	Mallampati score
O	Obstruction
N	Neck mobility

Table 4. Mallampati Classification

Class	Description
1	Full view of tonsils, uvula, and soft palate
2	Visibility of hard and soft palate, upper portion of tonsils and uvula
3	Soft and hard palate and base of uvula are visible
4	Only hard palate is visible

inline stabilization has been shown to obtain better Cormack-Lehane views and lower intubation difficulty scores when compared to direct laryngoscopy.[20] Video laryngoscopes and optical laryngoscopes allow glottis views without the necessity of aligning the oral, pharyngeal, and laryngeal axes. The optical laryngoscopes rely on a combination of lenses and prisms rather than fiberoptics. While the views obtained with these laryngoscopes are better, time to intubation and patient outcomes are not always improved. Further studies are needed to determine the optimal roles of video-assisted laryngoscopy and direct laryngoscopy in the management of the trauma patient.

Facial Fractures

Maxillofacial injuries can make emergent airway management a nightmare in many different ways. Maxillary fractures may obstruct the nasopharynx, and mandibular fractures can allow movement of the mandible and tongue posteriorly, causing obstruction when supine. A litany of loose material, such as teeth, bone, blood, secretions, or foreign bodies, can obstruct the airway.[21] Soft tissue edema, swelling, expanding hematoma, or hemorrhage can cause immediate obstruction, aspiration, or continue to expand, leading to delayed airway obstruction.[22] Emergency providers should complete the trauma assessment before focusing on facial trauma. Initial attention to facial fractures and the cosmetically alarming features due to rapidly expanding edema from the rich blood supply to the face may distract from recognition of more life-threatening systemic injuries.[23]

Immediate need for airway management in patients with facial trauma has been found to be quite rare overall, only 1.7% in retrospective reviews. The LeFort classification system categorizes mid-facial fractures. (*See Table 6.*)

The need for airway management is much increased in LeFort fractures, in which emergent intubation occurred in 34%, with increasing risk of intubation associated with increasing severity of fracture. Urgent intubation rates are also quite high in facial gunshot wounds, up to as many of 70% of cases. These airways pose an even greater challenge due to the tissue loss and disruption of the anatomy.[23,24,25] The mortality in facial gunshot wounds has been found to be very high, with up to 79% dying within 48 hours of admission.[24] Early elective intubation is recommended in facial trauma patients with high likelihood of developing airway compromise, which includes worsening edema, hemorrhage, mandible fractures, or close-range shotgun wounds.

The effectiveness of bag-mask ventilation is greatly impaired in LeFort II and LeFort III fractures due to lack of seal and obstruction of the nares.[21] Endotracheal intubation by direct laryngoscopy is similarly expected to be difficult in maxillofacial trauma due to the disruption of the anatomy and the volume and diversity of material in the oropharynx. If the patient with significant facial injuries requiring intubation is conscious and/or breathing on his or her own, then this should be preserved.

These patients should undergo awake intubation (described below) rather than RSI, as their respiratory effort may be pivotal in maintaining airway patency and, if inhibited, may lead to an unable to ventilate, unable to intubate scenario. It is often necessary to clear the airway of debris with Magill forceps and suctioning and to achieve hemorrhage

Table 5. Cormack-Lehane Grade

Grade	Description
I	Full view of entire glottis aperture
II	Partial glottis view
III	Epiglottis only
IV	Inability to visualize epiglottis

Table 6. LeFort Classification Scheme

Type	Description
LeFort I	Horizontal fracture of the maxilla inferior to the nose
LeFort II	Larger portion of maxilla from nasal bones to premolar region
LeFort III	Total disarticulation of the mid-face; craniofacial disjunction

control with pressure, gauze, nasal packing, or other commercially available nasal epistatic devices before intubation should be attempted.[23] Any nasal packing would interfere with apneic oxygenation if that technique is being used.

Apneic oxygenation is the use of a nasal cannula at 15 L/hr as soon as the decision to intubate is reached, which is in addition to the facemask or BVM used in the pre-oxygenation phase. This high-flow nasal cannula remains in place throughout airway management until the endotracheal tube is secured. This technique serves to continue flushing the nasopharynx with oxygen throughout the procedure and significantly reduces the incidence of oxygen desaturation.[26]

Facial trauma, neck trauma, airway edema, and blood in the airway have been found to be statistically significant predictors of difficult airway in both prehospital and emergency department intubations.[27,28] The use of oropharyngeal airways (OPA) or nasopharyngeal airways (NPA) has been debated in the literature and may be harmful or even unsafe in facial trauma. OPA is often poorly tolerated by trauma patients, as they can stimulate the gag reflex causing vomiting, or if improperly inserted, may force the tongue backward.[29] NPA can cause epistaxis and is contraindicated in midface injuries or basilar skull fractures. There are several case reports of intracranial insertion of NPA, with patients doing poorly, although not definitively caused by the NPA. If an NPA is found to terminate intracranially, it should be left in place and removed with direct visualization to optimize control of hemorrhage and to repair the dura.[30,31]

Fiberoptic bronchoscope is a recommended method in anticipated difficult-to-intubate trauma patients, but facial injuries may pose unique risks due to the likelihood of foreign material encountered and bleeding. Also, an awake fiberoptic bronchoscopy requires a cooperative patient and may not be possible in many community settings. Similarly, video-assisted laryngoscopy may be difficult due to foreign material, but it may prove useful when compared to direct laryngoscopy when there is soft tissue swelling of the tongue or difficulty visualizing the epiglottis, especially while immobilizing the neck. It is recommended that direct laryngoscopy be reserved for patients who have maintained their neck surface anatomy and, if undertaken, a surgical airway setup also should be ready if intubation fails.[22]

A secondary option for intubation that has been found helpful in maxillofacial trauma or other difficult airways is retrograde intubation. The stepwise nature of the procedure also allows for mask ventilation to occur in between steps. This procedure may take a relatively long time to accomplish, (up to 4 minutes), but in trained individuals has been shown in case studies to be successfully combined with laryngeal mask airway (LMA) to establish a definitive airway.[15,23,32] Supraglottic airways such as the LMA or intubating laryngeal mask airway (ILMA) are recommended as rescue airways in patients with facial trauma, but placement may be difficult due to limited space in the mouth. These would likely serve as a bridge to a tracheostomy, which is often the most ideal airway in these patients.

Although 80-100% of patients with facial trauma who require airway management may initially undergo successful endotracheal intubation, 30-41% are converted to tracheostomy during either the immediate operative repair of their injuries or before discharge from the hospital.[24,25,33]

Blunt Airway Trauma

The most important blunt neck injury from an airway perspective is injury to the respiratory tract, often described broadly in the term laryngotracheobronchial injuries, which includes some concomitant chest injuries. It is estimated that 30-80% of patients who suffer laryngotracheobronchial injuries die at the scene, so the true incidence is unknown but is estimated at 2% of all patients with chest and neck injuries.[34] It is further stratified with 3-6% of neck injuries having tracheal injuries. It should be noted that penetrating injuries are 10 times more likely to have associated airway injury than blunt trauma, 4.5% vs 0.4%.[34]

Motor vehicle collision (MVC) is the most common cause of blunt neck trauma in the United States and likely worldwide, but other causes include hanging, strangulation, chokehold, and clothesline-type injuries.[35,36] The basic mechanisms of airway injury are from the shearing forces of acceleration and deceleration or from direct trauma against a fixed object.[35]

Blunt trauma also causes neck hyperextension, which can lead to vascular stretching over the C-spine, laryngotracheal tears, fractures, or, most devastatingly, a complete separation. There are

Figure 1. Zones of the Neck

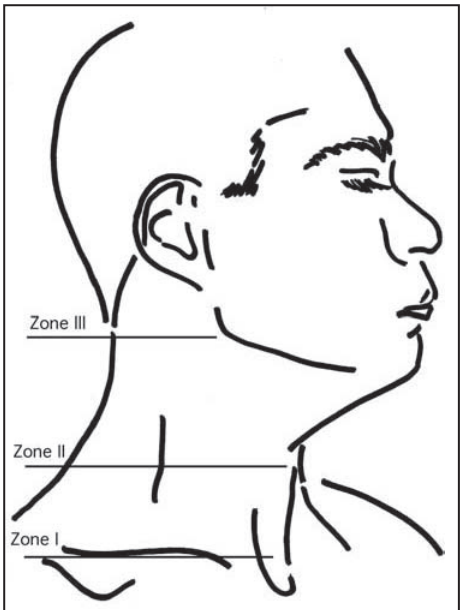

Illustration courtesy of Marcus Eubanks, MD. Reprinted from Hanlon D, et al. *Trauma Rep* 2006;7:4.

several direct mechanisms of injury, such as: steering wheel or dashboard collision damaging the thyroid and cricoid cartilages; the trachea and esophagus being violently compressed against the cervical spine; or an improperly fitting seat belt causing intratracheal pressure against a closed glottis. The combination of both hyperextension and direct trauma is called the "padded dashboard syndrome."[34]

Vascular structures are also subject to the mechanisms mentioned, resulting in intimal tears in the vessel wall. Depending on the severity, this can lead to a gamut of injuries ranging from pseudoaneurysm, dissection, fistula, thrombus formation, or even complete transection. Patients with these vascular injuries may manifest stroke symptoms at initial presentation or in delayed fashion.

Some atypical mechanisms of injury include chokeholds and hanging. Chokehold injuries tend to result in vascular trauma by either carotid occlusion or carotid body injuries, whereas hanging usually leads to death by strangulation once jugular occlusion causes loss of consciousness.[34]

Clinical signs of tracheobronchial injury with neck trauma include: crepitus in up to 87% of patients, hoarseness, dysphonia or aphonia, hemoptysis, air escape out of the neck, visible or palpable disruption of laryngotracheal anatomy, airway obstruction, shock, respiratory distress, or Hamman's sign, a crunching sound synchronous with the heartbeat.[34,35,36] These signs are important to recognize, as they can indicate a respiratory system that will worsen or destabilize with positive pressure ventilation.

Blunt neck trauma initially may present with an unremarkable exam, with gradual airway compromise over hours secondary to expanding hematoma, edema, or occult fracture of the larynx. It is recommended that all patients with blunt neck trauma with a normal exam undergo a period of observation and frequent re-examination. This likely exceeds the capabilities of a community hospital because, if any of these complications develop, the patient will need emergent endoscopic exam of the airway and possibly surgical intervention.[36]

Airway management in patients with airway injury from blunt trauma may be quite difficult, as the upper airway may be distorted or completely obstructed by the injury. Blind intubation, whether nasotracheal or via ILMA, is highly discouraged as it may worsen the injury or create a false track. Blind insertion of extraglottic devices may have the same fate.

Although not always possible, it is recommended that intubation be undertaken only after the airway has been completely examined by flexible fiberoptic bronchoscopy and found to have either intact anatomy or only partial separation or avulsion.[34] Furthermore, the patient's respiratory effort may be critical in maintaining the open airway, and once paralyzed with loss of the smooth muscle tone, there may be further distortion of the anatomy or even complete collapse. For these reasons, flexible fiberoptic bronchoscopy is the procedure of choice to locate the tracheobronchial injury and successfully ensure the endotracheal (ET) tube's cuff is inflated beyond the injury.

Sometimes the injury may extend distally enough to necessitate single lung ventilation. If the ET tube is inflated proximal to the injury, such as an undiagnosed carinal injury, positive pressure will likely cause air leak outside of the respiratory tract. This will immediately lead to tension-type physiology with ventilatory compromise and pending arrest. In patients with signs of laryngotracheobronchial injuries as outlined above, intubation should be deferred if possible until arrival at a trauma center with the capabilities for complete visual inspection of the airway, unless the clinical scenario dictates otherwise.[34,36] In cases of complete laryngeal fracture, the patient will almost certainly require tracheostomy. In this subset, the procedure is ideally performed on an awake patient under local anesthesia so that the patient's respiratory drive and smooth muscle tone assist in maintaining a patent airway until the tracheostomy is secured.[37]

If laryngotracheobronchial injury is not suspected but early airway management is indicated, orotracheal intubation with manual inline mobilization is recommended. Intubation with direct laryngoscopy, video-assisted laryngoscopy, or bronchoscopy (if available) all have strengths and drawbacks in the diverse setting of neck trauma, and the provider must be familiar with several modalities, as none have been found to be 100% successful in securing the airway in this difficult population.[35]

Penetrating Neck Injuries

Traditionally, penetrating neck injuries have been managed according to the zones of the neck. Zone I is the area between the sternal notch and the cricoid membrane. Zone II extends from the cricoid membrane to the angle of the jaw, and Zone III is between the angle of the jaw and the base of the skull. (*See Figure 1.*)

While the overall management may change with the involved zone, the principles of airway management do not. In fact, with the advent of multislice computed tomography angiography (MCTA) as a diagnostic tool, the importance of the zones may disappear, as this study may be effective as a single investigative test.[38]

The initial management of a patient with penetrating neck trauma is similar

Table 7. Hard Signs of Arterial Injury in Neck Trauma

- Pulsatile bleeding
- Expanding hematoma
- Palpable thrill
- Bruit
- Cerebral ischemia

Table 8. Symptoms and Signs of Inhalation Injury

- Singed nasal hairs
- Pharyngeal erythema
- Carbonaceous sputum
- Hoarseness
- Drooling
- Dysphagia
- Stridor

to any potential major trauma patient. With these patients, airway compromise and excessive bleeding are the major concerns. Due to rapid bleeding, the airway may deteriorate precipitously. This type of hemorrhage should be anticipated if the hard signs of vascular injury are present. (*See Table 7.*)

There is not a universal agreement for either the timing or indication for active airway management or even the optimal technique. Approximately 10% of these patients will present with either partial or complete airway obstruction.[39] Anticipating or recognizing this airway compromise is essential. Early intubation has been recommended to avoid the airway that has been even further distorted.

Orotracheal intubation using a rapid sequence induction technique is the method of choice in the majority of patients with penetrating neck trauma. There have been concerns that using RSI in these patients may lead to greater anatomical distortion of the airway due to loss of muscle tone and increased bleeding from a previously tamponaded wound. These changes may lead to a failed airway. In addition, there are concerns of converting a partial laryngotracheal injury into a complete transection.[40]

Due to these potential complications, awake intubation is often recommended. Despite these concerns, three cases of failed awake fiberoptic intubation were successfully intubated using an RSI technique in one retrospective study.[40] Awake fiberoptic intubation is considered the safest technique in cooperative patients with suspected airway injury at some trauma centers; however, this technique is time consuming, not readily available in community settings, and may be difficult if the airway is bloody.[41]

Other options for airway management also must be considered. Direct intubation into the distal segment of an injured airway through the wound may be possible depending on the characteristics of the wound. The trachea is stabilized with either a hemostat, tracheal hook, or towel clip, and the endotracheal tube is placed directly into the distal segment. In some cases, a gum elastic bougie has facilitated the direct placement of an endotracheal tube.[42] Cricothyrotomy may be used as a rescue method if the injury is above the level of the cricothyroid membrane. Finally, in some cases, surgical colleagues will need to perform a tracheostomy. The method of stabilizing the airway will depend upon the skills of the providers available.

Burns

Thermal burns are the third leading cause of accidental death worldwide.[43] Extremes of age, increased total body surface area (TBSA) involved, and inhalational injury are correlated with increased mortality in most studies.[44,45] The management of burn patients can be a tremendous challenge for even the most experienced physicians. The well-known mantra of the ABCs (airway, breathing, circulation) dictates priorities. Airway evaluation and management is the initial priority. The traditional dogma has been to consider early intubation in patients with severe burns before the anatomy gets progressively altered. Any burn patient from an enclosed space needs to be assessed for inhalation injury. The signs of inhalation injury are listed in Table 8.

These signs are helpful but not fully predictive, and clinical judgment is recommended.[46] Notably, the absence of these markers cannot reliably exclude the presence of supraglottic and laryngeal edema.[47] Acute airway obstruction occurs in up to one-third of patients hospitalized with inhalation injuries and is secondary to chemical and thermal supraglottic injuries.[46] Upper airway edema peaks at 24 hours and usually resolves within the first week, but this edema can progress more rapidly, leading to acute airway obstruction.[46, 48]

Endotracheal intubation is a Level 1 recommendation by the Eastern Association for the Surgery of Trauma practice management guideline for patients with smoke inhalation,[1] specifically, any such patients with airway obstruction or impending obstruction, severe altered mental status (Glasgow Coma Scale < 8), adults with cutaneous burns greater than 40% body surface area, or prolonged transport time to definitive care.[1] In children, intubation may be necessary for patients younger than the 3 years of age if there are burns more than 20% TBSA.[49]

The three main indications for intubation in patients with airway burns are

decreased mental status, upper airway obstruction, or respiratory failure. The causes may stem directly from inhalation injury or edema for pulmonary indications, to carbon monoxide or drug or alcohol intoxication depressing the mental status.[46] In addition, cutaneous thermal injuries cause a generalized edema that will affect the airway, hence the recommendation for intubation in patients with extensive burns. While the presence of inhalation injury cannot be predicted strictly by the presence of cutaneous burns, larger burns are also increasingly associated with smoke inhalation and airway damage.[43]

Not all inhalation burns require intubation; however, these patients require close monitoring. Some specialists recommend awake endoscopic examination to evaluate these patients.[49] There is a grading system for laryngoscopic findings that is beyond the scope of emergency medicine. A small retrospective study of patients with inhalational injury and facial burns found that more than 70% of patients with findings that met indications for intubation did not actually require intubation throughout their clinical course.[50] Their findings suggest that clinical judgment may be superior to the traditional indications for intubation; however, these findings from a small retrospective study must be interpreted with caution. In the United States, failure to manage the airway remains the major risk of litigation for emergency physicians in the management of burn patients.

A low threshold for intubation should be maintained, especially in pediatric patients who have a narrower airway that is less tolerant of edema.[43] It is also recommended to prophylactically intubate any patient being transferred to a burn center who will require long transport, as patients may rapidly deteriorate and need emergent surgical intervention if the airway is not secure.[46] Although early or prophylactic intubation is generally advisable, there is controversy as to the ideal technique. Due to the edema and altered anatomy, there will be challenges to both bag-mask ventilation and the actual procedure of intubation. Ideally, if intubation is performed early, there will be minimal changes to the upper airway anatomy, and intubation can be undertaken with the standard rapid sequence technique that is the cornerstone of emergency airway management. Local practices may vary. In China, emergent tracheotomy is the preferred method of airway management, and this procedure was performed in 37% of all patients with inhalational injury.[51]

If there is edema or other altered anatomy, then airway management becomes truly difficult. In addition, local burns may compromise mouth opening due to decreased skin elasticity. The approach must be well planned. Options for airway management include an awake intubation, standard RSI, fiberoptic bronchoscopic intubation, or surgical airway. Most emergency medicine practitioners will not have the option of fiberoptic bronchoscopy in their practice setting.

Preoxygenation should be undertaken as soon as the decision to intubate is reached, with a plan for apneic oxygenation during the procedure if using paralytics.[26] Rescue supraglottic devices and a cricothyrotomy kit should be immediately available. An awake laryngoscopy with topical anesthesia and sedation can be used when anticipating a difficult airway. Ketamine is an ideal sedative for this situation, as it provides a strong analgesic effect without suppressing respirations. With this strategy, the patient can be intubated, if possible, or the technique can be converted to an RSI if the initial, awake assessment shows visualization of the vocal cords to optimize the procedure. Succinylcholine has the most rapid onset of the paralytics, and it is safe in acutely burned patients. If unsuccessful, then an open cricothyrotomy will be needed. An open technique is preferred to the percutaneous Seldinger technique due to the anatomical changes in burn patients.

If the patient is uncooperative or acutely deteriorating, an RSI approach will be needed. Prolonged, repeated attempts at intubation must be avoided, and the decision to proceed to an open cricothyrotomy must be made rapidly under these circumstances. Orotracheal intubation simply may be impossible due to edema.[49] If the patient desaturates and bag-valve mask is unsuccessful, a supraglottic device can be placed to restore adequate oxygenation while establishing a definitive airway whether using bronchoscopy or a surgical airway.

Once an airway has been placed, the tube must be secured. Adhesive tape does not work with a burned face and neck, so the tube must be secured with a commercial tube holder, cotton tape, umbilical tape, or even IV tubing.[49] The security of the airway must be rechecked any time the patient is moved or transported.

Ventilation management should include the low tidal volumes (6 mL/kg) and low plateau pressures to attempt to prevent barometric lung trauma and acute lung injury (ALI). Chest wall burns may require escharotomy if they interfere with ventilation. Carbon monoxide poisoning is suspected in any burned patient with loss of consciousness or who was exposed to smoke in an enclosed space. Carboxyhemoglobin levels should be checked. Oxygen 100% is the initial treatment, with consideration of hyperbaric oxygen treatment at the tertiary care center. Any burn patient with persistent lactic acidosis despite adequate fluid resuscitation must be suspected of cyanide poisoning. The preferred treatment for cyanide toxicity is with hydroxocobalamin. Steroids and prophylactic antibiotics have no role in the management of inhalation injuries.[47]

In summary, the management of the severe burn victim includes aggressive airway management, gentle mechanical ventilation, appropriate fluid resuscitation, evaluation for associated toxins (i.e., carbon monoxide, cyanide), and burn center transfer.[49]

The Obese Trauma Patient

Thirty percent of the U.S. adult population is obese, and this percentage seems to be increasing.[52] The incidence of trauma remains significant. With the preponderance of both conditions, it is not surprising that the emergency medicine provider will manage the obese trauma patient. These patients are challenging in many ways because of the anatomic and physiologic changes due to obesity. Many obese patients have multiple medical comorbidities. In addition, obesity adversely affects bag-mask ventilation, intubation, medication doses, and the time to

Table 9. Induction and Paralytic Agents Used in Airway Management

Medication	Dose (IV)	Weight	BP Effect	Comments
Etomidate	0.3 mg/kg	TBW	Neutral	Lipophilic
Ketamine	1–2 mg/kg	LBW	Increase	Respiratory drive and upper airway reflexes are preserved.
Propofol	1–2 mg/kg	IBW	Decrease	Lipophilic but recommended to use IBW due to hypotensive effect.
Fentanyl	1-4 mcg/kg; 15-30 mcg/kg	TBW	Neutral	Some recommend LBW due to individual variability. Larger dose is when using as sole induction agent.
Midazolam	0.3 mg/kg	TBW	Decrease	Subsequent doses on IBW, as half-life is increased in obesity.
Succinylcholine	1 mg/kg	TBW	Neutral	Inadequate paralysis if IBW
Rocuronium	0.6 mg/kg	IBW	Neutral	Hydrophilic
Vecuronium	0.15 mg/kg	IBW	Neutral	Hydrophilic
TBW = Total Body Weight, IBW = Ideal Body Weight, LBW = Lean Body Weight[50,58]				

oxygen desaturation.[52]

Obesity affects the airway anatomy with redundant tissue. In addition, obesity causes multiple changes to the respiratory system. These changes are at least partly responsible for the increased mortality in critically ill obese patients.[52] Decreased chest wall compliance and increased abdominal pressure produce a decrease in vital capacity and total lung capacity.[52] The collapse of small airways produces decreased ventilation in the lung bases, causing a ventilation-perfusion mismatch.[53] Functional residual capacity declines as body mass index (BMI) increases. Obese patients have a higher incidence of hypoxemia and hypercapnia, even in the absence of underlying lung disease.[54]

The sum of these changes make the obese patient much more likely to rapidly desaturate during apnea. Benumof et al calculated the time to desaturation below 90% among patients after the administration of succinylcholine. Healthy adults took 8 minutes, moderately ill patients took 5 minutes, and obese patients desaturated in only 2.7 minutes.[26] Although obese patients have increased intraabdominal pressure, gastroesophageal reflux, and an increased incidence of hiatal hernias, there is debate if obesity alone increases the risk of aspiration.[55]

Surprisingly, obesity may not always predict a difficult intubation, but it does consistently produce difficult bag-mask ventilation.[52] With the tendency to rapidly desaturate, the importance of adequate bag-mask is essential. The two-person technique is used to try optimize ventilation with a two-handed jaw thrust, nasal airway, and a properly sized mask. Unfortunately, the favored ramped position using a shoulder roll to facilitate neck extension is not possible unless the cervical spine has already been cleared, but reverse Trendelenberg is possible, although not well studied. As mentioned, there is some controversy about whether obesity alone predicts a difficult intubation. With the positioning restrictions in the trauma patient, it is intuitive to think that the obese trauma patient would be a difficult intubation. At least one study on these patients does not confirm this suspicion.[56]

The indications for airway management in the obese trauma patient are the same as for other trauma patients; however, the decision on how to manage the airway may proceed more cautiously. These patients consistently desaturate more rapidly and are difficult to bag-mask ventilate, so intubation must be efficient and rapid even if the intubation itself is not necessarily more difficult. Preparation and preparedness for the nuances of the obese patient are essential.

Preoxygenation is standard, but it may not be as beneficial as anticipated, especially in critically ill patients.[57] Incorporating continuous positive airway pressure at 10 cm H_20 increased the duration of non-hypoxia by one minute in obese patients undergoing elective surgery, but it has not been studied in obese trauma patients.[58] Continued oxygenation (apneic oxygenation) with high-flow nasal cannula should be continued throughout the procedure. Ramachandran et al performed a randomized, controlled trial of obese patients who required intubation for surgery. The apneic oxygenation group received 5 L/minute of oxygen during their apneic period, and these patients maintained their oxygen saturation above 95% for 5.29 minutes compared with 3.49 minutes in the control group.[59]

The scarcity of published studies prevents an evidence-based approach to induction and paralytic agents in the obese trauma patient.[52] The dosing must consider increased renal blood flow and clearance and the increased volume of distribution for lipophilic medications.[60] Lipophilic drugs are usually given based on total or actual body weight, while hydrophilic drugs are given based on ideal weight. To further complicate matters, some medications, such as ketamine, are based on lean body weight, which is estimated to be 120% of ideal body weight. Caution in dosing is advised due to individual patient variability, and vigilant monitoring is necessary.[52,60] (*See Table 9.*)

With the tenuous combination of potentially ineffective bag-mask ventilation and the tendency of the obese patient to desaturate, early use of a supraglottic device, such as a laryngeal mask airway in case of a failed intubation or ineffective ventilation, may be required. This equipment must be readily available. In trauma patients, the benefits of optimal positioning cannot be used, as the cervical spine must remain immobilized. The critical decision is whether to perform a standard RSI intubation strategy, an awake intubation, or some other advanced airway technique.

An awake strategy requires a cooperative patient, and the upper airway must be anesthetized with either atomized or nebulized lidocaine. Sedation may be used as well. The fiberoptic bronchoscope, video laryngoscope, or direct laryngoscope can be obscured by blood, secretions, and redundant upper airway tissue. If the patient cannot cooperate or the procedure is unsuccessful, then an RSI technique can be used. If the patient has desaturated, then a supraglottic rescue device can be employed. A tracheal tube introducer (gum elastic bougie) can be used when only a restricted view of the glottis aperature can be obtained. The endotracheal tube can then be placed over the bougie. Video-assisted laryngoscopy has been shown to obtain a Cormack-Lehane grade I or II in more than 93% of patients with BMI greater than 40 kg/m^2 undergoing general anesthesia.[61]

Cricothyrotomy can be used if unable to intubate and unable to ventilate. This procedure should be done open if being performed in the obese patient. It is more difficult due to the obscuration of landmarks. After placement of an airway, whether orally or surgical, the endotracheal tube must be confirmed with capnography. Clinical findings of successful tube placement are even less reliable in obese patients.[52]

Tidal volume for mechanical ventilation should be based on ideal body weight. The addition of positive end expiratory pressure improves ventilation and prevent atelectasis. Reverse Trendelenburg prevents abdominal pressure from limiting the excursion of the diaphragm.[62] These obese trauma patients require a well thought out strategy from initial management to intubation and mechanical ventilation.

Conclusion

Each of these difficult scenarios requires appropriate preparation and planning. The nuances of each situation must be thoroughly considered, and the expected clinical course must be anticipated. It must be determined whether there is going to be a difficult bag-mask ventilation, difficult laryngoscopy, difficult intubation, or all of the above. In addition to the initial airway management plan, a backup plan must be considered and equipment must be readily available.

Appropriate preoxygenation is essential for any airway attempt, and apneic oxygenation should be used during rapid sequence intubation. A rescue strategy must be planned as well, especially in those patients in whom bag-valve mask is ineffective or difficult. Surgical cricothyrotomy is used when intubation strategies are not successful. Although generally reserved for use after several failed intubation attempts, cricothyrotomy should not be delayed unnecessarily. This surgical technique should be employed while the patient is still very salvageable.

References

1. Mayglothing J, et al. Emergency tracheal intubation immediately following traumatic injury: An Eastern Association for the Surgery of Trauma practice management guideline. *J Trauma Acute Care Surg* 2012;73:S333-S340.
2. Bair AE, et al. Failed intubation in the emergency department: Analysis of prevalence, rescue techniques, and personnel. *J Emerg Med* 2002;23:131–140.
3. Tayal VS, et al. Rapid-sequence intubation at an emergency medicine residency: Success rate and adverse events during a two-year period. *Acad Emerg Med* 1999;6:31–37.
4. Grossman MD, et al. National survey of the incidence of cervical spine injury and approach to cervical spine clearance in U.S. trauma centers. *J Trauma* 1999;47:684-690.
5. Miraflor E, et al. Timing is everything: Delayed intubation is associated with increased mortality in initially stable trauma patients. *J Surg Res* 2011;170: 117-121.
6. Esposito TJ, et al. Analysis of preventable deaths and inappropriate trauma care in a rural state. *J Trauma* 1995;39:955-962.
7. Teixeira PGR, et al. Preventable or potentially preventable mortality at a mature trauma center. *J Trauma* 2007;63: 1638-1650.
8. Kortbeek JB, et al. Advanced trauma life support, 8th edition, the evidence of change. *J Trauma* 2008;64:1638-1650.
9. Reed MJ, et al. Can an airway assessment score predict difficulty at intubation in the emergency department? *Emerg Med J* 2005;22:99-102.
10. Lee A, et al. A systematic review (meta-analysis) of the accuracy of the Mallampati tests to predict the difficult airway. *Anesth Analg* 2006;102:1867-1878.
11. Cormack RS, Lehane J. Difficult tracheal intubation in obstetrics. 1984;39: 1105-1111.
12. Vissers RJ, Gibbs MA. The high risk airway. *Emerg Med Clin N Am* 2010;28: 203-217.
13. Graham CA, Beard D, et al. Rapid sequence intubation of trauma patients in Scotland. *J Trauma* 2004;56:1105- 1111.
14. Aoi Y, et al. Airway scope laryngoscopy under manual inline stabilization and cervical collar immobilization: A crossover in vivo cinefluoroscopic study. *J Trauma* 2011;71:32-36.
15. Langeron O, et al. Airway management in trauma. *Minerva Anestesiol* 2009;75: 307-311.
16. Holley J, Jorden R. Airway management in patients with unstable cervical spine fractures. *Ann Emerg Med* 1989;18:1237–1239.
17. Chang RS, et al. Declining rate of cricothyrotomy in trauma patients with an emergency medicine residency: Implications for skills training. *Acad Emerg Med* 1998;5:247-251.
18. Kanwar R, et al. Emergency department evaluation and treatment of cervical spine injuries. *Emerg Med Clin North Am* 2015;33:241-282.
19. Aoi Y, et al. Airway scope versus Macintosh laryngoscope in patients with simulated limitation of neck movements. *J Trauma* 2010;69:838–842.
20. Aziz M. Use of video-assisted intubation devices in the management of patients with trauma. *Anesthesiol Clin* 2013;31: 157-166.
21. McRae M, Frodel J. Midface fractures. *Facial Plast Surg* 2000;16:107–113.
22. Barak M, et al. Airway management of the patient with maxillofacial trauma: Review of the literature and suggested clinical approach. *Biomed Res Int* 2015;2015: 724-732.

23. Kellman RM, Losquadro WD. Comprehensive airway management of patients with maxillofacial trauma. *Craniomaxillofac Trauma Reconstr* 2008;1:39-47.

24. Shackford SR, et al. Gunshot wounds and blast injuries to the face are associated with significant morbidity and mortality: Results of an 11-year multi-institutional study of 720 patients. *J Trauma Acute Care Surg* 2014;76:347-352.

25. Norris O, et al. Maxillofacial gunshot injuries at an urban Level I Trauma Center — 10-year analysis. *J Oral Maxillofac Surg* 2015;73:1532-1539.

26. Weingart SD, Levitan RM. Preoxygenation and prevention of desaturation during emergency airway management. *Ann Emerg Med* 2012;59:165-175.

27. Gaither JB, et al. Prevalence of difficult airway predictors in cases of failed prehospital endotracheal intubation. *J Emerg Med* 2014;47:294-300.

28. Mosier JM, et al. Difficult airway management in the emergency department: GlideScope video laryngoscopy compared to direct laryngoscopy. *J Emerg Med* 2012;42:629-634.

29. Perry M, Morris C. Advanced trauma life support (ATLS) and facial trauma: can one size fit all? Part 2: ATLS, maxillofacial injuries and airway management dilemmas. *Int J Oral Maxillofac Surg* 2008;37: 309-320.

30. Ellis DY, et al. Intracranial placement of nasopharyngeal airways: Is it all that rare? *Emerg Med J* 2006;23:661.

31. Martin JE, et al. Intracranial insertion of a nasopharyngeal airway in a patient with craniofacial trauma. *Mil Med* 2004;169:496-497.

32. Miner JR, et al. Retrograde intubation with an extraglottic device in place. *J Emerg Med* 2015.

33. Cogbill TH, et al. Management of maxillofacial injuries with severe oronasal hemorrhage: A multicenter perspective. *J Trauma* 2008;65:994-999.

34. Prokakis C, et al. Airway trauma: A review on epidemiology, mechanisms of injury, diagnosis and treatment. *J Cardiothorac* Surg 2014;9:117-125.

35. Rathlev NK, et al. Evaluation and management of neck trauma. *Emerg Med Clin North Am* 2007;25:679-694.

36. Schaefer SD. Management of acute blunt and penetrating external laryngeal trauma. *Laryngoscope* 2014;124:233-244.

37. Verschueren DS, et al. Management of laryngo-tracheal injuries associated with craniomaxillofacial trauma. *J Oral Maxillofac Surg* 2006;64:203-214.

38. Inaba K, et al. Prospective evaluation of screening multislice helical computed tomographic angiography in the initial evaluation of penetrating neck injuries. *J Trauma* 2006;61:144-149.

39. Craducci B, et al. Penetrating neck trauma: Consensus and controversies. *Ann Emerg Med* 1986;15:208-215.

40. Mandavia DP, et al. Emergency airway management in penetrating neck injury. *Ann Emerg Med* 2000;35:221-225.

41. Desjardins G, Varon AJ. Airway management for penetrating neck injuries: The Miami experience. *Resuscitation* 2001;48:71-75.

42. Steinfeldt J, et al. Use of gum elastic bougie in a zone II penetrating neck trauma: A case report. *J Emerg Med* 2003;24: 267-270.

43. McClure J, Moore EC. Burns and inhalational injury. *Anesthesia and Intensive Care Med* 2011;12:393-398.

44. Moore EC, et al. The burns evaluation and mortality study (BEAMS): Predicting deaths in Australian and New Zealand burn patients admitted to intensive care with burns. *J Trauma Acute Care Surg* 2013;75:298-303.

45. Ryan CM, et al. Objective estimates of the probability of death from burn injuries. *N Engl J Med* 1998;338:362-366.

46. Cochran A. Inhalation injury and endotracheal intubation. *J Burn Care Res* 2009;30:190-191.

47. Darling G, et al. Pulmonary complications in inhalation injuries associated with cutaneous burn. *J Trauma* 1996;40:83-89.

48. Bourdeaux C, Manara A. Burns and smoke inhalation. *Anesthesia and Intensive Care Med* 2008;9:404-408.

49. Cancio LC. Airway management and smoke inhalation injury in the burn patient. *Clin Plast Surg* 2009;36:555-567.

50. Benaron D, et al. The FLAMBE (factors leading to airway management in burn emergencies). *Ann Emerg Med* 2015;66:S37-S38(a).

51. Fang-Gang N, et al. Laryngeal morphologic changes and epidemiology in patients with inhalation injury: A retrospective study. *Burns* 2015;41:1340-1346.

52. Dargin J, Medzon R. Emergency department management of the airway in obese adults. *Ann Emerg Med* 2010;56:95-104.

53. El-Solh A, et al. Morbid obesity in the medical ICU. *Chest* 2001;120:1989-1997.

54. Sahembjami H, Gartside PS. Pulmonary function in obese patients with a normal FEV1/FVC ratio. *Chest* 1996;110: 1425-1429.

55. Pieracci FM, et al. Critical care of the bariatric patient. *Crit Care Med* 2006;34:1796-1804.

56. Sifri ZC, et al. The impact of obesity on the outcome of emergency intubation in trauma patients. *J Trauma* 2008;65: 396-400.

57. Mort TC. Preoxygenation in critically ill patients requiring emergency tracheal intubation. *Crit Care Med* 2005;33:2672-2675.

58. El-Khatib MF, et al. Noninvasive bilevel positive airway pressure for preoxygenation of the critically ill morbidly obese patient. *Can J Anaesth* 2007;54:744-747.

59. Ramachandran SK, et al. Apneic preoxygenation during prolonged laryngoscopy in obese patients: A randomized, controlled trial of nasal oxygen administration. *J Clin Anesth* 2010;22:164-168.

60. Ogunnaike BO, et al. Anesthetic considerations for bariatric surgery. *Anesth Analg* 2002;95:1793-1805.

61. Cooper RM, et al. Early clinical experience with a new video laryngoscope in 728 patients. *Can J Anaesth* 2005;52:191-198.

62. Perilli V, et al. The effects of the reverse Trendelenburg position on respiratory mechanics and blood gases in morbidly obese patients during bariatric sugery. *Anesth Analg* 2000;91:1520-1525.

CME/CE Questions

1. Which of the following facial injuries (in isolation) is most likely to require emergent intubation?
   A. Nasal fracture
   B. Mandibular fracture
   C. Facial gunshot wound
   D. LeFort fracture

2. What is the most preferred intubation technique in a patient with suspected tracheobronchial injury?
   A. Rapid sequence orotracheal intubation with manual inline stabilization
   B. Rigid bronchoscopic intubation
   C. Blind nasotracheal intubation
   D. Fiberoptic bronchoscopic intubation after complete endoscopic exam of airway

3. When does airway edema peak after an acute burn injury?
   A. 4 hours
   B. 12 hours
   C. 24 hours
   D. 48 hours

4. Which of the following medications is considered unsafe for use when

intubating patients with acute burn injury?
A. Ketamine
B. Rocuronium
C. Etomidate
D. Succinylcholine
E. All are considered safe for use in patients with acute burn injury.

5. With known unstable cervical spine fractures, which of the following is recommended for airway management?
A. Blind nasal intubation
B. Orotracheal intubation with patient wearing a cervical collar using RSI
C. Orotracheal intubation with patient undergoing manual inline stabilization using RSI
D. Immediate cricothyrotomy
E. Video laryngoscopy only

6. Which of the following is an advantage of video laryngoscopy over direct laryngoscopy ?
A. More rapid intubation in all cases
B. A better view of the glottis aperture in most cases
C. No need for medications
D. A distinct advantage if excessive blood and secretions are present
E. An equal number of subsequent surgical airways

7. Which of the following is most correct in regard to airway management in the obese trauma patient?
A. Difficult bag mask ventilation; easy intubation; unchanged ventilation
B. Unchanged bag mask ventilation; inconsistent intubation; difficult ventilation
C. Difficult bag mask ventilation; inconsistent intubation; difficult ventilation
D. Easy bag mask ventilation; easy intubation; unchanged ventilation
E. Difficult bag mask ventilation; easy intubation; difficult ventilation

8. Which is the recommended technique to use when performing a cricothyrotomy in the obese trauma patient?
A. A horizontal skin incision using an open technique
B. A percutaneous Seldinger technique
C. A vertical skin incision using an open technique
D. A Rapid 4 Step technique

9. Which medication should be dosed on total or actual body weight in the obese patient?
A. Ketamine
B. Rocuronium
C. Vecuronium
D. Succinylcholine

10. The attempted visualization of the vocal cords in trauma patients only provides a Cormack-Lehane grade III or IV view what percentage of the time?
A. 15-25%
B. 26-50%
C. 51-75%
D. < 76% of cases

EMERGENCY MEDICINE REPORTS

CME/CE Objectives

Upon completion of this educational activity, participants should be able to:

- recognize specific conditions in patients presenting to the emergency department;
- apply state-of-the-art diagnostic and therapeutic techniques to patients with the particular medical problems discussed in the publication;
- discuss the differential diagnosis of the particular medical problems discussed in the publication;
- explain both the likely and rare complications that may be associated with the particular medical problems discussed in the publication.

Correction

In the Jan. 15, 2016 issue, a sentence on page 15 should say: "Direct stimulation of ADH secretion by MDMA and its metabolites results in dilutional hyponatremia; excess water intake to counter hyperthermia is common in MDMA and is likely a contributing factor.

CME/CE INSTRUCTIONS

To earn credit for this activity, please follow these instructions:

1. Read and study the activity, using the references for further research.
2. Scan the QR code at right or log onto www.AHCMedia.com and click on My Account. *First-time users must register on the site.*
3. Pass the online tests with a score of 100%; you will be allowed to answer the questions as many times as needed to achieve a score of 100%.
4. After successfully completing the test, a credit letter will be emailed to you instantly.
5. Twice yearly after the test, your browser will be directed to an activity evaluation form, which must be completed to receive your credit letter.

EMERGENCY MEDICINE REPORTS™
(ISSN 0746-2506) is published twice per month by AHC Media LLC, One Atlanta Plaza, 950 East Paces Ferry Road NE, Suite 2850, Atlanta, GA 30326. Telephone: (800) 688-2421 or (404) 262-7436.

Editorial & Continuing Education Director: Lee Landenberger

Executive Editor: Shelly Morrow Mark

GST Registration No.: R128870672

Periodicals Postage Paid at Atlanta, GA 30304 and at additional mailing offices.

POSTMASTER: Send address changes to ***Emergency Medicine Reports,*** P.O. Box 550669, Atlanta, GA 30355.

Back issues: $31. Missing issues will be fulfilled by customer service free of charge when contacted within one month of the missing issue's date.

AHC Media

SUBSCRIBER INFORMATION

CUSTOMER SERVICE: 1-800-688-2421

Customer Service E-Mail Address:
customerservice@ahcmedia.com

Editorial E-Mail Address:
shelly.mark@ahcmedia.com

Online:
AHCMedia.com

SUBSCRIPTION PRICES

1 year with 66 ACEP/72 AMA/39 AAFP Category 1/Prescribed credits: $564

1 year *without* credit: $419
Add $19.99 for shipping & handling

MULTIPLE COPIES:
Discounts are available for group subscriptions, multiple copies, site-licenses, or electronic distribution. For pricing information, please contact our Group Account Managers at Groups@AHCMedia.com or 866-213-0844.

ACCREDITATION

AHC Media is accredited by the Accreditation Council for Continuing Medical Education to provide continuing medical education for physicians.

AHC Media designates this enduring material for a maximum of 72 *AMA PRA Category 1 Credits™*. Each issue has been designated for a maximum of 3.0 *AMA PRA Category 1 Credits™*. Physicians should claim only credit commensurate with the extent of their participation in the activity.

Approved by the American College of Emergency Physicians for a maximum of 66.00 hour(s) of ACEP Category I credit.

This Enduring Material activity, Emergency Medicine Reports, has been reviewed and is acceptable for up to 39.00 Prescribed credit(s) by the American Academy of Family Physicians. Term of approval begins 01/01/2016. Term of approval is for one year from this date. Physicians should claim only the credit commensurate with the extent of their participation in the activity.

The American Osteopathic Association has approved this continuing education activity for up to 60 AOA Category 2-B credits.

AHC Media is accredited as a provider of continuing nursing education by the American Nurses Credentialing Center's Commission on Accreditation.

This activity has been approved for 3.0 nursing contact hours using a 60-minute contact hour. Provider approved by the California Board of Registered Nursing, Provider # CEP14749, for 3.0 Contact Hours.

This is an educational publication designed to present scientific information and opinion to health professionals, to stimulate thought, and further investigation. It does not provide advice regarding medical diagnosis or treatment for any individual case. It is not intended for use by the layman. Opinions expressed are not necessarily those of this publication. Mention of products or services does not constitute endorsement. Clinical, legal, tax, and other comments are offered for general guidance only; professional counsel should be sought for specific situations.

This CME/CE activity is intended for emergency and family physicians and nurses. It is in effect for 36 months from the date of the publication.

EMERGENCY MEDICINE REPORTS

Emergency Airway Management: A Targeted Review of Difficult Trauma Situations

Level 1 Indications for Endotracheal Intubation

- Airway obstruction
- Hypoventilation
- Persistent hypoxemia ($SaO_2 \leq 90\%$) despite supplemental oxygen
- Glasgow Coma Scale (GCS) ≤ 8
- Severe hemorrhagic shock
- Cardiac arrest

Level 3 Indications for Endotracheal Intubation

- Facial or neck injury with potential for airway obstruction
- GCS 9-12
- Persistent combativeness refractory to pharmacologic agents
- Respiratory distress
- Preoperative management
- Early ETI is indicated in cervical spinal cord injury (SCI) with any evidence of respiratory insufficiency (complete SCI or incomplete injuries C5 and above)

LEMON Mnemonic

L	Look externally (facial trauma, large incisors, large tongue, or facial hair)
E	Evaluate 3-2-2 rule (incisor distance < 3 patient finger breadths, hyoid to mental distance < 3 fingers, thyroid to hyoid distance < 2 fingers)
M	Mallampati score
O	Obstruction
N	Neck mobility

Mallampati Classification

Class	Description
1	Full view of tonsils, uvula, and soft palate
2	Visibility of hard and soft palate, upper portion of tonsils and uvula
3	Soft and hard palate and base of uvula are visible
4	Only hard palate is visible

Cormack-Lehane Grade

Grade	Description
I	Full view of entire glottis aperture
II	Partial glottis view
III	Epiglottis only
IV	Inability to visualize epiglottis

LeFort Classification Scheme

Type	Description
LeFort I	Horizontal fracture of the maxilla inferior to the nose
LeFort II	Larger portion of maxilla from nasal bones to premolar region
LeFort III	Total disarticulation of the mid-face; craniofacial disjunction

Induction and Paralytic Agents Used in Airway Management

Medication	Dose (IV)	Weight	BP Effect	Comments
Etomidate	0.3 mg/kg	TBW	Neutral	Lipophilic
Ketamine	1–2 mg/kg	LBW	Increase	Respiratory drive and upper airway reflexes are preserved.
Propofol	1–2 mg/kg	IBW	Decrease	Lipophilic but recommended to use IBW due to hypotensive effect.
Fentanyl	1-4 mcg/kg; 15-30 mcg/kg	TBW	Neutral	Some recommend LBW due to individual variability. Larger dose is when using as sole induction agent.
Midazolam	0.3 mg/kg	TBW	Decrease	Subsequent doses on IBW, as half-life is increased in obesity.
Succinylcholine	1 mg/kg	TBW	Neutral	Inadequate paralysis if IBW
Rocuronium	0.6 mg/kg	IBW	Neutral	Hydrophilic
Vecuronium	0.15 mg/kg	IBW	Neutral	Hydrophilic
TBW = Total Body Weight, IBW = Ideal Body Weight, LBW = Lean Body Weight[50,58]				

Hard Signs of Arterial Injury in Neck Trauma

- Pulsatile bleeding
- Expanding hematoma
- Palpable thrill
- Bruit
- Cerebral ischemia

Symptoms and Signs of Inhalation Injury

- Singed nasal hairs
- Pharyngeal erythema
- Carbonaceous sputum
- Hoarseness
- Drooling
- Dysphagia
- Stridor

Zones of the Neck

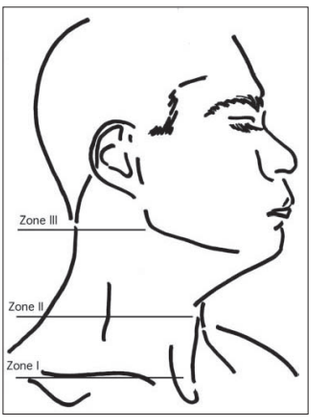

Illustration courtesy of Marcus Eubanks, MD. Reprinted from Hanlon D, et al. *Trauma Rep* 2006;7:4.

Supplement to *Emergency Medicine Reports*, March 1, 2016: "Emergency Airway Management: A Targeted Review of Difficult Trauma Situations." Authors: Dennis Hanlon, MD, Emergency Medicine Attending, Quality Site Director, Allegheny General Hospital, Pittsburgh, PA; and Kirby Black, MD, Emergency Medicine, Allegheny General Hospital, Pittsburgh, PA.