EMERGENCY MEDICINE REPORTS

Practical, Evidence-Based Reviews in Emergency Care

JUNE 15, 2021 VOL. 42, NO. 12

AUTHORS

**Philip Nawrocki, MD,** Core Faculty, EMS Fellowship, EMS Medical Director, Allegheny General Hospital, Associate Medical Director, Critical Care Transport, Pittsburgh, PA

**Jillian Hughart, DO,** Emergency Medicine Resident, Allegheny General Hospital, Pittsburgh, PA

**Jessica Morgenstern, MD,** Emergency Medicine Resident, Allegheny General Hospital, Pittsburgh, PA

PEER REVIEWER

**Colin G. Kaide, MD, FACEP, FAAEM,** Professor of Emergency Medicine, Specialist in Hyperbaric Medicine, Department of Emergency Medicine, Wexner Medical Center at The Ohio State University, Columbus

STATEMENT OF FINANCIAL DISCLOSURE

Dr. Kaide reports that he is on the speaker's bureau for Portola Pharmaceuticals. All of the relationships for this individual have been mitigated. None of the other authors or planners for this educational activity have relevant financial relationships to disclose with ineligible companies whose primary business is producing, marketing, selling, re-selling, or distributing healthcare products used by or on patients

Relias Media
From Relias

# Tracheostomy Emergencies

## Introduction

Tracheostomy refers to a surgically created opening in the anterior neck for placement of a tube to secure an airway. These tubes may be temporarily or permanently used as a definitive airway to facilitate oxygenation and ventilation.

It has been estimated that more than 100,000 tracheostomies are performed annually in the United States alone.[1] They may be placed for prolonged intubation, advanced neuromuscular disease, emergent situations due to upper airway obstruction or the inability to intubate, or following surgical resection of the airway due to cancer. Up to 10.7% of patients who are mechanically ventilated for more than 12 hours in the intensive care unit may undergo tracheostomy.[2] One study of 4,776 patients suggested that the complication rate in patients who received tracheostomy tubes associated with acute respiratory failure may be as high as 60.7%.[3]

## Background

### Tracheostomy Overview

A tracheostomy commonly is done through an open surgical approach or via percutaneous Seldinger technique, either at the bedside or in the operating room. Tracheostomy differs from emergent cricothyroidotomy in that the opening generally is made below the level of the cricoid cartilage rather than above. In general, these procedures are performed by general surgeons or otolaryngologists rather than emergency physicians.

### Historical Perspective

In Egypt, hieroglyphs display images consistent with tracheostomy dating as far back as 3600 B.C. There are also descriptions of this procedure performed by Alexander the Great[4] and Hippocrates. In the 16th century, Andreas Vesalius performed a successful tracheotomy on a pig with a reed. This reed was later upgraded to pipe made with wire and leather, which later evolved into curved metal tubes with sponge cuffs. Based on these early designs, Friedrich Trendelenberg was able to produce a tube with an attached inflatable cuff in the late 1800s.[5]

### Anatomy

The cartilaginous structures that form the larynx are divided into three unpaired and six paired cartilages. The unpaired cartilages, listed from superior to inferior, are the epiglottis, thyroid, and cricoid cartilages. These cartilages provide the landmarks for emergent and surgical airway interventions. The thyroid cartilage prominence, known as the "Adam's apple," is easiest to palpate in males. The

## EXECUTIVE SUMMARY

- Common complications of tracheostomy include infection (tracheitis, cellulitis, pneumonia) and clogged tracheal tube.
- Exchanging a tracheostomy tube within the first week after placement is associated with a high rate of complications. If possible, this procedure should be done by a surgeon. When the track is mature (four weeks), exchange can be done in the emergency department.
- A tracheostomy tube may need to be replaced if the tube is clogged and exchanging the inner cannula or suctioning is not effective. More often they are exchanged because the parts are broken or dislodged.
- A potential fatal complication is erosion into the innominate artery. This can be compressed by hyperinflation of the balloon or manually by placing a finger into the stoma and applying pressure anteriorly.

cricoid cartilage is just below the thyroid cartilage, separated in the vertical plane by the cricothyroid membrane. This membrane is the anatomic target of the surgical cricothyroidotomy.

The cross section of the trachea has a D-shaped appearance, with the flattened portion of the "D" making up the posterior wall. The hard, cartilaginous rings make up the curve but do not continue around the complete circumference of the trachea. The posterior wall is comprised of the membranous portion of the cartilaginous rings and is more susceptible to injury. The thyroid is located anterior to the trachea but below the level of the cricoid cartilage. The bilateral lobes cover the trachea laterally. The inferior thyroid artery supplies blood to the cervical trachea. The jugular veins are just lateral to the trachea on both sides, and the innominate (brachiocephalic) artery crosses over the right anterolateral trachea at approximately the sixth to tenth tracheal rings.

A tracheostomy tube generally is inserted below the level of the cricoid cartilage (*see Figure 1*), as opposed to a surgical cricothyroidotomy, which is performed above this level. The distal tip of the tube sits in the trachea below the level of the vocal cords but above the level of the carina.

**Figure 1. Tracheostomy Anatomy**

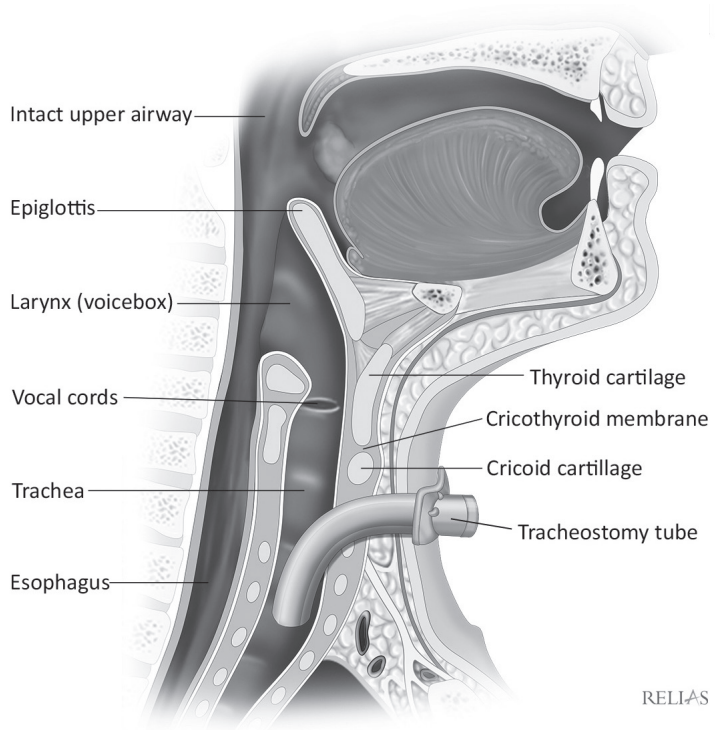


### Tracheostomy Tube and Components

Typically, the tracheostomy tube has the following three components: outer cannula, inner cannula, and an obturator. (*See Figure 2.*) The outer cannula is the curved tube that is inserted through the stoma and holds the tracheostomy open. The external portion consists of wings bilaterally known as the neck plate or flanges. These flanges serve as the attachment points for the tracheostomy ties. The neck plate also is the site of important information about the trach, including the brand name of the manufacturer and whether the trach has a cuff, although the presence of a pilot balloon gives away this information as well. The size of the cuff will be listed, as well as the inner diameter (ID) and the outer diameter (OD) of the cannula.

The outer cannula requires a tool for insertion, known as an obturator. This should always be kept at the bedside with the tracheostomy patient in case of tube dislodgement. The obturator fits inside the lumen of the outer cannula and extends past its distal tip. This provides a smoother, blunter tip for easier and safer insertion so that the outer cannula tube tip does not create a false tract or damage the posterior tracheal wall during insertion. The obturator does occlude the airway while it is in place and must be removed immediately after the trach tube is inserted through the stoma. The obturator removal is immediately followed by insertion of the inner cannula. The inner cannula slides into the outer cannula and locks into place via plastic locking tabs. The trach cuff, if present, is inflated as the final step.

The inner cannula may be disposable or permanent. A disposable cannula usually is discarded daily, while a permanent cannula requires frequent removal and cleaning to prevent the buildup of mucus. When the inner cannula is

## Figure 2. Tracheostomy Tube

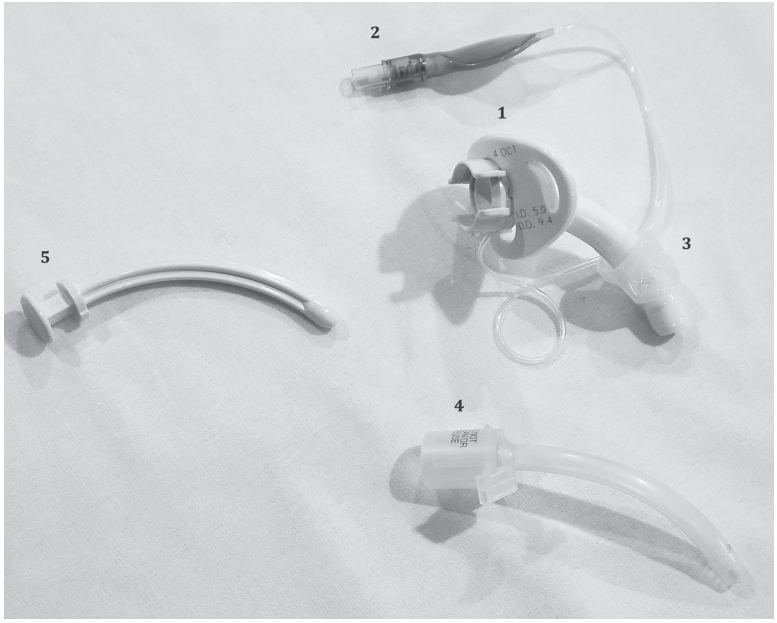


Key components of a standard tracheostomy tube. 1 – Outer cannula with faceplate, 2 – Inflation port and pilot balloon, 3 – Cuff, 4 – Inner cannula, 5 –Obturator.

being exchanged or removed, the patient will be able to breathe normally as the outer cannula holds the stoma patent. However, it is important to note that the inner cannula usually provides the adapter necessary for attachment of a ventilator or bag valve device. Without the inner cannula inserted, the patient cannot be mechanically ventilated.[6]

Patients who no longer require positive pressure ventilation may have their tracheostomy tubes exchanged for an uncuffed tube while they await complete decannulation. Uncuffed tubes have the benefit of lower incidences of tracheal mucosa damage because there is no cuff pressure on the trachea. However, they cannot be used in patients who are still a significant aspiration risk, since gastric contents can make their way into the lungs around the lumen of the tube. Uncuffed tubes also are inappropriate for patients who require supplemental oxygen, since the patient inhales air from both the trach tube and the oropharynx simultaneously. Thus, a hypoxic patient with an uncuffed tube should have oxygen applied both to the tracheostomy by trach mask and to the oropharynx by face mask or nasal cannula. If there is a deterioration in respiratory status, the patient's uncuffed tube should be exchanged for a cuffed tube so that the patient can be mechanically ventilated. Otherwise, the ventilated air would escape superiorly through the oropharynx without the cuffed seal.

Fenestrated tubes may have one hole or multiple holes in both the inner and outer cannulas. The fenestrations allow air to pass through both the tracheostomy tube and through the oropharynx. This may allow the patient to vocalize, but it increases the risk of aspiration events, since oral and gastric contents have an opportunity to enter the lungs, even with a cuff inflated. If a patient requires positive pressure ventilation emergently, a non-fenestrated inner lumen may be passed through the fenestrated outer cannula to allow for short-term positive pressure ventilation. It should be followed by the exchange of the fenestrated outer cannula for a non-fenestrated trach as soon as possible.

Speaking valves are another option for patients with uncuffed tubes who wish to recover some ability to phonate. These are removable one-way valves that attach to the inner cannula adapter. The valve allows air entry through the tracheostomy on inhalation but closes during exhalation. This forces exhaled air around and past the uncuffed or deflated tube, allowing the air to pass the vocal cords and out the oropharynx, creating speech. When the speaking valve is attached, the trach tube absolutely must be deflated or uncuffed or else the patient will not be able to exhale at all, which could result in respiratory distress or death.[7] It should be removed immediately in the event of any respiratory distress or emergent situation.

Air that flows through a trach tube bypasses the heating and humidifying process that is usually performed by the upper airways. Patients with a trach should be provided with humidified oxygen to prevent formation of thickened secretions and mucus plugs. Patients may present with their own heat and moisture exchanger, which is an attachable device, or they may require a humidified trach mask while present in the emergency department.

### Common Indications for Placement

A list of common indications is summarized in Table 1.[8] There are a few contraindications to tracheostomy as a procedure. An overlying infection at the site of the procedure presents a risk of inoculating the blood or the airway, causing further infection. Patients on anticoagulation deserve additional consideration and may require reversal agents or replacement of blood products prior to the procedure. Abnormal neck anatomy, obesity, or an unstable cervical spine may present relative contraindications to surgery; however, risk vs. benefit should be made on a case-by-case basis.[9]

### The Tracheostomy Procedure

The cricothyroid membrane is the location of the incision for an emergent surgical cricothyroidotomy, a procedure emergency physicians must be familiar with. A tracheostomy differs from a cricothyroidotomy since the tube is passed between two of the upper tracheal rings This is generally not a procedure performed by emergency physicians.

More than 100,000 tracheostomies are performed in the United States every year.[10] Medical critical care intensivists typically perform the percutaneous dilational (Seldinger) technique rather than surgical or open tracheostomy. It is associated with decreased stoma infection

## Table 1. Common Indications for Tracheostomy[8]

- Acute respiratory failure with expected need for prolonged mechanical ventilation
- Failure to wean from mechanical ventilation
- Upper airway obstruction
  - Infections (epiglottitis, Ludwig's angina, etc.)
  - Foreign body
  - Edema
  - Neoplasm/mass
- Airway protection
  - Traumatic brain injury
  - Neuromuscular disease
  - Inability to manage secretions
- Difficult airway (when less invasive techniques not successful)

and improved scar cosmesis.[11] This procedure may be performed in the operating room or at the bedside depending on provider preference and patient clinical condition.

The percutaneous procedure begins with a midline vertical incision over the space between the first and second tracheal rings or the second and third tracheal rings. This site can be identified by landmarks or, more often, by bronchoscopy guidance, which is able to illuminate the site from within the trachea to mark the desired skin incision location. Dissection is performed and then the trachea is breached by a 14 G introducer needle at a slight angle to avoid injuring the posterior tracheal wall. Placement is confirmed with bronchoscopy visualization and aspiration of air. A guidewire then is introduced, followed by removal of the introducer needle, and then a single dilation is performed until the tracheostomy tube can be introduced. The cuff is then inflated, and tube placement is confirmed with usual methods, including capnography, chest rise, and breath sounds. Finally, the orotracheal tube is removed, and the tracheostomy neck plate is sutured to the skin.

Surgical, or open, tracheostomy is typically performed in the operating room under general anesthesia. This procedure begins with a midline vertical skin incision 1 cm below the cricoid cartilage. The subsequent layers of subcutaneous tissue and platysma are divided or dissected. Strap muscles are retracted. The thyroid isthmus is either divided or retracted if it is mobile. A hook is used on the cricoid cartilage to elevate the trachea prior to tracheal incision. The existing orotracheal tube is retracted slightly to allow for the passage of the tracheostomy tube through the incision, followed by the trach inner cannula. The new cuff is inflated, the ventilator is attached, and placement is confirmed prior to removal of the previous orotracheal tube. The trach then is secured by suturing the trach flanges to the skin.[12]

### Routine Care and Maintenance

Patients and families may be helpful sources of information, since they likely have received education and training on several aspects of tube management and maintenance. If needed, the emergency physician also can request that the family retrieve device-specific supplies or replacements from home. Generally, patients also will have a replacement or backup tracheostomy tube of the same size in the event of device malfunction or complication, and ideally will bring this to the hospital with them. A product manual and quick reference guide is readily available on the device manufacturer's website and is a useful source of information.

The provider should take note of the specific size, device type, and brand (ex. 6.5 cuffed single-cannula). The sizing of the tube (ex. 6.5) refers to the inner diameter of the tracheostomy tube in millimeters. The stoma of the tracheostomy tube should be inspected for any signs of infection, including redness, warmth, and purulent drainage. The presence of additional features, such as tube fenestrations and speaking valves, also should be noted.

If the tracheostomy tube is cuffed, the cuff pressure should be checked using a handheld manometer. The purpose of the cuff is to prevent an air leak during positive pressure ventilation as well as to prevent aspiration of secretions or vomit into the respiratory tract.[13] The ideal cuff pressure to accomplish both of the goals is 20-30 cm $H_2O$.[14] Excessive pressures may impair tracheal mucosal blood flow, leading to tracheal injury.[15] Over time, this can lead to tracheal stenosis or dilation, tracheomalacia, or fistula, making future airway interventions more difficult. A recent prehospital study of one helicopter-based emergency medical services (EMS) service reported that patients transported from a referring hospital or EMS agency had a mean endotracheal tube cuff pressure of 70 cm $H_2O$, with many exceeding 120 cm $H_2O$.[16] Care should be taken not to overinflate the cuff and to monitor for excess pressures.

Regular cleaning of the tracheostomy tube and stoma is essential in preventing infection, tube obstruction, and other device complications. If the patient has a reusable inner cannula, they should be instructed to clean it on a daily basis by soaking it in a solution of hydrogen peroxide for several minutes and then brushing the cannula with a soft tip brush.[17] Equipment should be rinsed in sterile water or saline prior to reuse. Patients with a disposable inner cannula should have this replaced at regular intervals. The stoma should be inspected for secretions or drainage and should undergo routine wound care. Clean dressings should be applied regularly, and soiled tube ties should be replaced as needed.

One of the more common procedures involved with tracheostomy tube management is the use of suction to remove excessive secretions or aspirated material from the tube lumen. Obstruction of the tube should be considered in all tracheostomy patients with respiratory issues, particularly in those who show signs of hypoxia, dyspnea, respiratory distress, or have high inspiratory pressures on mechanical ventilation. A closed-suction system may be used inline with ventilator tubing during mechanical ventilation, while an open system may be used for patients using passing supplemental

## Figure 3. Tracheostomy Suction Devices

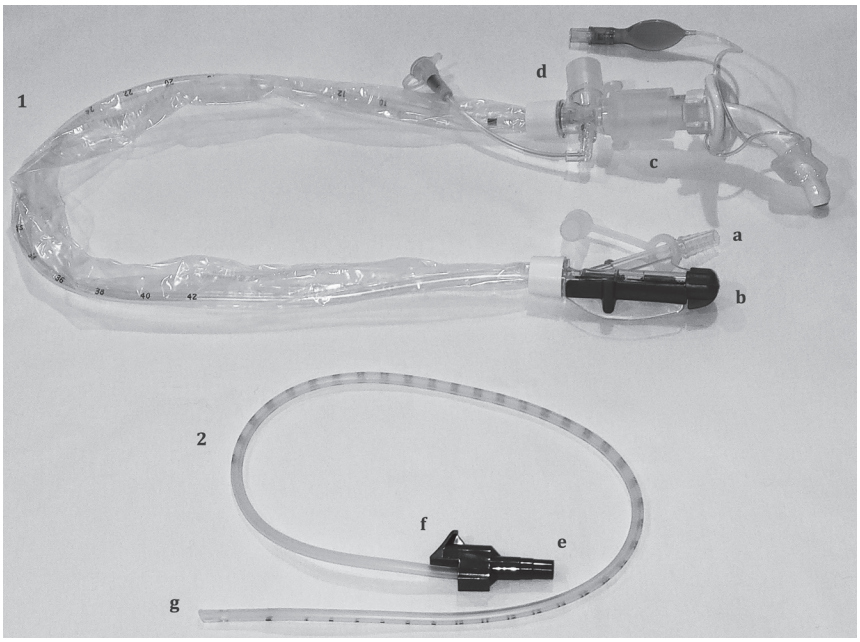


Common suction devices for use with tracheostomy tubes. 1 – Closed-system suction catheter (for use with mechanical ventilation tubing), a – Connecting port for suction tubing (connects to vacuum device), b – Manual thumb suction control valve, c – Connector port for tracheostomy tube, d – Connector port for ventilator circuit, 2 – Open tracheal suction catheter, e – Connecting port for suction tubing, f – Manual thumb suction control valve, g – Distal suction catheter tubing.

oxygen or those on room air oxygen. (*See Figure 3.*)

The patient should be appropriately monitored and preoxygenated for at least 30-60 seconds prior to suctioning. Aseptic technique should be maintained throughout the procedure. The suction catheter should be advanced 10-15 cm through the inner cannula, at which time a suction pressure of 80-120 mmHg should be applied while slowly withdrawing the catheter over 10-15 seconds.[18] Complications of suctioning include damage to the tracheal mucosa, hypoxia from temporary interruption in ventilation, arrhythmia, and increased intracranial pressure.[19] Instillation of normal saline before suctioning may have an adverse effect on oxygen saturation and is no longer recommended.[20]

Certain clinical scenarios may require the emergency medicine physician to exchange the tracheostomy tube. This should only be done a minimum of seven days after initial tube placement to ensure the stoma and tract are mature to avoid the increased risk of false tract creation. The emergency physician should gather equipment to replace the tube, including a tube of the same size and one smaller, as well as supplies for a backup airway should the exchange be unsuccessful. The patient should be placed in a semi-recumbent position with the neck slightly extended and should be preoxygenated for several minutes. The tube cuff should be deflated, and the original tube should be removed. A new tube lubricated with water-based jelly (with obturator in place) should be inserted to the stoma at a 90-degree angle and pushed downward in a sweeping motion. The obturator should then be removed, the inner cannula inserted, and the cuff inflated to an appropriate pressure. Alternatively, a bougie may be used to facilitate tube exchange.[18]

### Oxygenation and Ventilation

Depending on the circumstances under which the tube was initially placed, as well as ongoing indications for use, there are several options to oxygenate and ventilate the patient. If supplemental oxygen is provided, it should be warmed and humidified to prevent thickening and hardening of secretions.

Patients and families may be a useful source of information, since they generally have received specific training regarding the ventilator device and mode of ventilation. The specific ventilation mode generally depends on the underlying medical condition and the needs of the patient.

Many patients are able to spontaneously generate breaths but still require some form of supplemental oxygen. In such cases, a tracheostomy mask may be used, which is similar in appearance and concept to a nonrebreather face mask. (*See Figure 4.*) Color-coded dilution jets that can be found within a venturi mask kit also may be connected inline to the tracheostomy mask to provide a fraction of inspired oxygen ($FiO_2$) of 24% to 60%.[21]

Finally, some patients may simply require the tube as a conduit to secure an airway and do not require supplemental oxygen or assisted ventilation. Patients who have had a tube placed due to chronic illness but who are improving and in the process of weaning from ventilatory support also may not need supplemental oxygen or assisted ventilation. Those in the final stages of the weaning process also may have a tracheostomy "button" or "plug" intentionally obstructing the tube lumen as a means to trial the patient's ability to breathe without a tracheostomy.

### Considerations for Monitoring

The majority of patients presenting with tracheostomy emergencies should have multimodal continuous monitoring in place, including cardiac monitoring, frequent noninvasive blood pressure measurement, and continuous pulse oximetry. The emergency physician also should strongly consider using continuous waveform capnography to confirm correct placement of the tube and to gain insight to the patient's underlying respiratory physiology. Patients who require mechanical ventilation benefit from an inline continuous quantitative waveform capnography device connected between the patient end of the ventilator circuit and the 15 mm connector hub of the inner cannula. For patients using passive ventilation, a strategy of placing a nasal waveform capnography device at the tracheal stoma using common

**Figure 4. Tracheostomy Mask**


tracheostomy equipment has been described.[22]

## Complications and Emergencies

Of the estimated 100,000 tracheostomies placed annually in the United States, up to half may result in at least one complication. As many as 0.5% of patients who undergo tracheostomy will have a significant complication that leads to death.[10] Complications associated with the percutaneous technique are higher at 10% compared to 8.7% for the open tracheostomy.[23] In the pediatric population, tracheostomy-related deaths have been reported to be 10 times higher than those found in adults.[24] Children younger than 12 months of age have a seven times greater risk of mortality with tracheostomy compared to those older than 1 year of age, and patients 1 to 4 years old have a fourfold increased risk of complications compared to those older than age 13 years.[25] Complications also are more likely with emergency tracheostomy placement compared to those performed as an elective procedure.[26] Mortality rates are higher in those who experience complications in the early postoperative period.[27]

Specific complications related to tracheostomy and tracheostomy tubes commonly are divided into early and delayed. (*See Table 2.*) Early complications generally arise in the operating room or directly following the procedure, while delayed complications may occur days, weeks, or years after the initial procedure. Specific complications that the emergency physician should be familiar with are described in the following sections.

### Early

Creation of a false passage occurs when the tracheostomy tube is inserted between soft tissue planes of the anterior neck instead of the tracheal lumen. This may result in subcutaneous emphysema, respiratory distress, and the need for an emergent airway, which the emergency physician may be called upon to assist with, depending on local policy.

The most common complication that arises in both the early and delayed period is bleeding.[4,26] This may be secondary to inadequate hemostasis or due to surgical complications. With initial placement or tube manipulation, it is possible to injure surrounding vessels and structures, such as the inferior thyroid vein, anterior jugular vein, or the thyroid isthmus.[28] A more serious operative injury involves the innominate artery, which lies anterior to the ninth tracheal ring. Injury to this vessel is infrequent but is associated with high mortality and requires immediate ligation to prevent life-threatening bleeding and death.[29]

For minor bleeding that occurs in the postoperative period, the first intervention is to apply direct pressure. If bleeding cannot be controlled with pressure, it could indicate a more serious underlying source, and a surgical consult should be obtained promptly. Use of a hemostatic gauze product, topical thrombin, or topical tranexamic acid also may aid hemostasis. Consideration also should be given to correcting any underlying coagulopathy, such as thrombocytopenia, or reversing any anticoagulant the patient may be taking.

A significant complication that is more prevalent in an emergent tracheostomy compared to an elective procedure is the development of pneumothorax, particularly early in the postoperative period.[25] Patients who develop pneumothorax may present with sinus tachycardia, ipsilateral decreased or absent breath sounds, dyspnea or hypoxia, and other signs of respiratory distress.[30] Adjuncts to the physical exam for diagnosis include a chest X-ray, which may show lung markings that do not extend to the lung periphery or a deep costophrenic angle. Supplemental oxygen should be given to patients with pneumothorax regardless of their oxygen saturation. Small pneumothoraxes in an otherwise stable patient can be monitored closely without further intervention. For pneumothoraxes that are larger in size, bilateral, or in patients who are unstable, a pigtail or tube thoracostomy may be inserted for therapy.

Subcutaneous emphysema is another possible complication that can develop after bag-valve ventilation, negative pressure, or positive pressure ventilation. This also may develop after initial placement or an attempt at tube replacement creates a false passage through subcutaneous tissue. Treatment priority should be given to confirming correct placement of the airway device within the trachea. Direct visualization of the respiratory tract may be needed to assess the origin of the subcutaneous emphysema, since tracheal injury or leak may be possible. Most often, subcutaneous emphysema and pneumomediastinum are benign and self-limited and only require close observation.

Another possible complication includes injury of the recurrent laryngeal nerve (RLN) during surgery due to its close anatomic proximity. This nerve innervates the muscles that are responsible for sound and phonation in the larynx.[31] Damage to one side of the RLN will affect the voice; however,

**Table 2. Complications of Tracheostomy[35,54]**

| Early | Delayed |
|---|---|
| • False tract<br>• Bleeding<br>• Pneumothorax/ pneumomediastinum<br>• Subcutaneous emphysema<br>• Damage to local structures (thyroid, vasculature, trachea, cartilage, recurrent laryngeal nerve)<br>• Loss of airway | • Bleeding<br>• Tracheal stenosis<br>• Tracheal dilation<br>• Tracheomalacia<br>• Tracheoinnominate fistula<br>• Tracheoesophageal fistula<br>• Infection<br>- Surgical site/cellulitis<br>- Tracheitis<br>- Ventilator-associated pneumonia<br>• Mechanical complications<br>- Obstruction<br>- Accidental decannulation<br>• Device failure<br>- Cuff rupture<br>- Equipment fracture |

bilateral nerve injury may lead to airway compromise secondary to denervation of the musculature involved with opening the vocal cords and that normally helps prevent aspiration of oropharyngeal secretions.[32] Evaluation for injury commonly is done by direct visualization of the vocal cords with a laryngoscopy. Minor injuries can be monitored for recovery prior to surgical intervention. A complete transection must be repaired operatively.[33]

Inability to insert the tracheostomy tube or failed airway is uncommon, but has been reported, and is particularly a concern for morbidly obese patients.[34] In these instances, emergency orotracheal intubation or surgical cricothyroidotomy may be required.

### Delayed

Late complications following trachestomy may occur weeks, months, or even years after the initial procedure. Patients with these complications frequently require specialized equipment and resources, which the emergency physician should be familiar with.

Tracheal stenosis (TS) typically occurs secondary to local granulation tissue formation or tracheal mucosal injury related to excess tracheostomy tube cuff pressures.[35] TS results in airway narrowing, which can lead to stridor, respiratory distress, retained secretions, and air trapping. It may present in patients with chronic tracheostomy tubes or even weeks to months after decannulation. Stenosis also can occur from an improperly sized trach tube tip damaging the posterior tracheal wall, highlighting the importance of proper tube sizing. In general, the smallest trach tube that permits adequate oxygenation and ventilation should be used. The use of high-volume, low-pressure cuffs to reduce damage also may help prevent TS. Several surgical options exist for the treatment of TS, including resection, dilation, and/or stenting of the trachea.[36] Practitioners should be aware of the possibility of silicon stents in place within the trachea for patients who have had surgery to correct TS. Orotracheal intubation may be difficult or impossible in patients with TS, and an emergent cricothyrotomy may be necessary if supportive care with nebulized bronchodilators, heliox, and/or racemic epinephrine are not useful. In extreme cases, extracorporeal membrane oxygenation (ECMO) may be used to support oxygenation in patients with critical TS as a bridge to definitive surgical care.[37]

Chronic excess elevation in cuff pressure also may lead to abnormal dilation of focal segments of the trachea. This may lead to difficulty in obtaining a good cuff seal and difficulty in delivering adequate tidal volumes when using positive-pressure or mechanical ventilation due to a cuff leak. If possible, a tracheostomy tube or endotracheal tube cuff should be inflated distal to the dilated segment. Prompt ENT or surgical consultation is needed.

Tracheomalacia is the dynamic expiratory collapse of the trachea due to weakening of the cartilaginous structures that support the airways. Patients generally present with signs of airway obstruction, including wheezing and expiratory stridor, as well as signs of increased work of breathing. Tracheomalacia may lead to retained respiratory secretions and air trapping. Similar to tracheal stenosis, the treatment options are primarily surgical.[38]

Tracheoinnominate fistula (TIF) can occur in either the early or late phase and carries a high mortality rate. Most often, it occurs approximately four weeks after the initial procedure but may occur at any time.[39] TIF occurs when there is erosion by the tube into the innominate (brachiocephalic) artery. This results in massive hemorrhage both externally and into the respiratory tract. Death can result from either asphyxiation or exsanguination. Risk factors for TIF include low placement of tracheostomy, malnutrition, prior radiation, and use of steroids.[40] TIF may present initially with a minor, self-limited, sentinel bleed and should be considered in any instance of postoperative bleeding.

Initial steps in management must focus on hemorrhage control. A recommended initial action is to hyperinflate the tracheostomy cuff in an attempt to tamponade the bleeding. A cuffless tube should rapidly be exchanged with a cuffed tracheostomy or endotracheal tube. Digital compression also can be attempted by inserting the index finger through the stoma with the thumb placed externally in an attempt to compress the bleeding innominate artery against the sternum. If the patient is unstable, an airway must be established that will bypass and/or tamponade the fistula to prevent life-threatening hemorrhage into the respiratory tract. Passing a small endotracheal tube into the distal trachea (either through the tracheostomy stoma or from the oropharynx), posterior to the index finger, to facilitate ventilation may be needed. Emergent surgical consultation should be obtained as soon as possible. Definitive management requires operative repair via sternotomy or, in some

## Figure 5. Tracheoinnominate Fistula

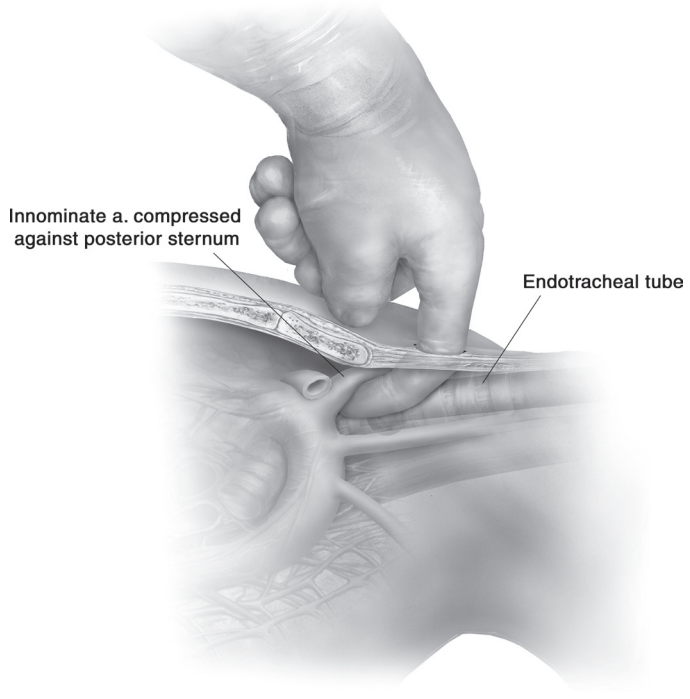


Reprinted from: *Operative Techniques in Thoracic and Cardiovascular Surgery*, vol. 14, Ailawadi G, Technique for managing tracheo-innominate artery fistula, p.p. 66-72, 2009, with permission from Elsevier.

rare cases, an endovascular stent.[39] (*See Figure 5.*)

Tracheoesophageal fistula (TEF) is an uncommon delayed complication following tracheostomy. This commonly presents with increased secretions, dysphagia, recurrent aspiration pneumonias, abdominal distention, and coughing after swallowing.[12,41] This results from an abnormal connection between the trachea and the esophagus after injury to the posterior tracheal wall and anterior esophagus. Barium esophagography aids in diagnosis by directly demonstrating this abnormal connection in patients who are able to swallow. TEF also may be diagnosed with the use of bronchoscopy or computed tomography (CT) scan. Immediate treatment includes inflation of the cuff below the level of the fistula after tube exchange, prompt surgical consultation, and admission for surgical correction.[41]

Infections can occur at multiple different anatomic sites associated with tracheostomy. Patients may develop cellulitis or stomal infections, aspiration, pneumonia, and tracheobronchitis. Patients with tracheostomy tubes lose the beneficial immune functions of the nasal passages and upper respiratory tract due to bypass of these upper airways. Risks of infection include prolonged hospitalization, impaired immunity, poor nutrition, and underlying medical conditions.[18] Infection rates were found to be lower in percutaneous dilatational tracheostomy relative to open tracheostomy in a recent meta-analysis.[42] Common organisms implicated in tracheostomy-associated infections include *Pseudomonas aeruginosa*, methicillin-resistant *Staphylococcus aureus* (MRSA), *Serratia marcescens*, and *Klebsiella pneumoniae*.[43] Broad-spectrum antibiotic coverage should be initiated in all suspected cases and appropriately narrowed depending on respiratory culture results.

Strict wound care and routine cleaning and maintenance are essential after placement to decrease infection risk. Care should be taken to keep this area clean and dry. Cellulitis is a common post-operative infection that may occur around the stoma site. Inspection of the stoma and surrounding tissue may show redness, warmth, tenderness, induration of the skin, or purulent drainage from the stoma itself. Management of cellulitis includes replacement of the cannula, local wound care, and antibiotic therapy.

Tracheitis in tracheostomy patients is thought to be secondary to colonization of the tube. The bacterial growth may cause increased secretions and edema leading to narrowing of the airway. Patients may present with fever, dyspnea, hypoxia, and signs of respiratory distress. A preceding viral illness may lead to bacterial tracheitis as a secondary infection.[44] Labs and imaging often are nonspecific. If there is a high suspicion based on physical exam alone, treatment should be started. If further diagnostic studies are warranted, diagnosis can be definitively made by bronchoscopy. Initial treatment of tracheitis is to secure the airway, followed by broad-spectrum antibiotics with coverage that includes MRSA and *Pseudomonas*.[43] The greatest risk for acquiring tracheitis is from poor tracheostomy care. The tracheostomy tube itself should be exchanged at least monthly to decrease the risk of infection.[45]

Patients requiring chronic mechanical ventilation are at risk for ventilator-associated pneumonia (VAP). A recent meta-analysis reported decreased incidence of VAP with early tracheostomy (≤ 7 days) compared with late intervention in those requiring prolonged mechanical ventilation.[46] All signs of infection require immediate evaluation and prompt medical treatment with close follow-up. The majority of patients with proven or suspected tracheostomy-related infections will require admission for further evaluation and management.

Obstruction of the tracheostomy tube is a significant complication in adults and the leading cause of tracheostomy-related deaths in the pediatric population.[10] Obstruction can be due to secretions, blood, granulation tissue, or foreign body, although the most common cause of cannula obstruction is from mucous plugging.[23] Attempts at assisting ventilation should be performed such as the "head tilt, chin lift" maneuver.

If a patient is still in respiratory distress, any external devices that may be contributing to obstruction should be removed. This includes filters, speaking valves, caps, or bandages. If device removal is unsuccessful in relieving the obstruction, the inner cannula should be removed, at which point a suction

catheter should be inserted to remove any secretions or mucous plugging.[47] If the catheter cannot be fully passed through the tracheostomy, a complete obstruction is present, or the tracheostomy tube may be displaced.

It is important to preoxygenate the patient while attempting to relieve the obstruction when possible to avoid hypoxemia. When bagging by the mouth, the cuff on the tube will need to be deflated to permit air to flow around the tube into the lungs. As a last resort, the tracheostomy may need to be replaced completely. If replacement is unsuccessful, oxygen should be administered by both the stoma and the mouth until another definitive airway can be secured.[10] After the airway has been secured, the patient's oxygen saturation and waveform capnography should be monitored.

Mechanical ventilation should be considered based on the patient's work of breathing and underlying medical conditions. When mechanical ventilation is used, a cuffed tube is mandatory to prevent large air leaks.

Decannulation, or accidental removal of the tracheostomy tube, has been found to be a significant complication in adults and is the leading cause of death in up to 2% of children who have undergone tracheostomy.[25] It is imperative that the tube be replaced as soon as possible. Attempting replacement with a smaller tube may be required due to the risk of narrowing of the stoma, even with mature stomas that have been in place longer than two weeks. In tubes that have been in place less than two weeks, the tract will not yet be mature, and surgical consultation may be required.[10] Attempting to pass a new tube through a stoma has the potential to create a false passage, resulting in further complications and the inability to oxygenate the patient. If replacement via stoma is unsuccessful, emergent endotracheal intubation may be required. Patients who have undergone laryngectomy will not be able to undergo orotracheal intubation.

Equipment failures are another category of delayed complications. Fractures of tracheostomy tubes and equipment are uncommon. When they occur, it is most often at the juncture of the neck plate and tube connection.[18] Fracture fragments can be aspirated into the lower respiratory tract, resulting in signs of respiratory distress, including cough, choking, wheezing, or recurrent infection. The entire tube should be replaced, and bronchoscopy should be performed to remove any identified foreign body. Cuff failure from perforation may lead to a poor seal for ventilation, resulting in increased risk of aspiration or respiratory distress. The cuff also may be abnormally distended, which can result in obstruction of the distal tip of the trach tube. For either of the mentioned situations, replacement of the trach tube is indicated.

**Table 3. Key Differences in the Pediatric Airway and Trachea Relative to Adult Patients[48]**

| Anatomic Region | Anatomic Difference | Implications |
|---|---|---|
| Head | • Proportionally larger head and occiput | • Passive head and neck flexion while supine<br>• Consider placing a towel or roll between scapulae for neutral airway alignment |
| Oropharynx | • Relatively larger tongue<br>• Smaller mouth opening | • Airway is more easily obstructed<br>• Need for appropriately sized equipment |
| Larynx | • More anterior and superior<br>• Epiglottis is relatively larger and longer | • May make visualization of glottic opening more difficult |
| Trachea | • Shorter distance to carina<br>• Narrower in diameter<br>• Smaller cricothyroid membrane (CTM)<br>• Cartilage (CTM and tracheal rings) not completely formed yet | • Easier to accidentally intubate right mainstem bronchus<br>• Increased resistance to airflow<br>• Surgical cricothyroidotomy contraindicated on pediatric patients < ~10 years[49]<br>• Airway structures more prone to collapse |

## Special Populations and Considerations

One of the more common underlying etiologies for which a pediatric patient may have a tracheostomy tube is to assist in the management of a variety of congenital neurologic or neuromuscular conditions. Tracheostomy placement also may be recommended for pediatric patients with underlying craniofacial abnormalities, airway obstruction or abnormalities, or who require prolonged ventilation.[46] Complications and mortality may be higher in pediatric patients with tracheostomy, although it has been suggested this is related to their underlying conditions rather than to the tracheostomy procedure itself.[48]

The key features and differences of the pediatric airway relative to the adult airway are highlighted in Table 3.

A primary step in the initial management of tracheostomy emergencies in the pediatric patient is to rapidly gather and prepare additional equipment and resources. Requesting additional personnel, including respiratory therapists, anesthesiologists, pediatric ear, nose, and throat (ENT) specialists, and/or intensivists, should be considered based on local availability. Additional equipment, including extra tracheostomy tubes (one of the same size and one that is one size smaller), appropriately sized suction devices, bag-valve-mask, and backup airway equipment should be immediately available.

Pediatric patients may be less able to cooperate with attempts at tracheostomy tube manipulation or other therapeutic interventions. Sedation and/or analgesia

should be used in these cases. For patients who are in arrest or in extremis, the emergency physician should have a high suspicion for tube obstruction or other underlying respiratory process, since these are more likely underlying etiologies in the pediatric population. Pediatric patients with acute illness and who require admission likely will require transfer to a hospital with pediatric capabilities.

Relative to younger adults, geriatric patients may have decreased range of motion of the mouth, head, and neck, making neck extension and airway management difficult. From a physiologic standpoint, the diminished cognitive ability of some elderly patients may affect their ability to cooperate with medical treatment.[50] Muscle stiffness and atrophy may interfere with ideal positioning when attempting to manipulate tracheostomy tubes or perform airway procedures.[51] Elderly patients also may have diminished physiologic reserve, making timely management of tracheostomy emergencies essential. Geriatric patients who undergo placement of a tracheostomy tube also have a higher mortality and are more likely to be ventilator-dependent when discharged.[52,53]

Discussions with patients and families regarding goals of care as they pertain to further tracheostomy tube management or airway interventions should occur.

Respiratory tract secretions may cause discomfort to the patient and should be managed with gentle suctioning. Alternatively, anticholinergic medications that produce an antisialagogue effect, such as glycopyrrolate or scopolamine, may be used to decrease secretions. Supplemental oxygen to the tracheostomy tube and analgesic medications also should be provided to prevent discomfort associated with "air hunger" and underlying painful conditions.

## Summary

Management of tracheostomy emergencies requires the use of specialized knowledge, resources, and equipment. Providers should elicit the underlying reason for placement of the tube, as well as other specific pertinent information, including when the tube was initially placed, size and specific model of tube, and any history of tracheostomy complications. Initial steps in the management of the unstable patient include confirming that the tube is in the correct location, confirming the tube is patent (unobstructed), and providing supplemental oxygen and assisted ventilations as needed. Emergency physicians can manage many common tracheostomy emergencies independently, although when a serious or life-threatening complication is identified, prompt surgical consultation is mandatory.

## References


1. Yu M. Tracheostomy patients on the ward: Multiple benefits from a multidisciplinary team? *Crit Care* 2010;14:109.
2. Frutos-Vivar F, Esteban A, Apezteguia C, et al. Outcome of mechanically ventilated patients who require a tracheostomy. *Crit Care Med* 2005;33:290-298.
3. Freeman BD, Stawalley D, Lambert D, et al. High resource utilization does not affect mortality in acute respiratory failure patients managed with tracheostomy. *Respir Care* 2013;58:1863-1872.
4. Raimonde AJ, Westhoven N, Winters R. Tracheostomy. In: *StatPearls*. StatPearls Publishing;2020. Updated Nov. 30, 2020. https://www.ncbi.nlm.nih.gov/books/NBK559124/
5. Reilly E, Walters B. A brief history of the endotracheal tube. *Emergency Physicians Monthly.* Published Nov. 9, 2020. https://epmonthly.com/article/a-brief-history-of-the-endotracheal-tube/
6. Molnar H. Tracheostomy Service. Types of tracheostomy tubes. Johns Hopkins Medicine. https://www.hopkinsmedicine.org/tracheostomy/about/types.html
7. Al-Shaikh B, Stacey SG. Tracheal tubes, tracheostomy tubes and airways. In: Al-Shaikh B, Stacey SG, eds. *Essentials of Equipment in Anaesthesia, Critical Care and Peri-Operative Medicine*. 5th ed. Elsevier; 2018:73-79.
8. Cheung NH, Napolitano LM. Tracheostomy: Epidemiology, indications, timing, technique, and outcomes. *Respir Care* 2014;59:895-915.
9. Gupta S, Dixit S, Choudhry D, et al. Tracheostomy in adult intensive care unit: An ISCCM expert panel practice recommendations. *Indian J Crit Care Med* 2020;24(Suppl 1):S31-S42.
10. Bontempo LJ, Manning SL. Tracheostomy emergencies. *Emerg Med Clin North Am* 2019;37:109-119.
11. Reed CR, Haines KL, Agarwal SK. Tracheostomy. In: Cameron JL, Cameron AM, eds. *Current Surgical Therapy.* 13th ed. Elsevier;2019:1394-1404.
12. Kraft SM, Schindler JS. Tracheotomy. In: Flint PW, Haughey BH, Lund VJ, et al, eds. *Cummings Otolaryngology: Head and Neck Surgery*. 7th ed. Elsevier; 2020:81-89.
13. Sengupta P, Sessler DI, Maglinger P, et al. Endotracheal tube cuff pressure in three Hospitals, and the volume required to produce an appropriate cuff pressure. *BMC Anesthesiol* 2004;4:8.
14. Park YJ, Lee J, Kim SH, et al. Care status of the ALS patients with long-term use of tracheostomy tube. *Ann Rehabil Med* 2015;39:964-970.
15. Seegobin RD, van Hasselt GL. Endotracheal cuff pressure and tracheal mucosal blood flow: Endoscopic study of effects of four large volume cuffs. *BMJ (Clin Res Ed)* 1984;288:965-968.
16. Tennyson J, Ford-Webb T, Weisberg S, LeBlanc D. Endotracheal tube cuff pressures in patients intubated prior to helicopter EMS transport. *West J Emerg Med* 2016;17:721-725.
17. Minsley MA, Wrenn S. Long-term care of the tracheostomy patient from an outpatient nursing perspective. *ORL Head Neck Nurs* 1996;14:18-22.
18. Greenwood JC, Winters ME. Tracheostomy care. In: Custalow CB, Roberts JR, Thomsen TW, Hedges JR, eds. *Roberts and Hedges' Clinical Procedures in Emergency Medicine*. 6th ed. Saunders; 2013:134-151.
19. Fiorentini A. Potential hazards of tracheobronchial suctioning. *Intensive Crit Care Nurs* 1992;8:217-226.
20. Ackerman MH, Mick DJ. Instillation of normal saline before suctioning in patients with pulmonary infections: A prospective randomized controlled trial. *Am J Crit Care* 1998;7:261-266.
21. Bateman NT, Leach RM. ABC of oxygen. Acute oxygen therapy. *BMJ* 1998;317:798-801.
22. Williams AR, Shelbourne C, Pinosky M. A method for measuring carbon dioxide at the tracheal stoma. *Anesthesiology* 1998;89:799-800.
23. Nicks BA, Manthey D. Pneumothorax, tracheostomy. In: Tintinalli JE, Stapczynski J, Ma OJ, et al, eds. *Emergency Medicine: A Comprehensive Study Guide*. 8th ed. McGraw-Hill;2016:465-467,1619-1624.
24. Cramer J, Graboyes EM, Brenner MJ. Mortality associated with tracheostomy complications in the United States: 2007-2016. *Laryngoscope* 2019;129:619-626.
25. Neto JFL, Castagno OC, Schuster AK. Complications of tracheostomy in children: A systematic review. *Braz J Otorhinolaryngol* 2020; Dec 30. doi: 10.1016/j.bjorl.2020.12.006. [Online ahead of print].
26. Akhlaq M, Ahmad W, Ali MM, et al. Comparison of early complications of elective tracheostomy with early complications of emergency tracheostomy. *PJMHS* 2020;14:648-650.
27. Jotic AD, Milovanovic JP, Trivic AS, et al. Predictors of complications occurrence associated with emergency surgical

tracheotomy. *Otolaryngol Head Neck Surg* 2021;164:346-352.
28. Kaye C, MacLeod I, Dhillon M. Bleeding during percutaneous dilatational tracheostomy — What to do while waiting for the surgeon? *J Intensive Care Soc* 2018;19: 64-68.
29. Okada Y, Narumiya H, Ishii W, Ryoji I. Damage control management of innominate artery injury with tracheostomy. *Surg Case Rep* 2016;2:17.
30. Yilmaz F. Successfully managed bilateral pneumothorax and subcutaneous emphysema after emergency open surgical tracheotomy. *Ain-Shams Journal of Anesthesiology* 2021;13:14.
31. Allen E, Minutello K, Murcek BW. Anatomy, head and neck, larynx recurrent laryngeal nerve. In: *StatPearls*. StatPearls Publishing;2020. Updated July 27, 2020. https://www.ncbi.nlm.nih.gov/books/NBK470179/
32. Woodson G. Pathophysiology of recurrent laryngeal nerve injury. In: Randolph GW, eds. *Surgery of the Thyroid and Parathyroid Glands*. 3rd ed. Elsevier;2021:404-409.
33. Culp JM, Patel G. Recurrent laryngeal nerve injury. In: *StatPearls*. StatPearls Publishing;2020. Updated July 25, 2020. https://www.ncbi.nlm.nih.gov/books/NBK560832/
34. Ahuja H, Mathai AS, Chander R, Mathew AE. Case of difficult tracheostomy tube insertion: A novel yet simple solution to the dilemma. *Anesth Essays Res* 2013;7:402-404.
35. Epstein SK. Late complications of tracheostomy. *Respir Care* 2005;50:542-549.
36. Maurizi G, Vanni C, Rendina EA, et al. Surgery for laryngotracheal stenosis: Improved results. *J Thorac Cardiovasc Surg* 2021;161:845-852.
37. Pu H, Lei Y, Yuan D, Zhou Y. Tracheal reconstruction surgery supported by extracorporeal membrane oxygenation for patients with traumatic post-tracheotomy tracheal stenosis. *Ann Thorac Cardiovasc Surg* 2020;26:327-331.
38. Thompson DM, Cotton RT. Lesions of the larynx, trachea and upper airway. In: Grosfeld J, O'Neill J, Coran A, Fonkalsrud E, eds. *Pediatric Surgery*. 6th ed. Elsevier; 2006:983.
39. Khanafer A, Hellstern V, Meißner H, et al. Tracheoinnominate fistula: Acute bleeding and hypovolemic shock due to a trachea-innominate artery fistula after long-term tracheostomy, treated with a stent-graft. *CVIR Endovasc* 2021;4:30.
40. Thorp A, Hurt TL, Kim TY, Brown L. Tracheoinnominate artery fistula: A rare and often fatal complication of indwelling tracheostomy tubes. *Pediatr Emerg Care* 2005;21:763-766.
41. Kim HS, Khemasuwan D, Diaz-Mendoza J, Mehta AC. Management of tracheo-oesophageal fistula in adults. *Eur Respir Rev* 2020;29:200094.
42. Johnson-Obaseki S, Veljkovic A, Javidnia H. Complication rates of open surgical versus percutaneous tracheostomy in critically ill patients. *Laryngoscope* 2016;126:2459-2467.
43. Tan CY, Chiu NC, Lee KS, et al. Respiratory tract infections in children with tracheostomy. *J Microbiol Immunol Infect* 2020;53:315-320.
44. Al-Mutairi B, Kirk V. Bacterial tracheitis in children: Approach to diagnosis and treatment. *Paediatr Child Health* 2004;9:25-30.
45. Burton LV, Silberman M. Bacterial tracheitis. In: *StatPearls*. StatPearls Publishing;2020. Updated Jan. 17, 2021. https://www.ncbi.nlm.nih.gov/books/NBK470240/
46. Mahadevan M, Barber C, Salkeld L, et al. Pediatric tracheotomy: 17 year review. *Int J Pediatr Otorhinolaryngol* 2007;71: 1829-1835.
47. Doherty C, Neal R, English C, et al. Multidisciplinary guidelines for the management of paediatric tracheostomy emergencies. *Anaesthesia* 2018;73:1400-1417.
48. Adewale L. Anatomy and assessment of the pediatric airway. *Pediatr Anaesth* 2009;19(Suppl 1):1-8.
49. Murray K, Peterson AC, Yealy DM. Surgical airways. In: Tintinalli JE, Ma OJ, Yealy DM, et al, eds. *Tintinalli's Emergency Medicine: A Comprehensive Study Guide*. 9e. McGraw-Hill;2021.
50. Johnson KN, Botros DB, Groban L, Bryan YF. Anatomic and physiopathologic changes affecting the airway of the elderly patient: Implications for geriatric-focused airway management. *Clin Interv Aging* 2015;10:1925-1934.
51. Lee SY, Shih SC, Leu YS, et al. Implications of age-related changes in anatomy for geriatric-focused difficult airways. *Int J Gerontol* 2017;11:130-133.
52. Baskin JZ, Panagopoulos G, Parks C, et al. Clinical outcomes for the elderly patient receiving a tracheotomy. *Head Neck* 2004;26:71-75.
53. Engoren MC, Arslanian-Engoren CM. Outcome after tracheostomy for respiratory failure in the elderly. *J Intensive Care Med* 2005;20:104-110.
54. Morris LL, Whitmer A, McIntosh E. Tracheostomy care and complications in the intensive care unit. *Crit Care Nurse* 2013;33:18-30.

## CME/CE Questions

1. Which of the following should you consider when providing end-of-life care to a patient with a tracheostomy?
   a. Providing supplemental oxygen
   b. Using anticholinergic medications to reduce secretions
   c. Having a conversation with patient and family regarding goals of care
   d. All of the above
2. What is the most common postoperative complication in tracheostomy patients?
   a. Obstruction
   b. Hemorrhage
   c. Decannulation
   d. Infection
3. What is the most common cause of obstruction in tracheostomy patients?
   a. Secretions
   b. Blood
   c. Granulation tissue
   d. Mucous plugging
4. Injury to which structure may cause airway compromise due to loss of the ability to appropriately open and close the vocal cords?
   a. Cricothyroid muscle
   b. Anterior innominate artery
   c. Recurrent laryngeal nerve
   d. Thyroid
5. A patient presents with hemoptysis. The patient states that he had a single episode of a small amount of hemoptysis earlier today. The patient is approximately four weeks out from tracheostomy with a cuffed trach tube. Which of the following would be the most appropriate immediate course of action?
   a. Surgical consultation
   b. Chest X-ray
   c. Electrocardiogram
   d. Computed tomography angiography chest
6. Development of subcutaneous emphysema after tracheostomy tube exchange is most likely a sign of which of the following?
   a. Equipment fracture and retained foreign body
   b. False passage during replacement of trach tube
   c. Placement of trach tube through a tracheoesophageal fistula
   d. Tube tip obstruction from aspiration of gastric contents

*EMERGENCY MEDICINE REPORTS™*
**(ISSN 0746-2506) is published semimonthly by Relias LLC, 1010 Sync St., Ste. 100, Morrisville, NC 27560-5468. Periodicals postage paid at Morrisville, NC, and additional mailing offices. POSTMASTER: Send address changes to *Emergency Medicine Reports*, Relias LLC, 1010 Sync St., Ste. 100, Morrisville, NC 27560-5468.**

**Executive Editor:** Shelly Morrow Mark
**Associate Editor:** Mike Gates
**Editorial Group Manager:** Leslie Coplin
**Accreditations Director:** Amy M. Johnson, MSN, RN, CPN

GST Registration No.: R128870672





**Back issues: $30**. Missing issues will be fulfilled by customer service free of charge when contacted within one month of the missing issue's date.

## SUBSCRIBER INFORMATION

**CUSTOMER SERVICE: (800) 688-2421**

Customer Service Email Address:
customerservice@reliasmedia.com

Editorial Email Address:
smark@relias.com

Online:
ReliasMedia.com

**MULTIPLE COPIES:**
Discounts are available for group subscriptions, multiple copies, site-licenses, or electronic distribution. For pricing information, please contact our Group Account Managers at groups@reliasmedia.com or (866) 213-0844.

Relias Media
From **Relias**


## ACCREDITATION

JOINTLY ACCREDITED PROVIDER™
INTERPROFESSIONAL CONTINUING EDUCATION

In support of improving patient care, Relias LLC is jointly accredited by the Accreditation Council for Continuing Medical Education (ACCME), the Accreditation Council for Pharmacy Education (ACPE), and the American Nurses Credentialing Center (ANCC), to provide continuing education for the healthcare team.

The Relias LLC designates this enduring material for a maximum of 3 *AMA PRA Category 1 Credits™*. Physicians should claim only the credit commensurate with the extent of their participation in the activity.

3 ANCC contact hours will be awarded to participants who meet the criteria for successful completion

Approved by the American College of Emergency Physicians for a maximum of 3 hour(s) of ACEP Category I credit.

This Enduring Material activity, *Emergency Medicine Reports*, has been reviewed and is acceptable for credit by the American Academy of Family Physicians. Term of approval begins 01/01/2020. Term of approval is for one year from this date. Physicians should claim only the credit commensurate with the extent of their participation in the activity. Approved for 3 AAFP Prescribed credits.

The American Osteopathic Association has approved this continuing education activity for up to 2.5 AOA Category 2-B credits.

This is an educational publication designed to present scientific information and opinion to health professionals, to stimulate thought, and further investigation. It does not provide advice regarding medical diagnosis or treatment for any individual case. It is not intended for use by the layman. Opinions expressed are not necessarily those of this publication. Mention of products or services does not constitute endorsement. Clinical, legal, tax, and other comments are offered for general guidance only; professional counsel should be sought for specific situations.

This CME/CE activity is intended for emergency and family physicians and nurses. It is in effect for 36 months from the date of the publication.

EMERGENCY MEDICINE REPORTS

# Tracheostomy Emergencies

## Tracheostomy Anatomy

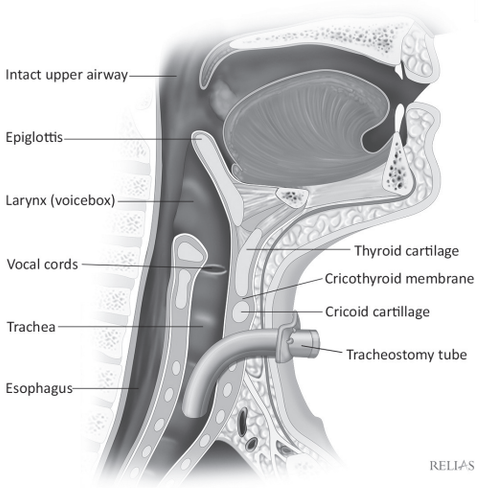


## Common Indications for Tracheostomy

- Acute respiratory failure with expected need for prolonged mechanical ventilation
- Failure to wean from mechanical ventilation
- Upper airway obstruction
  - Infections (epiglottitis, Ludwig's angina, etc.)
  - Foreign body
  - Edema
  - Neoplasm/mass
- Airway protection
  - Traumatic brain injury
  - Neuromuscular disease
  - Inability to manage secretions
- Difficult airway (when less invasive techniques not successful)

## Key Differences in the Pediatric Airway and Trachea Relative to Adult Patients

| Anatomic Region | Anatomic Difference | Implications |
|---|---|---|
| Head | • Proportionally larger head and occiput | • Passive head and neck flexion while supine<br>• Consider placing a towel or roll between scapulae for neutral airway alignment |
| Oropharynx | • Relatively larger tongue<br>• Smaller mouth opening | • Airway is more easily obstructed<br>• Need for appropriately sized equipment |
| Larynx | • More anterior and superior<br>• Epiglottis is relatively larger and longer | • May make visualization of glottic opening more difficult |
| Trachea | • Shorter distance to carina<br>• Narrower in diameter<br>• Smaller cricothyroid membrane (CTM)<br>• Cartilage (CTM and tracheal rings) not completely formed yet | • Easier to accidentally intubate right mainstem bronchus<br>• Increased resistance to airflow<br>• Surgical cricothyroidotomy contraindicated on pediatric patients < ~10 years<br>• Airway structures more prone to collapse |

## Complications of Tracheostomy

| Early | Delayed |
|---|---|
| • False tract<br>• Bleeding<br>• Pneumothorax/ pneumomediastinum<br>• Subcutaneous emphysema<br>• Damage to local structures (thyroid, vasculature, trachea, cartilage, recurrent laryngeal nerve)<br>• Loss of airway | • Bleeding<br>• Tracheal stenosis<br>• Tracheal dilation<br>• Tracheomalacia<br>• Tracheoinnominate fistula<br>• Tracheoesophageal fistula<br>• Infection<br>  - Surgical site/cellulitis<br>  - Tracheitis<br>  - Ventilator-associated pneumonia<br>• Mechanical complications<br>  - Obstruction<br>  - Accidental decannulation<br>• Device failure<br>  - Cuff rupture<br>  - Equipment fracture |

## Tracheostomy Tube

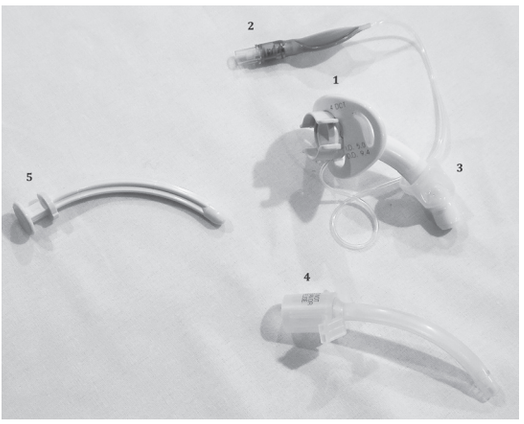


Key components of a standard tracheostomy tube. 1 – Outer cannula with faceplate, 2 – Inflation port and pilot balloon, 3 – Cuff, 4 – Inner cannula, 5 –Obturator.

## Tracheostomy Mask

## Tracheostomy Suction Devices

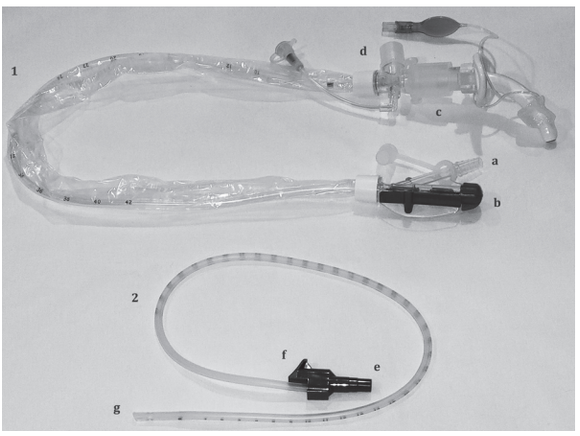


Common suction devices for use with tracheostomy tubes. 1 – Closed-system suction catheter (for use with mechanical ventilation tubing), a – Connecting port for suction tubing (connects to vacuum device), b - Manual thumb suction control valve, c – Connector port for tracheostomy tube, d – Connector port for ventilator circuit, 2 – Open tracheal suction catheter, e – Connecting port for suction tubing, f – Manual thumb suction control valve, g – Distal suction catheter tubing.

Supplement to *Emergency Medicine Reports*, June 15, 2021: "Tracheostomy Emergencies." Authors: Philip Nawrocki, MD, Core Faculty, EMS Fellowship, EMS Medical Director, Allegheny General Hospital, Associate Medical Director, Critical Care Transport, Pittsburgh, PA; Jillian Hughart, DO, Emergency Medicine Resident, Allegheny General Hospital, Pittsburgh, PA; Jessica Morgenstern, MD, Emergency Medicine Resident, Allegheny General Hospital, Pittsburgh, PA.