PEDIATRIC EMERGENCY MEDICINE REPORTS

Practical, Evidence-Based Reviews in Pediatric Emergency Care

April 2018 VOL. 23, NO. 4

AUTHORS

Chisom A. Agbim, MD, Pediatrics Resident, Lucile Packard Children's Hospital Stanford, Palo Alto, CA

N. Ewen Wang, MD, Professor, Emergency Medicine, Associate Director, Pediatric Emergency Medicine, Stanford University Medical School, Stanford, CA

Moon Lee, MD, MPH, Quality Director of Pediatric Emergency Medicine, Assistant Professor, Stanford University Medical School, Stanford, CA

PEER REVIEWER

Steven M. Winograd, MD, FACEP, Mt. Sinai Queens Hospital Center, Jamaica Queens, NY; Assistant Clinical Profesor of Emergency Medicine, Mt. Sinai Medical School, New York City; Assistant Clinical Professor of Emergency Medicine, NYiTCOM, Old Westbury, NY

STATEMENT OF FINANCIAL DISCLOSURE

To reveal any potential bias in this publication, and in accordance with Accreditation Council for Continuing Medical Education guidelines, we disclose that Dr. Hocum (pharmacist reviewer) reports he is an employee of United Therapeutics. Dr. Dietrich (editor), Dr. Skrainka (CME question reviewer), Dr. Agbim (author), Dr. Wang (author), Dr. Lee (author), Dr. Winograd (peer reviewer), Ms. Wurster (nurse reviewer), Ms. Coplin (executive editor), Ms. Mark (executive editor), and Ms. Hatcher (editorial group manager) report no relationships with companies related to the field of study covered by this CME activity.

RELIAS Formerly AHC Media

Respiratory Distress in Pediatric Patients

Respiratory diseases are common in pediatrics, and providers need to have an in-depth knowledge of the presentation, diagnostic approach, and therapeutic options to optimize outcomes.

— Ann Dietrich, MD, FAAP, FACEP, Editor

Respiratory illness is the most common presenting complaint for pediatric emergency department (ED) visits.[1,2] Overall, respiratory illness accounts for more than 9 million annual visits to the ED in children aged 0 to 17 years.[1] Together, pneumonia, asthma, and bronchiolitis account for approximately 11% of annual pediatric ED visits and 25% of all pediatric hospital admissions.[1] Although the majority of children will recover uneventfully, some progress to respiratory distress and a minority to respiratory failure. It is imperative that emergency physicians caring for children understand how to recognize and treat respiratory deterioration expediently.

This article describes a general approach to pediatric patients in respiratory distress and reviews new options in noninvasive airway management. The authors discuss specific disease processes of the upper and lower airway, including the epidemiology, clinical presentation, diagnosis, treatment, and disposition. After reading this article, providers should be able to expediently recognize respiratory distress in a pediatric patient, start initial treatment, develop a differential diagnosis, and treat patients in urgent and emergent settings. The article also discusses special patient populations, specifically patients with cystic fibrosis and neuromuscular diseases. Traumatic causes of respiratory distress and management of respiratory failure are outside the scope of this article.

Recognizing Respiratory Distress

Respiratory failure is the most common cause of cardiopulmonary arrest in the pediatric population; therefore, it is important for emergency providers to recognize respiratory distress quickly in children of all ages and intervene aggressively to prevent respiratory failure. The initial approach to the pediatric patient in respiratory distress consists of three major components: general assessment of the child, recognition of respiratory distress, and intervention.

General Assessment

The Advanced Pediatric Life Support (APLS) Pediatric Assessment Triangle is a well-known, easy-to-apply, standardized rapid assessment tool for the evaluation of infants and children.[3] The Pediatric Assessment Triangle uses appearance, work of breathing, and circulation to quickly gauge the severity of illness and identify the underlying physiologic disturbance. (*See Figure 1.*) Although it can be used to identify a variety of physiologic disturbances, this article will focus on its use for respiratory distress. Early respiratory distress presents with a normal appearance, abnormal work

EXECUTIVE SUMMARY

- The Pediatric Assessment Triangle uses appearance, work of breathing, and circulation to quickly gauge the severity of illness and identify the underlying physiologic disturbance.
- Inspiratory stridor generally is a sign of obstruction above the vocal cords, while expiratory stridor is an indication of obstruction in the trachea. Biphasic stridor is an indication of subglottic narrowing, whereas signs of lower airway obstruction include grunting, wheezing, and crackles.
- Heated humidified high-flow nasal cannula is studied most commonly as an alternative form of respiratory support where continuous positive airway pressure (CPAP) is indicated. Outside of its role in infants with bronchiolitis, there is relatively limited evidence for heated humidified high-flow nasal cannula therapy in children.
- The CPAP apparatus is available as a nasal plug, a nasal mask that covers the nares, a face mask that covers both the nares and the mouth, or a complete face mask that covers the entire face. When CPAP is used, the recommendation is to start low pressures (5 cmH_2O) and increase in increments of 1 cmH_2O as tolerated by the patient for goals of an exhaled tidal volume > 7 mL/kg, a respiratory rate normal for given age, and oxygen saturation > 90%.
- Traditionally, bi-level positive airway pressure (BiPAP) has been used for pediatric patients with neuromuscular disorders, chronic lung disease, and obstructive airways. In the pediatric population, it has been limited to children weighing more than 20 kg because of the concern that small children are incapable of initiating supported breaths while on BiPAP; however, recent studies have shown BiPAP as a beneficial treatment modality for acute severe asthma exacerbations in children of all weights.
- New American Academy of Pediatrics guidelines for bronchiolitis do not recommend routine chest radiographs or trials of albuterol or epinephrine aerosols.

of breathing, and normal circulation to the skin. As distress progresses, there is a more pronounced work of breathing and inability to compensate. Respiratory failure is characterized by abnormal appearance, abnormal work of breathing, and normal to abnormal circulation to the skin. Patients in full cardiorespiratory failure will present with abnormal general appearance, abnormal work of breathing, and abnormal circulation. Using the Pediatric Assessment Triangle, ED providers quickly can determine what type of intervention is needed and how rapidly it needs to occur. (*See Figure 2.*) Children in mild respiratory distress may need only supplemental oxygen. Children in moderate distress may require high-flow nasal cannula oxygen to avert a further respiratory deterioration.

The pediatric respiratory exam should begin with a general assessment of the child's work of breathing. Children in distress will use accessory muscles to generate higher negative pleural pressures to overcome airway obstruction. Respiratory distress commonly is graded by the level of severity. For example, mild distress involves tachypnea and shortness of breath, which can progress to subcostal retractions and nasal flaring, which are present in moderate distress. Supraclavicular tugging and head bobbing are present with severe distress. In some cases of severe respiratory distress, the entire sternum may retract, which is referred to as paradoxical breathing.

Providers also may witness pediatric patients with respiratory distress assuming a position of maximal respiratory comfort.

Figure 1. The Pediatric Assessment Triangle

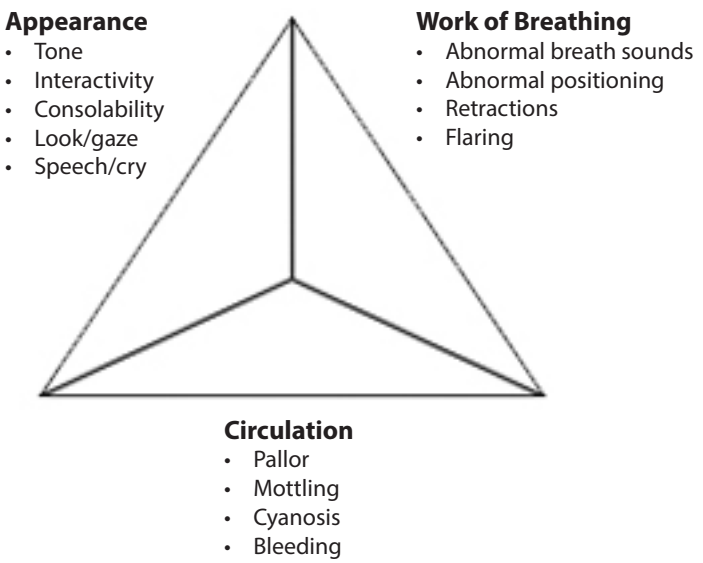

Adapted from: Dieckmann RA, Brownstein D, Gausche-Hill M. The pedatric assessment triangle: A novel approach for the rapid evaluation of children. *Pediatr Emerg Care* 2010;26:312-315.

For example, tripod positioning enhances the full use of the thoracoabdominal muscles to ease work of breathing. This occurs when children position themselves in an upright position while leaning over to support the upper body with their arms placed on either the thighs or the bed. It is the final stage of recruitment of the accessory muscles of respiration before respiratory failure.

While observing the level of respiratory distress, ED providers also should be aware of the patient's vital signs — especially the respiratory rate, heart rate, and oxygen saturation and use age-specific vital signs. (*See Tables 1 and 2.*) Most commonly, tachypnea is the first sign of respiratory distress. It can indicate obstruction or inflammation anywhere in the respiratory tract, anxiety, metabolic acidosis, cardiac disease, or even the onset of fever. Apnea and bradypnea in children usually is the result of respiratory muscle fatigue. Tachycardia due to increased sympathetic tone is common in

Figure 2. Approach to the Pediatric Patient in Respiratory Distress

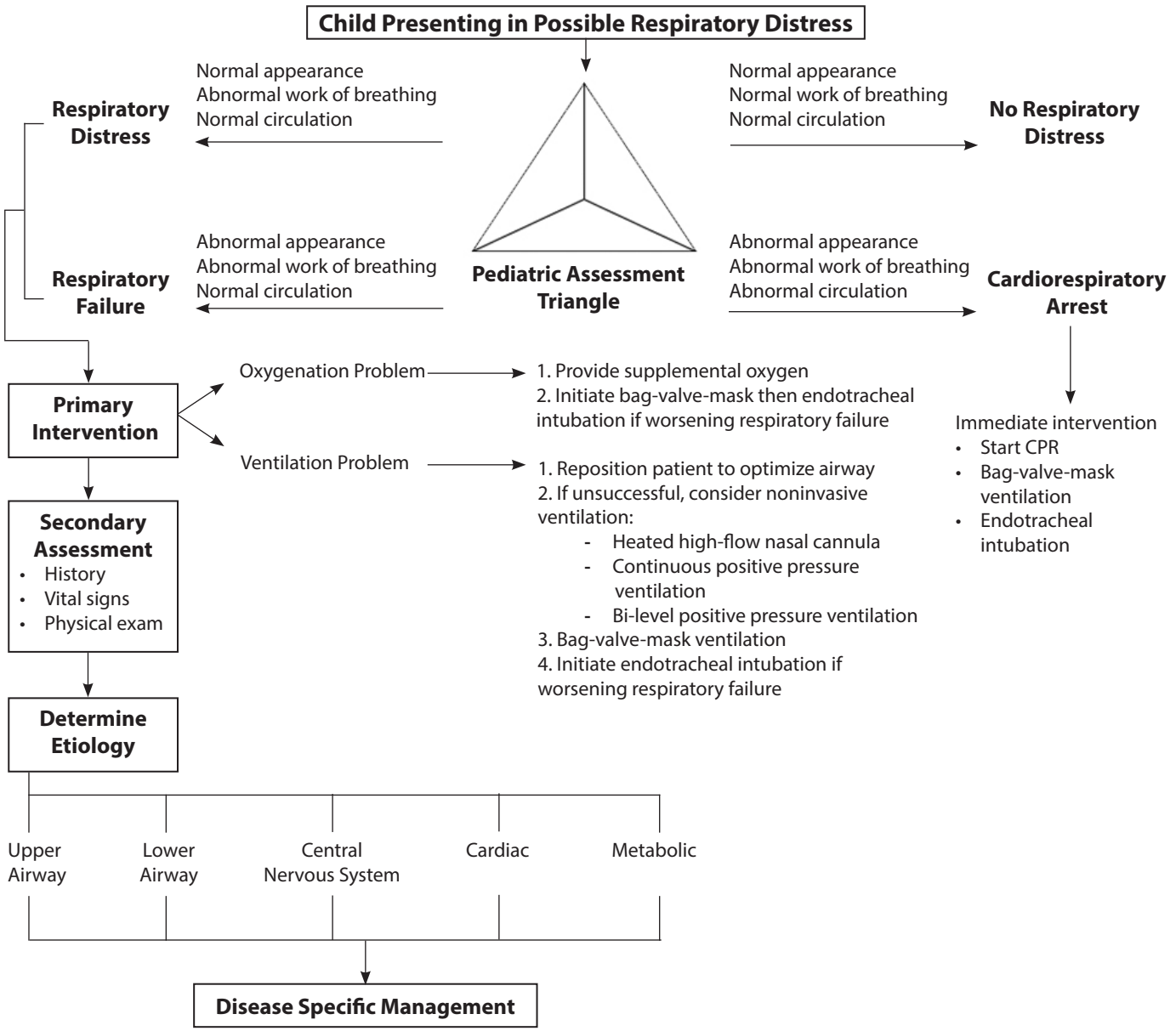

Source: Author created.

children with respiratory distress and also can manifest in children with dehydration and/or fever. Bradycardia in children with respiratory distress is a late finding and an ominous precursor of cardiorespiratory arrest.

The provider should be able to assess a child's respiratory status with the Pediatric Assessment Triangle within the first minute of observation. If the child is in respiratory distress and hypoxic, he or she should be given supplemental oxygen. If the child has a ventilation problem, adjuncts such as high-flow nasal cannula, continuous positive pressure ventilation (CPAP), and bi-level positive pressure ventilation (BiPAP) have been demonstrated to avert respiratory failure.[1,4-9] Primary interventions, such as providing supplemental oxygen or noninvasive ventilation (heated humidified high-flow nasal cannula, CPAP, or BiPAP), should be given to patients with significant oxygenation or ventilation deficits.

After initial intervention, a secondary assessment including a detailed history and exam should be performed for patients in respiratory distress or respiratory failure. Disease-specific diagnostic and management interventions should follow.

Sounds coming from the airway may assist the provider in localizing the affected part of the airway. Findings from a complete respiratory exam allow the practitioner to localize the origin of respiratory distress and initiate appropriate treatment.[10] (*See Table 3.*)

Stridor, stertor, and changes in vocal pitch (hoarseness, muffled voice, or a brassy cough) indicate an upper airway process or obstruction. Stridor can be inspiratory, expiratory, or biphasic, which can indicate the location of the obstruction. Inspiratory stridor generally is a sign of obstruction above the vocal cords, while expiratory

Table 1. Normal Pediatric Respiratory Rates

Age	Respiratory Rate (breaths/min)
< 1 year	30-60
1 to 3 years	24-40
4 to 5 years	22-34
6 to 12 years	18-30
13 to 18 years	12-16

Adapted from: American Heart Association. Systemic approach to the seriously ill or injured child. *Pediatric Advanced Life Support — Provider Manual.* Ashcraft J, ed. Dallas. 2011; 13.

Table 2. Normal Pediatric Heart Rates

Age	Awake Heart Rate (beats/min)	Sleeping Heart Rate (breaths/min)
Newborn to 3 months	85-205	80-160
3 months to 2 years	100-190	75-160
2 years to 10 years	60-140	60-90
> 10 years	60-100	50-90

Adapted from: American Heart Association. Systematic approach to the seriously ill or injured child. *Pediatric Advanced Life Support — Provider Manual.* Ashcraft J, ed. Dallas. 2011; 13.

stridor is an indication of obstruction in the trachea. Biphasic stridor is an indication of subglottic narrowing. Stertor is a sound characterized by heavy snoring or gasping and can localize obstruction above the larynx. It is caused by vibrations of the tissue in the naso-
pharynx, pharynx, or soft palate. A child who presents with significant drooling may have a substantial upper airway obstruction due to pooled secretions and a partially obstructed airway. Similarly, a prolonged inspiratory phase may indicate a supraglottic obstruction.

Signs of lower airway obstruction include grunting, wheezing, and crackles. Grunting is a low-pitched sound that is produced with exhalation against a closed glottis and is used to increase end-expiratory pressure and keep the alveoli open. Wheezing is a high-pitched musical sound that occurs in inflamed lower airways and can occur during both phases of breathing. Although common in patients with asthma, it does not always indicate this diagnosis. Crackles are caused by the abrupt opening of small lower airways that are obstructed by fluid, exudate, or lack of aeration during expiration. A prolonged expiratory phase is indicative of a lower airway obstruction.

Interventions: From Respiratory Distress to Respiratory Failure

Noninvasive Ventilation in the ED

Oxygen can be provided effectively to the majority of pediatric patients presenting in respiratory distress with the use of a nasal cannula or face mask. The nasal cannula is a well-established mode of delivery of oxygen therapy, but the amount of oxygen that can be delivered traditionally has been limited by poor tolerance of flow rates > 2 L/min in children.[7] The flow rate generally is 0.5 to 1 L/min for infants and 1 to 2 L/min for older children to prevent drying and discomfort of the nasal mucosa and other mucosal complications.[5,11] For older children, oxygen is best given by face mask.

Heated Humidified High-flow Nasal Cannula

Heated humidified high-flow nasal cannula is a noninvasive form of respiratory support that provides heated and humidified oxygen to patients via a nasal cannula interface, which prevents drying and discomfort of the nasal mucosa.[12] Compared to nasal cannula, heated humidified high-flow nasal cannula allows for adjustments to flow independent of FiO_2. For example, a patient can be on 10 L of nasal cannula flow.

There is no universally accepted definition of the minimum flow rate that defines "high" flow, and the optimal maximal flow for heated humidified high-flow nasal cannula is unknown.[5,12] Some studies report using age-based protocols, such as 2 L/min for patients younger than 6 months, 4 L/min for 6 to 18 months, and 8 to 12 L/min for infants and 20 to 30 L/min for children. Other studies have used weight-based dosing, such as 1 to 2 L/kg/min.[4,12] Although heated humidified high-flow nasal cannula provides some positive airway pressure based on flow rate, the pressure is variable and difficult to predict.[9]

Heated humidified high-flow nasal cannula most commonly is studied as an alternative form of respiratory support in which continuous positive airway pressure (CPAP) is indicated.[9] Outside of its role in infants with bronchiolitis, there is relatively limited evidence for heated humidified high-flow nasal cannula therapy in children.[7,13] A few studies have suggested that heated humidified high-flow nasal cannula may be more efficacious than nasal cannula oxygen and similarly efficacious as CPAP for providing noninvasive ventilator support.[12] The use of heated humidified high-flow nasal cannula and other forms of noninvasive positive pressure ventilation have decreased the need for intubation and mechanical ventilation in the pediatric population.[1,12] A recent large retrospective study of pediatric patients admitted to a tertiary care hospital ED for acute respiratory distress showed an 83% reduction in the frequency of intubations after the implementation of a pediatric heated humidified high-flow nasal cannula usage guideline.[1]

Although heated humidified high-flow nasal cannula reduced the need for endotracheal intubation in the ED, there was not a significant change in mortality or median pediatric intensive care unit (PICU) length of stay after the introduction of a high-flow nasal cannula pathway.[9]

Continuous Positive Airway Pressure

Noninvasive ventilation in the form of CPAP is another alternative to endotracheal intubation for pediatric patients presenting in severe respiratory distress. CPAP is a form of noninvasive positive pressure ventilation that applies continuous end-expiratory pressure to stent open the alveoli to recruit more surface area for ventilation. The CPAP apparatus is available as a nasal plug, a nasal mask that covers the nares, a face mask that covers both the nares and the mouth, or a complete face mask that covers the entire face. When CPAP is used, the recommendation is to start low pressures (5 cmH_2O) and increase in increments of 1 cmH_2O as tolerated by the patient for goals of an exhaled tidal volume

Table 3. Localization of Respiratory Distress by Physical Exam Findings

Exam Finding	Description	Localization
Tachypnea	Rapid rate of breathing above normal parameters for age Often the first sign of respiratory distress	**Nonspecific localization** • Can be due to obstruction of the upper or lower airway • Can also be due to anxiety
Bradypnea	Slow rate of breathing below the normal parameters for age	**Nonspecific localization** • Slow and large tidal breath volumes can indicate central control abnormalities • Can be used as a mechanism to minimize the turbulence and resistance in significant extrathoracic airway obstruction • Also, a nonspecific sign of fatigue
Changes in vocal pitch	Obstruction in different locations of the airway can lead to changes in the pitch of voice	**Upper respiratory tract** • Muffled voice: Indicates a supraglottic lesion • Weak/hoarse voice: Indicates a glottic lesion • Normal voice/brassy cough: Indicates a subglottic lesion
Cough	A protective reflex used to clear the airway of phlegm or irritants	**Nonspecific localization**
Drooling	May imply pooled secretions and a partially obstructed airway Usually indicates significant upper airway obstruction	**Upper respiratory tract**
Nasal flaring	The outward and inward flaring of the nares with inspiration Implies general respiratory distress	**Nonspecific localization**
Retractions	Use of accessory muscles to facilitate breathing	**Upper or lower respiratory tract**
Grunting	A sound produced by exhalation against a closed glottis; an attempt to increase functional residual capacity and lung volume to avoid alveolar collapse; used by children to provide increased end-expiratory pressure and keep the end airways open	**Lower respiratory tract**
Stridor	Noisy breathing that occurs due to obstructed airflow through a narrowed airway	**Upper respiratory tract** • Inspiratory stridor: Indicates obstruction above the vocal cords • Expiratory stridor: Indicates an obstruction in the trachea • Biphasic stridor: Indicates narrowing of the subglottis

Adapted from: Weiner DL. Acute respiratory distress in children: Emergency evaluation and initial stabilization. In: UpToDate. Waltham, MA: UpToDate. Available at: https://www.uptodate.com/contents/acute-respiratory-distress-in-children-emergency-evaluation-and-initial-stabilization. Accessed Feb. 23, 2018.

> 7 mL/kg, a respiratory rate of normal for given age, and oxygen saturation > 90%.[14]

The initiation of both CPAP and bi-level positive airway pressure (BiPAP) have been studied in adult populations in the ED; however, there is a paucity of studies in the pediatric population. Their application in pediatric emergency settings is difficult because of the limited compliance and cooperation of infants or children to tolerate a nasal plug, nasal mask, face mask, or complete face mask for CPAP delivery.[4] CPAP usually is tolerated only with some form of sedation, which can compromise respiratory drive. However, the introduction of dexmedetomidine, an α2-adrenergic receptor agonist that causes sedation without any respiratory depression, has provided an alternative to traditional sedation. The use of dexmedetomidine has been limited to the PICU.[4]

Large studies comparing heated humidified high-flow nasal cannula and CPAP are scarce. A small retrospective study comparing heated humidified high-flow nasal cannula and nasal CPAP in infants with acute bronchiolitis who were admitted to the PICU showed that there was no significant difference between groups for respiratory parameters (respiratory rate, PCO_2, FiO_2, and duration of oxygen support) or length of stay in the PICU, suggesting that heated humidified high-flow nasal cannula is as efficient as nasal CPAP in improving respiratory distress in infants with acute bronchiolitis.[15]

Bi-level Positive Airway Pressure

BiPAP is considered the strongest form of noninvasive respiratory support. It provides both an inspiratory peak airway pressure (IPAP) and an expiratory peak airway pressure (EPAP) for each breath. The level of pressure support in BiPAP is equivalent to the difference between the IPAP and EPAP. With BiPAP, the IPAP setting may range from 4 to 24 cmH_2O, while the EPAP setting may vary from

Table 3. Localization of Respiratory Distress by Physical Exam Findings (continued)		
Exam Finding	**Description**	**Localization**
Stertor	A sound that is characterized by heavy snoring or gasping. Caused by partial obstruction of the airway above the level of the larynx and by vibrations of the tissue of the nasopharynx, pharynx, or soft palate	**Upper respiratory tract**
Perioral cyanosis	A bluish discoloration of the lips due to an increased concentration of deoxygenated hemoglobin in the capillary bed	**Nonspecific localization** • General indicator of severe respiratory distress
Wheezing	High-pitched whistling sound that occurs in inflamed lower airways while breathing. Can occur during inspiration and expiration	**Lower respiratory tract**
Crackles (rales)	Brief discontinuous popping noises transmitted from the alveoli during inspiration. Crackles are caused by the "popping open" of small airways that are collapsed by fluid, exudate, or lack of aeration during expiration	**Lower respiratory tract**
Pleural rub	Audible sound produced when pleural layers of lung are inflamed and have lost their lubrication; occurs during inspiration and expiration	**Nonspecific localization**
Prolonged phases of breathing	Normally inspiration and expiration should occur in equal duration	**Upper or lower respiratory tract** • Prolonged inspiratory phase: Supraglottic obstruction • Prolonged expiratory phase: Lower respiratory tract obstruction
Tripod position	A wide-based position established while sitting by leaning over to support the upper body with the arms placed on either side of the thighs. Maximized recruitment of the accessory muscles and is a sign of impending respiratory failure	**Nonspecific localization**

Adapted from: Weiner DL. Acute respiratory distress in children: Emergency evaluation and initial stabilization. In: UpToDate. Waltham, MA: UpToDate. Available at: https://www.uptodate.com/contents/acute-respiratory-distress-in-children-emergency-evaluation-and-initial-stabilization. Accessed Feb. 23, 2018.

2 to 20 cmH_2O. Typical initial settings for BiPAP are 8 to 10 cmH_2O IPAP and 2 to 4 cmH_2O EPAP.[14] The mechanism of cycling between the two pressures reduces the stress on the diaphragm and accessory muscles by increasing the tidal volume and minute ventilation, opening obstructed alveoli, and decreasing the frequency of occlusive apnea and hypopnea.[16]

Traditionally, BiPAP has been used for pediatric patients with neuromuscular disorders, chronic lung disease, and obstructive airways. It has been limited to children weighing > 20 kg because of the concern that small children are incapable of initiating supported breaths while on BiPAP; however, recent studies have shown it to be a beneficial treatment modality for acute severe asthma exacerbations in children of all weights.[16]

Disease-specific Interventions

The next section will focus on the presentation and management of need-to-know pediatric respiratory illnesses encountered in the ED. (*See Table 4.*)

Foreign Body Aspiration

Background. Foreign body aspiration is the sixth most common cause of accidental death in children in the United States, with most cases occurring in preschool aged children.[17] A foreign body in the airway can present with nonspecific symptoms such as coughing, wheezing, fever, dyspnea, or hypoxia. In severe cases, it can cause complete obstruction leading to death. The most common anatomic location for a foreign body to lodge is the bronchi (80-90%), followed by the trachea (3-12%) and the larynx (2-12%).[18]

Presentation. Physical findings are variable depending on the size, location, and duration that the object has been in the airway. Children with complete obstruction of the larynx generally present in respiratory failure or cardiopulmonary arrest requiring a surgical airway or a rapid intubation with a small sized endotracheal tube and foreign body removal in the operating room.[19] Partial laryngeal obstruction can present as dysphonia, hoarseness, a cough, or stridor.[20] A tracheal foreign body can present with dysphonia, dysphagia, dry cough, and biphasic stridor.[20] A foreign body in the lower airway can present with asymmetrical breath sounds, wheezing, and tachypnea. Fever and pneumonia may be the presenting symptoms in cases in which the foreign body is undetected for a prolonged amount of time.

Diagnosis. If a foreign body aspiration is suspected in an otherwise stable patient, ED providers should proceed with the appropriate diagnostic workup and coordinate removal of the object. If possible, the plan for diagnostic workup should be made in conjunction with an otolaryngologist. Plain films are very sensitive for directly showing radiopaque foreign bodies, including all metals except aluminum, glass, and most animal bones.[21] Approximately 90% of foreign bodies are not radiopaque and include plastic objects, wooden objects, and most fish bones. Plain films may show indirect signs of air trapping, atelectasis, and consolidation.[21] As many as 80% of children with laryngotracheal foreign bodies and 30-50% of children with bronchial foreign bodies have normal chest radiographs; therefore, a normal appearing radiograph does not exclude foreign body.[1,21] In cases that are highly suggestive

Table 4. Need-to-know Pediatric Respiratory Emergencies	
System	**Disease**
Upper Airway	• Anaphylaxis • Foreign body • Trauma - Blunt/penetrating neck injury - Airway burns (thermal and chemical) • Laryngospasm • Epiglottitis • Croup • Mediastinal mass • Retropharyngeal abscess/peritonsillar abscess
Lower Airway	• Asthma • Tension pneumothorax • Pulmonary embolism (rare in children) • Pneumonia
Cardiac	• Cardiac tamponade • Acute decompensated heart failure
Central Nervous System	• Altered mental status • Neuromuscular weakness (multiple etiologies)
Metabolic	• Diabetic ketoacidosis • Toxic ingestion

Adapted from: Weiner DL. Acute respiratory distress in children: Emergency evaluation and initial stabilization. In: UpToDate. Waltham, MA: UpToDate. Available at: https://www.uptodate.com/contents/acute-respiratory-distress-in-children-emergency-evaluation-and-initial-stabilization. Accessed Feb. 23, 2018.

of a foreign body aspiration with a normal chest radiograph, a rigid bronchoscopy should be considered. Prompt bronchoscopy is essential, as a delay of more than 24 hours from presentation increases the incidence of complications, such as pneumonia.[21]

CT also may be considered in the diagnostic workup of a foreign body aspiration, as it is a superior imaging study when visualizing non-radiopaque foreign bodies that are undetectable on plain films and can clearly show different airway pathologies that may mimic foreign body aspiration. ED providers should obtain CT only in consultation with an otolaryngologist, considering the severity of symptoms, chronicity, and the radiation exposure.

Management. Rigid bronchoscopy performed by an otolaryngologist is the gold standard for removal of a foreign body in the airway.[19] Immediate intervention with direct visualization or rigid bronchoscopic removal of the foreign body is warranted when a child presents in severe respiratory distress. Immediate rigid bronchoscopy also is warranted for patients presenting after a witnessed aspiration event regardless of symptoms, or for patients with a choking episode or suggestive radiographic findings.[22]

Disposition/Prognosis. The longer that a foreign body is retained in the airway, the higher the likelihood of complications, such as secondary pneumonia, bronchiectasis, and atelectasis. Prompt removal is critical for a favorable outcome. No pediatric patient with a confirmed foreign body aspiration or with a high suspicion for a foreign body aspiration should be discharged from the ED. After completing a rigid bronchoscopy under general anesthesia, disposition should be determined by the subspecialty service. For patients with some suspicion of a foreign body but no definitive physical examination or imaging findings, observation in the ED or inpatient service for 12 to 24 hours is appropriate to watch for changes in respiratory status or evolving radiologic findings.[20]

Anaphylaxis

Background. Anaphylaxis is a severe, potentially life-threatening allergic reaction. The incidence and prevalence of anaphylaxis is higher than previously thought. Publications from the past five years reveal an incidence of between 50 and 112 episodes per 100,000 person-years, with an estimated prevalence of 0.3-5.1%. Figures are higher in children, particularly children 0 to 4 years of age. The frequency of admissions due to anaphylaxis has increased (five- to seven-fold in the last 10 to 15 years).[23] An anaphylactic reaction can occur within seconds to minutes of exposure to an allergen.

Presentation. There is no universal agreement on the definition and diagnosis of anaphylaxis. In 2005 and 2006, the National Institute of Allergy and Infectious Disease and Food Allergy and Anaphylaxis Network developed formal guidelines for the diagnosis and treatment of anaphylaxis.[24,25] (*See Table 5.*) Generally, anaphylaxis will involve a combination of skin or mucosal tissue, reduced blood pressure, gastrointestinal symptoms, and/or respiratory compromise. It can cause significant airway edema manifesting as dyspnea, wheezing, stridor, or hypoxemia, which can progress rapidly to cardiorespiratory arrest.

Diagnosis. The diagnosis of anaphylaxis is made by a thorough history and clinical exam.

Management. Management consists of administration of intramuscular epinephrine as well as fluids, antihistamines, and steroids. In addition to epinephrine, nebulized albuterol can be used as an adjunctive therapy for symptoms of bronchospasm.[26]

Disposition/Prognosis. There is no consensus for the duration of observation time following an anaphylactic episode. According to the most recent practice parameter, patients with moderate to severe anaphylaxis should be observed for a minimum of four to eight hours. A longer observation period with possible admission should be considered when: 1) risk factors for more severe anaphylaxis (e.g., history of severe asthma) are present; 2) the allergens have been ingested; 3) more than one dose of epinephrine is required; 4) pharyngeal edema is present; and 5) severe or prolonged symptoms (e.g., prolonged wheezing or hypotension) are noted.[26] Patients presenting with an anaphylactic episode should be prescribed an epinephrine autoinjector and trained on its use.

Croup

Background. Croup is the most common infectious cause of upper airway obstruction in children.[19] Usually, it is caused by viruses, most commonly parainfluenza virus and rhinovirus. Other viral causes include enterovirus, respiratory syncytial virus, influenza virus, and human bocavirus.[27]

Presentation. Croup usually presents with a viral prodrome of fever and cough

followed by respiratory distress and stridor in children ages 6 months to 6 years.

Diagnosis. The diagnosis of croup is clinical and is based on history and physical exam findings of a barky cough and stridor. Although stridor is a strong indicator of croup, it also is important to consider other potential diagnoses that present with stridor, including structural abnormalities such as vascular rings and laryngotracheomalacia.

Management. Croup can be managed with supportive therapy at home in most cases. Children presenting to the ED with audible stridor at rest should receive nebulized epinephrine and systemic steroids. A single dose of dexamethasone 0.15 to 0.6 mg/kg (max 10 mg) is sufficient and is indicated in all children with viral croup irrespective of severity.[27] If patients have persistent stridor at rest following the administration of nebulized epinephrine and systemic steroids, they require additional doses of nebulized epinephrine and hospital admission for observation.

Disposition/Prognosis. Observation for three to four hours following the administration of nebulized epinephrine is recommended prior to discharge from the ED because croup symptoms may recur because of the limited duration of action of the medication.[27] Other studies, both retrospective and prospective, suggest that patients treated with adrenaline may be safely discharged if their symptoms do not recur for at least two to three hours after treatment.[28,29] Patients who remain stable without any return of stridor at rest may be discharged from the ED. Patients do not require any additional medications for home use at discharge. Patients with croup who have lower oxygen saturations on presentation or past history of croup or intubation are more likely to have a prolonged or complicated hospital course.[30]

Table 5. Clinical Definition of Anaphylaxis

Anaphylaxis is highly likely when any one of the following three criteria are fulfilled:
Acute onset of an illness (minutes to several hours) with involvement of the skin, mucosal tissue, or both (e.g., generalized hives, pruritis or flushing, swollen lips-tongue-uvula) *and* at least one of the following: Respiratory compromise (e.g., dyspnea, wheeze/bronchospasm, stridor, reduced peak expiratory flow, hypoxemia) Reduced blood pressure or associated symptoms of end-organ dysfunction (e.g., hypotonia or collapse, syncope, incontinence)
Two or more of the following that occur rapidly after exposure to a likely allergen for that patient (minutes to several hours): Involvement of the skin or mucosal tissue (e.g., generalized hives, pruritis or flushing, swollen lips-tongue-uvula) Respiratory compromise (e.g., dyspnea, wheeze/bronchospasm, stridor, reduced peak expiratory flow, hypoxemia) Reduced blood pressure or associated symptoms (e.g., hypotonia or collapse, syncope, incontinence) Persistent gastrointestinal symptoms (e.g., cramping abdominal pain, vomiting)
Reduced blood pressure after exposure to a known allergen for that patient (minutes to several hours): Infants and children: low systolic blood pressure (age-specific) or > 30% decrease in systolic blood pressure Adults: systolic blood pressure < 90 mmHg or > 30% decrease from patient's baseline
Adapted from: Simons FE. Anaphylaxis. *J Allergy Clin Immunol* 2010;125:S162.

Epiglottitis

Background. Epiglottitis is defined by supraglottic inflammation secondary to a bacterial infection. In an eight-year retrospective (1998–2006) review of epiglottitis admissions, Shah et al found that epiglottitis continues to be a significant entity, with two uniquely vulnerable populations: infants (< 1 year of age) and the elderly (> 85 years of age). The pediatric cohort of patients (patients < 18 years of age) showed 34.4% were < 1 year of age, which had increased in frequency, representing 26.8% of pediatric patients in 1998 and 41.1% in 2006.[31]

Epiglottitis usually presents with high fever followed by rapid respiratory deterioration within a few hours. Historically, it was mostly commonly caused by *Haemophilus influenzae* type b; however, with vaccination against *H. influenzae* type b, it is now more commonly caused by *Streptococcus pyogenes* and *Staphylococcus aureus*.[27]

Presentation. Classically, children will present in severe respiratory distress with tripod positioning. Other characteristic presenting features are drooling, dysphagia, dysphonia, and dyspnea.

Diagnosis. Radiography may be helpful in evaluation but should be obtained only if the patient is not critically ill and it does not distress the patient. A portable lateral neck radiograph that visualizes an edematous epiglottis (the classic "thumb print" sign) may be helpful in diagnosis; however, absence of this sign does not rule out the diagnosis. The gold standard for diagnosis is direct visualization through laryngoscopy, which should be attempted only by a highly skilled professional.

Management. Management is established with rapid stabilization of the airway, often through endotracheal intubation. ED providers must take extra care not to destabilize the patient while providing treatment. Early consultation of anesthesiology and otolaryngology should be considered.

Disposition/Prognosis. Antibiotics should be initiated as early as possible. Patients with epiglottitis should be admitted to the hospital for antibiotic administration and close monitoring of their airway and intervention as needed.

Peritonsillar Abscess

Background. Peritonsillar abscess is the most common superficial neck infection. It is defined as a collection of pus located between the capsule of the palatine tonsil and the pharyngeal muscles.

Presentation. Peritonsillar abscess presents in older children and adolescents with acute tonsillitis, high fever, severe throat pain, and dysphagia.

Diagnosis. The diagnosis is clinical and may reveal trismus, foul-smelling breath, cervical adenopathy, and an edematous uvula pushed to one side. Peritonsillar abscess usually causes mild respiratory distress, which typically does not progress to respiratory failure.

Treatment. Treatment is achieved by administration of antibiotics and drainage.

Disposition/Prognosis. Children presenting with a peritonsillar abscess

require needle aspiration or incision and drainage, which can be performed by an experienced provider in the ED. Younger children may benefit from the procedure being completed in the operating room.

Retropharyngeal Abscess

Background. Retropharyngeal abscess usually presents in patients aged 6 months to 6 years with a median age range of 3 to 5 years. The peak incidence occurs before the lymph nodes in this potential space atrophy, making abscess formation much less common with increasing age. They usually are polymicrobial infections; however, the predominant bacterial species are *S. pyogenes*, *S. aureus*, and respiratory anaerobes.

Presentation. Patients usually present with a high fever, sore throat, inspiratory stridor, and difficulty swallowing. Often, torticollis patients will hyperextend their necks to decrease their airway obstruction.

Diagnosis. The diagnosis of a retropharyngeal abscess is made with a lateral neck radiograph or a computed tomography (CT) scan, which will reveal airway narrowing and widening of the retropharyngeal space. Imaging often is done in conjunction with otolaryngology because of the risk of respiratory decompensation.

Management. Management involves maneuvers to maintain airway patency, timely administration of antibiotics, and drainage of the abscess by otolaryngology.

Disposition/Prognosis. Children with a retropharyngeal infection should be hospitalized and managed in conjunction with an otolaryngologist.

Mediastinal Mass

Background. Although rare, mediastinal masses are absolute airway emergencies. A recent study investigating 120 cases of mediastinal masses showed that the most common etiology was a malignant neurogenic tumor followed by lymphoma.[32] They can present in a variety of ways, most commonly with respiratory symptoms. Patients are very tenuous and their airways can be difficult to manage.

Presentation. Most commonly patients will present with dyspnea, wheezing, or stridor depending on the degree of tracheal compression. Other symptoms may include fatigue, fever, back pain, or, in some cases, superior vena cava syndrome. Up to one-third of mediastinal masses in children are asymptomatic.[32] Most institutions have protocols involving rapid involvement of anesthesia to secure the airway and a PICU admission.

Diagnosis. Diagnosis is achieved through a screening chest radiograph or chest CT scan. Diagnostic workup should be coordinated carefully in conjunction with anesthesia, otolaryngology, and possibly oncology.

Treatment. Airway management should be performed in the ICU in consultation with anesthesia, otolaryngology, and oncology. As most mediastinal masses are oncologic in nature, management may involve timely administration of systemic steroids and initiation of chemotherapy and/or radiation. If the patient is stable, treatment is delayed until definitive oncologic diagnosis and oncologic staging are completed.

Disposition/Prognosis. Most patients are admitted to a PICU.

Lower Airway Obstruction

Lower airway obstruction may occur at the level of the trachea, bronchi, or bronchioles. It is most commonly due to infectious processes, although asthma, congenital disease, and foreign body inhalation also are common culprits. Typical findings include wheezing and lung hyperinflation in addition to the general findings of respiratory distress.

Bronchiolitis

Background. Bronchiolitis is a clinical diagnosis characterized by inflammation of the lower airways and increased mucous production in children younger than 2 years of age. Although bronchiolitis most typically is caused by respiratory syncytial virus, it can be caused by other viruses, including human rhinovirus, influenza, human metapneumovirus, and adenovirus.

Presentation. Usually children with bronchiolitis experience an onset of cold symptoms with worsening respiratory symptoms and respiratory distress by days 2 to 4 of illness. Patients with more severe illness will have increased work of breathing that may be accompanied by wheezing and intermittent crackles.

Diagnosis. Bronchiolitis is a clinical diagnosis. New American Academy of Pediatrics (AAP) guidelines for bronchiolitis do not recommend routine chest radiographs or trials of albuterol or epinephrine aerosols.[33] If a chest radiograph is obtained, there is usually some degree of peribronchial thickening consistent with a viral process. (*See Figure 3.*)

Management. Management includes providing respiratory support in the form of oxygen via nasal cannula or, in some cases, noninvasive positive pressure ventilation through high-flow nasal cannula or CPAP. Patients who progress to respiratory failure may require intubation. The 2014 AAP guidelines state that clinicians should not administer albuterol (or salbutamol) to infants and children with a diagnosis of bronchiolitis (Evidence Quality: B; Recommendation Strength: Strong Recommendation). Clinicians should not administer epinephrine to infants and children with a diagnosis of bronchiolitis (Evidence Quality: B; Recommendation Strength: Strong Recommendation). Nebulized hypertonic saline should not be administered to infants with a diagnosis of bronchiolitis in the ED. (Evidence Quality: B; Recommendation Strength: Moderate Recommendation).[33]

Disposition/Prognosis. Patients presenting with increased work of breathing, hypoxia, or those with copious secretions requiring frequent suctioning may be admitted to the hospital for respiratory support. Younger patients also may require hospitalization for intravenous fluid resuscitation due to dehydration from inability to feed because of respiratory distress.

Asthma

Background. Asthma is a chronic inflammatory process that affects the lower respiratory tract. Asthma is one of the most common causes of respiratory distress. It affects more than 6.2 million children in the United States younger than 18 years of age and accounted for 20 million ED visits in 2014.[34] Although asthma and asthma-like symptoms (reactive airway disease) caused by bronchospasm are common in childhood, few patients diagnosed with childhood asthma have persistent symptoms into adulthood.[35]

Presentation. Typically, patients with an asthma exacerbation will present with shortness of breath or chest tightness, an audible wheeze on auscultation, and possibly hypoxia. Although a decreased oxygen saturation generally is a reliable indicator of worsening respiratory status, it can be misleading in patients with asthma because of ventilation and perfusion (V/Q) mismatching. This may be apparent after the initial administration of a bronchodilator. For example, patients with asthma may experience a further decline in their oxygen saturation after

Figure 3. Bronchiolitis

Viral bronchiolitis presenting with cough in an 11-month-old girl. Chest radiographs demonstrate diffuse peribronchial thickening and mild hyperinflation, seen as flattening of the diaphragm and air anterior to the heart. This is better appreciated on the lateral view.

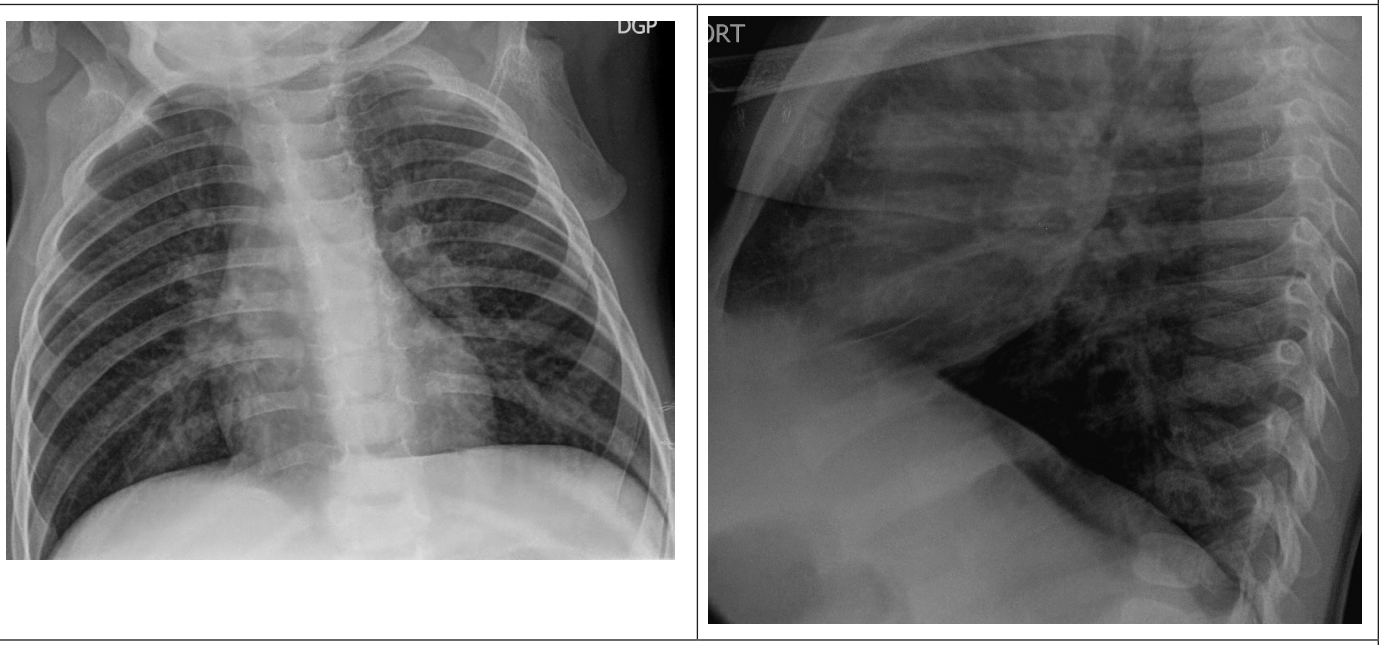

Images courtesy of N. Ewen Wang, MD.

Table 6. Steps in Management of Asthma

Step, Therapy	Notes
1. Albuterol, ipratropium, steroids	Order for all patients; give systemic corticosteroids in moderate or severe exacerbations or for patients who fail to respond promptly and completely to short-acting beta agonists; addition of inhaled ipratropium bromide in moderate to severe exacerbations
2. Continuous albuterol	0.5 to 1 mg/kg/hour If < 20 kg, give 10 to 20 mg/hour 20 to 30 kg, give 10 to 30 mg/hour > 30 kg, give 15 to 45 mg/hour
3. Intravenous magnesium	25 to 50 mg/kg/dose (max 2 g) infused over 20 to 30 minutes. Follow by continuous infusion of 15 to 25 mg/kg/hour. Magnesium level is approximately 4 mg/dL. Monitor for hypotension.
4. Heliox	Provide oxygen using non-rebreathing mask. May combine oxygen by nasal cannula if necessary to maintain SaO_2 > 92%
5. Intravenous terbutaline	Loading dose of 10 mcg/kg over 10 minutes followed by 0.4 mcg/kg/min. Increase by 0.4 mcg/kg/min every 15 minutes. Range 0.1 to 10 mcg/kg/min (average dose: 4 mcg/kg/min)
6. Intravenous theophylline	Loading dose of 5 mg/kg over 20 minutes followed by continuous infusion of 0.5 to 1 mg/kg/hour. Check serum theophylline concentration 30 minutes after the end of the loading dose. Target theophylline concentration is 10 to 20 mg/L.
7. Noninvasive ventilation	Consider bi-level continuous positive pressure to unload work of breathing. Inspiratory peak airway pressure: 10 Expiratory peak airway pressure: 5
8. Intravenous ketamine	1 mg/kg/hr for sedation in critical care setting; bronchodilatory properties; increase airway secretions.
9. Intubation (RSI agents)	Ketamine, midazolam, rocuronium
10. Ventilation	Try to avoid neuromuscular blockade; permissive hypercapnia; pressure control/pressure-regulated volume control/pressure support ventilation; monitor peak to plateau pressure difference.

Adapted from: Nievas IF, Anand KJ. Severe acute asthma exacerbation in children: A stepwise approach for escalating therapy in a pediatric intensive care unit. *J Pediatr Pharmacol Ther* 2013;18:88-104.

Table 7. Inpatient and Outpatient Treatment for Pediatric Pneumonia by Age

Age Group	Presumed bacterial pneumonia	Presumed atypical pneumonia	Presumed influenza pneumonia
Outpatient			
< 5 years of age(preschool)	Amoxicillin, oral	Azithromycin oral	Oseltamivir
	Alternative: oral amoxicillin clavulanate	Alternatives: oral clarithromycin or oral erythromycin	
≥ 5 years of age	Oral amoxicillin; for children with presumed bacterial CAP who do not have clinical, laboratory, or radiographic evidence that distinguishes bacterial CAP from atypical CAP, a macrolide can be added to a beta-lactam antibiotic for empiric therapy; alternative: oral amoxicillin clavulanate	Oral azithromycin; alternatives: oral clarithromycin; erythromycin, doxycycline for children > 7 years of age	Oseltamivir or zanamivir (for children ≥ 7 years of age); alternatives: peramivir, oseltamivir and zanamivir (all intravenous) are under clinical investigation in children; intravenous zanamivir available for compassionate use
Inpatient (all ages)			
Fully immunized with conjugate vaccines for *Haemophilus influenzae* type b and *Streptococcus pneumoniae*; local penicillin resistance in invasive strains of pneumococcus is minimal	Ampicillin or penicillin G; alternatives: ceftriaxone or cefotaxime; addition of vancomycin or clindamycin for suspected community acquired methicillin-resistant *Staphylococcus aureus* (CA-MRSA)	Azithromycin (in addition to beta-lactam, if diagnosis of atypical pneumonia is in doubt); alternatives: clarithromycin or erythromycin; doxycycline for children > 7 years of age; levofloxacin for children who have reached growth maturity, or who cannot tolerate macrolides	Oseltamivir or zanamivir (for children ≥ 7 years of age; alternatives: peramivir, oseltamivir and zanamivir (all intravenous) are under clinical investigation in children; intravenous zanamivir available for compassionate use
Not fully immunized for *H. influenzae* type b and *S. pneumoniae*; local penicillin resistance in invasive strains of pneumococcus is significant	Ceftriaxone or cefotaxime; addition of vancomycin or clindamycin for suspected CA-MRSA; alternative: levofloxacin; addition of vancomycin or clindamycin for suspected CA-MRSA	Azithromycin (in addition to beta-lactam, if diagnosis in doubt); alternatives: clarithromycin or erythromycin; doxycycline for children > 7 years of age; levofloxacin for children who have reached growth maturity or who cannot tolerate macrolides	As above

Adapted from: Bradley JS, Byington CL, Shah SS, et al. The management of community-acquired pneymona in infants and children older than 3 months of age: Clinical practice guidelines by the Pediatric Infectious Diseases Society and the Infections Diseases Society of America. *Clin Infect Dis* 2011;53:e34.

receiving albuterol, due to V/Q mismatch or intrapulmonary shunting, even though their overall clinical status is improving.[36] However, this decline in oxygen saturation should be temporary. Persistent decline in oxygenation and further respiratory distress would indicate deteriorating respiratory status.

Management. Management consists of rapid administration of albuterol, an inhaled beta-agonist, ipratropium, and systemic steroids. Most institutions have developed treatment pathways specifically for asthma. Patients with severe asthma may require adjunct medications including intravenous magnesium. Other potential therapies include terbutaline and/or aminophylline, usually instituted in the PICU. Severe refractory asthma may warrant noninvasive positive pressure ventilation or endotracheal intubation. Recent studies have shown decreased need for endotracheal intubation and improved outcomes with use of noninvasive positive pressure support.[7,16,37,38] (*See Table 6.*)

Disposition/Prognosis. Asthma patients presenting in mild exacerbations may return to baseline following a dose of systemic steroids and albuterol/ipratropium combination aerosols. Patients should be observed for a prescribed amount of time following aerosol administration to prevent recurrence of symptoms following discharge. Patients who remain stable following initial treatment may be discharged from the ED. Patients with persistent or refractory asthma symptoms require repeated doses of continuous albuterol, additional therapy, and prolonged observation in the ED or hospital.

Pneumonia

Background. Pneumonia is an infection of the lung parenchyma generally caused by a virus or bacteria. (*See Table 7.*)

Presentation. The clinical presentation of pneumonia in children varies greatly, depending on severity and the pathogen. Presenting symptoms may include shortness of breath, high fever, tachypnea, and hypoxia; symptoms can be subtle, particularly in infants. Pneumonia is a clinical diagnosis. However, if a patient presents with respiratory distress and unknown etiology, a chest radiograph can be used to rule out other diagnoses. (*See Figures 4 and 5.*)

Management. Treatment involves supporting respiratory status with administration of appropriate empiric antibiotics, and fluids when needed.

Figure 4. Pneumococcal Infection

(A, B) Pneumococcal pneumonia in a 5-year-old child. Frontal chest radiograph demonstrates air space consolidation in the left lower lobe with preservation of the left heart border (arrows); there is opacity overlying the spine on the lateral view (arrows). (C-D) Pneumococcal empyema in a 12-year-old patient. (C) Chest radiograph demonstrates almost complete opacification of the right hemithorax with irregular lucency in the right mid lung (arrow). It is uncertain whether the opacified hemithorax reflects fluid, atelectasis, or consolidated lung. (D) Contrast-enhanced CT clearly differentiates the large pleural effusion from the heterogeneously enhancing lung parenchyma containing an irregular air-filled cavity, findings suggesting necrotizing pneumonia and possible empyema. (E) Longitudinal ultrasound demonstrates multiple septations within the fluid, not well seen on CT, confirming a likely empyema rather than reactive effusion.

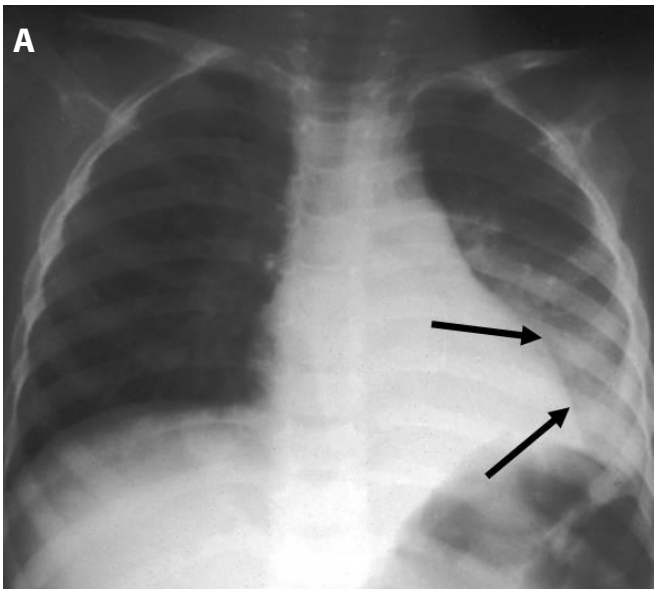

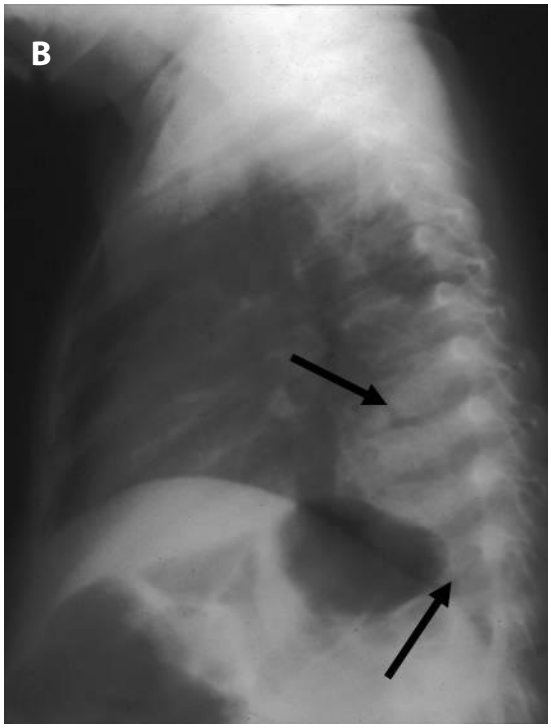

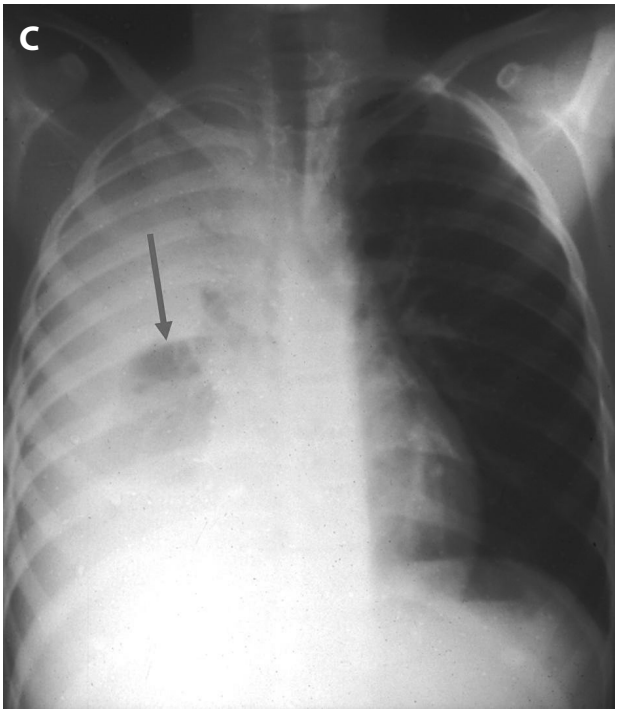

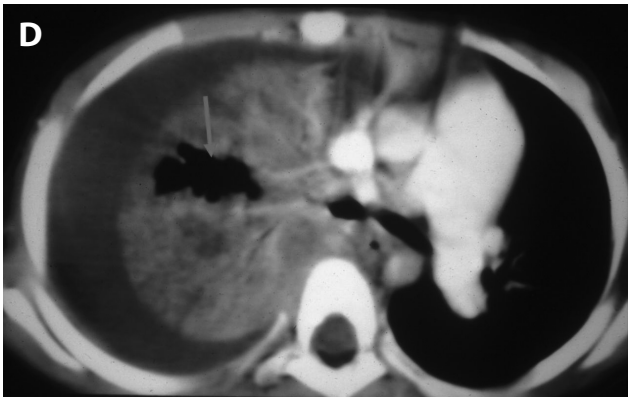

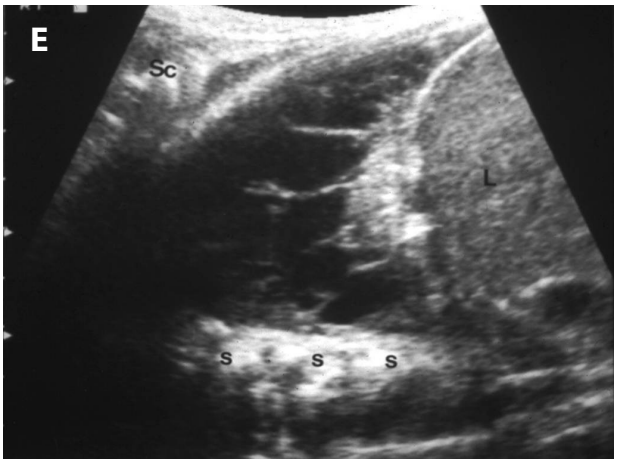

Sc: subcutaneous tissue; s: spine; l: liver
Images courtesy of N. Ewen Wang, MD.

Figure 5. Variable Pattern of *Mycoplasma* Pneumonia

(A) Frontal chest radiograph in a 7-year-old child shows patchy air space consolidation in both lungs (arrows). (B) Frontal chest radiograph in a 4-year-old child shows reticulonodular infiltrates in bilateral perihilar and lower lobes.

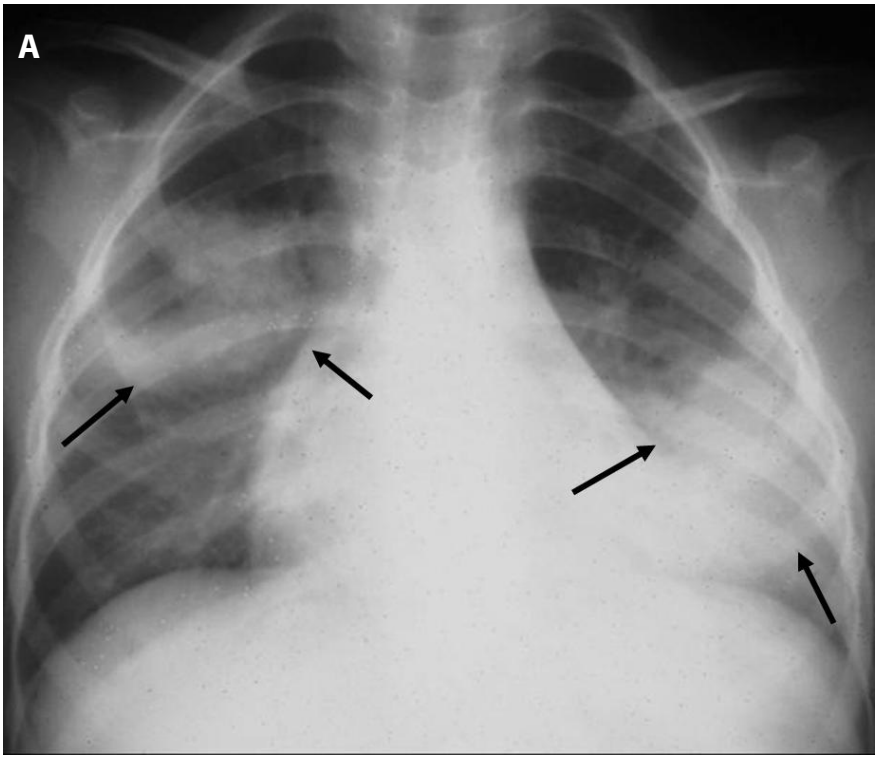

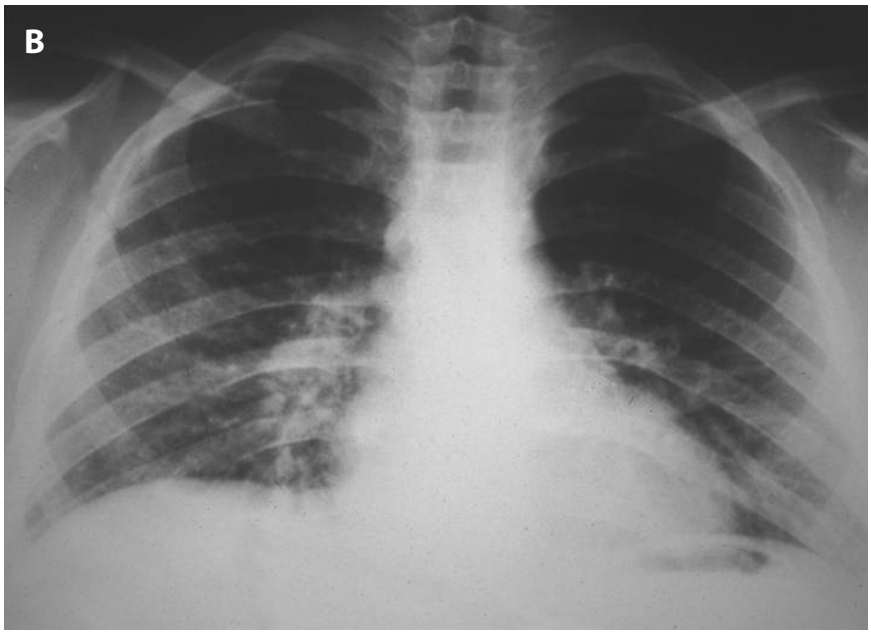

Images courtesy of N. Ewen Wang, MD.

Disposition/Prognosis. Otherwise healthy individuals presenting with an uncomplicated pneumonia who otherwise are stable may be discharged from the ED with a course of antibiotics. Pediatric patients with pneumonia in respiratory distress or with complicated pneumonia should be admitted to the hospital for observation, administration of intravenous antibiotics, and management of respiratory status. A complicated pneumonia involving a parapneumonic effusion may require drainage via thoracentesis or with placement of a chest tube.

Special Populations

Cystic Fibrosis

Cystic fibrosis is a multi-organ disease that primarily affects the lungs. Although it is a chronic process, people with cystic fibrosis intermittently can experience "pulmonary exacerbations." The exact definition of a pulmonary exacerbation has not been standardized; however, the clinical features include increased cough, increased sputum production, dyspnea, chest pain, weight loss, anorexia, and lung function decline.[39] Treatment for cystic fibrosis pulmonary exacerbations also lacks standardization. A recent study used clinical case examples to assess treatment for cystic fibrosis exacerbations and found wide variation among pulmonary centers and individual physicians.[40]

When a pediatric patient with cystic fibrosis presents to the ED with worsening pulmonary symptoms but is otherwise stable, providers should obtain a chest radiograph looking for pneumothorax as well as signs of hemorrhage and worsening infiltrate or atelectasis. Airway clearance therapy, usually with vest treatments and nebulized hypertonic saline, should be initiated rapidly. Both the frequency and duration of treatments should be increased for the duration of the exacerbation. Systemic antibiotics with *Pseudomonas* coverage also should be started as soon as possible. Patients with cystic fibrosis usually are followed by pediatric pulmonology specialists who, if available, can help guide treatment strategies and antibiotic selection. Providers should be judicious when selecting antibiotic therapy, paying attention to previous organisms that the patient has grown out in the past. Antibiotic selection, the need for bronchoscopy, and disposition should be decided in conjunction with a pulmonologist.

Scant to moderate hemoptysis also is common in cystic fibrosis patients.[39] Hemoptysis ≥ 5 mL can be considered a pulmonary exacerbation and is usually treated with antibiotics.[39] Caution is advised for cases of moderate to severe hemoptysis, given the need to balance effective airway clearance treatment with the concern of worsening hemoptysis.

Neuromuscular Disorders

Patients with neuromuscular disorders are at high risk of developing pulmonary infections as a result of their decreased ability to clear the airway. Recent studies have supported noninvasive ventilation combined with mechanical insufflation-exsufflation cough assist as a first-line treatment to manage acute respiratory failure in patients with neuromuscular disease.[41] Mechanical insufflation-exsufflation cough assist uses positive pressure to inflate the lungs slowly, followed by a burst of negative pressure in repeated cycles to produce coughing and promote airway clearance.

Most studies involving noninvasive ventilation in patients with neuromuscular disease have been conducted in intensive care settings and have correlated the use of noninvasive ventilation with decreased frequency of endotracheal intubation. Data for initiation of noninvasive support for these patients in the ED setting are limited; however, extreme caution must be taken if deciding on rapid sequence intubation, as depolarizing agents such as succinylcholine can cause a potentially massive potassium efflux, leading to fatal hyperkalemia, muscle fiber swelling, and rhabdomyolysis.[42]

Patients with neuromuscular disorders are at risk for aspiration, especially in the context of acute respiratory disease. When prescribing antibiotics, providers should consider coverage for atypical bacteria in addition to coverage of *Streptococcus pneumoniae* due to potential aspiration of normal flora.

Conclusion

The ability to identify and treat respiratory distress quickly is a critical skill for all ED physicians. Providers should be comfortable with rapidly identifying key components of the general and respiratory exam that aid in localizing the etiology of respiratory distress. ED providers should also know which circumstances call for rapid intervention and which require more disease-specific management.

References

1. Wing R, James C, Maranda LS, Armsby CC. Use of high-flow nasal cannula support in the emergency department reduces the need for intubation in pediatric acute respiratory insufficiency. *Pediatr Emerg Care* 2012;28:1117-1123.
2. Richards AM. Pediatric respiratory emergencies. *Emerg Med Clin North Am* 2016;34:77-96.
3. Dieckmann RA, Brownstein D, Gausche-Hill M. The pediatric assessment triangle: A novel approach for the rapid evaluation of children. *Pediatr Emerg Care* 2010;26:312-315.
4. Schibler A, Franklin D. Respiratory support for children in the emergency department. *J Paediatr Child Health* 2016;52:192-196.
5. Mikalsen IB, Davis P, Oymar K. High flow nasal cannula in children: A literature review. *Scand J Trauma Resusc Emerg Med* 2016;24:93.
6. Jat KR, Mathew JL. Continuous positive airway pressure (CPAP) for acute bronchiolitis in children. *Cochrane Database Syst Rev* 2015;1:CD010473.
7. Hutchings FA, Hilliard TN, Davis PJ. Heated humidified high-flow nasal cannula therapy in children. *Arch Dis Child* 2015;100:571-575.
8. Mas A, Masip J. Noninvasive ventilation in acute respiratory failure. *Int J Chron Obstruct Pulmon Dis* 2014;9:837-852.
9. Kelly GS, Simon HK, Sturm JJ. High-flow nasal cannula use in children with respiratory distress in the emergency department: Predicting the need for subsequent intubation. *Pediatr Emerg Care* 2013;29:888-892.
10. Weiner DL. Acute respiratory distress in children: Emergency evaluation and initial stabilization. In: UpToDate. Waltham, MA: UpToDate. Available at: https://www.uptodate.com/contents/acute-respiratory-distress-in-children-emergency-evaluation-and-initial-stabilization. Accessed Feb. 23, 2018.
11. Mathew JL, Singhi SC. Approach to a child with breathing difficulty. *Indian J Pediatr* 2011;78:1118-1126.
12. Slain KN, Shein SL, Rotta AT. The use of high-flow nasal cannula in the pediatric emergency department. *J Pediatr* (Rio J) 2017;93(Suppl 1):36-45.
13. Mayfield S, Jauncey-Cooke J, Hough JL, et al. High-flow nasal cannula therapy for respiratory support in children. *Cochrane Database Syst Rev* 2014;3:CD009850.
14. Stewart C. Noninvasive airway management techniques: How and when to use them. *Emerg Med Pract* 2001;3:7.
15. Metge P, Grimaldi C, Hassid S, et al. Comparison of a high-flow humidified nasal cannula to nasal continuous positive airway pressure in children with acute bronchiolitis: Experience in a pediatric intensive care unit. *Eur J Pediatr* 2014;173:953-958.
16. Williams AM, Abramo TJ, Shah MV, et al. Safety and clinical findings of BiPAP utilization in children 20 kg or less for asthma exacerbations. *Intensive Care Med* 2011;37:1338-1343.
17. Sahin A, Meteroglu F, Eren S, Celik Y. Inhalation of foreign bodies in children: Experience of 22 years. *J Trauma Acute Care Surg* 2013;74:658-663.
18. Rodriguez H, Passali GC, Gregori D, et al. Management of foreign bodies in the airway and oesophagus. *Int J Pediatr Otorhinolaryngol* 2012;76(Suppl 1): S84-S91.
19. D'Agostino J. Pediatric airway nightmares. *Emerg Med Clin North Am* 2010;28: 119-126.
20. Maraynes M, Agoritsas K. Inhaled foreign bodies in pediatric patients: Proven management techniques in the emergency department. *Pediatr Emerg Med Pract* 2015;12:1-14; quiz 15.
21. Hegde SV, Hui PK, Lee EY. Tracheobronchial foreign bodies in children: Imaging assessment. *Semin Ultrasound CT MR* 2015;36:8-20.
22. Ruiz FE. Airway foreign bodies in children. In: UpToDate Waltham, MA: UpToDate; 2017. Available at: https://www.uptodate.com/contents/airway-foreign-bodies-in-children. Accessed Feb. 23, 2018.
23. Tejedor Alonso MA, Moro Moro M, Mugica Garcia MV. Epidemiology of anaphylaxis. *Clin Exp Allergy* 2015;45:1027-1039.
24. Sampson HA, Munoz-Furlong A, Campbell RL, et al. Second symposium on the definition and management of anaphylaxis: Summary report — Second National Institute of Allergy and Infectious Disease/Food Allergy and Anaphylaxis Network symposium. *J Allergy Clin Immunol* 2006;117:391-397.
25. Sampson HA, Munoz-Furlong A, Campbell RL, et al. Symposium on the definition and management of anaphylaxis: Summary report — Second National Institute of Allergy and Infectious Disease/Food Allergy and

Anaphylaxis Network symposium. *J Allergy Clin Immunol* 2005;115:584-591.
26. Lieberman P, Nicklas RA, Randolph C, et al. Anaphylaxis — a practice parameter update 2015. *Ann Allergy Asthma Immunol* 2015;115:341-384.
27. Petrocheilou A, Tanou K, Kalampouka E, et al. Viral croup: Diagnosis and a treatment algorithm. *Pediatr Pulmonol* 2014;49:421-429.
28. Kelley PB, Simon JE. Racemic epinephrine use in croup and disposition. *Am J Emerg Med* 1992;10:181-183.
29. Corneli HM, Bolte RG. Outpatient use of racemic epinephrine in croup. *Am Fam Physician* 1992;46:683-684.
30. Narayanan S, Funkhouser E. Inpatient hospitalizations for croup. *Hosp Pediatr* 2014;4:88-92.
31. Shah RK, Stocks C. Epiglottitis in the United States: National trends, variances, prognosis and management. *Laryngoscope* 2010;120:1256-1262.
32. Gun F, Erginel B, Unuvar A, et al. Mediastinal masses in children: Experience with 120 cases. *Pediatr Hematol Oncol* 2012;29:141-147.
33. Ralston SL, Lieberthal AS, Meissner HC, et al. Clinical Practice Guideline: The Diagnosis, Management, and Prevention of Bronchiolitis. *Pediatrics* 2015;134:e1474-e1502.
34. Centers for Disease Control and Prevention. Asthma. Available at: https://www.cdc.gov/nchs/fastats/asthma.htm. Accessed Feb. 23, 2018.
35. Fuchs O, Bahmer T, Rabe KF, von Mutius E. Asthma transition from childhood into adulthood. *Lancet Respir Med* 2017;5:224-234.
36. Bates ML, Jacobson JE, Eldridge MW. Transient intrapulmonary shunting in a patient treated with beta(2)-adrenergic agonists for status asthmaticus. *Pediatrics* 2014;133:e1087-1091.
37. Abramo T, Williams A, Mushtag S, et al. Paediatric ED BiPAP continuous quality improvement programme with patient analysis: 2005-2013. *BMJ Open* 2017;7:e011845.
38. Pardue Jones B, Fleming GM, Otillio JK, et al. Pediatric acute asthma exacerbations: Evaluation and management from emergency department to intensive care unit. *J Asthma* 2016;53:607-617.
39. Stenbit AE, Flume PA. Pulmonary exacerbations in cystic fibrosis. *Curr Opin Pulm Med* 2011;17:442-447.
40. Kraynack NC, Gothard MD, Falletta LM, McBride JT. Approach to treating cystic fibrosis pulmonary exacerbations varies widely across US CF care centers. *Pediatr Pulmonol* 2011;46:870-881.
41. Chen TH, Hsu JH, Jong YJ. Noninvasive airway approaches for acute neuromuscular respiratory failure in emergency departments. *Pediatr Pulmonol* 2017;52:E55-e57.
42. Marsh S, Ross N, Pittard A. Neuromuscular disorders and anaesthesia. Part 1: Generic anaesthetic management. Continuing Education in *Anaesthesia Critical Care & Pain* 2011;11:115-118. Available at: https://academic.oup.com/bjaed/article/11/4/115/267032. Accessed Feb. 23, 2018.

CME/CE Questions

1. A 6-month-old male infant presents to the ED with two days of difficulty breathing. His vitals are T 37.9° C, BP 82/66, HR 120, RR 68, SpO_2 85% on room air, WT 6.4 kg. The infant has decreased energy with subcostal and intercostal retractions. On auscultation, he has patchy areas of diffuse crackles and a bilateral mild end-expiratory wheeze. His capillary refill is < 2 seconds. You diagnose that infant with bronchiolitis. How would you best support his respiratory status?
   a. 0.5 L/min of 100% oxygen via nasal cannula
   b. 12 L /min of 25% oxygen via heated humidified high-flow nasal cannula
   c. 6 L/min of 100% oxygen via face mask
   d. No respiratory support is required
2. A 4-year-old female is brought to the ED by her parents after she was witnessed choking on a peanut. She developed a mild intermittent cough but otherwise is afebrile and well-appearing. Her vitals are T 37.0° C, BP 100/78, HR 80, RR 22, SpO_2 100% on room air. On exam, you note that her breath sounds are mildly asymmetrical (R > L). Her chest X-ray shows air trapping of the right lung. What is the next best step?
   a. Consult otolaryngology (ENT) as this patient most likely will need a bronchoscopy.
   b. Attempt to remove foreign body with the Heimlich maneuver.
   c. Discharge the patient home, as the findings are most likely incidental.
   d. Intubate the patient in the ED and use forceps remove the foreign body.
3. A 24-month-old male is diagnosed with croup in the ED. On initial presentation, he has stridor at rest and receives both nebulized epinephrine and oral dexamethasone. His symptoms improve and he is observed for one hour. He remains stable with no rebound stridor at rest and is tolerating small sips of water. His mother asks if she can be discharged from the ED. Which is the best response?
   a. The patient is stable and can be discharged from the ED now.
   b. The patient should get another dose of epinephrine now and be observed for another two hours.
   c. The patient needs to be observed for at least another hour to monitor for recurrent stridor before he can be discharged.
   d. The patient should be admitted to the hospital for observation.
4. An 11-year-male with a history of cystic fibrosis presents to the ED with three days of a worsening cough and increased sputum production. Several members of his family have similar symptoms. He is afebrile with normal vitals on room air. A chest X-ray taken in the ED shows a small left lower lobe opacity. What is the next best step?
   a. Consult the patient's pulmonologist for antibiotic recommendations and admit the patient to the hospital for intravenous antibiotics and more frequent airway clearance therapy.
   b. Discharge patient home with oral antibiotics.
   c. Start high-dose oral steroids and admit the patient for observation.
   d. Administer intravenous steroids and oral steroids in ED in addition to continuous albuterol.

PEDIATRIC EMERGENCY MEDICINE REPORTS™ (ISSN 1082-3344) is published 12 times annually by AHC Media, a Relias Learning company. 111 Corning Road, Suite 250, Cary, NC 27518-9238. Telephone: (800) 688-2421.

Executive Editor: Leslie Coplin
Executive Editor: Shelly Mark
Editorial Group Manager: Terrey Hatcher
Senior Accreditations Officer: Lee Landenberger

GST Registration No.: R128870672

Periodicals Postage Paid at Cary, NC, and additional mailing offices.

POSTMASTER: Send address changes to ***Pediatric Emergency Medicine Reports,*** Relias Learning, 111 Corning Road, Suite 250, Cary, NC 27518-9238.

Back issues: $65. Missing issues will be fulfilled by customer service free of charge when contacted within one month of the missing issue's date.

SUBSCRIBER INFORMATION

CUSTOMER SERVICE: (800) 688-2421

Customer Service Email Address:
Customer.Service@AHCMedia.com

Editorial Email Address:
lcoplin@relias.com

Website:
AHCMedia.com

SUBSCRIPTION PRICES

1 year with 36 AMA, AAP or ACEP Category 1 credits: $349
Add $19.99 for shipping & handling

MULTIPLE COPIES:
Discounts are available for group subscriptions, multiple copies, site-licenses, or electronic distribution. For pricing information, please contact our Group Account Managers at Groups@AHCMedia.com or (866) 213-0844.

All prices U.S. only. U.S. possessions and Canada, add $30 plus applicable GST. Other international orders, add $30.

RELIAS
Formerly AHC Media

ACCREDITATION

Relias Learning is accredited by the Accreditation Council for Continuing Medical Education (ACCME) to provide continuing medical education for physicians.

Relias Learning designates this enduring material for a maximum of 3 *AMA PRA Category 1 Credits*™. Physicians should claim only credit commensurate with the extent of their participation in the activity.

Approved by the American College of Emergency Physicians for a maximum of 3 hours of ACEP Category I credit.

This continuing medical education activity has been reviewed by the American Academy of Pediatrics and is acceptable for a maximum of 3 AAP credits. These credits can be applied toward the AAP CME/CPD Award available to Fellows and Candidate Members of the American Academy of Pediatrics.

The American Osteopathic Association has approved this continuing education activity for up to 2.5 AOA Category 2-B credits.

Relias Learning LLC is accredited as a provider of continuing nursing education by the American Nurses Credentialing Center's Commission on Accreditation. Contact hours [3] will be awarded to participants who meet the criteria for successful completion. California Board of Registered Nursing, Provider CEP#13791.

This CME activity is intended for emergency and pediatric physicians and nurses. It is in effect for 36 months from the date of the publication.

This is an educational publication designed to present scientific information and opinion to health professionals, to stimulate thought, and further investigation. It does not provide advice regarding medical diagnosis or treatment for any individual case. It is not intended for use by the layman. Opinions expressed are not necessarily those of this publication. Mention of products or services does not constitute endorsement. Clinical, legal, tax, and other comments are offered for general guidance only; professional counsel should be sought for specific situations.

PEDIATRIC EMERGENCY MEDICINE REPORTS

Practical, Evidence-Based Reviews in Pediatric Emergency Care

Respiratory Distress in Pediatric Patients

Approach to the Pediatric Patient in Respiratory Distress

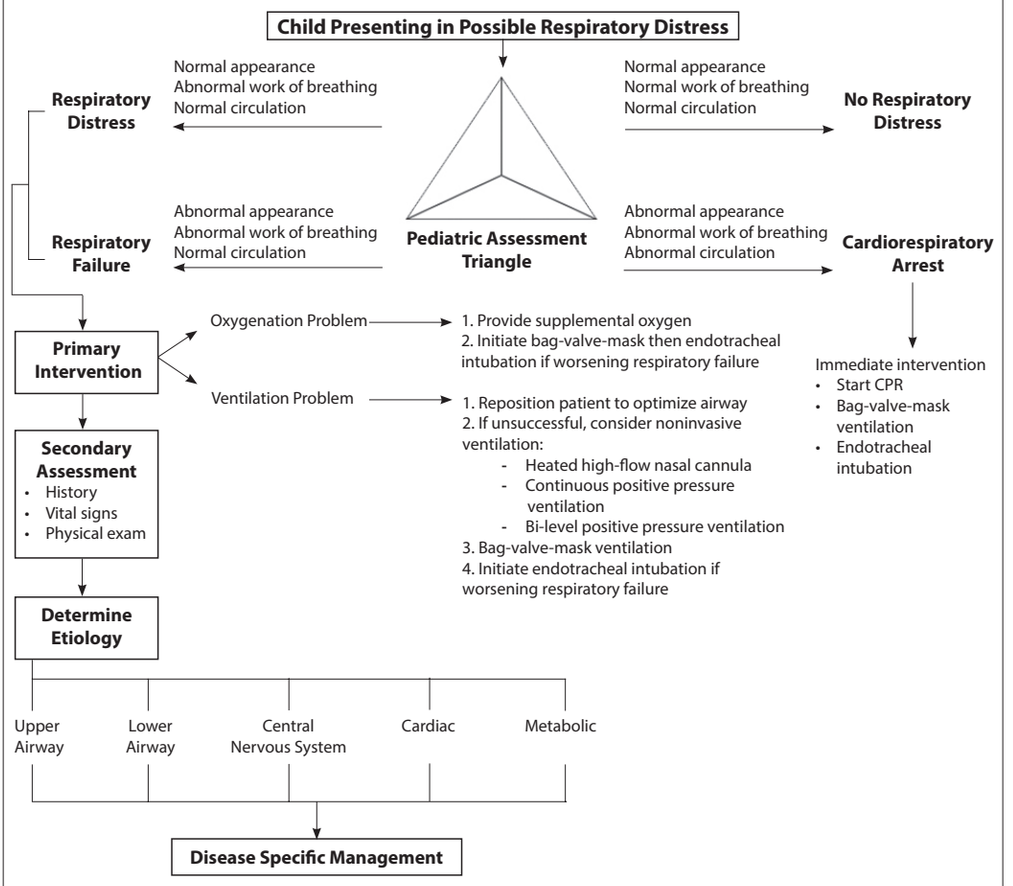

Source: Author created.

The Pediatric Assessment Triangle

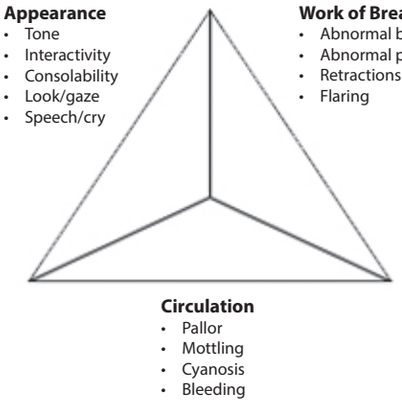

Adapted from: Dieckmann RA, Brownstein D, Gausche-Hill M. The pedatric assessment triangle: A novel approach for the rapid evaluation of children. *Pediatr Emerg Care* 2010;26:312-315.

Normal Pediatric Respiratory Rates

Age	Respiratory Rate (breaths/min)
< 1 year	30-60
1 to 3 years	24-40
4 to 5 years	22-34
6 to 12 years	18-30
13 to 18 years	12-16

Adapted from: American Heart Association. Systemic approach to the seriously ill or injured child. *Pediatric Advanced Life Support — Provider Manual.* Ashcraft J, ed. Dallas. 2011; 13.

Normal Pediatric Heart Rates

Age	Awake Heart Rate (beats/min)	Sleeping Heart Rate (breaths/min)
Newborn to 3 months	85-205	80-160
3 months to 2 years	100-190	75-160
2 years to 10 years	60-140	60-90
> 10 years	60-100	50-90

Adapted from: American Heart Association. Systematic approach to the seriously ill or injured child. *Pediatric Advanced Life Support — Provider Manual.* Ashcraft J, ed. Dallas. 2011; 13.

Localization of Respiratory Distress by Physical Exam Findings

Exam Finding	Description	Localization
Tachypnea	Rapid rate of breathing above normal parameters for age Often the first sign of respiratory distress	**Nonspecific localization** • Can be due to obstruction of the upper or lower airway • Can also be due to anxiety
Bradypnea	Slow rate of breathing below the normal parameters for age	**Nonspecific localization** • Slow and large tidal breath volumes can indicate central control abnormalities • Can be used as a mechanism to minimize the turbulence and resistance in significant extrathoracic airway obstruction • Also, a nonspecific sign of fatigue
Changes in vocal pitch	Obstruction in different locations of the airway can lead to changes in the pitch of voice	**Upper respiratory tract** • Muffled voice: Indicates a supraglottic lesion • Weak/hoarse voice: Indicates a glottic lesion • Normal voice/brassy cough: Indicates a subglottic lesion
Cough	A protective reflex used to clear the airway of phlegm or irritants	**Nonspecific localization**
Drooling	May imply pooled secretions and a partially obstructed airway Usually indicates significant upper airway obstruction	**Upper respiratory tract**
Nasal flaring	The outward and inward flaring of the nares with inspiration Implies general respiratory distress	**Nonspecific localization**
Retractions	Use of accessory muscles to facilitate breathing	**Upper or lower respiratory tract**
Grunting	A sound produced by exhalation against a closed glottis; an attempt to increase functional residual capacity and lung volume to avoid alveolar collapse; used by children to provide increased end-expiratory pressure and keep the end airways open	**Lower respiratory tract**
Stridor	Noisy breathing that occurs due to obstructed airflow through a narrowed airway	**Upper respiratory tract** • Inspiratory stridor: Indicates obstruction above the vocal cords • Expiratory stridor: Indicates an obstruction in the trachea • Biphasic stridor: Indicates narrowing of the subglottis
Stertor	A sound that is characterized by heavy snoring or gasping. Caused by partial obstruction of the airway above the level of the larynx and by vibrations of the tissue of the nasopharynx, pharynx, or soft palate	**Upper respiratory tract**
Perioral cyanosis	A bluish discoloration of the lips due to an increased concentration of deoxygenated hemoglobin in the capillary bed	**Nonspecific localization** • General indicator of severe respiratory distress
Wheezing	High-pitched whistling sound that occurs in inflamed lower airways while breathing. Can occur during inspiration and expiration	**Lower respiratory tract**
Crackles (rales)	Brief discontinuous popping noises transmitted from the alveoli during inspiration. Crackles are caused by the "popping open" of small airways that are collapsed by fluid, exudate, or lack of aeration during expiration	**Lower respiratory tract**
Pleural rub	Audible sound produced when pleural layers of lung are inflamed and have lost their lubrication; occurs during inspiration and expiration	**Nonspecific localization**
Prolonged phases of breathing	Normally inspiration and expiration should occur in equal duration	**Upper or lower respiratory tract** • Prolonged inspiratory phase: Supraglottic obstruction • Prolonged expiratory phase: Lower respiratory tract obstruction
Tripod position	A wide-based position established while sitting by leaning over to support the upper body with the arms placed on either side of the thighs. Maximized recruitment of the accessory muscles and is a sign of impending respiratory failure	**Nonspecific localization**

Adapted from: Weiner DL. Acute respiratory distress in children: Emergency evaluation and initial stabilization. In: UpToDate. Waltham, MA: UpToDate. Available at: https://www.uptodate.com/contents/acute-respiratory-distress-in-children-emergency-evaluation-and-initial-stabilization. Accessed Feb. 23, 2018.

Need-to-know Pediatric Respiratory Emergencies

System	Disease

Upper Airway	• Anaphylaxis
	• Foreign body
	• Trauma
	  - Blunt/penetrating neck injury
	  - Airway burns (thermal and chemical)
	• Laryngospasm
	• Epiglottitis
	• Croup
	• Mediastinal mass
	• Retropharyngeal abscess/peritonsillar abscess

Lower Airway	• Asthma • Tension pneumothorax • Pulmonary embolism (rare in children) • Pneumonia
Cardiac	• Cardiac tamponade • Acute decompensated heart failure
Central Nervous System	• Altered mental status • Neuromuscular weakness (multiple etiologies)
Metabolic	• Diabetic ketoacidosis • Toxic ingestion

Adapted from: Weiner DL. Acute respiratory distress in children: Emergency evaluation and initial stabilization. In: UpToDate. Waltham, MA: UpToDate. Available at: https://www.uptodate.com/contents/acute-respiratory-distress-in-children-emergency-evaluation-and-initial-stabilization. Accessed Feb. 23, 2018.

Supplement to *Pediatric Emergency Medicine Reports*, April 2018: "Respiratory Distress in Pediatric Patients." Authors: Chisom A. Agbim, MD, Pediatrics Resident, Lucile Packard Children's Hospital Stanford, Palo Alto, CA; N. Ewen Wang, MD, Professor, Emergency Medicine, Associate Director, Pediatric Emergency Medicine, Stanford University Medical School, Stanford, CA; and Moon Lee, MD, MPH, Quality Director of Pediatric Emergency Medicine, Assistant Professor, Stanford University Medical School.