PEDIATRIC EMERGENCY MEDICINE REPORTS

Practical, Evidence-Based Reviews in Pediatric Emergency Care

December 2018 VOL. 23, NO. 12

AUTHORS

Amanda L. Bogie, MD, FAAP, Section Chief and Fellowship Program Director, Pediatric Emergency Medicine, University of Oklahoma Health Sciences Center, Oklahoma City

Charles Paul Bogie III, MD, PhD, Ophthalmology Private Practice and Trauma, Oklahoma City

PEER REVIEWER

Kim Cooper, MD, Clinical Faculty of Ophthalmology, Lucile Packard Children's Hospital, Stanford, CA

STATEMENT OF FINANCIAL DISCLOSURE

To reveal any potential bias in this publication, and in accordance with Accreditation Council for Continuing Medical Education guidelines, we disclose that Dr. Dietrich (editor), Dr. Skrainka (CME question reviewer), Dr. Amanda Bogie (author), Dr. Charles Bogie III, (author), Dr. Cooper (peer reviewer), Ms. Wurster (nurse planner), Ms. Coplin (executive editor), Ms. Mark (executive editor), and Ms. Hatcher (editorial group manager) report no relationships with companies related to the field of study covered by this CME activity.

RELIAS MEDIA

Pediatric Ocular Trauma: A Clinical Perspective

Eye trauma can be devastating to a child and challenging to the clinician. These authors review common traumatic eye injuries and provide tips for the clinical evaluation of our youngest patients.

— Ann Dietrich, MD, FAAP, FACEP, Editor

Ocular trauma can result from blunt, penetrating, or other traumatic injuries to the eyeball, such as a blast or chemical injury. Ocular adnexal trauma refers to injuries of the adjacent tissues, such as the eyelids, eyebrows, conjunctiva, lacrimal gland, and orbit. It is estimated that 18 million people worldwide are affected by blindness caused by traumatic injury, with a disproportionate number occurring in the pediatric population.[1,2] In the United States, approximately 2.4 million eye injuries occur yearly, with 35% in children 17 years of age and younger.[3] Cataracts, refractive errors, and glaucoma are the leading causes of blindness in adults, but ocular trauma is the leading cause of acquired blindness and the second leading cause of visual loss in the pediatric population.[4,5] Ocular trauma accounts for 8-14% of total childhood injuries, and nearly 8% of children registered in the National Pediatric Trauma Registry sustained ocular injury.[5,6]

Over a one-year period, it was estimated that more than 7,500 children and young adults (< 20 years of age) across the United States were hospitalized with significant ocular trauma as the primary or secondary diagnosis.[4] The demographics suggest a high male-to-female ratio, with a trend toward increasing incidence of sports-related injury for older children.[2] More than 440,000 children (< 17 years of age) visited U.S. emergency departments (EDs) between 1990 and 2012 for sports- and recreation-related eye injuries.[7] Boys sustain open globe injuries more often than girls, most commonly at home and due to penetration with a sharp object, further emphasizing the importance of prevention and parental oversight in avoiding these injuries in this population.[3,8] These statistics justify placing a high priority on ocular injury prevention and treatments supported by sound academic rigor.

Fortunately, from 1992 to 2002 and 2006 to 2014, the annual incidence of pediatric ocular injury declined, which can be attributed to various causes, including improved handgun safety and legislation, airbag modifications, and improvement in household chemical safety.[8,9] Even the worrisome trend toward a more sedentary lifestyle in childhood is cited as a cause of declining injury by exposing children to fewer kinetic forces. Other authors have included seat belt usage and automobile glass improvements as additional reasons for the declining trend.[10] Despite a general decline of 26% in pediatric ocular trauma from 2006 to 2014, the areas of sport injury and animal bites showed a trend of increasing incidence.[8] This is despite the American Academy of Pediatrics' 2004

EXECUTIVE SUMMARY

- Ocular trauma accounts for 8-14% of total childhood injuries, and nearly 8% of children registered in the National Pediatric Trauma Registry sustained ocular injury.
- If the mechanism or observable extent of the injury suggests that the globe may be violated, the practitioner should minimize further attempts at examination, place an eye shield over the affected eye, and consider sedation. Considerable iatrogenic injury may result if intraocular contents are expelled during attempts to restrain and examine an uncooperative child. If an open globe is even suspected, this circumstance requires an exam under anesthesia by an ophthalmic surgeon capable of immediate treatment.
- Sedation can be useful; however, ketamine, which is used commonly for procedural sedation in pediatric EDs, may be contraindicated in the ophthalmic exam because of the induced nystagmus and potential increase in intraocular pressure changes.
- A larger subconjunctival hemorrhage that involves the entire sclera, encircling the cornea in a 360-degree pattern, is highly suggestive of a ruptured globe and deserves further detailed examination and ophthalmologic consultation.
- Traumatic corneal or conjunctival epithelial defects are common in infants and children, with self-induced fingernail injury playing a significant role. Presenting complaints vary from minimal symptoms to unusual irritability, significant foreign body sensation, tearing, and photophobia. In young infants, it has been well reported that corneal abrasions are a potential cause of the irritable, afebrile infant.
- Traumatic iritis typically presents one to three days following blunt trauma and involves complaints of photophobia (sometimes extreme), pain, redness, and possible visual loss. Absence of concurrent corneal injury and lack of response to topical anesthetic are typical.
- Although retinal hemorrhages can be seen with a direct ophthalmoscope, ophthalmological consult is required for verification and confirmation in the face of legal ramifications. Emergency medicine personnel are encouraged to maintain a high index of suspicion for nonaccidental trauma in any case involving retinal hemorrhages.
- Recent focus on pediatric concussive syndromes associated with contact sports has identified an entity called vestibular-ocular motor dysfunction (VOMD) and is associated with visual difficulty and disruption of the vestibular-ocular reflex. This reflex elicits eye movement by stimulating the vestibular system to stabilize images on the retina during movement of the head, thus preserving the image on the center of the visual field. Vestibular-ocular dysfunction associated with concussion may be responsible for some of the vague and poorly described visual complaints common after concussions and may be seen in as many as 60% of sports-related concussions. VOMD often is under-appreciated in concussion; a new screening tool is proposed to identify patients at risk, but its utility remains to be determined.

recommendations for protective eye wear to be worn while participating in high-risk sports.[11]

Ocular injuries in children after major trauma are not rare. Serious ocular injuries associated with motor vehicle collisions should be suspected with injury severity scores of 15 or higher. Significant ocular injuries even have been found in the absence of open adnexal wounds in patients with significant mechanism of injury.[12]

Examination

Examination of the traumatized child can be difficult regardless of the injury's location. Pain and anxiety are compounded in the presence of an ocular injury. The approach to ocular examination, involving bright lights and positioning in the slit lamp, does little to calm a child's fear. Careful planning and preparation are required to ensure an adequate exam is accomplished on the first attempt. The age of the child, mechanism of injury, potential extent of the injury, and current level of pain will influence the examiner's approach. Of primary concern is the presence of an open globe injury. If the mechanism or observable extent of the injury suggests that the globe may be violated, the practitioner should minimize further attempts at examination, place an eye shield over the affected eye, and consider sedation. Considerable iatrogenic injury may result if intraocular contents are expelled during attempts to restrain and examine an uncooperative child. If an open globe is even suspected, this circumstance requires an exam under anesthesia by an ophthalmic surgeon capable of immediate treatment.

When the injury is not suggestive of an open globe, sedation and/or restraint of the child may become necessary. Although children with ocular trauma often will not be able to participate in the exam, planning and a few "tricks of the trade" can elicit participation from initially reluctant children as young as 4 years of age. First, a few drops of any topical anesthetic should be instilled by the ancillary staff. The eventual examiner will not want to participate at this point because of the momentary pain associated with the drops and the physical restraint required to apply them. Then the child can be left alone with the family for a few minutes to allow both the pain and anxiety to subside. The immediate and complete pain relief from a corneal injury that is provided by the topical anesthetic is invaluable in allowing subsequent slit lamp examination, but it can be short lived. A good rule of thumb is that the anesthetic is effective in 20 seconds and lasts 20 minutes.

Prior to approaching the child with a slit lamp, the examiner must be familiar with its operation and assured of its functionality. The window of opportunity for examination may pass while changing bulbs or locating a working electric outlet. Asking a trusted family member to position himself or herself in the slit lamp before moving on to the child also will increase the likelihood of success. Begin the slit lamp examination with a low-intensity beam and slowly

Figure 1. Paper Clips as Eyelid Retractors



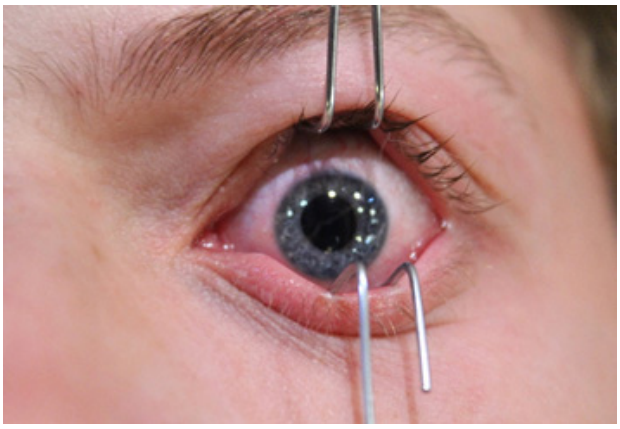

Source: Charles Paul Bogie III, Ophthalmology Private Practice and Trauma

increase the light to minimize the initial shock and keep the skittish child in place. Although physically manipulating the eyelids may be required, initially allowing the child to sit in the slit lamp without any contact from the examiner may provide the child with some level of comfort before "helping" with the eyelids. Finally, having a family member hold a toy on the examiner's ear may help control the patient's gaze direction. A skilled examiner can convince children as young as 5 years of age into a successful slit lamp examination.

All eye examinations must include an attempt to record visual acuity, as it is one of the most important predictors of visual outcome. Detailed and precise visual acuity measurements rarely are obtainable from the injured child; however, the examiner almost always can develop a rough sense of the level of visual acuity in the injured eye. Children between 6 months and 2 to 3 years of age should be able to fix and follow an object, face, or light source. Sometime after 2 to 3 years of age, visual acuity can be examined using a more objective chart. Most physicians are familiar with the traditional Snellen chart, but similar measurements can be made using a chart with pictures, or "tumbling E," or using one of the many apps available for smartphones. Patients unable or unwilling to participate in a formal evaluation of visual acuity still can be evaluated by identifying objects in the room or on the television, reading a clock, counting fingers, or identifying the presence and location of a light source. Comparison to the uninjured eye is important, and vision in both eyes should be documented in the medical record.[13]

Physical restraint and sedation may be necessary for an effective examination in some ocular injuries. It is imperative that the possibility of an open globe injury be considered and eliminated prior to using any physical restraint to aid the exam. Sedation can be useful; however, ketamine, which is used commonly for procedural sedation in pediatric EDs, may be contraindicated in the ophthalmic exam because of the induced nystagmus and potential increase in changes to intraocular pressure. In addition to papoosing in a blanket, it is useful to place the child in a C-collar to control flexion and extension of the head with an assistant holding the head to prevent rotation. Despite sedation, the restrained child will close his or her eyes tightly. Dry gauze beneath a gloved finger helps manipulate the wet periocular skin, but edematous lids still may require more retraction. Although Desmarres eyelid retractors are a common intraoperative tool, they rarely are available in a busy pediatric ED; bent paper clips may serve as a good substitute.[14] (*See Figure 1.*) However, never use any instrument to open the eye or irrigate unless the patient has had topical anesthesia placed in the eye.

Anatomy

Ocular adnexal structures include the eyelids, eyebrows, conjunctiva, lacrimal gland, and lacrimal drainage system. Common adnexal injuries include eyelid lacerations, lacrimal duct lacerations, foreign bodies, injury to extraocular muscles, and orbital fractures. The globe is divided into anterior and posterior segments. Anterior segment structures include the cornea, anterior chamber, lens, and ciliary body. Common anterior segment injuries include chemical injury, corneal and conjunctival abrasions and lacerations, corneal foreign bodies, hyphema, traumatic iritis, and traumatic cataract. Posterior segment injuries include damage to the vitreous and retina, retained intraocular foreign bodies, and the retinal or optic nerve effects of blunt trauma.

Types of Injury

Hyphema

A collection of blood in the anterior chamber, hyphema is a common complication of ocular trauma and requires urgent ophthalmologic consultation. A hyphema can vary from a few suspended erythrocytes (Grade 0) visible only by slit lamp to up to 100% of the anterior

Figure 2. Hyphema Occupying Anterior Half of Eye

Source: Author: Rakesh Ahuja, MD. Courtesy of the Creative Commons licensing agreement, Copyright 2006; Wikipedia. Accessed July 26, 2018.

Table 1. Hyphema Clinical Pearls

- Avoid aspirin-containing products.
- The size of the initial hyphema does not correlate with the chance of rebleed but does correlate with the risk of elevated intraocular pressure.
- Have a high suspicion for a ruptured globe.
- Although rare in the absence of trauma, other diagnoses, such as leukemia, juvenile xanthogranuloma, coagulopathy, or retinoblastoma, must be considered.
- Nonaccidental trauma always must be considered.

chamber filled with blood (eight-ball hyphema; Grade IV). (*See Figure 2.*) Patients will present with pain, photophobia, and decreased visual acuity and may demonstrate either an increase or decrease in intraocular pressure (IOP). A lower-grade hyphema typically will clear within one to two weeks, but the potential for rebleeding occurs around days 5-7 as the initial clot undergoes remodeling. Rebleeding is associated with a greater risk of complications, such as corneal blood staining and glaucoma. Any patient at risk for sickle cell trait or disease must undergo laboratory evaluation when their sickle cell status is unknown. Patients with either sickle cell trait or disease have a significantly increased risk of elevated IOP in the presence of a hyphema.[15,16] All hyphemas should be evaluated by an ophthalmologist. See Table 1 for hyphema clinical pearls.

Eyelid Lacerations

The depth and location of an eyelid laceration guides the need for further ophthalmologic consultation. Partial thickness lacerations that are lateral to the lacrimal puncta and with no lid margin involvement can be closed primarily in the ED. This type of laceration repair in the ED is well within the scope of emergency medicine practice and routinely results in excellent outcomes. However, lacerations that involve the lid margin or medial canthal areas (requiring investigation of the lacrimal drainage system) call for urgent ophthalmologic consultation. (*See Figures 3 and 4.*) If closure in the ED is elected, the choice of suture material and technique mirrors that of other facial injuries. It is preferable to choose a 6-0 or smaller suture, with a trend toward absorbable suture material in younger patients. With care, tissue adhesives can be used successfully in well-chosen eyelid or eyebrow lacerations. These wounds tend to be smaller, linear, non-gaping, and follow or parallel the eyelid crease. Lacerations resulting from an animal bite should be closed with sutures, not tissue adhesive. See Table 2 for eyelid lacerations clinical pearls.

Subconjunctival Hemorrhage

Subconjunctival hemorrhage (SCH) secondary to trauma occurs because of episcleral and conjunctival blood vessel involvement and usually is uncomplicated.[16] The examiner must maintain an index of suspicion for additional significant trauma, such as orbital fractures, corneal or conjunctival lacerations, or a ruptured globe. A larger SCH that involves the entire sclera, encircling the cornea in a 360-degree pattern, is highly suggestive of a ruptured globe and deserves further detailed examination and ophthalmologic consultation.[16-19] Isolated and uncomplicated SCH requires no intervention, and most will resolve slowly over one to two weeks. SCH in the setting of significant trauma needs a complete dilated eye exam by an ophthalmologist. In older patients without a history of trauma, check blood pressure for hypertensive crisis and ask about blood thinners (including aspirin, ibuprofen, or homeopathic products) and activities such as heavy lifting, bending, or straining (coughing or vomiting).

Conjunctival and Corneal Abrasions

Corneal abrasions secondary to trauma represent up to 3% of all ED visits and usually are associated with a good prognosis.[20] In the cornea, the epithelium can be cleanly abraded or separated from the underlying stroma along a relatively weak dissection plane. This usually results in a complete loss of epithelium in one geographic area without injury to the underlying

Figure 3. Eyelid Laceration

Source: Charles Paul Bogie III, Ophthalmology Private Practice and Trauma

Figure 4. Eyelid Laceration With Lid Margin Involvement

Source: Image courtesy of Blake Forcina, MD, Children's Eye Care, Oklahoma City, OK

basement membrane or stroma. (*See Figure 5.*) Traumatic corneal or conjunctival epithelial defects are common in infants and children, with self-induced fingernail injury playing a significant role.[21,22] Presenting complaints vary from minimal symptoms to unusual irritability, significant foreign body sensation, tearing, and photophobia. In young infants, it has been well reported that corneal abrasions are a potential cause of the irritable, afebrile infant.[22-24]

Table 2. Eyelid Lacerations Clinical Pearls

- Lacerations medial to or overlying the lacrimal puncta require probing and irrigation to determine canalicular involvement.
- Maintain a high index of suspicion for foreign body, ruptured globe, and deeper injury.
- The need for tetanus prophylaxis and/or antibiotics in injuries involving animals must not be overlooked.
- The presence of orbital fat should alert the physician to a deeper laceration.

See Table 3 for corneal abrasion clinical pearls.

Infants also may present with a chief complaint of "not waking up" or lethargy because they refuse to open their eyes. The differential diagnosis of the irritable or lethargic infant who is well-appearing and afebrile should include an exam for a corneal abrasion. Topical anesthetics can be both therapeutic (temporary pain relief) and diagnostic, causing the previously "sleeping" infant to become rapidly more alert. Abrasions may be detected with fluorescein dye, which stains the permeable, exposed corneal stroma but not the surrounding intact epithelium. Treatment for corneal abrasions remains controversial, despite its prevalence.

The safety and efficacy of topical nonsteroidal anti-inflammatory drops, topical antibiotics, and patching remain unsupported by good randomized clinical trials.[21,25-31] The dogma against the use of topical anesthetics outside of the ED also is questioned. In adults, the short-term use of topical tetracaine for pain control in uncomplicated, non-infectious corneal abrasions has been shown to be safe and efficacious.[32,33] Our own randomized clinical trial comparing placebo to topical tetracaine for 24 hours of outpatient use also demonstrated no detrimental side effects. In adult patients, any use of topical anesthetics for outpatient pain management limits the potential for severe and long-term corneal injury by dispensing only 1 to 2 mL of volume. Providers should

Figure 5. Abrasion



Source: Image courtesy of Blake Forcina, MD, Children's Eye Care, Oklahoma City, OK

Table 3. Conjunctival and Corneal Abrasions Clinical Pearls

- Always apply topical anesthetics before any exam to decrease patient pain and increase cooperation.
- Patients often complain persistently of a foreign body sensation with no foreign body found.
- Avoid an iatrogenic corneal abrasion by moistening the fluorescein strips with topical anesthetic drops and allow the drops to fall into the palpebral fissure or touch only the inner aspect of the lower lid and not the eye itself. Otherwise, you can create a corneal abrasion.
- Fluorescein is completely nontoxic and may be reapplied.

maintain personal control of the larger bottles of topical anesthetic at all times because of the risk of diversion, abuse, and long-term corneal injury. Although the authors of these studies did not look at pediatric patients specifically, the era of focused pain management, complicated by the national opioid crisis, warrants further study in this area. Given the lack of consensus on corneal abrasion management, tailored patient-specific treatment would appear to be the best option.

Corneal Foreign Body

Ferrous and non-ferrous metals, plant material, and sand represent common retained corneal foreign bodies. (*See Figure 6.*) In patients complaining of a foreign body sensation, eye rubbing is a complicating factor. Even children who are old enough to tolerate a slit lamp examination may not be stoic enough to allow for foreign body removal. As in the case of corneal abrasion, topical anesthetic is very useful in providing pain relief and allowing an adequate exam. Cotton tip applicators or flexible ear curettes offer a relatively atraumatic means of foreign body removal, but a needle may be used in older children who will remain still. Sedation may be useful in some cases, but ophthalmologic consultation and removal in the OR will avoid the need for repeat sedation if the foreign body is not removed in its entirety in the ED. With successful foreign body removal in the ED, these cases can be managed as corneal abrasions with ophthalmology follow-up. It is imperative to rule out full thickness corneal perforation with any foreign body.

Periorbital Ecchymosis

Periorbital ecchymosis, also known as "panda sign" or "raccoon eyes," can occur with mild to severe orbital trauma, frontal or midline forehead injuries, and basilar skull fractures.[34-37] The soft tissues of the eyelid are connected loosely to the overlying skin, allowing blood to track between them with sometimes dramatic accumulation around the eye.[15] Most patients with periorbital ecchymosis will have a history of injury; however, a high suspicion for nonaccidental trauma (NAT) is important in the nonambulatory pediatric patient. Rarely, the presence of spontaneous periorbital ecchymosis also could alert the examiner to the diagnosis of neuroblastoma.[38,39]

Open Globe

Open globe injuries can occur with either sharp or blunt trauma and represent a true ophthalmologic emergency. Full thickness lacerations to the cornea and/or sclera result from a wide variety of traumatic mechanisms and can be difficult to detect initially. A high index of suspicion is required to avoid missing an injury that has self-sealed or is plugged with iris tissue, as these injuries may be subtle in appearance. Any disruption of corneal or scleral tissue should be considered full thickness until proven otherwise, and the presence of a distorted pupil, exposed pigment beneath the sclera, or a traumatic cataract is highly suggestive. (*See Figure 7.*) Special attention should be given to the patient who presents with injury from a high-speed mechanism. History of hammering metal on metal, the use of power tools (especially resulting in a broken drill bit or grinding wheel), or any blast injury requires additional consideration. The presence

Figure 6. Metallic Foreign Body With Rust Ring

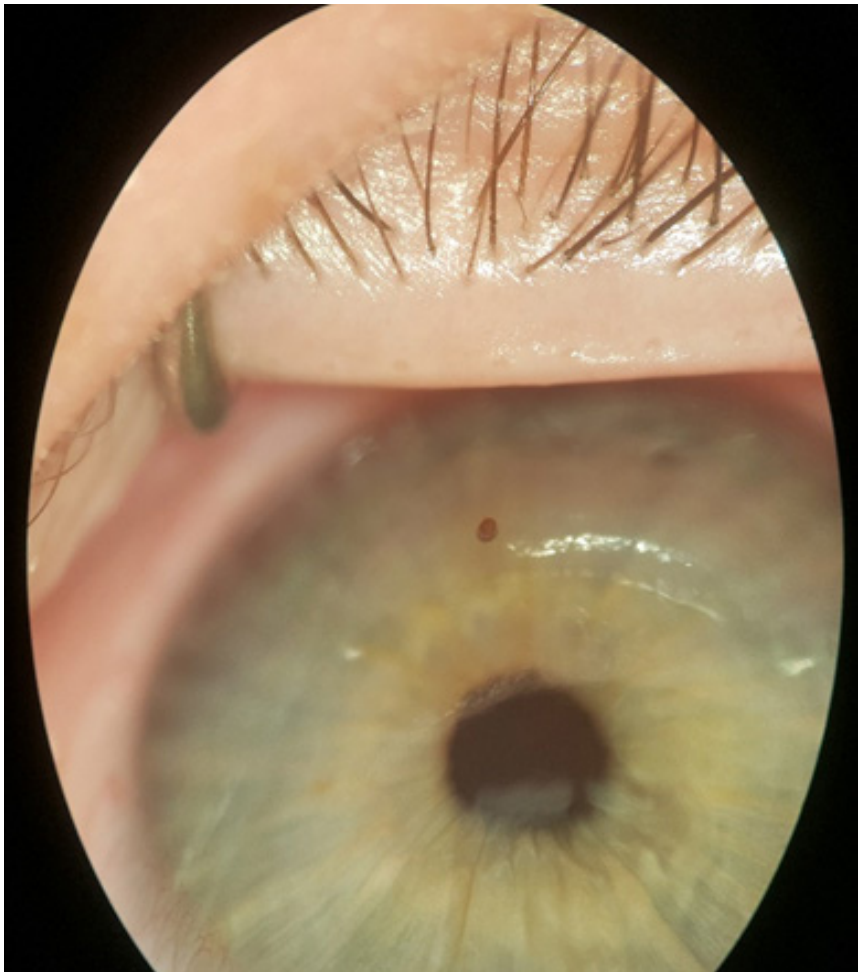

Source: Image courtesy of Blake Forcina, MD, Children's Eye Care, Oklahoma City, OK

of significant eyelid swelling limiting the exam, extreme discomfort or anxiety, and a high-risk mechanism should be referred for ophthalmologic consultation. Although the diagnosis of an open globe typically is based on the physical exam, particularly if the pupil is irregular, diagnostic imaging maybe useful in identifying the presence of a retained intraocular foreign body (IOFB) and in evaluating the posterior segment of the globe.[40] Table 4 summarizes the most common modalities.[41-44]

Seidel testing for open globe injury often is misunderstood. In short, if there is a full thickness corneal injury that is leaking aqueous fluid through the wound, fluorescein dye will be diluted by the aqueous fluid and will exhibit the peculiar characteristic of becoming more vividly fluorescent as it runs down the cornea. This technique can highlight an actively leaking ocular wound. Readers are directed to an informative video: https://www.youtube.com/watch?v=chHTGyKNNwY.

Traumatic Iritis

Detection of traumatic iritis in the pediatric patient by physical exam is difficult in the ED setting. An effective slit lamp examination for iritis requires a dark, calm setting, well-maintained equipment, a compliant patient, and well-honed examiner skills. Most emergency providers would admit that all of these criteria rarely are met, rendering identification of the 10-20 micron immune cells suspended in the anterior chamber nearly impossible. Alternatively, the patient's history can be very helpful in diagnosis. Traumatic iritis typically presents one to three days following blunt trauma and involves complaints of photophobia (sometimes extreme), pain, redness, and possible visual loss.[15] Absence of concurrent corneal injury and lack of response to topical anesthetic are typical. Traumatic iritis has been described in pediatric patients following blunt trauma from air bag deployment, bottle rockets, airsoft guns, water balloon slingshots, and many sports (i.e., high-velocity missile injuries).[45-49] Despite previous dogma admonishing the use of topical ophthalmic steroids in the ED, this author routinely advises his emergency medicine colleagues on the use of topical steroids with an intact cornea and close follow-up in the eye clinic.

Traumatic Cataract

Clouding of the human lens or cataract formation can result congenitally, with increasing age, or from systemic disease, certain drugs, or trauma. The lens capsule or basement membrane of the lens's epithelial cells acts as an osmotic barrier between the aqueous humor and the crystalline lens proteins. Disruption of the lens capsule by either penetrating or blunt injury can result in formation of a cataract seen as a whitening of the substance of the lens. This clouding is seen within minutes or hours of the loss of osmotic control. Formation of a traumatic cataract requires a thorough ophthalmic inspection for penetrating injury and retained IOFB.

Chemical Injury

Chemical injury commonly results in corneal epithelial loss, regardless of the offending agent, but rarely results in deeper long-term injury in acidic injuries. Household detergents, cosmetics, and various hydrocarbons are typical offending agents that result in pain, conjunctivitis, and corneal epithelial loss, but carry a more favorable prognosis. However, alkali or chemicals on the basic side of the pH scale are the obvious exception and can cause profound lifelong injury, in part because of the liquefaction necrosis that occurs under alkaline conditions. Extensive and deep injury occurs within minutes of exposure to basic chemicals. Irrigation in the ED mitigates, but does not eliminate, the caustic tissue damage and long-term visual consequences. Industrial

Figure 7. Complex Eyelid Laceration With Scleral Rupture

Source: Image courtesy of Blake Forcina, MD, Children's Eye Care, Oklahoma City, OK

detergents, pool maintenance, and the illicit manufacture of methamphetamines commonly are associated with exposure to basic chemicals. Infants and small children crawling on the floor can get cat litter stuck under their eyelids and will need lid eversion and irrigation to remove this adherent alkali foreign body.

Delayed healing of corneal and conjunctival epithelial loss after chemical exposure is related to the concomitant injury of conjunctival accessory lacrimal glands. These accessory lacrimal glands are required for a healthy tear film and to support the re-epithelialization of the cornea. Injury to these glands at the time of the initial chemical exposure affects the complex environment of the precorneal tear film and slows epithelial growth. Because of the possibility of a retained offending agent, patching is never indicated in chemical exposure.[50]

Treatment for chemical exposure involves irrigation, irrigation, and more irrigation after instillation of anesthetic eye drops. Checking the pH of the tear film is allowed, as long as it does not delay irrigation. Various sources recommend from one to several liters of irrigation volume. Evidence supports the use of borate buffered eye wash for irrigation, but normal saline or lactated Ringer's solution is considered adequate.[50] Irrigation is continued until the pH normalizes and remains stable; extensive irrigation and examination of the conjunctival fornices are especially important in cases of exposure to granular chemicals. After effective irrigation, subsequent examination of the eye will determine the urgency of referral. Uncomplicated limited chemical injury can be managed as a corneal abrasion with urgent ophthalmologic follow-up, whereas more extensive or alkali injury requires emergent ophthalmology involvement.[51]

A surprisingly common form of chemical injury is exposure to cyanoacrylate glue. Many Super Glue products are marketed in a bottle that looks similar to eye drops. These products are readily confused by children and adult caregivers. Upon instillation, the glue polymerizes immediately from a liquid to a solid form. At the very least, the lids and lashes are glued shut and, at worst, a shield-like layer of solid, abrasive glue is present beneath the adherent lids and abrades the corneal epithelium with every eye movement. Very rarely, the glue will stick to the cornea or conjunctival surfaces and act as a large retained foreign body held directly against the cornea.[52]

Treatment involves applying ophthalmic lubricants, trimming the adherent lashes, and physically opening the lids to remove the retained, solid glue. This should be done in consultation with an ophthalmologist. If the older, reliable pediatric patient is not complaining of a painful retained foreign body, a conservative approach may be taken. Sending the patient home with ophthalmic lubricant to be massaged into the lids will allow the lids to open within a few days.[53] Pediatric patients rarely glue their own eyes shut, especially both eyes. All pediatric patients with this type of injury should be suspected of being victims of child abuse.

Child Abuse

All types of ocular trauma can result from NAT of the pediatric patient, and a full discussion of nonaccidental ocular injuries is beyond the scope of this article. Retinal hemorrhages appear to represent the most common orbital manifestations of NAT associated with head injury.[15] Although retinal hemorrhages can be seen with a direct ophthalmoscope, ophthalmological consult is required for verification and confirmation in the face of legal ramifications.[54,55] Emergency medicine personnel are encouraged to maintain a high index of suspicion for NAT in any case involving retinal hemorrhages.

Traumatic Visual Loss

Traumatic visual loss (TVL) associated with no obvious ocular or intracranial injury can be either organic or nonorganic. Scant literature is available to describe TVL not associated with overt injury. Traumatic asphyxia associated with compression of the chest has been associated with transient TVL in pediatric patients, and transient cortical blindness following closed head trauma is a known cause of TVL.[15,56,57]

Table 4. Diagnostic Modalities for Possible Retained Intraocular Foreign Body	
Diagnostic Method	**Benefits**
X-ray	• Quick, easy, affordable, and readily available • Good for metallic foreign body detection
Computerized tomography	• 94.9% sensitive for intraocular foreign body with decreasing ability metal > glass > wood • Motion artifact in pediatric patients as well as concerns for radiation exposure[41-43]
B-scan ultrasonography	• Rapid, cost effective, useful in assessing posterior segment integrity • Requires extreme caution by an experienced technician or physician to avoid further extrusion of intraocular contents[41-44]
Magnetic resonance imaging	• Only used when metallic intraocular foreign body has been ruled out by other modalities and wood intraocular foreign body or orbital fractures are suspected[43]

Recent focus on pediatric concussive syndromes associated with contact sports has identified an entity called vestibular-ocular motor dysfunction (VOMD), which is associated with visual difficulty and disruption of the vestibular-ocular reflex. This reflex elicits eye movement by stimulating the vestibular system to stabilize images on the retina during movement of the head, thus preserving the image on the center of the visual field.[58,59] Vestibular-ocular dysfunction associated with concussion may be responsible for some of the vague and poorly described visual complaints common after concussions and may be seen in as many as 60% of sports-related concussions. VOMD often is under-appreciated in concussion; a new screening tool is proposed to identify patients at risk, but its utility remains to be determined.[60]

Nonorganic TVL, or functional visual loss, commonly is seen following stressful traumatic events. Functional visual loss is a complex and fascinating topic and should be suspected in older children in whom the level of visual loss far outweighs the objectively identifiable injury. These patients may claim unilateral (or bilateral) blindness or loss of visual field after a traumatic event but without obvious cause. This form of conversion reaction appears more common after motor vehicle collisions (especially where there may be legal consequences) and in circumstances in which there is palpable conflict within the family members present. Several examination techniques may allow the emergency medicine physician to differentiate this from organic visual loss, although ophthalmologic consultation still may be required. Patients with true visual loss usually are anxious and demonstrate an inability to navigate around their environment, whereas functional patients reflect a very calm demeanor. Despite a claimed tunnel field, functional patients will shake a hand when offered in greeting by the examiner. Functionally blind patients usually will follow their own image reflected in a handheld mirror passed in front of them and claim an inability to legibly sign their own name, while truly blind patients retain the ability to write. Emergency medicine providers are cautioned against approaching these patients cynically, as functional visual loss truly is a diagnosis of exclusion. Functional visual loss is associated regularly with concomitant ocular disease and is highly associated with depression. Not all functional patients are malingering.[61,62]

Summary

Trauma is a leading cause of morbidity and mortality in the pediatric population, one of the most underrecognized major health problems facing the nation, and, importantly, mostly preventable.[63] Although not associated with a high mortality rate, ocular trauma has tremendous financial, physical, and emotional implications. Children have a disproportionate number of ocular injuries that can result in lifelong disability. Prevent Blindness America has established August as Child Eye Health and Safety Month and September as Sports Eye Safety Month, clearly highlighting the impact of this on our pediatric patients.[64] The American Academy of Pediatrics, the American Academy of Pediatric Ophthalmology and Strabismus, and the American Academy of Ophthalmology strongly recommend protective eyewear for all pediatric patients participating in sports at high risk for ocular trauma. This is particularly important for athletes who are functionally one-eyed and those athletes who have undergone previous eye surgery or trauma. Further information can be found in the Children's Sports Eye Safety Position Statement through Prevent Blindness America.

References

1. World Health Organization. Global Data on Visual Impairments 2010. Available at: http://www.who.int/blindness/publications/global-data/en/. Accessed July 25, 2018.
2. Abbott J, Shah P. The epidemiology and etiology of pediatric ocular trauma. *Surv Ophthalmol* 2013;58:476-485.
3. Prevent Blindness America. The Scope of the Eye Injury Problem. Available at: https://www.preventblindness.org/sites/default/files/national/documents/fact_sheets/FS93_ScopeEyeInjury.pdf. Accessed July 25, 2018.
4. Brophy M, Sinclair S, Hostetler S, et al. Pediatric eye injury-related hospitalizations in the United States. *Pediatrics* 2006;117:e1263-1271.
5. Lukish JR, Eichelberger MR. Chapter 18: Infants and children as accident victims and their emergency management. In: Coran A, Caldamone A, eds. *Pediatric Surgery*. 7th ed. New York: Elsevier Inc.; 2012:261-270.
6. Garcia TA, McGetrick BA, Janik JS. Ocular injuries in children after major trauma. *J Pediatr Ophthalmol Strabismus* 2005;42:349-354.
7. Miller KN, Collins CL, Chounthirath T, et al. Pediatric sports- and recreation-related eye injuries treated in US emergency departments. *Pediatrics* 2018;141:e20173083.

8. Matsa E, Shi J, Wheeler KK, et al. Trends in US emergency department visits for pediatric acute ocular injury. *JAMA Opththalmol* 2018;136:865-903. Available at: https://jamanetwork.com/journals/jamaophthalmology/fullarticle/2683730?utm_campaign=articlePDF&utm_medium=articlePDFlink&utm_source=articlePDF&utm_content=jamaophthalmol.2018.2062. Accessed July 25, 2018.
9. McGwin G, Hall TA, Xie A, et al. Trends in eye injury in the United States, 1992-2001. *Investig Ophthalmol Vis Sci* 2006;47:521-527.
10. Patel BCK, Morgan LH. Penetrating eye injuries in road traffic accidents. *Arch Emerg Med* 1988;5:21-25.
11. American Academy of Pediatrics. Protective eyewear for young athletes. *Pediatrics* 2004;113: 619-622.
12. Garcia TA, McGetrick BA, Janik JS. Spectrum of ocular injuries in children with major trauma. *J Trauma* 2005;59:169-174.
13. Trobe JD. *The Physician's Guide to Eye Care.* San Francisco: The Academy of Opthalmology; 1983.
14. Cheng LHH, Kumar P. Retraction of oedematous eyelids with paper-clips. *Ann R Coll Surg Engl* 2008;90:253.
15. Levin AV. Chapter 117: Eye Trauma. In: Fleisher GR, Ludwig S, eds. *Textbook of Pediatric Emergency Medicine*. 6th ed. Philadelphia: Lippincott Williams & Wilkins; 2010:1454-1457.
16. Lazzaro DR, Kulak A, Scott W. Chapter 8: Opthalmology. In: Shah BR, Lucchesi M, eds. *Atlas of Pediatric Emergency Medicine*. 2nd ed. New York: The McGraw-Hill Companies; 2013:330-332.
17. Mody AP, Silverman BK. Chapter 95: Problems in the Early Neonatal Period. In: Fleisher GR, Ludwig S, eds. *Textbook of Pediatric Emergency Medicine.* 6th ed. Philadelphia: Lippincott Williams & Wilkins; 2010:1001.
18. Wood JN, Ludwig S. Chapter 132: Child Abuse. In: Fleisher GR, Ludwig S, eds. *Textbook of Pediatric Emergency Medicine*. 6th ed. Philadelphia: Lippincott Williams & Wilkins; 2010:1670.
19. Harlan JB, Ng EWM, Pieramici J. Chapter 9: Evaluation. In: Kuhn F, Pieramici DJ, eds. *Ocular Trauma: Principles and Practice*. New York: Thieme; 2002:59.
20. Willmann, D, Melanson SW. Corneal Injury. StatPearls. 2017. Available at: https://www.ncbi.nlm.nih.gov/books/NBK459283/. Accessed July 24, 2018.
21. Al-Saleh GS, Alfawaz AM. Management of traumatic corneal abrasion by a sample of practicing ophthalmologists in Saudi Arabia. *Saudi J Ophthalmol* 2017;32:105-109.
22. Shope TR, Rieg TS, Kathiria NN. Corneal abrasions in young infants. *Pediatrics* 2010; 125:e565-569.
23. Poole SR. The infant with acute, unexplained, excessive crying. *Pediatrics* 1991;88:450-455.
24. Poole SR. Corneal abrasion in infants. *Pediatr Emerg Care* 1995;11:25-26.
25. Smith CH, Goldman RD. Topical nonsteroidal anti-inflammatory drugs for corneal abrasions in children. *Can Fam Physician* 2012;58: 748-749.
26. Lawrenson A, Wakai A. 11 Topical nsaids for analgesia in traumatic corneal abrasions: A systematic review and meta-analysis. *Emerg Med J* 2017;34:868.
27. Ross M, Deschênes J. Practice patterns in the interdisciplinary management of corneal abrasions. *Can J Ophthalmol* 2017;52:548-551.
28. Thiel B, Sarau A, Ng D. Efficacy of topical analgesics in pain control for corneal abrasions: A systematic review. *Cureus* 2017;9:e1121.
29. Calder L, Balasubramanian S, Stiell I. Lack of consensus on corneal abrasion management: Results of a national survey. *Can J Emerg Med* 2004;6:402-407.
30. Menghini M, Knecht PB, Kaufmann C, et al. Treatment of traumatic corneal abrasions: A three-arm, prospective, randomized study. *Ophthalmic Res* 2013;50:13-18.
31. Lim CHL, Turner A, Lim BX. Patching for corneal abrasion (Review). *Cochrane Database Syst Rev* 2016;7:CD004764.
32. Waldman N, Densie IK, Herbison P. Topical tetracaine used for 24 hours is safe and rated highly effective by patients for the treatment of pain caused by corneal abrasions: A double-blind, randomized clinical trial. *Acad Emerg Med* 2014;21:374-382.
33. Waldman N, Winrow B, Densie I, et al. An observational study to determine whether routinely sending patients home with a 24-hour supply of topical tetracaine from the emergency department for simple corneal abrasion pain is potentially safe. *Ann Emerg Med* 2018;71: 767-778.
34. Reid JM, Williams D. Panda sign due to severe coughing. *J R Coll Physicians Edinb* 2013;43:35.
35. Schutzman S. Chapter 37: Injury—Head. In: Fleisher GR, Ludwig S, eds. *Textbook of Pediatric Emergency Medicine.* 6th ed. Philadelphia: Lippincott Williams & Wilkins; 2010:338.
36. Herbella FAM, Mudo M, Delmonti C, et al. 'Racoon eyes' (periorbital haematoma) as a sign of skull base fracture. *Injury* 2001;32:745-747.
37. van Woerkom JM, van Toorn DW. A domestic fight or something else? *Nephrol Dial Transplant* 2000;15:1253-1254.
38. Komori K, Yanagisawa R, Fujihara I, et al. Failure to thrive and bilateral periorbital ecchymosis. *J Pediatr* 2016;172;215.e2.
39. Alaghband P, Long V. Periorbital ecchymosis. *J Pediatr* 2016;168:245.e1.
40. Li X, Zarbin MA, Bhagat N. Pediatric open globe injury: A review of the literature. *J Emerg Trauma Shock* 2015;8:216-223.
41. Patel SN, Langer PD, Zarbin MA, et al. Diagnostic value of clinical examination and radiographic imaging in identification of intraocular foreign bodies in open globe injury. *Eur J Ophthalmol* 2012;22:259-268.
42. Perisinakis K, Raissaki M, Tzedakis A, et al. Reduction of eye lens radiation dose by orbital bismuth shielding in pediatric patients undergoing CT of the head: A Monte Carlo study. *Med Phys* 2005;32:1024-2031.
43. Kubal WS. Imaging of orbital trauma. *Radiographics* 2008;28:1729-1739.
44. Fielding JA. The assessment of ocular injury by ultrasound. *Clin Radiol* 2004;59:301-312.
45. Khan M, Reichstein D, Recchia FM. Ocular consequences of bottle rocket injuries in children and adolescents. *Arch Ophthalmol* 2011;129:639-642.
46. Lueder GT. Air bag-associated ocular trauma in children. *Ophthalmology* 2000;107: 1472-1475.
47. Ramstead C, Ng M, Rudnisky CJ. Ocular injuries associated with Airsoft guns: A case series. *Can J Ophthalmol* 2008;43:584-587.
48. Bullock JD, Ballal DR, Johnson DA, et al. Ocular and orbital trauma from water balloon slingshots: A clinical, epidemiologic, and experimental study. *Ophthalmology* 1997;104: 878-887.
49. Orlando RG, Doty JH. Ocular sports trauma: A private practice study. *J Am Optom Assoc* 1996;67:77-80.
50. Dohlman CH, Cade F, Pfister R. Chemical burns to the eye: Paradigm shifts in treatment. *Cornea* 2011;30:613-614.
51. Colby K. Chemical injuries of the cornea. *Focal Points* 2010;28:1-14.
52. Knight IJ. Mistaken eye drops and subsequent instillation of superglue. *Eye* (Lond) 2001;15:663.
53. Reddy SC. Superglue injuries of the eye. *Int J Ophthalmol* 2012;5:634-637.
54. Mungan NK. Update on shaken baby syndrome: Ophthalmology. *Curr Opin Ophthalmol* 2007;18:392-397.
55. Levin AV, Christian CW. The eye examination in the evaluation of child abuse. *Pediatrics* 2010;126:376-380.
56. Baldwin GA, Macnab AJ, McCormick AQ. Visual loss following traumatic asphyxia in children. *J Trauma* 1988;28:557-558.
57. Kaye EM, Herskowitz J. Transient post-traumatic cortical blindness: Brief v prolonged syndromes in childhood. *J Child Neurol* 1986;1:206-210.
58. Ellis M, Cordingley DM, Vis S, et al. Vestibulo-ocular dysfunction in pediatric sports-related concussion. *J Neurosurg Pediatr* 2015;16:248-255.
59. Ellis M, Cordingley DM, Vis S, et al. Clinical predictors of vestibulo-ocular dysfunction in pediatric sports-related concussion. *J Neurosurg Pediatr* 2017;19:38-45.
60. Mucha A, Collins MW, Elbin RJ, et al. A brief vestibular/ocular motor screening (VOMS) assessment to evaluate concussions. *Am J Sports Med* 2014;42:2479-2486.
61. Ney JJ, Volpe NJ, Liu GT, et al. Functional visual loss in idiopathic intracranial hypertension. *Ophthalmology* 2009;116:1808-13.e1.
62. Lim SA, Siatkowski RM, Farris BK. Functional visual loss in adults and children patient characteristics, management, and outcomes. *Ophthalmology* 2005;112:1821-1828.
63. National Research Council. Injury Control: A Review of the Status and Progress of the Injury Control Program at the Centers for Disease Control. Washington, DC: Natl Acad Press; 1988.
64. Prevent Blindness. Prevent Blindness Eye Health and Safety Observance Calendar. Available at: https://www.preventblindness.org/prevent-blindness-eye-health-and-safety-observance-calendar. Accessed Sept. 24, 2018.

CME/CE INSTRUCTIONS

To earn credit for this activity, please follow these instructions:

1. Read and study the activity, using the references for further research.
2. Log on to ReliasMedia.com and click on My Account.
3. Pass the online tests with a score of 100%; you will be allowed to answer the questions as many times as needed to achieve a score of 100%.
4. After completing the test, a credit letter will be emailed to you instantly.
5. Twice yearly after the test, your browser will be directed to an activity evaluation form, which must be completed to receive your credit letter.

CME/CE Questions

1. Which of the following is the best treatment option for simple corneal abrasion?
   a. Topical antibiotics
   b. Topical nonsteroidal anti-inflammatory drops
   c. Patching
   d. No ideal treatment has been proven more efficacious than another
2. Which of the following is the best diagnostic tool for the detection of a retained intraocular metallic foreign body?
   a. Plain film of the orbit
   b. Ultrasound of the eye
   c. Magnetic resonance imaging
   d. Computed tomography scan
3. Which of the following is the leading cause of blindness in pediatric patients in the United States?
   a. Infection
   b. Trauma
   c. Congenital abnormalities
   d. Refractive errors
4. What is the most common eye injury seen in nonaccidental trauma that needs ophthalmological confirmation?
   a. Subconjunctival hemorrhage
   b. Cigarette burn
   c. Ruptured globe
   d. Retinal hemorrhages
5. Which of the following ocular trauma injuries causes foreign body sensation without the presence of a foreign body?
   a. Corneal abrasion
   b. Subconjunctival hemorrhage
   c. Hyphema
   d. Periorbital ecchymosis
6. The Seidel test is used to help determine which of the following ocular injuries?
   a. Hyphema
   b. Open globe
   c. Foreign body
   d. Visual acuity
7. Which of the following diseases places a patient with a hyphema at high risk for complications?
   a. Type 1 diabetes
   b. Tay-Sachs disease
   c. Osteomyelitis
   d. Sickle cell disease
8. Which of the following is the best modality to diagnose traumatic iritis?
   a. Direct ophthalmoscope
   b. Visual acuity testing
   c. Slit lamp exam
   d. Woods light and fluorescein
9. Which of the following injuries results in a distorted pupil?
   a. Ruptured globe
   b. Subconjunctival hemorrhage
   c. Retinal hemorrhages
   d. Corneal abrasion
10. Which of the following is the best method of determining visual acuity in a 3- to 5-year-old child?
    a. Snellen acuity
    b. Picture cards or "tumbling E" chart
    c. Parent's best guess
    d. It is not possible to guess visual acuity in children younger than 5 years of age

PEDIATRIC EMERGENCY MEDICINE REPORTS

CME/CE Objectives

Upon completion of this educational activity, participants should be able to:

- recognize specific conditions in pediatric patients presenting to the emergency department;
- describe the epidemiology, etiology, pathophysiology, historical and examination findings associated with conditions in pediatric patients presenting to the emergency department;
- formulate a differential diagnosis and perform necessary diagnostic tests;
- apply up-to-date therapeutic techniques to address conditions discussed in the publication;
- discuss any discharge or follow-up instructions with patients.

PEDIATRIC EMERGENCY MEDICINE REPORTS™ (ISSN 1082-3344) is published monthly by Relias Learning, 111 Corning Road, Suite 250, Cary, NC 27518-9238. Periodicals postage paid at Cary, NC, and additional mailing offices. POSTMASTER: Send address changes to *Pediatric Emergency Medicine Reports*, Relias Learning, 111 Corning Road, Suite 250, Cary, NC 27518-9238.

Executive Editor: Leslie Coplin

Executive Editor: Shelly Mark

Editorial Group Manager: Terrey Hatcher

Senior Accreditations Officer: Lee Landenberger

GST Registration No.: R128870672

Back issues: $65. Missing issues will be fulfilled by customer service free of charge when contacted within one month of the missing issue's date.

SUBSCRIBER INFORMATION

CUSTOMER SERVICE: (800) 688-2421

Customer Service Email Address:
customerservice@reliasmedia.com

Editorial Email Address:
lcoplin@relias.com

Website:
ReliasMedia.com

SUBSCRIPTION PRICES

1 year with 36 AMA, AAP or ACEP Category 1 credits: $349
Add $19.99 for shipping & handling

MULTIPLE COPIES:

Discounts are available for group subscriptions, multiple copies, site-licenses, or electronic distribution. For pricing information, please contact our Group Account Managers at groups@reliasmedia.com or (866) 213-0844.

All prices U.S. only. U.S. possessions and Canada, add $30 plus applicable GST. Other international orders, add $30.

RELIAS MEDIA

ACCREDITATION

Relias LLC is accredited by the Accreditation Council for Continuing Medical Education (ACCME) to provide continuing medical education for physicians.

Relias LLC designates this enduring material for a maximum of 3 *AMA PRA Category 1 Credits*™. Physicians should claim only credit commensurate with the extent of their participation in the activity.

Approved by the American College of Emergency Physicians for a maximum of 3 hours of ACEP Category I credit.

This continuing medical education activity has been reviewed by the American Academy of Pediatrics and is acceptable for a maximum of 3 AAP credits. These credits can be applied toward the AAP CME/CPD Award available to Fellows and Candidate Members of the American Academy of Pediatrics.

The American Osteopathic Association has approved this continuing education activity for up to 2.5 AOA Category 2-B credits.

Relias LLC is accredited as a provider of continuing nursing education by the American Nurses Credentialing Center's Commission on Accreditation. Contact hours [3] will be awarded to participants who meet the criteria for successful completion. California Board of Registered Nursing, Provider CEP#13791.

This CME activity is intended for emergency and pediatric physicians and nurses. It is in effect for 36 months from the date of the publication.

This is an educational publication designed to present scientific information and opinion to health professionals, to stimulate thought, and further investigation. It does not provide advice regarding medical diagnosis or treatment for any individual case. It is not intended for use by the layman. Opinions expressed are not necessarily those of this publication. Mention of products or services does not constitute endorsement. Clinical, legal, tax, and other comments are offered for general guidance only; professional counsel should be sought for specific situations.