PEDIATRIC EMERGENCY MEDICINE REPORTS

Practical, Evidence-Based Reviews in Pediatric Emergency Care

September 2019 VOL. 24, NO. 9

AUTHORS

Jeffrey T. Sakamoto, MD, Resident, Stanford Emergency Medicine Residency Program, Stanford, CA

Monika Thomas-Uribe, MD, MPH, Department of Pediatrics, UCSF-Fresno

Pablo Tarsicio Uribe-Leitz, MD, MPH, Center for Surgery and Public Health: Harvard Medical School, Harvard T.H. Chan School of Public Health, and the Department of Surgery, Brigham & Women's Hospital, Boston, MA

N. Ewen Wang, MD, Professor of Emergency Medicine, Stanford School of Medicine, Stanford, CA

PEER REVIEWER

Larry B. Mellick, MD, MS, FAAP, FACEP, Vice Chairman for Academic Affairs, Interim Section Chief of Pediatric Emergency Medicine, Assistant Residency Director, Professor of Emergency Medicine, University of South Alabama, Mobile

STATEMENT OF FINANCIAL DISCLOSURE

To reveal any potential bias in this publication, and in accordance with Accreditation Council for Continuing Medical Education guidelines, we disclose that Dr. Dietrich (editor), Dr. Skrainka (CME question reviewer), Dr. Sakamoto (author), Dr. Thomas-Uribe (author), Dr. Uribe-Leitz (author), Dr. Wang (author), Dr. Mellick (peer reviewer), Ms. Wurster (nurse reviewer), Ms. Coplin (editorial group manager), Ms. Roberts (associate editor), and Ms. Mark (executive editor) report no relationships with companies related to the field of study covered by this CME activity.

RELIAS MEDIA

Approach to Pediatric Abdominal Pain in the ED: Part II

Abdominal pain is challenging in pediatrics. This two-part series deals with must-not-miss diagnosis and common etiologies of abdominal pain. In this second part, the authors focus on toddlers and older children.

— Ann M. Dietrich, MD, Editor

Acute abdominal pain is a common chief complaint among pediatric emergency department (ED) patients. Part I of this two-part series on pediatric abdominal pain discussed background information, pertinent pathophysiology, the general approach to the initial history and physical examination of a child with abdominal pain, and a suggested age-based differential diagnosis. Part I also reviewed emergent as well as common, benign causes of abdominal pain in neonates. Part II will focus on the etiologies of abdominal pain in the infant and toddler/child. Abdominal pain due to trauma and obstetric/gynecology causes are beyond the scope of this article.

As discussed in Part I, we suggest using an age-based differential diagnosis as an approach to pediatric abdominal pain listed in Tables 1 and 2.

Case #2

A 2-year-old girl presents to the ED with intermittent fussiness. The birth and medical history are noncontributory. Over the past day, the patient has had decreased oral intake and wet diapers. Her mother has noticed 10-minute episodes of clutching her abdomen, pulling her legs into her abdomen, and being "out of it," with normal behavior in between episodes. On exam, the patient appears pale, but consolable, with a soft, nondistended, nontender abdomen. Vital signs are heart rate of 120 beats per minute, respiratory rate of 25, and blood pressure of 85/50 mmHg.

Differential Diagnosis

In infants and toddlers, the differential diagnosis of acute abdominal pain requiring urgent/emergent intervention includes intussusception, incarcerated inguinal hernia, and Hirschsprung's disease. Other causes include Meckel's diverticulum. This differential is listed in the second column of Table 1.

Intussusception

Intussusception is defined as proximal bowel that telescopes into a more distal portion of bowel causing obstruction and colicky abdominal pain. (*See Figure 1.*) It is the most common abdominal emergency in children younger than 2 years of age, with a yearly incidence of approximately 31 to 38 in 100,000 during the first two years of life.[1,2] The majority of cases are idiopathic and occur in the ileocolic region, presumably due to hypertrophy of the Peyer's patches after a viral infection. Other less common etiologies include intra-abdominal mass, Henoch-Schönlein purpura (due to bowel wall hematoma/edema), and enteritis.[3] Cases in children older than

EXECUTIVE SUMMARY

- In infants with abdominal pain, always consider intussusception, Hirschsprung's disease, and incarcerated hernia.
- In toddlers and young children with abdominal pain, always consider appendicitis, testicular or ovarian torsion, Meckel's diverticulum, and intussusception.
- The classically described triad of intermittent colicky abdominal pain, red currant jelly stool, and sausage-shaped abdominal mass is seen only in 15-40% of children with intussusception. In stable patients with ultrasound-confirmed intussusception, standard management includes nonoperative reduction by a pediatric radiologist with an air or hydrostatic enema.
- Clinical scores, such as the Alvarado score and the pediatric appendicitis score, have been created to aid in risk stratification of children with suspected appendicitis. They include physical exam findings, vital signs, and lab results, and have been validated prospectively with moderate predictive accuracy. However, none have been shown to surpass clinician gestalt or improve outcomes.
- Admission with appendectomy is the most common standard of care for acute appendicitis. However, nonsurgical treatment can be offered to a subset of patients who are older, without fecalith, and have lower inflammatory markers. Shared decision making with the family should be employed in this situation. Nonsurgical management still requires admission for administration of broad-spectrum IV antibiotics (i.e., piperacillin/tazobactam) until white blood cell count normalizes and symptoms improve. In a large meta-analysis, patients treated non-surgically had a recurrence rate of 22% at one year.
- The rule of 2s is commonly applied to Meckel's diverticulum, with 2% of population, presentation at age 2 years, two feet from ileocecal junction, and two inches in length.

6 years of age are more likely to have pathology.

Clinical Features. The classically described triad of intermittent colicky abdominal pain, red currant jelly stool, and sausage-shaped abdominal mass is seen only in 15-40% of children.[4] More commonly, children will present with intermittent, sudden onset, colicky abdominal pain lasting approximately 10-20 minutes caused by peristalsis against obstruction. The child may return to baseline between episodes. These episodes may be associated with emesis, lethargy, and poor oral intake. Importantly, some infants only present with poor oral intake and lethargy, thus clouding the diagnostic picture. Given the prevalence and inconsistent presentation of intussusception in infants, it is reasonable to pursue this diagnosis in infants presenting with nonspecific lethargy.[3]

The initial abdominal exam may be soft with focal tenderness, but may transition to distension as obstruction worsens. Vital signs can progress quickly from normal to shock because of dehydration. Late findings include currant jelly stool, bilious emesis, and hypotension.

Diagnostic Imaging and Laboratory Workup. If the child is toxic-appearing, a kidney, ureter, and bladder (KUB) X-ray should be obtained immediately to exclude perforation. In the stable-appearing infant, ultrasound is the preferred diagnostic imaging with a sensitivity and specificity approaching 100%.[5] The "target" or "bull's-eye" appearance on ultrasound confirms telescoping bowel.

Initial labs should include a complete blood count and basic metabolic panel. If the child is toxic-appearing, lactate level, liver function tests, and coagulation factors can be added.

ED Management/Disposition. If there are signs of perforation, resuscitation should be initiated along with antibiotics and immediate transfer to the operating room with a pediatric surgeon. In stable patients with ultrasound-confirmed intussusception, standard management includes nonoperative reduction by a pediatric radiologist with an air or hydrostatic enema. There is a 10% chance of recurrence, mostly occurring within the first three days.[6] In all cases of suspected or confirmed intussusception, pediatric surgery should be consulted in case nonoperative reduction is unsuccessful. Antibiotics are not indicated unless perforation is suspected.[3,7]

Rarely, small bowel intussusception may occur. If the patient is symptomatic, has a long segment of intussuscepted bowel, or has had prior surgery, the same management discussed earlier should be initiated in collaboration with pediatric surgery, keeping in mind that nonoperative reduction is less successful in these cases.[8] If the patient is asymptomatic and without the aforementioned risk factors, following collaboration with pediatric surgery, the patient can be discharged with close follow-up. The majority of pediatric cases do not have an identifiable etiology; in about 10% of cases, a lead point will be found. Congenital gastrointestinal tract abnormalities, such as Meckel's diverticulum, intestinal duplication, or the presence of lesions, such as polyps, hamartomas, or malignancies (lymphoma, carcinoma due to juvenile polyposis syndromes), all can result in intussusception. In children with cystic fibrosis, foreign bodies, intestinal parasites, and inspissated feces may result in lead points in the ileum causing ileocolic intussusception. With increasing age, the likelihood of identifiable causes of intussusception increases. Further imaging may be required to identify potential etiologies of intussusception (i.e., mass, Meckel's diverticulum), but should be done in consultation with pediatric radiology and surgery.

Older patients or patients with recurrent intussusception (two or more occurrences) should undergo further evaluation for a mass or Meckel's diverticulum.[9]

Incarcerated Hernia

Inguinal hernia occurs in approximately 3% of children, with a predominance in males (6% males vs. 0.7% females) and preterm infants.[10,11] Incarceration is defined as an inability to reduce a hernia sac, which can lead to obstruction or strangulation (vascular compromise of the hernia contents). The incidence of incarceration varies between studies from 5% to 31%, but it occurs most commonly in males and children younger than 1 year of age.[10,12] Umbilical hernias typically do

Table 1. Age-Based Differential Diagnosis for Emergency and Common Causes of Pediatric Abdominal Pain

	Neonate (0-28 days)	Infant (1-24 months)	Toddler/Child (2-10 years)	Adolescent (11-18 years)
Emergent/Urgent	• Necrotizing enterocolitis • Malrotation with midgut volvulus • Hirschsprung's disease with toxic megacolon • Pyloric stenosis • Testicular torsion • Obstruction from atresia	• Intussusception • Incarcerated hernia • Hirschsprung's disease with toxic megacolon • Meckel's diverticulitis • Hemolytic uremic syndrome	• Appendicitis • Meckel's diverticulitis • Testicular/ovarian torsion • Intussusception • Hemolytic uremic syndrome	• Appendicitis • Cholecystitis/ cholangitis • Testicular/ovarian torsion • Ectopic pregnancy
Common/Generally Benign	• Colic • Reflux • Milk protein allergy	• Gastroenteritis • Viral syndrome	• Gastroenteritis • Viral syndrome • Constipation	• Gastroenteritis • Viral syndrome • Constipation

Table 2. Age-Based Differential Diagnosis for Pediatric Non-Gastrointestinal Causes of Apparent Abdominal Pain

	Neonate (0-28 days)	Infant (1-24 months)	Toddler/Child (2-10 years)	Adolescent (11-18 years)
Other Causes of Nonspecific Abdominal Pain	• Sepsis • Inborn errors of metabolism	• Sepsis • Urinary tract infection • Foreign body • Pneumonia	• Sepsis • Urinary tract infection • Foreign body • Pneumonia • Henoch-Schönlein purpura • Diabetic ketoacidosis • Malignancy • Toxic ingestion	• Sepsis • Urinary tract infection • Foreign body • Pneumonia • Diabetic ketoacidosis • Malignancy • Toxic ingestion • Pelvic inflammatory disease • Tuboovarian abscess • Ovarian cyst • Hepatitis • Nephrolithiasis

not incarcerate and close spontaneously in almost all children by 5 years of age.[13] In females, it is common for the hernia sac to contain the ovary, which is at risk for torsion.[14]

Clinical Features. Incarcerated hernia may have a variety of clinical presentations. The history should involve surgical history, oral intake, nausea/emesis, and presence of any groin "bulges or masses." (*See Figure 2.*) Infants with an incarcerated hernia may present with nonspecific symptoms, including fussiness and decreased oral intake. If the incarcerated hernia is strangulated or causing obstruction, infants may present with a distended abdomen, bilious emesis, or shock. The physical exam should include visualization or palpation of a firm, non-reducible mass located in the inguinal canal.[10]

Diagnostic Imaging and Laboratory Workup. The imaging modality of choice is ultrasound, which can identify hernia sacs with good accuracy as well as other pathologies, such as testicular and ovarian torsion.[15,16] Generally, a laboratory workup is unnecessary unless the patient is toxic-appearing with signs of obstruction and strangulation.

ED Management. If the patient is toxic-appearing with signs of obstruction, resuscitation should be initiated and pediatric surgery should be consulted. In stable infants without reproductive organs in the hernia sac, manual reduction should be attempted in the ED. General strategies include placing an ice pack on the area, placing the patient in the Trendelenburg position, and administering sedation/analgesia. Once these have been implemented, gentle pressure on the hernia sac can be attempted to milk its contents back into the abdomen. Further proximal and distal pressure with two hands can be applied to manipulate the sac into the abdomen. If the hernia cannot be reduced, pediatric surgery should be consulted, as there is a risk of progression to strangulation or obstruction without surgical repair.[17]

If the ovary is within the sac, reduction can be attempted with sedation and very gentle pressure, given the risk of torsing or injuring the ovary in the process. If this fails, pediatric surgery should be consulted for surgical reduction and repair.[18]

Disposition. Patients with incarcerated hernias that cannot be reduced manually should be taken for surgical reduction immediately. Patients with manually reduced hernias require a surgical

consultation and most likely will still be admitted to the hospital for urgent repair within 24 to 48 hours since there is a high risk of reincarceration.[19]

Common Benign Causes of Abdominal Pain

Gastroenteritis is a common cause of abdominal pain compared to those discussed earlier and accounts for up to 4 million physician visits each year.[20] An in-depth description of the infectious agents is out of the scope of this article, but the diagnosis and management of uncomplicated viral or toxin-induced acute gastroenteritis (AGE) will be discussed briefly.

Clinical Features. The history should focus on quantifying and qualifying the amount of emesis and diarrhea as well as sick contact, travel history, general activity of the infant, and hydration status (wet diapers, oral intake). Symptoms include nonbloody/nonbilious emesis, nonbloody diarrhea, and cramping intermittent abdominal pain. The physical exam should focus on the abdomen and assessing hydration status. A benign history, nontoxic general appearance, and normal abdominal exam typically can differentiate AGE from other emergent causes of abdominal pain. Of note, the hydration status can vary, and infants can become profoundly dehydrated quickly without adequate oral intake.

Diagnostic Imaging and Laboratory Workup. In patients with suspected viral gastroenteritis without signs of severe dehydration, labs generally are not indicated or useful. In patients with possible bacterial gastroenteritis (bloody diarrhea, international travel history), it may be reasonable to obtain a complete blood count, stool culture, fecal leukocytes, *Clostridioides difficile* polymerase chain reaction (PCR), and stool ova and parasites. If available, gastroenteritis PCR also can be accurate and used to identify the etiology of diarrhea. Stool studies and basic labs also may be useful in patients with prolonged symptoms (> 1 week) or immunocompromised patients to identify etiology and appropriate antibiotic treatment.

ED Management/Disposition. Treatment in the ED should focus on rehydration. In patients who do not tolerate oral hydration or who are profoundly dehydrated, IV fluids such as normal saline should be initiated, with an initial bolus of 20 mL per kg. In all other patients who are nontoxic-appearing, oral rehydration should be initiated. In infants with continued nausea and emesis, ondansetron has been shown to be an effective and safe antiemetic in patients older than 6 months of age.[21]

Infants with suspected viral gastroenteritis who are immunocompetent and tolerating oral fluids with adequate hydration status can be discharged home safely with close primary care follow-up. Viral gastroenteritis is typically self-limiting and lasts less than five days. Parents should be counseled on maintaining oral hydration and returning to the ED for signs of dehydration and intolerance of oral fluids. Patients who are profoundly dehydrated or who are not tolerating oral fluids require admission to the hospital for IV hydration.

Figure 1. Depiction of Intussusception Showing Telescoping of Terminal Ileum Into the Cecum

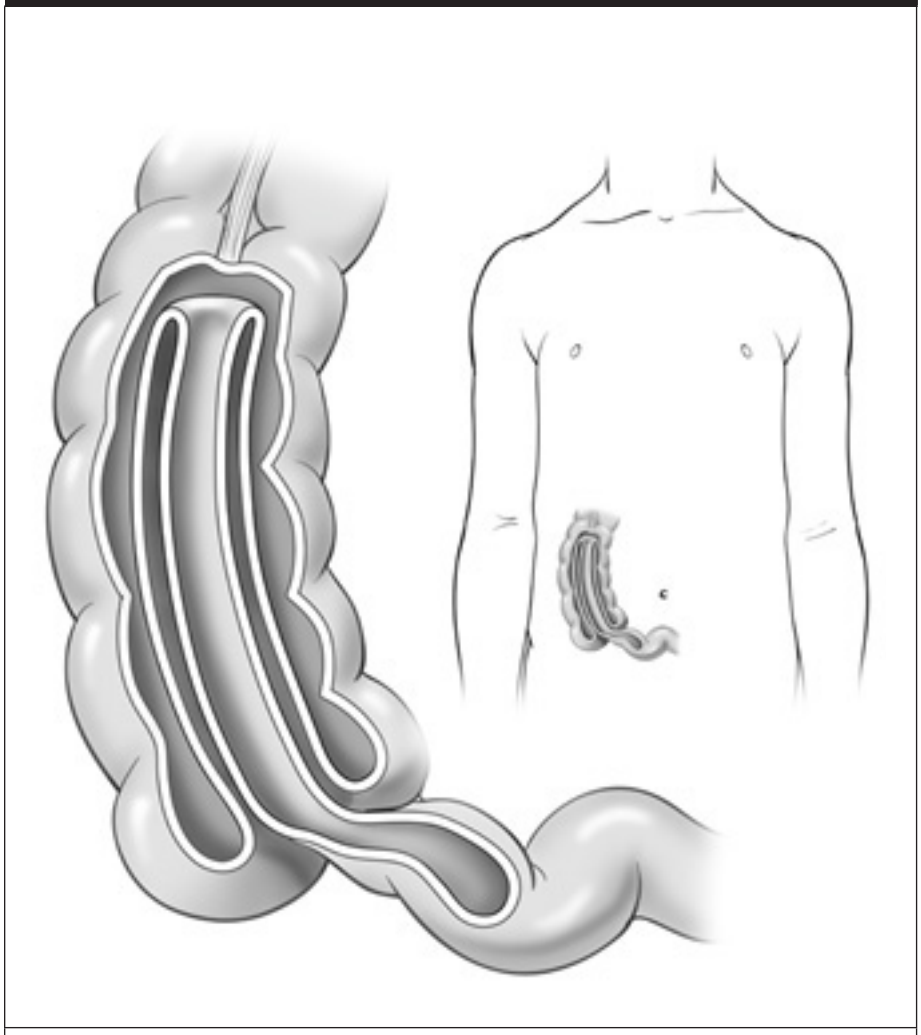

Image courtesy of N. Ewen Wang, MD.

Case #3

A 5-year-old boy presents to the ED complaining of right-sided abdominal pain. The child has no significant past medical history. Over the past day, the patient has had worsening periumbilical, right lower quadrant abdominal pain associated with tactile fevers, nausea, and one episode of nonbilious emesis. On exam, the patient appears nontoxic, with a soft, nondistended abdomen tender to palpation in the right lower quadrant. Testicular exam is normal. Vital signs include a heart rate of 110 beats per minute, respiratory rate of 20, and blood pressure of 100/60 mmHg.

Differential Diagnosis

In toddlers and school-age children, the differential diagnosis of acute abdominal pain requiring urgent/emergent intervention includes appendicitis, Meckel's

Figure 2. Hernia

diverticulum, testicular/ovarian torsion, and intussusception. This differential is listed in the third column of Table 1.

Appendicitis

Appendicitis is the most common cause of abdominal pain requiring surgical intervention. The incidence is approximately 28 in 10,000 for children younger than 14 years of age. However, it is less common in children younger than 4 years of age, and almost nonexistent in neonates because the funnel-shaped appendix is less prone to obstruction.[22] Typically, appendicitis is caused by inflammation of the appendix due to obstruction.

Clinical Features. Classically, patients present with right lower quadrant pain, anorexia, nausea, emesis, and fever. Migration from periumbilical to right lower quadrant pain also is specific for appendicitis, with a likelihood ratio of up to 3.1.[23] History should focus on the time course of symptoms, quality of pain, oral intake, hydration status, and prior abdominal surgeries.

The physical exam should focus on palpating the abdomen to find the area of maximal tenderness as well as assessing for peritonitis. Further physical exam findings, such as Rovsing's sign (pain in right lower quadrant with palpation of left lower quadrant), obturator sign (pain with hip flexion and internal rotation), and psoas sign (pain with hip extension), can increase suspicion for appendicitis. Further exam maneuvers, such as percussing the foot and having the child jump up and down, can assess for peritonitis. A genitourinary exam also should be performed, because testicular or ovarian pathology also can cause lower quadrant pain. Interestingly, in one study, fever with right lower quadrant pain was shown to be the most useful physical exam finding, with a likelihood ratio of 3.4 for acute appendicitis. Rebound tenderness had a likelihood ratio of 3.0.[23]

However, the absence of classic findings does not rule out appendicitis, since up to 80% of patients may not have a fever and up to 50% may not have migration of pain to the right lower quadrant, anorexia, or rebound tenderness.[24] Therefore, diagnosis should be made using the constellation of symptoms and clinical gestalt. Further, patients younger than 5 years of age and especially younger than 2 years of age may present with nonspecific symptoms, such as abdominal distension, diffuse abdominal pain, sepsis, decreased oral intake, and fever. Because the signs are nonspecific in this age group, diagnosis may be delayed, leading to perforation in up to 80% of neonates[25] and up to 69% of children younger than 5 years of age.[26] Fortunately, these account for less than 5% of cases.[22]

Diagnostic Imaging and Laboratory Workup. In stable patients with clinical signs or symptoms of possible appendicitis, labs often can be deferred until imaging is complete. However, labs potentially helpful in diagnosing acute appendicitis include complete blood count (CBC), C-reactive protein (CRP), and urinalysis. An elevated white blood cell count (WBC) has a sensitivity and specificity of approximately 80% for appendicitis

Figure 3. Findings Indicative of Appendicitis

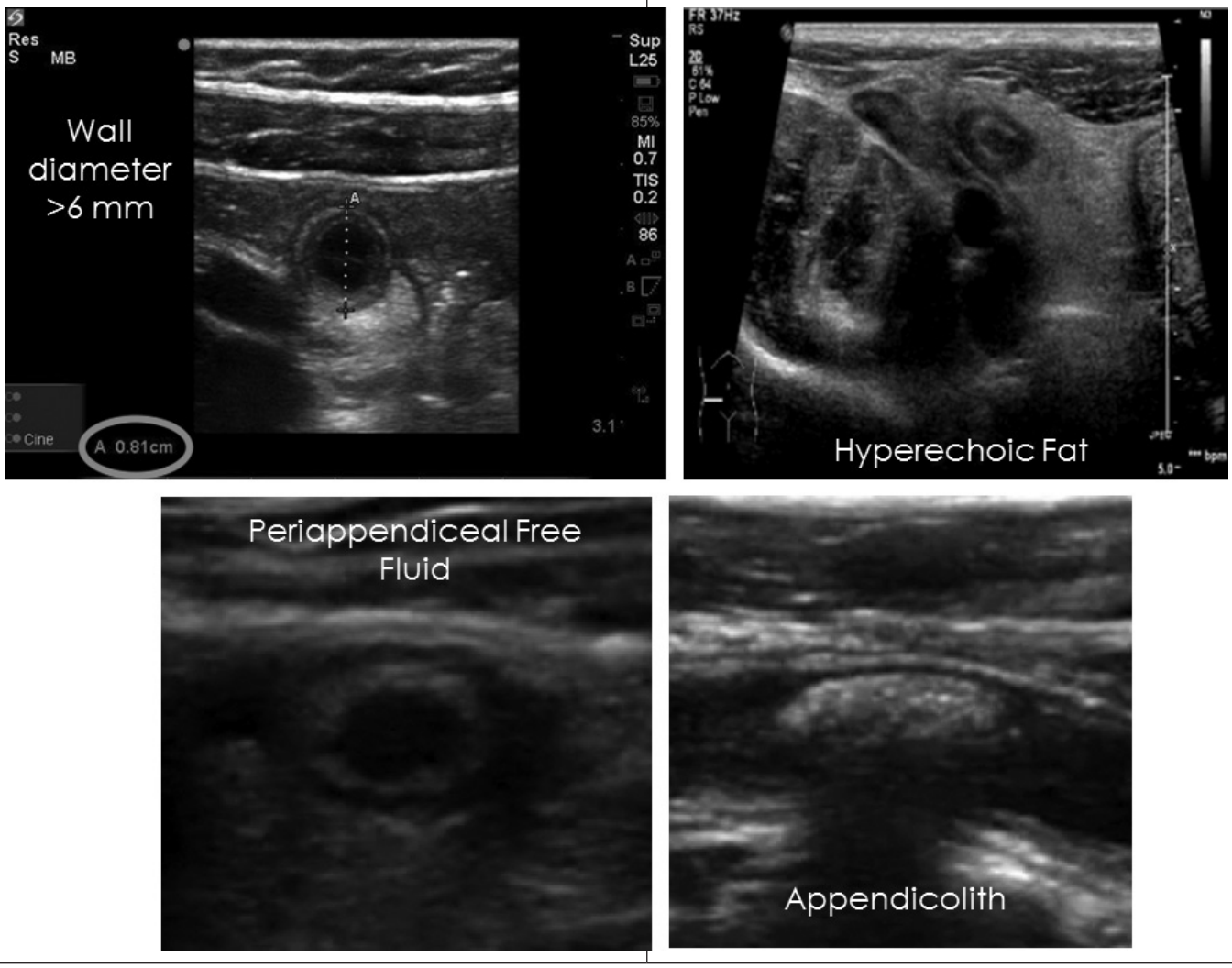

Images courtesy of Kimberly M. Fender, MD; Daniel B. Park, MD; and Daniel Migliaccio, MD, University of North Carolina, Chapel Hill.

among patients with nontraumatic abdominal pain in the ED.[27] Negative likelihood ratios for appendicitis with a WBC < 10,000 and absolute neutrophil count < 6,750 were 0.22 and 0.06, respectively, in a large systematic review.[23] Elevated CRP can be associated with appendicitis, but sensitivities and specificities have varied significantly in multiple studies. The CRP level may have a role in diagnosing perforation if it is greater than 5.[28] Elevation in both CRP and WBC is up to 90% specific, but is not sensitive.[29] Urinalysis should be done to rule out a urinary tract infection and nephrolithiasis that may be mimicking appendicitis symptoms.

Clinical scores, such as the Alvarado score and the pediatric appendicitis score (PAS), have been created to aid in risk stratification. They include physical exam findings, vital signs, and lab results, and have been validated prospectively with moderate predictive accuracy. However, none have been shown to surpass clinician gestalt or improve outcomes.[23] Therefore, routine use of scores is likely not necessary, but the scores can be used for risk stratification to aid in the decision to obtain imaging.

If the patient has a high probability of appendicitis based on clinical gestalt, history and physical exam, and available laboratory data, surgical consultation should be obtained prior to imaging. Depending on surgeon preference, the patient may be taken straight to the operating room for exploratory laparoscopy or imaging, such as ultrasound or computed tomography (CT) scan of the abdomen and pelvis with IV contrast.

In patients with equivocal clinical suspicion, imaging algorithm/practice has evolved over the past years. (*See Figures 3, 4, and 5.*) Current options include ultrasound, CT scan, and MRI. If available, most pediatric EDs perform ultrasound of the right lower quadrant for initial diagnostic imaging. Visualizing the appendix is dependent on the operator and patient body habitus, but can be as high as 80-90%. If the appendix is visualized, sensitivity and specificity were shown to be 98% and 92%, respectively, in a large cohort study.[30] If the ultrasound is equivocal (i.e., the appendix is not clearly visualized), there are three options. The first is to obtain a CT scan with IV contrast, which has a sensitivity and specificity approaching 100%. A benefit

Figure 4. Ultrasound of Appendicitis

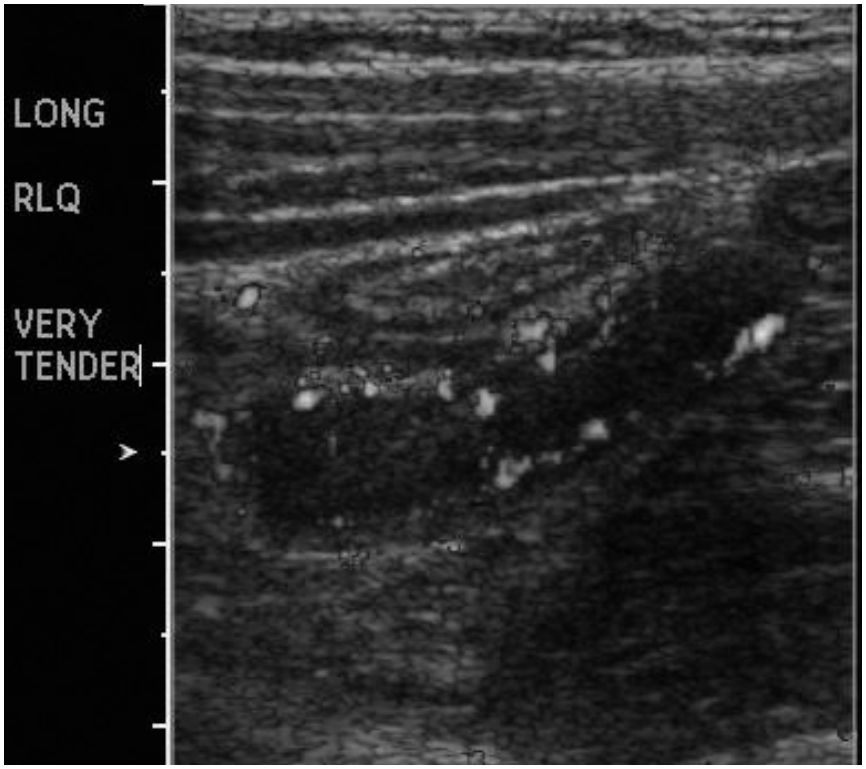

Figure 5. CT of Appendicitis

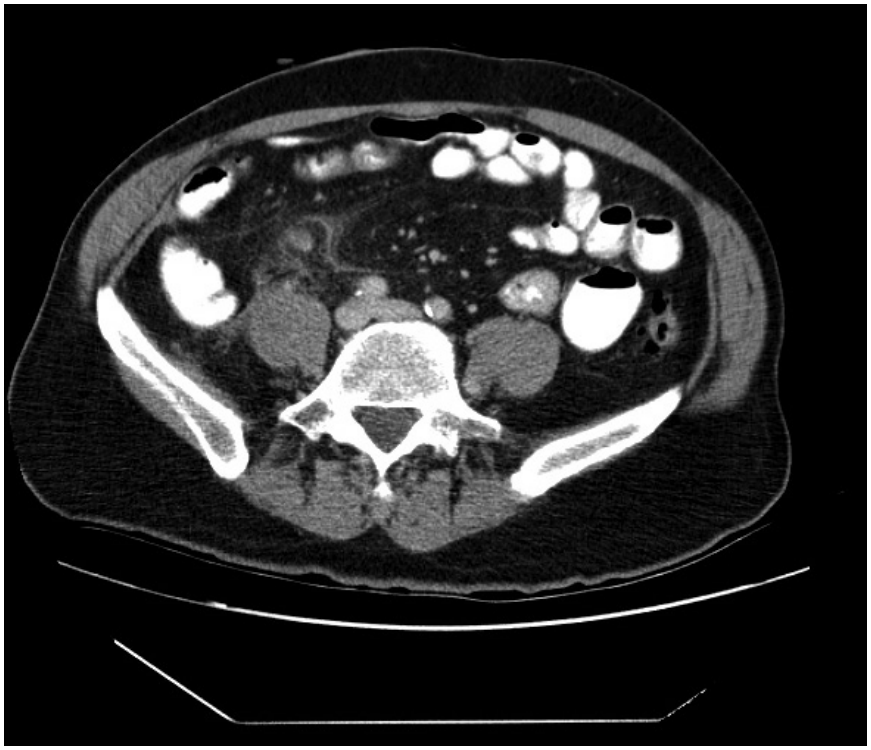

of CT includes rapid results, while a major disadvantage is exposure to radiation. The second option is to obtain an MRI, which has similar diagnostic accuracy to CT.[31] A benefit of MRI is lack of radiation, but the disadvantages include increased time, need for sedation in smaller children, and increased cost. Further, MRI scanners are not readily available in many EDs. The third option is to admit the patient for serial abdominal exams and repeat ultrasound, which also has been shown to be highly sensitive and specific, decreasing the need for CT scans.[32]

ED Management/Disposition. If the child is septic or ill-appearing with concern for perforation and generalized peritonitis, attention to airway, breathing, and circulation (ABCs); resuscitation; and consultation with pediatric surgery should be started immediately. IV access should be obtained with initiation of IV fluids and broad-spectrum antibiotics such as piperacillin/tazobactam. Once the diagnosis of appendicitis is confirmed either with high clinical suspicion or positive imaging, pediatric surgery should be consulted for further management.

Antibiotics should be initiated. In nonperforated appendicitis, the Infectious Diseases Society of America recommends a third-generation cephalosporin, such as ceftriaxone, combined with metronidazole, or a second-generation cephalosporin, such as cefoxitin or cefotetan.[33] In patients allergic to penicillin/cephalosporin, gentamicin and metronidazole can be used.[33] Broad-spectrum antibiotics, such as piperacillin/tazobactam, have been advocated by some surgeons, although subsequent studies have not shown benefit.[34]

Admission with appendectomy is the most common standard of care. However, nonsurgical treatment can be offered to a subset of patients who are older, without fecalith, and have lower inflammatory markers. Shared decision making with the family should be employed in this situation. Nonsurgical management still requires admission for administration of broad-spectrum IV antibiotics (i.e., piperacillin/tazobactam) until WBC normalizes and symptoms improve. In a large meta-analysis, patients treated nonsurgically had a recurrence rate of 22% at one year.[35] In a five-year follow-up study comparing surgical to nonsurgical management, there was a 39.1% rate of appendectomy in nonsurgically managed children.[36]

Figure 6. Testicular Torsion

The first Doppler image illustrates compromised vascular flow observed in testicular torsion. The second image of the male pelvis demonstrates the bladder and seminal vesicles in the transverse view.

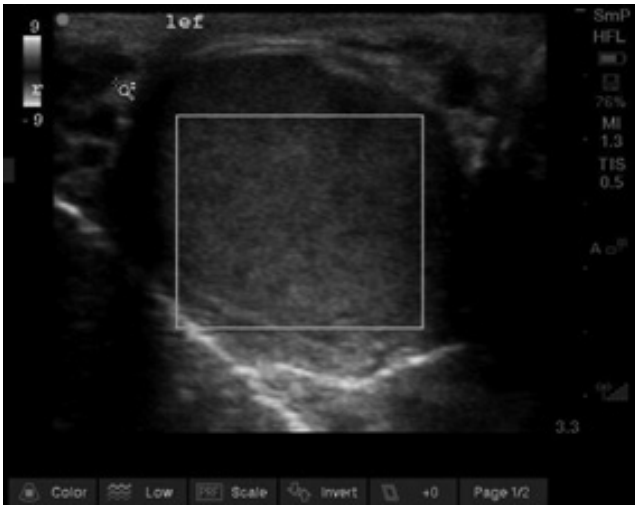

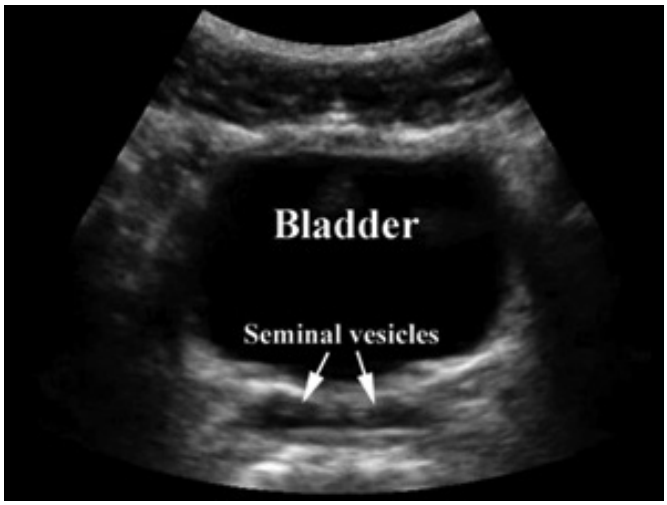

Images courtesy of Kimberly M. Fender, MD; Daniel B. Park, MD; and Daniel Migliaccio, MD, University of North Carolina, Chapel Hill.

Meckel's Diverticulum

Meckel's diverticulum is an outpouching of the small intestines into the vitelline duct typically located near the ileocecal junction. The prevalence is approximately 1-2%, with a predominance in males.[37] Children typically present between 2 and 8 years of age. The rule of 2s is commonly applied to Meckel's diverticulum, with 2% of population, presentation at age 2 years, two feet from ileocecal junction, and two inches in length. Uncommonly, the diverticulum can become inflamed (diverticulitis), causing abdominal pain.

Clinical Features. Patients with symptomatic Meckel's diverticulum can present with a wide variety of symptoms, including lower GI bleeding, intussusception, obstruction, diverticulitis, and perforation. Painless lower GI bleeding is the most common presentation.[37]

Diagnostic Imaging and Laboratory Workup. Diagnostic imaging and laboratory workup will be dictated by the clinical presentation. If the patient is toxic-appearing, the laboratory workup should include a complete blood count, comprehensive metabolic panel, and lactate. If obstruction or perforation is suspected, KUB should be obtained.

Since intussusception and appendicitis also likely are part of the differential diagnosis, performing a right lower quadrant ultrasound is recommended. Adding inflammatory markers also is reasonable for further evaluation, although this has not been studied in the setting of Meckel's diverticulitis. CT scan or MRI also can be performed if the ultrasound is nondiagnostic to further evaluate for diverticulitis.[37,38] Generally, Meckel's scans are not obtained in the ED, especially in children with focal abdominal pain and signs of obstruction, for two reasons. First, there are more common etiologies of obstruction and abdominal pain that will be diagnosed better with ultrasound or CT/MRI. Second, there may be false-negative results in the setting of necrotic tissue from obstruction/diverticulitis.[9,37,38]

ED Management/Disposition. For patients with intussusception, management is discussed earlier. In patients with obstruction or perforation, IV fluid resuscitation, possible nasogastric tube placement, broad-spectrum antibiotic administration (for perforation), and consultation with a pediatric surgeon should be obtained for operative management. If Meckel's diverticulitis is present, antibiotics should be initiated and pediatric surgery should be consulted for admission. There are no good studies on the addition of antibiotics in the setting of Meckel's diverticulitis, but given the similar pathophysiology to appendicitis, starting cefoxitin or ceftriaxone and metronidazole is reasonable. In patients with nondiagnostic imaging and a high index of suspicion for surgical pathology including Meckel's diverticulum or appendicitis, surgical consultation should be obtained for possible operative exploration and admission.[37]

Testicular and Ovarian Torsion

Testicular torsion also may occur in the toddler and school-age child. In the child, torsion is typically intravaginal in nature. The incidence is approximately 1 in 4,000 in males younger than 25 years of age.[39] Testicular torsion most commonly occurs during puberty, but it may occur in children of any age.[39] The majority of ovarian torsion cases occur in post-menarchal patients, but should be considered in children of any age because ovarian masses, such as cysts, increase the risk.

Clinical Features. The clinical features of testicular torsion include pain in the testicle. The history may include intermittent, severe lower abdominal pain associated with nausea. The physical exam should focus on examination of the testicle, including palpation, lie, and cremaster reflex. Horizontal lie and absent cremaster reflex can be predictive of torsion.[39] However, the physical exam, specifically the absent cremaster reflex, is not as sensitive or specific for testicular torsion as once thought and should not be relied on for diagnosis.[40] Similarly, ovarian torsion presents with severe,

Figure 7. Ovarian Torsion

The first image shows the peripheral distribution of the hypoechoic ovarian follicles, a common finding in ovarian torsion. The second image depicts a longitundinal view of the bladder, uterus, and posterior cul-de-sac.

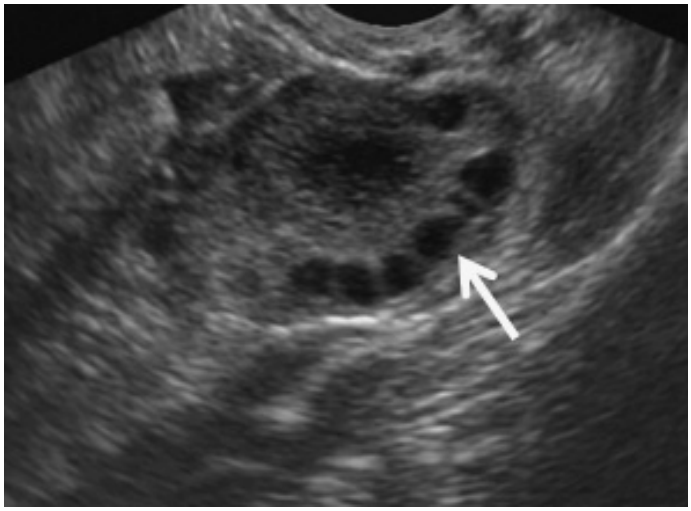

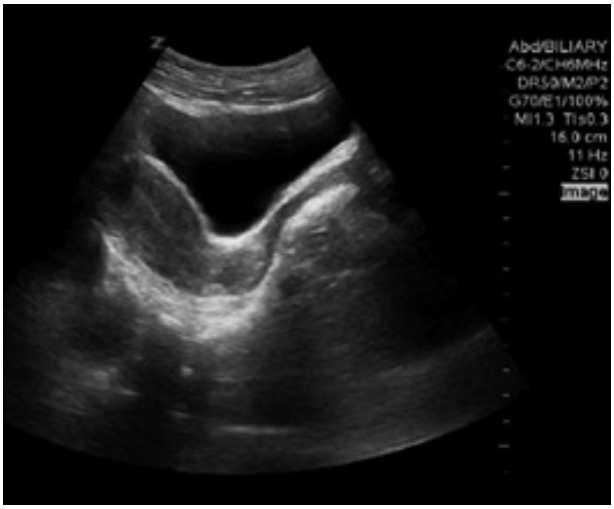

Images courtesy of Kimberly M. Fender, MD; Daniel B. Park, MD; and Daniel Migliaccio, MD, University of North Carolina, Chapel Hill.

intermittent lower abdominal or pelvic pain, typically unilateral, associated with nausea and emesis. The abdominal exam typically reveals tenderness to palpation in either lower quadrant with possible adnexal mass. A pelvic exam generally is deferred in children.

Diagnostic Imaging and Laboratory Workup. As with neonatal torsion, ultrasound with color Doppler is the first-line imaging modality. However, recent studies have shown poor sensitivity of 76% in surgically confirmed torsion cases.[41] (*See Figure 6.*) High-resolution ultrasound, advanced radiology training, and identification of whirlpool sign (a swirl mass along the spermatic cord) can improve the sensitivity and specificity.[41,42] The diagnostic imaging of choice for ovarian torsion also is ultrasound. However, the sensitivity of ultrasound is only approximately 51% for torsion. Interestingly, the presence of a mass 5 cm or larger was 83% sensitive for torsion in children.[43] Labs typically are not required. (*See Figure 7.*)

ED Management/Disposition. If there is a high clinical suspicion for testicular torsion, pediatric urology should be consulted immediately and patients should be taken urgently to the OR. Ovarian torsion presents a diagnostic challenge because ultrasound imaging is not sensitive enough to rule out the condition. Therefore, the entire clinical scenario including history, physical, ultrasound findings, and presence of ovarian mass should be used for risk stratification. If there is high suspicion, pediatric gynecology should be consulted for further evaluation and possible exploratory laparoscopy. If there is low suspicion, discharge with close follow-up and strict return precautions is reasonable.

Common Benign Causes of Abdominal Pain

Acute gastroenteritis and constipation are common in this age group. Constipation is a common cause of abdominal discomfort and affects up to one-third of children, especially those in the midst of toilet training.[44] The etiology is functional in more than 95% of cases.[45] The Rome IV criteria were created to identify patients with functional constipation and include: two or fewer defecations per week, one episode of fecal incontinence per week, a history of stool withholding, a history of painful or hard bowel movements, the presence of fecal mass in the rectum, and a history of large diameter stools. The presence of two criteria defines functional constipation.[44]

Clinical Features. The history should focus on diet, water intake, weight gain, pain with defecation, last bowel movement, regularity of bowel movements, and prior issues with constipation. Further history should concentrate on ruling out other serious causes of constipation, such as Hirschsprung's disease, neurogenic causes, and obstruction. Important information includes delayed meconium passage, blood in stool, comorbidities, and prior surgical history. The physical exam should reveal a nondistended and nontender abdomen. The stool sometimes may be palpated. The anus should be inspected for normal anatomy, presence of fissures, and anal wink. A rectal exam typically can be deferred. A neurologic exam should be completed to rule out neurogenic causes of constipation. The presence of any abnormalities on the physical exam should raise suspicion for a malignant cause of abdominal pain.

Diagnostic Imaging and Laboratory Workup. Diagnostic testing typically is not needed in the ED. If there are risk factors for organic causes of constipation, testing can be targeted based on the history and physical examination, such as urinalysis, electrolytes, or blood lead level. Abdominal X-rays are not indicated because they are not helpful in diagnosing constipation and even can be misleading.[46,47] Ultrasound measurement of the transrectal diameter has been proposed to aid in the diagnosis of constipation. A cutoff of 3.8 cm or greater had a sensitivity of 86% and specificity of 71%.[48]

ED Management/Disposition. ED management typically consists of inducing a bowel movement with suppository or enema. If a bowel movement cannot be induced and the patient is having significant pain with passing stool or showing signs of obstruction, admission may be necessary for bowel clean out. For patients who are discharged, parents should be counseled on changing the diet to increase fiber and fluid intake. In children who are withholding or who have pain with defecation, polyethylene glycol (PEG, Miralax) can be prescribed to loosen stool. Petroleum jelly can be used to treat anal fissures or anal pain. In addition to laxatives, a sodium-phosphate enema can be recommended to parents for children who have not had a bowel movement in a few days. However, enemas should not be used in children with comorbid gastrointestinal motility disorders, renal disease, or cardiac disease because they can cause life-threatening electrolyte derangements.[49] In a randomized, controlled trial comparing milk and molasses enema to PEG, patients who received the enema had quicker improvement in symptoms but were more upset with ED treatment. Improvement of symptoms at days three and five were not different between the groups.[50] Children can be discharged home safely if they are tolerating oral intake with a benign abdominal exam.

Conclusion

An age-based differential diagnosis for pediatric abdominal pain (neonates, infants, toddlers/children, adolescents) provides a framework for emergency providers to quickly recognize life-threatening diseases as well as common etiologies. Performing a targeted history, physical, and diagnostic workup based on the differential provided will allow for prompt diagnosis and treatment of pathology.

References

1. Aboagye J, Goldstein SD, Salazar JH, et al. Age at presentation of common pediatric surgical conditions: Reexamining dogma. *J Pediatr Surg* 2014;49:995-999.
2. Buettcher M, Baer G, Bonhoeffer J, et al. Three-year surveillance of intussusception in children in Switzerland. *Pediatrics* 2007;120:473-480.
3. Mandeville K, Chien M, Willyerd FA, et al. Intussusception: Clinical presentations and imaging characteristics. *Pediatr Emerg Care* 2012;28:842-844.
4. Kuppermann N, O'Dea T, Pinckney L, Hoecker C. Predictors of intussusception in young children. *Arch Pediatr Adolesc Med* 2000;154:250-255.
5. Hryhorczuk AL, Strouse PJ. Validation of US as a first-line diagnostic test for assessment of pediatric ileocolic intussusception. *Pediatr Radiol* 2009;39:1075-1079.
6. Whitehouse JS, Gourlay DM, Winthrop AL, et al. Is it safe to discharge intussusception patients after successful hydrostatic reduction? *J Pediatr Surg* 2010;45:1182-1186.
7. Yang WC, Chen CY, Wu HP. Etiology of non-traumatic acute abdomen in pediatric emergency departments. *World J Clin Cases* 2013;1:276-284.
8. Vandewalle RJ, Bagwell AK, Shields JR, et al. Radiographic and clinical factors in pediatric patients with surgical small-bowel intussusception. *J Surg Res* 2019;233:167-172.
9. Tseng YY, Yang YJ. Clinical and diagnostic relevance of Meckel's diverticulum in children. *Eur J Pediatr* 2009;168:1519-1523.
10. Chang SJ, Chen JY, Hsu CK, et al. The incidence of inguinal hernia and associated risk factors of incarceration in pediatric inguinal hernia: A nation-wide longitudinal population-based study. *Hernia* 2016;20:559-563.
11. Peevy KJ, Speed FA, Hoff CJ. Epidemiology of inguinal hernia in preterm neonates. *Pediatrics* 1986;77:246-247.
12. Puri P, Guiney EJ, O'Donnell B. Inguinal hernia in infants: The fate of the testis following incarceration. *J Pediatr Surg* 1984;19:44-46.
13. Hall DE, Roberts KB, Charney E. Umbilical hernia: What happens after age 5 years? *J Pediatr* 1981;98:415-417.
14. Merriman TE, Auldist AW. Ovarian torsion in inguinal hernias. *Pediatr Surg Int* 2000;16:383-385.
15. Erez I, Schneider N, Glaser E, Kovalivker M. Prompt diagnosis of 'acute groin' conditions in infants. *Eur J Radiol* 1992;15:185-189.
16. Toki A, Watanabe Y, Sasaki K, et al. Ultrasonographic diagnosis for potential contralateral inguinal hernia in children. *J Pediatr Surg* 2003;38:224-226.
17. Brandt ML. Pediatric hernias. *Surg Clin North Am* 2008;88:27-43, vii-viii.
18. Boley SJ, Cahn D, Lauer T, et al. The irreducible ovary: A true emergency. *J Pediatr Surg* 1991;26:1035-1038.
19. Gahukamble DB, Khamage AS. Early versus delayed repair of reduced incarcerated inguinal hernias in the pediatric population. *J Pediatr Surg* 1996;31:1218-1220.
20. Elliott EJ. Acute gastroenteritis in children. *BMJ* 2007;334:35-40.
21. Freedman SB, Adler M, Seshadri R, Powell EC. Oral ondansetron for gastroenteritis in a pediatric emergency department. *N Engl J Med* 2006;354:1698-1705.
22. Addiss DG, Shaffer N, Fowler BS, Tauxe RV. The epidemiology of appendicitis and appendectomy in the United States. *Am J Epidemiol* 1990;132:910-925.
23. Bundy DG, Byerley JS, Liles EA, et al. Does this child have appendicitis? *JAMA* 2007;298:438-451.
24. Becker T, Kharbanda A, Bachur R. Atypical clinical features of pediatric appendicitis. *Acad Emerg Med* 2007;14:124-129.
25. Schwartz KL, Gilad E, Sigalet D, et al. Neonatal acute appendicitis: a proposed algorithm for timely diagnosis. *J Pediatr Surg* 2011;46:2060-2064.
26. Nance ML, Adamson WT, Hedrick HL. Appendicitis in the young child: A continuing diagnostic challenge. *Pediatr Emerg Care* 2000;16:160-162.
27. Wang LT, Prentiss KA, Simon JZ, et al. The use of white blood cell count and left shift in the diagnosis of appendicitis in children. *Pediatr Emerg Care* 2007;23:69-76.
28. Chung JL, Kong MS, Lin SL, et al. Diagnostic value of C-reactive protein in children with perforated appendicitis. *Eur J Pediatr* 1996;155:529-531.
29. Kwan KY, Nager AL. Diagnosing pediatric appendicitis: Usefulness of laboratory markers. *Am J Emerg Med* 2010;28:1009-1015.
30. Mittal MK, Dayan PS, Macias CG, et al. Performance of ultrasound in the diagnosis of appendicitis in children in a multicenter cohort. *Acad Emerg Med* 2013;20:697-702.
31. Moore MM, Kulaylat AN, Hollenbeak CS, et al. Magnetic resonance imaging in pediatric appendicitis: A systematic review. *Pediatr Radiol* 2016;46:928-939.
32. Schuh S, Chan K, Langer JC, et al. Properties of serial ultrasound clinical diagnostic pathway in suspected appendicitis and related computed tomography use. *Acad Emerg Med* 2015;22:406-414.
33. Bratzler DW, Dellinger EP, Olsen KM, et al. Clinical practice guidelines for antimicrobial prophylaxis in surgery. *Surg Infect* 2013;14:73-156.
34. Kronman MP, Oron AP, Ross RK, et al. Extended- versus narrower-spectrum antibiotics for appendicitis. *Pediatrics* 2016;138. pii: e20154547. doi: 10.1542/peds.2015-4547.
35. Huang L, Yin Y, Yang L, et al. Comparison of antibiotic therapy and appendectomy for acute uncomplicated appendicitis in children: A meta-analysis. *JAMA Pediatr* 2017;171:426-434.
36. Salminen P, Tuominen R, Paajanen H, et al. Five-year follow-up of antibiotic therapy for uncomplicated acute appendicitis in the APPAC randomized clinical trial. *JAMA* 2018;320:1259-1265.
37. Huang CC, Lai MW, Hwang FM, et al. Diverse presentations in pediatric Meckel's diverticulum: A review of 100 cases. *Pediatr Neonatol* 2014;55:369-375.
38. Olson DE, Kim YW, Donnelly LF. CT findings in children with Meckel diverticulum. *Pediatr Radiol* 2009;39:659-663; quiz 766-657.

CME/CE INSTRUCTIONS

To earn credit for this activity, please follow these instructions:

1. Read and study the activity, using the provided references for further research.
2. Log on to ReliasMedia.com and click on My Account. First-time users must register on the site. Tests are taken after each issue.
3. Pass the online test with a score of 100%; you will be allowed to answer the questions as many times as needed to achieve a score of 100%.
4. After successfully completing the test, your browser will be directed to the activity evaluation form, which you will submit online.
5. Once the completed evaluation is received, a credit letter will be emailed to you.

39. Williamson RC. Torsion of the testis and allied conditions. *Br J Surg* 1976;63:465-476.
40. Mellick LB. Torsion of the testicle: It is time to stop tossing the dice. *Pediatr Emerg Care* 2012;28:80-86.
41. Kalfa N, Veyrac C, Lopez M, et al. Multicenter assessment of ultrasound of the spermatic cord in children with acute scrotum. *J Urol* 207;177:297-301.
42. Osumah TS, Jimbo M, Granberg CF, Gargollo PC. Frontiers in pediatric testicular torsion: An integrated review of prevailing trends and management outcomes. *J Pediatr Urol* 2018;14:394-401.
43. Oltmann SC, Fischer A, Barber R, et al. Cannot exclude torsion — a 15-year review. *J Pediatr Surg* 2009;44:1212-1216; discussion 1217.
44. Robin SG, Keller C, Zwiener R, et al. Prevalence of pediatric functional gastrointestinal disorders utilizing the Rome IV criteria. *J Pediatr* 2018;195:134-139.
45. Loening-Baucke V. Prevalence, symptoms and outcome of constipation in infants and toddlers. *J Pediatr* 2005;146:359-363.
46. Freedman SB, Thull-Freedman J, Manson D, et al. Pediatric abdominal radiograph use, constipation, and significant misdiagnoses. *J Pediatr* 2014;164:83-88 e82.
47. Reuchlin-Vroklage LM, Bierma-Zeinstra S, Benninga MA, Berger MY. Diagnostic value of abdominal radiography in constipated children: A systematic review. *Arch Pediatr Adolesc Med* 2005;159:671-678.
48. Doniger SJ, Dessie A, Latronica C. Measuring the transrectal diameter on point-of-care ultrasound to diagnose constipation in children. *Pediatr Emerg Care* 2018;34:154-159.
49. Mendoza J, Legido J, Rubio S, Gisbert JP. Systematic review: The adverse effects of sodium phosphate enema. *Aliment Pharmacol Ther* 2007;26:9-20.
50. Miller MK, Dowd MD, Friesen CA, Walsh-Kelly CM. A randomized trial of enema versus polyethylene glycol 3350 for fecal disimpaction in children presenting to an emergency department. *Pediatr Emerg Care* 2012;28:115-119.

CME/CE Questions

1. A 5-year-old child presents with fever, nausea, anorexia, and periumbilical/right lower quadrant tenderness. Which of the following imaging tests is best for initial assessment?
   a. CT scan
   b. Ultrasound
   c. X-ray of the abdomen
   d. MRI
2. The same child from question 1 has an ultrasound that is nondiagnostic. The ultrasound was unable to visualize the appendix but there are no other abnormal findings. You are still considering appendicitis as a possible diagnosis. Which of the following is an appropriate next step?
   a. PT, PTT
   b. Serial procalcitonins
   c. CT abdomen
   d. Serial PAS scores
3. A 13-year-old female presents to the ED with intense right lower quadrant pain for the past 10 hours associated with nausea, vomiting, and anorexia. Vital signs are as follows: heart rate 90 beats per minute, blood pressure 110/70 mmHg, RR 16, SpO_2 100% on RA, Temp 37° C. Which is the most appropriate initial imaging studies to obtain?
   a. CT abdomen
   b. Ultrasound of appendix and ovaries
   c. Kidney, ureter, and bladder X-ray
   d. Complete blood count
4. A 14-month-old presents with colicky abdominal pain, fussiness worse than normal, decreased oral intake, and decreased wet diapers. Which of the following imaging modalities is the most useful for this patient?
   a. CT scan
   b. Ultrasound
   c. X-ray of the abdomen
   d. Upper GI series
5. Which of the following may cause painless bloody stools?
   a. Intussusception
   b. Meckel's diverticulum
   c. Appendicitis
   d. Ovarian torsion

PEDIATRIC EMERGENCY MEDICINE REPORTS

CME/CE Objectives

Upon completion of this educational activity, participants should be able to:

- recognize specific conditions in pediatric patients presenting to the emergency department;
- describe the epidemiology, etiology, pathophysiology, historical, and examination findings associated with conditions in pediatric patients presenting to the emergency department;
- formulate a differential diagnosis and perform necessary diagnostic tests;
- apply up-to-date therapeutic techniques to address conditions discussed in the publication;
- discuss any discharge or follow-up instructions with patients.

PEDIATRIC EMERGENCY MEDICINE REPORTS™ (ISSN 1082-3344) is published monthly by Relias LLC, 1010 Sync St., Ste. 100, Morrisville, NC 27560-5468. Periodicals postage paid at Morrisville, NC, and additional mailing offices. POSTMASTER: Send address changes to ***Pediatric Emergency Medicine Reports***, Relias LLC, 1010 Sync St., Ste. 100, Morrisville, NC 27560-5468.

Associate Editor: Journey Roberts

Executive Editor: Shelly Mark

Editorial Group Manager: Leslie Coplin

Accreditations Manager: Amy M. Johnson, MSN, RN, CPN

GST Registration No.: R128870672

Back issues: $65. Missing issues will be fulfilled by customer service free of charge when contacted within one month of the missing issue's date.

SUBSCRIBER INFORMATION

CUSTOMER SERVICE: (800) 688-2421

Customer Service Email Address:
customerservice@reliasmedia.com

Editorial Email Address:
jroberts@relias.com

Website:
ReliasMedia.com

MULTIPLE COPIES:

Discounts are available for group subscriptions, multiple copies, site licenses, or electronic distribution. For pricing information, please contact our Group Account Managers at groups@reliasmedia.com or (866) 213-0844.

RELIAS MEDIA

ACCREDITATION

Relias LLC is accredited by the Accreditation Council for Continuing Medical Education (ACCME) to provide continuing medical education for physicians.

Relias LLC designates this enduring material for a maximum of 3 *AMA PRA Category 1 Credits*™. Physicians should claim only credit commensurate with the extent of their participation in the activity.

Approved by the American College of Emergency Physicians for a maximum of 3 hours of ACEP Category I credit.

This continuing medical education activity has been reviewed by the American Academy of Pediatrics and is acceptable for a maximum of 3 AAP credits. These credits can be applied toward the AAP CME/CPD Award available to Fellows and Candidate Members of the American Academy of Pediatrics.

The American Osteopathic Association has approved this continuing education activity for up to 2.5 AOA Category 2-B credits.

Relias LLC is accredited as a provider of continuing nursing education by the American Nurses Credentialing Center's Commission on Accreditation. Contact hours [3] will be awarded to participants who meet the criteria for successful completion. California Board of Registered Nursing, Provider CEP#13791.

This CME activity is intended for emergency and pediatric physicians and nurses. It is in effect for 36 months from the date of the publication.

This is an educational publication designed to present scientific information and opinion to health professionals, to stimulate thought, and further investigation. It does not provide advice regarding medical diagnosis or treatment for any individual case. It is not intended for use by the layman. Opinions expressed are not necessarily those of this publication. Mention of products or services does not constitute endorsement. Clinical, legal, tax, and other comments are offered for general guidance only; professional counsel should be sought for specific situations.

PEDIATRIC EMERGENCY MEDICINE REPORTS

Practical, Evidence-Based Reviews in Pediatric Emergency Care

Approach to Pediatric Abdominal Pain in the ED: Part II

Age-Based Differential Diagnosis for Emergency and Common Causes of Pediatric Abdominal Pain

	Neonate (0-28 days)	Infant (1-24 months)	Toddler/Child (2-10 years)	Adolescent (11-18 years)
Emergent/Urgent	• Necrotizing enterocolitis • Malrotation with midgut volvulus • Hirschsprung's disease with toxic megacolon • Pyloric stenosis • Testicular torsion • Obstruction from atresia	• Intussusception • Incarcerated hernia • Hirschsprung's disease with toxic megacolon • Meckel's diverticulitis • Hemolytic uremic syndrome	• Appendicitis • Meckel's diverticulitis • Testicular/ovarian torsion • Intussusception • Hemolytic uremic syndrome	• Appendicitis • Cholecystitis/ cholangitis • Testicular/ovarian torsion • Ectopic pregnancy
Common/Generally Benign	• Colic • Reflux • Milk protein allergy	• Gastroenteritis • Viral syndrome	• Gastroenteritis • Viral syndrome • Constipation	• Gastroenteritis • Viral syndrome • Constipation

Depiction of Intussusception Showing Telescoping of Terminal Ileum Into the Cecum

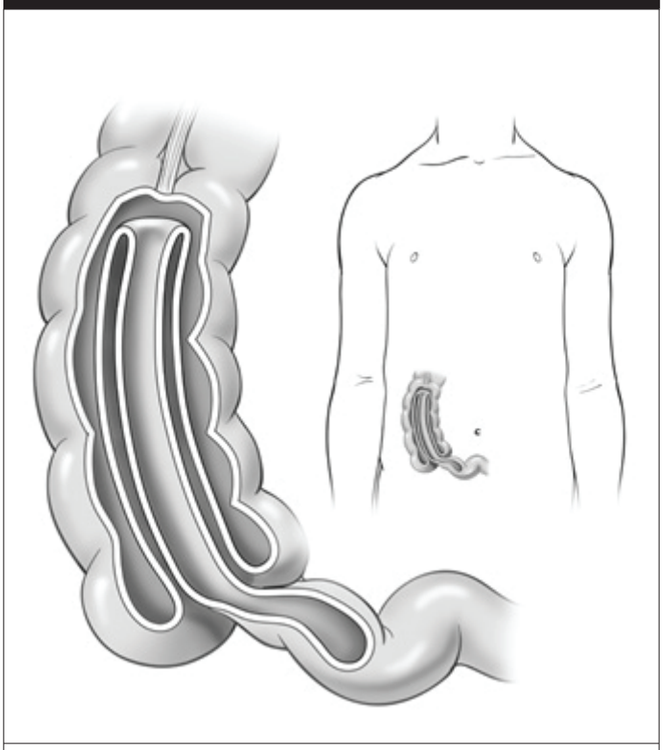

Image courtesy of N. Ewen Wang, MD.

Hernia

Findings Indicative of Appendicitis

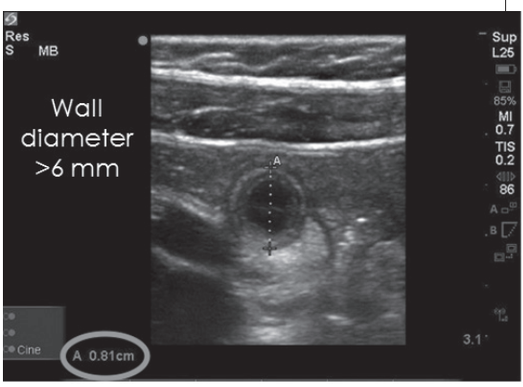

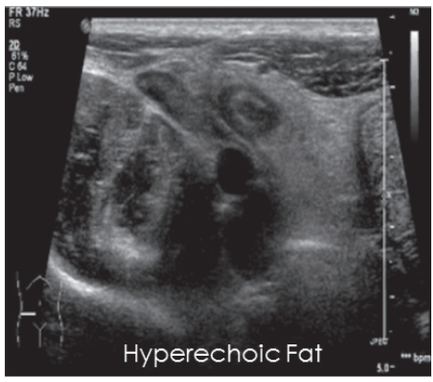

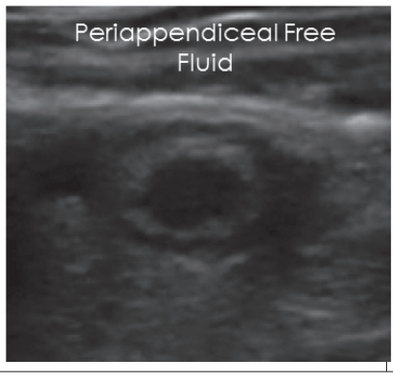

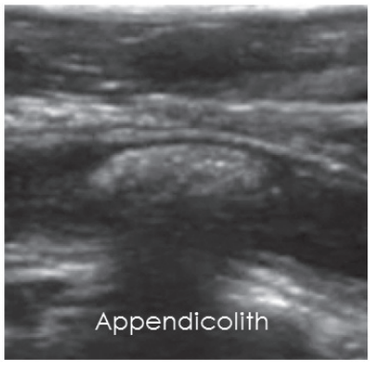

Images courtesy of Kimberly M. Fender, MD; Daniel B. Park, MD; and Daniel Migliaccio, MD, University of North Carolina, Chapel Hill.

Testicular Torsion

The first Doppler image illustrates compromised vascular flow observed in testicular torsion. The second image of the male pelvis demonstrates the bladder and seminal vesicles in the transverse view.

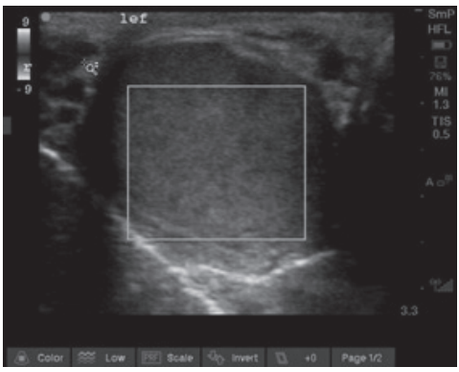

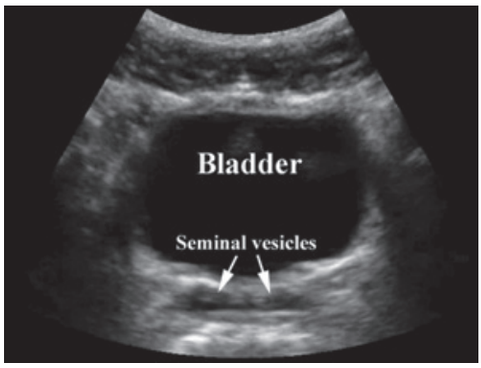

Images courtesy of Kimberly M. Fender, MD; Daniel B. Park, MD; and Daniel Migliaccio, MD, University of North Carolina, Chapel Hill.

Ovarian Torsion

The first image shows the peripheral distribution of the hypoechoic ovarian follicles, a common finding in ovarian torsion. The second image depicts a longitundinal view of the bladder, uterus, and posterior cul-de-sac.

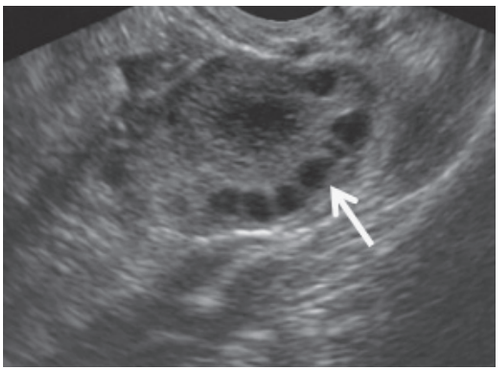

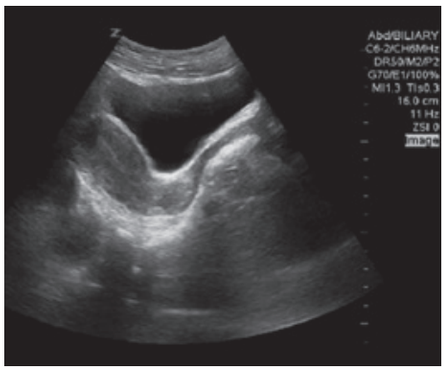

Images courtesy of Kimberly M. Fender, MD; Daniel B. Park, MD; and Daniel Migliaccio, MD, University of North Carolina, Chapel Hill.

Supplement to *Pediatric Emergency Medicine Reports*, September 2019: "Approach to Pediatric Abdominal Pain in the ED: Part II." Authors: Jeffrey T. Sakamoto, MD, Resident, Stanford Emergency Medicine Residency Program, Stanford, CA; Monika Thomas-Uribe, MD, MPH, Department of Pediatrics, UCSF-Fresno; Pablo Tarsicio Uribe-Leitz, MD, MPH, Center for Surgery and Public Health: Harvard Medical School, Harvard T.H. Chan School of Public Health, and the Department of Surgery, Brigham & Women's Hospital, Boston, MA; and N. Ewen Wang, MD, Professor of Emergency Medicine, Stanford School of Medicine, Stanford, CA.