PEDIATRIC EMERGENCY MEDICINE REPORTS

Practical, Evidence-Based Reviews in Pediatric Emergency Care

November 2020 VOL. 25, NO. 11

AUTHORS

Zahra M. Ghazi-Askar, MD, Clinical Assistant Professor; Director, Pediatric Ultrasound Education; Department of Emergency Medicine, Stanford School of Medicine, Stanford, CA

R. Conner Dixon, MD, Chief Resident Physician, Stanford University School of Medicine, Stanford, CA

N. Ewen Wang, MD, Professor of Emergency Medicine, Stanford School of Medicine, Stanford, CA

PEER REVIEWER

Aaron Leetch, MD, FACEP, Associate Professor, Director Pediatric Emergency Medicine Residency, University of Arizona, Tucson

STATEMENT OF FINANCIAL DISCLOSURE

To reveal any potential bias in this publication, and in accordance with Accreditation Council for Continuing Medical Education guidelines, we disclose that Dr. Dietrich (editor), Dr. Skrainka (CME question reviewer), Dr. Ghazi-Askar (author), Dr. Dixon (author), Dr. Wang (author), Dr. Leetch (peer reviewer), Ms. Bauer (nurse reviewer), Ms. Coplin (editorial group manager), Mr. Gates (associate editor), and Ms. Mark (executive editor) report no relationships with companies related to the field of study covered by this CME activity.

Relias Media
From Relias

Pediatric Musculoskeletal Point-of-Care Ultrasound: Everything but the Bones

Ultrasound is an incredible tool that keeps becoming more valuable. In this article, the authors show how point-of-care ultrasound of the musculoskeletal system can help clinicians identify a diversity of diseases, including soft tissue infections, abscesses, and foreign bodies! In a later issue, the authors explore the use of ultrasound to identify bone and joint issues.

— Ann M. Dietrich, MD, FAAP, FACEP

Introduction

Point-of-care ultrasound (POCUS) has become a staple in the evaluation and treatment of patients in the emergency department (ED). From focused assessment with sonography in trauma to echocardiogram, the use of POCUS to guide diagnostic tests and treatment has been adopted into the emergency physician's broad purview.

Initially, ED POCUS was limited to the evaluation of trauma and obstetrical diseases. In the past decade, there has been not only rapid development in ultrasound (US) technology, but also evidence of the value of US in the investigation of musculoskeletal disorders in the ED and on the sidelines of sports fields.

This article reviews techniques and imaging appearances of normal musculoskeletal structures and discusses pediatric clinical applications in the evaluation and treatment of patients with common musculoskeletal complaints.

This article also will review normal tissue, starting from the skin, then moving through subcutaneous fat, muscle, tendons, and lymph nodes. Then, normal tissue will be compared to pathology: cellulitis, abscess, muscle and tendon hematoma and rupture, and lymphadenopathy/lymphadenitis.

After reviewing this article, practitioners should be able to use the steps necessary to acquire and optimize a US image; understand the different US appearances of skin, muscles, tendons, and nerves; and identify pathology for diagnostic and interventional purposes.

Indications

US can be used to identify and differentiate tendons, muscles, ligaments, nerves, and vessels with great resolution. These tissues generally are described by their echogenicity: isoechoic, hypoechoic, anechoic, hyperechoic. Musculoskeletal US also uses the artifact of anisotropy or

EXECUTIVE SUMMARY

- Anisotropy is the different ultrasound (US) echogenicity of normal tissue when the angle of the US beam is not perpendicular to the plane of the structure being imaged. Depending on the angle of the probe in relation to the axis of the structure, the structure can appear with a different echogenicity. This technique is helpful for following structures, such as tendons, their entire lengths and can be used to discern discontinuities and other pathologies.
- Higher frequency linear array transducers do not penetrate deep into the tissues, making them ideal for imaging superficial body structures. For most musculoskeletal imaging, an 8- to 14-MHz transducer should be used.
- The stage and the severity of infection determines the appearance of cellulitis on ultrasound. Initially, there is a thickening of the subcutaneous soft tissue, along with a loss of normal morphology. There is a diffuse increase in echogenicity of the skin and adjacent adipose tissue.
- In cellulitis, the increased echogenicity may be seen in other conditions causing soft tissue edema, such as a local allergic reaction. As the infection progresses, the inflamed and hyperechoic fat lobules are separated by fluid.
- On US, both radiolucent and radiopaque materials appear hyperechoic. There is often a surrounding hypoechoic rim, and posterior shadowing or reverberation artifact often are also detected.

"the angle dependent appearance of a tissue." (*See Figure 1.*)

Anisotropy is the different US echogenicity of normal tissue when the angle of the US beam is not perpendicular to the plane of the structure being imaged. Depending on the angle of the probe in relation to the axis of the structure, the structure can appear with a different echogenicity. This technique is helpful for following structures, such as tendons, their entire lengths and can be used to discern discontinuities and other pathologies. Anisotropy is more pronounced in tendons and is less pronounced in other soft tissues, including muscles, ligaments, and nerves.

Some structures, such as tendons, appear hyperechoic (white) when the probe is perpendicular to them. But they will look hypoechoic (black) if the angle of insonation (the US beam relative to the tissue or organ of interest) is not at 90 degrees. This property helps identify structures that manifest anisotropy.

Probe Selection

The key to obtaining useful information about most musculoskeletal pathologies is using the highest frequency linear array transducer available. Because higher frequencies do not penetrate deep into the tissues, they are ideal for imaging superficial body structures. For most musculoskeletal imaging, an 8- to 14-MHz transducer should be used. The indicator on the US transducer should be pointing to the right side of the patient in the transverse view and cephalad in the longitudinal view.

Technique

The probe should be positioned initially in the transverse and then in the longitudinal orientation on the area of interest. Copious gel allows better visualization of very superficial structures and eliminates the need for applying excessive pressure during the often-painful indications for musculoskeletal US.

Water Bath Technique

The small field of view, relative compressibility of the soft-tissue structures by the transducer, patient motion, and discomfort from contact of the transducer with the pathology often limit conventional US evaluation with direct contact of the probe over the structure to be examined. A water bath technique can overcome these limitations.

This technique is especially useful in the US imaging of shallow skin ulcers, subcutaneous masses, vascular malformations, osteomyelitis, and foreign bodies. The body part to be evaluated is immersed in a bucket or tray filled with water. The probe head then is held about 1 cm above the body part.

This technique is used most often to study the hands and feet. It does not require US gel, since the water itself is an excellent conductor of US waves. Most US probes are water resistant up to the level of the cord.

The Bladder Technique

If a risk of infection is present, or when the water bath technique cannot be utilized for other reasons, the bladder technique can be used. The bladder technique involves using a small balloon (or glove) filled with water or gel. The balloon is pressed against the area of interest, and the US transducer is pressed against the balloon. The US waves pass through the balloon and will provide the desired image.

Normal Anatomy

US provides excellent visualization and distinction between the different soft tissues because they vary substantially in water content and echogenicity. (*See Figure 2.*) Skin is the most echogenic tissue, while fat is the least echogenic.

Skin

Sonographically, the epidermis and dermis appear as thin, linear, echogenic stripes. In non-disease states, the two layers are often too thin to be distinguished from each other. (*See Figure 2.*)

Subcutaneous Fat

Normal subcutaneous tissue appears hypoechoic, with thin and linear echogenic structures separating the fat lobules. The linear structures are parallel to the overlying skin.[1] (*See Figure 2.*)

Muscle

Normal muscle tissue consists of multiple muscle fascicles. These

Figure 1. Insonation of an Achilles Tendon Ultrasound

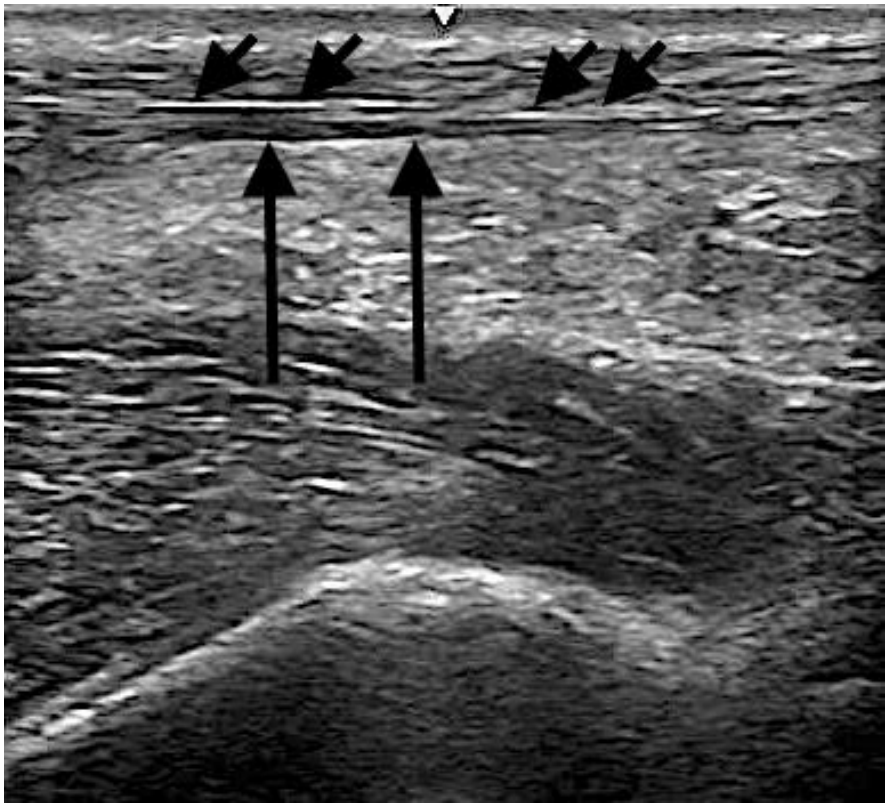

Long-axis view of a normal Achilles tendon comprised of fibrous connective tissue. Note how the tendon can appear both hyperechoic when the angle of insonation is at 90 degrees, or perpendicular, to the US probe (short arrows) and anechoic when the angle is different than 90 degrees (long arrows) because of anisotropy artifacts.

Image courtesy of Zahra M. Ghazi-Askar, MD; Vinson Vong, MD; and R. Conner Dixon, MD.

fascicles appear hypoechoic compared to the hyperechoic sheath, called the perimysium, that surrounds the muscle structure.[1] (*See Figure 3.*)

Tendons

Tendons manifest an organized, fibrillar orientation on long-axis sonographic views. On the short axis, tendons appear oval-shaped and contain small, dot-like structures. Tendons have no vascularity on color flow imaging. Ligaments have a similar appearance to tendons, except they are more compact.[1] (*See Figures 4 and 5.*)

Nerve

US demonstrates nerves as "honeycomb" or "pepper pot" structures composed of hypoechoic spots embedded in a hyperechoic background. They appear distinctly different from tendons in a transverse/short-axis image. (*See Figure 6.*)

Fluid

Fluid has an anechoic appearance on US and can be confirmed with dynamic interrogation, as it should respond to pressure. Figure 7 shows the anechoic or black appearance of fluid within the deep infrapatellar bursa of the knee.

Lymph Nodes

Normal lymph nodes have an oval shape. The central hilum appears hyperechoic, and the vascularity pattern on color flow imaging is seen on the peripheral aspect of the lymph node.[1] (*See Figures 8 and 9 in the appendix.*)

Sonographic Appearances of Musculoskeletal Pathology

Cellulitis

The stage and the severity of infection determines the appearance of cellulitis on ultrasound. Initially, there is a thickening of the subcutaneous soft tissue, along with a loss of normal morphology. There is a diffuse increase in echogenicity of the skin and adjacent adipose tissue. (*See Figure 10 in the appendix.*). Within the first few days of infection, there is a loss of the lines that separate the fat lobules.[1,2]

The increased echogenicity may be seen in other conditions causing soft tissue edema, such as a local allergic reaction. As the infection progresses, the inflamed and hyperechoic fat lobules are separated by fluid.[2] The increasing edema and fluid accumulation between the fat labules manifest as hypoechoic or anechoic areas. The appearance of hyperechoic fat lobules separated by hypoechoic/anechoic fluid is called cobblestoning.[1] (*See Figures 11 and 12 in the appendix.*)

Abscess

An abcess appears as a demarcated hypoechoic fluid collection on US. Heterogenous components, debris, and septations may be visualized in some cases.[1,3] (*See Figures 12, 13, and 14 in the appendix.*)

Abscesses often demonstrate posterior acoustic enhancement on US. Gentle, repetitive pressure placed over the abscess with the ultrasound probe produces a circular and swirling motion of the abscess contents. This is oftened lightheartedly referred to as "pustalsis" in the ultrasound world.[1]

Soft Tissue Foreign Bodies

US is useful in identifying nonradiopaque foreign bodies that are not readily visualized on conventional radiographs. Examples of nonradiopaque foreign bodies include wood, plant thorns, and certain glass material. On US, both radiolucent and radiopaque materials appear hyperechoic. (*See Figure 15 in the appendix.*) There is often a surrounding hypoechoic rim, and posterior shadowing or reverberation artifact often are also detected.[1]

When looking smaller (< 3 mm) foreign bodies that may not be readily visible, look for the artifacts mentioned in association with surrounding hyperemia with color

Figure 2. Echogenicity in Ultrasound Images

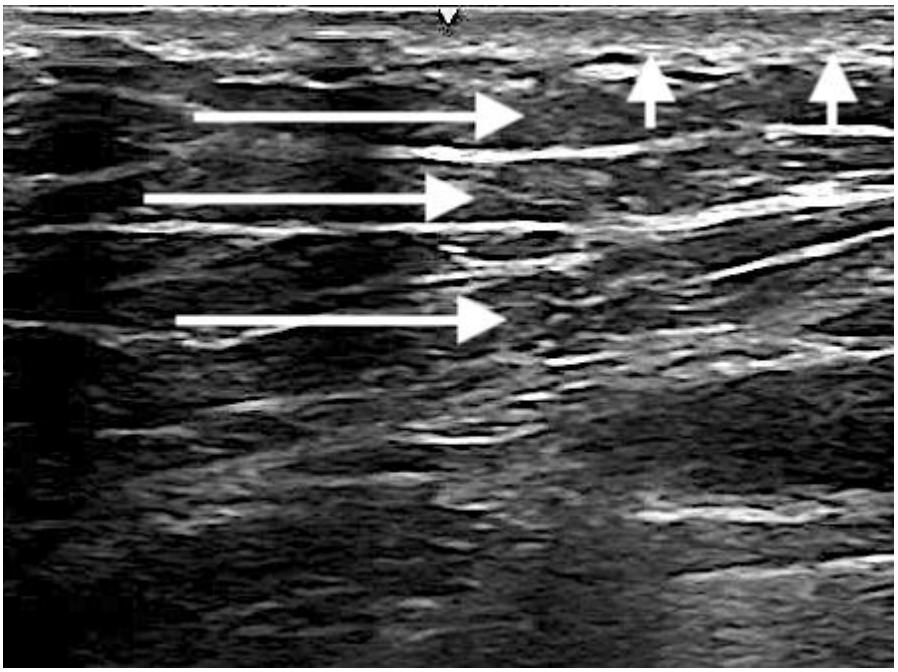

Ultrasound of the superficial abdomen demonstrating dense, hyperechoic epidermis (short arrows) and relatively hypoechoic subcutaneous fat (long arrows).

Image courtesy of Zahra M. Ghazi-Askar, MD; Vinson Vong, MD; and R. Conner Dixon, MD.

Figure 3. Ultrasound of Muscle Tissue

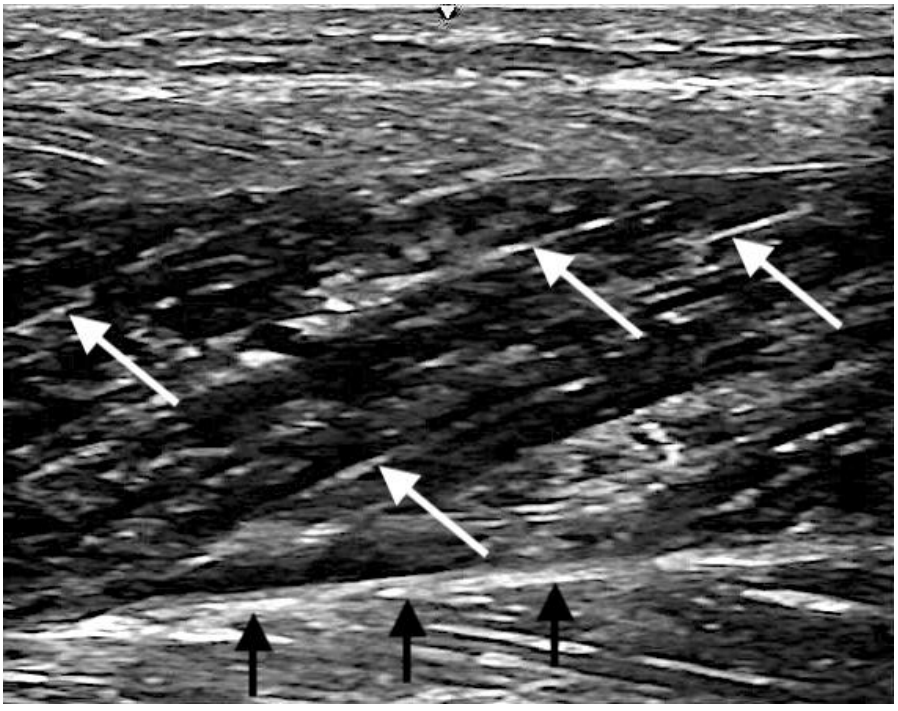

Long-axis view of forearm muscles with hypoechoic fascicles (white arrows) and hyperechoic perimysium (black arrows).

Image courtesy of Zahra M. Ghazi-Askar, MD; Vinson Vong, MD; and R. Conner Dixon, MD.

Doppler imaging and loss of tissue structure. Gas in soft tissues often produces shadowing and reverberation artifacts, which may make detection of foreign bodies challenging on ultrasound.[1,4,5]

Tendon Injuries

Tendons manifest with an organized, fibrillar orientation on long-axis views on sonography. Dynamic US imaging readily identifies an injured tendon as an area of hypoechoic defect within the organized structure of the tendon. In the case of a ruptured tendon, the torn end of the tendon may be retracted proximal to the site of insertion.[6] (*See Figure 16 in the appendix.*) As an adjunct to a physical examination, POCUS serves as a useful tool for patients presenting to the ED with musculoskeletal complaints.[1]

Lymphadenitis

The sonographic appearances of normal lymph nodes differ from those of abnormal nodes. Sonographic features that help to identify abnormal nodes include shape (round), absent hilus, intranodal necrosis, reticulation, calcification, matting, soft-tissue edema, and peripheral vascularity (rather than the central vascularity of a normal node).

Inflamed lymph nodes in reactive lymphadenopathy, while larger in size, maintain their shape and architecture. The length of the lymph node does not exceed 1 cm. As the inflammatory reaction progresses or infection sets in, the structural integrity of the lymph node is lost, the hilum becomes more hypoechoic, and the vascularity and hyperemia is seen throughout the structure.[1] (*See Figures 17 and 18 in the appendix.*)

Conclusion

The superficial location and ease of access to the structures of the musculoskeletal system, in combination with the quick, focused, portable, real-time, and dynamic quality of US exams, makes POCUS a practical tool for providing limited, focused studies to answer specific questions in the busy ED setting. Learning to identify pathology in musculoskeletal

structures is simple when the comparison to the contralateral normal side is available on patients. Caution must be exercised to understand the limitations of musculoskeletal US and set realistic expectations to keep diagnostic errors to a minimum.

References

1. Connell MJ, Wu TS. Bedside musculoskeletal ultrasonography. *Crit Care Clin* 2014;30:243-273.
2. Gottlieb M, Avila J, Chottiner M, Peksa GD. Point-of-care ultrasonography for the diagnosis of skin and soft tissue abscesses: A systematic review and meta-analysis. *Ann Emerg Med* 2020;76:67-77.
3. Marin JR, Dean AJ, Bilker WB, et al. Emergency ultrasound-assisted examination of skin and soft tissue infections in the pediatric emergency department. *Acad Emerg Med* 2013;20:545-553.
4. Mohammadi A, Ghasemi-Rad M, Khodabakhsh M. Non-opaque soft tissue foreign body sonographic findings. *BMC Med Imaging* 2011;11:9.
5. Varshney T, Kwan C, Fischer JW, Abo A. Emergency point-of-care ultrasound diagnosis of retained soft tissue foreign bodies in the pediatric emergency department. *Pediatr Emerg Care* 2017;33:434-436.
6. Simard R. Ultrasound imaging of orthopedic injuries. *Emerg Med Clin North Am* 2020;38:243-265.
7. Friedman N, Tseng F, Savic R, et al. Reliability of neck mass point-of-care ultrasound by pediatric emergency physicians. *J Ultrasound Med* 2019;38:2893-2900.

CME/CE QUESTIONS

1. The echogenicity of subcutaneous fat on ultrasound (US) is:
   a. anechoic.
   b. hypoechoic.
   c. hyperechoic.
   d. dependent on the angle of insonation.
2. A high-frequency transducer is used most frequently in musculoskeletal US.
   a. True
   b. False
3. Which of these structures manifest a honeycombing appearance on US?
   a. Muscles
   b. Lymph nodes
   c. Nerves
   d. Tendons

Figure 4. Ultrasound of an Achilles Tendon

Long-axis view of Achilles tendon (arrows).

Image courtesy of Zahra M. Ghazi-Askar, MD; Vinson Vong, MD; and R. Conner Dixon, MD.

Figure 5. Ultrasound of Patellar Tissues

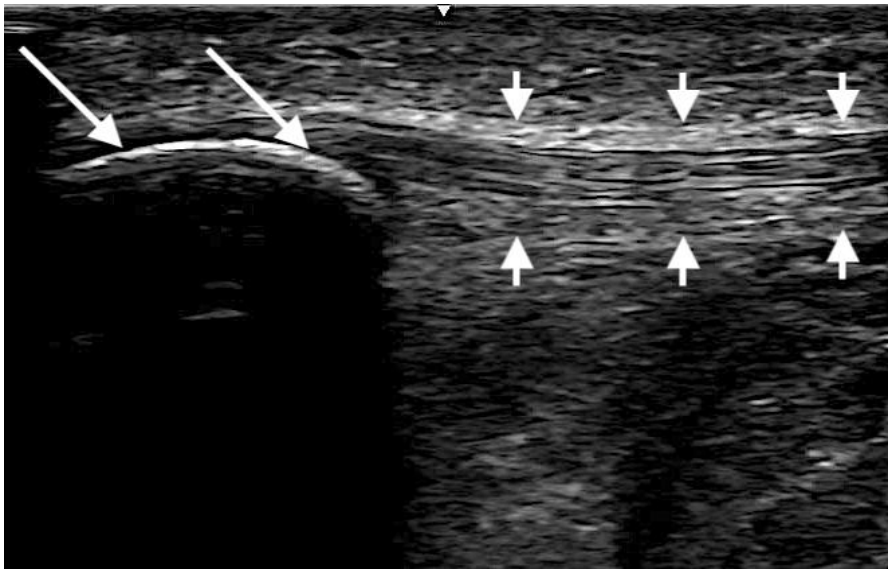

Longitudinal gray-scale image of part of the patellar "tendon."

Image courtesy of Zahra M. Ghazi-Askar, MD; Vinson Vong, MD; and R. Conner Dixon, MD.

Figure 6. Ultrasound of Median Nerve

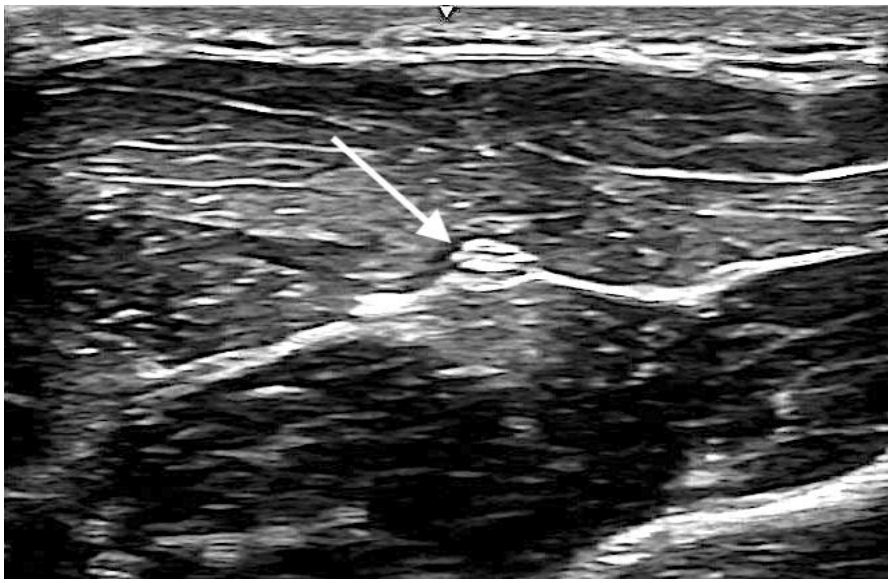

A short-axis view of the median nerve (arrow).

Image courtesy of Zahra M. Ghazi-Askar, MD; Vinson Vong, MD; and R. Conner Dixon, MD.

Figure 7. Ultrasound of Patellar Ligament

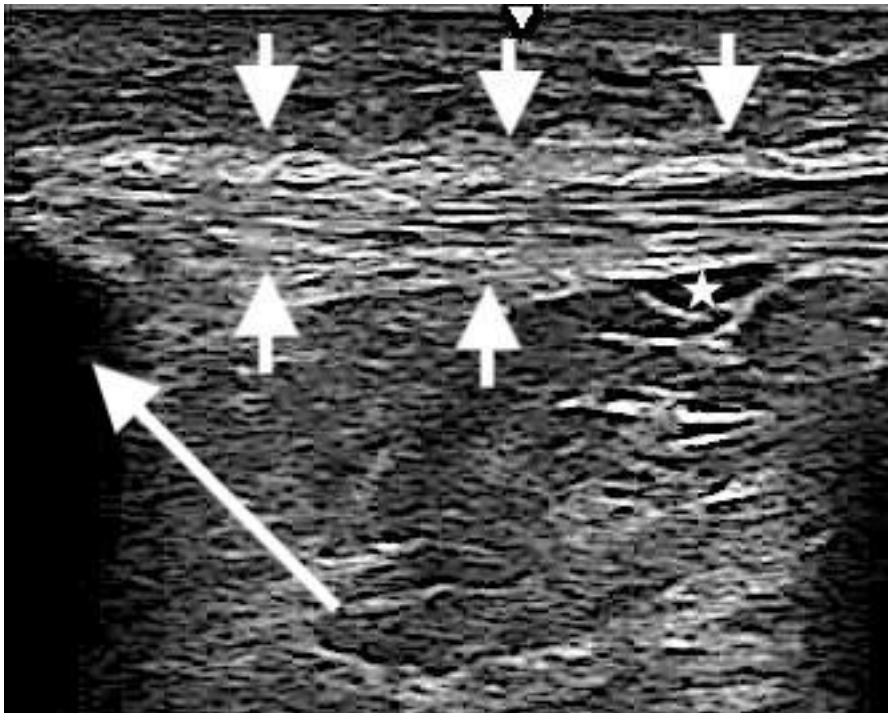

A long-axis view of patellar ligament (short arrows), the patella (long arrow), and the deep infrapatellar bursa (star).

Image courtesy of Zahra M. Ghazi-Askar, MD; Vinson Vong, MD; and R. Conner Dixon, MD.

4. On a grayscale image, the color appearance of an anechoic structure is white.
   a. True
   b. False
5. What is the artifact of anisotropy?
   a. It is an artifact associated with abscess formation.
   b. It is a part of normal artifacts seen in a lymph node US.
   c. It is an artifact related to the angle of insonation seen in tendon US.
6. The appearance of a normal lymph node on US is oval-shaped.
   a. True
   b. False
7. The width of a normal lymph node on US is 2.5 cm.
   a. True
   b. False
8. What is the vascular pattern seen in a normal-appearing lymph node on US?
   a. Central vascularity
   b. Peripheral vascularity
   c. Both central and peripheral
9. What is the echogenicity of foreign bodies on US?
   a. Hyperechoic
   b. Hypoechoic
   c. Anechoic
10. What does the term cobblestoning refer to when seen on US, with respect to musculoskeletal US?
    a. Cobblestoning is a characteristic finding in normal tissue US.
    b. Cobblestoning is a characteristic finding in cellulitis on US.
    c. Cobblestoning is a characteristic finding in tendon tear on US.

Figure 8. Ultrasound of a Lymph Node

The echogenic hilum characteristic of a normal lymph node (arrow). These are enlarged lymph nodes that have kept their oval structue, and have an echogenic hilum.

Image courtesy of Zahra M. Ghazi-Askar, MD.

Figure 9. Ultrasound of a Cervical Lymph Node

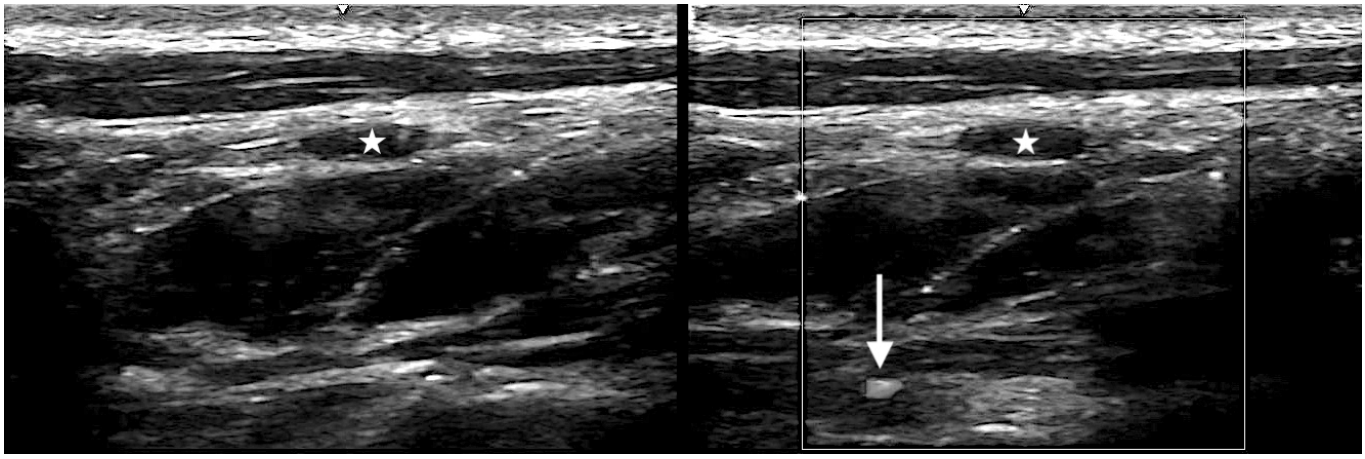

A cervical lymph node (star) and blood vessel (arrow).

Image courtesy of Zahra M. Ghazi-Askar, MD; Vinson Vong, MD; and R. Conner Dixon, MD.

Figure 10. Ultrasound of Cellulitis

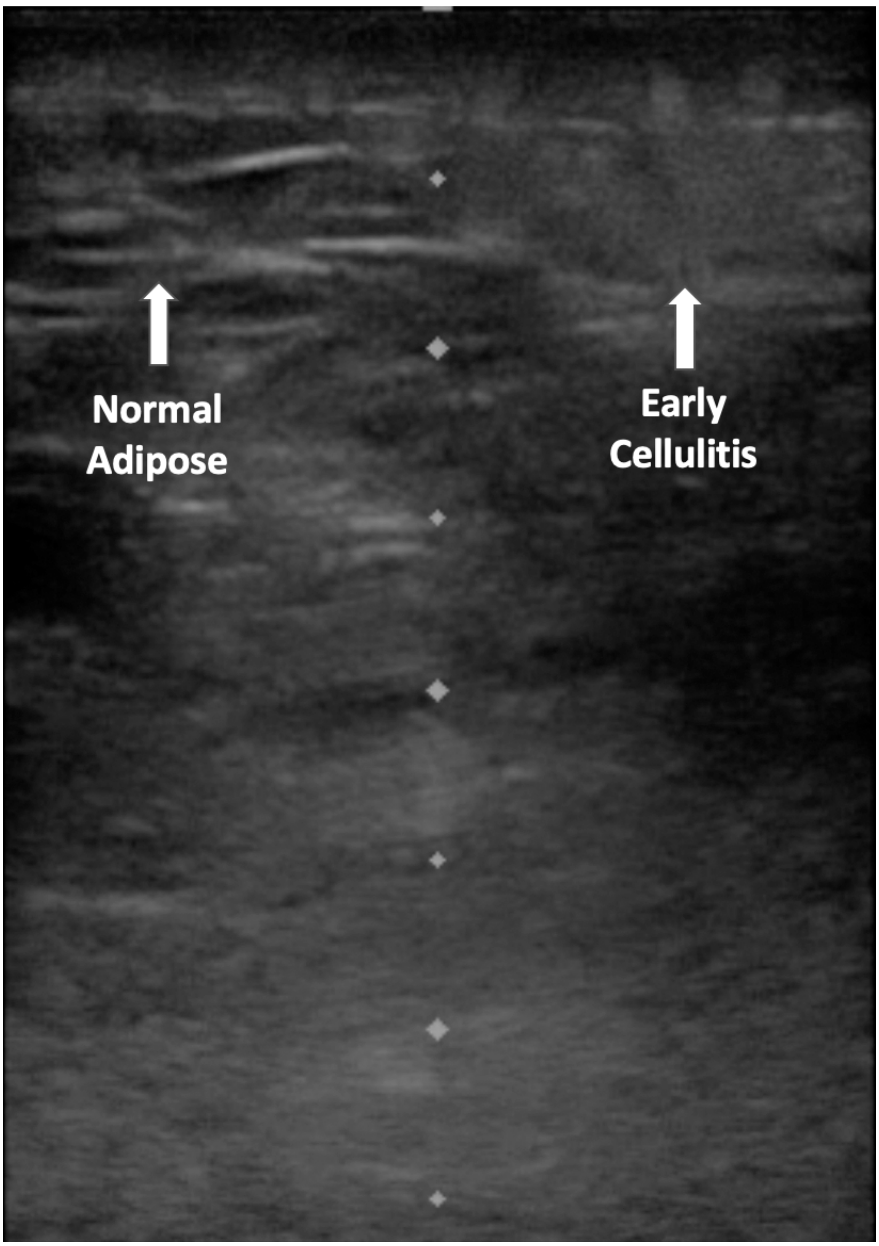

There is diffuse increase in echogenicity of the subcutaneous adipose tissue. The fat lobules are no longer distinct.

Image courtesy of Zahra M. Ghazi-Askar, MD; Vinson Vong, MD; and R. Conner Dixon, MD.

Figure 11. Cobblestoning on Ultrasound

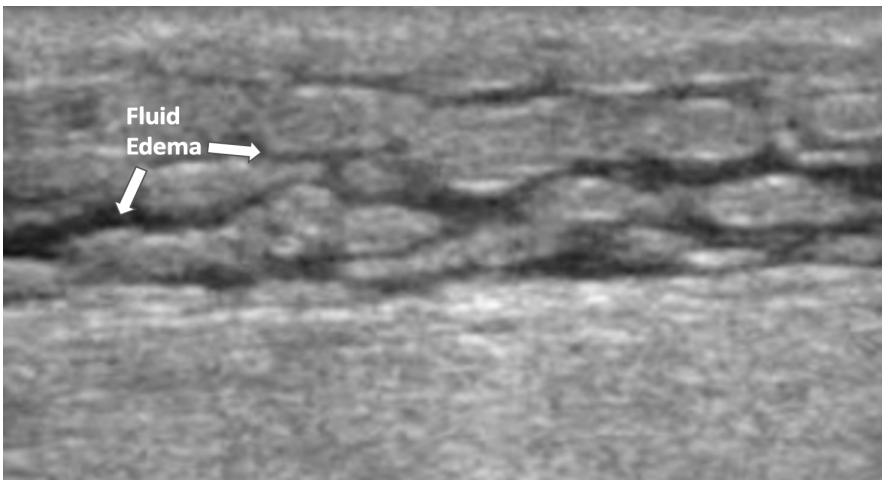

Grayscale image demonstrating superficial cellulitis with inflammatory edema separating layers of the subcutaneous tissue (cobblestoning).

Image courtesy of Zahra M. Ghazi-Askar, MD; Vinson Vong, MD; and R. Conner Dixon, MD.

Figure 12. Severe Cellulitis on Ultrasound

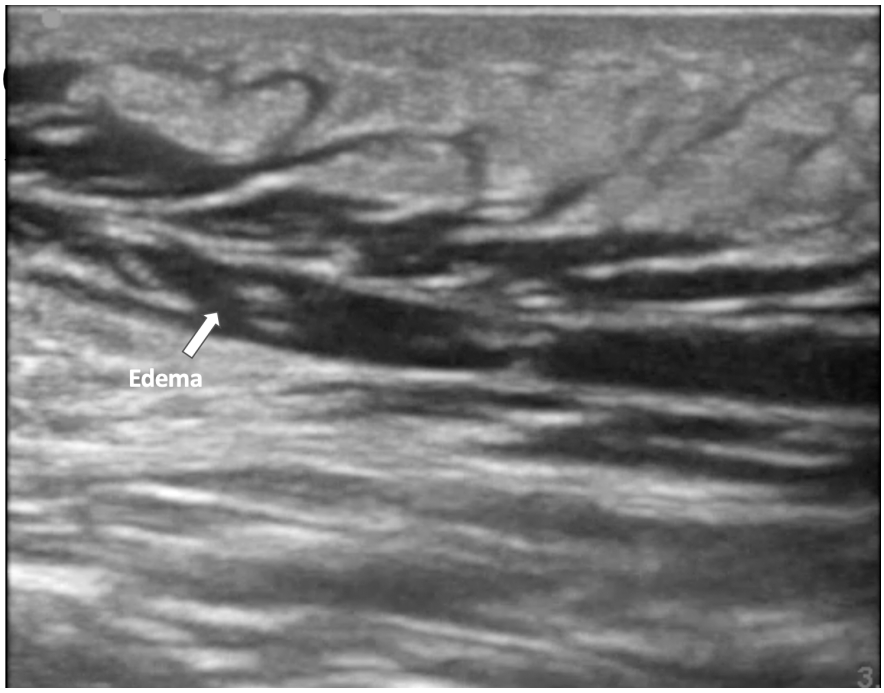

Extensive cellulitis with a cobblestone appearance over the healthy underlying muscle tissue.

Image courtesy of Zahra M. Ghazi-Askar, MD; Vinson Vong, MD; and R. Conner Dixon, MD.

Figure 13. Abscess with Debris

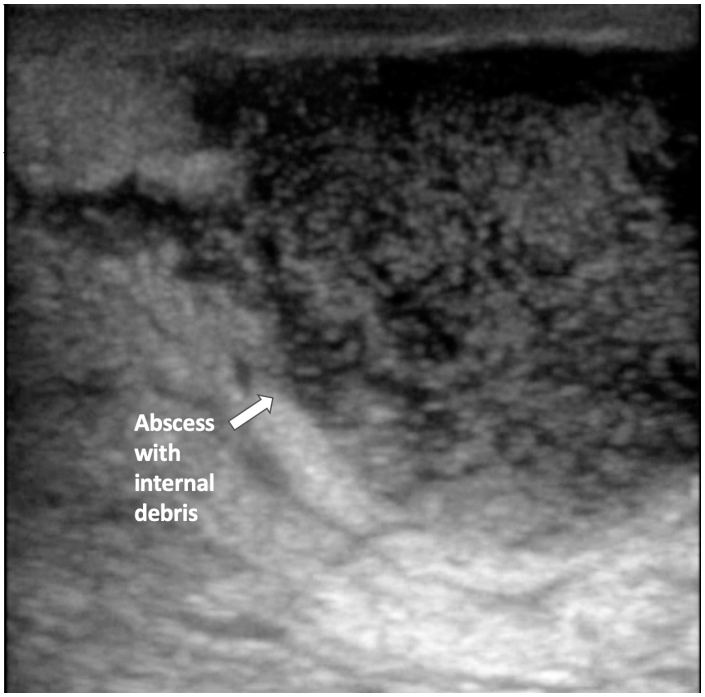

Moderately circumscribed abscess demonstrated by a collection of hypoechoic fluid with internal debris and air scattering.

Image courtesy of Zahra M. Ghazi-Askar, MD; Vinson Vong, MD; and R. Conner Dixon, MD.

Figure 14. Abscess in Subcutaneous Fat

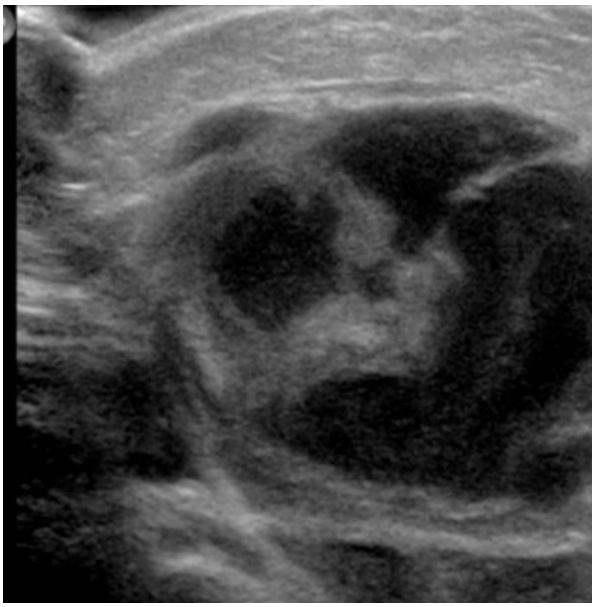

An abscess seen as a hypoechoic lesion with scattered debris.

Image courtesy of Zahra M. Ghazi-Askar, MD; Vinson Vong, MD; and R. Conner Dixon, MD.

Figure 15. Ultrasound of a Foreign Body

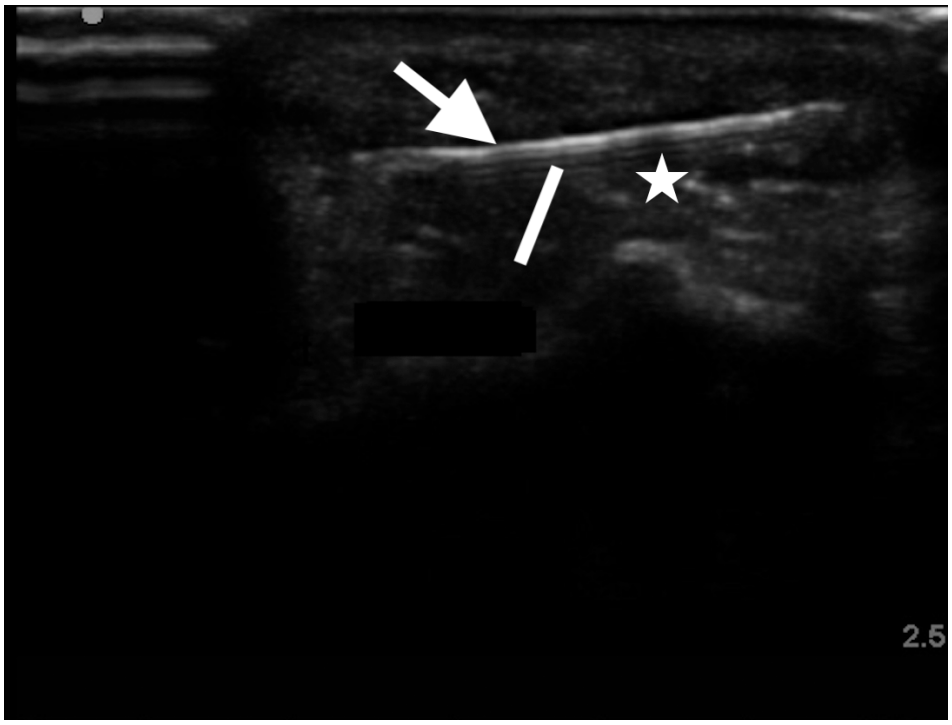

The hyperechoic appearance of a wooden tooth pick (arrow). Note the reverberation (line) and the posterior shadow (star).

Image courtesy of Zahra M. Ghazi-Askar, MD.

Figure 16. Ultrasound of an Achilles Tendon Rupture

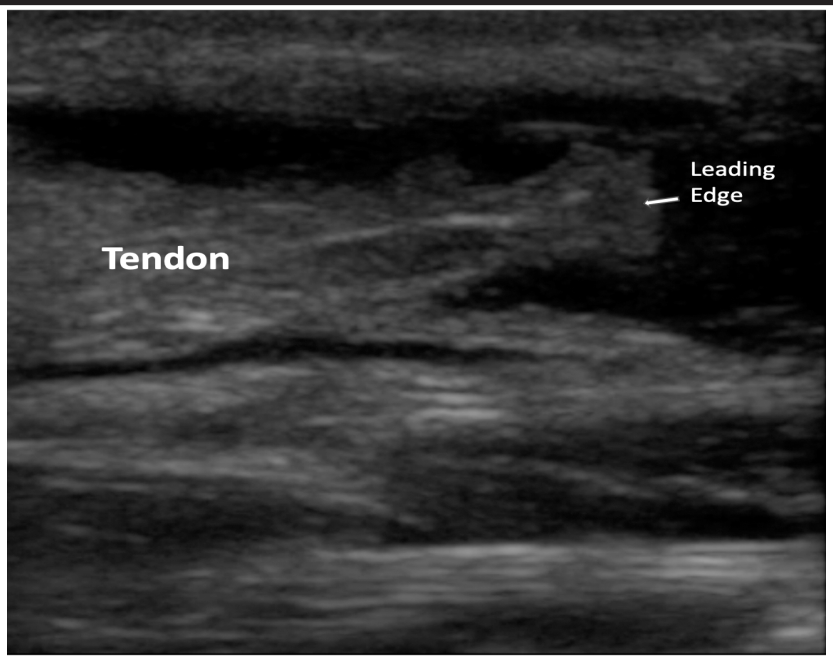

Long-axis image of an Achilles tendon rupture . The torn tendon is retracted, denoted by a wavy appearance.

Image courtesy of Zahra M. Ghazi-Askar, MD; Vinson Vong, MD; and R. Conner Dixon, MD.

Figure 17. Lymph Node on Ultrasound

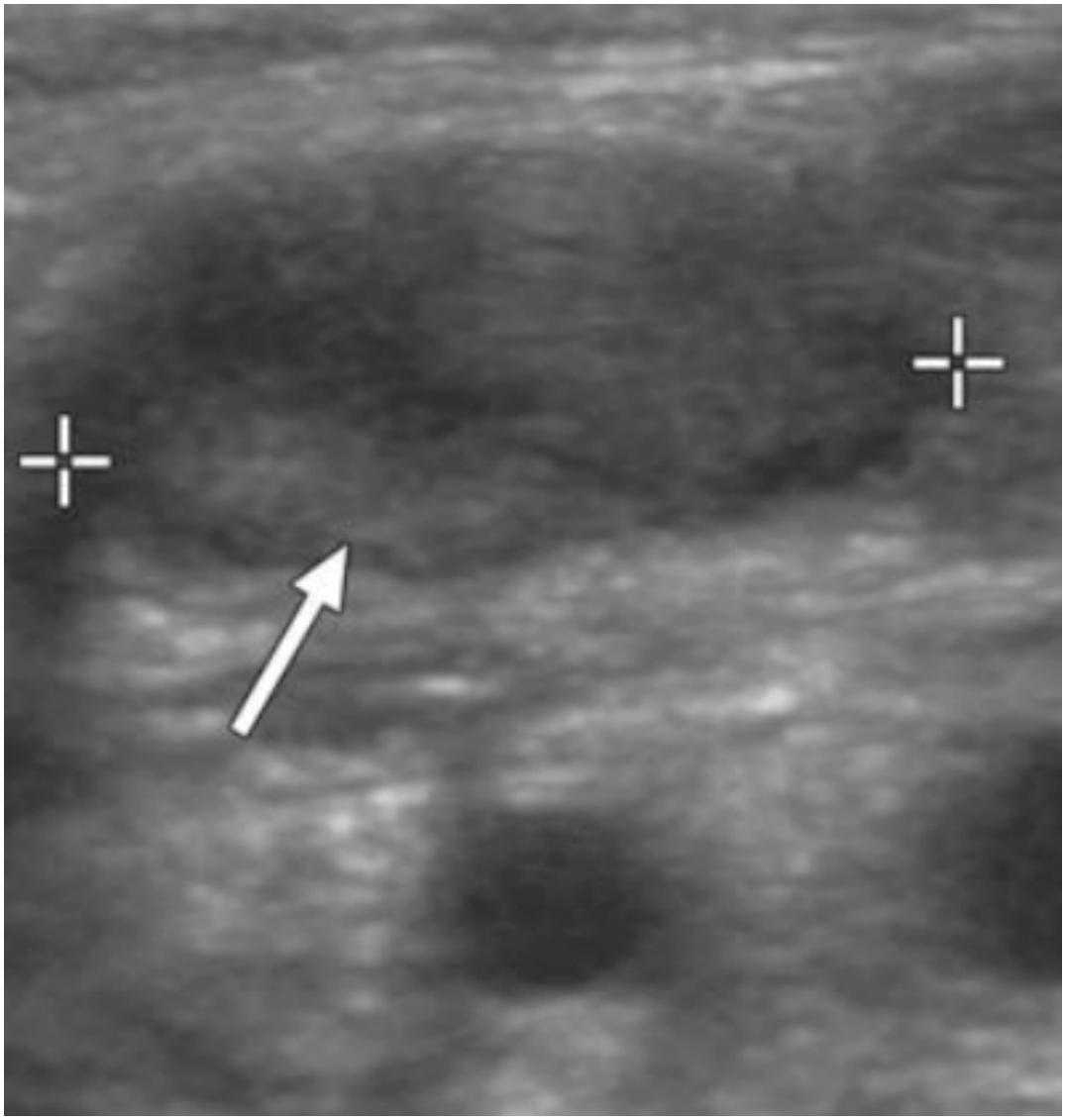

Grayscale ultrasound showing increased cortical echogenicity (arrow) and a lack of echogenic hilum consistent with a reactive lymph node.

Image courtesy of Zahra M. Ghazi-Askar, MD; Vinson Vong, MD; and R. Conner Dixon, MD.

Figure 18. Infected Lymph Node

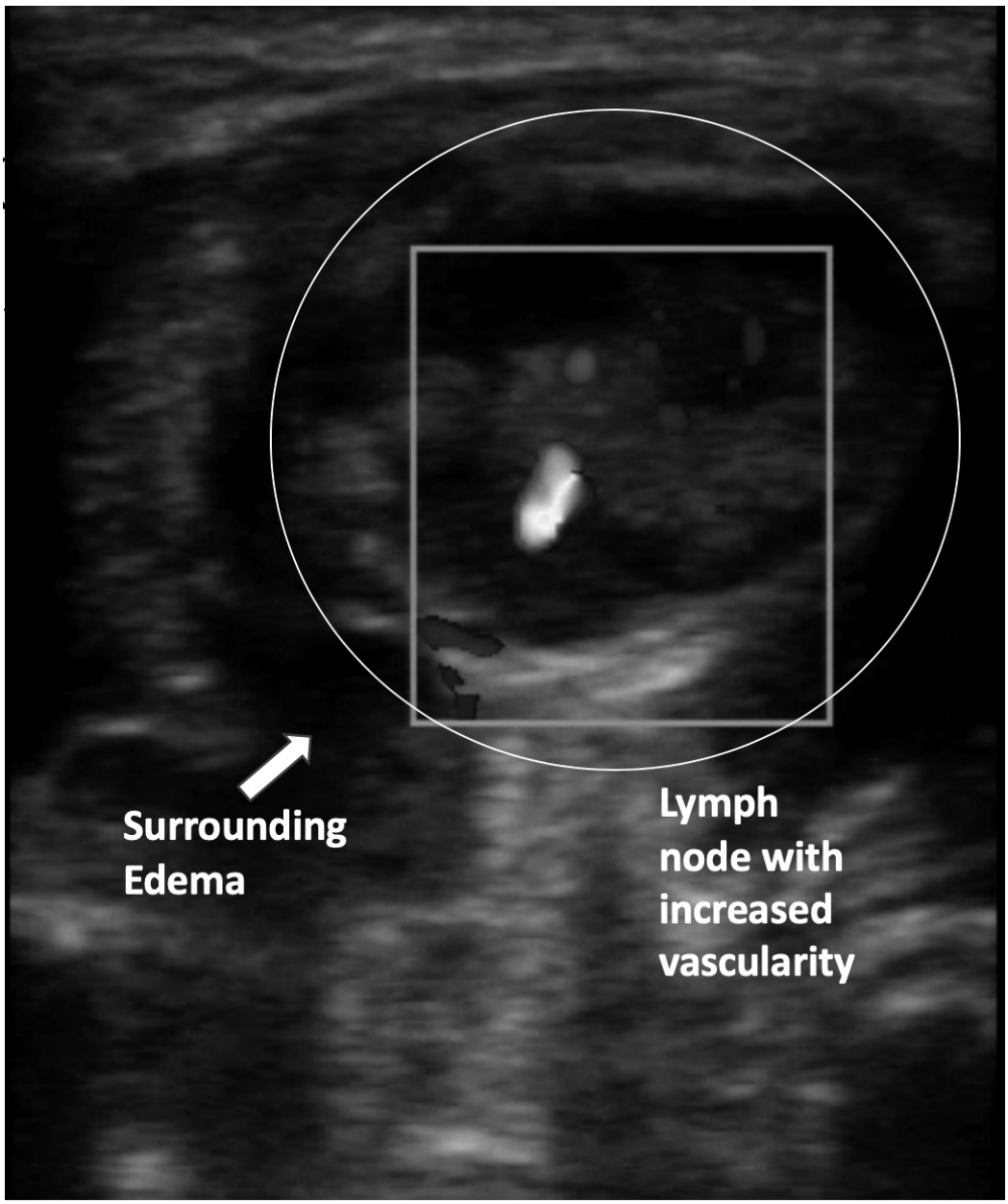

Grayscale and color-flow ultrasound images of an infected lymph node with a developing central abscess. The shape is no longer maintained. The size is increased and the hilum appears hypoechoic. Color version available at https://bit.ly/36ftMKP.

Image courtesy of Zahra M. Ghazi-Askar, MD; Vinson Vong, MD; and R. Conner Dixon, MD.

Check out this webinar series: The State of the Art in Case Management - 2020 and Beyond: Bootcamp Ep. 1 (Series)

Credits: 4 Credit Hours CME/CE

Duration: 4 hours (60 min. each)

Visit us online at ReliasMedia.com/Webinars or call us at (800) 688-2421.

RELIAS MEDIA

DocuSign Envelope ID: 8CF39966-87F5-4E06-9704-2D11EAEDCE5C

Statement of Ownership, Management, and Circulation (All Periodicals Publications Except Requester Publications)

UNITED STATES POSTAL SERVICE®

1. Publication Title	2. Publication Number	3. Filing Date
Pediatric Emergency Medicine Reports	1 0 8 2 – 3 3 4 4	10/1/2020
4. Issue Frequency	5. Number of Issues Published Annually	6. Annual Subscription Price
Monthly	12	$299

7. Complete Mailing Address of Known Office of Publication *(Not printer) (Street, city, county, state, and ZIP+4®)*

1010 Sync St., Ste.100, Morrisville, NC 27560-5468.

Contact Person: Sabrina Johnson

(919) 459-9495

8. Complete Mailing Address of Headquarters or General Business Office of Publisher *(Not printer)*

1010 Sync St., Ste.100, Morrisville, NC 27560-5468.

9. Full Names and Complete Mailing Addresses of Publisher, Editor, and Managing Editor *(Do not leave blank)*

Publisher *(Name and complete mailing address)*

Relias LLC, 1010 Sync St., Ste.100, Morrisville, NC 27560-5468.

Editor *(Name and complete mailing address)*

Mike Gates

Managing Editor *(Name and complete mailing address)*

Leslie Coplin

10. Owner *(Do not leave blank. If the publication is owned by a corporation, give the name and address of the corporation immediately followed by the names and addresses of all stockholders owning or holding 1 percent or more of the total amount of stock. If not owned by a corporation, give the names and addresses of the individual owners. If owned by a partnership or other unincorporated firm, give its name and address as well as those of each individual owner. If the publication is published by a nonprofit organization, give its name and address.)*

Full Name	Complete Mailing Address
Relias LLC	1010 Sync St., Ste.100, Morrisville, NC 27560-5468.
Bertelsmann Learning LLC	1745 Broadway, New York, NY 10019

11. Known Bondholders, Mortgagees, and Other Security Holders Owning or Holding 1 Percent or More of Total Amount of Bonds, Mortgages, or Other Securities. If none, check box → ☑ None

Full Name	Complete Mailing Address

12. Tax Status *(For completion by nonprofit organizations authorized to mail at nonprofit rates) (Check one)*

The purpose, function, and nonprofit status of this organization and the exempt status for federal income tax purposes:

☑ Has Not Changed During Preceding 12 Months

☐ Has Changed During Preceding 12 Months *(Publisher must submit explanation of change with this statement)*

PS Form **3526**, July 2014 *(Page 1 of 4 (see instructions page 4))* PSN: 7530-01-000-9931 **PRIVACY NOTICE:** See our privacy policy on *www.usps.com*.

The Latest and Greatest Is Here!

Featuring article texts and useful study tools, **Emergency Medicine Reports' LLSA Exam Study Guide 2021** also comes with the chance to earn CME while you study.

WHAT'S INSIDE

- ☑ Digital study guide
- ☑ Key study points for each article
- ☑ 38 CME credits
- ☑ Earn CME while you study

ReliasMedia.com

DocuSign Envelope ID: 8CF39966-87F5-4E06-9704-2D11EAEDCE5C

13. Publication Title	14. Issue Date for Circulation Data Below
Pediatric Emergency Medicine Reports	September 2020

15. Extent and Nature of Circulation			Average No. Copies Each Issue During Preceding 12 Months	No. Copies of Single Issue Published Nearest to Filing Date
a. Total Number of Copies *(Net press run)*			296	264
b. Paid Circulation *(By Mail and Outside the Mail)*	(1)	Mailed Outside-County Paid Subscriptions Stated on PS Form 3541 (Include paid distribution above nominal rate, advertiser's proof copies, and exchange copies)	240	214
	(2)	Mailed In-County Paid Subscriptions Stated on PS Form 3541 *(Include paid distribution above nominal rate, advertiser's proof copies, and exchange copies)*	0	0
	(3)	Paid Distribution Outside the Mails Including Sales Through Dealers and Carriers, Street Vendors, Counter Sales, and Other Paid Distribution Outside USPS®	6	5
	(4)	Paid Distribution by Other Classes of Mail Through the USPS (e.g., First-Class Mail®)	13	14
c. Total Paid Distribution *[Sum of 15b (1), (2), (3), and (4)]*			259	233
d. Free or Nominal Rate Distribution *(By Mail and Outside the Mail)*	(1)	Free or Nominal Rate Outside-County Copies Included on PS Form 3541	4	1
	(2)	Free or Nominal Rate In-County Copies Included on PS Form 3541	0	0
	(3)	Free or Nominal Rate Copies Mailed at Other Classes Through the USPS (e.g., First-Class Mail)	0	0
	(4)	Free or Nominal Rate Distribution Outside the Mail *(Carriers or other means)*	2	2
e. Total Free or Nominal Rate Distribution *(Sum of 15d (1), (2), (3) and (4))*			6	3
f. Total Distribution *(Sum of 15c and 15e)*			265	236
g. Copies not Distributed *(See Instructions to Publishers #4 (page #3))*			31	28
h. Total *(Sum of 15f and g)*			296	264
i. Percent Paid *(15c divided by 15f times 100)*			98%	99%

* If you are claiming electronic copies, go to line 16 on page 3. If you are not claiming electronic copies, skip to line 17 on page 3.

DocuSign Envelope ID: 8CF39966-87F5-4E06-9704-2D11EAEDCE5C

UNITED STATES POSTAL SERVICE®

Statement of Ownership, Management, and Circulation (All Periodicals Publications Except Requester Publications)

16. Electronic Copy Circulation	Average No. Copies Each Issue During Preceding 12 Months	No. Copies of Single Issue Published Nearest to Filing Date
a. Paid Electronic Copies		
b. Total Paid Print Copies (Line 15c) + Paid Electronic Copies (Line 16a)		
c. Total Print Distribution (Line 15f) + Paid Electronic Copies (Line 16a)		
d. Percent Paid (Both Print & Electronic Copies) (16b divided by 16c ⌀ 100)		

☐ **I certify that 50% of all my distributed copies (electronic and print) are paid above a nominal price.**

17. Publication of Statement of Ownership

☑ If the publication is a general publication, publication of this statement is required. Will be printed in the November issue of this publication. ☐ Publication not required.

18. Signature and Title of Editor, Publisher, Business Manager, or Owner	Date
DocuSigned by: Philipp Rusch 40074DA3CF6246E... Chief Financial Officer	23-Sep-2020

I certify that all information furnished on this form is true and complete. I understand that anyone who furnishes false or misleading information on this form or who omits material or information requested on the form may be subject to criminal sanctions (including fines and imprisonment) and/or civil sanctions (including civil penalties).

on-demand WEBINARS

Instructor led Webinars

On-Demand

New Topics Added Weekly

CONTACT US TO LEARN MORE!

Visit us online at ReliasMedia.com/Webinars or call us at (800) 686-2421.

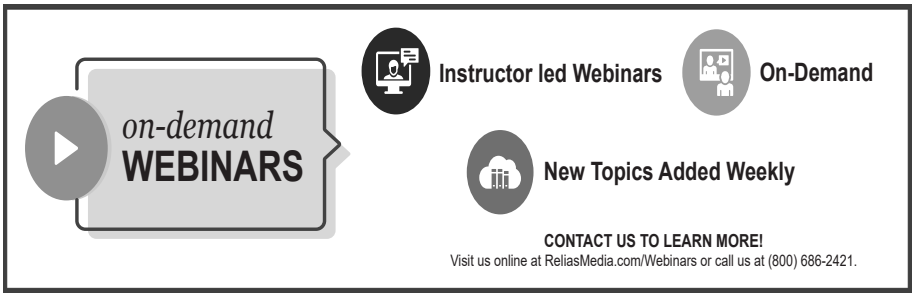

PEDIATRIC EMERGENCY MEDICINE REPORTS

CME/CE Objectives

Upon completion of this educational activity, participants should be able to:

- recognize specific conditions in pediatric patients presenting to the emergency department;
- describe the epidemiology, etiology, pathophysiology, historical, and examination findings associated with conditions in pediatric patients presenting to the emergency department;
- formulate a differential diagnosis and perform necessary diagnostic tests;
- apply up-to-date therapeutic techniques to address conditions discussed in the publication;
- discuss any discharge or follow-up instructions with patients.

Is there an article or issue you'd like posted to your website? Interested in a custom reprint? There are numerous opportunities to leverage editorial recognition to benefit your brand.

Call us at (800) 688-2421 or email reliasmedia1@gmail.com.

Discounts are available for group subscriptions, multiple copies, site licenses, or electronic distribution. For pricing information, please contact us at:

Phone: (866) 213-0844
Email: groups@reliasmedia.com

To reproduce any part of Relias Media newsletters for educational purposes, please contact The Copyright Clearance Center for permission:

Email: info@copyright.com
Website: www.copyright.com
Phone: (978) 750-8400

EDITORS

EDITOR-IN-CHIEF

Ann Dietrich, MD, FAAP, FACEP
Associate Professor of Primary Care-Lead, Ohio University Heritage College of Medicine
Associate Pediatric Medical Director, MedFlight

EDITOR EMERITUS

Larry B. Mellick, MD, MS, FAAP, FACEP
Professor of Emergency Medicine and Pediatrics
Vice Chairman for Academic Affairs
Division Chief of Pediatric Emergency Medicine
Department of Emergency Medicine
University of South Alabama

EDITORIAL BOARD

Jeffrey Bullard-Berent, MD, FAAP, FACEP
Medical Director Child Ready Virtual Pediatric Emergency Department
Professor, Emergency Medicine and Pediatrics; University of New Mexico School of Medicine

James E. Colletti, MD, FAAP, FAAEM, FACEP
Associate Residency Director
Emergency Medicine
Mayo Clinic College of Medicine
Rochester, MN

George L. Foltin, MD, FAAP, FACEP
Associate Professor of Pediatric and Emergency Medicine
New York University School of Medicine
New York, NY

Michael Gerardi, MD, FAAP, FACEP
Clinical Assistant Professor of Medicine, New Jersey Medical School
Director, Pediatric Emergency Services, Goryeb Children's Hospital, Morristown Memorial Hospital
Morristown, NJ

Christopher J. Haines, DO, FAAP, FACEP
Chief Medical Officer
Children's Specialized Hospital
New Brunswick, NJ
Associate Professor of Pediatrics and Emergency Medicine
Drexel University College of Medicine
Attending Physician
St. Christopher's Hospital for Children
Philadelphia, PA

Dennis A. Hernandez, MD
Medical Director
Pediatric Emergency Services
Walt Disney Pavilion
AdventHealth for Children
Orlando, FL

Steven Krug, MD
Head, Division of Pediatric Emergency Medicine, Children's Memorial Hospital
Professor, Department of Pediatrics
Northwestern University Feinberg School of Medicine, Chicago, IL

Aaron Leetch, MD
Associate Professor of Emergency Medicine & Pediatrics; Residency Director, Combined Emergency Medicine & Pediatrics Residency
University of Arizona College of Medicine, Tucson

Jeffrey Linzer Sr., MD, FAAP, FACEP
Professor of Pediatrics and Emergency Medicine
Emory University School of Medicine
Associate Medical Director for Compliance; Emergency Pediatric Group, Children's Healthcare of Atlanta at Egleston and Hughes Spalding, Atlanta, GA

Daniel Migliaccio, MD
Clinical Assistant Professor, Ultrasound Fellowship Director, Department of Emergency Medicine, University of North Carolina, Chapel Hill

Charles Nozicka, DO, FAAP, FAAEM
Division Director
Pediatric Emergency Medicine
Advocate Children's Hospital
Park Ridge, IL
Clinical Professor
of Emergency Medicine
Rosalind Franklin University
Libertyville, IL

Alfred Sacchetti, MD, FACEP
Chief of Emergency Services
Our Lady of Lourdes Medical Center
Camden, NJ
Clinical Assistant Professor
Emergency Medicine
Thomas Jefferson University
Philadelphia, PA

John P. Santamaria, MD, FAAP, FACEP
Affiliate Professor of Pediatrics
University of South Florida School of Medicine, Tampa, FL

Robert W. Schafermeyer, MD, FACEP, FAAP, FIFEM
Associate Chair, Department of Emergency Medicine, Carolinas Medical Center, Charlotte, NC
Clinical Professor of Pediatrics and Emergency Medicine
University of North Carolina School of Medicine, Chapel Hill, NC

Ghazala Q. Sharieff, MD, MBA
Clinical Professor, University of California, San Diego
Corporate Director, Physician Outreach and Medical Management
Scripps Health, San Diego, CA

Jonathan I. Singer, MD, FAAP, FACEP
Professor of Emergency Medicine and Pediatrics, Boonshoft School of Medicine
Wright State University, Dayton, OH

Milton Tenenbein, MD, FRCPC, FAAP, FAACT
Professor of Pediatrics and Pharmacology
University of Manitoba
Director of Emergency Services
Children's Hospital
Winnipeg, Manitoba

N. Ewen Wang, MD
Professor of Emergency Medicine, Associate Director
Pediatric Emergency Medicine
Stanford School of Medicine
Stanford, CA

James A. Wilde, MD, FAAP
Professor of Emergency Medicine, Associate Professor of Pediatrics
Augusta University, Augusta, GA

Steven M. Winograd, MD, FACEP
Mt. Sinai Queens Hospital Center, Jamaica Queens, NY; Assistant Clinical Professor of Emergency Medicine, Mt. Sinai Medical School, New York City; Assistant Clinical Professor of Emergency Medicine, NYiTCOM, Old Westbury, NY

NURSE REVIEWER

Laura Bauer, RN, BSN, CPEN
Pediatric Emergency Dept RN
Banner University Medical Center
Tucson, AZ

© 2020 Relias LLC. All rights reserved.

PEDIATRIC EMERGENCY MEDICINE REPORTS™ (ISSN 1082-3344) is published monthly by Relias LLC, 1010 Sync St., Ste. 100, Morrisville, NC 27560-5468. Periodicals postage paid at Morrisville, NC, and additional mailing offices. POSTMASTER: Send address changes to ***Pediatric Emergency Medicine Reports***, Relias LLC, 1010 Sync St., Ste. 100, Morrisville, NC 27560-5468.

Associate Editor: Mike Gates

Executive Editor: Shelly Mark

Editorial Group Manager: Leslie Coplin

Accreditations Director: Amy M. Johnson, MSN, RN, CPN

© 2020 Relias LLC. All rights reserved. Reproduction, distribution, or translation without express written permission is strictly prohibited.

This is an educational publication designed to present scientific information and opinion to health professionals, to stimulate thought, and further investigation. It does not provide advice regarding medical diagnosis or treatment for any individual case. It is not intended for use by the layman. Opinions expressed are not necessarily those of this publication. Mention of products or services does not constitute endorsement. Clinical, legal, tax, and other comments are offered for general guidance only; professional counsel should be sought for specific situations.

SUBSCRIBER INFORMATION

CUSTOMER SERVICE: (800) 688-2421

Customer Service Email Address:
customerservice@reliasmedia.com

Editorial Email Address:
mgates@relias.com

Website:
ReliasMedia.com

MULTIPLE COPIES:

Discounts are available for group subscriptions, multiple copies, site licenses, or electronic distribution. For pricing information, please contact our Group Account Managers at groups@reliasmedia.com or (866) 213-0844.

All prices U.S. only. U.S. possessions and Canada, add $30 plus applicable GST. Other international orders, add $30.

GST Registration No.: R128870672

Back issues: $65. Missing issues will be fulfilled by customer service free of charge when contacted within one month of the missing issue's date.

ACCREDITATION

JOINTLY ACCREDITED PROVIDER™
INTERPROFESSIONAL CONTINUING EDUCATION

In support of improving patient care, Relias LLC is jointly accredited by the Accreditation Council for Continuing Medical Education (ACCME), the Accreditation Council for Pharmacy Education (ACPE), and the American Nurses Credentialing Center (ANCC), to provide continuing education for the healthcare team.

The Relias LLC designates this enduring material for a maximum of 3 *AMA PRA Category 1 Credits*™. Physicians should claim only the credit commensurate with the extent of their participation in the activity.

Approved by the American College of Emergency Physicians for a maximum of 3 hours of ACEP Category I credit.

This continuing medical education activity has been reviewed by the American Academy of Pediatrics and is acceptable for a maximum of 3 AAP credits. These credits can be applied toward the AAP CME/CPD Award available to Fellows and Candidate Members of the American Academy of Pediatrics.

The American Osteopathic Association has approved this continuing education activity for up to 2.5 AOA Category 2-B credits.

3 ANCC contact hours will be awarded to participants who meet the criteria for successful completion. California Board of Registered Nursing, Provider CEP#13791.

This CME activity is intended for emergency and pediatric physicians and nurses. It is in effect for 36 months from the date of the publication.

PEDIATRIC EMERGENCY MEDICINE **REPORTS**

Practical, Evidence-Based Reviews in Pediatric Emergency Care

Pediatric Musculoskeletal Point-of-Care Ultrasound Part 1: Everything but the Bones

Ultrasound of Cellulitis

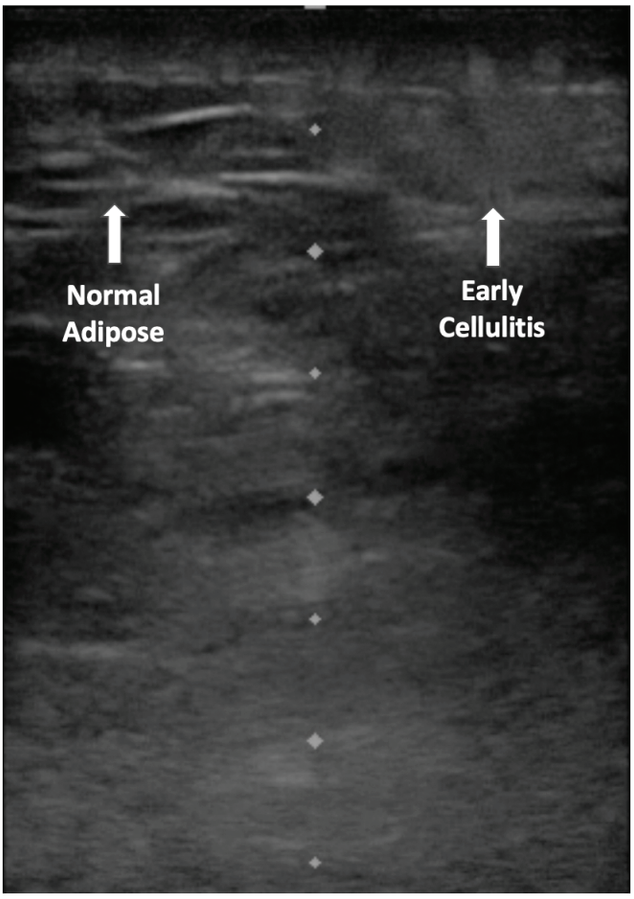

Grayscale image in a patient with early cellulitis at the transition between normal tissue (left) and inflamed tissue (right). Note the loss of distinct fat lobules and the uniform hyperechoic appearance of subcutaneous adipose tissue.

Image courtesy of Zahra M. Ghazi-Askar, MD; Vinson Vong, MD; and R. Conner Dixon, MD.

Abscess with Debris

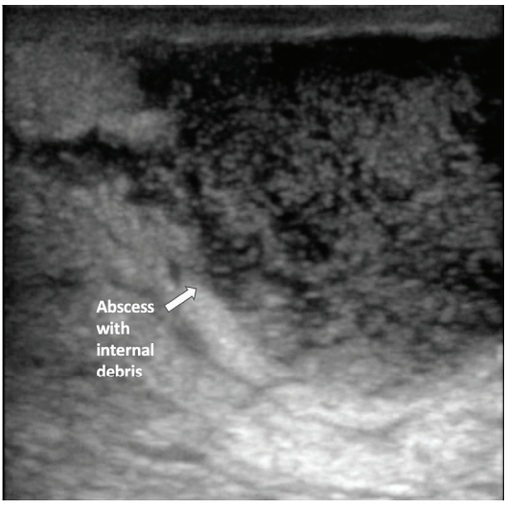

Moderately circumscribed abscess demonstrated by a collection of hypoechoic fluid with internal debris and air scattering.

Image courtesy of Zahra M. Ghazi-Askar, MD; Vinson Vong, MD; and R. Conner Dixon, MD.

Echogenicity in Ultrasound Images

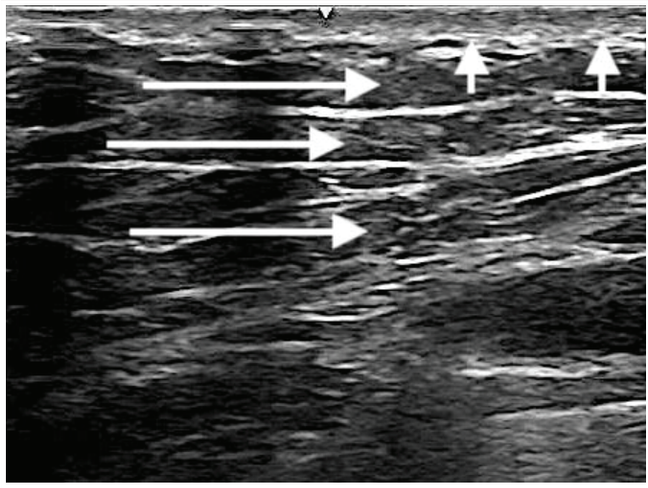

Ultrasound of the superficial abdomen demonstrating dense, hyperechoic epidermis (short arrows) and relatively hypoechoic subcutaneous fat (long arrows).

Image courtesy of Zahra M. Ghazi-Askar, MD; Vinson Vong, MD; and R. Conner Dixon, MD.

Ultrasound of a Foreign Body

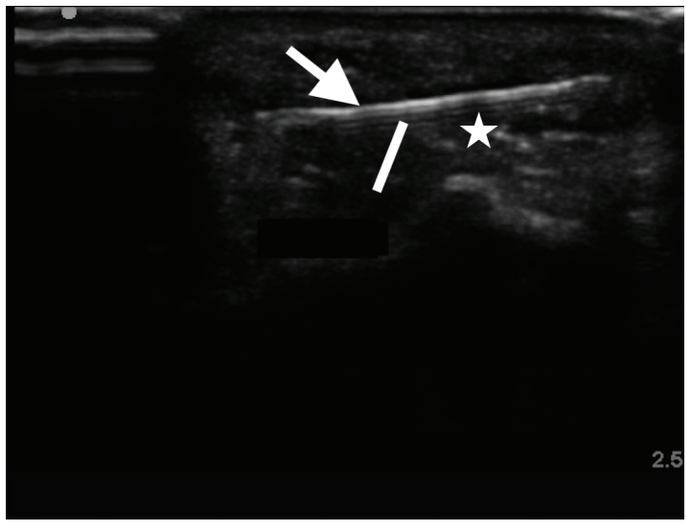

The hyperechoic appearance of a wooden tooth pick (arrow). Note the reverberation (line) and the posterior shadow (star).

Image courtesy of Zahra M. Ghazi-Askar, MD.

Insonation of an Achilles Tendon Ultrasound

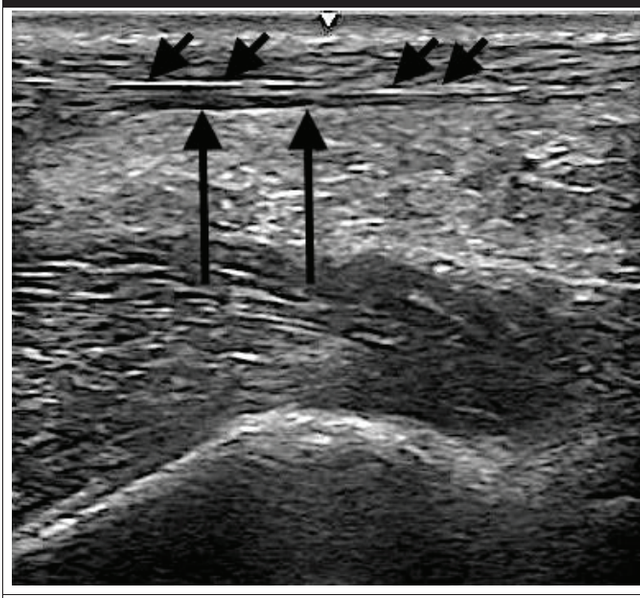

Long-axis view of a normal Achilles tendon comprised of fibrous connective tissue. Note how the tendon can appear both hyperechoic when the angle of insonation is at 90 degrees, or perpendicular, to the US probe (short arrows) and anechoic when the angle is different than 90 degrees (long arrows) because of anisotropy artifacts.

Image courtesy of Zahra M. Ghazi-Askar, MD; Vinson Vong, MD; and R. Conner Dixon, MD.

Supplement to *Pediatric Emergency Medicine Reports*, November 2020: "Pediatric Musculoskeletal Point-of-Care Ultrasound: Everything but the Bones." Authors: Zahra M. Ghazi-Askar, MD, Clinical Assistant Professor; Director, Pediatric Ultrasound Education; Department of Emergency Medicine, Stanford School of Medicine, Stanford, CA, R. Conner Dixon, MD, Chief Resident Physician, Department of Emergency Medicine, Stanford School of Medicine, Stanford, CA, and N. Ewen Wang, MD, Professor of Emergency Medicine, Stanford School of Medicine, Stanford, CA. *Pediatric Emergency Medicine Reports*' "Rapid Access Guidelines." © 2020 Relias LLC. Editor-in-Chief: Ann Dietrich, MD, FAAP, FACEP. Editorial Group Manager: Leslie Coplin. Associate Editor: Mike Gates. For customer service, call: 1-800-688-2421. This is an educational publication designed to present scientific information and opinion to health care professionals. It does not provide advice regarding medical diagnosis or treatment for any individual case. Not intended for use by the layman.