TRAUMA REPORTS

Practical, Evidence-Based Reviews in Trauma Care

SEPT/OCT 2018 VOL. 19, NO. 5

AUTHORS

Benjamin J. Lawner, DO, MS, EMT-P, FACEP, Medical Director of Prehospital Services, Allegheny General Hospital, Pittsburgh; Clinical Associate Professor, Department of Emergency Medicine, Temple University School of Medicine, Philadelphia

Faye Pedersen, MD, Emergency Medicine Residency, Allegheny Health Network, Pittsburgh

Michael Shukis, MD, Emergency Medicine Residency, Allegheny Health Network, Pittsburgh

PEER REVIEWER

Colin Kaide, MD, Associate Professor of Emergency Medicine, The Ohio State University, Columbus

FINANCIAL DISCLOSURE

Dr. Kaide (peer reviewer) is a stockholder and chief content editor for Callibra Inc., which makes software for discharge instructions. Dr. Dietrich (editor in chief), Dr. Lawner (author), Dr. Pedersen (author), Dr. Shukis (author), Ms. Behrens (nurse planner), Ms. Mark (executive editor), Ms. Coplin (executive editor), and Ms. Hatcher (editorial group manager) report no relationships with companies related to this field of study.

RELIAS MEDIA

Trauma Mythology: Looking Beyond the ABCD and ATLS

Introduction

Trauma presents a variety of time-sensitive and clinically important challenges to the emergency physician (EP). EPs routinely are tasked with the initial resuscitation and stabilization of trauma patients. The rapid and reliable identification of a life-threatening illness is an overriding principle of evidence-based trauma care. EPs and other clinicians involved in trauma care rely on established guidelines to inform treatment decisions. Although they are intended to support a universal standard of care, guidelines sometimes may contribute to clinical dogma and inadvertently discourage critical analysis of new and emerging literature. Indeed, there is a certain "lag time" that follows the adoption of clinical guidelines and the integration of new research. This article examines some commonly held assumptions related to the emergency care and stabilization of trauma patients. This review article will incorporate both clinical guidelines and recent emergency medicine-focused literature. It provides the practicing clinician with information needed to inform important clinical decisions about spinal immobilization, thromboelastography, direct oral anticoagulants (DOACs), and the Focused Abdominal Sonography in Trauma (FAST) exam.

Methods

The PubMed database was queried to identify articles relevant to a particular clinical question. Key word search terms were developed for each topic, and the authors independently reviewed abstracts and determined suitability for inclusion. Inclusion criteria were articles published within the past 10 years, full text articles, and English language. Case reports and brief research reports were excluded from the literature review. Articles were excluded if there was a lack of consensus on behalf of study authors. On rare occasions, select older manuscripts were highlighted to provide necessary clinical context.

Myth: CT Alone Is Insufficient for Radiographic Clearance of a Cervical Spine

Altered mental status may be a significant predictor of underlying cervical spine injury. In accordance with existing standards of care, a blunt trauma patient with an altered sensorium is presumed to have an underlying injury to the cervical spine. Although relatively uncommon, a missed cervical spine injury has the potential to result in significant morbidity and mortality. The incidence of cervical spine injury in the setting of blunt trauma is estimated to be 2-4%.[1,2]

EXECUTIVE SUMMARY

- The incidence of cervical spine injury in the setting of blunt trauma is estimated to be 2-4%. This estimate skyrockets to more than 30% when focusing on obtunded or unconscious patients.
- Late-generation computed tomography (CT) scanners perform admirably in the detection of clinically significant spinal trauma.
- The rate of missed injuries is exceedingly low, and CT scanners are nearly ubiquitous in modern trauma centers.
- Patients who fail NEXUS or a clinical decision rule should undergo CT scanning, and magnetic resonance imaging can be reserved for those with persistently abnormal motor deficits.
- Anticoagulated patients with a normal neurological exam, normal initial head CT, and adequate social support may be candidates for discharge.
- Consider thromboelastography to guide blood and blood component therapy in the setting of an anticipated massive transfusion.
- The relatively low cost and ubiquitous nature of the FAST exam make it ideally suited as an initial screening tool for patients with blunt abdominal trauma.

Further complicating the question of cervical spine clearance is the fact that many blunt trauma patients present to the emergency department (ED) with an abnormal mental status. Estimates for cervical spine injury skyrocket to more than 30% when focusing on obtunded or unconscious patients.[1,2] Accordingly, EPs and trauma clinicians have a low threshold to image and immobilize the cervical spine initially in a patient with a significant mechanism of injury. The authors of one study that evaluated routine toxicological testing found that almost 50% of trauma patients tested positive for alcohol or drugs.[3] Furthermore, more than 20% of patients with a confirmed unstable cervical spine injury were found to have intoxicants in either their blood or urine.[3]

Computed tomography (CT) has emerged as the standard of care for initial imaging, as it is relatively widespread and does not require an extended investment of clinician time. CT has evolved significantly since its inception. The first-generation CT scanners incorporated only a few slices, while current scanners have multidetector (MD) capability that permits three-dimensional reconstruction of injury patterns. However, CT scans are less reliable for the investigation of underlying ligamentous or cord injury. Ligamentous disruption and the presence of fractures often are used as surrogate markers for cord injury, and those patients generally require additional imaging and consultation to clear their spine radiographically. Considering the increased sensitivity of MDCT scanners, which patients require magnetic resonance imaging (MRI): all patients or just those with an abnormal mental status?

In 2013, Raza et al published the results of a combined meta-analysis and cohort study.[1] The authors retrospectively examined 10 studies that focused exclusively on obtunded blunt trauma patients and MDCT findings. The authors also performed MRI on 53 obtunded trauma patients who had negative cervical spine CT scans. Data pooled from 10 studies revealed a 99.7% negative predictive value for a normal CT.

The authors cited several limitations in the calculation of sensitivity values given that two of the included studies did not have any true positive results. In the cohort study of patients who underwent MRI of the cervical spine, no unstable injuries were discovered. The study authors could not specifically answer a question about whether an unstable cervical spine injury could be present in a patient with a normal MDCT. Indeed, the percentage of patients with missed injuries following MDCT was exceedingly low, and most of the injuries discovered on subsequent MRI did not result in a meaningful change in patient management. The authors concluded that radiologic clearance following a normal MDCT was a reasonable approach in the blunt trauma patient.

A prospective, multicenter observational study was published in the *Journal of Trauma and Acute Care Surgery* in 2016.[2] The authors of this study prospectively enrolled patients who failed NEXUS low-risk criteria. The trial's goal was to assess the accuracy of MDCT for the identification of clinically significant spinal trauma. Clinical significance was defined as patients who required one of the following: surgical intervention, a spinal orthotic brace, or a halo traction device. More than 10,000 adult patients were enrolled at U.S. Level I and Level II trauma centers. Most patients (49%) reported midline cervical tenderness, and a small percentage (5.6%) of the study population had a neurologic symptom that precluded clinical clearance. MDCT performed extremely well as a screening examination for significant spinal injury. For all patients, CT scanning exhibited a sensitivity of 98.5% and a specificity of 91.0%. A few important injuries were missed. MRI revealed a fracture of the anterior portion of the T9 vertebra, and another negative CT scan missed an inferior articular facet fracture. The neurosurgical service caring for these patients considered the injuries to be stable. If initial CT scans were paired with the presence of a neurological finding during the initial physical exam, the sensitivity and negative predictive value of CT scanning would increase to 100%. Simply stated, the spinal clearance algorithm should not stop at negative initial CT if the patient has demonstrated motor deficits on physical examination.

This prospective study lends substantial support to the use of CT as an initial and definitive method of ruling out cervical spine injury. However, the presence of an abnormal motor examination

or the patient's inability to move all four extremities warrants additional investigation. Late-generation CT scanners perform admirably in the detection of clinically significant spinal trauma. The rate of missed injuries is exceedingly low, and CT scanners are nearly ubiquitous in modern trauma centers. Patients who fail NEXUS or a clinical decision rule should undergo CT scanning, and MRI can be reserved for those with persistently abnormal motor deficits.

Finally, a study published in *Annals of Emergency Medicine* featured cost modeling to examine the utility of MRI for cervical spine clearance.[4] The authors acknowledged certain variations in clinical practice. Namely, MRI is used to definitively establish the absence of potentially unstable injuries in patients who present to the ED with an intact neurological exam. The authors referenced national databases and created several clinical scenarios for follow-up to match true positive, false positive, true negative, and false negative settings for MRI results. The structured scenarios also considered the costs associated with prolonged disability, including the real potential for missed injuries following an initially negative CT scan.

The authors concluded that MRI, when added to patient scenarios that involved a negative initial CT scan, did not contribute meaningfully to patient outcomes. MRI did not offer any health benefits and came at a significantly increased cost. When coupled with the extremely low risk for missed cervical spine injuries (0.011%), follow-up MRI scanning did not provide patients with any added benefit.

Limitations of this article were acknowledged readily. Clinical scenarios were extrapolated from existing data and assumptions about missed injuries and theoretical information about patient disability. That said, it is important for practicing clinicians to realize that the likelihood of a missed injury in the setting of a normal CT scan and the absence of any neurological deficit is extremely rare. Risk tolerance among practicing emergency and trauma clinicians is difficult to quantify, but the information about the prevalence of unstable injuries can be used to inform decisions about additional imaging in CT-negative patients.

Key Points

- MDCT and a reassuring motor exam can be used to rule out clinically important cervical spine injuries.
- Reserve MRI to clear the cervical spine in patients unable to participate in a motor examination. (*See Figure 1.*)

Myth: All Patients Taking Anticoagulation Therapy Require Admission and Imaging for Delayed Intracranial Hemorrhage

Traumatic brain injury (TBI) results in 1.3 million ED visits, 275,000 hospitalizations, and 52,000 deaths annually in the United States. Patients older than 65 years of age account for 10% of the ED visits and 30% of admissions for TBI.[5] Concurrently, there is also an increased use of prescription oral anticoagulants. From 1998 to 2004, there was a 45% increase in warfarin prescriptions.[6] DOACs, previously known as novel oral anticoagulants (NOACs), bind directly to factors X and II without the need to complex first with antithrombin. These agents, including rivaroxaban, apixaban, edoxaban, betrixaban, and dabigatran, are prescribed with increasing frequency. Many of the anticoagulated patients have concomitant vascular diseases that necessitate dual (DOAC and antiplatelet) and triple (DOAC, antiplatelet, and aspirin) therapy.

Clinical decision rules, such as the Canadian CT Head Rule, the New Orleans criteria, and the NEXUS-II criteria, do not apply to patients taking anticoagulation therapy. Patients who experience injury while taking long-term anticoagulation have an increased incidence of intracranial hemorrhage (ICH) compared to those not taking anticoagulation (8% vs. 5.3%, $P < 0.0001$) and increased mortality with ICH (21.9% vs. 14.2%, $P = 0.04$).[7] For anticoagulated patients taking warfarin who have minor head injuries (loss of consciousness [LOC], amnesia/confusion, Glasgow Coma Scale [GCS] of 13-15) and minimal head injuries (no LOC, amnesia, or confusion, GCS of 15), the rate of ICH was 21.9% and 4.8%, respectively, suggesting the need to maintain a low threshold for ordering CT scans for anticoagulated patients.[6] This correlates with Cohn et al's paper that found a risk of ICH of 6.2-29% in patients taking warfarin therapy.[5] The risk of ICH in patients taking DOACs still is being studied. In the absence of specific guidelines related to initial imaging and final disposition, it is common practice for these patients to undergo initial noncontrast CT scanning on presentation.

What Is the Disposition of Anticoagulated Patients After Head Injury?

For patients with more than minor head trauma, neurological deficits, or CT positive for ICH, there is little debate about obtaining repeat imaging or admission. However, patients who experience minor head injury while taking anticoagulation but who have benign initial head CTs present a quandary for the emergency physician because there are no uniform guidelines about the necessity of repeat imaging to evaluate for delayed ICH. National and international guidelines on the management of mild traumatic brain injury (mTBI) offer limited and sometimes conflicting recommendations. The Eastern Association for the Surgery of Trauma (EAST) recognizes the lack of consistent definitions for injury but provides a Level 3 recommendation that patients taking warfarin who are supra-therapeutic and have normal initial CT be admitted for a period of observation.[8] The European Federation of Neurological Societies suggests a 12- to 24-hour period for close neurologic observation and repeat CT prior to discharge. The Australian head injury guideline suggests performing a routine repeat CT scan within 24 hours or an urgent repeat CT scan if the patient shows signs of deterioration, but reserves clinical judgment for disposition if the initial CT scan and international normalized ratio (INR) are normal. Furthermore, the guideline suggests that prolonged observation and close follow-up either in the hospital or in the community are reasonable until

Figure 1. Suggested Approach to Radiological Clearance of Cervical Spine With Multidetector Computed Tomography

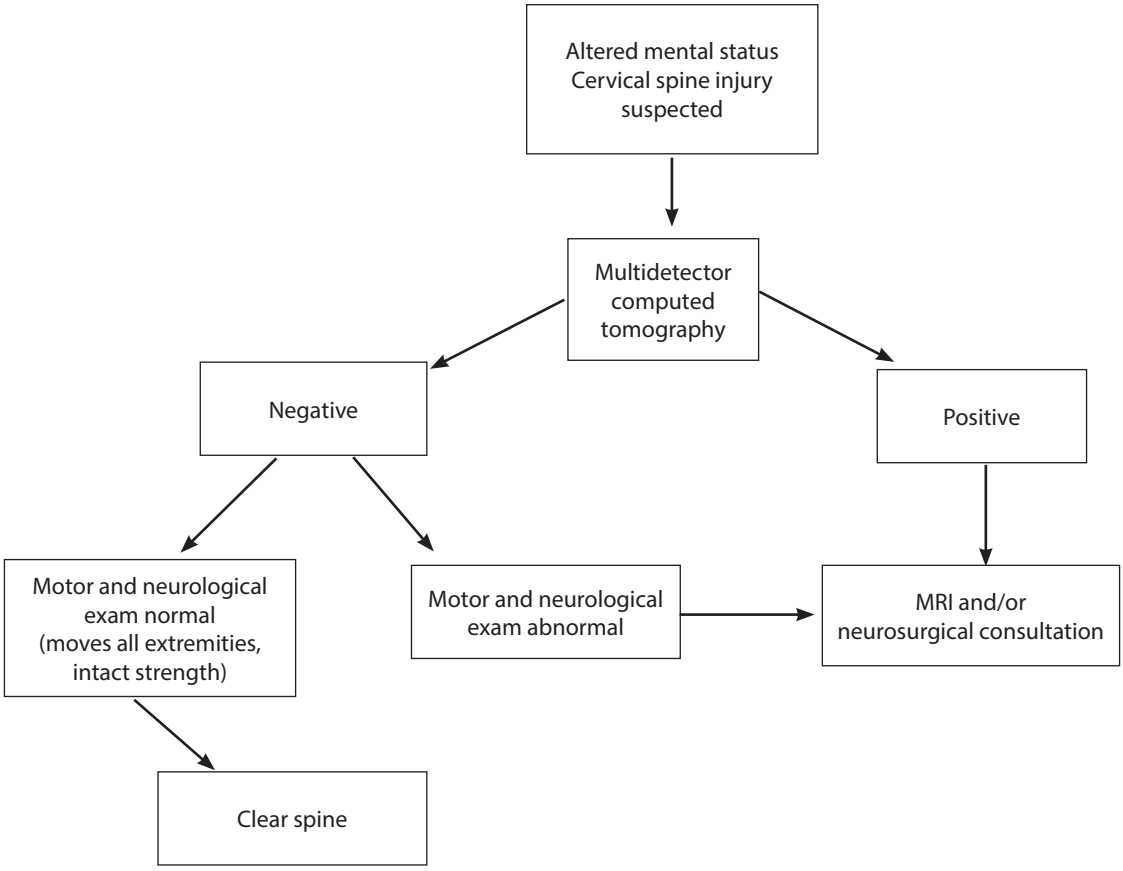

additional evidence is available to guide management.[9,10]

What Is the Prevalence of Delayed Intracranial Hemorrhage?

The prevalence of delayed intracranial hemorrhage (DICH) in the anticoagulated patient after head injury has not been as well studied until recently. Miller et al performed a systematic review to identify the incidence of DICH in mTBI patients who were anticoagulated.[11] The researchers identified five studies, two that were retrospective and three that were prospective with cohorts that included 1,257 patients with minor head injury taking warfarin. The risk of DICH varied between 0 to 72 per 1,000 patients. The study by Nishijima et al had the largest sample size (687), and Miller et al suggested that this study was most applicable to the U.S. population given its multicenter design. Nishijima's study found the risk of DICH to be six per 1,000 cases (95% confidence interval [CI], 2-15).[11,12]

Because of the Risk of DICH, What Is the Value of Repeat Imaging or 24-hour Observation?

Most centers have institutional protocols for patients who experience head injury while taking anticoagulation therapy. Protocols can include admission, repeat imaging, and neurological checks. Menditto et al reviewed the European protocol of 24-hour observation to detect the incidence of DICH. Five of 87 patients (6%) were found to have new hemorrhages, and one experienced neurological deterioration and underwent craniotomy.[13] Two of these five patients returned after discharge. The researchers concluded that their findings support the advisability of initial CT scanning and 24-hour observation.

There are arguments against the protocol of admission or even repeat CT scanning. Kaen et al conducted a prospective study that included 137 patients and observed intracranial bleeding in the subsequent CT in two patients (1.4%), neither of whom required neurosurgical intervention.[14] Cohn et al studied four articles to evaluate whether observation or repeat imaging is warranted.[5] They concluded that the incidence of delayed ICH after a benign CT ranged from 0.6% to 6%; however, the majority of these patients required no neurosurgical intervention or had no documented adverse outcome. The incidence of death or deterioration requiring surgical intervention was 0 to 1.1%.

In a retrospective single study conducted in the Netherlands, 211 of 6,830 patients with suspected head trauma met inclusion criteria for elevated INR on anticoagulation and minor TBI and a normal presenting head CT.[15] Five patients had deterioration, although one of the five had a missed subdural hemorrhage on initial CT with clinical deterioration requiring craniotomy and eventually died. The other four patients developed neurological symptoms after the 24-hour period. One had surgical intervention, but all four had complete recovery. Because of the low risk of secondary deterioration in the 24-hour period, the authors suggested that their study did not support the recommendation of the current guidelines arguing for the 24-hour period, particularly since neurological decline occurred after the observation period.

Can Anticoagulated Patients With Normal Initial Head CT Be Discharged?

Some would argue that a period of observation in the anticoagulated patient who experiences head injury frequently is appropriate to address other medical problems that contributed to the incident, including an assessment of risk factors, use of medication, whether continuing anticoagulation is appropriate, and evaluation of overall fitness for safe discharge. Prior medical conditions or the inability to perform an appropriate neurological assessment because of known medical conditions and social situations (inability to follow up, noncompliance, inability to perform neurological checks) may necessitate a short admission.

Some authors also have suggested that anticoagulated patients with mTBI can be discharged home safely with a negative imaging result. Rendell et al proposed that because of a reassuringly small risk of DICH, it would seem reasonable to discharge patients with an INR of less than 3 and a normal initial CT, with good instructions and follow-up.[16] In a recent prospective, observational cohort study at 11 centers, Chenoworth et al followed patients with blunt head trauma taking anticoagulant and antiplatelet medications for delayed hemorrhage within 14 days.[17] Of the 859 patients enrolled in the study, 343 were taking anticoagulation or antiplatelet medications, but only three patients (0.3%; 95% CI, 0.1-1.0%) had DICH at the 14-day follow-up. Of the three patients, one was taking warfarin alone and the other two were not taking any anticoagulation or antiplatelet medications, and hemorrhage was noted outside the 24-hour observation period. Despite some patients lost to follow-up or death unconfirmed to have DICH, the authors noted a low incidence of DICH after blunt trauma, even while patients were taking anticoagulation or antiplatelet medications, and further suggested that mandatory 24-hour observation and serial CT may be unnecessary.

Admitting every anticoagulated elderly patient for repeat head CT and frequent neurological checks to monitor for deterioration may not always be feasible economically or practically for the community and hospital. Healthcare is not a limitless pool of resources, and emergency medicine providers often are tasked with helping allocate resources. To put this into perspective, the number needed to treat (NNT) (to hospitalize mTBI patients using oral anticoagulation with initial head CT) for the Schoonman study was 211. (Although this is somewhat incorrect in that the initial CT for the patient who experienced neurological decline was positive in this study.)[15] For the Mendetti study, the NNT was 97.[13] In terms of economics, an editorial suggests that the 24-hour observation and routine serial CT would cost an average of approximately $1 million per patient saved.[5]

Alternatives to repeat head CT or admission are needed. The Australian head injury guideline suggests that either clinical or community follow-up is reasonable. Using the model of centers that follow up on patients with diabetes, chronic obstructive pulmonary disease, and congestive heart failure, it might not be unreasonable to establish mTBI centers that will assess these patients for clinical decline to save them hospital admission.

An aging and medically complex population likely will demand more resources. Studies are needed urgently to corroborate clinical practices and risk-stratify head-injured patients appropriately. Admitting all head injury patients for serial examinations and additional scanning increases costs and may not contribute to improved patient outcomes. It is clear that the use of DOACs is associated with a heightened risk of ICH and delayed bleeding. Patients who present to the ED with a normal mental status, adequate social support, and robust outpatient follow-up may represent a population suitable for outpatient follow-up. Additional studies are needed to develop evidence-based clinical decision rules to support such dispositions. Shared medical decision-making, paired with emergency physician gestalt, may help inform a reasonable discharge plan.

Key Point

- Anticoagulated patients with a normal neurological exam, normal initial head CT, and adequate social support may be candidates for discharge.

Myth: All Bleeding Trauma Patients Require a Thromboelastogram

A thromboelastogram (TEG) is a measure of whole blood that analyzes clot formation and viscoelasticity under low shear stress, and is an assessment of the coagulation cascade. Specifically, TEG examines clot formation, stabilization, and breakdown. In addition to measuring clot strength, one of its unique features is that it is useful in quantifying fibrinolysis, allowing for tailoring of antifibrinolytic drugs such as cryoprecipitate and fibrinogen concentrate.[18] TEG has been used for some time in other fields of medicine, including cardiothoracic surgery and liver transplantation, to inform transfusion practices. TEG recently has become more prevalent in the assessment of trauma patients for trauma-induced coagulopathy.[19]

Massive post-traumatic bleeding is the leading cause of potentially reversible death in patients who sustain severe trauma. Authors of a single-center, randomized clinical trial published in the *Annals of Surgery* attempted to compare conventional coagulation

assays (CCA) with TEG in trauma patients who required mass transfusion protocol (MTP) activation.[20] The primary outcome was survival at 28 days. Ultimately, the researchers found that the TEG-guided MTP group had improved mortality over the CCA group (CCA 36.4% mortality vs. TEG 19.6%; $P = 0.049$). The researchers also concluded that most of these deaths occurred in the first six hours, with worse outcomes in the CCA group. Both groups used the same amount of red blood cell units, but the TEG group deviated from the traditional 1:1:1 by using less platelets and fewer plasma units on average. This allows for more goal-directed transfusions. This was demonstrated in additional papers that also found decreased hospital length of stay and ICU length of stay associated with TEG-directed resuscitation.[21]

The utility of TEG has been well demonstrated to guide management in post-traumatic coagulopathy, but TEG's role becomes less clear when the patient is anticoagulated prior to a traumatic injury. Conventional anticoagulants, such as vitamin K antagonists and unfractionated and low molecular-weight heparins, have a well-established dose response curve established by CCAs.

In 2015, Dias et al demonstrated the ability to use rapid TEG to create a dose response curve for rivaroxaban, apixaban, and dabigatran on blood from healthy patients that was exposed to anticoagulants.[22] This test was not performed on patients who had to take the medicine for underlying pathology and was not tested in a trauma setting. It was unclear if TEG should be used to guide reversal of anticoagulation in these patients.[22] Ali et al attempted to answer this question in a retrospective chart review of blunt trauma patients. They found that coagulopathy was not significantly different in the anticoagulated vs. nonanticoagulated groups (15% vs. 11%, respectively; $P = 0.99$), and instead recommended that CCA, as well as medical history and last known anticoagulant ingestion, still should be used to guide reversal decisions.[23] This was a limited study, as it was performed at a single center with a very small sample size of 54. Additional testing is warranted to determine if this finding holds for a larger, more generalized population.

Concurrent intoxication with alcohol has the potential to confound TEG's utility. As previously stated, there is a high correlation between alcohol and trauma. In 2015, Howard et al performed a prospective case-control study with 415 trauma patients and found that alcohol caused a hypocoagulable state as interpreted by TEG, but showed no evidence of coagulopathy on CCAs.[24] It also did not change management or outcomes in these patients, as their transfusion requirements remained the same, and there was no change in mortality outcome.[24] This could indicate a false-negative hypocoagulable state in patients who ingest alcohol prior to trauma or it could represent a test that is more sensitive than clinically necessary to guide transfusion practices.[25]

Thromboelastography has emerged as an important adjunct for patients who require massive transfusions of blood products or who exhibit fibrinolysis. The availability of rapid, point-of-care testing has resulted in increased use of the clotting assay. Clinicians tasked with the initial and ongoing resuscitation of hemorrhaging patients may find utility in the test's ability to quantify fibrinolysis or indicate the need for specific blood components. Its utility as a screening test for all trauma arrivals is questionable because the results may not affect downstream management. Conversely, TEG represents a more accurate measurement of the dynamic coagulopathy in trauma and may be considered for hemodynamically unstable patients. Specifically, TEG results can predict the need for massive transfusion and guide ongoing decisions about blood components or adjuncts such as tranexamic acid.[26]

Key Points

- Consider thromboelastography to guide blood and blood component therapy in the setting of an anticipated massive transfusion.
- Thromboelastography may not be useful as an initial screening test for all bleeding trauma patients.

Myth: Gotta Get That FAST, Fast! All Patients With Blunt Abdominal Trauma Require a CT Scan

The FAST examination is incorporated routinely for most patients who arrive in the ED as a trauma alert. Established guidelines recommend that the FAST exam be performed on almost all patients who experience blunt abdominal trauma (BAT).[27-29] It is widely accepted that penetrating abdominal injuries mandate operative exploration or surgical fixation. Conversely, blunt trauma patients present clinical challenges for emergency resuscitation teams. These patients may undergo CT scanning and extended periods of observation prior to eventual disposition. The FAST exam often is used indiscriminately upon arrival, and its results are incorporated into decisions about accelerated diagnostic management, operative intervention, or a period of watchful waiting.

The widespread availability of ultrasound technology contributes to the incorporation of the FAST exam into diagnostic algorithms. Physicians from various specialties have demonstrated proficiency in image acquisition and interpretation, and the studies indicate that FAST can be performed in the ED with high specificity and reasonable sensitivity.[28,30] Although FAST is less than ideal for the diagnosis of solid organ injury, test results may guide downstream decisions about surgical management or medical intervention.[31,32]

Considering broad indications and widespread use, an ongoing debate persists with respect to the limitations of the FAST exam. To support its continued role in the evaluation of the BAT patient, it is imperative to evaluate this technology for its clinical benefit. Fortunately, emergency physicians, trauma surgeons, and other clinicians engaged in the initial evaluation and resuscitation of trauma patients have expressed interest in this very question. (*See Table 1.*)

One study conducted in a Chinese ED retrospectively evaluated emergency physicians' performance of a screening FAST exam on BAT patients. FAST exams were performed in 242 of 273

Table 1. Summary of Studies on FAST Exams

Study	Method	Number of Patients; Sensitivity/Specificity (if available)	Conclusion
Dammers D, et al; 2017	FAST performed on patients with blunt abdominal trauma who are hemodynamically stable vs. negative events (exploratory laparotomy, embolization, death from abdominal trauma)	n = 421 Sensitivity: 67% Specificity: 99%	Ultrasound can provide prognostic information during the early stage of resuscitation in hemodynamically stable patients with blunt abdominal trauma.
Tsui CL, et al; 2008	Emergency physician performance of FAST in blunt abdominal trauma; patients observed with serial exams or underwent scan in six hours	n = 242 Sensitivity: 86% Specificity: 99%	FAST can be a valuable screening tool.
Smith ZA, et al; 2014	FAST with hemodynamic assessment vs. hemodynamic assessment alone and confirmed by computed tomography, laparotomy	n = 166 Blunt abdominal trauma: Sensitivity: 93% Specificity: 100% Penetrating trauma: Sensitivity: 90% Specificity: 100%	FAST is valuable in all trauma patients, especially if hemodynamically stable, to improve diagnostic capabilities vs. hemodynamic assessments alone.
Barbosa RR, et al; 2013	Measured impact of positive FAST to operating room time since increased time to operating room was associated with increased mortality	n = 115	In patients with positive FAST who required urgent laparotomy, a delay in operating room time was associated with increased mortality. If FAST is positive, decisions must be made quickly to obtain additional diagnostic studies or proceed to the operating room.
Stengel D, et al; 2015	Assessed whether algorithms using ultrasound reduced morbidity and mortality in patients with blunt abdominal trauma	Cochrane review of four randomized, controlled trials	FAST may prompt reduction in the frequency of ordering CT scans, but the review does not provide sufficient evidence to comment on ultrasound-based algorithms in trauma.

cases of BAT.[33] The authors noted an exceptionally high sensitivity and specificity, at 86% and 99%, respectively. (A positive scan was defined as the presence of free intraperitoneal fluid.) The FAST scan had a high negative predictive value at 0.98. Therefore, the authors suggested that FAST exams serve as a valuable screening tool. Because there is a threshold below which free fluid may be missed by the ultrasound examination, patients in this study were observed for at least six hours so that a serial exam or CT exam could be performed. Five false-negative scans were reported, and all involved "small amounts of free intraperitoneal fluid" seen on CT scan. Three patients had mesenteric hematomas, and two cases involved liver lacerations. The authors observed that the use of a full or partially full bladder as an acoustic window may have aided in the discovery of a small amount of free fluid. Other international studies have replicated encouraging results regarding the sensitivity of ultrasound in the setting of BAT. The authors reported results from four other trials that cited sensitivities ranging from 81-86.5%.[33]

A more recent study by Smith and Wood supports the case for conducting FAST exams on abdominal trauma patients.[34] The prospective study included 166 patients who presented with abdominal trauma to a 554-bed government hospital in a South African ED. Patients were assessed immediately for hemodynamic stability and had scans performed in the ED. Scans were confirmed by diagnostic means in 47.6% of cases — CT (56), laparotomy (21), and diagnostic peritoneal lavage (2). The remaining scans were confirmed by a blinded ED ultrasonographer. All patients were followed for at least 24 hours. The authors of this study reported 100% specificity and positive predictive value for FAST in all types of trauma, which was consistent with prior studies. The FAST exam sensitivity was better for blunt abdominal trauma (93.1%) than for penetrating trauma (90%). The authors further noted that the study

demonstrated a significant statistical relationship between hemodynamically unstable blunt trauma patients and those with positive scans ($P = 0.004$). Despite the high sensitivity for ultrasound, it is important to consider the limitations of any study modality when interpreting results. Two patients in the false-negative scan cohort required emergency laparotomy. Bowel injury and solid organ injury that does not result in the production of significant abdominal free fluid can confound initially negative results.[34]

Within much of the emergency medicine and trauma literature, there is consensus about performing a FAST examination. Focused abdominal ultrasound is useful as an initial screen for significant trauma, and the technology is widely available. The finding of positive abdominal free fluid heightens clinical suspicion for a life-threatening injury. When paired with hemodynamic compromise, the presence of free fluid is associated with increased mortality.[34] What should occur following the identification of free abdominal fluid? The answer remains clear when faced with an unstable trauma patient. In the patient who is hemodynamically stable, next steps involve the synthesis of excellent clinical judgment and the performance of gold standard radiologic tests such as the CT scan.

In a retrospective analysis of patients from the Prospective Observational Multicenter Major Trauma Transfusion (PROMMTT) study, investigators examined a subset of patients who presented to area trauma centers and received a FAST exam. Of 1,245 injured patients enrolled in the original study that looked at massive blood transfusion, 115 received a FAST evaluation and underwent emergency laparotomy within 90 minutes.[35] These patients required the "highest level activation" at area trauma centers. All hemodynamically unstable patients had an emergency laparotomy that was deemed therapeutic. Furthermore, the study authors reported a significant association between delayed time to operative management and mortality at 24 hours. The association between definitive hemorrhage control and improved outcomes is well known to emergency and trauma clinicians. Despite the link between positive free fluid and mortality, the positive FAST exam did not necessarily correlate with the need for an emergent operation.

When including the larger cohort of PROMMTT patients, only 72% of patients with a positive FAST exam received a laparotomy within 24 hours. The authors reported that certain injury patterns were "amenable" to non-operative management. Direct transfer to the operating room would lead to an increased proportion of nontherapeutic laparotomies and expose patients to additional and perhaps unnecessary risk. The study reaffirms the long-standing practice of transitioning unstable patients with a positive FAST result to the operating room. With respect to stable patients, additional diagnostic studies may be required for operative planning or definitive diagnosis. Because positive FAST findings are associated with adverse outcomes, even hemodynamically stable patients should be prioritized for downstream CT scans and the "highest levels of trauma activation." When patients arrive at hospitals without immediate surgical capability, the authors recommended that clinicians consider transferring FAST-positive patients to area trauma centers prior to obtaining a confirmatory CT scan.

Limitations to the application of FAST in abdominal trauma were highlighted in a recent Cochrane review. In 2015, Stengel et al assessed the clinical effectiveness of an evaluation algorithm that incorporated the FAST exam into a diagnostic pathway for BAT.[36] The authors searched available randomized, controlled trials to determine the effect of FAST examination on patient mortality. They also examined the effect of ultrasound on the use of MDCT or other invasive procedures. The cost-effectiveness of ultrasound also was included as an outcome measure. Four trials met criteria for inclusion, and the authors found significant heterogeneity between the trial results. The lack of input from randomized, controlled trial authors, coupled with significant methodological flaws, made it difficult to draw definitive conclusions about the ability of a FAST-based diagnostic algorithm to influence patient outcomes.

Pooled data from the randomized, controlled trials revealed a trend toward reduced MDCT use by as much as 50%. Mortality data were available for three trials, and researchers observed no evidence of a difference in patients undergoing a FAST-diagnostic pathway. However, the Cochrane reviewers encouraged caution when looking at FAST as a sole imaging modality for BAT. The review referenced data from a German trauma registry and commented that a "primary CT scan is lifesaving" and further observed that CT scans represent the standard of care when making decisions about "admission and clinical monitoring." The randomized, controlled trials featured in the review affirmed the high specificity of FAST scans for significant abdominal trauma. However, the overall sensitivity of the FAST exam remained low, at or below 90%.

Although an initially negative FAST result is reassuring, it cannot be compared to the ability of MDCT to definitively rule out the presence of solid organ injury or developing hemorrhage. The study authors acknowledged that FAST is well positioned to function as an initial triage tool and may have additional implications in prehospital or mass casualty scenarios.[36] Clinical guidelines and well-established practices support the use of the FAST examination for the evaluation of BAT patients.[29,37] FAST exams can be performed reliably and offer clinicians valuable prognostic information, especially when free fluid is discovered. Because these scans represent no increased risk and have the potential to complement a clinical examination, the FAST exam is recommended almost universally in the initial evaluation of stable blunt trauma patients.

Key Points

- The relatively low cost and ubiquitous nature of the FAST exam make it ideally suited as an initial screening tool for patients with BAT.
- When incorporated into existing trauma protocols, the FAST exam may expedite time to operative intervention

and improve mortality in a select group of patients.

Summary

Guidelines provide emergency clinicians with information needed to make sound, consistent, and evidence-based decisions about diagnostic and therapeutic treatment strategies. Despite their widespread availability, they are not intended to substitute for clinical judgment and experience. Myths develop when practice patterns become ingrained as they are passed down from one generation of clinicians to another. The practice of emergency medicine is at the intersection of protocols and evidence-based practice. Trauma care requires adherence to routine so that critical patients can be triaged, examined, and directed to definitive care rapidly. Unfortunately, axioms featured in courses such as Advanced Trauma Life Support and Advanced Cardiac Life Support can become so entrenched into practice that they somehow transform into dogma.

This review article dissected four commonly held assumptions about specific trauma-based care pathways. First, not all patients with a cervical spine injury require MRI. MDCT scanners are exceptionally accurate. Instead, MRI should be reserved for the small cohort of patients who have motor weakness on exam and an altered mental status. Second, the widespread prescription of DOACs has challenged the applicability of clinical decision rules. Patients taking DOACs are at high risk for intracranial injury and require a slightly tailored approach for ED disposition. Patients with a clear sensorium, a minor mechanism of injury, and an initially negative MDCT may be candidates for close interval outpatient follow-up after blunt head trauma. Admission should be pursued for patients who sustained a loss of consciousness following the injury. Third, TEG has been incorporated into clinical guidelines recently. TEG can guide the administration of blood and blood products in acutely unstable patients. It has little to no role in the screening of an undifferentiated trauma patient population. Finally, the FAST exam has demonstrated utility in the workup of patients with BAT. It cannot be used to rule out retroperitoneal, solid organ, or bowel wall injury definitively. It is performed with little to no risk to the patient and potentially can identify life-threatening injuries early in the course of evaluation.

References

1. Raza M, Elkhodair S, Zaheer A, Yousaf S. Safe cervical spine clearance in adult obtunded blunt trauma patients on the basis of a normal multidetector CT scan — a meta-analysis and cohort study. *Injury* 2013;44:1589-1595.
2. Inaba K, Byerly S, Bush LD, et al. Cervical spine clearance: A prospective Western Trauma Association multi-institutional trial. *J Trauma Acute Care Surg* 2016;81:1122-1130.
3. Martin MJ, Bush LD, Inaba K, et al. Cervical spine evaluation and clearance in the intoxicated patient: A prospective Western Trauma Association multi-institutional trial and survey. *J Trauma Acute Care Surg* 2017;83:1032-1040.
4. Wu X, Malhotra A, Geng B, et al. Cost-effectiveness of magnetic resonance imaging in cervical spine clearance of neurologically intact patients with blunt trauma. *Ann Emerg Med* 2018;71:64-73.
5. Cohn B, Keim SM, Sanders AB. Can anticoagulated patients be discharged home safely from the emergency department after minor head injury? *J Emerg Med* 2014;46:410-417.
6. Alrajhi KN, Perry JJ, Forster AJ. Intracranial bleeds after minor and minimal head injury in patients on warfarin. *J Emerg Med* 2015;48:137-142.
7. Pieracci F, Eachempati S, Shou J, et al. Use of long-term anticoagulation is associated with traumatic intracranial hemorrhage and subsequent mortality in elderly patients hospitalized after falls: Analysis of the New York State Administrated Database. *J Trauma* 2007;63:519-524.
8. Barbosa RR, Jawa R, Watters JM, et al. Evaluation and management of mild traumatic brain injury: An Eastern Association for the Surgery of Trauma practice management guideline. *J Trauma Acute Care Surg* 2012;73(5Suppl4):S307-S314.
9. Vos PE, Alekseenko Y, Battistin E, et al; European Federation of Neurological Societies. Mild traumatic brain injury. *Eur J Neurol* 2012;19:191-198.
10. NSW Ministry of Health. Adult Trauma Clinical Practice Guidelines. Initial Management of Closed Head Injury in Adults, 2nd ed. 2011. Available at: https://www.aci.health.nsw.gov.au/__data/assets/pdf_file/0003/195150/Closed_Head_Injury_CPG_2nd_Ed_Full_document.pdf. Accessed July 24, 2018.
11. Miller J, Lieberman L, Nahab B, et al. Delayed intracranial hemorrhage in the anticoagulated patient: A systematic review. *J Trauma Acute Care Surg* 2015;79:310-313.
12. Nishijima DK, Offerman SR, Ballard DW, et al. Immediate and delayed traumatic intracranial hemorrhage in patients with head trauma and preinjury warfarin or clopidogrel use. *Ann Emerg Med* 2012;59:460-468.e7.
13. Menditto VG, Lucci M, Polonara S, et al. Management of minor head injury in patients receiving oral anticoagulant therapy: A prospective study of a 24-hour observation protocol. *Ann Emerg Med* 2012;59:451-455.
14. Kaen A, Jimenez-Roldan L, Arrese I, et al. The value of sequential computed tomography scanning in anticoagulated patients suffering from minor head injury. *J Trauma* 2010;68:895-898.
15. Schoonman GG, Bakker DP, Jellema K. Low risk of late intracranial complications in mild traumatic brain injury patients using oral anticoagulation after an initial normal brain computed tomography scan: Education instead of hospitalization. *Eur J Neurol* 2014;21:1021-1025.
16. Rendell S, Sultan L. Towards evidence based emergency medicine: Best BETs from the Manchester Royal Infairmay. BET 3: Observation is unnecessary following a normal CT brain in warfarinised head injuries: An update. *Emerg Med J* 2014;31:339-342.
17. Chenoweth JA, Gaona SD, Faul M, et al. Incidence of delayed intracranial hemorrhage in older patients after blunt head trauma. *JAMA Surg* 2018;153:570-575.
18. da Luz LT, Nascimento B, Rizoli S. Thrombelastography (TEG®): Practical considerations on its clinical use in trauma resuscitation. *Scand J Trauma Resusc Emerg Med* 2013;21:29.
19. Smart L, Mumtaz K, Scharpf D, et al. Rotational thromboelastometry or conventional coagulation tests in liver transplantation: Comparing blood loss, transfusions, and cost. *Ann Hepatol* 2017;16:916-923.
20. Gonzalez E, Moore EE, Moore HB, et al. Goal-directed hemostatic resuscitation of trauma-induced coagulopathy: A pragmatic randomized clinical trial comparing a viscoelastic assay to conventional coagulation assays. *Ann Surg* 2016;263:1051-1059.
21. Mohamed M, Majeske K, Sachwani GR, et al. The impact of early thromboelastography directed therapy in trauma resuscitation. *Scand J Trauma Resusc Emerg Med* 2017;25:99.

22. Dias JD, Norem K, Doorneweerd DD, et al. Use of thromboelastography (TEG) for detection of new oral anticoagulants. *Arch Pathol Lab Med* 2015;139:665-673.

23. Ali JT, Daley MJ, Vadiei N, et al. Thromboelastogram does not detect pre-injury anticoagulation in acute trauma patients. *Am J Emerg Med* 2017;35: 632-636.

24. Howard BM, Kornblith LZ, Redick BJ, et al. The effects of alcohol on coagulation in trauma patients: Interpreting thrombelastography with caution. *J Trauma Acute Care Surg* 2014;77:865-871.

25. Cook MR, Louis SG, McCully SP, et al. Positive blood alcohol is associated with reduced DVT in trauma. *Injury* 2015;46:131-135.

26. Cotton BA, Faz G, Hatch QM, et al. Rapid thromboelastography delivers real-time results that predict transfusion within 1 hour of admission. *J Trauma* 2011;71:407-417.

27. Dammers D, El Moumni M, Hoogland II, et al. Should we perform a FAST exam in haemodynamically stable patients presenting after blunt abdominal injury: A retrospective cohort study. *Scand J Trauma Resusc Emerg Med* 2017;25:1-8.

28. Savatmongkorngul S, Wongwaisayawan S, Kaewlai R. Focused assessment with sonography for trauma: Current perspectives. *Open Access Emerg Med* 2017;9:57-62.

29. American Institute of Ultrasound Medicine. AIUM Practice Parameter for the Performance of the Focused Assessment With Sonography for Trauma (FAST) Examination. Available at: https://www.aium.org/resources/guidelines/fast.pdf. Accessed March 19, 2018.

30. Boulanger BR, McLellan BA, Brenneman FD, et al. Prospective evidence of the superiority of a sonography-based algorithm in the assessment of blunt abdominal injury. *J Trauma* 1999;47:632-637.

31. Ollerton JE, Sugrue M, Balogh Z, et al. Prospective study to evaluate the influence of FAST on trauma patient management. *J Trauma* 2006;60:785-791.

32. Mohammadi A, Ghasemi-Rad M. Evaluation of gastrointestinal injury in blunt abdominal trauma "FAST is not reliable": The role of repeated ultrasonography. *World J Emerg Surg* 2012;7:2.

33. Tsui CL, Fung HT, Chung KL, Kam CW. Focused abdominal sonography for trauma in the emergency department for blunt abdominal trauma. *Int J Emerg Med* 2008;1:183-187.

34. Smith ZA, Wood D. Emergency focussed assessment with sonography in trauma (FAST) and haemodynamic stability. *Emerg Med J* 2014;31:273-277.

35. Barbosa RR, Rowell SE, Fox EE, et al. Increasing time to operation is associated with decreased survival in patients with a positive FAST examination requiring emergent laparotomy. *J Trauma Acute Care Surg* 2013;75(1 Suppl1):S48-S52.

36. Stengel D, Rademacher G, Ekkernkamp A, et al. Emergency ultrasound-based algorithms for diagnosing blunt abdominal trauma. *Cochrane Database Syst Rev* 2015;9:CD004446.

37. Richards JR, McGahan JP. Focused Assessment with Sonography in Trauma (FAST) in 2017: What radiologists can learn. *Radiology* 2017;283:30-48.

CME/CE Questions

1. A 32-year-old patient sustains a blunt head injury. He arrives in the emergency department complaining of mild head and neck pain. The neurological exam is significant for slight confusion and amnesia, but otherwise is nonfocal. The motor examination reveals no deficits or areas of weakness. The patient has tenderness to palpation of the posterior cervical spine and undergoes a CT scan. The next-generation MDCT scan is negative for acute fracture or dislocation. The patient has persistent neck pain. What is the most appropriate step in patient management?
   a. Repeat the CT scan.
   b. Consider the patient's cervical spine to be radiologically cleared.
   c. Obtain a stat MRI.
   d. Obtain flexion/extension views of the spine.

2. An 84-year-old male with a history of atrial fibrillation on apixaban presents to the emergency department after a minor ground-level fall. The patient denies any loss of consciousness. The patient is hypertensive but otherwise hemodynamically stable. The patient has a reassuring and nonfocal neurologic examination. A noncontrast CT scan is negative for any obvious bleeding. The patient is observed for six hours in the emergency department. What is the next most appropriate step in management?
   a. Obtain an MRI.
   b. Repeat the CT scan.
   c. Admit the patient for observation.
   d. Consider discharge if the patient has close outpatient follow-up.

3. A patient with a history of hepatitis and alcoholism arrives in the emergency department following a minor motor vehicle crash. The patient was tachycardic upon arrival and received CT scans of the chest, abdomen, and pelvis. The patient's CT scans show no obvious bleeding, but the patient is admitted by the trauma service for observation and abdominal examinations. The patient has normal hemoglobin and INR levels. Which of the following is true regarding thromboelastography in this patient?
   a. Thromboelastography is not likely to change patient management.
   b. Thromboelastography should be obtained because of the patient's history of alcoholism.
   c. Thromboelastography is indicated because of possible coagulopathy from liver disease.
   d. Serial thromboelastography scans should be considered in this patient.

4. Which of the following statements accurately describes characteristics of the Focused Abdominal

CME/CE INSTRUCTIONS

To earn credit for this activity, please follow these instructions:

1. Read and study the activity, using the references for further research.
2. Log onto ReliasMedia.com and click on My Account. *First-time users must register on the site.*
3. Pass the online test with a score of 100%; you will be allowed to answer the questions as many times as needed to achieve a score of 100%.
4. After successfully completing the test, a credit letter will be emailed to you instantly.
5. Twice yearly after the test, your browser will be directed to an activity evaluation form, which must be completed to receive your credit letter.

Sonography for Trauma (FAST) exam?
   a. It is unnecessary to perform FAST exams on stable blunt trauma patients.
   b. FAST exams can identify solid organ injuries such as a liver laceration reliably.
   c. The suprapubic window, the right and left colic gutter window, and the pleural windows all are components of the FAST exam.
   d. The FAST exam is a noninvasive and well-tolerated adjunct to the evaluation of trauma patients. Clinicians should have a low threshold for performing this examination.

5. FAST exams have demonstrated high sensitivity and specificity in the setting of significant abdominal injury. However, CT scans remain the diagnostic test of choice when seeking to rule out intra-abdominal trauma definitively. Which of the following injury patterns represents known limitations of the FAST examination?
   a. Mesenteric hematoma
   b. Retroperitoneal bleeding
   c. The presence of a small amount of intra-abdominal free fluid
   d. All of the above

TRAUMA REPORTS

CME/CE Objectives

Upon completing this program, the participants will be able to:

- discuss conditions that should increase suspicion for traumatic injuries;
- describe the various modalities used to identify different traumatic conditions;
- cite methods of quickly stabilizing and managing patients; and
- identify possible complications that may occur with traumatic injuries.

TRAUMA REPORTS™ (ISSN 1531-1082) is published 6 times annually by Relias LLC, 111 Corning Road, Suite 250, Cary, NC 27518-9238. Telephone: (800) 688-2421.

Executive Editor: Shelly Morrow Mark

Executive Editor: Leslie Coplin

Editorial Group Manager: Terrey L. Hatcher

Senior Accreditations Officer: Lee Landenberger

GST Registration No.: R128870672

Periodicals Postage Paid at Cary, NC, and additional mailing offices.

POSTMASTER: Send address changes to ***Trauma Reports,*** Relias LLC, 111 Corning Road, Suite 250 Cary, NC 27518-9238.

Missing issues will be fulfilled by customer service free of charge when contacted within one month of the missing issue's date.

SUBSCRIBER INFORMATION

CUSTOMER SERVICE: (800) 688-2421

Customer Service Email Address:
Customer.Service@AHCMedia.com

Editorial Email Address:
mmark@relias.com

Online:
ReliasMedia.com

SUBSCRIPTION PRICES

$259 per year. Add $19.99 for shipping & handling

FREE to subscribers of *Emergency Medicine Reports* and *Pediatric Emergency Medicine Reports*

MULTIPLE COPIES:
Discounts are available for group subscriptions, multiple copies, site-licenses, or electronic distribution. For pricing information, please contact our Group Account Managers at Groups@AHCMedia.com or (866) 213-0844.

RELIAS MEDIA

ACCREDITATION

Relias LLC is accredited by the Accreditation Council for Continuing Medical Education (ACCME) to provide continuing medical education for physicians.

Relias LLC designates this enduring material for a maximum of 3 *AMA PRA Category 1 Credits*™. Physicians should claim only the credit commensurate with the extent of their participation in the activity.

Approved by the American College of Emergency Physicians for a maximum of 3 hours of ACEP Category I credit.

The American Osteopathic Association has approved this continuing education activity for up to 2.5 AOA Category 2-B credits per issue.

Relias LLC is accredited as a provider of continuing nursing education by the American Nurses Credentialing Center's Commission on Accreditation. Contact hours [3] will be awarded to participants who meet the criteria for successful completion. California Board of Registered Nursing, Provider CEP#13791.

This is an educational publication designed to present scientific information and opinion to health professionals, to stimulate thought, and further investigation. It does not provide advice regarding medical diagnosis or treatment for any individual case. It is not intended for use by the layman. Opinions expressed are not necessarily those of this publication. Mention of products or services does not constitute endorsement. Clinical, legal, tax, and other comments are offered for general guidance only; professional counsel should be sought for specific situations.

This CME/CE activity is intended for emergency, family, osteopathic, trauma, surgical, and general practice physicians and nurses who have contact with trauma patients. It is in effect for 36 months from the date of publication.