AMERICAN HEALTH CONSULTANTS®

EMERGENCY MEDICINE ALERT

An essential monthly update of developments in emergency medicine

From the Publishers of Emergency Medicine Reports™

Volume 7 Index included in this issue

American Health Consultants Home Page—http://www.ahcpub.com

CME for Physicians—http://www.cmeweb.com

Coronary Reperfusion: Stent vs. Fibrinolysis

ABSTRACT & COMMENTARY

Source: Le May MR, et al. Stenting versus thrombolysis in acute myocardial infarction trial (STAT). *J Am Coll Cardiol* 2001;37:985-991.

EARLY AND COMPLETE REPERFUSION IS THE PRIMARY GOAL FOR THE treatment of acute myocardial infarction (AMI) in the emergent setting. However, the best reperfusion strategy remains controversial. Pharmacologic therapy (fibrinolysis/thrombolysis) and mechanical reperfusion (angioplasty or percutaneous transluminal coronary angioplasty [PTCA]) each have advantages and disadvantages that depend on the patient's clinical presentation and available hospital resources. Recent work with the use of stents has shown significant benefit over standard PTCA in the setting of AMI. This study, termed STAT, directly compares the use of mechanical stents to pharmacologic fibrinolysis.

Experienced investigators at an university medical center randomized 123 AMI patients to stenting (62) or accelerated-dosed tissue plasminogen activator (tPA, 61). Exclusion criteria were cardiogenic shock, active bleeding, history of stroke, prior stent or coronary artery bypass graft, recent surgery, trauma, or PTCA. The primary end point was a composite of death, reinfarction, stroke, or repeat target vessel revascularization (TVR) for ischemia. Stent placement was successful in 50 (81%) subjects, and the number of patients with TIMI-3 (normal) angiographic flow increased from one to 46 in the stent group. All patients assigned to tPA received the medication, seven of which (11.5%) underwent rescue PTCA due to lytic failure.

The combined end point of death, reinfarction, stroke, and repeat TVR was significantly lower for the stent vs. tPA group during hospitalization (19% vs 47%), at six weeks (19% vs 51%), and at six months (24% vs 56%). Most of this difference was due to repeat TVR rates, as the incidence of death, stroke, and reinfarction was not significantly different between the two groups when studied separately. Recurrent unstable ischemia after treatment was significantly lower in the stent group at six months (9.7 vs 26.2%). Median lengths of hospital stay were shorter for those who were in the stent

Volume 8 • Number 1 • June 2001 • Pages 1-8

INSIDE

group (4 vs 7 days). Based on their results, the authors conclude that primary stenting in the AMI setting may be an attractive alternative to fibrinolytic therapy in terms of outcome and length of hospitalization.

COMMENT BY THEODORE C. CHAN, MD, FACEP

New advances continue to alter the ongoing debate between pharmacologic and mechanical reperfusion strategies for AMI. Newer fibrinolytic agents, such as tenecteplase, have improved the ease of administration and reduced the adverse effects associated with pharmacologic therapy. Stenting has been shown to have additional benefits over standard angioplasty for mechanical reperfusion.[1]

In this study comparing stenting to fibrinolysis, stenting demonstrated a clear advantage over pharmacologic reperfusion in terms of recurrent unstable ischemia and the need for repeat TVR within six months. In addition, stented patients had significantly shorter hospital stays. However, these results should be viewed with some caution. First, this study was limited by its small sample size, which may explain why no significant differences were found when comparing rates of death, reinfarction, and stroke separately (as opposed to the combined end point which included repeat TVR). Second, prior studies have shown that emergent mechanical reperfusion, unlike fibrinolytic therapy, varies with hospital resources, experience, and volume.[2] This study was conducted at a single institution with experience in mechanical reperfusion and a high volume of angioplasties (> 1200 per year). The benefit of stenting (as well as the shorter hospital stays) seen in this study may be limited only to high-volume, experienced centers.

It is interesting to note that routine use of platelet glycoprotein inhibitors initially was discouraged. When growing evidence suggested benefit from stenting, the use of these agents was left to the discretion of the physician and, ultimately, 12 patients in the stent group received abciximab. Although no analysis was performed, recent reports suggest significant benefit from the combined therapy of stenting and platelet inhibition over fibrinolysis.[3] There likely will be greater interest in and research on combination therapies (platelet inhibition, fibrinolysis, and mechanical reperfusion) as optimal strategies for AMI treatment in the future.[4] ❖

References

1. Grines CL, et al. Coronary angioplasty with or without stent implantation for acute myocardial infarction. *N Engl J Med* 1999;341:1949-1956.
2. Magid DJ, et al. Relation between hospital primary angioplasty volume and mortality for patients with acute MI treated with primary angioplasty vs thrombolytic therapy. *JAMA* 2000;284:313-318.
3. Schomig A, et al. Coronary stenting plus platelet glycoprotein IIb/IIIa blockade compared with tissue plasminogen activator in acute myocardial infarction. *N Engl J Med* 2000;343:385-391.
4. Sayre MR. Facilitated percutaneous coronary intervention for acute myocardial infarction. *J Emerg Med* 2000;19(3 suppl):27S-32S.

Midazolam vs. Pentobarbital for Pediatric Sedation

ABSTRACT & COMMENTARY

Source: Moro-Sutherland DM, et al. Comparison of intravenous midazolam with pentobarbital for sedation for head computed tomography imaging. *Acad Emerg Med* 2000;7:1370-1375.

THESE AUTHORS SOUGHT TO DETERMINE WHETHER pentobarbital is a more effective sedative than midazolam for young patients undergoing computed

***Emergency Medicine Alert*™,** ISSN 1075-6914, is published monthly by American Health Consultants, 3525 Piedmont Rd., NE, Bldg. 6, Suite 400, Atlanta, GA 30305.

Vice President and Group Publisher: Brenda Mooney.
Editorial Group Head: Valerie Loner.
Managing Editor: Suzanne Zunic.
Associate Managing Editor: Allison Mechem.
Marketing Manager: Schandale Kornegay.

GST Registration Number: R128870672.

Periodical postage paid at Atlanta GA 30304. **POSTMASTER:** Send address changes to ***Emergency Medicine Alert*™**, P.O. Box 740059, Atlanta, GA 30374.

Back issues: $38. One to nine additional copies, $183 each; 10 to 20 additional copies, $137 each.

AMERICAN HEALTH CONSULTANTS
THOMSON HEALTHCARE

Subscriber Information

Customer Service: 1-800-688-2421

Customer Service E-Mail Address: customerservice@ahcpub.com
Editorial E-Mail Address: paula.cousins@ahcpub.com
World-Wide Web: http://www.ahcpub.com

Subscription Prices

United States: $229 per year (Resident rate: $114)
Canada: $239 per year plus GST (Resident rate: $120)
Elsewhere: $239 per year (Resident rate: $120)

Accreditation

American Health Consultants (AHC) is accredited by the Accreditation Council for Continuing Medical Education (ACCME) to provide continuing medical education for physicians.

This CME activity was planned and produced in accordance with ACCME Essentials.

American Health Consultants designates this continuing medical education activity for up to 20 hours in category 1 credit towards the Physician's Recognition Award. Each physician should only claim those hours of credit that he/she actually spent in the educational activity. ***Emergency Medicine Alert*™** is also approved by the American College of Emergency Physicians for 20 hours of ACEP category 1 credit. This CME activity was planned and produced in accordance with the ACCME Essentials. ***Emergency Medicine Alert*™** has been approved by the American Academy of Family Physicians as having educational content acceptable for Prescribed credit hours. This volume has been approved for up to 20 Prescribed credit hours. Term of approval covers issues published within one year from the beginning distribution date of June 2000. Credit may be claimed for one year from the date of this issue. **For CME credit, add $50.**

Questions & Comments

Please call **Allison Mechem**, Associate Managing Editor, at (404) 262-5589 between 8:30 a.m. and 4:30 p.m. ET, Monday-Friday.

Statement of Financial Disclosure

To reveal any potential bias in this publication, and in accordance with Accreditation Council for Continuing Medical Education guidelines, we disclose that Dr. Brady is on the speaker's bureau for Genentech. Dr. Gibbs is a consultant and is involved in research for LMA North America. Dr. Karras is a consultant for Bayer Pharmaceuticals; is a consultant, speaker, and is involved in research for Aventis; is involved in research for Bristol-Myers Squibb; and is involved in research for Sepracro. Dr. Grauer is president of KG/EKG Press. Drs. Abbuhl, Chan, Felz, Harrigan, Hamilton, and Ufberg report no financial relationships with companies having ties to this field of study.

tomography (CT) of the head. Children ages 6 months to 6 years were eligible if they required a head CT for any reason, needed intravenous sedation, and had no underlying cardiopulmonary disease. After obtaining parental consent, the children were randomized to receive pentobarbital or midazolam. Pentobarbital was given as a 2.5 mg/kg IV dose followed by two 1.25 mg/kg doses at 1-minute intervals (total dose of 5 mg/kg over 3.5 minutes). Midazolam was given as a 0.1 mg/kg IV dose followed by two 0.05 mg/kg doses. Each midazolam dose was given over 2 minutes and was followed by a 2-minute wait (total dose of 0.2 mg/kg over 10 minutes). The authors found it impossible to blind the staff to the medication being administered.

The primary end point of the study was the quality of sedation, which was judged to be "good" if the patient was sedated and the CT completed; "adequate" if the patient was not sedated but the study completed; and "poor" or "unsuccessful" if the study was non-diagnostic or was not performed because of poor sedation.

Fifty-five subjects were enrolled over 2.5 years. In the pentobarbital group, 28 of 29 patients had good sedation and were successfully scanned. In the midazolam group, three of 26 had good sedation and another two had adequate sedation. Most of the subjects in the midazolam group subsequently were given pentobarbital to allow completion of the CT. There were no serious adverse events in either group; however, four patients receiving pentobarbital had mild oxygen desaturation. Because so few patients receiving midazolam had successful scans, the authors presented no formal analyses of the differences between the groups, and concluded that IV pentobarbital is more effective than IV midazolam in sedating young children for head CT.

COMMENT BY DAVID J. KARRAS, MD, FAAEM, FACEP

The authors attempted to perform a carefully controlled study of two sedative agents for young children. Unfortunately, major limitations of this study's design leave the question unsettled. The study was unblinded, introducing the possibility of observer bias, and data collection was performed by staff who were aware of which drug was being administered. Secondly, midazolam was administered over a much longer period of time than was pentobarbital. The most important concern, however, is that the total dose of midazolam (0.2 mg/kg) was on the low end of the therapeutic range for achieving sedation in young children. The manufacturer's current recommendation is that a total midazolam dose of 0.6 mg/kg (given in 0.05-0.1 mg/kg increments) may be necessary to achieve procedural sedation in this age group. These limitations detract significantly from what appears to be a fairly straightforward study, making it difficult to accept the authors' conclusions regarding any advantages of pentobarbital over midazolam for pediatric sedation. ❖

Intubating Laryngeal Mask Airway in Patients with Suspected C-Spine Injury

ABSTRACT & COMMENTARY

Source: Waltl B, et al. Tracheal intubation and cervical spine excursion: Direct laryngoscopy vs. intubating laryngeal mask. *Anaesthesia* 2001;56:221-226.

THE AIM OF THIS STUDY WAS TO COMPARE THE EXCURsion of the upper cervical spine during tracheal intubation using direct laryngoscopy to intubation using the intubating laryngeal mask airway (ILMA, Fastrach™), by examination of lateral cervical spine radiographs in healthy young adults. Forty patients without any pathology of the cervical spine or airway who were scheduled for elective orthopedic surgery were randomized to two groups. In group A, patients were intubated using conventional laryngoscopy with a size 3 or 4 Macintosh blade. In group B, patients were intubated using a size 3, 4, or 5 ILMA. Cricoid pressure and stabilization of the head and neck were not applied in either group. Airway insertion time was recorded. Three lateral cervical spine x-rays were taken. The first radiograph was taken before any manipulation. In each group a second radiograph was taken at the point of greatest cervical excursion. In group A this was when the best possible view of the larynx was obtained. In group B this was when the ILMA reached the posterior pharynx and the rigid curved tube was advanced into the airway. The third radiograph was obtained immediately after intubation. The radiographs were analyzed for movements at cervical segments C1/2 and C2/3. A reference line was drawn along the posterior longitudinal ligament. Lines along the base of C1 and C3 were drawn through the reference line and respective angles were measured. The angles of the second and third x-rays were compared to the angle of the first x-ray. Radiographs were blinded and read by a radiologist who was unaware of the purpose of the study.

Intubation with direct laryngoscopy was successful on the first attempt in all patients. The ILMA was inserted successfully on the first attempt in all patients, and the trachea was intubated successfully on the first attempt in 17 patients. Intubation required more than one attempt in two patients, and was not possible in one

patient (tracheal intubation success rate 95%). The mean time to successful intubation was 21 seconds (SD = 5 seconds) in group A and 39 seconds (SD = 7 seconds) in group B. The degree of cervical spine excursion during intubation with the ILMA was significantly less compared to intubation by direct laryngoscopy ($P < 0.008$). There were no complications in either group.

COMMENT BY MICHAEL A. GIBBS, MD, FACEP

I have two comments. First, I believe that oral endotracheal intubation using rapid sequence intubation is the airway maneuver of choice in the blunt trauma patient with known or suspected cervical spine injury, provided laryngoscopy and intubation are performed in a gentle, atraumatic manner and precise cervical immobilization is maintained throughout the procedure. There are several large case series demonstrating the safety of oral intubation in this setting. Second, the intubating laryngeal mask airway is an excellent technique for airway rescue in the emergency department when rapid sequence intubation fails. The technique is easy to learn, atraumatic, can be rapidly performed, and has few complications. Most importantly, the ILMA is the only blind airway rescue device that provides a definitive airway with a cuffed endotracheal tube. Although this study will not change my initial approach to the trauma airway, it does provide further evidence that the ILMA is a very reasonable rescue technique to use in the injured patient at high risk for cervical injury. ❖

Delayed Pneumothorax and Repeat Chest X-ray After Penetrating Thoracic Injury

ABSTRACT & COMMENTARY

Source: Shatz DV, et al. Efficacy of follow-up evaluation in penetrating thoracic injuries: 3- vs. 6-hour radiographs of the chest. *J Emerg Med* 2001:20:281-284.

THE INCIDENCE OF DELAYED PNEUMOTHORAX (PTX) resulting from penetrating injuries of the chest has been reported to be as high as 12%. In most hospitals, serial chest x-rays (CXRs) are used to manage patients with penetrating chest trauma without PTX on initial radiograph. The suggested time interval for performing follow-up CXR is variable, ranging from six to 48 hours. Kerr and coworkers validated the use of a six-hour follow-up CXR to eliminate the risk of delayed PTX.[1]

This study examined the possibility of shortening the time period to follow-up CXR from six to three hours in patients with penetrating chest injuries. All patients with penetrating wounds that were bounded by the clavicles, the base of the neck superiorly, and the costal margin and iliac crest posteriorly were included if they were asymptomatic on arrival to the emergency department (ED), had no PTX or hemothorax on initial CXR, and did not require immediate admission to the intensive care unit (ICU) or operating room. Enrolled patients had initial, three-hour, and six-hour expiratory CXRs during the ED stay. A CT was performed only if intra-abdominal injury was suspected. Wound care was provided as necessary. Patients were discharged if the results of all CXRs and physical examinations were negative. All patients were telephoned on the day following the injury and given follow-up appointments in the trauma clinic.

Over 15 months, 116 asymptomatic patients with negative initial CXR were enrolled. Ninety-three were victims of stabbings, 23 were victims of gunshot wounds, and 22 sustained multiple penetrating injuries to the thorax. Two patients had a negative initial CXR, but demonstrated PTX on CT scan, and were dropped from the study. One patient had a negative initial CXR, but developed a PTX during the three-hour study and required tube thoracostomy. None of the remaining patients developed a PTX on the six-hour CXR. Six patients left against medical advice (AMA) prior to the completion of all three CXRs. Of these, two had follow-up with no sign of PTX and four patients were lost to any follow-up. Nine patients were admitted prior to the six-hour CXR, but all had negative in-house CXRs within 24 hours. Nine patients were discharged before the six-hour film, of which five had no problems on follow-up and four were lost to follow-up.

The authors conclude that the six-hour CXR offers no additional information that was not available from the three-hour CXR. They state that asymptomatic patients with negative initial and three-hour radiographs are safe for discharge.

COMMENT BY JACOB W. UFBERG, MD

This study seems to validate a rule that will reduce the length of stay for patients with seemingly minor penetrating torso trauma. It also will help reduce the number of patients who leave AMA prior to being "cleared" by serial radiographs. One drawback of this study is the number of patients who were lost to follow-up. The authors could not help that some of the patients left AMA; however, the study would have been "cleaner" had they not discharged nine patients prior to completion of the protocol (four of which were lost to follow-up). Furthermore, only one patient developed a CXR-detected PTX during the study period; is that sufficient to conclude the three-hour rule can replace the six-hour rule?

This is the second study examining the use of a three-hour CXR to rule out delayed PTX and hemothorax in asymptomatic patients with negative initial CXRs.[2] Both of these studies suggest that the three-hour film is as reliable as the six-hour film; however, the study by Kiev and Kerstein and the above-mentioned Kerr et al study (6-hour rule) eliminated patients with precordial and periclavicular wounds. This study does not specifically mention these cases (they state only that patients requiring immediate admission to the operating room or ICU were excluded), and we are left to wonder whether these patients underwent pericardial exploration for precordial wounds or angiography for periclavicular wounds. One question that remains to be answered is how long to observe and how best to manage the several asymptomatic patients in each study with a PTX visible only by CT scan. ❖

References

1. Kerr TM, et al. Prospective trial of the six hour rule in stab wounds of the chest. *Surg Gynecol Obstet* 1989; 169:223-225.
2. Kiev J, Kerstein MD. Role of three hour roentgenogram of the chest in penetrating and nonpenetrating injuries of the chest. *Surg Gynecol Obstet* 1992;175: 249-253.

Special Feature

Costochondritis: Take a Scientific Stand in the Emergency Department

By Michael Felz, MD

FEW COMPLAINTS ARE AS CHALLENGING AND COMPLEX for the emergency department (ED) physician as the evaluation of acute chest pain. Although the dramatic symptoms, ECG findings, and laboratory data in acute myocardial infarction (MI) often are straightforward, other pain syndromes may be poorly characterized, creating much diagnostic uncertainty. Costochondritis (CC) represents a surprisingly frequent cause of chest pain in the ED—one that often is not considered until other etiologies have been excluded. This review of the current literature is intended to place the entity of CC on firm scientific footing and in proper priority for physicians treating patients with acute chest pain.

Anatomic Considerations

The costal cartilages serve as elastic struts enabling compliant chest wall excursions during respiration and trunkal movement.[1] The first seven ribs articulate individually with the sternum, whereas ribs 8-10 share a conjoint anterior junction known as the costal arch.[2] Ribs 11 and 12 terminate freely in the upper abdominal wall. A closely applied collagenous perichondrium provides vascularity to these hyaline articulations. Most of the chest wall innervation derives from intercostal nerves.

Clinical Presentation and Pathogenesis

The dominant feature of CC is the demonstration of localized anterior chest wall pain at chondrosternal articulations that can be duplicated by focused palpation at the same sites. No soft-tissue swelling is evident. A similar but quite rare disorder, Tietze's syndrome (TS) is an inflammatory condition resembling CC in that localized chest pain is reproducible by the examiner, but soft tissue swelling also is present at the tender foci.[3] CC usually affects multiple sites, whereas TS is unifocal.

The etiology of CC may involve minor trauma that result in small tears in costosternal ligaments, as may be caused by coughing, sneezing, or excessive trunkal movements.[4] Others have documented rare occurrences of infection with *Staphylococcus*, *Streptococcus pneumoniae*, *Mycobacterium tuberculosis*, and *Candida* species.[5] TS, in contrast, has been linked to Coxsackie A and B viral infections. Biopsy studies from 24 cases of TS have revealed infiltration of lymphocytes, with pathologic changes not in cartilage but in surrounding soft tissues.[6]

Differential Diagnosis and Management

Both CC and TS must be distinguished from other causes of acute or recurrent anterior chest wall pain, such as trauma, pyogenic infection, osteomyelitis, herpes zoster, neoplasm, rheumatoid arthritis, and fibromyalgia. Even teenagers with tenderness in the thorax will elicit concern about "heart trouble" and require careful evaluation.[7] How can ED physicians accurately identify CC (or the more uncommon TS) in patients with acute chest pain? Without doubt, the first priority must be to consider MI or some other life-threatening cardiopulmonary condition. In an effort to stratify risk for coronary artery disease (CAD) syndromes, Lee and associates assessed 596 patients (average age 56 years) who presented with anterior chest pain to a Boston ED.[8] Parameters were clinical exam, ECG, enzymes, and technetium cardiac scanning. Final diagnoses included 104 patients (17%) with MI, 143 (24%) with unstable angina, and 349 (59%) with other disorders (including 158 patients with reproducible chest wall tenderness). They observed three statistically significant clinical predictors of low-risk status for CAD: sharp or stabbing

pain, absence of prior documented CAD, and pain reproduced by chest wall palpation or positional trunk movement.

In a study of 100 patients (mean age 51 years) with chest pain and previously normal coronary angiography, Wise and associates found 69% had tenderness of the neck, shoulder, or thorax, whereas 23% displayed tenderness of the costosternal region that reproduced pain symptomatology.[9] They concluded that chest wall palpation evoking typical chest pain symptoms is a common, specific finding in patients known to be free of CAD.

A prospective analysis of 122 patients with chest pain in a New York ED revealed a diagnosis of MI in seven (6%) patients compared to 36 (30%) found to have CC, of which 17 (15%) had tenderness, which precisely duplicated original symptoms.[10] Interestingly, the diagnosis of MI (28%) was far more frequent in a control population. The authors concluded that CC is a common etiology for acute chest pain in the ED and that such patients are distinguished by reproducible symptoms and a lower frequency of MI, despite similar risk factors.

Mukerji and colleagues studied 40 patients (average age 43 years) who had chest pain and normal coronary angiography, and found that 30% had fibromyalgia, 10% had CC, and 3% had rheumatoid arthritis.[11] This contrasted with 40 controls with proven CAD, of which one (3%) had fibromyalgia and none had CC. They emphasize, as do others,[12] that rheumatologic conditions are common in patients with angiographically normal coronary arteries. The frequency of simultaneous CC and CAD is rare (3-5%) according to two clinical series with a total of 916 patients.[4,8]

From the standpoint of a busy office, Klinkman and associates analyzed 399 outpatients with chest pain in a Michigan primary care research network and found relative frequencies of 20% for musculoskeletal conditions, 13% for gastroesophageal reflux disease, 13% for CC, 10% for stable angina, and only 1.5% for MI.[13] These diverse studies, all emphasizing the value of chest wall palpation, were further clarified and affirmed in a recent, extensive clinical review.[14] Finally, timely testing for troponin[15] and D-dimer[16] has been shown to be of considerable value for confirming or excluding acute CAD events in the ED and office settings.

Diagnostic confirmation of TS is possible by CT scanning of tender, swollen costochondral junctions. Findings include erosions, calcification, and subchondral sclerosis, and exclude similar disorders such as neoplasm, tuberculosis, and occult fracture.[17] CC has been reported in elderly males, with confirmation by gallium uptake,[18] and in postpartum females as confirmed by radionuclide bone scanning or SPECT imaging.[19]

Management of CC and TS usually centers on analgesics, local heat, and patient reassurance, although no placebo-controlled trials are available. One investigator has documented the utility of lidocaine and steroid injections for acute pain relief in TS, correlating with an 82% reduction in echogenicity and cartilage broadening by serial ultrasound assessment.[20] Historically, pain relief by local steroid injection was felt to have diagnostic value in excluding CAD.[4] Curiously, one 52-year-old patient has been described whose reproducible tenderness over the right 10th costochondral junction resolved with a shift in the beltline position of his beeper.[21]

Conclusions

Costochondritis is a far more common occurrence, by two- to 15-fold, than CAD events in the ED or office setting. Of all chest pain patients, 10-30% will be found to have CC or chest wall syndromes upon final diagnosis. Diagnostic certainty is enhanced by demonstration of precise replication of original symptoms by palpation. Non-evocative chest wall tenderness is a helpful but less specific finding and may be present in a minority (3-5%) of patients with underlying CAD. Normal ECG tracings and enzyme levels, especially if they span 4-6 hours, are helpful for exclusion of ischemic events in patients with presentations suggestive of CC, TS, or other atypical entities for chest pain.

My own anecdotal experience with roughly 200 patients thought to have CC is consistent with the published data regarding this common occurrence in acute chest pain patients, particularly young healthy females who fear a "heart attack." NSAIDs and heat seem to provide dependable pain relief within our academic family medicine practice. I am impressed with the frequency of reproducible chest wall tenderness among our primary care patients admitted from the office or ED for "rule out MI" protocols, in which the vast majority have CAD excluded. On about 10 occasions, I have injected tender costochondral junction regions with 2 cc of 1% lidocaine with gratifying, instant results in pain resolution and diagnostic confirmation.

Perhaps a memorable statement from 25 years ago pertains to ED management of CC today: "If local pressure applied to the anterior part of the chest wall becomes a routine procedure in the physical examination of all patients with precordial pain, a surprisingly large number of cases of costosternal syndrome will be discovered."[4] Sounds to me like a good place to start, and stand, in the ED. ❖

References

1. Chicarilli ZN, et al. Costochondritis: Pathogenesis, diagnosis, and management considerations. *Plast*

Reconstr Surg 1986;77:50-58.
2. Fam AG, Smythe HA. Musculoskeletal chest wall pain. *CMAJ* 1985;133:379-389.
3. Ontell FK, et al. The costal cartilages in health and disease. *Radiographics* 1997;17:571-577.
4. Wolf E, Stern S. Costosternal syndrome: Its frequency and importance in differential diagnosis of coronary heart disease. *Arch Intern Med* 1976;136:189-191.
5. Meyer CA, White CS. Cartilaginous disorders of the chest. *Radiographics* 1998;18:1109-1123.
6. Kayser HL. Tietze's syndrome. *Am J Med* 1956;21: 982-989.
7. Brown RT, Jamil K. Costochondritis in adolescents. A follow-up study. *Clin Pediatr* 1993;32:499-500.
8. Lee TH, et al. Acute chest pain in the emergency room. Identification and examination of low-risk patients. *Arch Intern Med* 1985;145:65-69.
9. Wise CM, et al. Musculoskeletal chest wall syndromes in patients with noncardiac chest pain: A study of 100 patients. *Arch Phys Med Rehabil* 1992;73:147-149.
10. Disla E, et al. Costochondritis: A prospective analysis in an emergency department setting. *Arch Intern Med* 1994;154:2466-2469.
11. Mukerji B, et al. The prevalence of rheumatologic disorders in patients with chest pain and angiographically normal coronary arteries. *Angiology* 1995;46: 425-430.
12. Ghaffari S. Detection and management of coronary artery disease in patients with rheumatologic disorders. *Rheum Dis Clin North Am* 1999;25:657-669.
13. Klinkman MS, et al. Episodes of care for chest pain: A preliminary report from MIRNET. *J Fam Pract* 1994;38:345-352.
14. Jouriles NJ. Atypical chest pain. *Emerg Med Clin North Am* 1999;17:717-731.
15. Ebell MH, et al. A systematic review of troponin T and I for diagnosing acute myocardial infarction. *J Fam Pract* 2000;49:550-556.
16. Bayes-Genis A, et al. D-dimer is an early diagnostic marker of coronary ischemia in patients with chest pain. *Am Heart J* 2000;140:379-384.
17. Jurik AG, et al. Radiographic findings in patients with clinical Tietze's syndrome. *Skeletal Radiol* 1987;16: 517-523.
18. Ikehira H, et al. Acute pan-costochondritis demonstrated by gallium scintigraphy. *Br J Radiol* 1999; 72:210-211.
19. Wadhwa SS. Anterior chest wall pain in postpartum costochondritis. *Clin Nucl Med* 1999;24:404-406.
20. Kamel M. Ultrasonographic assessment of local steroid injection in Tietze's syndrome. *Br J Rheumatol* 1997;36:547-550.
21. Kleinman I. Beeper costochondritis [letter]. *JAMA* 1992;267:56.

CME Questions

1. In the recent study by Le May, the reduction in composite end point that suggests clinical benefit for mechanical stenting compared to pharmacologic fibrinolysis was primarily due to:
a. significantly decreased rates of death in the stented group.
b. significantly decreased rates of reinfarction in the stented group.
c. significantly decreased rates of repeat target vessel revascularization for ischemia in the stented group.
d. decreased length of hospitalization in the stented group.

2. When performing procedural sedation in young children:
a. adverse events are common with midazolam.
b. pentobarbital should be administered as a rapid bolus of 5 mg/kg.
c. midazolam should be administered in increments of 0.05-0.1 mg/kg.
d. anesthetic agents are unnecessary for painful procedures.

3. In the study comparing the intubating laryngeal mask airway (ILMA) to direct laryngoscopy with respect to cervical spine excursion, it is important to remember:
a. ILMA outperformed direct laryngoscopy with regard to time.
b. ILMA outperformed direct laryngoscopy with regard to success rate.
c. aspiration was less likely with ILMA.
d. the cervical spine was not immobilized when excursion was assessed radiographically.

4. Repeat chest x-rays are recommended after penetrating injury to the torso because:
a. pneumothorax that was not seen on the initial film may develop.
b. aspiration pneumonia has been shown to rapidly develop in this population.
c. this is a reliable way to exclude solid abdominal organ penetration.
d. foreign bodies not seen in the initial trauma scout film may be detected.

5. In contrast to costochondritis, Tietze's syndrome:
a. is usually fatal.
b. is caused by atypical tuberculous strains.
c. may demonstrate focal soft-tissue swelling.
d. calls for prompt anti-staphylococcal antibiotic therapy.

6. The relative frequency of costochondritis compared to acute ischemic coronary events among patients with acute chest pain is:
a. equal to MI.
b. 2-15 times more frequent than MI.
c. one-tenth as frequent as MI.
d. not studied or published.

7. The most useful diagnostic maneuver(s) for confirmation of costochondritis in the ED is/are:
a. chest x-ray.
b. CBC and ESR.
c. reproducible tenderness over painful sites.
d. ECG evidence of slight ST elevation.

A Multi-Chambered Problem

By Ken Grauer, MD

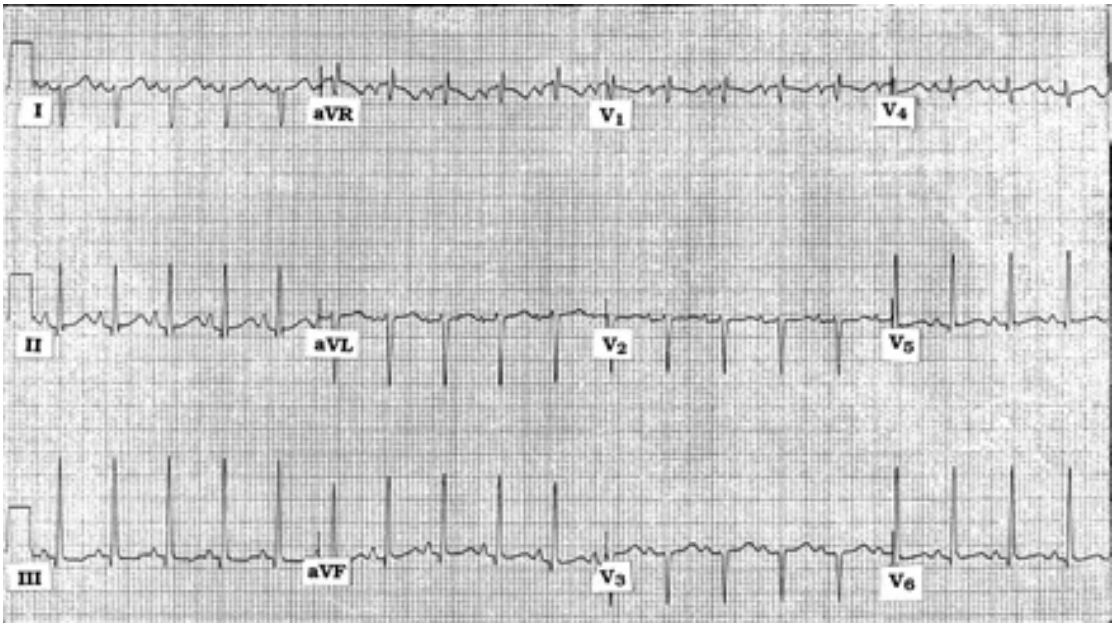

Figure. ECG obtained from a 60-year-old woman with shortness of breath.

Clinical Scenario: The 60-year-old woman whose ECG is shown in the Figure presented to the emergency department (ED) with shortness of breath. Can you guess why?

Interpretation: The rhythm is sinus tachycardia at a rate of 125 beats/min. The PR and QRS intervals are normal. The QT interval may be prolonged, although it is difficult to tell for sure given the rapid rate. Marked right axis deviation (RAD) is present, as determined by the predominantly negative QRS complex in lead I.

Regarding assessment for chamber enlargement (and the explanation of the title of this ECG Review, plus the answer to our clinical question)—we suspect that this patient has *four*-chamber enlargement. The tall peaked (pointed) P wave in standard lead II suggests right atrial enlargement (RAE). The notched P wave in lead I and the fairly deep (albeit pointed) negative component to the P wave in lead V_1 suggests that there also may be left atrial enlargement (LAE). The surprisingly tall R wave in lead V_6 (that exceeds 18 mm) is a less commonly invoked voltage criterion for left ventricular hypertrophy, but one that is probably accurate given the overall clinical picture. Finally, we suspect right ventricular hypertrophy (RVH). Admittedly, QRS morphology in standard leads I, II, and III is consistent with left posterior hemiblock. However, the constellation of RAD, RAE and an rSr' pattern in lead V_1 is better explained by proposing RVH.

Possible explanation for this patient's dyspnea (in view of the ECG findings of sinus tachycardia and four-chamber enlargement) include heart failure from dilated congestive cardiomyopathy and/or pulmonary hypertension from pulmonary emboli or end-stage pulmonary disease. Despite predominant negativity in lead I of this tracing, the reasons we *don't* suspect lead misplacement or dextrocardia here include: 1) that a small positive deflection (r wave) is seen in lead I of this tracing; 2) both the P wave and T wave are upright in lead I here; 3) an upright P wave is seen in lead II; and 4) there is normal R wave progression in the precordial leads. ❖

In Future Issues: What's New in Antibiotic Therapy for Otitis Media?

AMERICAN HEALTH CONSULTANTS®

Supplement to
Emergency Medicine Alert June 2001

EMERGENCY MEDICINE ALERT®

An essential monthly update of developments in emergency medicine

From the Publishers of Emergency Medicine Reports™

CUMULATIVE INDEX

Volume 7, Numbers 1-12, Pages 1-96

June 2000-May 2001