AMERICAN HEALTH CONSULTANTS®

Primary Care Reports™

The Practical, Peer-Reviewed Journal for Primary Care and Family Physicians

Volume 7, Number 10 **May 14, 2001**

Ankle Sprains: What to Do and What Else to Look For

Authors: **Robert C. Schenck, Jr., MD**, Professor and Division Chief, Sports Medicine Division, Department of Orthopaedic Surgery and Rehabilitation, University of New Mexico Health Science Center, Albuquerque, NM; and **Michael J. Coughlin, MD**, Clinical Professor, Division of Orthopaedics and Rehabilitation, Oregon Health Science Center, Portland, Ore.

Editor's Note—*Ankle sprains are a commonplace injury with approximately 27,000 occurring per day in the United States.[16] Although the diagnosis is usually straightforward and, with appropriate treatment, resolution of symptoms rapid, the clinician should learn to suspect other conditions that can mimic the garden variety ankle sprain. Furthermore, the indications for radiographic evaluation have been well defined and are dependent upon functional and physical evaluations.[2,6,18,20] Treatment primarily involves symptomatic measures with physical agents (ie, ice), judicious use of nonsteroidal anti-inflammatory drugs (NSAIDs), functional bracing (ie, Air-Stirrup® ankle brace, Aircast® , Inc., Summit, NJ), and functional exercises.[1,3,8,10-12,14,15,17,18] Lastly, it is when the patients' symptoms do not resolve by 4-6 weeks that the clinician should use a careful repeat physical examination, repeat plain radiographs, and consider additional imaging techniques such as scintigraphy.[2] This monograph will discuss in detail the diagnosis (and most common differential), treatment, and reevaluation of the commonly occurring ankle sprain. Finally, a brief description of surgical reconstructions for the patient with recurrent ankle instability will be presented.[5-7]*

Anatomy

The ankle joint is a mortise and tenon shaped articulation involving the talus articulating in a mortise created by the distal tibia and fibula. Ligamentous support of the talus in the ankle mortise (tibia and fibula) is created laterally by the anterior talofibular ligament (ATFL), calcaneofibular ligament (CFL), and posterior talofibular ligament (PTFL). Classically, ankle sprains involve injury to the ATFL and CFL, with the PTFL being rarely injured and an infrequent clinical presentation for ankle sprains. Medially, the deltoid ligament creates ligamentous support with both superficial and deep portions. Ankle sprains involving the deltoid ligament are also less common than the classic and more common injury to the ankle mortise involving the tearing of the ATFL and CFL. Lastly, the ankle mortise has strong ligamentous attachments between the tibia and fibula, namely the syndesmosis ligaments. Injury to the syndesmosis ligaments are less commonly seen, are classified as high ankle sprains, and are frequently more difficult to diagnose and treat than injuries to the lateral ankle ligaments.

Injury and Diagnosis

The ankle sprain (again, sprain = partial ligament tear, strain = partial tear of a musculotendinous unit; simple mnemonic device is the "T" in strain implies tendon) occurs most commonly related to an ankle inversion injury; however, many patients are unable to remember the ankle position at the time of injury. It is a useful sports medicine evaluation

technique to have the athlete describe the injury as if they were watching it on film. It allows the clinician to thoroughly understand the mechanism and in turn aid the clinician in making the correct diagnosis. For example, a foot and ankle injury that is plantar flexed and suffering an axial load (as if landing on "tip toes") will more commonly be associated with an injury to the tarsometatarsal joints (Lisfranc injury) than an ankle sprain. Inversion injury, or when the patient rolls the ankle, is the most common mechanism of ankle sprains and is useful information. Finally, in any sports evaluation, direct questioning of previous injuries and diagnoses will often simplify the diagnosis. Athletes' comments such as, "this feels just like my previous sprains" is useful for the clinician. Similarly, the athlete noting that "this one feels different" is information that should alert the clinician for thinking beyond the typical injury to the ATFL or CFL.

Classification of ankle sprains can be confusing as varying descriptions are used to describe injury patterns. However, 2 classification systems are routinely used. The first is that created by the American Medical Association (AMA) involving 3 grades or degrees of injury. The AMA system specifically identifies the severity of injury to the ligament and is in 3 grades.[23] A grade I ankle sprain involves microscopic tearing of the ligament with normal gross and functional evaluation of the ligament. The grade II ankle ligament sprain involves partial tearing of the ligament such that if gross inspection were performed, partial tearing of the ligament would be seen. Likewise, functional evaluation of the injury reveals partial functional loss but without evidence of gross disruption. Lastly, a grade III ligament sprain involves complete tearing of the ligament with complete loss of function of the ligament. This system is used in ligament injuries about any joint. With respect to the ankle specifically, such a system is difficult to apply. A clinically oriented classification system, such as that described by Jackson and colleagues, is more useful and is as follows: Grade I (mild sprain) is an intraligamentous tear with minimal swelling and tenderness, no instability, and minimal disability. Grade II (moderate ankle sprain) is an incomplete ligament tear with moderate ankle pain and swelling. Patients can walk after a grade II injury, but with appreciable disability or limp. Grade III sprains are complete ruptures with marked pain and swelling and an inability to walk without assisting devices. When describing a grade III injury to the lateral ligamentous structures of the ankle, complete tearing of the ATFL and CFL are implied and will usually present with gross swelling.[22,24] In practical application, the clinically oriented system is most useful in the evaluation and grading of ankle sprains.

Physical examination is extremely useful. However, in any musculoskeletal examination, the use of a functional examination is of primary importance. Use of history and functional examination followed by physical examination was first described by Liorzou in evaluation of the knee and is easily applied to any injury.[25] Observation of the patient's gait (if possible) requires an extra step in the evaluation process, but seeing the athlete walk normally vs. the patient being unable to bear weight gives the clinician extremely valuable information with respect to severity of injury and need for radiographic evaluation. Obviously, the clinician should use common sense in considering evaluation of gait in any acute injury to avoid displacement or worsening of an already present fracture. Nonetheless, patients frequently present ambulating after an ankle sprain, and evaluation of that gait, normal or abnormal is important in determining the need for plain radiographs as outlined below. Physical examination including observation, palpation, and ligamentous evaluation is the final layer of information to make 95% of all diagnoses about the ankle.[2] Asking the patient to "point with one finger where it hurts the most" is a useful technique that directs the clinician where to examine last. Presence of tenderness along the distal fibula, ATFL, CFL, deltoid ligament (less common), lateral process of the talus, base of the 5th (Jones fracture) or 2nd (Lisfranc sprain) metatarsals, and any anatomic area with overlying swelling will make clinical diagnoses based upon anatomy straightforward. A globally swollen ankle is one of great concern and implies a grade III ankle sprain and/or continued activity on an injured joint. Careful evaluation to rule out a syndesmosis sprain ("high ankle sprain") is important in the thorough evaluation of an ankle injury. Clinical findings suspicious for a syndesmotic sprain include: 1) syndesmosis tenderness; 2) pain on external rotation of the ankle on the leg; and 3) tenderness when compressing the tibia and fibula at mid-leg level, a so called, "positive squeeze test." In contrast to the treatment of the commonly seen lateral ligamentous injuries of the ankle, syndesmotic sprains are treated with initial nonweightbearing and have a slower course of recovery than the standard inversion ankle sprain with injury to the ATFL and CFL.

***Primary Care Reports*™**, ISSN 1040-2497, is published biweekly by American Health Consultants, 3525 Piedmont Rd., NE, Bldg. 6, Suite 400, Atlanta, GA 30305.

VICE PRESIDENT/GROUP PUBLISHER: Donald R. Johnston.
EDITORIAL GROUP HEAD: Glen Harris.
MANAGING EDITOR: Robin Mason.
ASSOCIATE MANAGING EDITOR: Neill Larmore.
SENIOR COPY EDITOR: Robert Kimball
MARKETING PRODUCT MANAGER: Schandale Kornegay.
GST Registration Number: R128870672.
POSTMASTER: Send address changes to ***Primary Care Reports*™**, P.O. Box 740059, Atlanta, GA 30374.

Periodical rate postage paid at Atlanta, GA.
Back issues: $23. Missing issues will be fulfilled by Customer Service free of charge when contacted within one month of the missing issue's date.

AMERICAN HEALTH CONSULTANTS™
THOMSON HEALTHCARE

Subscriber Information

Customer Service: 1-800-688-2421.

E-Mail Address: customerservice@ahcpub.com
Editorial E-Mail Address: robin.mason@ahcpub.com
World-Wide Web: http://www.ahcpub.com

Subscription Prices

United States
$299 per year (Student/Resident rate: $150).

Multiple Copies
1-9 additional copies: $269 each; 10 or more copies: $239 each.

Canada
Add GST and $30 shipping

Elsewhere
Add $30 shipping

For 50 AMA/AAFP Category 1/Prescribed hours, add $100.

Accreditation

American Health Consultants (AHC) designates this continuing medical education (CME) activity for up to 50 hours in Category 1 credit toward the AMA Physician's Recognition Award. Each physician should claim only those hours of credit that he/she actually spent in the educational activity.

AHC is accredited by the Accreditation Council for Continuing Medical Education (ACCME) to provide CME for physicians.

This CME activity was planned and produced in accordance with the ACCME Essentials.

This program has been approved by the American Academy of Family Physicians as having educational content acceptable for Prescribed credit hours. Term of approval covers issues published within one year from the beginning distribution date of Jan. 1, 2001. This volume has been approved for up to 50 Prescribed credit hours. Credit may be claimed for one year from the date of this issue.

Questions & Comments

Please call **Robin Mason,** Managing Editor, at (404) 262-5517 or e-mail: robin.mason@ahcpub.com between 8:30 a.m. and 4:30 p.m. ET, Monday-Friday.

Statement of Financial Disclosure

In order to reveal any potential bias in this publication, we disclose that Dr. Schenck is on the speaker's bureau of Nutramax Laboratories, Inc., in Edgewood, Md.

Functional evaluation of ankle ligaments involves the anterior drawer (testing the ATFL) and varus stress (testing the CFL). Varus stress testing is performed by placing the heel of the injured foot/ankle, placing a varus stress, and comparing to the opposite side. The acute evaluation of a sprained ankle frequently allows modification of testing due to pain and swelling, but usually a gentle drawer test can be performed at the time of initial presentation. However, clinical discretion is necessary and in the swollen and painful acute injury, delay of the drawer/varus stress tests and reevaluation in 7-10 days can be useful. The drawer and varus stress tests become extremely useful in the recurrent unstable ankle and should always be compared to the normal side.[7]

The indications for plain radiographs have been defined by Canadian investigators and are referred to as the Ottawa rules. Need for plain radiographs are indicated when there is bony tenderness of the fibula, the patient is unable to bear weight on the injured extremity, and gross swelling or obvious deformity is present.[21] The first 2, bony tenderness and ability to bear weight, are very useful components of the rules and the absence of which should be documented any time x-rays are not obtained. The need for 3 views of the ankle (anteroposterior [AP], mortise [slight internal rotation from the AP view], and lateral) has recently been questioned. Some authors advocate only a mortise and lateral view; however, in my clinical practice, 3 views are routinely obtained. It is essential that radiographs are obtained in 2 planes and include a lateral x-ray.[2] Presence of avulsion fractures of the tip of the fibula are of little clinical relevance but should be explained carefully to the patient. Inspection for osteochondral injuries of the talar dome (most commonly the anterolateral talar surface), fractures of the fibula, and any shift of the talus under the tibial plafond should alert the clinician for consultation with an orthopaedist. Recently, I was evaluating a lineman complaining of an ankle injury during a critical football game. Using the Ottawa rules of direct tenderness of the fibula and an inability to walk were useful clinical indicators to me that radiographs were needed. These films revealed a supination external rotation, stage II (SER II, which implies nonoperative treatment) fracture, which was treated effectively with casting and supported my decision to obtain an x-ray (*see Figures 1A & 1B*).

Lastly, the clinician should understand that ankle radiographs involve only the ankle and not the foot. Pain, swelling, or tenderness about the foot requires a separate radiographic evaluation that is not included when ordering ankle films. In such scenarios, one should order 3 views of the foot *and* ankle to evaluate the injured extremity. The use of stress radiographs are rarely needed in the evaluation of an acute injury but are routinely used in the evaluation of recurrent instability in an attempt to document the presence of tibiotalar or subtalar subluxation giving direct evidence of chronic injury to the ATFL and CFL.[4-7]

Treatment

The routine ankle sprain with bony tenderness requires radiographic evaluation, but once radiographs are negative

Figure 1A. Bony Tenderness/Ankle Fracture

Anteroposterior radiograph of patient and division I football player JL with a fracture of the distal fibula classified as supination eversion rotation II (SER II).

Figure 1B. Bony Tenderness/Ankle Fracture

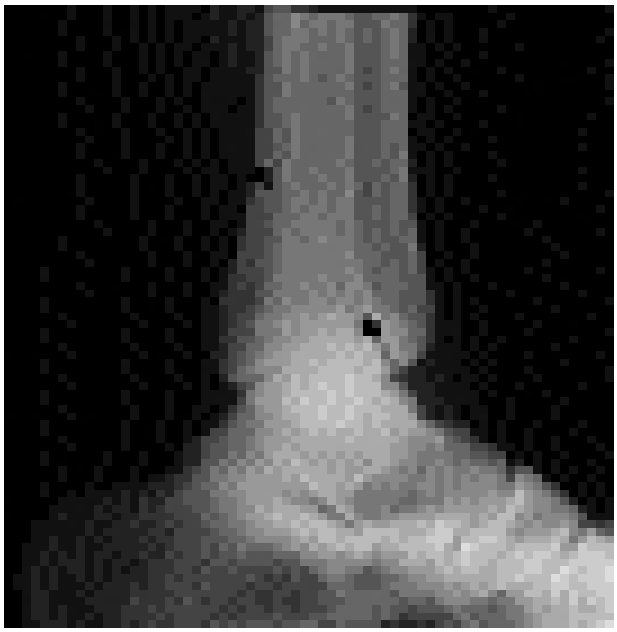

Lateral radiograph of same patient revealing a reduced joint on the fibular fracture. Patient was treated with casting (initially nonweightbearing, followed by a weightbearing walker) with uneventful healing and return to functional activities.

for fracture, treatment involves the institution of functional rehabilitation. Indications for surgery after an acute ankle sprain are rarely present, as most clinical trials evaluating casting vs. functional bracing vs. surgery have favored functional bracing (surgery has an increased number of wound complications and joint stiffness as compared to functional bracing).[14] Nonetheless, short-term casting for the grade III ankle sprain (ie, complete ruptures of the ATFL and CFL) is recommended by many and should be given as an option to the patient. As a note, most athletes are resistant to the use of a cast for treatment, but in the clinical scenario of a grade III ankle sprain with global swelling, in my experience, short-term casting up to 2-3 weeks will decrease the time of functional disability and should be recommended.

Most authors recommend initial nonoperative management of the routine sprained ankle, be it compressive wraps, functional ankle stirrup, or casting.[1,2,5,8,10-12,14,15,18,21] Initial use of the mnemonic RICE (Rest, Ice, Compression, and Elevation) in any acute injury, and especially in the sprained ankle is very useful. RICE is an excellent starting point for the treatment of the sprained ankle. In my experience, functional bracing to allow early return to weightbearing is critical and, when combined with compressive icing (ie, ice with ace wrap), quickly reduces swelling, pain, and functional disability. Clearly, initial crutch ambulation is useful to allow progressive weightbearing and should be used during the first 72 hours. In several clinical studies in sports medicine, early range of motion and weightbearing provides for improved ligament healing and decreased atrophy as compared to immobilization and nonweightbearing. Furthermore, prolonged crutch use is nonfunctional, creates muscle atrophy and osteopenia, and should be avoided if possible. Obviously, functional exercises (functional usually implying closed kinetic chain or weightbearing exercises) are predicated on the diagnosis and *clear exclusion* of a fracture or intra-articular abnormality. In addition to a quick return to a normal gait, compressive icing 3 times a day (20 minutes on/20 minutes off/avoiding thermal injury to skin) and once before bedtime aids in the recovery of joint function and ligamentous healing. Use of icing before bedtime aids in pain control and allows for better sleep, and it is very useful to instruct patients on this technique. Use of NSAIDs for additional pain control and down regulation of inflammation and swelling can aid in recovery. Ibuprofen, 800 mg, 3 times a day consistently for 7-10 days is very useful to aid in recovery without significant expense. Careful patient education of the risks of NSAIDs is critical for the safe usage of such medications even in the healthy 20-year-old athlete. It should be emphasized to the athlete, barring any GI distress with the medication, to be compliant with the prescription.

Most authors note functional instability occurring in only 5-20% of patients after initial conservative treatment.[3-7,9] Initial nonoperative treatment includes physiotherapy to improve eversion strength of the ankle as well as affected ankle joint proprioception. Use of the Biomechanical Ankle Platform System (BAPS) balance board, as well as other proprioceptive devices and sports specific exercises, is the final stage to return to sport. The use of ankle taping (but more commonly an ankle stirrup support) allows for early return to sport or functions such as work (*see Figure 2*).[2,21]

Figure 2. Functional Ankle Brace

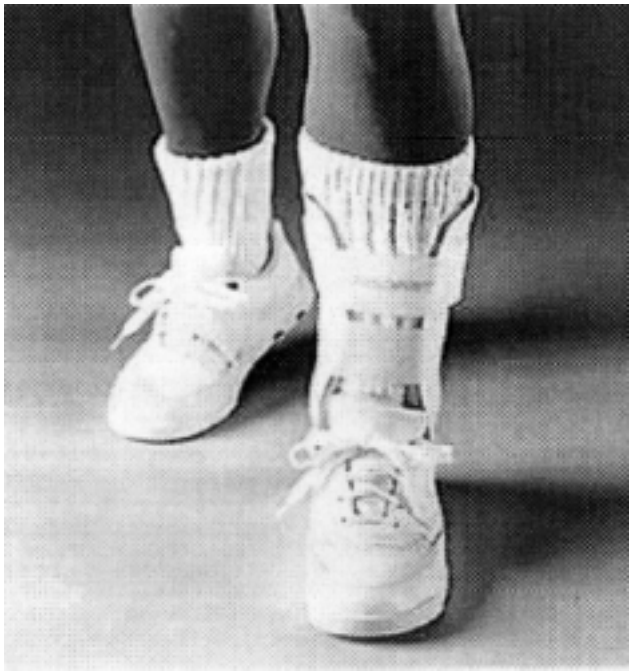

Air-Stirrup® ankle brace as applied to patient and can be worn with patient shoe to allow for functional use.

Occasionally, the patient with a suspected ankle sprain will return for evaluation after continued pain and swelling noting incomplete relief with functional treatment and nonoperative means. In such complaints, the clinician must carefully reevaluate his or her initial diagnosis and look carefully for other diagnoses. The most commonly associated and overlooked injuries involve the following:

1. Lateral process fracture of the talus (look for lateral talar tenderness and carefully inspect plain radiographs).
2. Syndesmosis sprain or high ankle sprain. Clinical examination with syndesmosis tenderness, pain on external rotation of the ankle in the mortise, and a positive squeeze test. Radiographs are inspected for any widening of the ankle mortise on weightbearing views. This injury can have a prolonged recovery course and may involve MR evaluation.
3. Osteochondral injury of the talar dome (look for an ankle joint effusion and carefully repeat plain radiographs and compare to the initial films if available).
4. Jones fracture of the base of the 5th metatarsal (bony tenderness anatomically and presence of a fracture line at the tuberosity). Foot radiographs!
5. Lisfranc injury or tarso-metatarsal sprain (tenderness at the base of the 2nd metatarsal, requires comparison *weightbearing* AP, oblique and lateral foot radiographs).
6. Deltoid ligament injury.
7. Nonspecific synovitis usually involving the anterolateral gutter.
8. Undiagnosed ankle mortise fracture (bony tenderness at the fibula or medial malleolus with associated findings on plain radiographs).[24]

Figure 3A. Stress Radiographs

Anteroposterior stress radiograph showing abnormal varus tilt of both the tibiotalar and subtalar joints in the patient LG presenting with longstanding ankle instability and multiple ankle sprains. Note increased joint opening at the lateral edge of the tibiotalar joint.

Figure 3B. Stress Radiographs

Lateral stress radiographs showing abnormal anterior translation of the talus on the tibia as a result of a nonfunctional ATFL, radiographically documenting what is palpated on the anterior drawer test in patient LG. Any stress radiograph requires comparison to the normal side to evaluate for physiologic joint laxity or looseness.

Figure 3C. Magnetic Resonance Imaging

Magnetic resonance imaging revealing a medial talar osteochondral lesion as well as a large joint effusion in patient LG. The complete MR evaluation revealed a large loose body and incompetent ATFL and CFL.

Figure 3D. Ankle Reconstruction for Instability

Diagram illustrating drill holes for anatomic recreation of the ATFL, with the gracilis tendon routed through tunnels as performed in patient LG. Additionally, patient underwent arthroscopic drilling of the medial talar osteochondral lesion and removal of the loose body. Short-term postoperative immobilization is required in a short leg cast followed by physiotherapy. Patient LG has since returned to functional activities with restoration of ankle stability.

Despite the careful re-evaluation and repeat normal radiographs, the diagnosis frequently is still in question and ancillary studies are required. Although the patient is usually more familiar with magnetic resonance imaging (MRI), the variability of a radiologist's reading of an MRI, the need to MRI scan the foot and ankle, the lack of comparison views, and cost, make bone scintigraphy (bone scan) a useful technique and, in my clinical practice, is obtained first in such a diagnostic dilemma. MRI very well may be required, but as a useful screening test for continued symptoms after a "supposed ankle

sprain," bone scanning is an ideal and inexpensive test that provides comparison views of the normal uninjured side.[2] Nonetheless, MRI is useful in evaluating a specific site such as the ankle joint when localization of the injury is clear. Evaluation of ligaments, osteoarticular injury, and surrounding soft tissues are best evaluated with MRI. Thus, bone scan should be used for general screening when the diagnosis is unclear, and MRI should be used for careful evaluation of the ankle joint itself.

The patient who presents late with recurrent instability episodes is one who is usually considered for reconstructive surgery.[3,-7,9,13] Clinical findings of increased anterior drawer and inversion stress testing documenting degree of joint opening on comparison stress radiographs confirm abnormal joint laxity and are important findings in the consideration for surgical treatment. It is in these patients that, in addition to stress radiographs, MRI is useful to evaluate osteochondral surfaces, loose bodies, joint status in general, and presence or absence of the ATFL and CFL.

Despite continued attempts at physical therapy and functional bracing, surgery is occasionally required and various surgical techniques are noted in a review of orthopaedic literature.[2-7,9,13] Reconstruction of the unstable ankle involves the combination of various techniques, most commonly that of nonaugmented (modified Bröstrom, tightening the capsular ligaments that are present)[3] and augmented reconstructions (recreating the ligaments with a portion of a tendon) frequently using the peroneus brevis.[5] Recent advances in the surgical ligament augmentation of ankle instability have included both a more anatomic graft placement as well as avoiding a tenodesis effect of the subtalar joint and avoidance of the peroneus brevis as a graft source.[9,7,13] Unfortunately, most studies use a portion of the peroneus brevis to provide graft augmentation, which inherently weakens ankle eversion as well as potentially limiting subtalar motion.[4,6] In Bröstrom's original description, later modified by Gould, a midsubstance repair of the free ends of the ATFL is performed either in the acute or chronic injury.[3]

Anatomic reconstructions for ankle instability using tissue augmentation has gained recent popularity. Coughlin, Paterson, and others have used a portion of the hamstring tendon to reconstruct anatomically the ATFL and CFL.[7,13] This avoids the difficulties associated with nonanatomic reconstructions using a tenodesis of the peroneus brevis. This also avoids the weakening of the ankle evertors by leaving the peroneus brevis unharmed. The most recent generation of ankle ligamentous reconstruction involves a free tendon graft, including the gracilis tendon (*see Figures 3A, 3B, 3C, & 3D*).[7]

Summary

Ankle sprains are commonplace and straightforward in management with successful results with simple functional treatment including weightbearing, ankle support/stirrup, and icing. Nonetheless, clinical experience and a careful examination will aid in the overall management of foot and ankle injuries. Observation of functional ambulation and the presence of bony tenderness are useful indicators of a need for an x-ray. Palpation of the foot and ankle will direct evaluation to areas other than the ankle per se. Remembering that foot radiographs may be needed in addition to ankle films is critical to avoid a misdiagnosis. Patients not responding to initial functional treatment should undergo repeat radiographic evaluation and even bone scintigraphy (bone scan) as dictated clinically. Surgery for ankle sprains is rarely indicated and then only with recurrent functional instability. The modified Bröstrom procedure or ligamentous augmentations for the ATFL and CFL provide reliable success in those patients failing conservative treatment.

Acknowledgement

The authors would like to acknowledge Sandy Mosher for the assistance in preparation of this manuscript.

References

1. Alves JW, Alday RV, Ketcham DL, et al. A comparison of the passive support provided by various ankle braces. *J Orthop Sports Phys Ther*. 1992;15(1):10-18.
2. Bergfeld JA, et al. Symposium: Management of acute ankle sprains. *Contemporary Orthopedics*. 1986;13(3): 83-116.
3. Bröstrom L. Sprained ankles. V. Treatment and prognosis in recent ligament ruptures. *Acta Chir Scandinavica*. 1966;132:537-550.
4. Chrisman OD, Snook GA. Reconstruction of lateral ligament tears of the ankle: An experimental study and clinical evaluation of seven patients treated by a new modification of the Elmslie procedure. *J Bone Joint Surg Am*. 1969; 51(5):904-912.
5. Colville MR. Reconstruction of the lateral ankle ligaments. *J Bone Joint Surg Am*. 1994;76A:109-110.
6. Colville MR, Marder RA, Zarins B. Reconstruction of the lateral ankle ligaments. A biomechanical analysis. *Am J Sports Med*. 1992;20:594-600.
7. Coughlin MJ, Schenck Jr RC. Lateral ankle reconstruction: Technique tip. *Foot Ankle Int*. In press.
8. Elff PM, Smith AT, Smith GE. Early mobilization versus immobilization in the treatment of lateral ankle sprains. *Am J Sports Med*. 1994;22(1):83-88.
9. Elmslie RC. Recurrent subluxation of the ankle joint. *Ann Surg*. 1934;100:364-367.
10. Klein J, et al. Functional treatment with a pneumatic ankle brace versus cast immobilization for recent ruptures of the fibular ligament in ankle. *Unfallchirurg*. 1991;94:99-104.
11. Konradsen L, Holmer P, Sondergaard L. Early mobilizing treatment for grade III ankle ligament injuries. *Foot Ankle Int*. 1991;12(2):69-73.
12. Leanderson J, Wredmark T. Treatment of acute ankle sprain: Comparison of a semi-rigid ankle brace and compression bandage in 73 patients. *Acta Orthopaedica Scandinavica*. 1995;66(6):529-531.
13. Paterson R, et al. Reconstruction of the lateral ligaments of the ankle using semi-tendinosis graft. *Foot Ankle Int*. 2000;21:413-419.
14. Povacz P, et al. A randomized prospective study of operative and nonoperative treatment of injuries of the fibular collateral ligaments of the ankle. *J Bone Joint Surg Am*.

1998;80(3):345-351.
15. Raerny H, Jakob RP. Functional treatment of fresh fibular ligament lesions using the Aircast Ankle Brace. *Swiss J Sports Med*. 1983;2(31):53-57.
16. Renstrom P. Persistently painful sprained ankle. *J Am Acad Orthop Surg*. 1994;2:270-280.
17. Rettig AC, Kraft DE. Treat ankle sprains fast—It pays. *Your Patient & Fitness*. 1991;4(4):6-9.
18. Sitler M, et al. The efficacy of a semirigid ankle stabilizer to reduce acute ankle injuries in basketball. *Am J Sports Med*. 1994;22(4):454-461.
19. Sommer HM, Schreiber R. Early functional conservative therapy of a fresh fibular rupture of the capsular ligament from a socioeconomic point of view. *Sportverletz Sportschaden*. 1993;7:40-46.
20. Stiell IG, et al. Implementation of the Ottawa ankle rules. *JAMA*. 1994;271(11):827-832.
21. Stover CN. Air-stirrup management of ankle injuries in the athlete. *Am J Sports Med*. 1980;8(5):360-365.
22. Jackson DW, Ashley RL, Powell JW. Ankle sprains in young athletes: Relation of severity and disability. *Clin Orthop*. 1974;101:201-215.
23. Standard nomenclature of athletic injuries. In: *Report of the Committee on the Medical Aspects of Sports*. Chicago, Ill: American Medical Association; 1966.
24. Clanton TO. Athletic injuries to the soft tissues of the foot and ankle. In: Coughlin MJ, Mann RA, eds. *Surgery of the Foot and Ankle*. 7th ed. St. Louis, Mo: Mosby; 1999.
25. Liorzou G, Finlayson D. *Knee Ligaments: Clinical Examination*. Berlin, Germany: Springer-Verlag; 1991.

Physician CME Questions

41. The most commonly injured ligament in ankle sprains is:
    a. the deltoid ligament.
    b. the calcaneofibular ligament.
    c. the anterior tibiofibular ligament.
    d. the anterior talofibular ligament.

42. Radiographs are indicated in the evaluation of ankle sprains for which of the following reasons?
    a. Swelling
    b. Inability to bear weight and/or bony tenderness
    c. Severe tenderness
    d. Positive anterior drawer

43. Routine ankle sprains should be treated initially with:
    a. rest, ice, compression, elevation.
    b. functional weight bearing.
    c. ankle stirrup brace.
    d. crutches and elevation.

44. Surgery in the treatment of ankle sprains:
    a. is never indicated.
    b. is more commonly used than casting.
    c. is used only in chronic conditions.
    d. has a higher complication rate than bracing.

45. Instability is best documented by history, physical examination, and:
    a. magnetic resonance imaging of the ATFL.
    b. anterior drawer testing.
    c. stress x-rays.
    d. anterolateral pivot shift.

46. Classification of ankle sprains is best made by:
    a. AMA guidelines of ligamentous injury.
    b. clinically based, dependent upon the ability to walk.
    c. degree of ankle joint opening on stress examination.
    d. variation by 3 grades or degrees.

47. In re-evaluating the ankle sprain where treatment has not resolved symptoms, which of the following is the best ancillary test for further evaluation?
    a. Stress radiographs
    b. Magnetic resonance imaging of the ankle
    c. Three-phase bone scan
    d. Thermography

Attention Subscribers. . .

A special supplement to *Primary Care Reports* titled "Antibiotics Anonymous Redux" is included with this issue, as a bonus to our subscribers. The supplement takes a tongue-in-cheek look at a problem facing many physicians: over-prescription of antibiotics. Here is an editorial note from Stan Deresinski, MD, editor of *Infectious Disease Alert*:

The problem of antibiotic resistance continues to worsen. An important contribution to this problem is the inappropriate prescription of antibiotics by physicians. For example, excess prescription of antibiotics for respiratory tract infections, particularly in children, has been identified as an important factor in the emergence of penicillin-resistant *Streptococcus pneumoniae*. Indeed, it has been suggested that some physicians have lost control over their antibiotic prescribing—that they have become, in effect, antibiotic dependent. I have, as a consequence, devised a questionnaire for the diagnosis of this dreaded addiction afflicting practicing physicians. If the answer to one or more of these questions is yes, you have a problem!

Attention *Primary Care Reports* Subscribers

No one knows the clinical information and analysis that primary care physicians want and need as much as readers of *Primary Care Reports*. To tap into that expertise, we are happy to announce that we are opening up our monograph selection process to our readers.

Monographs range from 25-35 Microsoft Word document, double-spaced pages. Each article is thoroughly peer reviewed by colleagues and physicians specializing in the topic being covered. Once the

idea for an article has been approved, deadlines and other details will be arranged. Authors will be compensated upon publication.

As always, we are eager to hear from our readers about topics they would like to see covered in future issues. Readers who have ideas or proposals for future single-topic monographs can contact Managing Editor Robin Mason at (404) 262-5517 or (800) 688-2421 or by e-mail at robin.mason@ahcpub.com.

Readers are Invited. . .

Readers are invited to submit questions or comments on material seen in or relevant to *Primary Care Reports*. Send your questions to: Robin Mason, *Primary Care Reports*, c/o American Health Consultants, P.O. Box 740059, Atlanta, GA 30374. For subscription information, you can reach the editors and customer service personnel for *Primary Care Reports* via the internet by sending e-mail to robin.mason@ahcpub.com.

In Future Issues:

RU 486 for Primary Care Providers—
Mark Nichols, MD

Antibiotics Anonymous Redux*

By Stan Deresinski, MD, FACP, Editor, Infectious Disease Alert

Are *You* Antibiotic Dependent?

- ❑ Do you prescribe antibiotics to relieve tension?
- ❑ Do you prescribe antibiotics more than other physicians but are able to hide it?
- ❑ Do you sometimes feel guilty about the way you prescribe antibiotics?
- ❑ Do you have a strong urge to prescribe antibiotics at a particular time of day?
- ❑ Have you lost ambition since you began prescribing antibiotics in this way?
- ❑ Has another physician advised you to stop or cut down your prescribing?
- ❑ Are you harder to get along with when you are heavily prescribing?
- ❑ Have you ever tried to cut back?
- ❑ Do you have difficulty sleeping a full night?
- ❑ Have you ever been in trouble with the antibiotic police?
- ❑ Have you ever done anything while prescribing that you don't remember (have a blackout)?
- ❑ Have you ever promised yourself you would cut back on your prescribing and then broken that promise?
- ❑ Have you ever tried to convince people that you were not prescribing antibiotics when you were?
- ❑ Do you wish people would mind their own business about your antibiotic prescribing—that they stop telling you what to do?
- ❑ Have you ever switched from one kind of antibiotic to another in the hope that this would keep you from going over the edge?
- ❑ Have you had to have an eye-opener (ie, prescribed an antibiotic immediately upon awakening, in the last year)?
- ❑ Do you envy people who can prescribe antibiotics without getting into trouble?

For those who have answered yes to one or more of these questions, I have begun the development of a 12-step program. But I am only halfway there.

- ❑ You must admit that you are powerless over your antibiotic prescribing.
- ❑ You must believe that a power (an antibiotic guru) greater than yourself can restore you to sanity.
- ❑ You must make a decision to turn your will and life over to the care of that power.
- ❑ You must make a searching and fearless moral inventory of yourself.
- ❑ You must admit to the power and to yourself the exact nature of your misprescribing.
- ❑ You must humbly ask the power to remove your antibiotic shortcomings.

* *Lockwood WR. Letter: Antibiotics anonymous. N Engl J Med 1974;290:465-466.*