AMERICAN HEALTH CONSULTANTS®

Rapid Access Card Enclosed

Enclosed in this issue: Trauma Reports and Bioterrorism Watch

PEDIATRIC

The Practical Journal of Pediatric Emergency Medicine

Emergency Medicine Reports

Volume 7, Number 3 March 2002

Pediatric Shoulder, Elbow, and Forearm Injuries: Early Identification and Age-Appropriate Management

Author: **Mary Jo A. Bowman, MD, FAAP**, Associate Professor of Clinical Pediatrics, The Ohio State University College of Medicine; Attending Physician, Columbus Children's Hospital, Columbus, OH.

Peer Reviewer: **Michael Altieri, MD, FAAP, FACEP**, Chief, Pediatric Emergency Medicine, Fairfax Hospital; Pediatric Residency Director, University of Virginia/Fairfax Hospital for Children, Falls Church, VA.

Unintentional injuries are the leading cause of death and disability among children in the United States. Musculoskeletal system trauma accounts for approximately one-third of injury-related hospital admissions and half of injury-related emergency department (ED) visits.[1] The cost, both in terms of dollars spent and time lost in normal activities, is significant.[2]

The recognition of unique pediatric anatomic differences and special fracture types is crucial to the management of orthopedic injuries in children. This article will briefly review the unique features of the pediatric skeleton, discuss common orthopedic injuries to the upper extremity, and offer insight into less well-recognized clinical entities.

— The Editor

Pediatric Skeletal Properties

The bone of a growing child is more porous than mature adult bone. Because of this property, children are more prone to unique injuries, such as torus (buckling) and greenstick fractures, as well as bowing or plastic deformation.

Another anatomic difference of pediatric bone is the presence of a thick periosteum in children. This separates from the bone easily and is more resistant to tearing, often remaining intact on one side of the fracture. The thickness of the periosteum decreases the incidence of fracture displacement and increases the probablility of a more stable fracture. Pediatric periosteum also possesses increased osteogenic capability, leading to faster healing and making nonunion a rare occurrence in children.

Children's bones are in a dynamic state of growth, with the new bone growth that occurs at fracture sites generally laid down in the plane of motion of the joint. This corrects some fracture longitudinal malalignment and allows for toleration of greater degrees of angulation, especially if the child has at least two years of growth remaining.[3]

Finally, growth plate or physeal injuries are unique to the pediatric population. Growth plates are weak structures, as they are composed mostly of cartilage. An injury to the physis is more likely to occur than an adjacent ligamentous injury. This is important to recognize to prevent growth imbalance and deformity. The Salter-Harris classification is used to describe physeal injuries.[1, 3-6]

Clinical Evaluation

Attention to life-threatening injuries takes precedence, especially in the multiply-injured child. Once this is accomplished, a

detailed history and more focused physical examination can take place. Most upper extremity injuries are isolated in nature, and certain characteristic fractures occur commonly.

History. A history should be obtained from the patient, if possible, and any witnesses to the injury. Pain and fear may make this task more difficult, but a calm and gentle approach will facilitate this. Details of the mechanism of injury, combined with the child's developmental level, often enable the treating physician to predict the type of injury likely to be present. Histories that are vague or inconsistent should raise concern about nonaccidental injury.

Physical Examination. The overlying skin should be inspected for any break that would signify an open fracture. The neurovascular status should be evaluated carefully, especially before and after any splinting or reduction takes place. The injured area, including the joints above and below, should be palpated and checked for deformity, pain, swelling, and abnormal motion.

Table 1. Ossification Centers of the Elbow

OSSIFICATION CENTERS	AGE OF APPEARANCE
Capitellum	1 yr.
Medial epicondyle	4-5 yrs.
Radial head	4-6 yrs.
Olecranon	6-9 yrs.
Trochlea	8-10 yrs.
Lateral epicondyle	10-12 yrs.

Diagnosis. The injured extremity should be splinted before radiographs are obtained, and appropriate analgesia should be administered. Radiographs should include at least two perpendicular views, usually anteroposterior (AP) and lateral, with the joints above and below included. Comparison views of the noninjured extremity may be helpful, especially in the elbow area, but are not routinely recommended.[7]

Special Considerations

Elbow Alignment. Elbow fractures may be obvious or very subtle in their presentation. Knowledge of the normal alignment and ossification centers is needed to correctly identify the more subtle fractures. The average age of appearance of ossification centers is noted in Table 1.

A true lateral view of the elbow is needed to ascertain proper alignment. The anterior humeral line is a line drawn down the anterior margin of the humerus.[3,8] In the true lateral view, this line should intersect the capitellum in its posterior two-thirds. *(See Figure 1.)* If it does not, suspect an occult fracture (usually supracondylar).

The radius should point to the capitellum in all views to assure proper alignment. If not, look for an elbow dislocation, Monteggia fracture, lateral condyle fracture, or radial neck fracture.[8]

Comparison views of the nontraumatized elbow sometimes are used when the diagnosis is in question. However, several studies have shown that this practice is not helpful for improving overall diagnostic accuracy and rarely should be used.[7,9]

Posterior Fat Pads. Another subtle sign of an occult elbow fracture is the presence of a posterior fat pad. On a true lateral x-ray, a posterior fat pad may be seen as a radiolucency posterior to the distal humerus adjacent to the olecranon fossa. This sign was first described in 1954 and was thought to be associated with a fracture of the elbow.[10] Several subsequent studies reported the prevalence of a fracture in those with a posterior fat pad and no detectable fracture to be 6-29%.[11,12] These studies were retrospective and included both adults and children. A recent prospective study of children demonstrated that the posterior fat pad sign was predictive of an occult fracture in 76% of the children in whom no detectable fracture was noted.[13] The authors recommend conservative treatment as a nondisplaced fracture when a posterior fat pad is noted.

Summary of Fractures

Table 2 lists general guidelines for the most common upper extremity fractures seen in children. The treatments listed are

Pediatric Emergency Medicine Reports™ (ISSN 1082-3344) is published monthly by American Health Consultants, 3525 Piedmont Road, N.E., Six Piedmont Center, Suite 400, Atlanta, GA 30305. Telephone: (800) 688-2421 or (404) 262-7436.

Vice President/Group Publisher: Brenda Mooney
Editorial Group Head: Valerie Loner
Managing Editor: Allison Mechem
Marketing Manager: Schandale Kornegay

GST Registration No.: R128870672

Periodical Postage Paid at Atlanta, GA 30304.

POSTMASTER: Send address changes to ***Pediatric Emergency Medicine Reports***, P.O. Box 740059, Atlanta, GA 30374.

Back issues: $53.
Missing issues will be fulfilled by customer service free of charge when contacted within one month of the missing issue's date.

Subscriber Information

Customer Service: 1-800-688-2421
Customer Service E-Mail Address:
customerservice@ahcpub.com
Editorial E-Mail Address: valerie.loner@ahcpub.com
World-Wide Web page: http://www.ahcpub.com

Subscription Prices

1 year *with* 30 ACEP, AMA, or AAP Category 1 credits: $369;
1 year without credit: $319;

Multiple copies:
One to nine additional copies: **$287 each;**
10 or more additional copies: **$255 each.**

Resident's Rate: **$184.50**

All prices U.S. only. U.S. possessions and Canada, add $30 postage plus applicable GST.
Other international orders, add $30.

Accreditation

Pediatric Emergency Medicine Reports'™ continuing education materials are sponsored and supervised by American Health Consultants. American Health Consultants designates this continuing education activity as meeting the criteria for 30 credit hours in Category 1 for Education Materials for the Physician's Recognition Award of the American Medical Association, provided it has been completed according to instructions.

This CME activity was planned and produced in accordance with the ACCME Essentials.

Pediatric Emergency Medicine Reports is also approved by the American College of Emergency Physicians for 30 hours of ACEP Category 1 credit. This continuing medical education activity has been reviewed by the American Academy of Pediatrics and is acceptable for 30 AAP Credit hours. These credits can be applied toward the PREP Education Award available to Fellows and Candidate Fellows of the American Academy of Pediatrics.

American Health Consultants is accredited by the Accreditation Council for Continuing Medical Education to sponsor continuing medical education for physicians.

THOMSON
AMERICAN HEALTH CONSULTANTS™

Questions & Comments
Please call **Valerie Loner,** Editorial Group Head, at (404) 262-5475 between 8:30 a.m. and 4:30 p.m. ET, Monday-Friday.

Statement of Financial Disclosure

American Health Consultants does not receive material commercial support for any of its continuing medical education publications. In order to reveal any potential bias in this publication, and in accordance with Accreditation Council for Continuing Medical Education guidelines, we disclose that Drs. Bowman (author), and Altieri (peer reviewer) report no consultant, stockholder, speaker's bureau, research, or other financial relationships with companies having ties to this field of study. Dr. Dietrich, editor-in-chief, also reports no consultant, stockholder, speaker's bureau, research, or other financial relationships with companies having ties to this field of study.

Table 2. Summary of Fractures

Bone	Mechanism of Injury	Treatment
CLAVICLE		
Middle	Fall onto shoulder or outstretched hand	Figure-of-eight or sling/swathe
Distal	Fall onto shoulder or outstretched hand	Sling/swathe
HUMERUS		
Proximal	Extension of arm in adduction	Sling/swathe
Shaft	Fall on elbow or hand/direct impact	Sling/swathe Sugar tong (adolescents)
ELBOW		
Supracondylar	Hyperextension fall	Nondisplaced: Posterior splint with elbow at 90° Displaced: Orthopedic reduction, pinning
Lateral condyle	Fall on outstretched hand	Nondisplaced: Posterior splint Displaced: > 2mm, reduction/pinning
Medial condyle	Fall on hand with valgus stress	Nondisplaced: Posterior splint Displaced: Open reduction
Olecranon	Direct trauma	Nondisplaced: Splint in partial extension Displaced: Open reduction/fixation
Radial head/neck	Fall on outstretched hand	Nondisplaced: Posterior splint Displaced or >15° angle: Reduction
RADIUS/ULNA		
Shaft	Fall on outstretched hand	Nondisplaced: Long arm cast or splint >10° angle: Reduction (open/closed)
Distal	Fall on outstretched hand	Nondisplaced: Cast or splint Displaced or >10-15° angle: Reduction
Monteggia	Fall on outstretched hand	Reduction
Galeazzi	Fall on outstretched hand	Reduction

conservative in nature and do not reflect regional preferences. Individual specific treatment and referral will vary institutionally.

Specific Fractures. *Clavicle.* The clavicle is one of the more frequently fractured bones in the body.[1] The area between the middle and lateral thirds is the most common site of fracture.[3] These fractures may occur from both direct and indirect force. Short falls onto a shoulder with medially directed impact or falls onto an extended arm may result in a fracture.

On physical examination, pain is noted with movement of the upper arm or neck. Local swelling, tenderness, and crepitus at the fracture site can help with the diagnosis. AP radiographs are sufficient to visualize most fractures and to determine the degree of displacement or angulation.

A figure-of-eight, or clavicle strap, often is used for treatment of a mid-shaft fracture. This strap holds the shoulders in abduction. Older children and adults may be more comfortable in a sling and swathe. This is the recommended treatment for distal third fractures. The treatment usually lasts 3-4 weeks, with reduction rarely indicated except in the case of severe displacement or tenting of the skin.[1,3-6]

Scapula. Fractures of the scapula are rare in children and usually occur as the result of direct high-energy trauma or a crush injury and frequently are associated with other, more serious injuries.

On examination, pain usually is noted over the scapula, and the child will be reluctant or unable to move the upper arm.

Plain AP radiographs usually will reveal the fracture. *(See Figure 2.)* Tangential or oblique views are sometimes necessary, however, to see the fracture. Most fractures are not displaced.

Treatment for the isolated scapular fracture is a sling and swathe for 3-4 weeks.[4,5]

Humerus: Proximal. Most proximal humerus fractures occur at the epiphysis.[6] Salter I and Salter II fractures occur frequently, especially in children ages 11-15.[1,3] These fractures result from falling on an extended arm that is adducted, such as the position assumed in breaking a fall. Direct trauma also can cause a fracture.

In addition to pain with even slight movement of the arm, swelling and tenderness are noted at the site. AP and lateral radiographs should be obtained.

Treatment consists of a sling and swathe in most instances. If there is greater than 40° angulation, evidence of malrotation, or displacement of more than 1 cm, reduction may be needed.[3-6]

Humerus: Shaft. Shaft fractures of the humerus are not common. When they do occur, the middle third is the most common location.[4,5] Falling on an elbow or hand can cause an oblique or comminuted fracture. Spiral fractures may occur if the body twists during the fall. Although these fractures may occur from accidental trauma, they should raise concern about potential

Figure 1. Anterior Humeral Line Bisects Capitellum

Figure 2. Scapular Fracture

non-accidental trauma, as a twisting force is necessary for this type of fracture.[4,5,14]

The child usually will have pain with motion on examination. Swelling, tenderness, and sometimes deformity can be seen. The radial nerve may be injured, and it is important to check for sensation dorsally between the thumb and index finger. Motor function can be checked by having the patient extend the wrist and finger extensors. AP and lateral radiographs are sufficient for the diagnosis. *(See Figure 3.)*

Treatment with a sling and swathe is used in the younger child. A sugar tong or coaptation splint with the elbow at 90° may be more comfortable for the older child. Reduction may be needed if there is excessive overriding or angulation (> 20° in child or 10° in adolescent) of the fracture.[4-6] Radial nerve injury requires orthopedic consultation and close follow-up.

Elbow. *Supracondylar.* Supracondylar fractures are the most common elbow fracture in children.[1,3,8] Most fractures occur in children between 3 and 10 years of age. A fall on an outstretched arm with hyperextension of the elbow is the most common mechanism of injury.

Three types of supracondylar fractures commonly are described.[8] Type I is a nondisplaced fracture. Type II is a displaced and angulated fracture but with the posterior cortex intact. Type III is a completely displaced fracture with no cortical contact. *(See Figure 4.)* Most type III fractures have the distal fragment displaced posteriorly.

On physical examination, pain with flexion of the elbow often is noted and tenderness over the distal humerus usually is present. The swelling varies depending on the type of fracture and associated underlying neurovascular injury. The assessment of the distal neurovascular status is especially important in this type of fracture. Increasing pain and/or paresthesias are worrisome signs and may signal a compartment syndrome.[4,5,8]

AP and true lateral radiographs should be obtained after splinting. Type I fractures may be subtle, and attention should be paid to alignment of the anterior humeral line and posterior fat pad sign.

Treatment of a type I supracondylar fracture is immobilization in a long arm posterior splint with the elbow flexed to 90° with the forearm neutral or pronated.[4,5,15] Reassessment of neurovascular status after splinting should be done and documented. Follow-up for definitive casting should take place within 48-72 hours.

Types II and III supracondylar fractures require prompt orthopedic consultation, reduction, and usually, admission to the hospital. Closed reduction with percutaneous pinning and even open reduction sometimes are used with these fractures.[4,5,8,15]

Lateral and Medial Condylar. Fractures of the lateral condyle account for about 15% of elbow fractures.[6] Medial condyle fractures are seen less often. Falling on an outstretched hand with the forearm abducted is the usual mechanism of injury.

Usually, a large amount of swelling is noted, and pain is noted on examination, especially with rotation of the elbow. A careful neurovascular examination must be done. AP and lateral radiographs will delineate the fracture in most instances, but

Figure 3. Oblique Humeral Shaft Fracture

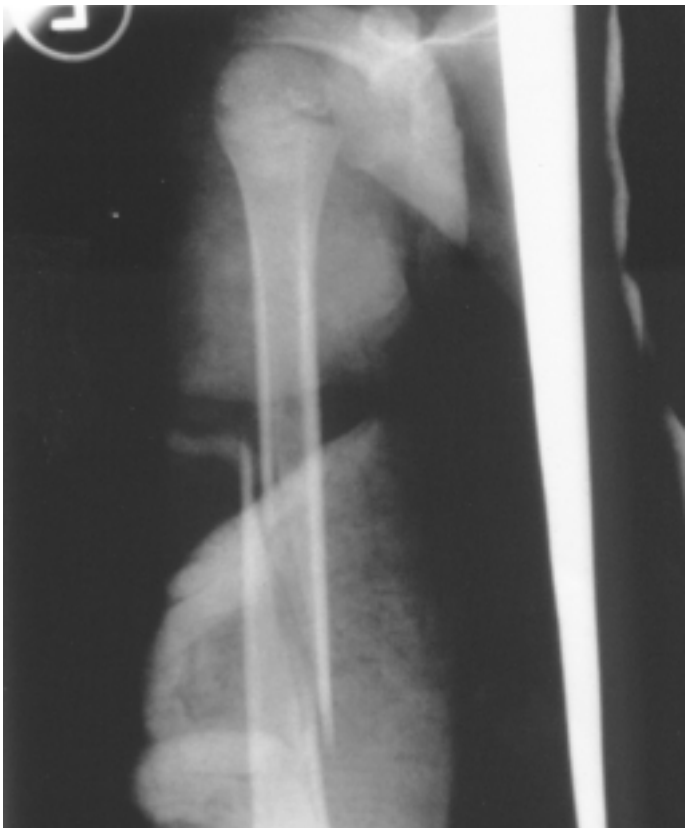

Figure 4. Type III Supracondylar Fracture

occasionally an oblique view is needed.

Treatment of a nondisplaced fracture is immobilization in a long arm posterior splint with the elbow flexed to 90° and the forearm neutral or supinated. Close orthopedic follow-up is required, as displacement may occur. A fracture that is displaced more than 2 mm requires immediate orthopedic consultation, reduction, and usually pinning, as this fracture is unstable.[4,5,8,15]

Olecranon. Fractures of the olecranon are infrequent and usually are the result of a direct blow to the elbow. There is usually tenderness at the olecranon and decreased motion of the elbow. The neurovascular examination is important. AP and lateral radiographs generally discern most fractures; however, they may be subtle. A posterior fat pad usually is present.

Treatment of a nondisplaced or presumptive fracture is immobilization in a long-arm posterior splint. Some authors recommend the elbow be flexed to 90°, while others prefer partial extension. Close orthopedic follow-up is warranted. A displaced fracture requires orthopedic consultation and reduction which may include open reduction and internal fixation.[4,5,16]

Radial Head/Neck. Fractures of the radial head or neck are more common after 5 years of age.[4] The mechanism of injury is usually a fall on an outstretched and supinated arm. On physical exam there often is restriction of both flexion/extension and supination/pronation. Swelling and ecchymosis of the elbow are noted, and point tenderness over the proximal radius often can be elicited. Pain often is referred to the wrist, so careful evaluation is of the elbow is warranted in children complaining of wrist pain. The neurovascular status should be checked with particular attention to the radial nerve. AP and lateral radiographs should be obtained.

Orthopedic referral is recommended for all fractures of the radial head or neck as complications may occur, such as loss of motion and avascular necrosis. Nondisplaced and incomplete fractures can be immobilized in a long-arm posterior splint with the elbow flexed to 90° and the forearm neutral. Displaced fractures or fractures with greater than 15° of angulation require prompt orthopedic referral.[4,5,16]

Radius/Ulna. Forearm fractures are very common in children. The distal radius and ulna are two of the more frequent bones that are broken.[4-6] Fortunately, complications are infrequent. While direct blows cause some fractures, a fall on an outstretched hand is the usual mechanism.

Greenstick fractures, in which only one side of the cortex is involved, can be seen in the radius and ulna. Plastic deformation, or bowing fractures, can occur as well, especially in the shaft of these bones. Torus or buckle fractures are common distal fractures in which buckling or angulation of the cortex may be seen. Salter-Harris type I and II fractures frequently are seen at the distal radius.

On physical examination, localized tenderness and swelling usually are noted at the fracture site. Obvious deformities may be seen, especially when the fracture is accompanied by displacement or angulation.

AP and lateral radiographs should be obtained and should include the entire forearm, elbow, and wrist.

Treatment depends on the type of fracture, its location, and

alignment. Rotational deformities are common with shaft fractures and require orthopedic consultation and reduction. It is important to remember that remodeling decreases with the distance from the epiphysis and the age of the child. A general rule of thumb is that any fracture with greater than 10-15° of angulation should be evaluated by an orthopedic surgeon.[4,16]

A torus fracture of the distal radius/ulna can be treated in a volar splint or a short or long arm cast with follow-up in 3-4 weeks.[4,5] Greenstick or transverse fractures that are not grossly deformed or angulated can be placed in a long arm posterior splint or sugar tong splint with referral to orthopedics in 3-5 days.[4,5]

Complete mid-shaft fractures of the radius and ulna usually require orthopedic consultation for closed reduction. Open reduction and internal fixation may be needed in the older child or adolescent.[4,5,16]

Monteggia Fracture. While Monteggia fractures only account for approximately 2% of elbow fractures in children, they easily can be overlooked, resulting in serious complications.[4-6,16] A Monteggia fracture is a combination of ulnar fracture (usually mid-shaft) with radial head dislocation. *(See Figure 5.)* This fracture usually occurs as the result of a fall on an outstretched hand with some rotation of the humerus. Any suspected Monteggia fracture requires immediate orthopedic referral for reduction.

Galeazzi Fracture. The Galeazzi fracture is a radial shaft fracture with a dislocation of the distal radioulnar joint.[4-6] This type of fracture is rare in children and requires orthopedic referral for reduction.

Radial Head Subluxation

Radial head subluxation, also known as nursemaid's elbow, is an injury frequently seen in the ED. The majority of patients are younger than 6 years of age, with a peak in children ages 1-3.[5] The usual mechanism of injury is longitudinal traction on an extended (often pronated) arm, which may occur with pulling or swinging a child by the arms.[4,5,17] This traction enables the annular ligament to slip over the margin of the radial head and become trapped between the radial head and capitellum.

Physical Examination. On physical examination, the child generally holds the affected arm close to the body with it partially flexed and pronated. The child also may just hold the arm limply to the side. Any attempts at motion cause pain and the child will not reach for objects. Careful palpation of the extremity usually will not elicit tenderness except, perhaps, at the radial head.

Diagnosis. Radiographs generally are not indicated for straightforward cases, and if obtained, will be normal. They should, however, be obtained if the child has bony tenderness, an unusual history, or does not regain function after reduction attempts.[17]

Treatment. Classically, the reduction technique involves supination of the forearm followed by either flexion or extension at the elbow. The elbow is held with the thumb on the radial head to feel for a click during reduction. The other hand grasps the child's wrist and then rapidly fully supinates the arm and flexes it at the elbow.[4,5] A click or pop frequently is felt over the radial head. Success rates for reduction range from 80-92%.[18,19]

Figure 5. Monteggia Fracture

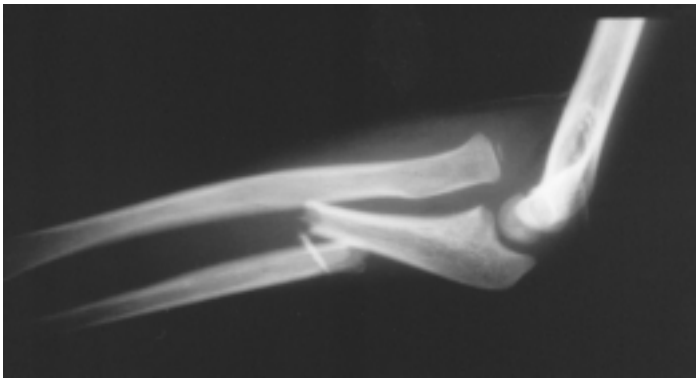

Several recent studies have compared a hyperpronation reduction to the classic supination/flexion method. The child's arm is held as in the above maneuver, but then is pronated rather than supinated to achieve reduction. One group used hyperpronation without flexion in their study.[20] They found that the hyperpronation technique required fewer attempts at reduction when compared with supination/flexion, was successful more often than supination, and often was successful when supination failed. Ninety-five percent of patients in the hyperpronation group were reduced successfully on the first attempt, compared to 77% in the supination group. Overall, 97.5% of patients in the hyperpronation group were reduced successfully, compared to 86% in the supination group.

Another group used a technique that combined hyperpronation with flexion vs. supination with flexion.[21] While they found a near equal success rate with both maneuvers on the first attempt, they did find more success with pronation on subsequent attempts. They also attempted to measure perceived pain during the maneuvers and found that physicians rated the pronation method as less painful.[21,22]

Compartment Syndrome

Compartment syndrome is a rare but potentially devastating problem in children with upper extremity injuries. Increased interstitial pressure within a closed fascial compartment can obstruct microcirculation to the nerves and muscles lying within the involved space and cause tissue necrosis. This necrosis of the muscle and subsequent fibrosis can cause permanent disability known as Volkmann's contracture.[5,23] Tight dressings or casts, along with the fracture itself, can contribute to the problem. A fracture, though, is not necessary to have a compartment syndrome.

Physical Examination. The hallmark finding is pain out of proportion to the injury.[23-25] The pain may be worsened by passive stretching of the muscle. An increase in analgesic requirement and anxiety in smaller children may be found as well.

Other "Ps" that may be noted include paresthesias, pallor, paralysis, and pulselessness. The latter two are late findings and may be seen when irreversible muscle damage already has occurred.

Diagnosis. If the diagnosis of compartment syndrome is suspected, the pressure within the compartment should be mea-

sured. Pressures can be measured using several techniques, including infusion, wick-catheter, and slit-catheter techniques. A compartment syndrome is present when the measurement is 20 mmHg or less, calculated by subtracting the compartment pressure from the diastolic blood pressure.[23-25]

Treatment. Treatment for a suspected compartment syndrome begins with splitting or removing any casts or padding.[23] Elevation of the extremity and ice also will help. If these measures do not relieve the symptoms, and compartment pressures are elevated, the patient should be taken to the operating room and fasciotomy of the affected compartment(s) should be performed.[23-25] A good prognosis is associated with early and prompt recognition leading to definitive treatment.

Reflex Sympathetic Dystrophy

Reflex sympathetic dystrophy (RSD) is a clinical entity that increasingly is becoming recognized in the pediatric population.[26,27] It is a disorder characterized by severe and continuous pain in an extremity associated with vasomotor instability. It was first described by Mitchell in 1864[28] during the American Civil War, with the role of the sympathetic nervous system postulated in 1916.[26] The term "reflex sympathetic dystrophy" came about in 1953. A recent international consensus panel refers to RSD as "complex regional pain syndrome," or CRPS.[29]

The International Association for the Study of Pain provides the following definition: "RSD is continuous pain in a portion of an extremity after trauma which may include fracture, but does involve a major nerve, associated with sympathetic hyperactivity. This usually involves the distal extremity adjacent to a traumatized area and the main feature is pain described as burning, continuous, exacerbated by movement, cutaneous stimulation, or stress, with onset usually weeks after injury."[30]

Four cardinal and six secondary signs and symptoms have been described.[26,31] Some authors feel all four cardinal signs are required to make the diagnosis, while others suggest any combination of signs and symptoms that are not explained by another condition are adequate. The cardinal signs and symptoms include pain, edema, stiffness, and discoloration.

The pain is out of proportion to the injury and generally is intense and burning. It may involve the entire extremity. Edema often is one of the first signs, and almost all patients will have it to some degree. Joint stiffness also is out of proportion to what would be expected and worsens because motion causes more pain. The discoloration varies from cyanosis to pale to intense red, especially in the hand area.

Secondary signs include demineralization, pseudomotor and thermoregulatory changes (hyperhidrosis to dryness), vasomotor instability (most commonly seen as decreased capillary refill), trophic changes, and palmar fibromatosis. The involved skin often has a glossy, shiny appearance.

Diagnosis. The diagnosis of RSD is primarily clinical.[26,27] Plain radiographs often are obtained to exclude other injuries or causes of pain. The most widely used imaging modality is the three-phase bone scan but results and their meaning are controversial and not well-studied in children.[26] Magnetic resonance imaging may become a useful diagnostic tool in this disorder, but no widespread studies have been done.[32]

Treatment. It is thought that children respond more favorably to treatment of RSD than adults.[26] Several therapeutic modalities have been used to treat RSD. These include physical therapy, steroids, psychotherapy, transcutaneous nerve stimulation, and regional nerve blocks.[26,27,33] Immobilization in casts or splints often exacerbates the problem and is not recommended.

Recently, gabapentin, a new anti-epileptic medication, successfully has been used in both adults and children to treat RSD.[34] Gabapentin is a structural analogue of the inhibitory neurotransmitter gamma-aminobutyric acid that crosses the blood-brain barrier. It also induces an increase in serotonin levels in the central nervous system (CNS). The suggested mechanism of action of relief of pain in RSD is a gabapentin-induced increase in CNS serotonin, which modulates the central monoaminergic pain pathways, inhibiting pain sensation.[37] This also could reverse some of the skin changes by way of serotonin-mediated activity on the raphe spinal cord-descending pathways.

Regardless of treatment options, the role of the emergency physician is evaluation and recognition in a timely manner, as favorable outcomes are associated with early diagnosis and treatment.

Conclusion

There are many upper extremity injuries that are unique to the pediatric patient. Knowledge and understanding of these principles will enable the emergency physician to appropriately assess and treat these injuries. Awareness of less common entities such as compartment syndrome and RSD will enable the physician to recognize these and assure appropriate treatment and referral.

References

1. England SP, Sundberg S. Management of common pediatric fractures. *Pediatr Clin North Am* 1996;43:991-1012.
2. Malek M, Bei-hung C, Gallagher S, et al. The cost of medical care for injuries to children. *Ann Emerg Med* 1991;20:997-1005.
3. Della-Giustina K, Della-Giustina DA. Emergency department evaluation and treatment of pediatric orthopedic injuries. *Emerg Med Clin North Am* 1999;17:895-922.
4. Bachman D, Santora S. Orthopedic trauma. In: Fleisher GR, et al, eds. *Textbook of Pediatric Emergency Medicine*. 4th Ed. Philadelphia: Lippincott, Williams and Wilkins; 2000:1435-1457.
5. Joffe M. Upper extremity injuries. In: Barkin RM, et al, eds. *Pediatric Emergency Medicine: Concepts and Clinical Practice*. 2nd Ed. St. Louis: Mosby Year Book; 1997:403-420.
6. Greenfield RH. Orthopedic injuries and injuries of the upper extremities. In: Strange GR, et al, eds. *Pediatric Emergency Medicine: A Comprehensive Study Guide*. New York: McGraw-Hill; 1996: 113-125.
7. Chacon D, Kissoon N, Brown T, et al. Use of comparison radiographs in the diagnosis of traumatic injuries of the elbow. *Ann Emerg Med* 1992;21:895-899.
8. Skaggs D, Pershad J. Pediatric elbow trauma. *Ped Emerg Care* 1997;13:425-434.
9. McCauley RG, Schwartz AM, Leonidas JC, et al. Comparison views in extremity injury in children: An efficacy study. *Pediatr Radiol* 1979;131:95-97.

10. Norell H. Roentgenologic visualization of the extracapsular fat. Its importance in the diagnosis of traumatic injuries to the elbow. *Acta Radiol* 1954;42:205-210.
11. De Beaux AC, Beattie T, Gilbert F. Elbow fat pad sign: Implications for clinical management. *J R Coll Surg Edinb* 1992;37:205-206.
12. Morewood DJ. Incidence of unsuspected fractures in traumatic effusions of the elbow joint. *British Med J* 1987;295:109-110.
13. Skaggs DL, Mirzayan R. The posterior fat pad sign in association with occult fracture of the elbow in children. *J Bone Joint Surg* 1999;79A:1429-1433.
14. Gallagher D, Dabezies EJ. Fractures of the humerus. In: MacEwen GD, et al, eds. *Pediatric Fractures: A Practical Approach to Assessment and Treatment*. Philadelphia: Lippincott, Williams and Wilkins; 1993:121-132.
15. Flynn JC, Zink WP. Fractures and dislocations of the elbow. In: MacEwen GD, et al, eds. *Pediatric Fractures: A Practical Approach to Assessment and Treatment*. Philadelphia: Lippincott, Williams and Wilkins; 1993:133-164.
16. Kasser JR. Forearm fractures. In: MacEwen GD, et al, eds. *Pediatric Fractures: A Practical Approach to Assessment and Treatment*. Philadelphia: Lippincott, Williams and Wilkins; 1993:165-190.
17. Sacchetti A, Ramoska EE, Glascow C. Nonclassic history in children with radial head subluxations. *J Emerg Med* 1990;8:151-153.
18. Quan L, Marcuse EK. The epidemiology and treatment of radial head subluxation. *Am J Dis Child* 1985;139:1194-1197.
19. Schunk JE. Radial head subluxation: Epidemiology and treatment of 87 episodes. *Ann Emerg Med* 1990;19:1019-1023.
20. Macias CG, Bothner J, Wiebe R. A comparison of supination/flexion to hyperpronation in the reduction of radial head subluxations. *Pediatrics* 1998;102:e10.
21. McDonald J, Whitelaw C, Goldsmith LJ. Radial head subluxation: Comparing two methods of reduction. *Acad Emerg Med* 1999;6: 715-718.
22. Macias CG. Radial head subluxation. *Acad Emerg Med* 2000;7: 207-208.
23. Joffe M, Loiselle J. Orthopedic emergencies. In: Fleisher GR, et al, eds. *Textbook of Pediatric Emergency Medicine*. 4th Ed. Philadelphia: Lippincott, Williams and Wilkins; 2000:1595-1612.
24. Kadiyala RK, Waters PM. Upper extremity pediatric compartment syndromes. *Hand Clinics* 1998;14:467-475.
25. Alonso JE. Musculoskeletal injuries. In: MacEwen GD, et al, eds. *Pediatric Fractures: A Practial Approach to Assessment and Treatment*. Philadelphia: Lippincott, Williams and Wilkins;1993:30-37.
26. Parrillo SJ. Reflex sympathetic dystrophy in children. *Ped Emerg Care* 1998;14:217-220.
27. Cimaz R, Matucci-Cerinic M, Zulian F, et al. Reflex sympathetic dystrophy in children. *J Child Neurol* 1999;14:363-368.
28. Mitchell SW, Morehouse GR, Keen WW. Gunshot wounds and other injuries of the nerves. Philadelphia: JB Lippincott, 1864.
29. Stanton-Hicks M, Janig W, Hassenbusch S, et al. Reflex sympathetic dystrophy: Changing concepts and taxonomy. *Pain* 1993;63: 127-133.
30. International association for the study of pain (IASP). Classification of chronic pain syndromes and definitions of pain terms. Prepared by the Subcommittee on Taxonomy. *Pain* 1986 (suppl 3).
31. Lankford LL. Reflex sympathetic dystrophy. In: Hunter JM, et al, eds. *Rehabilitation of the Hand–Surgery and Therapy*. 3rd ed. St. Louis: CV Mosby; 1990:763-786.
32. Schweitzer ME, Mandel S, Schwartzman RJ, et al. Reflex sympathetic dystrophy revisited: MR imaging findings before and after infusion of contrast material. *Radiology* 1995;195:211-214.
33. Murray CS, Cohen A, Perkins T, et al. Morbidity in reflex sympa-

thetic dystrophy. *Arch Dis Child* 2000;82:231-233.
34. Wheeler DS, Vaux KK, Tam DA. Use of gabapentin in the treatment of childhood reflex sympathetic dystrophy. *Pediatr Neurol* 2000;22:220-221.
35. Mellick LB, Mellick GA. Successful treatment of reflex sympathetic dystrophy with gabapentin. *Am J Emerg Med* 1995;13:96.
36. Mellick GA, Mellick LB. Gabapentin in the management of reflex sympathetic dystrophy. *J Pain Symptom Manage* 1995;10: 265-266.
37. Mellick GA, Mellick LB. Reflex sympathetic dystrophy treated with gabapentin. *Arch Phys Med Rehabil* 1997;78:98-105.

Physician CME Questions

21. Which of the following is/are unique pediatric skeletal properties?
    A. Pediatric bone is more porous.
    B. The periosteum is thicker than in adult bone.
    C. New bone is laid down in plane of motion of the joint.
    D. Physeal injuries are exclusive to pediatric bone.
    E. All of the above

22. Which of the following is true of the initial evaluation of a child with an upper extremity injury?
    A. Pain medicine should be withheld pending radiographs.
    B. An AP (anteroposterior) radiograph alone is adequate.
    C. The injured extremity should be splinted before radiographs.
    D. Comparison radiographs always should be obtained.

23. Which of the following is/are important principles in reading elbow radiographs?
    A. A true lateral view is needed to ascertain proper alignment.
    B. The radius should point to the capitellum in all views.
    C. The anterior humeral line should intersect the capitellum in its posterior two-thirds.
    D. All of the above

24. Which of the following nerves is most likely to be damaged with a humeral shaft fracture?
    A. Radial
    B. Median
    C. Ulnar
    D. Axillary

25. A Monteggia fracture:
    A. is a radial shaft fracture with a dislocation of the distal radioulnar joint.
    B. is an ulnar fracture (usually mid-shaft) with radial head dislocation.
    C. is another name for a type III supracondylar fracture.
    D. accounts for 25% of elbow fractures in children.
    E. can be splinted with orthopedic follow-up in two weeks.

26. The hallmark physical finding in a patient with compartment syndrome is:
    A. paresthesias.
    B. pallor.
    C. paralysis.

D. pulselessness.
E. pain out of proportion to the injury.

27. The four cardinal signs and symptoms of reflex sympathetic dystrophy include all of the following *except*:
A. pain.
B. palmar fibromatosis.
C. edema.
D. stiffness.
E. discoloration.

28. Which medication recently has been used successfully in the treatment of reflex sympathetic dystrophy?
A. Steroids
B. Carbamazepine
C. Gabapentin
D. Lamotrigine
E. Topiramate

29. The correct management of a child with an elbow injury and a radiograph posterior fat pad is:
A. immediate orthopedic consultation.
B. a bone scan.
C. oblique radiographs.
D. splint and close follow-up.

30. Which of the following is true regarding scapular fractures?
A. They are common pediatric fractures.
B. They may be associated with other serious injuries.
C. Treatment includes a long-arm cast.
D. The majority of fractures are displaced and require reduction.

CME Objectives

The CME objectives for *Pediatric Emergency Medicine Reports* are to help physicians:

a.) Quickly recognize or increase index of suspicion for specific conditions;

b.) Understand the epidemiology, etiology, pathophysiology, and clinical features of the entity discussed;

c.) Be educated about how to correctly perform necessary diagnostic tests;

d.) Take a meaningful patient history that will reveal the most important details about the particular medical problem discussed;

e.) Apply state-of-the-art therapeutic techniques (including the implications of pharmaceutical therapy discussed) to patients with the particular medical problems discussed;

f.) Understand the differential diagnosis of the entity discussed;

g.) Understand both likely and rare complications that may occur; and

h.) Provide patients with any necessary discharge instructions.

In Future Issues: **Evaluation of Pediatric Blunt Abdominal Trauma**

PEDIATRIC Emergency Medicine Reports

The Practical Journal of Pediatric Emergency Medicine

Shoulder, Elbow, and Forearm Injuries

Summary of Fractures

Bone	Mechanism of Injury	Treatment
CLAVICLE		
Middle	Fall onto shoulder or outstretched hand	Figure-of-eight or sling/swathe
Distal	Fall onto shoulder or outstretched hand	Sling/swathe
HUMERUS		
Proximal	Extension of arm in adduction	Sling/swathe
Shaft	Fall on elbow or hand/direct impact	Sling/swathe Sugar tong (adolescents)
ELBOW		
Supracondylar	Hyperextension fall	Nondisplaced: Posterior splint with elbow at 90° Displaced: Orthopedic reduction, pinning
Lateral condyle	Fall on outstretched hand	Nondisplaced: Posterior splint Displaced: > 2mm, reduction/pinning
Medial condyle	Fall on hand with valgus stress	Nondisplaced: Posterior splint Displaced: Open reduction
Olecranon	Direct trauma	Nondisplaced: Splint in partial extension Displaced: Open reduction/fixation
Radial head/neck	Fall on outstretched hand	Nondisplaced: Posterior splint Displaced or >15° angle: Reduction
RADIUS/ULNA		
Shaft	Fall on outstretched hand	Nondisplaced: Long arm cast or splint >10° angle: Reduction (open/closed)
Distal	Fall on outstretched hand	Nondisplaced: Cast or splint Displaced or >10-15° angle: Reduction
Monteggia	Fall on outstretched hand	Reduction
Galeazzi	Fall on outstretched hand	Reduction

Ossification Centers of the Elbow

OSSIFICATION CENTERS	AGE OF APPEARANCE
Capitellum	1 yr.
Medial epicondyle	4-5 yrs.
Radial head	4-6 yrs.
Olecranon	6-9 yrs.
Trochlea	8-10 yrs.
Lateral epicondyle	10-12 yrs.

Supplement to *Pediatric Emergency Medicine Reports*, March 2002: "Pediatric Shoulder, Elbow, and Forearm Injuries: Early Identification and Age-Appropriate Management." *Author*: **Mary Jo A. Bowman, MD, FAAP**, Associate Professor of Clinical Pediatrics, The Ohio State University College of Medicine; Attending Physician, Columbus Children's Hospital, Columbus, OH.

BIOTERRORISM WATCH

Preparing for and responding to biological, chemical and nuclear disasters

Anthrax aftermath: Adverse drug reactions, vaccine controversy undercut CDC extended treatment offer

Some 8,000 people say thanks but no thanks

Despite the lingering possibility of late-onset anthrax infection, more than 8,000 people potentially exposed in the bioterrorism attacks of 2001 have turned down offers of additional antibiotics and immunization with the controversial vaccine, *Bioterrorism Watch* has learned.

Faced with insufficient data to truly assess the risk, the Centers for Disease Control and Prevention (CDC) in Atlanta offered the additional measures but fell short of actually recommending them.

Additional treatment offered as an 'option'

Operating on a thin margin of data about anthrax exposures, incubation periods, and subsequent infections, the CDC concluded it couldn't make a formal recommendation. The additional antibiotics and vaccine were made available as "options" to those exposed.

"The feeling was that this was the best thing we could do for people, and at least, leave it up to them to make a decision," says **Ian Williams**, PhD, medical epidemiologist in the CDC national center for infectious diseases. "We don't know what the answer is, but these are the options. We were really caught between a rock and a hard place on this one."

The 10,000 people potentially were exposed to anthrax in Connecticut, Florida, New Jersey, New York City, and Washington, DC.

They were all originally recommended to take at least 60 days of post-exposure antibiotic prophylaxis, but emerging data suggest that there has been a surprising lack of compliance.

In some preliminary surveys, fewer than half of those exposed were fully adhering to their original 60-day regimen. The CDC now has undertaken a telephone survey of all 10,000 people to identify adverse reactions and other reasons for the lack of adherence. **(See related story, p. 3.)**

The vaccine and additional antibiotic options were brought into play in part because the CDC knew it had large numbers of people who had not completed the original 60-day regimen. But the offer of additional care may have been undermined to some degree by prior adverse antibiotic reactions and fear of an anthrax vaccine that has been mired in controversy for years. Then again, many of those exposed may have felt they were no longer at risk and if their status changed, they would consult a physician.

Anthrax alive at 100 days

Though no known cases of anthrax have developed in any of the individuals who were prescribed the 60-day antibiotic course, the CDC also was aware of some disturbing data in animal studies. Traces of live anthrax spores have been detected in test animals' lungs up to 100 days following exposure, raising the theoretical possibility that the spores remaining still could

This supplement was written by Gary Evans, editor of *Hospital Infection Control*. Telephone: (706) 742-2515. E-mail: gary.evans@ahcpub.com.

cause disease. In that regard, one of the additional options offered to the exposed people was to take antibiotics for another 40 days (bringing total therapy time out to 100 days).

The other option was to take the additional drug regimen and also be vaccinated against anthrax. The latter option included three doses of anthrax vaccine over a four-week period, but antibiotics still had to be taken as the vaccine took effect.

The vaccine was not designed for post-exposure prophylaxis, but the theory is that it may provide additional protection by inducing an immune response to anthrax.

"People were unclear what the upper limit [for the onset of infection] was," Williams says. "That is what really drove both the vaccine and the antibiotic [offer]. We thought that 40 additional days to make 100 days looked sufficient based on our scant data. The vaccine was added because, is 100 days enough? I can't tell you absolutely for sure that it is enough."

Thousands took their chances

Most people were willing to take their chances that late onset anthrax will not occur.

Of the exposed cohort of some 10,000 people, 1,547 elected to receive more antibiotics after their 60-day regimen. Another 192 opted to be immunized with the anthrax vaccine and take additional antibiotics while the series of shots is given. Are the other 8,000-plus people at any real risk?

"Our feeling is that there shouldn't be any late cases of anthrax, based on what we know," Williams says.

"But that very well might be dose-dependent. We can't quantify the dose. If you go back and look at the animal studies that were done, they were actually done with probably lower doses than we have seen in the [U.S. Senate] Hart office building. But based on the data we can draw from animal models, it looks like there shouldn't be late onset cases," he explains.

If such an event occurred, the disease presumably still could be treated — provided the person seeks medical care. Still, making assumptions about anthrax can be tricky.

The CDC has been on a steep learning curve throughout the bioterrorism attack, with officials caught off guard by the ability of anthrax to disperse and spread during mail handling.

In addition, the ability to predict risk of infection in an exposed individual remains elusive, said **Julie Gerberding**, MD, director of the CDC division of healthcare quality improvement.

"We know that the exposure dose probably varies depending on how close you are to the source when it's released and how long you are in the [area] of release," Gerberding reported at a recent CDC meeting on post-exposure prophylaxis for anthrax.

> *"This is not an experiment to help us later. We don't have a control group. All we are doing is using the best science we have, which suggests that this is best way to give protection to people."*

"[But] despite our capacity to think about populations, we cannot accurately identify individual exposure, and we cannot accurately quantify individual risk," she explained.

Faced with that conundrum, the CDC put the same options on the table for all 10,000 people potentially exposed.

"The risk was probably different in different places," Williams says. "If you look at Capitol Hill, the concentration of anthrax released was probably much higher than say, Connecticut, where a letter just went through a post office. But that's group risk. Individual risk is different. [We] can't tell you exactly what your risk is. We'll give you the best available data, but you are going to have to make that decision."

Of the 190 people receiving anthrax vaccine, 80 had some political connection in Washington, DC, and 44 were postal workers in that city. Another 49 people in New Jersey were vaccinated; and the remainder were in New York City (12), Florida (four), and Connecticut (three). Of those who chose additional antibiotics only, 849 were in Washington, DC; 354 in New Jersey; 248 in New York City; 55 in Connecticut; and 41 in Florida.

A mixed message?

The CDC has drawn criticism for its approach, particularly for making a controversial vaccine available but leaving the immunization decision up to patients and their providers.

"It would have been much better if they had come out and said, 'Yes, we think in order to have as much protection as possible against the potential of developing disease, you should receive both

Side effects undermine anthrax drug adherence

More than half dropped drugs by 30 days

Amid the hype and horror of the 2001 anthrax attacks, it seemed a given that the people potentially exposed would be particularly diligent in completing their antibiotic regimens. But as time passed — and side effects continued or worsened for some — compliance fell off dramatically for many of the 10,000 people put on 60-day regimens for ciprofloxacin and doxycycline, according to preliminary data from the Centers for Disease Control and Prevention (CDC).

None of the people who started on antibiotics have developed anthrax, but the CDC wants some answers on the lack of adherence. To that end, the CDC is conducting a telephone survey project that will attempt to reach all 10,000 people for whom post-exposure antibiotic prophylaxis was recommended. The interviews began in late January and are expected to continue through March 2002. The people were potentially exposed to anthrax in Connecticut, Florida, New Jersey, New York City, and Washington, DC.

"We are making sure we get in touch with all of these people to evaluate how they did in terms of taking antibiotics," says **Ian Williams**, PhD, medical epidemiologist in the CDC national center for infectious diseases. "We have data showing adherence definitely wasn't as high as people, prior to this outbreak, would have thought it would be."

The CDC attempted a variety of methods to assess compliance prior to the phone survey, including tracking individuals who did not return to refill their medication. Other methods include giving a sample of those exposed questionnaires that were self-administered, given by a nurse, or by telephone, according to **Nancy Rosenstein**, MD, medical epidemiologist in the CDC national center for infectious diseases.

"In general, adherence has declined over the course of the [first] 30 days to as low as 45%," Rosenstein said at a recent CDC meeting on post-exposure prophylaxis for anthrax.

Some groups were more compliant than others. For example, employees who worked in the American Media Building in Boca Raton, FL, were closer to 70% compliant, she said. But only 45% compliance at 30 days was also found in a "high risk group" of mail handlers in New York City, she added.

"Adherence experts tell me that when we actually count pills, the self-reporting numbers probably overestimate real adherence by as much as 20%," Rosenstein said. "So the real estimates of adherence — taking the antibiotics every day — are obviously substantially lower."

In terms of self-reported adverse events, within two weeks of taking ciprofloxacin, 19% were reporting severe nausea, vomiting, abdominal pain, and diarrhea. At 30-day surveys, many people had switched to doxycycline, but self-reported adverse events increased to 45%.

Again, the predominant symptoms were severe nausea, vomiting, diarrhea, and abdominal pain. About 12% of the people reporting adverse events required additional follow-up with medical chart review and physician interviews, she said.

"I don't want to in any way minimize the impact of these symptoms on people's daily life, but when we actually investigated further, we were unable to identify anybody who actually required hospitalization or an emergency room visit for their adverse events," Rosenstein said.

Thus, based on Food and Drug Administration criteria, no serious adverse events have been linked to taking antibiotics for anthrax exposure. A more complete picture of the adherence problems should emerge from the CDC telephone survey of all recipients. Preliminary surveys have found that 6% to 12% of respondents reported at least missing some of their doses because of the side effects, she said. ■

antibiotic and vaccine,'" says **Phillip Brachman**, MD, a professor in the Rollins School of Public Health at Emory University in Atlanta.

The vaccine has been embroiled in a safety dispute since the military began a mandatory immunization policy several years ago, with some veterans saying it made them sick and others refusing to take it.

"A number of [the exposed people] undoubtedly read about the problems some of the military

folks claimed they had experienced after having the vaccine," Brachman says.

"They associated their problem with the vaccine. Remember, that those people in the military who have made those complaints are a very small number, considering the total number of doses given," he adds. "So there are very few voices creating a lot of concern."

Brachman did what remains the only clinical trail on the safety and efficacy of an anthrax vaccine precursor when he worked for the CDC in the 1950s.

In a study of goat's-wool workers — which was once an occupational risk group for anthrax in the United States — he found the vaccine safe and effective. He reported few side effects to vaccination and an efficacy rate of 92.5%.[1] The vaccine used in the study was a protective-antigen variety similar to the current vaccine. However, the manufacturing process has since changed and a different strain of anthrax is now used.

"There have been a few minor changes, and some people make a lot more out of it then it really should be," he says. "A different strain is being used to prepare the vaccine, but that should make no difference because the organism is not in the vaccine. It is the protein product from the organism."

Dearth of data

An Institute of Medicine committee that convened to look at the current anthrax vaccine cited a dearth of data in concluding: "The published studies have found transient local and systemic effects (primarily erythema, edema, or induration) of the anthrax vaccine.

"There have been no studies of the anthrax vaccine in which the long-term health outcomes have been systematically evaluated with active surveillance. . . . The committee concludes that in the peer-reviewed literature, there is inadequate/insufficient evidence to determine whether an association does or does not exist between anthrax vaccination and long-term adverse health outcomes. . . . To date, published studies have reported no significant adverse effects of the vaccine, but the literature is limited to a few short-term studies,"[2] the committee said.

For its part, the CDC would not have made the vaccine an option for those exposed if it had any doubts about its safety, Williams says.

"It seems to be a very safe, efficacious vaccine," he says. "[The] CDC reviewed the data with the military, which has the most experience with this."

Still, some people may have been confused because the CDC did not roll out the vaccine right after the exposures occurred. Thus, the response was somewhat tepid to a vaccine "add-on" option 60 days after the potential exposure. One problem is that the U.S. military, which controls the dispersal of anthrax vaccine, did not release any stocks in the immediate aftermath of the bioterror attacks, he says.

"One of the lessons we have learned is that if the vaccine had been available when this first started, I think the post-exposure prophylaxis would have been approached much differently," Williams says.

With the military now more amicable on the issue, if a bioterrorist strikes again with anthrax, the vaccine could play an important role from the onset, he emphasizes.

"If this should happen again, the vaccine might be used closer to day zero," Williams says. "After a series of doses over a month or so, most people will develop an antibody response, so it would obviate the need for additional antibiotics. It will be used in more of a true post-exposure fashion."

Those who have been recently vaccinated will be followed over time. Indeed, the CDC is discussing following the whole cohort of 10,000 people. It is an interesting group, having been potentially exposed to anthrax, taken prolonged antibiotic regimens, and in some cases, received a vaccine whose long-term safety is in some question.

Another curious fact — as with other post-exposure regimens for diseases — is that no one will ever know if the additional measures taken by 1,739 of these people actually prevent a late-onset anthrax infection.

"This is not an experiment to help us later," Brachman says. "We don't have a control group. All we are doing is using the best science we have, which suggests that this is best way to give protection to people."

References

1. Brachman PS, Gold H, Plotkin S, et al. Field evaluation of a human anthrax vaccine. *Am J Public Health* 1962; 52:632-645.

2. Committee on Health Effects Associated with Exposures during the Gulf War. *An Assessment of the Safety of the Anthrax Vaccine: A Letter Report*. Washington, DC: Institute of Medicine; March 30, 2000. ■