AMERICAN HEALTH CONSULTANTS® A Medical Economics Company

EMERGENCY MEDICINE ALERT™

An essential monthly update of developments in emergency medicine

From the Publishers of Emergency Medicine Reports™

American Health Consultants Home Page—http://www.ahcpub.com

CME for Physicians—http://www.cmeweb.com

Intubation Using Sedation Without Neuromuscular Blockade: Say What?

ABSTRACT & COMMENTARY

Source: Garich TG, et al. Pre-hospital airway management in the acutely injured patient: The role of surgical cricothyrotomy revisited. *J Trauma Inj Infec Crit Care* 1998;45:312-314.

Authors from hannover, germany, have reported their use of a pre-hospital protocol for intubation of trauma patients that uses sedation without neuromuscular blockade. Garich and colleagues have maintained a registry of pre-hospital intubation cases, and report their results in 383 patients. They used a fixed protocol for endotracheal intubation, using only intravenous midazolam and fentanyl for sedation. Indications for intubation were comatose patients (GCS < 9), respiratory distress, hemodynamic instability, multi-system trauma, suspected thoracic trauma and three or more extremity fractures, and airway obstruction. The pre-hospital crew consisted of a physician (a resident in surgery at PGY-3 or higher) and a paramedic. Garich et al prepared this report because of their concerns over the inappropriately high use of surgical cricothyroidotomy in pre-hospital protocols that use neuromuscular blockade.

Of the 383 patients in the sample, 373 were successfully intubated by the time they reached the emergency department (ED), yielding a 97% success rate. The 10 patients who were not successfully intubated included eight who underwent cricothyroidotomy in the field (6 without previous attempts at intubation) and two with unrecognized esophageal intubation. Their conclusions are that pre-hospital endotracheal intubation can be accomplished by trained EMS personnel without the use of paralytic agents, and that the incidence of cricothyroidotomy can be kept low with proper training in field airway management.

COMMENT BY JEFFREY W. RUNGE, MD, FACEP

This article is another example of several articles in the recent trauma literature that attempt to document successful endotracheal

INSIDE

intubation using an inadequate technique of patient preparation. I chose this article for review because of the irony that just as emergency physicians are making great headway with the use of the time-tested techniques of rapid sequence intubation (RSI) using induction anesthetics and neuromuscular blockade, an approach that is a giant step backward appears in the literature. This article falls far short of constituting evidence for intubation using sedation only.

RSI done properly, with complete pharmacological control to make the patient suitable for a safe intubation, is now standard-of-care in emergency medicine. It may very well be standard of care in the future in the pre-hospital setting, once sufficient commitment is made to training and equipment for pre-hospital professionals.

Sedation with benzodiazepines and narcotics for intubation is the proverbial "20% solution." The profound sedation necessary to achieve adequate relaxation for intubation gives you all of the disadvantages of respiratory depression, myocardial depression, and hypotension, with none of the advantages of muscular relaxation. The protocol used by Garich et al includes the administration of 10-30 mg of midazolam with 250-500 mcg of fentanyl. Both of these drugs cause hypotension, do not reduce the risk of laryngeal spasm, and may increase the risk of vomiting and aspiration. Even at doses five times what is necessary for induction, 12.5% of the patients in this study required multiple attempts at intubation. More than half of the patients in this study were intubated because of coma, yet this protocol does nothing to address the increases in intracranial pressures caused by the act of intubation without neuromuscular paralysis. Nearly 15% of patients had multi-system trauma, the last people that should be subjected to iatrogenic hypotension. Their advocacy of avoiding neuromuscular blockade to avoid cricothyroidotomy is folly. A short-acting agent such as succinylcholine carries low risk in the hands of those well-trained in the procedures and complications of airway management.

The authors' impetus for reporting these data is presumably a rate of surgical cricothyroidotomy after neuromuscular blockade that they deemed to be inappropriately high. But the reference Garich et al give for this assertion is a study from Tucson in which pre-hospital personnel performed 56 cricothyroidotomies in 376 patients requiring emergency airway management in the field.[1] The Tucson EMS system, however, does not allow paramedics to use rapid sequence intubation techniques, so all of these cricothyroidotomies were performed without RSI. It should be argued that this rate of surgical cricothyroidotomy is unacceptably high, owing not to the use of RSI, but rather to its lack of use.

It is our duty as emergency physicians to insist on the highest standard of care for our injured patients. This includes patients at high risk of intracranial pressure from brain injury receiving interventions that do not exacerbate their problems with cerebral perfusion and secondary neuronal injury. In those patients who are bleeding, it is our duty to avoid exacerbating the problems of poor perfusion by avoiding medications that cause hypotension and myocardial depression. For those patients at risk for ARDS, the avoidance of vomiting and aspiration during airway control is of paramount importance.

All of these goals can be met through the use of carefully performed RSI using an induction agent that, given in proper doses, does not cause hypotension or myocardial depression followed by short acting neuromuscular blockade. At our institution, we also use intravenous lidocaine prior to other agents to mitigate rises in intracranial pressure, and atropine in children to block heightened vagal tone. The procedures for proper RSI should not be taken lightly, and all emergency physicians and pre-hospital personnel who use these techniques should be thoroughly trained in the pharmacolo-

Emergency Medicine Alert, ISSN 1075-6914, is published monthly by American Health Consultants, 3525 Piedmont Rd., NE, Bldg. 6, Suite 400, Atlanta, GA 30305.

General Manager: Thomas J. Kelly.
Publisher: Brenda Mooney.
Managing Editor: David Davenport.
Copy Editor: Suzanne Zunic.
Marketing Manager: Debra Zelnio.

GST Registration Number: R128870672.

Periodical postage paid at Atlanta GA 30304.
POSTMASTER: Send address changes to ***Emergency Medicine Alert,*** P.O. Box 740059, Atlanta, GA 30374.

Back issues: $15. One to nine additional copies, $57 each; 10 or more additional copies, $38 each.

Subscriber Information

Customer Service: 1-800-688-2421
Customer Service E-Mail Address: custserv@ahcpub.com
Editorial E-Mail Address: suzanne.zunic@medec.com
World-Wide Web: http://www.ahcpub.com

Subscription Prices

United States: $189 per year (Resident rate: $95)
Canada: $219 per year plus GST (Resident rate: $110)
Elsewhere: $219 per year (Resident rate: $110)

Accreditation

American Health Consultants is accredited by the Accreditation Council for Continuing Medical Education (ACCME) to provide CME for physicians. American Health Consultants designates this CME activity for 20 credit hours of Category 1 of the Physician's Recognition Award of the AMA. ***Emergency Medicine Alert*** is also approved by the American College of Emergency Physicians for 20 hours of ACEP category 1 credit. This CME activity was planned and produced in accordance with the ACCME Essentials. This program has been reviewed and is acceptable for up to 20 Prescribed hours by the American Academy of Family Physicians. Term of approval is for one year from beginning distribution date of 6/97 with option to request yearly renewal. **For CME credit, add $50.**

Questions & Comments

Please call **David Davenport,** Managing Editor, at (404) 262-5475 or **Suzanne Zunic,** Copy Editor, at (404) 262-5444 between 8:30 a.m. and 4:30 p.m. ET, Monday-Friday.

Statement of Financial Disclosure

American Health Consultants does not receive material commercial support for any of its continuing medical education publications. In order to reveal any potential bias in this publication, and in accordance with Accreditation Council for Continuing Medical Education guidelines, a statement of financial disclosure of editorial board members is published with the annual index.

gy of the drugs, the manual techniques of intubation, and the use of alternative airway management devices such as the laryngeal mask and the Combitube. Training in the proper use of bag-valve-mask ventilation is also imperative, so that failed attempts at intubation with a neuromuscular blocking agent on board do not necessarily result in the need for surgical airway intervention in order to ventilate.

Articles such as this that attempt to document success using inferior techniques that put patients at risk should be recognized for what they are and dismissed. ❖

Reference

1. Fortune JB. Efficacy of pre-hospital surgical cricothyroidotomy in trauma patients. *J Trauma Inj Infec Crit Care* 1997;44(5):832-838.

Epididymitis, Testicular Torsion, and Torsion of Appendix Testis

ABSTRACT & COMMENTARY

Source: Kadish HA, Bolte RG. A retrospective review of pediatric patients with epididymitis, testicular torsion, and torsion of testicular appendages. *Pediatrics* 1998;102:73-76.

When a pediatric patient presents with scrotal pain or swelling, it can be difficult to distinguish the causes. Investigators at the Primary Children's Medical Center in Utah report on a retrospective review of patients younger than 18 years of age with these conditions who recently presented to their hospital. Ninety patients were included—64 with epididymitis, 13 with testicular torsion, and 13 with torsion of appendix testis.

The peak incidence of all three conditions was during ages 9-14 years. Incidence of testicular torsion peaked at 12-16 years. Patients with torsion of appendix testis were evenly distributed between 1-14 years, and patients with epididymitis were seen in all age groups, with a peak incidence of 8-12 years. Historical features, such as fever, nausea, vomiting, dysuria, sexual activity, and history of trauma, were not helpful discriminators. Compared with epididymitis, patients with testicular torsion and torsion of appendix testis were more likely to present within 12 hours of the onset of symptoms. All patients with testicular torsion had an absent cremasteric reflex and a tender testicle, compared, respectively, with 14% and 69% of patients with epididymitis, and 0% and 31% of patients with torsion of appendix testis. The testicular lie was normal in all patients with epididymitis and torsion of appendix testis, yet was normal in only half of the patients with testicular torsion. Ninety-seven percent of patients with epididymitis had a tender epididymis, compared with only 23% of patients with testicular torsion. Only patients with torsion of appendix testis had isolated tenderness at the superior pole of the testis. In the 38 patients who had a color Doppler ultrasound, the sensitivity was 100% and the specificity was 97% for identifying testicular torsion.

COMMENT BY LEONARD FRIEDLAND, MD

There are some take-home messages from this retrospective review. In contrast to the history, the physical examination is very helpful when attempting to distinguish between testicular torsion, epididymitis, and torsion of appendix testis. Think testicular torsion when you note an absent cremasteric reflex, tender testicle, or abnormal testicular lie. Isolated tenderness at the superior pole of the testis is highly characteristic of torsion of appendix testis. Color Doppler ultrasound can be helpful in distinguishing among the causes; however, missed cases of testicular torsion have been reported. The practice at my institution mimics that of Kadish and associates: urology consultation is obtained in all uncertain cases. I was taught that epididymitis was a disease of sexually active patients, yet this paper confirms my experience that it occurs in children as well as adolescents. Epididymitis was observed across all age ranges; only 15% of patients with epididymitis had an abnormal urinalysis, and in those patients none cultured had a STD. Add epididymitis to your differential of the acute scrotum, even in young children. ❖

A Comparison of Two Techniques in the Reduction of Radial Head Subluxation

ABSTRACT & COMMENTARY

Source: Macias CG, et al. A comparison of supination/flexion to hyperpronation in the reduction of radial head subluxations. *Pediatrics* 1998;102:e10. URL: http://www.pediatrics.org/cgi/content/full/102/1/e10.

Radial head subluxation (rhs), more commonly known as nursemaid's elbow, is a frequent upper extremity injury seen in the emergency department

(ED). The traditional technique used in reduction involves supination at the wrist followed by flexion at the elbow. This prospective study attempts to compare two maneuvers: the traditional method with that of hyperpronation at the wrist. Children younger than 6 years of age, presenting to two urban pediatric EDs and two suburban pediatric ambulatory care centers with a diagnosis of RHS, were randomized to either group. After initial reduction, a second attempt was made if no return of function was observed within 15 minutes. The alternate method was used if the second attempt failed after 15 minutes of observation. Of the 90 patients enrolled, five had a final diagnosis of fracture and had to be removed from the study. Of the 41 patients included in the hyperpronation group, 39 (95%) were successfully reduced on the first attempt. The remaining two required a second attempt. However, only 34 (77%) of the 44 patients in the supination group were successful on the first attempt. The remaining 10 patients required a second attempt, of which six patients needed to crossover to the hyperpronation group. Of these, five were reduced in the first attempt of hyperpronation and one was reduced on the second attempt. One patient failed both techniques.

COMMENT BY RAEMMA PAREDES, MD

The current theory in the development of RHS is that the annular ligament, which holds the radial head in place between the proximal ulna and distal humerus, becomes trapped in the radiocapitellar joint. This occurs when a longitudinal traction force is applied to the wrist or hand with the elbow in extension and the forearm in pronation.[1] Recent studies, including this one, have shown that a history of a pull is obtained only half the time, while a history of a fall on the elbow is obtained in about 20%.[2] Maneuvers such as supination of the forearm and hyperextension of the elbow work as well.[2] Macias and associates did not attempt to explain how hyperpronation could bring the annular ligament back in place. Is there, perhaps, more than one explanation for the development of RHS?

This study reinforces the practice of getting radiographs if multiple attempts at reduction are unsuccessful. Five patients had radiographic evidence of a fracture. Because of the high recurrence rate found in the study (32.9%), and those in other studies (23.7-37%),[2-4] it is important for clinicians to counsel caretakers about this. In a child with recurrent subluxations and a reliable caretaker, hyperpronation at the wrist may be a simple maneuver to teach.

Macias et al should be congratulated for a well-designed and practical study. This study showed that the hyperpronation technique is definitely more successful than the traditional method of radial head reduction. It is also easier to do and less frightening to the patient and the parent. The clinician has more options in the management of RHS. *(Dr. Paredes is an attending in Pediatric Emergency Medicine, Temple University Hospital, Philadelphia, PA.)* ❖

References

1. Young GM. Reduction of common joint dislocations and subluxations. In: Henretig FH, et al, eds. *Textbook of Pediatric Emergency Procedures*. Baltimore: William and Wilkins; 1997:1075-1104.
2. Schunk JE. Radial head subluxation: Epidemiology and treatment of 87 episodes. *Ann Emerg Med* 1990; 19:1019-1023.
3. Schutzman SA, Teach S. Upper-extremity impairment in young children. *Ann Emerg Med* 1995;26:474-479.
4. Quan L, Marcuse EK. The epidemiology and treatment of radial head subluxation. *Am J Dis Child* 1985;139: 1194-1197.

Special Feature

Benign Early Repolarization

By William J. Brady, MD

The syndrome of benign early repolarization (BER) electrocardiographically includes diffuse ST segment elevation (STE), upward concavity of the initial portion of the ST segment, notching or slurring of the terminal QRS complex, and symmetric, concordant T waves of large amplitude.[1]

BER is a normal variant and is not indicative of underlying cardiac disease. The physiologic basis is poorly understood and remains a subject of ongoing controversy. In fact, the term "early repolarization" may be a misnomer from the electrophysiologic perspective in that one investigation found no increase in the temporal overlap between termination of ventricular depolarization and onset of repolarization—the theoretical basis of BER—in patients with the electrocardiographic pattern. Suggested mechanisms of BER include early subepicardial repolarization, earlier repolarization of the anterior wall of the left ventricle (LV) compared to the posterior wall, and regional differences in sympathetic/parasympathetic tone. BER has been reported in men and women of all age groups and in people of varying ethnic backgrounds. The mean age is approximately 40 years, with men manifesting BER

significantly more often; usually, BER is seen in patients younger than 50 years and is rarely encountered in individuals older than 70 years.[2] For unknown reasons, BER may be encountered more often in young black males. The general population will have early repolarization on the ECG in approximately 1% of cases; this pattern is seen in adult emergency department (ED) patients with an increased frequency, including: 1) young males, 1-2% of cases; 2) chest pain patients, 13% of cases; and 3) chest pain patients using cocaine, 23-48% of cases.[2,3]

The ST segment of the cardiac electrical cycle represents the period between depolarization and repolarization of the LV. In the normal state, the ST segment is isoelectric, meaning that it is neither elevated nor depressed relative to the TP segment. The electrocardiographic definition of BER includes the following characteristics: 1) STE; 2) upward concavity of the initial portion of the ST segment; 3) notching or slurring of the terminal QRS complex; 4) symmetric concordant T waves of large amplitude; 5) widespread or diffuse distribution of ST segment elevation on the ECG; and 6) relative temporal stability.[2,4,5]

The STE begins at the "J" (or junction) point—the portion of the electrocardiographic cycle where the QRS complex ends and the ST segment begins. *(See Figure 1.)* The degree of J point elevation is usually less than 3.5 mm; the J point itself is frequently notched or irregular in contour and is considered highly suggestive of BER. The STE morphologically appears as if the ST segment has been evenly lifted upward from the isoelectric baseline at the J point, with preservation of the normal concavity of the initial, up-sloping portion of the ST segment/T wave complex—an important electrocardiographic feature used to distinguish BER-related STE from STE associated with acute myocardial infarction (MI). The STE encountered in BER is usually less than 2 mm, but may approach 5 mm in certain individuals, with 90% of individuals demonstrating less than 2 mm STE in the precordial leads and less than 0.5 mm in the limb leads. The degree of STE related to BER is usually greatest in the mid- to left precordial leads (leads V_2 to V_5) with less pronounced elevations in the remaining electrocardiographic leads. "Isolated" BER in the limb leads (i.e., no precordial STE) is a rare finding and should prompt consideration of another explanation for the observed ST segment abnormality. Prominent T waves of large amplitude and slightly asymmetric morphology are also encountered; the waves may appear "peaked," suggestive of the hyperacute T wave encountered in patients with acute MI. The T waves are concordant with the QRS complex and are usually found in the

Figure 1



Various electrocardiographic leads demonstrating BER-related findings. Upper panel—STE with concavity of the initial segment and prominent T wave in lead II. Middle panel—STE with notching of the J point in lead II. Lower panel—Prominent T waves with STE in a precordial lead. (From Brady WJ: Mastering the electrocardiogram: State-of-the-art techniques for evaluating ST segment elevation in acute myocardial infarction and other clinical syndromes. Part II. *Emerg Med Rep* 1998;19:88-93.]

Figure 2

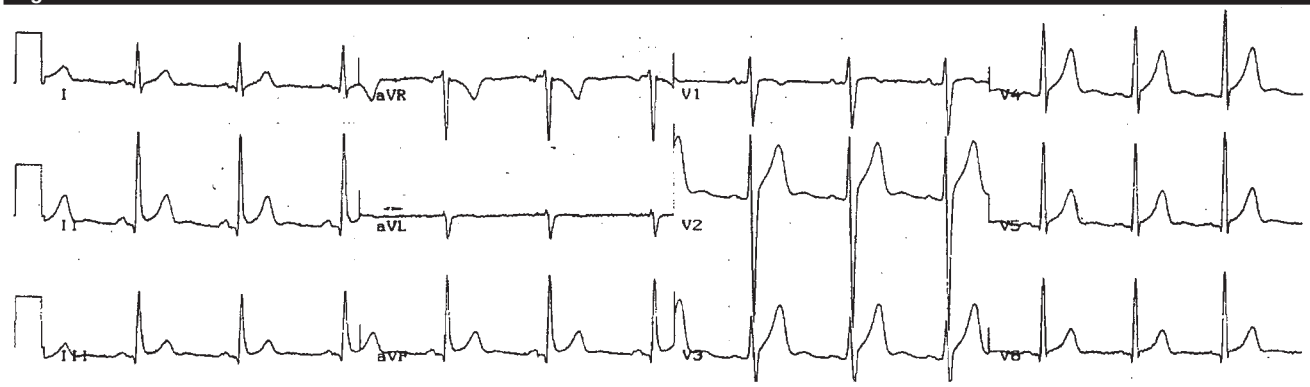

12-lead ECG of a patient with BER and widespread STE with prominent T waves. (From Brady WJ: Mastering the electrocardiogram: State-of-the-art techniques for evaluating ST segment elevation in acute myocardial infarction and other clinical syndromes. Part II. *Emerg Med Rep* 1998;19:88-93.)

Figure 3

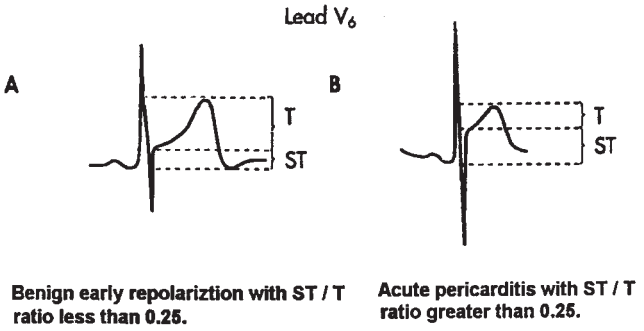

The STE/T wave height ratio may be helpful in discriminating between the STE resulting from BER and acute pericarditis. It is objectively assessed by comparing the heights of the ST segment and T wave in lead V_6— the ST segment/T wave magnitude ratio. Using the PR segment as the baseline for the ST segment and the J point as the beginning of the T wave, the heights are measured with calculation of the ratio. If the ratio is greater than 0.25, pericarditis is the likely diagnosis; with results less than 0.25, one should consider BER. (From Brady WJ: Mastering the electrocardiogram: State-of-the-art techniques for evaluating ST segment elevation in acute myocardial infarction and other clinical syndromes. Part II. *Emerg Med Rep* 1998;19:88-92.)

precordial leads. The height of the T waves in BER ranges from approximately 6.5 mm in the precordial distribution to 5 mm in the limb leads.[2,4,5] *(See Figure 2.)*

The electrocardiographic differential diagnosis of STE not only includes the benign variant BER but also potentially more malignant syndromes ranging from acute pericarditis and LVH to acute MI and LBBB. The emergency physician is quickly able to discard certain causes of STE in the chest pain patient with possible BER: 1) LBBB and other intraventricular conduction abnormalities by noting a normal QRS complex duration; 2) LVH with the absence of significant electrical forces in leads V_1 and V_6; and 3) left ventricular aneurysm if the patient lacks a history of MI. Acute pericarditis and BER are often difficult to distinguish on the ECG in that the STE encountered in the two syndromes is similar, both demonstrating a concavity of the initial, up-sloping portion of the ST segment/T wave complex.[6,7] Electrocardiographic features suggestive of BER of potential use in making this distinction include: 1) a normal PR segment (the PR segment is often depressed in patients with early pericarditis, particularly in lead V_6, with reciprocal PR segment elevation in lead aVR); 2) the static nature of the electrocardiographic changes (changes in the STE and other abnormalities evolve relatively rapidly in early pericarditis); 3) prominent, hyperacute T waves (the T wave in acute pericarditis frequently is of normal amplitude and morphology); and 4) the STE/T wave height ratio of less than 0.25 in lead V_6 (a ratio greater than 0.25 strongly suggests pericarditis).[6,7] The differentiation of STE due to BER from that associated with MI (yet another challenge) is made using several electrocardiographic issues, all suggestive of the early repolarization pattern, including: 1) the initial, up-sloping portion of the ST segment/T wave complex is concave in BER (compared to the either flattened or convex pattern observed in the acute MI patient); 2) reciprocal change is not encountered in patients with BER (considering the ECG of a patient with STE, ST segment depression greater than 1 mm in leads distant from the area of acute infarction should suggest the possibility of acute MI; and 3) the lack of evolving changes in the STE/T wave morphology (the performance of serial ECGs may demonstrate the dynamic electrocardiographic changes usually encountered in acute MI patients.[6,7] *(See Figure 3.)*

The importance of the BER pattern is found not in its presence—it does not indicate underlying cardiac disease. Rather, the emergency physician must recognize this pattern in the chest pain patient as BER and not mistake it for acute MI. BER is described as a normal variant pattern. Its presence, like the normal or nondiagnostic ECG, does not rule out the possibility of an early acute coronary ischemic event in a patient experiencing chest pain or other anginal equivalent complaints. Disposition decisions and therapeutic judgments—short of thrombolysis—must be made based upon the individual patient. ❖

References

1. Shipley RA, Hallaran WR. The four-lead electrocardiogram in two hundred normal men and women. *Am Heart J* 1936;11:325-345.
2. Mehta MC, Jain AC. Early repolarization on scalar electrocardiogram. *Am J Med Sci* 1995;309:305-311.
3. Parisi A, et al. The spectrum of ST segment elevation in the electrocardiograms of healthy adult men. *J Electrocardiography* 1971;4:136-144.
4. Golderger AL. *Myocardial infarction: Electrocardiographic differential diagnosis,* 4th ed. Mosby; St. Louis, 1991:100-126.
5. Aufderheide TP, Brady WJ. Electrocardiography in the patient with myocardial ischemia or infarction. In: Gibler WB, Aufderheide TP, eds. *Emergency Cardiac Care,* 1st ed. Mosby; St. Louis 1994:169-216.
6. Spodick DH. Differential diagnosis of the electrocardiogram in early repolarization and acute pericarditis. *N Engl J Med* 1976;295:523-526.

7. Glinzton LE, Laks MM. The differential diagnosis of acute pericarditis from the normal variant: New electrocardiographic criteria. *Circulation* 1982;65:1004-1009.

CME Questions

30. In a patient with atraumatic chest pain and ST-elevation (STE) on the ECG, electrocardiographic features suggestive of benign early repolarization include all of the following *except:*

a. concavity of the STE of the initial portion of the ST segment/T wave complex.
b. static nature of the STE over short-term observation in the ED.
c. isolated STE in the inferior leads in a 65-year-old patient.
d. absence of reciprocal ST segment depression in other electrocardiographic leads.

31. The following techniques have been used to reduce radial head subluxation (RHS):

a. Supination and flexion of the elbow
b. Supination and extension of the elbow
c. Hyperpronation at the wrist
d. a and c only
e. All of the above

32. The current theory in the pathogenesis of RHS is believed to be:

a. congenital subluxation of the radial head.
b. absence of the annular ligament, which holds the radius to the capitellum.
c. trapping of the annular ligament to the radiocapitellar joint.
d. bipartite annular ligament

33. All of the following statements are true *except:*

a. Epididymitis is a disease limited to adolescents and young adults.
b. Isolated tenderness at the superior pole of the testes is highly characteristic of torsion of appendix testis.
c. Absent cremasteric reflex, tender testicle, or abnormal testicular lie are characteristic of testicular torsion.
d. The physical examination is helpful when attempting to distinguish between testicular torsion, epididymitis, and torsion of appendix testis.

34. Which statement is *incorrect* regarding rapid sequence intubation?

a. Paralytic agents are only useful in patients with a GCS of less than 10.
b. Lidocaine blunts the rise in intracranial pressure.
c. Fentanyl can cause hypotension.
d. Increased intracranial pressure should be considered when choosing pharmacologic agents for rapid sequence intubation.

35. The differential diagnosis of STE on the ECG includes all of the following *except*:

a. benign early repolarization.
b. acute pericarditis.
c. acute MI.
d. right bundle branch block.

Annual Statement of Ownership, Management, and Circulation

Postal Bulletin — 21875, 9–1–94, Page 17

UNITED STATES POSTAL SERVICE

Statement of Ownership, Management, and Circulation
(Required by 39 U.S.C. 3685)

1. Publication Title	2. Publication No.	3. Filing Date
Emergency Medicine Alert	1 0 7 5 - 6 9 1 4	9/25/98
4. Issue Frequency	5. No. of Issues Published Annually	6. Annual Subscription Price
Monthly	12	$199.00

7. Complete Mailing Address of Known Office of Publication *(Street, City, County, State, and ZIP+4) (Not Printer)*
3525 Piedmont Road, Bldg. 6, Ste. 400, Atlanta, Fulton County, GA 30305

Contact Name: Willie Redmond

8. Complete Mailing Address of Headquarters or General Business Office of Publisher *(Not Printer)*
3525 Piedmont Road, Bldg. 6, Ste. 400, Atlanta, GA 30305

Telephone Number: 404/262-5448

9. Full Names and Complete Mailing Addresses of Publisher, Editor, and Managing Editor *(Do Not Leave Blank)*

Publisher *(Name and Complete Mailing Address)*
Brenda Mooney, 3525 Piedmont Road, Bldg. 6, Ste. 400, Atlanta, GA 30305

Editor *(Name and Complete Mailing Address)*
Catherine Harris, same as above

Managing Editor *(Name and Complete Mailing Address)*
David Davenport, same as above

10. Owner *(If owned by a corporation, its name and address must be stated and also immediately thereafter the names and addresses of stockholders owning or holding 1 percent or more of the total amount of stock. If not owned by a corporation, the names and addresses of the individual owners must be given. If owned by a partnership or other unincorporated firm, its name and address as well as that of each individual must be given. If the publication is published by a nonprofit organization, its name and address must be stated.) (Do Not Leave Blank.)*

Full Name	Complete Mailing Address
American Health Consultants	3525 Piedmont Road, Bldg. 6, Ste. 400
	Atlanta, GA 30305

11. Known Bondholders, Mortgagees, and Other Security Holders Owning or Holding 1 Percent or More of Total Amount of Bonds, Mortgages, or Other Securities. If none, check here. ☐ None

Full Name	Complete Mailing Address
Medical Economics, Inc.	Five Paragon Drive
	Montvale, NJ 07645

12. For completion by nonprofit organizations authorized to mail at special rates. The purpose, function, and nonprofit status of this organization and the exempt status for federal income tax purposes: *(Check one)* ☐ Has Not Changed During Preceding 12 Months ☐ Has Changed During Preceding 12 Months *(If changed, publisher must submit explanation of change with this statement)*

PS Form **3526**, July 1995 *(See instructions on Reverse)*

Page 18, 9–1–94, 21875 — *Postal Bulletin*

13. Publication Name: Emergency Medicine Alert

14. Issue Date for Circulation Data Below: September 1998

15. Extent and Nature of Circulation	Average No. of Copies Each Issue During Preceding 12 Months	Actual No. Copies of Single Issue Published Nearest to Filing Date
a. Total No. Copies *(Net Press Run)*	740	744
b. Paid and/or Requested Circulation (1) Sales Through Dealers and Carriers, Street Vendors, and Counter Sales *(Not Mailed)*	25	25
(2) Paid or Requested Mail Subscriptions *(Include Advertisers' Proof Copies/Exchange Copies)*	572	594
c. Total Paid and/or Requested Circulation *(Sum of 15b(1) and 15b(2)*	597	619
d. Free Distribution by Mail *(Samples, Complimentary, and Other Free)*	34	34
e. Free Distribution Outside the Mail *(Carriers or Other Means)*	0	0
f. Total Free Distribution *(Sum of 15d and 15e)*	34	34
g. Total Distribution *(Sum of 15c and 15f)*	631	653
h. Copies Not Distributed (1) Office Use, Leftovers, Spoiled	109	87
(2) Return from News Agents	0	0
i. Total *(Sum of 15g, 15h(1), and 15h(2)*	740	740
Percent Paid and/or Requested Circulation *(15c / 15g × 100)*	95	95

16. This Statement of Ownership will be printed in the November issue of this publication. ☐ Check box if not required to publish.

17. Signature and Title of Editor, Publisher, Business Manager, or Owner: Brenda L. Mooney, Publisher — Date: 9/25/98

I certify that all information furnished on this form is true and complete. I understand that anyone who furnishes false or misleading information on this form or who omits material or information requested on the form may be subject to criminal sanctions *(including fines and imprisonment)* and/or civil sanctions *(including multiple damages and civil penalties).*

Instructions to Publishers

1. Complete and file one copy of this form with your postmaster on or before October 1, annually. Keep a copy of the completed form for your records.
2. Include in items 10 and 11, in cases where the stockholder or security holder is a trustee, the name of the person or corporation for whom the trustee is acting. Also include the names and addresses of individuals who are stockholders who own or hold 1 percent or more of the total amount of bonds, mortgages, or other securities of the publishing corporation. In item 11, if none, check box. Use blank sheets if more space is required.
3. Be sure to furnish all information called for in item 15, regarding circulation. Fee circulation must be shown in items 15d, e, and f.
4. If the publication had second-class authorization as a general or requester publication, this Statement of Ownership, Management, and Circulation must be published; it must be printed in any issue in October or the first printed issue after October, if the publication is not published during October.
5. In item 16, indicate date of the issue in which this Statement of Ownership will be printed.
6. Item 17 must be signed.

Failed to file or publish a statement of ownership may lead to suspension of second-class authorization.

PS Form **3526**, July 1995

VT on Telemetry

By Ken Grauer, MD

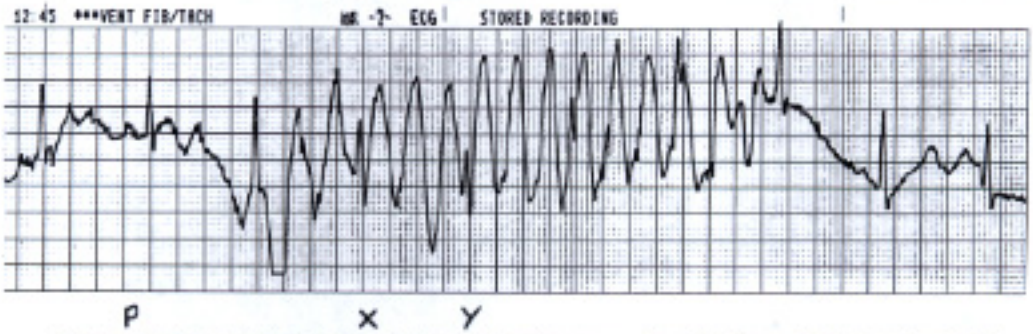

Figure. Lead II recording from an older adult in pulmonary edema. Is this ventricular tachycardia?

Clinical Scenario: The rhythm in the Figure was obtained from an older adult who presented in pulmonary edema. The patient was alert but in acute respiratory failure at the time this tracing was recorded. As shown in the figure, the telemetry recording interpreted this rhythm as ventricular tachycardia. *Do you agree?*

Interpretation: This is a difficult tracing to interpret. As noted above, the patient is in marked respiratory distress. This accounts for the wandering baseline and large amount of artifact. Nevertheless, the first two beats in the tracing appear to be sinus conducted—as suggested by a narrow and relatively normal-appearing QRS complex that is preceded by an upright P wave in this lead II recording. (The letter P indicates the P wave in front of the second QRS complex.) Note that the R-R interval between these first two sinus beats is four large boxes, which corresponds to a sinus rate of 75 beats/minute.

Thereafter, things change. Specifically, a series of large amplitude undulations at an exceedingly rapid rate are seen. However, despite telemetry indication of this run as *"VENT FIB/TACH"*—this is *not* the true interpretation of this rhythm.

The key to arriving at the correct diagnosis lies with use of *calipers* and appreciation that the underlying mechanism is normal sinus rhythm at a regular rate of 75 beats/minute. Set your calipers to this rate (i.e., to an R-R interval of 4 large boxes). While *maintaining* this setting, "walk" the calipers through the rhythm strip. Note that each advance of the calipers falls *right on* a narrow upright deflection—that in fact represents *persistence* of normal sinus rhythm at a regular rate of 75 beats/minute *throughout* the tracing. Admittedly, many of the QRS deflections are at least partially hidden by the large amplitude sinusoid-like undulations. Nevertheless, QRS complexes are regularly occurring every four large boxes. For example, directly above the letters x and y on this tracing are seen small narrow upright deflections that correspond to the fourth and fifth QRS complexes.

The large amplitude sinusoid-like undulations do *not* represent sinus tachycardia. They *can't*—because many of them occur too soon after the QRS complex (at a time when the *absolute* refractory period is operative). Proof that these large amplitude undulations represent artifact is forthcoming from the fact that the underlying rhythm (which is sinus) *continues* at a regular rate (of 75 beats/minute) *throughout* the tracing. ❖

In Future Issues: **Handlebars as Hidden Spears**