AHC Media LLC

Rapid Access Card Enclosed

PEDIATRIC Emergency Medicine Reports™

The Practical Journal of Pediatric Emergency Medicine

Volume 14, Number 2 February 2009

Knee and ankle injuries are very common in pediatrics. Sports and recreational activities are frequent sources of injury, hence are sources of typical emergency department (ED) visits. Although sprains and contusions frequently occur, it is critical that the unique aspects of the pediatric skeleton and its associated vulnerability are considered. Imaging and treatment are focused on identification of fractures and associated injuries; correct immobilization and appropriate follow-up, based on the injury, are necessary to maximize the outcome for each injury.

Physeal growth plate injuries are an example of a fracture pattern that is unique to children and mandate an understanding of the process of growth of a pediatric bone and potential injury patterns. This article provides a review of common pediatric knee and ankle injuries with an emphasis on the special pediatric features.

— The Editor

Knee and Ankle Injuries in Children and Adolescents

Authors: **Brian L. Springer, MD, FACEP,** Assistant Professor and Sports Medicine Director, Wright State University Boonshoft School of Medicine, Department of Emergency Medicine, Kettering, OH; **Scott W. Ahrenholz, DO, CAQ,** Sports Medicine Physician, Fairview Sports and Orthopedic Care, Wyoming, MN.

Peer Reviewer: **Moira Davenport, DO,** Attending Physician, Department of Emergency Medicine and Orthopedic Surgery, Allegheny General Hospital, Drexel University School of Medicine, Pittsburgh, PA.

Introduction

Musculoskeletal injuries or pain complaints comprise a large proportion of visits to EDs every year. In 2005, the National Hospital Ambulatory Medical Care Survey (NHAMCS) estimated there were 41.9 million ED visits related to injury.[1] Sports and recreational activities remain a common source of injury; from 1997 to 2001, NHAMCS estimated injuries from sports prompted 2.5 million visits yearly in pediatric patients, or 23% of all injury-related visits.[2] The number of children and adolescents participating in organized athletics has increased steadily over the last 10 years, along

Statement of Financial Disclosure

In order to reveal any potential bias in this publication, and in accordance with Accreditation Council for Continuing Medical Education guidelines, we disclose that Dr. Dietrich, editor-in-chief, Dr. Skrainka (CME question reviewer), Drs. Springer and Ahrenholz (authors) and Davenport (peer reviewer) report no consultant, stockholder, speaker's bureau, research, or other financial relationships with companies having ties to this field of study.

with an associated rise in ED visits. The Centers for Disease Control and Prevention found non-fatal sports- and recreation-related ED visits increased from 3.7 million in 1997–1998 to 4.3 million in 2000–2001, the highest percentage being persons age 10–14 years.[3] Links of sedentary lifestyle to current health concerns such as the obesity epidemic and appearance of Type 2 diabetes mellitus in younger patients have led to a push by public health officials for increased physical activity. While the long-term benefits may be significant, one suspects that this may also contribute to greater numbers of acute and overuse orthopedic injuries.[4]

All pediatric body parts may be injured in the course of normal day-to-day activities or while engaging in sports. However, the knee and ankle joints are perpetually involved in almost all recreational and athletic activities, particularly those that involve running and jumping. Mean age of presentation for lower-extremity injury is 12 years old, with a slightly higher percentage of males being injured. However, this may be activity related. Sprains, contusions, and fractures remain the most common injury types. Soccer poses the greatest risk for knee injury, while basketball poses the greatest risk of injury to the ankle and foot.[5]

This article will review the unique physiologic features of the pediatric patient that contribute to knee and ankle injury and affect treatment decisions, and the most common childhood knee and ankle injuries likely to be seen in the ED.

Pediatric Emergency Medicine Reports™ (ISSN 1082-3344) is published monthly by AHC Media LLC, 3525 Piedmont Road, N.E., Six Piedmont Center, Suite 400, Atlanta, GA 30305. Telephone: (800) 688-2421 or (404) 262-7436.

Associate Publisher: Coles McKagen
Managing Editor: Allison Weaver
Marketing Manager: Schandale Kornegay
GST Registration No.: R128870672
Periodicals Postage Paid at Atlanta, GA 30304 and at additional mailing offices.

POSTMASTER: Send address changes to ***Pediatric Emergency Medicine Reports***, P.O. Box 740059, Atlanta, GA 30374.

Back issues: $65. Missing issues will be fulfilled by customer service free of charge when contacted within one month of the missing issue's date.

Accreditation

AHC Media LLC is accredited by the Accreditation Council for Continuing Medical Education to provide continuing medical education for physicians.

AHC Media LLC designates this educational activity for a maximum of 30 *AMA PRA Category 1 Credits™*. Physicians should only claim credit commensurate with the extent of their participation in the activity.

Approved by the American College of Emergency Physicians for 30 hours of ACEP Category 1 credit.

This continuing medical education activity has been reviewed by the American Academy of Pediatrics and is acceptable for up to 30 (2.5 per issue) AAP credits. These credits can be applied toward the AAP CME/CPD Award available to Fellows and Candidate Fellows of the American Academy of Pediatrics.

This CME activity is intended for emergency and pediatric physicians. It is in effect for 36 months from the date of the publication.

This is an educational publication designed to present scientific information and opinion to health professionals, to stimulate thought, and further investigation. It does not provide advice regarding medical diagnosis or treatment for any individual case. It is not intended for use by the layman. Opinions expressed are not necessarily those of this publication. Mention of products or services does not constitute endorsement. Clinical, legal, tax, and other comments are offered for general guidance only; professional counsel should be sought for specific situations.

Subscriber Information

Customer Service: 1-800-688-2421
Customer Service E-Mail Address:
customerservice@ahcmedia.com
Editorial E-Mail Address: allison.weaver@ahcmedia.com
World-Wide Web page: http://www.ahcmedia.com

Subscription Prices

1 year *with* 30 ACEP, AMA, or AAP Category 1 credits: $439;
1 year without credit: $389;
Add $17.95 for shipping & handling
Multiple copies:
Discounts are available for group subscriptions, multiple copies, site-licenses or electronic distribution. For pricing information, call Tria Kreutzer at 404-262-5482.
One to nine additional copies: **$350 each;**
10 or more additional copies: **$311 each.**
Resident's Rate: **$194.50**
All prices U.S. only. U.S. possessions and Canada, add $30 postage plus applicable GST.
Other international orders, add $30.

Questions & Comments

Please call **Allison Weaver,** Managing Editor, (617) 629-5951, or e-mail allison.weaver@ahcmedia.com

AHC Media LLC

The Pediatric Skeleton

There are unique features of the pediatric bone that alter the injury patterns as compared to the adult. These patterns include physeal, apophyseal, and overuse injuries, and stress fractures.

Physeal. Elongation of a long bone occurs at the growth plate, or physis. This area is comprised of cartilage, and is capped by the bony epiphysis. In many joints, the epiphysis is the end of the bone that forms the articular surface.[6,7] Cartilaginous chondrocytes in the proximal growth plate proliferate, mature, and calcify, resulting in the deposition of new bone at the metaphysis of the growth plate. Blood supply to the metaphysis is provided by perichondral arteries that also supply the remainder of the diaphyseal bone. Blood supply to the epiphysis is limited to small epiphyseal arteries; therefore, disruption of the epiphysis may lead to compromised arterial flow and subsequent growth delay, non-union, or avascular necrosis.[8]

Physeal (growth plate) fractures have classically been described using the Salter-Harris classification system. *(See Figure 1.)* The most commonly seen injuries are Salter-Harris II fractures. The larger number carries an increased risk for growth plate arrest. **Salter-Harris type I** is a fracture through the physis; the physis is tender to palpation and may appear widened on radiographs. **Salter Harris type II** fractures are transverse through the physis into the metaphysis, and **Salter-Harris type III** fractures extend from the physis into the epiphysis (resulting in an intra-articular fracture).*(See Figure 2.)* **Salter-Harris type IV** fractures project through the metaphysis, across the physis, and through the epiphysis (these also have the potential for intra-articular involvement). **Salter-Harris type V** fractures result from compression to the physis, and are difficult to differentiate from a non-displaced Salter-Harris I fracture. Salter-Harris V fractures are often diagnosed retrospectively, following premature closure or asymmetric growth of the physis. Salter-Harris I and V injuries are typically difficult to diagnose in the acute setting; clinical suspicion is key.

Non-displaced Salter-Harris I and II fractures have an excellent prognosis, and should be treated with splint immobilization and outpatient followup. Significantly displaced fractures may require closed reduction, and a pediatric orthopedist should be consulted. Mild displacement (the actual degree of displacement accepted is dependent on the bone involved) is acceptable in adolescents, since they have little growth remaining; premature closure is unlikely to create significant deformity or limb-length discrepancy.[9] Growth plate arrest in Salter-Harris III fractures is rare; however, by definition the fracture involves the articular surface, and thus anatomic reduction prior to immobilization is critical. Salter-Harris IV fractures may result in growth plate arrest as well as damage to the articular surface, and again an orthopedist should be consulted early. In a Salter-Harris V injury, little can

Figure 1. Salter-Harris Classification

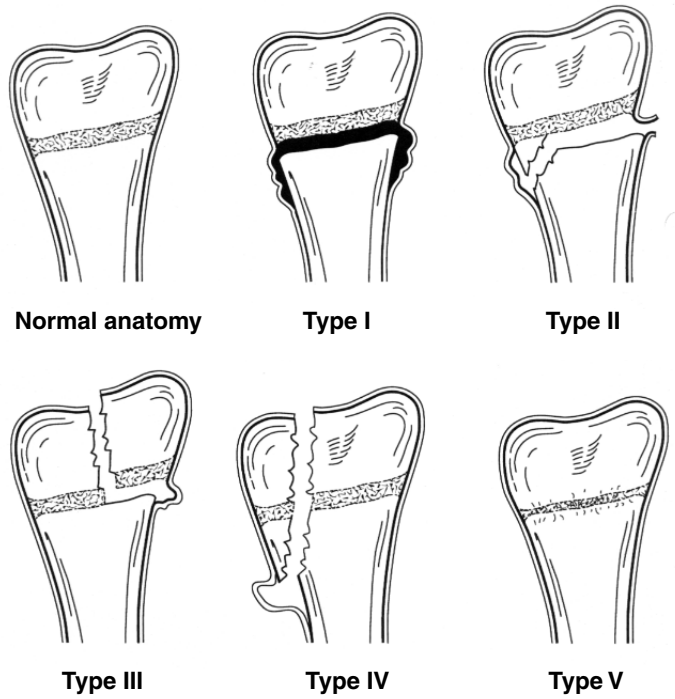

Original illustration courtesy of Steven Getch, Summa Health System, Akron, OH.

Figure 2. Salter-Harris III Fracture of the Distal Tibia

This fracture involves both the distal growth plate and articular surface of the joint, and should be treated with immobilization and prompt orthopedic follow-up.

be done to alter prognosis; if suspected, immobilize the injured area and refer to an orthopedist.

Avulsion Fractures. Similar to adults, the most commonly seen acute orthopedic injuries are contusions, muscle and tendon strains, and ligament sprains. Unlike in adults, the weak link in the pediatric kinetic chain is not connective tissue, but rather the growth plate. Children who sustain a significant sprain or strain in the vicinity of a bony attachment should receive radiographic evaluation. Films should be carefully examined for evidence of avulsion fracture. If the patient is tender over an apophysis, ensure the growth plate itself has not been avulsed. If uncertain, a comparison view of the contralateral growth plate may be obtained.

Metaphyseal Fractures. Thick periosteum and elastic bone result in unique pediatric fracture patterns. Compressive forces to the bone leading to failure result in a buckle or torus fracture, often at the junction of the metaphysis and diaphysis. These fractures are easy to overlook, especially when small. Greenstick fractures are incomplete fractures where the bone bows under stress, resulting in compression on the concave side and cortical disruption on the convex side.

Overuse Injuries. The pattern of overuse injury in the pediatric population has changed in recent years.[10,11] Children involved in free play or seasonal sports rarely develop overuse syndromes. Growing participation in competitive youth sports, combined with a trend towards year-round, same-sport participation, has led to an increase in overuse injury.

Like adults, children can develop inflammatory or degenerative changes to muscle and tendon. Once again, the growth plates remain the areas most vulnerable to injury. Traction apophysitis occurs with repetitive stress at the site of an apophysis (such as the tibial tuberosity, iliac crest, or calcaneous).[12] Patients initially note pain during athletic activity that sometimes progresses to pain during everyday activity. The physis will be tender to palpation, and soft tissue swelling may be evident. Radiographs may demonstrate mild growth plate widening, but are most often normal. From the standpoint of the emergency physician, the most important early intervention is cessation of inciting activity until symptoms abate.[13] A gradual return to activity is warranted, with an emphasis on cross-training to prevent further overuse and to maintain fitness in the interim.

Stress Fracture. Stress fractures are a common overuse injury that may be seen in the knee, ankle, or any bone that undergoes repetitive stress.[14,15] *(See Figure 3.)* Bone is living tissue and displays a typical physiological response to overload. Repetitive stress (either from direct shock or from repeated contraction of an attached muscle) results in micro-

Figure 3. Stress Fracture of the Distal Fibula

Note the late, sclerotic appearance of the bone secondary to physiologic repair.

fracture that triggers a healing cascade. Over time, areas affected by gradual overload will strengthen; however, if the rate of damage exceeds the rate of repair, a stress fracture may occur. History often reveals a typical scenario for stress fracture: a recent increase in activity (usually over several weeks) precipitates gradually worsening pain that impedes athletic activities and may affect daily activities. Physical examination reveals localized tenderness at the fracture site, and overlying soft tissue swelling may be present. Radiographs are often normal until late in the disease process, with periosteal elevation being the earliest finding. Eventually, sclerotic changes or a fracture line becomes evident. Diagnosis may be confirmed early with either magnetic resonance imaging (MRI) or bone scan.[16] ED patients with stress fractures, either clinically suspected or evident on radiograph, should be restricted from high-impact activities and referred to an orthopedist for followup.

The Pediatric Knee

Introduction. Sports and recreational activities are the most common cause of acute and chronic knee injuries in the pediatric and adolescent population. As previously noted, soccer is the sport most commonly associated with acute knee injury.[5]

A concerning phenomenon is the increasing number of anterior cruciate ligament (ACL) sprains in skeletally immature athletes. This is presumably due to increasing participation in competitive athletics at an increasingly younger age. Recognition of this injury is important, as its natural history when untreated is instability and reinjury.[17]

Anatomy. Four bones (femur, tibia, fibula, and patella) and four major ligaments (two cruciate and two collateral) make up the major structures of the knee. The femur and tibia articulate with each other in the sagittal plane to form a hinge joint. The patella, a sesamoid bone located in the anterior knee, protects the joint and increases the efficiency of the quadriceps during leg extension. The medial collateral ligament (MCL) prevents destabilization of the knee with valgus stress, as the lateral collateral ligament (LCL) does with varus stress. The ACL resists anterior translation of the tibia in relation to the femur, and the posterior cruciate ligament (PCL) prevents posterior translation. Articular cartilage covers the medial and lateral femoral condyles, tibial plateau, and the undersurface of the patella. The medial and lateral menisci are present over the respective portions of the tibial plateau. Skeletally immature patients have open growth plates in the distal femur as well as the proximal tibia and fibula. The patel-

la has multiple centers of ossification that fuse as the child ages. The primary motions of the knee are flexion and extension, with little additional physiologic rotation in extension.[18]

History. Obtaining a good history, including time, location, activity, and specific mechanism (if known) of injury is crucial in assessment of knee complaints. Inquire about attempts to return to play or activity; more severe injuries often result in an inability to continue or to ambulate under one's own power. Other important aspects of the history include the presence of a "pop" at the time of injury, the knee buckling or "giving way," or the knee locking, and subsequent soft tissue swelling, bruising, or joint effusion. Inquire about previous knee trauma or surgeries. If the injury is chronic in nature, ask about the onset of pain, course, current participation in athletics and recreational activities, effect of activities on the pain, and any prior treatment and its effects.[19,20]

Physical. Physical examination of the knee begins with general inspection, looking for soft tissue swelling, effusion, deformity, or bruising. Comparison to the contralateral knee facilitates identification of abnormalities. Significant effusion following trauma to the knee may indicate a hemarthrosis, which typically is attributed to one of the following injuries in the acute setting: intra-articular fracture, patellar dislocation, cruciate ligament tear, or meniscus injury.

Palpate the anterior, posterior, medial, and lateral surfaces of the joint, looking for any maximum points of tenderness. Tenderness of the medial and lateral joint lines may indicate cartilage injury but may be present in other benign conditions. Palpate the femoral condyles while in a flexed position, the superior and inferior poles of the patella, the patellar tendon and its insertion on the tibial tubercle, and the head and neck of the fibula. Specific tenderness of the physes of the distal femur and proximal tibia and fibula may indicate growth plate injury.[21] Gentle translation of the patella causes pain or apprehension following patellar subluxation or dislocation. Active and passive range of motion should be checked, noting any asymmetry with the contralateral knee. Feel for crepitus within the joint while performing motion testing.

Lachman and anterior drawer testing should be performed to assess the integrity of the ACL. The Lachman test is performed by placing one hand on the distal thigh and the other hand on the proximal leg; with the knee in approximately 20°–30° flexion, translate the tibia anteriorly on the femur. Anterior drawer testing is performed by placing the ipsilateral foot flat on the table with the patient supine and the knee in 90° flexion. Apply an anteriorly directed force on the proximal lower leg, attempting to translate the tibia anterior on the femur. Assess the amount of anterior translation as compared to the contralateral knee, and feel for a definitive "endpoint." Increased translation and soft endpoint upon Lachman and anterior drawer testing indicate possible ACL injury. The PCL is examined with posterior drawer testing. Place the patient into the same position used for anterior drawer testing, only now direct posterior force on the proximal tibia. Assess for laxity and presence of an endpoint. Varus and valgus stress on the knee in approximately 20°–30° flexion and in full extension examines the LCL and MCL, respectively, assessing for both laxity and pain. The presence of laxity in full extension may indicate a more severe collateral injury. Finally, the ability to bear weight, the patient's gait, and ability to squat or hop on the affected leg give useful information regarding the severity of the injury, provided the patient is able to cooperate.[18-20]

Imaging. Emergency imaging of the knee most often involves the use of plain radiography. Between two and four standard views may be used. At minimum, anteroposterior and lateral views should be obtained; internal and external obliques may help detect subtle fractures of the tibial plateau and patellar margin.[22] The Ottawa and Pittsburgh knee rules are clinical decision-making tools designed to cut down on unnecessary radiographs in the emergency setting. Originally designed for adults, the Ottawa rules have been prospectively validated in the pediatric population, with varied results.[23,24] As such, they should be used with caution in the pediatric population. Under the Ottawa Knee Rules, x-ray films of the knee should be obtained if the patient is more than 55 years old; has tenderness over the fibular head; cannot flex the knee to 90°; or cannot bear weight for four steps immediately following the injury and upon evaluation.[25] The Pittsburgh Knee Rules recommend a radiograph be obtained in any patient with a fall or blunt trauma about the knee when the patient is younger than 12 years and older than 50 years of age and is unable to take four weight-bearing steps in the ED.[26] Both sets of rules were designed for sensitivity in detecting clinically significant injury, and when used in the pediatric setting should never supersede clinical gestalt.

Radiographs should be examined for bony alignment, cortical bone integrity, and condition of the growth plates. Computed tomography (CT) scans of the knee can provide additional benefit when significant bony injury is present or if higher resolution is needed to view the bony structures, but is less useful when evaluating soft tissues. MRI of the knee is not often indicated acutely within the ED, and may be performed in the outpatient setting to further assess the soft tissues of the joint, particularly meniscus and articular cartilage and the major ligaments. MRI also demonstrates bone edema, indicating contusion or microfracture.[27]

Specific Knee Injuries

Acute Fractures Involving the Knee. Fractures of the knee may involve the growth plates, cortical bone, or both. Mechanism of injury may involve direct impact with one of the bones, or directional stress in a non-contact situation. Supracondylar and intracondylar fractures, along with tibial plateau and patellar fractures, may involve the articular sur-

face. In this setting, pain and swelling develop rapidly. Exam often reveals an effusion, decreased range of motion, and focal bony tenderness. Plain radiographs of the knee, especially AP and lateral, will reveal the majority of fractures. CT scan of the knee can further delineate a bony injury, if requested by the orthopedic surgeon. If the fracture is small and non-displaced, the patient may follow up as an outpatient. A knee immobilizer will support and protect the area until followup. Larger and displaced fractures, particularly those involving the joint surface, at minimum require orthopedic evaluation with possible surgical intervention.

Distal femoral physis fractures and proximal tibial physeal fractures comprise a small number of lower extremity growth plate injuries, and an even smaller proportion of all pediatric leg fractures. Automobile crashes are responsible for a large percentage of these injuries in younger patients, while adolescent femoral physeal fractures most often occur during sports. In both fractures, the most common mechanism is hyperextension, and the most common fracture pattern is Salter-Harris II. Significant hyperextension may result in injury to the popliteal artery, so thorough vascular assessment should be performed. Patients with non-displaced Salter-Harris I and II fractures should be immobilized and made non-weightbearing. Displaced fractures and types III and IV should be evaluated by an orthopedic surgeon, and often require closed reduction or percutaneous fixation.[21]

Tibial tuberosity fractures occur at the insertion of the patellar tendon. Rapid knee extension or eccentric loading of the quadriceps results in avulsion of a bony fragment of the anterior tibial epiphysis. Osgood-Schlatter disease may predispose some patients to this injury. Unless significant displacement of the fragment occurs, these patients can be immobilized and referred for outpatient followup.[21,28]

The tibial eminence or spine provides a bony insertion for the ACL. Hyperextension, rotation, or valgus stress may result in an avulsion fracture of the insertion. This occurs typically in patients age 8–14 years old.[21] Patients with this injury should be immobilized and advised to follow up with an orthopedic surgeon. Tibial eminence fractures carry a good prognosis, although many leave residual laxity in the knee. Those with minimally displaced fragments may respond well simply to casting of the leg. More significantly displaced fractures may require surgical fixation of the fragment, but this is controversial.[29]

Patellar fractures most often result from direct trauma to the anterior knee. *(See Figure 4.)* Patients present with swelling, tenderness, and weakness or failure of the extensor mechanism. These fractures are usually transverse, but a "sleeve" fracture may be seen where articular cartilage and a portion of bone from the inferior pole of the patella are avulsed. Patients should be immobilized and given timely outpatient referral. Fractures that are not significantly displaced often respond well to long leg casting, but more extensive injuries may require surgical intervention.[21]

Patellar Subluxation/Dislocation. Patellar subluxation and dislocation most often occur laterally. They are most often non-contact injuries, occurring with the foot of the affected leg planted, followed by an abrupt quadriceps contraction with the knee flexed. Tearing of the medial retinaculum and medial patellar ligament allows for lateral translation, and may be accompanied by a "pop" and rapidly appearing effusion. People who fall down and then stand or extend the leg may spontaneously reduce the patella. If not spontaneously reduced, the patella should be reduced by hip flexion and knee extension, along with gentle medial traction on the patella. Examination following acute subluxation reveals patellar tenderness, particularly on the lateral facet, as well as apprehension with lateral translation. With a dislocation, pain is typically more severe and the patient often refuses to flex the knee, making motion testing difficult. Significant hemarthrosis occurs, although the swelling can be less prominent with recurrent injury. Radiographs of the knee, particularly a dedicated patellar or "sunrise" view, should be obtained to investigate for patellar or intra-articular fracture. Acute subluxation may simply require rest, ice, and isometric quadriceps exercises to avoid muscle atrophy. For dislocations, the patient can be placed in a knee immobilizer in full extension and instructed to avoid weight-bearing activities for the following 24–48 hours, applying ice frequently. He or she can begin isometric straight-leg exercises as soon as comfort allows. Follow up with a specialist is indicated over the next several days to establish care and progress rehabilitation of the injury.[29,30]

Collateral Ligament Sprain. A valgus stress to the joint causes MCL sprain, and a varus stress can injure the LCL. Of the two, the MCL is injured more frequently. The stress can be applied by impact with an object or another athlete, or can come from a sudden side-to-side movement without contact. The patient may describe a "pop" and complain of pain medially or laterally for the MCL and LCL, respectively. Bruising and soft tissue swelling may develop at the injury site. Patients often remain ambulatory following isolated collateral sprains. Treatment of MCL and LCL sprains includes avoidance of painful activities, ice, and analgesics. Collateral hinged braces are useful, but often unavailable in the ED. True immobilization is not recommended. If significant instability is noted on exam, or the patient complains of severe discomfort or instability with ambulation, crutches with a prescription for a hinged knee brace (fully unlocked) is appropriate. Light range of motion and low-impact activities like cycling may be started soon after the injury. Collateral ligament sprains rarely require surgical intervention, but may occur in conjunction with another injury, particularly ACL or PCL injury.[21,29]

Cruciate Ligament Sprain. Prior to skeletal maturity, ACL tears are seen more often in males; following that time,

Figure 4. Transverse Patellar Fracture Following an Acute Fall onto a Flexed Knee

Although bipartite patella may be a normal variant, tenderness following trauma should be considered an acute fracture until proven otherwise.

they occur more frequently in girls.[31] Overall, females are two to eight times more likely to sustain an ACL tear.[32] ACL sprain and tear are most often non-contact injuries. The typical history of injury is a rapid stop or change of direction while the foot remains planted, resulting in either rotation of the flexed knee or joint hyperextension. Often, the patient feels or hears a pop. Sudden onset of pain and buckling of the knee immediately follow. Frequently, the child is unable to ambulate without assistance, and cannot return to activity. An effusion ensues over the next 24 hours, but may present sooner. The patient loses range of motion due to pain, swelling, and diminished muscle contraction of the quadriceps. Physical exam of the knee with an ACL sprain or tear usually demonstrates effusion and lack of full extension. The Lachman test and anterior drawer test are abnormal, with increased anterior translation of the tibia on the femur and lack of firm endpoint. These tests are operator-dependent and can be difficult in the acute setting if the patient is guarding.[19]

Radiographs should be obtained to investigate for fracture associated with the injury. In younger patients, a tibial eminence fracture may occur instead of rupture of the ACL, as noted previously. A Segond fracture, involving a small avulsion of the lateral aspect of the tibial plateau, is considered pathognomonic for ACL injury. *(See Figure 5.)* In the acute setting, one should advise rest and ice. The patient can ambulate with crutches, and may begin gentle isometric quadriceps exercises.[29] Orthopedic referral is needed for further care. MRI is usually obtained as an outpatient to both confirm injury and assess adjacent soft tissue structures such as the meniscus. ACL reconstructive surgery is indicated in patients who are young and lead active lifestyles. Controversy remains regarding the benefits of delayed repair versus early "physeal-safe" surgical repair in the skeletally immature patient.[17]

PCL sprains may occur in conjunction with other ligament injuries, or can be isolated. Mechanisms for injury include direct contact with the anterior proximal tibia while the knee is flexed as well as hyperflexion or hyperextension. A "pop" may accompany the event, and effusion follows. Observe for obvious step-off or posterior sag of the tibia on the femur, then evaluate for increased posterior translation with posterior drawer testing. Radiographs should be obtained to rule out fracture. Initial treatment is similar to that for ACL sprain — rest, ice, crutches, and gentle motion exercises. Outpatient MRI can demonstrate the injury and evaluate the soft tissues. A ruptured PCL may respond well to knee strengthening and functional bracing. Surgical reconstruction may be indicated for recurrent instability.[29,33]

Chronic (Overuse) Knee Injury. Chronic anterior knee

Figure 5. Segond Fracture

Avulsion fracture of the lateral tibia is strongly correlated with ACL rupture, and should prompt investigation of ligamentous stability of the knee.

Used with permission from: Johnson TR, Steinbach LS (eds.) *Essentials of Musculoskeletal Imaging*. Rosemont, IL: American Academy of Orthopaedic Surgeons; 2004:515.

pain in an active child goes by many names, but is frequently called patellofemoral pain syndrome (PFPS). PFPS occurs more frequently in females involved in running and jumping sports and may be related to lateral tilting or maltracking of the patella in the patellar groove, although the etiology of pain is not completely clear. PFPS appears to occur more often in athletes than in non-athletes.[34] Physical exam is usually unremarkable. Rarely, effusion is noted. Patellar irritability may be present, as well as tenderness about the patella and lateral facet of the patellofemoral joint. Pain may be reproducible by placing the knee in full extension. Examine for medial quadriceps (vastus medialis) weakness or atrophy, and assess hamstring flexibility. Radiographs of the knee, particularly a Merchant or sunrise view, may demonstrate lateral patellar misalignment but are typically normal. The decision to obtain radiographs in the ED may be affected by clinical findings, chronicity of the condition, and the availability of followup care for the individual. Treatment for PFPS includes reassurance, rest from painful activities, and avoidance of prolonged knee flexion. Strengthening the medial quadriceps with isometric thigh exercises can reduce symptoms. Improving hamstring flexibility also may reduce pressure on the anterior knee. Fitting the patient with a patellar support brace can provide comfort in the acute setting and the patient can wean brace use when pain improves.[35-37]

Osgood-Schlatter disease is a condition in which repeated traction from the patellar tendon on the tibial tubercle causes stress on the apophysis.[38] This typically develops in growing athletes involved in running and jumping sports, and occurs more frequently in males. Frequently there is no specific injury preceding the onset of pain, but multiple falls on the bony prominence may exacerbate symptoms. Examination most often reveals localized soft tissue edema and tenderness over the tibial tubercle, along with pain with passive knee flexion and resisted extension. Radiographs may demonstrate widening of the apophysis on lateral view. Treatment includes limitation of athletic activities as pain allows, ice, and appropriate quadriceps and hamstring flexibility and rehabilitation exercises. The area also may be protected with a protective pad to avoid direct contact on the painful apophysis during contact sports. The pain of Osgood-Schlatter disease usually completely resolves when growth is finished at the proximal tibia, but a prominent tibial tubercle can persist throughout adulthood.[34,39]

Osteochondritis dissecans (OCD) is a lesion of subchondral bone, just below the level of the articular cartilage. It can result from trauma, localized ischemia, or possibly from genetic factors.[40] OCD may be seen in several joints, including the ankle, elbow, and knee. In the knee, the injury most commonly occurs at the lateral aspect of the medial femoral condyle, and presents as chronic, non-specific knee pain. Traumatic etiology may be implicated, through contact of the condyle with the tibial spine. Patients often complain of generalized knee discomfort, with or without swelling. If a cartilaginous loose body is present, catching or locking may occur. *(See Figure 6.)*

On physical exam, a joint effusion often is present, and the patient may be tender to palpation over the affected femoral condyle with the knee in full flexion. The Wilson test may be used to evaluate for OCD. The knee is flexed to 90° with internal rotation of the tibia. As the knee is then extended, pain at approximately 30° of flexion indicates a positive test, and possible osteochondral lesion.[41] Plain AP and lateral radiographic views should be obtained to investigate the injury, including size, location, and potential displacement of the defect. A tunnel view radiograph, an AP film taken with the knee in flexion to focus on the femoral condyles, may better demonstrate the lesion. In the ED setting, patients with OCD should be removed from physical activities and advised to follow up with an orthopedist or sports medicine specialist. Younger children with smaller osteochondral lesions have a better prognosis for healing with activity modification and

appropriate rest over several weeks; it may take up to 12 weeks for complete healing.[28] Older patients, those with larger lesions (over 1–2 cm), and those with loose intra-articular bodies have a poorer prognosis, and often require further investigation of the area with MRI. Treatment for non-healing OCD involves arthroscopic surgery to promote revascularization or possible stabilization of the area if the lesion is intact, or removal of the fragment if it is loose in the joint.[42]

The Pediatric Ankle

Introduction. While estimates vary widely, ankle injuries are common. In the United States, there are between 1 million and 10 million ankle injuries annually, making them the most common injury seen in the primary care setting. Ankle sprains alone account for 25%–30% of all sports-related injuries.[43] Activities associated with the highest rates of ankle injury are those involving jumping (especially in close proximity to another individual) and rapid changes in direction while running. Specific sports that put young athletes at risk include football, basketball, soccer, and volleyball.[44] Interestingly, although athletic endeavors may result in ankle injury, obesity may put children at risk, as well. Higher body mass index may be associated with increased risk of ankle injury, and with greater risk of long-term ankle dysfunction following injury.[45,46]

Anatomy. The ankle joint is a hinge joint formed by the articulation of the talus, tibia, and fibula, and allows plantarflexion and dorsiflexion of the foot. The subtalar joint is formed by the articulation of the talus and calcaneous, and allows for inversion and eversion.

The ligaments of the lateral ankle are the most frequently injured and include the anterior talofibular ligament (ATFL), calcaneofibular ligament (CFL), and the posterior talofibular ligament (PTFL). Injury of the lateral ligaments occurs most often due to acute inversion of the foot. The medial (deltoid) ligament is fan-shaped and connects the medial malleolus to the navicular, calcaneous, and talus. It is injured far less frequently than the lateral ligaments, and typically occurs with eversion and/or external rotation of the foot. The syndesmosis stabilizes the distal tibia and fibula and may be injured with forced internal or (more commonly) forced external rotation of the foot.

History. A thorough history is useful in assessing mechanism for injury. Determine the time of injury, activity, and position of the foot and ankle when pain or instability was first noticed. Ask if any swelling of the foot or ankle developed subsequently. If the child cannot give a proper history, obtain it from an available adult, older sibling, or other witness. In chronic injury, inquire about recreational and athletic activities and any recent change in training time or intensity. Ascertain any history of instability or of the ankle "giving way." Ask what treatments the patient or parents have already attempted, and if they have been previously evaluated by a physician, therapist, or athletic trainer.

Figure 6. Osteochondral Loose Body

Note the OCD lesion on the medial femoral condyle. Timely referral for surgical excision of the loose body is required.

Physical. The ankle examination is best performed with the patient sitting and the lower leg hanging off the examination table. Goals of the ED evaluation are straightforward: determine the neurovascular status of the lower extremity, assess the gross ligamentous stability of the ankle, reveal the likelihood of bony injury, and determine if radiographic evaluation is necessary.

Observe the ankle and foot for swelling or ecchymosis. Comparison to the contralateral lower extremity is useful. Active motion with plantarflexion, dorsiflexion, inversion, and eversion should be assessed. Palpation of the dorsalis pedis and posterior tibial arteries may be challenging if significant soft-tissue swelling is present; if capillary refill is inadequate or vascular injury is strongly suspected, a Doppler may be used. Grossly assess sensation via light touch and pinprick (pinch), being aware that both hyper- and hyposensitivity may be present early in injury. Palpate the foot and ankle using a systematic approach, so as not to miss any injury. Always palpate a joint above and joint below the injured body part. Start at the knee, paying close attention to the proximal fibula, and work down, pressing anterior to assess for syndesmosis tenderness. Palpate the ankle joint

Figure 7. Medial Malleolus Fracture

This fracture of the medial malleolus resulted from a sports-related injury.

itself, being alert for tenderness in either malleolus or its growth plate. Palpate the base of the fifth metatarsal to assess for proximal shaft fracture, apophyseal traction injury, or bony avulsion at the insertion of the peroneus brevis tendon.

Assessment of ligamentous stability is challenging following acute injury secondary to soft tissue swelling, pain, and apprehension. If a fracture is suspected, defer stress testing until after radiographic clearance. The anterior drawer test assesses anterior–posterior translation. Stabilize the distal tibia with one hand while grasping the posterior heel and exerting anterior force. Significantly increased translation compared to the unaffected side suggests injury to the ATFL. Talar tilt is performed by applying inversion to the heel and feeling for excess mobility associated with CFL injury or limited mobility associated with tarsal coalition.

Syndesmotic injury is often subtle and may be missed without a careful exam. Swelling is often limited to the ankle or a level above, but significant proximal disruption may be present. Assess for syndesmosis injury by gently squeezing together the medial to distal tibia and fibula. Pain on the squeeze test suggests syndesmotic injury. Cautiously externally rotate the foot, looking for pain or evidence of laxity.

Imaging. When fracture is suspected, obtain a radiograph series that at least includes anteroposterior, lateral, and mortise views. Thoroughly scrutinize the malleoli (the most common sites of fracture) on the AP and lateral view. *(See Figure 7.)* Be cognizant of abnormalities on the proximal fifth metatarsal and tarsal navicular. Look for irregularities of the talar dome on the AP and mortise views. The mortise view is critical in assessing ligamentous stability of the distal tibiofibular articulation. Ensure that the joint space between the malleoli and the talus is of uniform thickness, and that the medial tibia and fibula overlap by at least 1 mm.[47]

The majority of ankle radiographs taken in the ED following acute injury do not affect clinical management. The Ottawa Foot and Ankle Rules were designed to cut down on unnecessary radiographs, enhance speed of care in the ED, and reduce the cost of treatment. These rules have been validated in a number of settings involving adult patients (older than 18 years of age) and, when properly applied, approach 100% sensitivity in picking up clinically relevant fractures (> or = 3 mm).[48] Attempts to validate the rules in the setting of pediatrics have shown mixed results, and therefore should be applied only with great care.[49,50] The rules state that radiographs are indicated if any of the following are present: Inability to walk four steps at the time of injury and in the ED; tenderness over the lateral or medial malleolus; or tenderness over the base of the fifth metatarsal or navicular.

Specific Ankle Injuries

Lateral Ankle Sprain and Salter-Harris Fractures of the Distal Fibula. The typical mechanism of lateral ankle injury may result in tear of the lateral ligaments, disruption of the distal fibula growth plate, or both. As noted, the physis is the weak link in the kinetic chain; as the adolescent skeleton matures, the rate of Salter-Harris injuries declines. Just prior to fusion of the distal fibula physis, it is possible to see a Salter-Harris I fracture along with significant tearing of the lateral ankle ligaments.[8] Tenderness over the growth plate mandates radiographic evaluation. Even if no evidence of fracture is seen, tenderness over the growth plate should elicit a diagnosis of non-displaced Salter-Harris I fracture, the ankle should be immobilized, and the patient made non-weight bearing.

The goal of initial treatment of ankle sprains is to reduce pain and swelling. Treatment is best summarized with the mnemonic PRICE (protection, rest, ice, compression, elevation). The ankle should be protected from further injury with a removable air splint. Have the patient remove the splint three or four times daily and move the ankle through a full range of active motion. Crutches may be required initially,

Figure 8. Distal Fibula Fracture Above the Level of the Mortise

This injury is associated with tear of the tibiofibular syndesmosis and disruption of the ankle mortise.

but weight-bearing should be encouraged as soon as tolerated. Posterior splint usage for sprains limits early range of motion, delays return to weight-bearing, and should generally be avoided. The patient should be referred for followup within several days to ensure adequate progress. Further rehabilitation will consist of strength and proprioceptive training and bracing. Ligamentous healing may take many months, so bracing with activity should be encouraged.

Distal fibula fractures are treated with immobilization in an air cast or plaster splint. The patient should be referred to an orthopedist for followup in the next several days. In radiographically silent Salter-Harris I fractures, the child is kept non-weight-bearing for approximately one week; if the ankle is non-tender on subsequent evaluation, weight-bearing is gradually increased. Radiographically evident fractures are often treated with a short leg cast.[13] Be aware that any fibula fracture at or above the mortise may result in disruption of the anterior tibiofibular ligaments, syndesmosis, or both, with resultant joint instability. *(See Figure 8.)* Carefully examine the mortise view for evidence of joint-space widening. Fractures at or above the mortise should prompt splint immobilization, restriction from weight-bearing, and timely orthopedic evaluation.

Proximal Fifth Metatarsal Fractures. While technically an injury to the foot, injury to the proximal fifth metatarsal is strongly associated with ankle injury. *(See Figure 9 a-b.)* Traction from the peroneus brevis tendon may result in acute or chronic apophyseal traction injury or an avulsion fracture. Fractures of the proximal fifth MT tend to occur in older children, and are often incurred during athletic activity on a level surface.[51] As per the Ottawa Foot and Ankle Rules, tenderness on the proximal fifth MT mandates radiographic evaluation. If you order a standard three-view ankle series, ensure you can visualize the proximal bone; if not, order a separate foot series. Traction apophysitis is differentiated from non-displaced Salter-Harris I injury by chronicity of the injury. In chronic apophysitis, the child should be removed from inciting activity until reevaluated by the pediatrician or an orthopedist. Acute non-displaced fractures may be placed in a rigid orthopedic shoe with instructions for limited weight-bearing. The apophysis is differentiated from avulsion fracture by its orientation parallel (rather than perpendicular) to the long axis. Avulsion fractures have an excellent prognosis, and may be treated with an orthopedic shoe and limited weight-bearing pending reevaluation. Fractures at the junction of the metaphysis and diaphysis (Jones fracture) are associated with high rates of non-union. This region is also

Figure 9 a-b. Fractures of the Proximal Fifth Metatarsal Secondary to Ankle Inversion

The fracture on left (9a) is a simple avulsion fracture. The fracture on the right (9b) is at the metaphyseal-diaphyseal junction (Jones fracture) and will require cast immobilization and possibly surgical stabilization.

susceptible to stress fracture where, as noted, initial radiographs are often non-diagnostic. Injury to the metaphyseal-diaphyseal junction should be treated with a rigid splint, restricted weight-bearing, and close followup. Definitive treatment for a Jones fracture (acute or chronic stress injury) entails prolonged casting and may require surgical stabilization. Avulsion fractures that are distal to the metaphysis (though not quite as distal as the shaft) are probably best treated as a Jones fracture, with immobilization and non-weight-bearing pending reevaluation.[521]

Distal Tibia Fracture. External rotation of the foot and/or eversion of the ankle may result in fracture of the distal tibia at the medial malleolus. A non-displaced fracture through the distal tibial epiphyseal plate can be difficult to visualize; however, the majority of distal tibia fractures in children are Salter-Harris II, III, or IV.[47] The tibial growth plate fuses over several years from medial to lateral. Significant external rotation applied when only the medial growth plate has fused may lead to Salter-Harris III fracture of the lateral tibial epiphysis, known as a juvenile Tillaux fracture. Triplane fractures occur when rotation leads to non-adjacent fractures through the medial epiphysis, lateral physis, and posterior malleolus. The fracture is named for the fact that the fracture occurs on three planes: sagittal, transverse, and coronal.[13] Both Tillaux and triplane fractures may be difficult to visualize on plain films, as the medial physis remains intact, while the disrupted lateral physis is obscured by the overlapping fibula. Suspect these injuries in the child who presents with a limp or refusal to bear weight and is tender and/or swollen at the distal tibia. If the radiographic diagnosis is uncertain, a CT should be obtained. An orthopedist should be consulted, as these injuries will always require prolonged immobilization and may also need either closed or open reduction.

Talar Dome Fracture. The dome of the talus lies in the mortise created by the tibial plafond, distal fibula, and malleoli, and serves as a weight-bearing surface for the entire body. As such, it is vulnerable when the ankle is forcibly inverted, everted, or rotated. Acute injury may be isolated to the articular cartilage (chondral lesion) or may penetrate through the subchondral bone (osteochondral lesion). Acute injury or repetitive microtrauma to the talus in the setting of diminished blood flow to the subchondral bone and possible genetic factors may lead to a loose segment of articular cartilage and subchondral bone (osteochondritis dissecans). OCD is seen as a complication of approximately 6.5% of ankle

sprains. The majority of injuries occur on either the anterolateral or posteromedial surface.[40,47]

The most common presenting complaint in talar osteochondral lesions is pain.[41] History may reveal a specific traumatic event, or pain of an insidious onset in a (frequently) active child. Antalgic gait is commonly seen, along with an ankle effusion. Palpate for tenderness posterior to the medial malleolus with the ankle dorsiflexed, and anterior to the lateral malleolus with the ankle plantar flexed. Obtain plain radiographs and look for any evidence of fracture line, which may be extremely small and subtle. Sensitivity of plain films for detecting OCD of the talus varies between 57% and 70%.[53] MRI may be required to detect the injury and ascertain extent of subchondral bone injury. If a lesion is seen or suspected (ongoing pain and effusion following ankle sprain), immobilize the ankle in a splint, limit weight-bearing, and obtain orthopedic followup. Non-displaced lesions will require prolonged immobilization, while displaced lesions often require surgery.

Overuse Injury of the Ankle. Chronic injuries to the ankle include aforementioned osteochondral lesions and stress injury to the proximal fifth metatarsal. Stress fractures to the distal tibia and fibula are relatively rare but do occur, most often in highly active and athletic populations (e.g., runners, dancers, and military recruits).[54,55] *(See Figure 3.)* Carefully evaluate radiographs for periostial elevation or early sclerosis suggestive of stress fracture. In light of normal films, restrict the child from inciting activities until followup can be arranged.

Summary

Pediatric knee and ankle injuries occur commonly and the ED clinician must be prepared to recognize and manage these injuries. Understanding the unique aspects of a child's knee and ankle facilitate a confident, focused approach, with early identification of critical injuries and avoidance of common pitfalls. *(See Table.)* It is most important that the clinician remember that tenderness along any growth plate is a fracture until proven otherwise. Other potential pitfalls include failure to perform and document a basic vascular exam following significant knee injury, forgetting to examine the joint above and below an injury, and missing subtle radiographic findings. Careful attention to detail, including a thorough history, physical exam, and appropriate radiographs, will assure the best outcome for each pediatric patient.

Table. Pediatric Knee and Ankle Pitfalls

- *Diagnosing a ligament sprain in the skeletally immature patient.* Tenderness on or about a growth plate is a fracture until proven otherwise.
- *Failure to perform (or document) a basic vascular examination following significant knee injury.* Though uncommon, popliteal artery injury may occur and should be part of your differential diagnosis.
- *Forgetting to examine "a joint above and a joint below" the injury site.* For example, injuries of the ankle may be associated with injury to the distal knee or proximal fifth metatarsal. Examine these areas and document your findings.
- *Missing subtle radiographic findings.* Osteochondral injury and early stress fractures may present with minimal abnormal findings on plain films; the emergency physician should recognize these findings and refer appropriately.

References

1. Nawar EW, Niska RW, Xu J. National Hospital Ambulatory Medical Care Survey: 2005 Emergency Department Summary. *Adv Data* 2007;386:1-32.
2. Simon TD, Bublitz C, Hambidge SJ. Emergency department visits among pediatric patients for sports-related injury: Basic epidemiology and impact of race/ethnicity and insurance status. *Pediatr Emerg Care* 2006;22:309-315
3. Centers for Disease Control and Prevention. Nonfatal sports and recreation-related injuries treated in emergency departments–United States, July 2000-June 2001. *MMWR Morb Mortal Wkly Rep* 2002;51:736-740.
4. U.S. Department of Health and Human Services, The Surgeon General's call to action to prevent and decrease overweight and obesity. Rockville, Maryland: US Department of Health and Human Services, Public Health Office, Office of the Surgeon General, 2001.
5. Danmore DT, Metzl JD, Ramundo M, et al. Patterns in childhood sports injury. *Pediatr Emerg Care* 2003;19:65-67.
6. Thompson GH. Growth and Development. In: Behrman RE, et al, eds. *Nelson Textbook of Pediatrics,*. 17th ed. Philadelphia: Saunders; 2004: 2251.
7. Johnson, MD. Physiology of Musculoskeletal Growth. In: Sallis RE, et al, eds. *Essentials of Sports Medicine*. St Louis: Mosby; 1997:530-531.
8. Grudziak JS, Musahl V. The Youth Athlete. In: McMahon PJ, ed. *Current Diagnosis and Treatment: Sports Medicine*. New York: McGraw-Hill;2007:194-256.
9. Aronsson DD, Bernstein RM, Blasier RD, et al. Pediatric Orthopaedics. In: Greene WB, ed. *Essentials of Musculoskeletal Care,* 2nd ed. Illinois: American Academy of Orthopaedic Surgeons;2001:578-723.
10. Lord J, Winell JJ. Overuse injuries in pediatric athletes. *Curr Opin Pediatr* 2004;16:47-50.
11. Hogan KA, Gross RH. Overuse injuries in pediatric athletes. *Orthop Clin North Am* 2003;34:405-415.
12. Moeller JL. Pelvic and hip apophyseal avulsion injuries in pediatric athletes. *Curr Sports Med Rep* 2003;2:110-115.
13. Pontell D, Hallivis R, Dollard MD. Sports injuries in the pediatric

and adolescent foot and ankle: Common overuse and acute presentations. *Clin Podiatr Med Surg* 2006;23:209-231.
14. Stanitski CL, McMaster JH, Scranton PE. On the nature of stress fractures. *Am J Sports Med* 1978;6:391-396.
15. Richardson C, Singer JI, Springer B. Subacute leg pain. *Pediatr Emerg Care* 2005;21:387-390.
16. Gaeta M, Minutoli F, Scribano E, et al. CT and MR imaging findings in athletes with early tibial stress injuries: Comparison with bone scintigraphy findings and emphasis on cortical abnormalities. *Radiology* 2005;235:553-561.
17. Schacter AK, Rokito AS. ACL injuries in the skeletally immature patient. *Orthopedics* 2007;30:365-70.
18. Swenson EJ. Knee Injuries. In; McKeag DB, et al, eds. *Primary Care Sports Medicine*. 2nd ed. Philadelphia: Lippincott Williams & Wilkins; 2007: 462-490.
19. Solomon DH, Simel DL, Bates DW, et al. Does this patient have a torn meniscus or ligament of the knee? Value of the physical examination. *JAMA* 2001;286:1610-1620.
20. Hergenroeder AC, Chorley JN. Management of Musculoskeletal Injury. In: Behrman RE, et al, eds. *Nelson Textbook of Pediatrics,* 17th ed. Philadelphia: Saunders; 2004: 2307.
21. Siow HM, Cameron DB, Ganley TJ. Acute knee injuries in skeletally immature athletes. P*hys Med Rehabil Clin N Am* 2008;19: 319-345.
22. Kowalenko T, Schwartz DT. The Knee. In: Schwartz DT, Reisdorff EJ, eds. *Emergency Radiology.* New York: McGraw-Hill; 2000: 185-215.
23. Khine H, Dorfman DH, Avner JR. Applicability of the Ottawa Knee Rule for knee injury in children. *Pediatr Emerg Care* 2001; 17:401-404.
24. Bulloch B, Neto G, Plint A, et al. Validation of the Ottawa Knee Rule in children: Amulticenter study. *Ann Emerg Med* 2003;42: 48-55.
25. Rooks YL, Corwell B. Common urgent Musculoskeletal injuries in primary care. *Prim Care* 2006;33:751-777.
26. Seaberg DC, Jackson R. Clinical decision rule for knee radiographs. *Am J Emerg Med* 1994;12:541-543.
27. Staser JA, Buckwalter, KA. Imaging in Sports Medicine. In: McKeag DB, et al, eds. *Primary Care Sports Medicine* 2nd ed. Philadelphia: Lippincott Williams & Wilkins; 2007:533-561.
28. Berquist TH. Osseous and myotendinous injuries about the knee. *Radiol Clin North Am* 2007;45:955-968.
29. LaBella CR. Common acute sports-related lower extremity injuries in children and adolescents. *CPEM* 2007;8:31-42.
30. Harner, CD, ed. Patellofemoral Instability and Malalignment. In: Griffin LY, et al, eds. *Essentials of Musculoskeletal Care,* 3rd ed. Rosemont, IL: American Academy of Orthopedic Surgeons; 2005: 541-545.
31. Prince JS, Laor T, Bean JA. MRI of anterior cruciate ligament injuries and associated findings in the pediatric knee: Changes with skeletal maturation. *AJR* 2005;185:756-762.
32. Giugliano DN, Jennifer L. Solomon JL. ACL tears in female athletes. *Phys Med Rehabil Clin N Am* 2007;18:417-438.
33. Harner, CD, ed. Posterior Cruciate Ligament Tear. In: Griffin LY, et al, eds. *Essentials of Musculoskeletal Care,* 3rd ed. Rosemont, IL: American Academy of Orthopedic Surgeons;2005:560-563.
34. Patel DR, Baker RJ. Musculoskeletal injuries in sports. *Prim Care* 2006;33:545-579.
35. Strakowski JA, Jamil T. Management of common running injuries. *Phys Med Rehabil Clin N Am* 2006;17:537-552.
36. LaBella C. Patellofemoral pain syndrome: Evaluation and treatment. *Prim Care* 2004;31:977-1003.
37. Dixit S, DiFiori JP, Burton M. Management of patellofemoral pain syndrome. *Am Fam Physician* 2007;75:194-202.
38. Gholve PA, Scher DM, Khakharia S, et al. Osgood Schlatter syndrome. *Curr Opin Pediatr* 2007;19:44-50.
39. Malanga GA, Chimes GP. Rehabilitation of basketball injuries. *Phys Med Rehabil Clin N Am* 2006;17:565-587.
40. Farmer JM, Martin DF, Boles CA, et al. Chondral and osteochondral injuries: Diagnosis and management. *Clin Sports Med* 2001; 20:299-320.
41. Bruce EJ, Hamby T, Jones DG. Sports-related osteochondral injuries: Clinical presentation, diagnosis, and treatment. *Prim Care* 2005;32:253-276.
42. Harner, CD, ed. Osteochondritis Dissecans. In: Griffin LY, et al, eds. *Essentials of Musculoskeletal Care*, 3rd ed. Rosemont, IL: American Academy of Orthopedic Surgeons;2005:528-530
43. Pomering TL, Kluchurosky L, Hall SL. Ankle and foot injuries in pediatric and adult athletes. *Prim Care Clin Office Pract* 2005;32: 133-161.
44. Nelson AJ, Collins CL, Yard EE, et al. Ankle injuries among United States high school sports athletes, 2005-2006. *J Athl Train* 2007;42:381-387.
45. Zanfrillo MR, Seiden JA, House EM, et al. The association of overweight and ankle injuries in children. *Ambul Pediatr* 2008; 8:66-69.
46. Timm NL, Grupp-Phalen J, Ho ML. Chronic ankle morbidity in obese children following an acute ankle injury. *Arch Pediatr Adolesc Med* 2005;159:33-36.
47. Williamson B, Schwartz DT. The ankle and leg. In: Schwartz DT, Reisdorff EJ, eds. *Emergency Radiology* New York; McGraw-Hill;2000:157-184.
48. Stiell IG, Greenberg GH, McKnight RD, et al. Decision rules for the use of radiography in acute ankle injuries: Refinement and prospective validation. *JAMA* 1993;269:1127.
49. Clark KD, Tanner S. Evaluation of the Ottawa Ankle Rules in children. *Pediatr Emerg Care* 2003;19:73-78.
50. Plint AC, Bulloch B, Osmond MH, et al. Validation of he Ottawa Ankle Rules in children with ankle injuries. *Acad Emerg Med* 1999;6:1006-1009.
51. Singer G, Cichocki M, Schalaman J, et al. A study of metatarsal fractures in children. *J Bone Joint Surg Am* 2008;4:772-776.
52. Chuckpaiwong B, Queen RM, Easley ME, et al. Distinguishing Jones and proximal diaphyseal fractures of the fifth metatarsal. *Clin Orthop Relat Res* 2008;epub 25 March, retrieved January 2009 from www.springerlink.com/content/6576m578u5351n74/.

53. Roach R. Osteochondral lesions of the talus. *J Am Podiatr Med Assoc* 2003;93:307-311.
54. Sherbondy PS, Sebastianelli WJ. Stress fractures of the medial malleolus and distal fibula. *Clin Sports Med* 2006;25:129-137.
55. Goulart M, O'Malley MJ, Hodgkins CW, et al. Foot and ankle injuries in dancers. *Clin Sports Med* 2008;27:295-304.

CME Questions

11. Avulsion fracture of the lateral aspect of the tibial plateau is strongly associated with which of the following acute knee injuries?
    a. Medial collateral ligament sprain
    b. Anterior cruciate ligament sprain
    c. Posterior cruciate ligament sprain
    d. Patellar dislocation

12. Which of the following is *true* regarding patellofemoral pain syndrome in children?
    a. It is associated with the development of an effusion.
    b. It occurs more frequently in non-athletes than athletes.
    c. It is often lacking in objective physical findings.
    d. It is characterized by patellar malalignment on radiographs.

13. A 16-year-old soccer player made a sudden lateral movement during a game, injuring her knee approximately 6 hours prior to presentation in the emergency department. She noted at the time of the injury she felt a "pop" and her knee gave way. She was unable to continue play and required assistance off the field. On exam, you note a large effusion. The most useful next step is to:
    a. Immobilize the knee and order radiographs
    b. Allow her to resume activity as tolerated in a hinged brace
    c. Perform the Lachman and anterior drawer tests
    d. Order Doppler ultrasound to evaluate the popliteal artery

14. A 7-year-old presents following a moderate velocity motor vehicle collision. He was unrestrained in the back seat, and his uninjured older brother saw his foot hit the back of the drivers seat with the leg in full extension. Radiographs ordered in triage reveal a displaced Salter-Harris III fracture of the distal femoral physis. The next most important step is:
    a. Closed reduction of the fracture fragment
    b. CT scan to delineate extent of the fracture
    c. Thorough assessment of ligamentous stability of the knee
    d. Thorough assessment of neurovascular status of the lower leg

15. Unique features of the pediatric skeleton that predispose to injury include:
    a. Growth plates, thick periosteum, elastic bone, rapid tendon growth
    b. Growth plates, thick periosteum, elastic bone, rapid bone growth
    c. Growth plates, thin periosteum, elastic bone, rapid bone growth
    d. Growth plates, thick periosteum, inelastic bone, rapid bone growth

16. In patients with ankle injury, the tibiofibular syndesmosis is evaluated with which test?
    a. Anterior drawer
    b. Talar tilt
    c. Squeeze test
    d. McMurray test

17. Significant external rotation of the ankle with partially fused tibial growth plate may result in a juvenile Tillaux fracture. The fracture pattern is described as which of the following?
    a. Salter-Harris III fracture of the lateral tibial epiphysis
    b. Salter-Harris III fracture of the medial tibial epiphysis
    c. Salter-Harris III fracture of the medial fibular epiphysis
    d. Salter-Harris III fracture of the lateral fibular epiphysis

18. Which of the following is most accurate regarding osteochondral injury to the talar dome?
    a. The most common presenting complaint is effusion
    b. Plain radiographs are rarely positive
    c. Injury most often occurs on the anteromedial or posterolateral surface of the talus
    d. The talar dome is least vulnerable to load injury in the neutral position

CME Instructions

Physicians participate in this continuing medical education program by reading the article, using the provided references for further research, and studying the questions at the end of the article. Participants should select what they believe to be the correct answers, then refer to the list of correct answers to test their knowledge.

To clarify confusion surrounding any questions answered incorrectly, please consult the source material. After completing this activity, you must complete the evaluation form that will be provided at the end of the semester and return it in the reply envelope provided to receive a credit letter. When your evaluation is received, a credit letter will be mailed to you.

CME Objectives

The CME objectives for *Pediatric Emergency Medicine Reports* are to help physicians:

a.) Quickly recognize or increase index of suspicion for specific conditions;

b.) Describe the epidemiology, etiology, pathophysiology, historical and physical examination findings associated with the entity discussed;

c.) Correctly formulate a differential diagnosis and perform necessary diagnostic tests;

d.) Apply state-of-the-art therapeutic techniques (including the implications of pharmacologic therapy discussed) to patients with the particular medical problems discussed;

e.) Provide patients with any necessary discharge instructions.

19. Fractures of the proximal fifth metatarsal associated with ankle inversion:
    a. are commonly prone to non-union.
    b. may result in avulsion of the apophysis.
    c. rarely involve the growth plate in skeletally immature patients.
    d. often require cast immobilization.

20. An 11-year-old male presents to the emergency department immediately following an ankle inversion injury sustained while running on uneven terrain. Examination reveals soft tissue swelling of the lateral malleolus and tenderness of the distal fibula and lateral ligaments. Radiographs show soft tissue swelling, open growth plates, and are interpreted as normal. The most likely diagnosis is:
    a. Salter-Harris I fracture of the distal fibula
    b. Anterior talofibular ligament sprain
    c. Anterolateral talar dome fracture
    d. Salter-Harris V fracture of the distal fibula

Answer Key: 11. b; 12. c; 13. c; 14. d; 15. b; 16. c; 17. a; 18. d; 19. b; 20. a

In Future Issues: **Bleeding Disorders**