Emergency Medicine Reports
The Practical Journal for Emergency Physicians
Volume 30, Number 7 / March 16, 2009 www.emreports.com

Authors:

Lisa Freeman Grossheim, MD, FACEP, Assistant Professor of Emergency Medicine, University of Texas Medical School at Houston

Katrin Takenaka, MD, FACEP, Assistant Professor of Emergency Medicine, University of Texas Medical School at Houston

Amy Noland, MD, Resident, Department of Emergency Medicine, University of Texas Medical School at Houston

Peer Reviewer:

Madelyn Garcia, MD, MPH, Assistant Professor of Emergency Medicine, Department of Emergency Medicine, University of Rochester School of Medicine, Rochester, NY.

Statement of Financial Disclosure

To reveal any potential bias in this publication, and in accordance with Accreditation Council for Continuing Medical Education guidelines, we disclose that Dr. Schneider (editor) serves on the advisory board of Logical Images. Dr. Farel (CME question reviewer) owns stock in Johnson & Johnson. Dr. Stapczynski (editor), Dr. Grossheim (author), Dr. Takenaka (author), Dr. Noland (author), and Dr. Garcia (peer reviewer) report no relationships with companies related to the field of study covered by this CME activity.

AHC Media LLC

Acute Appendicitis Diagnosis and Treatment in 2009: Part II

This second part concludes our discussion of acute appendicitis, focusing on three patient populations where the diagnosis can be challenging and imaging modalities are commonly used: the elderly, children, and pregnant women. In addition, this article will discuss the use of pre-operative antibiotics and the evolving concept of delaying appendectomy until the operating room is available during day-shift.
—J. Stephan Stapczynski, MD, FACEP, Editor

Special Populations

Elderly. Appendicitis in the elderly can be difficult to diagnose because many patients present atypically.[1,2] The presence of fever and elevated white blood count are not reliably present in the elderly, and many patients may have minimal or no right lower quadrant pain. About one-third to one-half of elderly patients are misdiagnosed initially, and half have perforation at time of operation.[1] Diverticulitis and bowel obstruction are common misdiagnoses in this age group. CT can be used more liberally in the elderly with abdominal pain, as the diagnostic yield is high and the risk of radiation-induced malignancy is less due to the time required to mainifest such complications.

Children. Acute appendicitis is the most common surgical emergency in childhood, responsible for 10% of all children admitted to the hospital.[3] The classic clinical picture of acute appendicitis has been widely known for more than 110 years. However, it has been mostly described in adult patients. The pathophysiology of appendicitis in children differs from that of adults because of the changing anatomical location and shape of the appendix throughout childhood. Neonates develop appendicitis infrequently because they have a funnel-shaped appendix.[4] Around age 1-2 years, the appendix assumes the typical tubular adult shape and becomes more susceptible to appendicitis.[5,6] Lymphoid follicle hyperplasia and follicular size gradually increase throughout childhood and peak in the adolescent years, corresponding to the period of highest incidence of appendicitis.[5,6]

Children are at increased risk of misdiagnosis due to atypical signs and symptoms. Many children present with clinical findings that are considered not classic for appendicitis. In one study, more than 50% of patients with appendicitis had no fever, negative Rosving's sign, and no rebound tenderness. Almost half had abrupt onset of pain or lack of pain migration.[7] In children younger than 3 years of age, diarrhea is reported in as many as 41% of cases of appendicitis and is more common in this age group than in older children. Additionally, local abdominal tenderness is not as frequent as in older children.[8,9]

In the past, ultrasound has been the radiologic test of choice to assist in the diagnosis of appendicitis in children. Ultrasound, however, is operator dependent, and wide ranges of sensitivity and specificity have been reported in the broad pediatric age population.[10-12] One pediatric subpopulation where ultrasound may be more useful is in younger children. Chang et al studied the utility of ultrasound in diagnosing appendicitis in children age 3 and younger. They reported a positive predictive value of 93% and a negative predictive value of 93%.[13]

Executive Summary

- Atypical symptoms and physical signs occur in up to half of children and elderly with acute appendicitis.
- Risk stratification can be used to guide imaging modality use in children.
- The white blood cell count or other inflammatory markers are more effective in supporting a clinical diagnosis of acute appendicitis than in excluding the diagnosis.
- Preoperative antibiotics reduce post-operative wound infection and abscess formation.
- Delay for surgical appendectomy if < 12 hours does not increase the incidence of complications.

CT has been shown to be highly sensitive and specific for diagnosing acute appendicitis in children. Reported sensitivities for CT range from 87-100% and specificity from 89-98%.[14-19] CT has a higher sensitivity for the diagnosis of appendicitis in children than ultrasound.[20,21] There is also evidence that CT improves outcomes as well. Reduced negative appendectomy rates[21,22] and reduced length of hospitalization[17] have been reported. However, due to the radiation risk, attempts should be made to minimize CT use in children whenever possible.

US and CT can be used as complementary studies for the evaluation of acute appendicitis in children. One approach is to use risk stratification to determine the initial imaging study and the need for alternative studies. Garcia-Pena et al retrospectively analyzed this risk stratification in a cohort of children with equivocal presentations for appendicitis who were divided into low-, medium-, and high-risk groups for appendicitis. Three different imaging guidelines were utilized. Low risk was defined as neutrophils ≤ 67%, bands < 5%, and no guarding on abdominal examination. High risk was defined as neutrophils > 67%, white blood cell count >10,000/mm^3, guarding, and abdominal pain > 13 hours. Imaging guideline number one (the standard practice at the authors' institution) dictated that all children with equivocal signs and symptoms for acute appendicitis have ultrasound first. If the ultrasound is positive, the child proceeds to appendectomy. If the ultrasound is negative, the child undergoes CT. Under guideline number two, low-risk children undergo ultrasound and, if negative, are discharged from the hospital. High-risk children undergo CT, and medium-risk children undergo ultrasound followed by CT. Under the third guideline, low-risk children undergo no imaging and are admitted for observation. High-risk children proceed directly to appendectomy without imaging studies. Medium-risk children undergo ultrasound followed by CT. Of the total 958 children studied, 61% had appendicitis. Two hundred twenty-five patients were classified as high-risk. Under imaging guideline 1, there were 22 negative appendectomies, 35 missed or delayed diagnoses, and 958 ultrasounds and 673 CT scans performed. Under guideline 2, there would have been 23 negative appendectomies, 36 missed or delayed diagnoses, and 733 ultrasounds and 637 CT scans performed. Under guideline 3, there would have been 36 negative appendectomies, 37 missed or delayed diagnoses, and 590 ultrasounds and 412 CT scans performed. The authors concluded that selective imaging guidelines can reduce the number of radiographic studies performed with a minimal diminution of accuracy in the diagnosis of pediatric appendicitis.[23]

Children with a low likelihood of appendicitis may be spared the expense and risk of a more invasive and costly workup for appendicitis and may be sent home safely with careful followup. The use of the pediatric appendicitis scale can help determine which patients can be considered low-risk. However, in particularly young children in whom the diagnosis of appendicitis is difficult to make, clinicians will continue to rely on radiologic studies and surgical evaluation to assess the potential appendicitis patient since the clinical examination alone cannot definitively confirm this diagnosis.[24]

Women. Non-pregnant female patients with acute abdominal pain usually require a lengthier and more extensive evaluation because of the different nature of their anatomy and pathologic processes. With the reproductive tract's adjacent location to the abdominal cavity, referred pain from multiple spaces and organs can be referred to the right lower quadrant. CT often is necessary in these patients for accurate diagnosis. Pregnancy further complicates the search for a diagnosis.

Pregnancy. Acute appendicitis complicates approximately 1 in 1500 pregnancies and is one of the leading indications for surgery during pregnancy.[25] Accurate diagnosis is important as delay in diagnosis leads to a higher rate of maternal and fetal complications.[26,27]

The clinical diagnosis of appendicitis in pregnancy is challenging, since some of the hallmarks of appendicitis, such as nausea, vomiting, and abdominal pain often are present in pregnant patients without appendicitis.[26-28] Anorexia, nausea, vomiting, and initial periumbilical pain are similar in the pregnant and non-pregnant state. Gross peritoneal signs with rebound and guarding are not normal in pregnancy, although the laxity of the anterior abdominal wall and enlarged uterus may delay or diminish these signs.

Figure 1A: Axial CT Image of a Pregnant Female

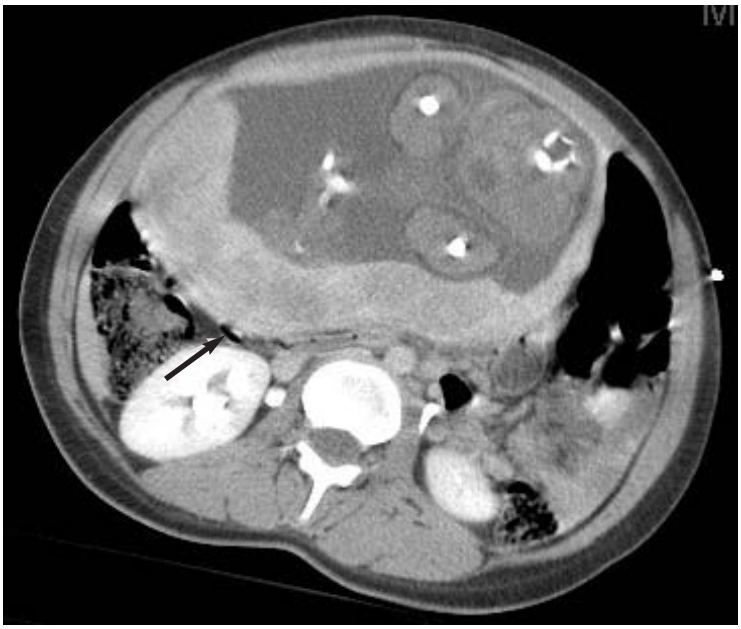

Axial CT image of a 9-month pregnant female who had CT scan performed due to blunt abdominal trauma sustained in a motor vehicle collision. The appendix has migrated up out of the pelvis and lies anterior to right kidney.
Image courtesy of Dan Gridley, MD, Vice Chair of Radiology, Maricopa Medical Center, Phoenix, AZ

Figure 1B: Coronal Reconstruction View of the Same Patient as in 1A

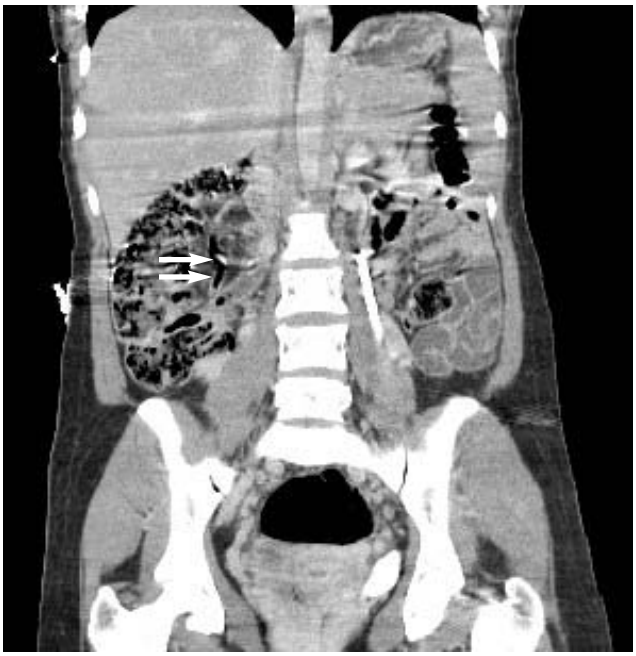

Image courtesy of Dan Gridley, MD, Vice Chair of Radiology, Maricopa Medical Center, Phoenix, AZ

The physical examination may be unreliable and the location of the appendix variable, depending on the size of the gravid uterus, which may reposition the appendix within the peritoneal cavity.[29,30] (*See Figures 1 A-B and 2 A-B.*) Early during pregnancy, peritoneal irritation develops in the right lower quadrant, but after the fifth month of gestation, the appediceal position and site of pain are shifted superiorly about the right iliac crest, and the appendix tip is rotated medially by the gravid uterus. The tenderness also becomes less localized as distention of the abdomen lifts the peritoneum away from the inflamed appendix and cecum.[27] The location of the appendix traditionally has been described as rising in the peritoneal cavity as the uterus enlarges, beginning at 12 weeks and reaching the iliac crest by 24 weeks.[31,32] More recently, this dogma has been challenged by a prospective study comparing the location of the appendix in women undergoing cesarean at term, in pregnant women undergoing appendectomy, and in non-pregnant women undergoing appendectomy, with no difference in appendix location among the three groups.[33]

The usefulness of ultrasound for diagnosing acute appendicitis in many pregnant patients is limited, as the appendix may be displaced from its expected location. The enlarged uterus may make graded compression difficult. If an abnormal appendix is seen on ultrasound, the specificity of sonography is high; however, if the appendix is not visualized, other imaging is needed.

MRI has been touted as a useful imaging modality for the detection of acute appendicitis in pregnant patients because it eliminates radiation exposure, avoids the operator dependency of ultrasound, facilitates alternative diagnoses, and is considered safe for use in pregnancy.[34] The use of ultrasound is limited to less than 35 weeks gestation, as the graded compression technique is not able to visualize the appendix clearly and is less useful later in pregnancy.[35] MRI can identify not only appendicitis, but also ovarian dis-

Figure 2A: Pregnant Female with Appendix in Right Lower Quadrant

Axial CT image of a 7-month pregnant female showing the appendix has remained in the right lower quadrant.
Image courtesy of Dan Gridley, MD, Vice Chair of Radiology, Maricopa Medical Center, Phoenix, AZ

Figure 2B: Coronal Reconstruction View of the Same Patient as in Figure 2A

Image courtesy of Dan Gridley, MD, Vice Chair of Radiology, Maricopa Medical Center, Phoenix, AZ

ease, colitis, abscesses, pyelonephritis, and fibroid degneration.[36] A study by Pedrosa et al evaluated 51 pregnant patients with clinical suspicion of acute appendicitis who subsequently had MRI. The sensitivity of MRI in this study was 100%, and the specificity was 93.6%.[37]

Israel et al published a small, retrospective study of 33 pregnant patients with suspected appendicitis, each of whom had an ultrasound and MRI. Appendicitis can be excluded only by graded compression ultrasound when a normal appendix is identified. In their study, in 88% of the ultrasound examinations, the appendix could not be identified, including three patients with pathologically proven appendicitis.[38] Similar results were seen by Pedrosa[39] and Cobben.[40] When the appendix was seen on MRI, 100% sensitivity, specificity, and positive and negative predictive value were achieved. When the appendix was seen on ultrasound, the sensitivity was 50%, specificity was 100%, PPV 100%, and NPV 66%.[41]

CT may be done in pregnancy if necessary. Fetal exposure from abdominal CT in the first trimester may double the likelihood of childhood cancer from 1/600 to 1/300.[42] Information from atomic bomb survivors shows the greatest risk to the fetus is exposure at 8-15 weeks gestation,[43] with radiation-induced mental retardation the highest specific potential danger. No single diagnostic radiographic procedure results in radiation exposure to a degree that would threaten the wellbeing of the developing fetus, according to the American College of Radiology.[44]

Pelvic Inflammatory Disease vs. Appendicitis. Part of the diagnostic dilemma of evaluating women of child-bearing age is differentiating appendicitis from pelvic pathology such as pelvic inflammatory disease (PID). Both conditions may present with abdominal/pelvic pain, nausea, vomiting, and fever. Vaginal discharge is not always present in PID. While the pain of appendicitis often begins in the epigrastrium or mid-abdomen, the pain from PID typically is in the lower abdomen. The afferent sensory nerves from the adnexae originate

Table 1: Appendicitis Mimics

Gastrointestinal Disease	Obstetric/Gynecologic Causes
Bowel obstruction	Ectopic pregnancy
Cholecystitis	Endometriosis
Diverticulitis (right-sided)	Mittelschmerz
Duodenal ulcer	Ovarian cyst (ruptured)
Epiploic appendagitis	Ovarian torsion
Gastroenteritis	Ovarian tumor
Hernia	Pelvic inflammatory disease
Ileocolitis	Tubo-ovarian abscess
Inflammatory bowel disease (Crohn's disease)	**Systemic**
Intussusception	Diabetic ketoacidosis
Meckel's diverticulitis	Porphyria
Mesenteric adenitis	Sickle cell disease
Neoplasm	Henoch-Schonlein purpura
Omental torsion	**Miscellaneous**
Pancreatitis	Parasitic infection
Perforated viscus	Pneumonia
Volvulus	Psoas abscess
Genitourinary Disease	Pulmonary infarction
Epididymoorchitis	Rectus sheath hematoma
Nephrolithiasis	
Perinephric abscess	
Prostatitis	
Pyelonephritis	
Testicular torsion	
Urinary tract infection	

from T12 to L2 and L5 to S1-3. This results in the pain being confined to the lower abdomen.[45] Morishita et al developed a clinical prediction rule to help distinguish the two conditions. The rule consists of 3 clinical criteria and can differentiate between appendicitis and PID with 99% sensitivity and 95% negative predictive value when a patient is classified as low risk for appendicitis by the following factors: no migration of pain; presence of bilateral abdominal tenderness; and no nausea and vomiting. Although these 3 factors cannot rule out appendicitis as a single criterion, the combination of these 3 findings could be used as a quick guide for clinical decision making.[46]

Inflammatory Markers. "What's the white count?" Medical mythology would have us believe that patients with presumed appendicitis need to have an elevated white blood cell count. Cardell et al demonstrated that a total WBC of > 10,000 cells/mm^3 has a sensitivity of 76% and a specificity of 52% for appendicitis. The positive predictive value was 42%, and the negative predictive value was 82%. These data suggest that the total WBC count has insufficient sensitivity and specificity to be of clinical value in the diagnosis of appendicitis.[47]

Other inflammatory markers that have been investigated include C reactive protein (CRP), leukocyte elastase activity, D-lactate, phospholipase A2, and interleukin-6. Deballon et al prospectively studied 134 patients with right lower quadrant pain who had complete blood counts and CRP levels drawn. Normal range for CRP was < 6 mg/L; normal for WBC was considered 4500-9600/mm^3, and normal for granulocytes was < 75%. The negative appendectomy rate in this study was 15%, while 66% of patients had appendicitis. Mean levels of CRP, WBC, and granulocytes were all significantly higher in patients with surgical diseases. CRP had the highest diagnostic accuracy of a single marker. However, when CRP was combined with WBC, it led to a diagnostic accuracy of 87% ($p < 0.0005$). WBC and CRP had better diagnostic accuracy in patients with greater than 12 hours of pain. The positive predictive value when CRP and WBC were elevated was 93%, while the negative predictive value if both were normal was 92%.[48] However, no threshold value for WBC or CRP will reliably diagnose or exclude appendicitis. Testing of the white blood cell count, neutrophil count, and C-reactive protein are more effective in supporting a clinical diagnosis of acute appendicitis in patients with typical clinical features than in excluding the diagnosis.[49]

Differential Diagnosis

The differential diagnosis for appendicitis is extensive. Various types of gastrointestinal, genitourinary, obstetric/gynecologic, systemic, and other conditions can mimic the clinical presentation of appendicitis. (*See Table 1.*)

In children, intussusception, Meckel's diverticulitis, gastroenteritis, and mesenteric lymphadenitis may be mistaken for appendicitis. Children with intussusception commonly present with vomiting and colicky abdominal pain interspersed with pain-free periods.[50-52] Rectal bleeding and a palpable right-sided abdominal mass may be noted on examination.[51,52] However, peritoneal signs usually are absent.[50] CT may demonstrate a segment of bowel that has telescoped in on itself, a mass, and/or a proximal bowel obstruction.[13] Plain abdominal radiographs can be used to rule out intussusception as well.

With Meckel's diverticulitis, children typically present with periumbilical pain and tenderness.[50] CT may reveal inflammation adjacent to a loop of small bowel (Meckel's diverticuli are usually located about 60 cm from the ileocecal valve) and occasionally an obstructing fecalith.[51,53]

Gastroenteritis is a common misdiagnosis in both children and adults with appendicitis. Patients with acute gastroenteritis present with varying degrees of nausea, vomiting, and diar-

Table 2: Antibiotic Options for Acute Appendicitis

Moderate Clinical Presentation
• Piperacillin/tazobactam • Ampicillin/sulbactam • Ticarcillin/clavulanate • Ertapenem • Moxifloxacin • Ciprofloxacin or levofloxacin + metronidazole • Cefepime + metronidazole • Tigeycline
Moderate/Severe Clinical Presentation
• Imipenem or meropenem or doripenem • Ampicillin + metronidazole + ciprofloxacin or levofloxacin • Ampicillin + metronidazole + anti-pseudomonal aminoglycoside

rhea that typically start before the onset of abdominal pain. Fever also may be present.[52,54] However, these patients usually do not have focal abdominal tenderness or peritoneal findings on examination.[50] In contrast, patients with appendicitis often have abdominal pain that precedes the onset of other gastrointestinal symptoms such as vomiting. In addition, diarrhea is less common in patients with appendicitis.

Mesenteric adenitis may occur following a viral infection.[52,53] Its clinical presentation may be nearly indistinguishable from that of appendicitis. On CT, patients with mesenteric lymphadenitis have enlarged mesenteric lymph nodes in the right lower quadrant without any other inflammatory changes except possibly mild thickening of the terminal ileum. The appendix, if visualized, is normal.[13,53]

In older patients, Crohn's disease and right-sided diverticulitis are also considerations. Patients with an acute exacerbation of Crohn's disease may present with right lower quadrant pain, fever, and leukocytosis.[13] CT may reveal mural stratification, skip lesions, thickened bowel wall (especially of the terminal ileum and cecum), creeping fat around affected bowel, and mesenteric fat stranding.[53,55] The center of inflammation should be away from the appendix.[13] Complications such as sinus tracts, fistulae, and abscesses also may be apparent on CT. Patients with diverticulitis may present with right lower quadrant pain if they have redundant sigmoid colon or right-sided diverticula.[56] Associated signs and symptoms can include fever, nausea, vomiting, anorexia, and a palpable abdominal mass.[56,57] The area of tenderness with diverticulitis may be larger than the classic McBurney's point of appendicitis.[50] Typical CT findings include focal asymmetric thickening of the cecal wall, adjacent fat stranding, diverticula, and a normal appendix.[13]

Another important consideration in the differential diagnosis is pyelonephritis. Patients with pyelonephritis may present with right-sided abdominal pain, fever, leukocytosis, and pyuria.[50] Some actually may have peritoneal signs on examination. CT commonly demonstrates low attenuation streaks and wedges in the renal parenchyma. Hydronephrosis and perinephric fat stranding also may be seen.[58]

The urinalysis can be deceptively benign in some cases of pyelonephritis, and this diagnosis may be found incidentally on CT obtained in patients with concerning abdominal examinations and unremarkable urinalyses.

In women presenting with right lower quadrant pain, ectopic pregnancy, pelvic inflammatory disease, ovarian torsion, and ruptured ovarian cysts also should be considered. The classic presentation of an ectopic pregnancy includes amenorrhea, abdominal pain, and vaginal bleeding. Although vaginal bleeding may be absent, abdominal pain is almost always present.[59] Physical examination may reveal abdominal tenderness, a slightly enlarged uterus, cervical motion tenderness, and/or an adnexal mass.[58] Ectopic pregnancy should be considered in the differential of any pregnant woman with right lower quadrant pain. Ultrasound may be helpful in ruling in (showing an adnexal mass, especially with a fetal pole) or ruling out (showing an intrauterine pregnancy) ectopic pregnancy or ovarian torsion (normal Doppler flow).

Pelvic inflammatory disease (PID) can be difficult to distinguish from appendicitis as patients with both can present with lower abdominal pain, fever, and leukocytosis. Abnormal cervical or vaginal discharge (mucopurulent) may also suggest PID.[60,61]

Patients with ovarian torsion may present with severe abdominal pain and nausea and vomiting. Unlike with appendicitis, the pain of a torsed ovary classically is abrupt in onset and described as sharp in nature. If intermittent torsion and spontaneous reduction occur, the pain may be more colicky.[59] A tender adnexal mass may be appreciated on examination. CT findings may include an ovarian mass and adjacent fat stranding.[13] However, if ovarian torsion is suspected, a pelvic ultrasound with Doppler is the preferred imaging study. With a ruptured ovarian cyst, women may present with peritoneal signs similar to patients with perforated appendicitis. If significant bleeding occurs, abdominal distention and hypotension may occur.[59] CT in these patients should reveal an ovarian cyst, inflammation in the adnexal area, free fluid in the pelvis, and a normal appendix.[13] Ultrasound is a useful imaging modality in these patients.

Complications

Perforation is the most common complication of appendicitis, occurring in about 15-20% of all patients, but perforation is significantly increased in the elderly and young

children, in whom the rate may be as high as 50-97%.[62-65] This is usually due to a delay in diagnosis.[64,65] In children, there appears to be an inverse relationship between age and risk for perforation. Patients at the extremes of age are at increased risk for perforation. Overall, children have a 23-88% incidence of perforation.[62,63,66] In this population, there appears to be an inverse relationship between age and risk for perforation.[67] In children 10-17 years old, the rate of perforation is 10-20%.[24,68] In those younger than 4 years old, it rises as high as 80-100%.[6,24,69] Similarly, the elderly have a 29-70% incidence.[62,63,67,70-72] Misdiagnosis and delayed diagnosis are common in both of these age groups due to atypical clinical presentations as well as limitations in obtaining a clear history and physicial exam, and may contribute to the higher perforation rates.[62]

After the appendix ruptures, patients may present with more severe or more generalized pain, higher temperature, and higher WBC counts with prominent left shifts.[68] According to a meta-analysis by Andersson, a high WBC ($\geq 15 \times 10^9$/L) and granulocyte count ($\geq 9 \times 10^9$/L) and an elevated CRP level (> 10 mg/L) had positive likelihood ratios of 7.2, 4.16, and 4.24, respectively, making them relatively strong predictors for perforation. In contrast, a WBC count < 10×10^9/L, a granulocyte count < 7×10^9/L, and CRP < 10 mg/L had negative likelihood ratios of 0.11-0.20, making perforation unlikely in patients with these laboratory values.[73]

Another important risk factor for appendiceal rupture is the time from onset of symptoms to treatment.[74] Bickell et al. performed a retrospective chart review of 219 patients with appendicitis and found that the risk of perforation was negligible within the first 36 hours after symptom onset (0-2%). However, for those with symptoms that were untreated for 36 hours or more, the risk rose to about 5% for each ensuing 12 hours without treatment.[75] Inherent delay in obtaining CT did not lead to an increase in the perforation rate. Perforation tends to be dependent on a delay in the initial presentation to the hospital.[76,77]

Once appendiceal rupture occurs, it is associated with increased morbidity and mortality. In some studies, morbidity rose from 3% with uncomplicated appendicitis to as high as 60% after perforation.[72,78] Perforation may result in a localized abscess, peritonitis, or sepsis.[70,75] In the general population, the mortality for appropriately treated appendicitis is less than 1%.[70-72] Appendiceal rupture has been associated with an 11-fold or greater increase in mortality.[63,79] Some people consider perforation the single best predictor of mortality.[70] Elderly patients with appendicitis also have a higher risk of death (4-15%) and account for half of deaths due to appendicitis.[70-72,74,75]

Management

Analgesia. Analgesia should not be withheld from patients for fear of masking a diagnosis. This practice dates prior to the development of the CT scan and has been debunked by multiple studies.[80,81] Even Silen, the current author of Sir Zachary Cope's classic treatise on acute abdominal pain (first written in 1921), condemns withholding analgesia for patients who are in pain, even undifferentiated abdominal pain.[80,82,83]

What about the patient who has been given analgesia who subsequently has little or no abdominal pain when re-examined? One small study recently addressed this question. In study patients with pain at McBurney's point or a positive Murphy's sign, there was no misdiagnosis of appendicitis or cholecystitis when analgesia was given in the absence of imaging.[83] Does administration of analgesia mandate imaging, a specific observation interval, or protocol incorporating both imaging and serial exams?[80] Further research is needed to answer this question.

Antimicrobials. All patients should receive broad-spectrum antibiotics preoperatively (1-3 doses), as their use has been shown to decrease the incidence of post-operative wound infection and intra-abdominal abscess formation.[84]

Unfortunately, there is no census among surgeons regarding antibiotic use in appendicitis. Some choose single agents, double agents, one-time dosing, and intraoperative dosing. (*See Table 2.*) There is no agreement on the length of treatment as well.[85] Prospective cohort studies and randomized controlled trials are lacking, explaining why there is a poor agreement among institutions as to what constitutes optimal care.[86]

Treatment. The timing and management of acute appendicitis has changed dramatically. The role of preoperative imaging has extended beyond a diagnostic tool to become important in identifying those complicated cases that may be amenable to alternatives other than immediate operation, such as extended antibiotic therapy with or without percutaneous drainage of abscesses.[38,87,88]

In a survey of 344 pediatric surgeons, 75% indicated that a clinically stable child with suspected appendicitis could be operated on in an urgent (3-12 hours from presentation) rather than emergent manner.[85] Twenty percent of these surgeons used imaging frequently, and 50% used imaging occasionally. When an imaging study is felt to be necessary in evaluating a child with possible appendicitis, a majority of respondents preferred CT to ultrasound (62% vs 30%).[85]

Laproscopic appendectomy is technically more difficult than open appendectomy, but in adults reduces wound infections, post-operative pain, and length of hospital stay, but may have an increased risk of intra-abdominal abscesses.[89] Patients who have periappendiceal abscesses often are diagnosed preoperatively. These patients are best treated with nonoperative management and selective percutaneous drainage. Immediate operation in these patients results in higher complication rates and longer hospital stays.[90,91]

Acute appendicitis has long been considered a surgical emergency that requires emergent appendectomy. Recently, the concept of a surgical emergency has been challenged and a proposal has been advanced that appendectomy can wait up to 12 hours

after diagnosis so that the procedure can be performed by fully rested and awake surgeons and support personnel during normal business hours without an increase in morbidity.[92] While the data are only retrospective, there is no evidence that delaying appendectomy up to 12 hours after diagnosis increases morbidity.[93,94] Some physicians and hospitals have devised protocols for patients to be held in the ED for observation, receive treatment with intravenous fluid, analgesics, and antibiotics while awaiting call to the OR in the morning.

Disposition

Patients in whom the physician believes the likelihood of acute appendicitis is low can be discharged with strict precautions to return if their symptoms or pain worsens.

A 23-hour admission for observation is a feasible option for patients whose pain is poorly tolerated in the emergency department and for whom a working diagnosis has not been found. This disposition also is an option for patients, particularly children, who might have poor follow-up and in whom the physician suspects a diagnosis of early appendicitis. Clear discharge instructions are particularly important in patients who have had a CT scan that was read as normal or nondiagnostic. The patient should be advised of the limitations of this test and that early appendicitis still may be present.

For ED providers, it is their role (medico-legally as well as ethically) to inform families of children with symptoms of short duration who request a CT scan that: if we image too early, we may miss the diagnosis; and CT scans expose children to radiation and future cancer risk. This is a hard decision made on a case-by-case basis with family/referring doctor and should take into consideration the risk of missing a diagnosis, the physician's responsibility to "do no harm" by the patient, and the ability to ensure safe and timely follow-up.

Summary

Patients with possible appendicitis can be risk-stratified based on their clinical findings and divided into groups. Patients with a high probability of uncomplicated appendicitis should undergo surgery. Patients suspected of having an appendiceal abscess should have a CT (or MRI if pregnant). For patients with a low likelihood of having appendicitis, an alternate diagnosis should be sought. Patients with intermediate probability will require either a combination of laboratory testing and imaging or extended observation. Most low-risk patients can be discharged with 12-24 hour follow-up. For patients who require imaging, the authors recommend CT for all patient groups except pregnant women. Pregnant women should undergo an ultrasound of the abdomen and pelvis in an attempt to visualize the appendix and to evaluate the fetus and adenexae. If these studies are non-diagnostic, an MRI is a reasonable next step for pregnant women. If MRI is not available, re-examine the patient's abdomen. If clinical suspicion still exists at this point, consultations with surgery and gynecology should be obtained, and the patient should be admitted.

References

1. Lee JF, Leow CK, Lau WY. Appendicitis in the elderly. *Aust N Z J Surg* 2000;70: 593-596
2. Gürleyik G, Gürleyik E. Age-related clinical features in older patients with acute appendicitis. *Eur J Emerg Med* 2003;10:200-203.
3. Reynolds SZ, Jaffe DM. Diagnosing abdominal pain in a pediatric emergency department. *Ped Emerg Care* 1992;8: 126-128.
4. Karaman A, Cavusoglu YH, Karaman I, et al. Seven cases of neonatal appendicitis with a review of the English language literature of the last century. *Pediatr Surg Int* 2003; 19:707-709.
5. Addiss DG, Shaffer N, Fowler BS, et al. The epidemiology of appendicitis and appendectomy in the United States. *Am J Epidemiol* 1990;132:910-925.
6. Rothrock SG, Skeoch G, Rush JJ, et al. Clinical features of misdiagnosed appendicitis in children. *Ann Emerg Med* 1991;20: 45-50.
7. Becker T, Kharbanda A, Bachur R. Atypical clinical features of pediatric appendicitis. *J Acad EM* 2007;14:124-129.
8. Horwitz JR, Gursoy M, Jaksic T, et al. Importance of diarrhea as a presenting symptom of appendicits in very young children. *Am J Surg* 1997;173:80-82.
9. Huang CB, Yu HR, Hung GC. Clinical features and outcome of appendicitis in children younger than two years of age. *Chang Gung Med J* 2000;13:28-32.
10. Puyalert JB, Rutgers PH, Lalisang RI, et al. A prospective study of ultrasonography in the diagnosis of appendicitis. *N Engl J Med* 1987;317:666-669.
11. Sivit CJ, Newman KD, Boenning BA, et al. Appendicitis: Usefulness of ultrasound in diagnosis in a pediatric population. *Radiology* 1992;185:549-552.
12. Siegel MJ, Carel C, Surratt S. Ultrasonography of acute abdominal pain in children. *JAMA* 1991;266:1987-1989.
13. Yu J, Fulcher AS, Turner MA, et al. Helical CT evaluation of acute right lower quadrant pain: Part II, Uncommon mimics of appendicitis. *AJR Am J Roentgenol* 2005;184:1143-1149.
14. Garcia-Pena BM, Taylor GA, Lund DP, et al. Effect of CT on patient management and costs in children with suspected appendicitis. *Pediatrics* 1999;104:440-446.
15. Sivit CJ, Applegate KE, Berlin SC, et al. Evaluation of suspected appendicitis in children and young adults: Helical CT. *Radiology* 2000;216:430-433.
16. Karakas SP, Guelfuat M, Leondias JC, et al. Acute appendicitis in children: comparision of clinical diagnosis with ultrasound and CT imaging. *Pediatr Radiol* 2000;30: 94-98.
17. Garcia-Pena BM, Taylor GA, Fishman SJ, et al. Costs and effectiveness of ultrasonography and limited CT for diagnosing appendicitis in children. *Pediatrics* 2000; 106:672-675.
18. Sivit CJ, Siegel MJ, Applegate KE, et al. When appendicitis is suspected in children. *Radiographics* 2001;21:247-262.
19. Lowe LH, Penney MW, Stein SM, et al. Unenhanced limited CT of the abdomen in the diagnosis of appendicitis in children: Comparision with sonography. *AJR* 2001; 176:31-35.
20. Sivit CJ, Applegate KE, Stallion A, et al. Imaging evaluation of suspected appendicitis in a pediatric population: effectiveness of sonography vs CT. *AJR Am J Roentgenol* 2000;175:977-980.
21. Garcia-Pena BM, Mandl KD, Kraus SJ, et al. Ultrasonography and limited CT in the diagnosis and management of appendicitis in children. *JAMA* 1999;282:1041-1046.
22. Applegate KE, Sivit CJ, Salvator AE, et al. The impact of cross-sectional imaging on negative appendectomy and perforation rates in children. *Radiology* 2001;103-107.
23. Garcia-Pena BM, Cook EF, Mandl KD. Selective imaging strategies for the diagnosis of appendicitis in children. *Pediatics* 2004;113(1 Pt 1):24-28.
24. Bundy DG, Byerley JS, Liles EA, et al. Does this child have appendicitis? *JAMA* 2007;298:438-451.
25. Wittich AC, DeSantis RA, Lockrow EG. Appendicitis during pregnancy: A survey of two army medical activities. *Mil Med* 1999;164:671-674.

26. Mourad J, Elliot JP, Erickson L, et al. Appendicitis in pregnancy: New information that contradicts long-held clinical beliefs. *Am J Obstet Gynecol* 2000; 182:1027-1029.

27. Stone K. Acute abdominal emergencies associated with pregnancy. *Clin Obstet Gynecol* 2002;45:553-561.

28. Birchard KR, Brown MA, Hyslop WB, et al. MRI of acute abdominal and pelvic pain in pregnant patients. *AJR Am J Roentgenol* 2005;184:452-458.

29. Owings MF, Kozak LJ. Ambulatory and Inpatient Procedures in the U.S., 1996. Vital and Health Statistics. Series 13. No. 139. Hyattsville, MD: National Center for Health Statistics, November 1998; p. 26 (DHHS publication no. {PHS} 2001-12500-0357.

30. Marudanayagam R, Williams GT, Rees BI. Review of the pathological results of 2660 appendiectomy specimens. *J Gastroenterol* 2006;41:745-749.

31. Baer J, Reis R, Arens R. Appendicitis in pregnancy with changes in position and axis of the normal appendix in pregnancy. *JAMA* 1932;98:1359-1363.

32. Oto A, Srinivisian PN, Ernst RD, et al. Revisiting MRI for appendix location during pregnancy. *AJR Am J Roentgenol* 2006;186: 883-887.

33. Hodjati H, Kazerooni T. Location of the appendix in the gravid patient: A re-evaluation of the established concept. *Int J Gynecol Obstet* 2003;81:245-247.

34. Shellock FG, Crues JV. MR Procedures: Biologic effects, safety and patient care. *Radiology* 2004;232:635-652.

35. Lim HK, Bae SH, Seo GS. Diagnosis of acute appendicitis in pregnant women: Value of sonography. *AJR Am J Roentgenol* 1992;159:539-542.

36. Singh A, Danrad R, Hahn PF, et al. MR imaging of the acute abdomen and pelvis: Acute appendicitis and beyond. *Radiographics* 2007;27:1419-1431.

37. Pedrosa I, Levine D, Eyrazzadeh AD, et al. MR imaging of acute appendicitis in pregnancy. *Radiology* 2006;238:891-899.

38. Oliak D, Yamin D, Udani VM, et al. Nonoperative management of perforated appendicitis without periappendiceal mass. *Am J Surg* 2000;179:177.

39. Pedrosa I, Levine D, Eyazzadeh AD, et al. MR imaging evaluation of acute appendicitis in pregnancy. *Radiology* 2006;238: 891-899.

40. Cobben LP, Groot I, Haans L, et al. MRI for clinically suspected appendicitis during pregnancy. *AJR Am J Roentgenol* 2004; 183:671-675.

41. Israel GM, Malguria N, McCarthy S. et al. MRI vs. ultrasound for suspected appendicitis during pregnancy. *J Magn Reson Imag* 2008;28:428-433.

42. Hurwitz LM, Yoshizumi T, Reiman RE, et al. Radiation dose to the fetus from body MDCT during early gestation. *AJR Am J Roentgenol* 2006;186:871-876.

43. Guidelines for diagnostic imaging during pregnancy: ACOG committee opinion number 299. American College of Obstetrics and Gynecologists 2004;104:647-651.

44. Gray JE. Safety of diagnostic radiology exposures. In: Janover ML, Linton WS, eds. American College of Radiology. *Radiation Risk: A Primer*. Reston (VA): ACR; 1996; p15-17.

45. Gray H, Standring S, Ellis H, et al. *Gray's Anatomy: The Anatomical Basis of Clinical Practice*. 39th ed. Edinburgh: Elsevier Churchill Livingstone; 2005.

46. Morishita K, Gushimiyagi M, Hashiguchi M, et al. Clinical predicition rule to distinguish pelvic inflammatory disease from acute appendicitis in women of childbearing age. *Am J Emerg Med* 2007;25: 152-157.

47. Cardall T, Glasser J, Guss DA. Clinical value of the total WBC count and the temperature in the evaluation of patients with suspected appendicitis. *Acad Emerg Med* 2004;11:1021-1027.

48. Ortega-Deballon P, Ruiz de Adara-Belbel J, Hernandez-Matias A, et al. Usefulness of laboratory data in the management of right iliac fossa pain in adults. *ASCRS* 2008;51: 1093-1099.

49. Birchley D. Patients with clinical acute appendicitis should have pre-operative full blood count and C-reactive protein assays. *Ann R Coll Surg Engl* 2006;88:27-32.

50. Maa J, Kirkwood KS. Ch. 49 The Appendix. In: Townsend CM, Beauchamp RD, Evers BM, et al. *Sabiston Textbook of Surgery*, 18th ed. Saunders: Philadelphia. 2008

51. Louie JP. Essential diagnosis of abdominal emergencies in the first year of life. *Emerg Med Clin North Am* 2007;25:1009-1040.

52. McCollough M, Sharieff GQ. Abdominal pain in children. *Pediatr Clin North Am* 2006;53:107-137.

53. Macari M, Balthazar E. The acute right lower quadrant: CT evaluation. *Radiol Clin North Am* 2003;41:1117-1136.

54. Ege G, Akman H, Sahin A, et al. Diagnostic value of unenhanced helical CT in adult patient with suspected acute appendicitis. *Br J Radiol* 2002;75:721-725.

55. Chang Y, Kong M, Hsia S, et al. Usefullness of ultrasonography in acute appendicitis in early childhood. *J Ped Gastroenterol Nutr* 2007;44:595-595.

56. Flasar MH, Goldberg E. Acute abdominal pain. *Med Clin North Am* 2006;90: 481-503.

57. Martinez JP, Mattu A. Abdominal pain in the elderly. *Emerg Med Clin North Am* 2006;24:371-388.

58. Ferentz KS, Nesbitt LS. Common problems and emergencies in the obstetric patient. *Prim Care* 2006;33:727-750.

59. Kamin RA, Nowicki TA, Courtney DS, et al. Pearls and pitfalls in the emergency department evaluation of abdominal pain. *Emerg Med Clin North Am* 2003;21:61-72.

60. Dixon JM, Elton RA, Rainey JB, et al. Rectal examination in patients with pain in the right lower quadrant of the abdomen. *BMJ* 1991;16:386-388.

61. Bergeron E, Richer B, Gharib R, et al. Appendicitis is a place for clinical judgment. *Am J Surg* 1999;177:460-462.

62. Birnbaum BA, Wilson SR. Appendicitis at the millenium. *Radiology* 2000;215: 337-348.

63. Rybkin AV, Thoeni RF. Current concepts in imaging of appendicitis. *Radiol Clin North Am* 2007;45:411-422.

64. Braveman P, Schaaf VM, Egerter S, et al. Insurance-related differences in the risk of

ruptured appendix. *N Engl J Med* 1994; 82:166-169.

65. Grosfeld JL, Weinberger M, Clatworthy HW Jr. Acute appendicitis in the first two years of life. *J Pediatr Surg* 1973;8: 285-293.

66. Brennan GD. Pediatric appendicitis: Pathophysiology and appropriate use of diagnostic imaging. *CJEM* 2006;8: 425-432.

67. Graffeo CS, Counselman FL. Appendicitis. *Emerg Med Clin North Am* 1996;14: 653-671.

68. Rothrock SG, Pagane J. Acute appendicitis in children: Emergency department diagnosis and management. *Ann Emerg Med* 2000;36:39-51.

69. Wagner JM, McKinney WP, Carpenter JL. Does this patient have appendicitis? *JAMA* 1996;276:1589-1594.

70. Bobrow BJ, Mohr J, Pollack CV Jr. An unusual complication of missed appendicitis. *J Emerg Med* 1996;14:719-722.

71. Martinez JP, Mattu A. Abdominal pain in the elderly. *Emerg Med Clin North Am* 2006;24:371-388.

72. Kraemer M, Franke C, Ohmann, et al. Acute appendicitis in late adulthood: Incidence, presentation, and outcome. Results of a prospective multicenter acute abdominal pain study and a review of the literature. *Langenbeck's Arch Surg* 2000;385:470-481.

73. Andersson REB. Meta-analysis of the Clinical and laboratory diagnosis of appendicitis. *Br J Surg* 2004;91:28-37.

74. Storm-Dickerson TL, Horattas MC. What have we learned over the past 20 years about appendicitis in the elderly? *Am J Surg* 2003;185:198-201.

75. Bickell NA, Aufses AH, Rojas M, et al. How time affects the risk of rupture in appendicitis. *J Am Coll Surg* 2006; 202:401-406.

76. Rao PM, Rhea JT, Rattner DW, et al. Introduction of appendiceal CT: Impact on negative appendectomy and perforation rates. *Radiology* 2002;225:131-136.

77. McDonald GP, Pendarvis DP, Wilmoth R, et al. Influence of pre-operative CT on patients undergoing appendectomy. *Am J Surg* 2001;67:1017-1021.

78. Henry MC, Walker A, Silvermann BL, et al. Risk factors for the development of abdominal abscess following operation for perforated appendicitis in children. *Arch Surg* 2007;142:236-241.

79. Dominguez EP, Sweeney JF, Choi YU. Diagnosis and management of diverticulitis and appendicitis. *Gastroenterol Clin North Am* 2006;35:367-391.

80. Knopp RK, Dries D. Analgesia in acute abdominal pain: What's next? *Ann Emerg Med* 2006;48:161-163.

81. Gallagher EJ, Esses D, Lee C, et al. Randomized clinical trial of morphine in acute abdominal pain. *Ann Emerg Med* 2006;48:150-160.

82. Silen W. *Cope's Early Diagnosis of the Acute Abdomen*. 21st edition. London: Oxford University Press; 2005.

83. Thomas SH, Silen W, Cheema F, et al. Effects of morphine analgesia on diagnostic accuracy in emergency department patients with abdominal pain: A prospective randomized trial. *J Am Coll Surg* 2003; 196:18-31.

84. Anderson BR, Kallehave FI, Anderson HK. Antibiotics vs placebo for prevention of post-operative infection after appendectomy. *Cochrane Database Syst Rev* 2005;(3): CD001439.

85. Muehlstedt SG, Pham TQ, Schmeling DJ. The management of pediatric appendicitis: A survey of North American pediatric surgeons. *J Ped Surg* 2004;39:875-879.

86. Newman K, Ponsky T, Kittle K, et al. Appendicitis 2000: Variability in practice, outcomes and resource utilization at 30 pediatric hospitals. *J Pediatr Surg* 2003;38:372-379.

87. Gillick J, Velaydham M, Puri P. Conservative management of appendiceal mass in children. *Br J Surg* 2001;88:1539.

88. Janik JS, Ein SH, Shandling B, et al. Nonsurgical management of appendiceal mass in late presenting children. *J Pediatr Surg* 1980;15:574.

89. Sauerland S, Leferring R, Neugebauer EA. Laproscopic versus open surgery for suspected appendicitis. *Cochrane Database Syst Rev* 2004;(4):CD0001546.

90. Oliak D, Yamini D, Udani VM, et al. Initial non-operative management for periappendiceal abscess. *Dis Colon Rectum* 2001; 44:936-941.

92. Brown C, Abrishami M, Miller M, et al. Appendiceal abscess: Immediate operation or percutaneous drainage. *Am Surg* 2003;69:829-833.

92. Stahlfeld K, Hower J, Homitsky S, Madden J. Is acute appendicitis a surgical emergency? *Am Surg* 2007;73:626-629.

93. Ditillo MF, Dziura JD, Rabinovici R. Is it safe to delay appendectomy in adults with acute appendicitis? *Ann Surg* 2006;244: 656-660.

94. Clyde C, Bax T, Merg A, et al. Timing of intervention does not affect outcome in acute appendicitis in a large community practice. *Am J Surg* 2008;195:590-592

Physician CME Questions

61. Regarding acute appendicitis in the elderly, which statement is true?
    A. There is a lower rate of perforation compared to young adults.
    B. The WBC is less likely to be elevated compared to young adults.
    C. There is a greater incidence of fever compared to young adults.
    D. Ultrasound is a useful modality to exclude the diagnosis.

62. Regarding appendicitis in childhood, which of the following statements is *false*?
    A. Diarrhea is more common in children < 3 years old than in older

Emergency Medicine Reports

CME Objectives

To help physicians:

- quickly recognize or increase index of suspicion for specific conditions;
- understand the epidemiology, etiology, pathophysiology, and clinical features of the entity discussed;
- apply state-of-the-art diagnostic and therapeutic techniques (including the implications of pharmaceutical therapy discussed) to patients with the particular medical problems discussed;
- understand the differential diagnosis of the entity discussed;
- understand both likely and rare complications that may occur.

CME Instructions

Physicians participate in this continuing medical education program by reading the article, using the provided references for further research, and studying the questions at the end of the article. Participants should select what they believe to be the correct answers, then refer to the list of correct answers to evaluate their knowledge. To clarify confusion surrounding any questions answered incorrectly, please consult the source material. *After completing this activity, you must complete the evaluation form that will be provided at the end of the semester and return it in the reply envelope provided to receive a certificate of completion.* When your evaluation is received, a certificate will be mailed to you.

children.
B. CT has higher sensitivity for the diagnosis of appendicitis in children than ultrasound.
C. Appendicitis is common in neonates.
D. Focal abdominal tenderness is not as common in young children with appendicitis as in older children.

63. Using a selective imaging approach for the diagnosis of acute appendicitis in children, which of the following statements is true?
A. Low-risk patients – CT
B. High-risk patients – no imaging, direct to OR
C. Intermediate-risk patients – US initially and, if negative, follow with CT
D. Intermediate risk patients – CT initially and, if negative, follow with US

64. Which of the following statements is *false*?
A. Traditionally, the appendix is thought to rise in the peritoneal cavity as pregnancy progresses, but recent research has called this dogma into question.
B. Ultrasound is equally useful in all stages of pregnancy to diagnose appendicitis.
C. Many symptoms seen in appendicitis may be seen in normal pregnancy as well.
D. Appendicitis is as common in pregnant patients as in the general population.

65. Which of the following statements is true regarding the use of MRI to diagnose acute appendicitis in a pregnant patient?
A. MRI is not as specific as CT.
B. MRI has known risks for fetal development.
C. MRI is not as useful as ultrasound.
D. MRI is highly sensitive.

66. Which of the following inflammatory marker combinations is the most sensitive for the diagnosis of acute appendicitis?
A. WBC > 10,000 and C-reactive protein < 6 mg/L
B. WBC > 9,000 and C-reactive protein > 6 mg/L
C. WBC > 10,000 and C-reactive protein > 6 mg/L
D. WBC < 10,000 and C-reactive protein < 6 mg/L

67. Which of the following statements regarding inflammatory markers in the diagnosis of acute appendicitis is *false*?
A. They are more sensitive early in the course (< 12 hours after onset of pain).
B. They cannot be used to exclude the diagnosis.
C. They are less useful in children and the elderly.
D. They are less specific than imaging modalities.

68. Regarding diagnosis and treatment of appendicitis, which of the following statements is *not true*?
A. Pre-operative antibiotic administration has been shown to decrease the incidence of post-operative wound infection and intra-abdominal abscess.
B. Laproscopic appendectomy is technically more difficult than traditional open appendectomy.
C. Analgesia should be withheld in abdominal pain patients until a firm diagnosis is established.
D. No threshold value for WBC or CRP will relaibly diagnose or exclude appendicitis.

69. Which of the following statements regarding surgical management of acute appendicitis is *false*?
A. Patients with a periappendiceal abscess should not undergo laporoscopic appendectomy.
B. Emergency surgery within 12 hours of diagnosis reduces the rate of perforation.
C. Laporoscopic appendectomy may increase the risk of post-operative abscess formation when compared to open appendectomy.
D. Open appendectomy is associated with a longer hospital stay than laporoscopic appendectomy.

70. What the most common complication of appendicitis?
A. generalized sepsis
B. appendico-cutaneous fistula
C. infertility
D. perforation
E. bowel obstruction

CME Answer Key

61. B; 62. C; 63. C; 64. B; 65. D; 66. C; 67. A; 68. C; 69. B; 70. D

In Future Issues

Oncologic Emergencies

Emergency Medicine Reports™ (ISSN 0746-2506) is published biweekly by AHC Media LLC, 3525 Piedmont Road, N.E., Six Piedmont Center, Suite 400, Atlanta, GA 30305. Telephone: (800) 688-2421 or (404) 262-7436.

Associate Publisher: Russ Underwood

Specialty Editor: Shelly Morrow Mark

Director of Marketing: Schandale Kornegay

GST Registration No.: R128870672

Periodicals Postage Paid at Atlanta, GA 30304 and at additional mailing offices.

POSTMASTER: Send address changes to Emergency Medicine Reports, P.O. Box 740059, Atlanta, GA 30374.

Back issues: $31. Missing issues will be fulfilled by customer service free of charge when contacted within one month of the missing issue's date.

Multiple copy prices: One to nine additional copies, $359 each; 10 to 20 additional copies, $319 each.

Subscriber Information

Customer Service: 1-800-688-2421

Customer Service E-Mail:
customerservice@ahcmedia.com
Editorial E-Mail:
shelly.mark@ahcmedia.com
World Wide Web page:
http://www.ahcmedia.com

Subscription Prices

1 year *with* 60 ACEP/60 AMA/60 AAFP Category 1/Prescribed credits: $544
1 year *without* credit: $399
Add $17.95 for shipping & handling
Resident's rate $199

Discounts are available for group subscriptions, multiple copies, site-licenses or electronic distribution. For pricing information, call Tria Kreutzer at 404-262-5482.

All prices U.S. only.
U.S. possessions and Canada, add $30 plus applicable GST. Other international orders, add $30.

Accreditation

AHC Media LLC is accredited by the Accreditation Council for Continuing Medical Education to provide continuing medical education for physicians.

AHC Media LLC designates this educational activity for a maximum of 60 *AMA PRA Category 1 Credits™*. Each issue has been designated for a maximum of 2.30 *AMA PRA Category 1 Credits™*. Physicians should only claim credit commensurate with the extent of their participation in the activity.

Approved by the American College of Emergency Physicians for 60 hours of ACEP Category 1 credit.

Emergency Medicine Reports has been reviewed and is acceptable for up to 39 Prescribed credits by the American Academy of Family Physicians. AAFP accreditation begins 01/01/09. Term of approval is for one year from this date. Each issue is approved for 1.50 Prescribed credits. Credit may be claimed for 1 year from the date of each issue. The AAFP invites comments on any activity that has been approved for AAFP CME credit. Please forward your comments on the quality of this activity to cmecomment@aafp.org.

This is an educational publication designed to present scientific information and opinion to health professionals, to stimulate thought, and further investigation. It does not provide advice regarding medical diagnosis or treatment for any individual case. It is not intended for use by the layman. Opinions expressed are not necessarily those of this publication. Mention of products or services does not constitute endorsement. Clinical, legal, tax, and other comments are offered for general guidance only; professional counsel should be sought for specific situations.

This CME activity is intended for emergency and family physicians. It is in effect for 24 months from the date of the publication.

AHC Media LLC

Emergency Medicine Reports
The Practical Journal for Emergency Physicians

Acute Appendicitis Part II

Appendicitis Mimics

Gastrointestinal Disease
- Bowel obstruction
- Cholecystitis
- Diverticulitis (right-sided)
- Duodenal ulcer
- Epiploic appendagitis
- Gastroenteritis
- Hernia
- Ileocolitis
- Inflammatory bowel disease (Crohn's disease)
- Intussusception
- Meckel's diverticulitis
- Mesenteric adenitis
- Neoplasm
- Omental torsion
- Pancreatitis
- Perforated viscus
- Volvulus

Genitourinary Disease
- Epididymoorchitis
- Nephrolithiasis
- Perinephric abscess
- Prostatitis
- Pyelonephritis
- Testicular torsion
- Urinary tract infection

Obstetric/Gynecologic Causes
- Ectopic pregnancy
- Endometriosis
- Mittelschmerz
- Ovarian cyst (ruptured)
- Ovarian torsion
- Ovarian tumor
- Pelvic inflammatory disease
- Tubo-ovarian abscess

Systemic
- Diabetic ketoacidosis
- Porphyria
- Sickle cell disease
- Henoch-Schonlein purpura

Miscellaneous
- Parasitic infection
- Pneumonia
- Psoas abscess
- Pulmonary infarction
- Rectus sheath hematoma

Antibiotic Options for Acute Appendicitis

Moderate Clinical Presentation

- Piperacillin/tazobactam
- Ampicillin/sulbactam
- Ticarcillin/clavulanate
- Ertapenem
- Moxifloxacin
- Ciprofloxacin or levofloxacin + metronidazole
- Cefepime + metronidazole
- Tigeycline

Moderate/Severe Clinical Presentation

- Imipenem or meropenem or doripenem
- Ampicillin + metronidazole + ciprofloxacin or levofloxacin
- Ampicillin + metronidazole + anti-pseudomonal aminoglycoside

Axial CT Image of a Pregnant Female

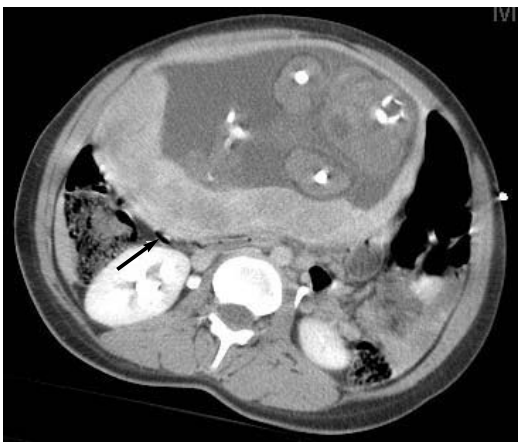

Axial CT image of a 9-month pregnant female who had CT scan performed due to blunt abdominal trauma sustained in a motor vehicle collision. The appendix has migrated up out of the pelvis and lies anterior to right kidney.
Image courtesy of Dan Gridley, MD, Vice Chair of Radiology, Maricopa Medical Center, Phoenix, AZ

Coronal Reconstruction View of the Same Patient as in Image Above

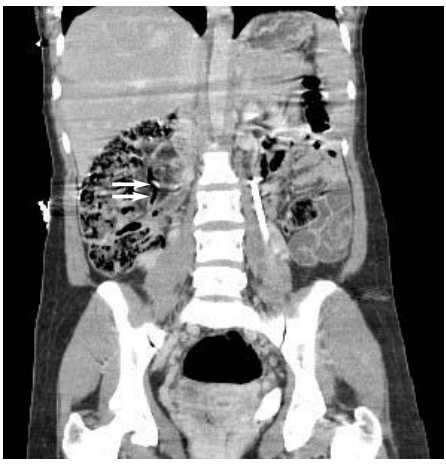

Image courtesy of Dan Gridley, MD, Vice Chair of Radiology, Maricopa Medical Center, Phoenix, AZ

Pregnant Female with Appendix in Right Lower Quadrant

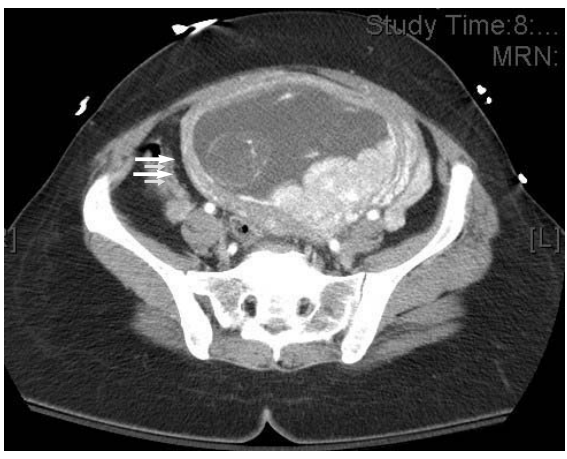

Axial CT image of a 7-month pregnant female showing the appendix has remained in the right lower quadrant.
Image courtesy of Dan Gridley, MD, Vice Chair of Radiology, Maricopa Medical Center, Phoenix, AZ

Coronal Reconstruction View of the Same Patient as in Image Above

Image courtesy of Dan Gridley, MD, Vice Chair of Radiology, Maricopa Medical Center, Phoenix, AZ

Supplement to *Emergency Medicine Reports*, March 16, 2009: "Acute Appendicitis Diagnosis and Treatment in 2009: Part II." *Authors:* **Lisa Freeman Grossheim, MD, FACEP**, Assistant Professor of Emergency Medicine, University of Texas Medical School at Houston; **Katrin Takenaka, MD, FACEP**, Assistant Professor of Emergency Medicine, University of Texas Medical School at Houston; and **Amy Noland, MD**, Resident, Department of Emergency Medicine, University of Texas Medical School at Houston.

Editors: Sandra M. Schneider, MD, FACEP, and J. Stephan Stapczynski, MD. **Associate Publisher:** Russ Underwood. **Specialty Editor:** Shelly Morrow Mark. For customer service, call: **1-800-688-2421.**

Emergency Medicine Reports
The Practical Journal for Emergency Physicians

EMRM031609TM

CME Evaluation

Please take a moment to answer the following questions to let us know your thoughts on the CME program. Fill in the appropriate space and return this page in the envelope provided. **You must return this evaluation to receive your certificate. ACEP members — Please see reverse side for option to mail in answers.** Thank you.

CORRECT ● INCORRECT ◐ ✓ ✗ ⚠

1. If you are claiming physician credits, please indicate the appropriate credential: ○ MD ○ DO ○ Other _____

After participating in this program, I am able to:	**Strongly Disagree**	**Disagree**	**Slightly Disagree**	**Slightly Agree**	**Agree**	**Strongly Agree**
2. Recognize or increase index of suspicion for specific conditions.	○	○	○	○	○	○
3. Understand the epidemiology, etiology, pathophysiology, and clinical features of the entity discussed.	○	○	○	○	○	○
4. Apply state-of-the-art diagnostic and therapeutic techniques (including the implications of pharmacologic therapy discussed) to patients with the particular medical problems discussed.	○	○	○	○	○	○
5. Understand the differential diagnosis of the entity discussed.	○	○	○	○	○	○
6. Understand both likely and rare complications that may occur.	○	○	○	○	○	○
7. The test questions were clear and appropriate.	○	○	○	○	○	○
9. I am satisfied with customer service for the CME program.	○	○	○	○	○	○
10. I detected no commercial bias in this activity.	○	○	○	○	○	○
11. This activity reaffirmed my clinical practice.	○	○	○	○	○	○
12. This activity has changed my clinical practice.	○	○	○	○	○	○

If so, how? _____

13. How many minutes do you estimate it took you to complete this entire semester (13 issues) activity? Please include time for reading, reviewing, answering the questions, and comparing your answers with the correct ones listed. _____ minutes.

14. Do you have any general comments about the effectiveness of this CME program?

_____

I have completed the requirements for this activity.

Name (printed) _____ **Signature** _____

Please make label address corrections here or PRINT address information to receive a certificate.

Account # _____

Name: _____

Company: _____

Address: _____

City: _____ State: _____ Zip _____

Fax: _____ Phone: _____

E-mail: _____

PLEASE NOTE: If your correct name and address do not appear below, please complete the section at left.

In accordance with ACEP requirements, below we provide the option for ACEP members to submit their answers to this CME activity. If you wish to submit answers to this activity, please refer to **Vol. 30, No. 7**, and circle the correct responses.

ACCIDENTAL HYPOTHERMIA

61. A B C D 62. A B C D 63. A B C D 64. A B C D 65. A B C D 66. A B C D 67. A B C D
68. A B C D 69. A B C D 70. A B C D