AHC Media LLC

Enclosed in this issue: CNE/CME Evaluation

Evidence-Based M[illegible] ED

Trauma Reports

Vol. 11, No. 1

Supplement to *Emergency Medicine Reports* and *Pediatric Emergency Medicine Reports*

Jan./Feb. 2010

Injuries of the hand and wrist present significant clinical challenges to the trauma practitioner because of the complex structures involved and the possibility of occult disruptions. The initially benign appearance of many hand/wrist injuries should not diminish the physician's cautionary attendance: if mismanaged, some injuries may progress to permanent disability or amputation. The authors discuss common hand and wrist injuries that can lead to significant disability if missed or not stabilized, and how complications can be prevented through a systematic examination and a heightened suspicion for hidden injuries.

— The Editor

Hand and Wrist Injuries: Diagnosing Challenges

Authors: **Michael C. Bond, MD, FACEP, FAAEM**, Assistant Professor, University of Maryland School of Medicine, Department of Emergency Medicine, Baltimore; and **George C. Willis, MD**, Emergency Medicine PGY-3, University of Maryland Medical Center, Baltimore.

Peer Reviewer: **Richard J.L. Phillips, MD, FAAP**, Assistant Professor of Surgery (retired), Wayne State University, Detroit, MI; Co-chief of Plastic Surgery (retired), Children's Hospital of Michigan.

Initial Evaluation

In the patient presenting with hand and/or wrist trauma, a thorough history, including the mechanism of injury, concomitant injuries, pre- and post-injury functional capacity of the hand and wrist, hand dominance, and effect of the injury on activities of daily living and on the patient's work status should be obtained. A thorough physical examination of the hand and wrist is necessary to elicit points of maximal tenderness, assess strength in the hand and wrist, and identify limitations in range of motion. The injured hand should be compared with the opposite hand to ascertain the patient's normal baseline function; determining functional status will ultimately guide disposition. Patients who have injured their dominant hand require more prompt follow-up to optimize functional outcome. A thorough initial evaluation will assist in avoiding repeat visits to the radiology department, delays in diagnosis, misdiagnosis, and other concomitant injuries.

Anatomy of the Hand and Wrist

An understanding of the functional anatomy of the hand is useful in guiding the physical examination. The skeletal relationships and function of specific areas of the hand and wrist allow

Statement of Financial Disclosure

Dr. Dietrich (editor in chief), Drs.Bond and Willis (authors), and Phillips (peer reviewer), and Ms. Behrens (nurse reviewer) report no relationships with companies related to this field of study.

toleration of some degree of angulation or displacement after certain fractures but not after others. The ability to accurately and concisely describe the bones of the hand and wrist and the injury sustained will facilitate communication with orthopedic/hand consultants.

Fractures should be described in reference to the patient's anatomic position, i.e., with the arms of the patient at his or her side with the palms facing anteriorly and the thumb lateral to the other digits. Volar angulation refers to angulation of the distal fragment anteriorly, and dorsal angulation refers to angulation of the distal fragment posteriorly.

The functional center of the hand is the base of the second and third metacarpals. This area acts as the immobile center around which all other movement of the hand is centered. Any misalignment or inadequate reduction in this area can have profound effects on hand movement. Moving away from this functional center, to sites where the bones are more mobile, more tolerance is allowed for imperfect reduction. For example, 30° to 40° of volar angulation is allowed with Boxer' fractures (fifth metacarpal neck fractures), but less than 10° is permitted for fractures of the second metacarpal neck.

Any degree of rotation of a fractured metacarpal or phalanx will result in overlap of fingers and thus functional impairment, and therefore requires a hand surgeon's evaluation. Three methods have been described to check for malrotation:

1. Look at the fingertips when the fingers are completely flexed. All of them should point to the medial proximal scaphoid.
2. Compare the planes of the fingernails on the injured hand with those on the uninjured hand. The corresponding finger on the opposite hand should have a similar fingernail plane.
3. Using the radiographs, measure the width of the bone on both sides of the fracture. They should be the same. A discrepancy suggests that the distal portion of the bone is rotated, displaced, or impacted.

Malrotation is difficult to reduce in spiral and oblique fractures of the phalanx and metacarpals. Usually, operative reduction and stabilization are required.

A thorough neurologic and tendon examination of the hand must be completed before anesthesia is administered. A normal individual should be able to distinguish two blunt points (formed with the end of a paper clip) that are 2 mm to 5 mm apart at the fingertips and 7 mm to 10 mm apart at the base of the palm.[1] The opposite hand can be used for comparison in individuals with suspected baseline neuropathies related to diabetes or other systemic diseases. A patient with a partial tendon laceration may retain full function and may experience pain only when resistance is applied. If a tendon injury is suspected, inspect and visualize the tendon through its full range of motion. It is common for a lacerated tendon to be missed if the hand is examined only in full extension (i.e., with the hand outstretched on a table), since most injuries occur with the fist clenched and the tendon will retract into the hand when the fingers are outstretched.

Adequate anesthesia allows a thorough examination for foreign bodies and occult tendon or vascular injuries without causing undue discomfort for the patient. Digital nerve blocks or wrist blocks provide excellent anesthesia and prevent distortion of local wound edges. Contrary to common teachings, lidocaine with epinephrine has been shown to be safe for digital and wrist nerve blocks.[2-8] It appears that highly acidic procaine (documented pH of 1) was the cause of the digital necrosis that was seen in the 1940s. The U.S. Food and Drug Administration (FDA) published a recall of procaine of several lots of procaine due to a documented pH of 1.[9] Epinephrine was an innocent bystander in less than half of the documented case reports.[7] Lidocaine with epinephrine is preferred over plain lidocaine or bupivicaine, as it prolongs the effect of the lidocaine, allows a higher dose of lidocaine to be given without toxic side effects, and helps to reduce bleeding that can obscure the field of view and make repair and evaluation of the patient more difficult.

High-Pressure Injection Injuries

High-pressure injection injuries of the hand often have an initially benign appearance but have the potential for devastating consequences, including amputation of the finger/hand or the need for multiple surgical debridements.[10] These injuries often occur when individuals attempt to clear the nozzle of a paint gun or power injector while the trigger is depressed. Unfortunately, the treatment of these injuries is often delayed because the patient does not consider the wound serious and thus does not seek immediate medical attention, or because the initial treating physician is fooled by the benign appearance of the wound. After several hours, the finger or hand swells, leading to a compart-

Trauma Reports™ (ISSN 1531-1082) is published bimonthly by AHC Media LLC, 3525 Piedmont Road, N.E., Six Piedmont Center, Suite 400, Atlanta, GA 30305. Telephone: (800) 688-2421 or (404) 262-7436.

Associate Publisher: Coles McKagen
Managing Editor: Allison Weaver
Director of Marketing: Schandale Kornegay

POSTMASTER: Send address changes to ***Trauma Reports***, P.O. Box 740059, Atlanta, GA 30374.

Accreditation

AHC Media LLC is accredited by the Accreditation Council for Continuing Medical Education to provide continuing medical education for physicians.

AHC Media LLC designates this educational activity for a maximum of 2.5 AMA *PRA Category 1 Credits™*. Physicians should only claim credit commensurate with the extent of their participation in the activity.

Approved by the American College of Emergency Physicians for 2.5 hours of ACEP Category 1 credit.

AHC Media LLC is accredited as a provider of continuing nursing education by the American Nurses Credentialing Center's Commission on Accreditation.

Provider approved by the California Board of Registered Nursing, Provider # 14749, for 1.5 Contact Hours.

AHC Media LLC

Subscriber Information

Customer Service: 1-800-688-2421

Customer Service E-Mail: customerservice@ahcmedia.com
Editorial E-Mail: allison.weaver@ahcmedia.com

World Wide Web page: http://www.ahcmedia.com

FREE to subscribers of *Emergency Medicine Reports* and *Pediatric Emergency Medicine Reports*

Subscription Prices

United States
$249 per year. Add $17.95 for shipping & handling
Multiple Copies
Discounts are available for group subscriptions, multiple copies, site-licenses or electronic distribution. For pricing information, call Tria Kreutzer at 404-262-5482.
All prices U.S. only. U.S. possessions and Canada, add $30 postage plus applicable GST.
Other international orders, add $30.

This is an educational publication designed to present scientific information and opinion to health professionals, to stimulate thought, and further investigation. It does not provide advice regarding medical diagnosis or treatment for any individual case. It is not intended for use by the layman. Opinions expressed are not necessarily those of this publication. Mention of products or services does not constitute endorsement. Clinical, legal, tax, and other comments are offered for general guidance only; professional counsel should be sought for specific situations.

This CME/CNE activity is intended for emergency, family, osteopathic, trauma, surgical, and general practice physicians and nurses who have contact with trauma patients.

It is in effect for 24 months from the date of publication.

For Customer Service,
Please call our customer service department at **(800) 688-2421.** For editorial questions or comments, please contact **Allison Weaver**, Managing Editor, at allison.weaver@ahcmedia.com.

ment syndrome associated with numbness and significant pain. The swelling can be secondary to tissue disruption by the high-pressure agent or to chemical irritation and an inflammatory response caused by the injected material. Even with optimal therapy, these injuries often result in amputation or permanent weakness, numbness, and loss of function.

Most high-pressure injection injuries occur in middle-age men and most commonly affect the non-dominant index finger. Hogan and colleagues[11] reviewed the published case reports of high-pressure injuries and found that injuries involving organic solvents (oil-based products) had a higher rate of amputation if the initial debridement took place more than six hours after the time of injury (58% versus 38%) or if debridement was not done (88%). The authors did not find a difference in amputation rates with non-organic solvents if there was a delay in debridement. Injection injuries to the fingers had a higher rate of amputation than injection injuries involving the thumb or palm. Due to the high pressure, the injected material can be forced along fascia planes, within tendon sheaths, or along neurovascular bundles, which can cause damage a fair distance from the initial injection site.

The initial management of a high-pressure injury should include radiographs and broad-spectrum antibiotics. Radiographs facilitate the assessment of the proximal spread of the injected agent. Radio-opaque compounds can be seen on the radiograph, and radiolucent compounds can be seen in the soft tissue as a lucency or as air that is concomitantly injected. Most hand surgeons recommend corticosteroids to decrease the inflammatory response, though no studies have proven their efficacy.[11] Obtain a prompt evaluation by a hand surgeon; to determine whether the patient needs operative debridement. The hand surgeon will want to know the type of liquid/ material that was injected, the time of injection, the pressure of the injection device, the location of the entrance wound, and the extent of radio-lucency or radio-opaque material on radiographs.The patient's tetanus immunization should be updated if warranted. Elevate the affected hand to reduce inflammation.

Fight Bites

Fight bites, or clenched-fist wounds, are high-risk injuries that often have delayed presentations and are associated with fractures, tendon lacerations, retained foreign bodies, joint involvement, and polymicrobial infections. The associated injuries can be easily overlooked by the unsuspecting emergency medicine physician. Caring for patients with these injuries is complicated by the fact that the patients often are intoxicated or give misleading stories about how the injury was sustained. Approach clenched-fist wounds methodically to prevent complications that could lead to permanent disability.[12]

Patients presenting soon after sustaining a fight bite may have a benign-appearing abrasion or laceration overlying the fourth or fifth metacarpal head. The skin overlying the metacarpal head provides little protection to underlying structures, so it is not uncommon for a tooth to penetrate into the extensor tendon, tendon sheath, or the metacarpophalangeal joint space. This can result in deep-seated infections that can be rapidly destructive and lead to permanent disability. Infections in this area are difficult to treat because of the relatively avascular nature of the extensor tendon and cartilage of the metacarpal head.[13]

All patients who present with injuries consistent with a fight bite should have a radiograph of their hand. This will identify fractures of the metacarpal and retained foreign bodies. The wound needs to be explored adequately to exclude tendon or joint space injuries. Examine the tendon through its full range of motion, in particular with the fingers fully flexed. The area of tendon that was injured at the time of impact would likely be pulled more proximally when the fingers are extended.

Place the patient on broad-spectrum antibiotics that cover the multiple aerobic and anaerobic bacteria in a human's mouth. Amoxicillin-clavulanic acid or clindamycin is recommended. Any fight bite with an associated fracture needs to be treated as an open fracture. Update the patient's tetanus immunization as necessary. Patients who do not have associated injuries should have close follow-up (in one or two days) to reevaluate for infection.

Patients with fight bites may also present several days after injury with a well-established infection that requires admission for intravenous antibiotics and a hand surgeon's evaluation.

Closed Tendon Injuries

Closed tendon injury—injury to a tendon without any laceration—is a high-risk injury that can be missed on the initial presentation. These injuries can initially appear benign and yield normal radiographs. If left untreated, these injuries can lead to loss of motion; many require surgical correction. All patients with closed tendon injuries should have timely follow-up with a hand surgeon to ensure proper healing and determine if surgical repair will be necessary.

Mallet Finger. Mallet finger usually results from a direct blow to the fingertip that forcefully extends the finger, causing disruption of the lateral bands of the extensor tendon as they insert into the base of the distal phalanx. Occasionally, an avulsion fracture of the base of the distal phalanx can be seen on radiographs, but it is not uncommon for the tendon to be pulled completely off without any bony deformity. Patients may complain of pain at the base of the distal phalanx and may have a lag in their ability to extend the finger or be unable to completely extend their fingertip. (However, lag may not develop for several days.[14]) This injury can result in permanent flexion of the fingertip and lead to a swan-neck deformity if not treated appropriately.[15]

Mallet fingers can usually be treated conservatively, with the distal interphalangeal (DIP) joint splinted in full extension for 6–8 weeks. Inform the patient that any flexion of the DIP joint restarts the six- to eight-week splinting period. Patients may need to adjust their splint at times and should be instructed to rest their finger on a countertop in full extension when they make adjustments. Apply the splint to the dorsal surface of the finger, with the proximal interphalangeal (PIP) and metacarpophalangeal (MCP) joints free.

Rupture of the Central Slip. Rupture of the central slip at the PIP joint typically results from forced flexion of the PIP joint when it is held in extension or from volar dislocation of the PIP

Figure 1. Ulnar Collateral Ligament Rupture

Ulnar collateral ligament rupture with fracture of the volar plate of the proximal phalanx.

joint, rupturing the volar plate. The result can be a boutonniere deformity.[16] This injury is common in sports; in many cases, the injured person or someone else, typically a coach or trainer, initially treats the injury by reducing the dislocation. Patients complain of swelling of the PIP joint and have maximal tenderness over its dorsal surface. There may be limited extension at the PIP joint, but full extension can be seen through the action of the lateral bands. Full extension at the PIP joint does not indicate that the central slip is undamaged.[16]

Obtain radiographs to rule out fractures and dislocations. Since a definitive diagnosis of central slip injury may not be made in the emergency department (ED), it is prudent to treat patients in which this diagnosis is suspected by splinting the PIP joint in full extension and facilitating close, timely follow-up with a hand surgeon. The MCP and PIP joints should be allowed to move freely to prevent contractures.[10]

Extensor Hood Rupture. An extensor hood rupture occurs at the MCP joint and allows subluxation of the central tendon, preventing full extension. This occurs from forced flexion or extension at the MCP joint or from blunt trauma. It is often called the "flea flicker" injury when it is a result of forcibly trying to flick something away,[14] and it has been called "boxer's knuckle" when associated with boxing or blunt trauma.[17,18] The injury is disruption of the peripherally located sagittal bands that hold the central tendon in place.[10] The central tendon can subluxate in either direction but typically subluxates ulnarly. The middle (long, third) finger is most commonly affected, followed by the index (second) finger.[14] Patients complain of pain overlying the MCP joint and may have loss of full extension at that joint, or they may notice popping and instability of the MCP joint when it is actively flexed and extended. Passive range of motion (ROM) is normal. The physician may notice the central tendon relocate centrally when the finger is fully extended. Though patients with this injury cannot fully extend the MCP joint actively, they are able to hold it in full extension once it is placed there passively.

Extensor hood injuries can be treated with surgical repair or extension splinting. Extension splinting can result in an extension contracture, so it is imperative that only the affected finger be splinted. Several case series summarized by Arai and colleagues[19] demonstrated that operative repair is associated with a more favorable functional outcome and decreased pain. When placing a patient in an extension splint, passively move the MCP joint until you see the central tendon relocate.[14] Splint the MCP joint in that position and arrange for urgent hand surgery evaluation.

If a closed tendon injury is suspected, the patient should be treated as such and instructed to follow up with a hand surgeon. As an adjunct and if readily available in your ED, consider obtaining magnetic resonance imaging (MRI) or ultrasound (US) imaging of the hand to help make the diagnosis. High-resolution (12- MHz to 15- MHz) ultrasound has been shown in several studies to be more sensitive than MRI in diagnosing complete and partial extensor tendon tears and is usually quickly and easily performed.[20-23] Since MRI and US are unlikely to change the emergent treatment, and, in the case of MRI in particular, can prolong length of stay, they are typically done on an outpatient basis.

Ulnar Collateral Ligament Rupture. Rupture of the ulnar collateral ligament (UCL) results from forced radial deviation and hyperextension of the thumb. Such an injury results in "gamekeeper's thumb." Gamekeeper's thumb was originally associated with hunters and farmers who snapped the necks of game animals. It is now more commonly associated with skiing, basketball, wrestling, and martial arts. It is common for the volar plate of the proximal phalanx to be pulled off with the ligament. *(See Figure 1.)*

The patient presents with a painful swollen thumb that is tender over the ulnar side of the MCP joint. The finger may be deviated radially. Radiographs should be obtained prior to stressing the joint (stressing the joint can displace a volar plate fracture [Stener lesion]).[24] If no fracture is seen on radiographs, the joint can be stressed to make the diagnosis of a partial or complete tear. Radial deviation of the thumb more than 35° as it is stressed indicates a complete tear. Use the uninjured thumb for comparison to ascertain the patient's normal degree of laxity.

UCL injuries can be treated with a thumb spica splint that allows movement at the interphalangeal (IP) joint. Referral to a hand surgeon is also recommended, and mandatory for suspected complete tear, since even if the patient does not require surgery, casting and custom splinting will be required to maximize functional outcomes and prevent long-term disability.[14]

Tendon Lacerations/Tears. Missed tendon lacerations can lead to permanent disability and increase the physician's risk of litigation. Though the emergency medicine physician is not expected to do a primary repair of tendon lacerations, the injury

Figure 2. Zone Classifications – Flexor Tendon injuries of the Hand

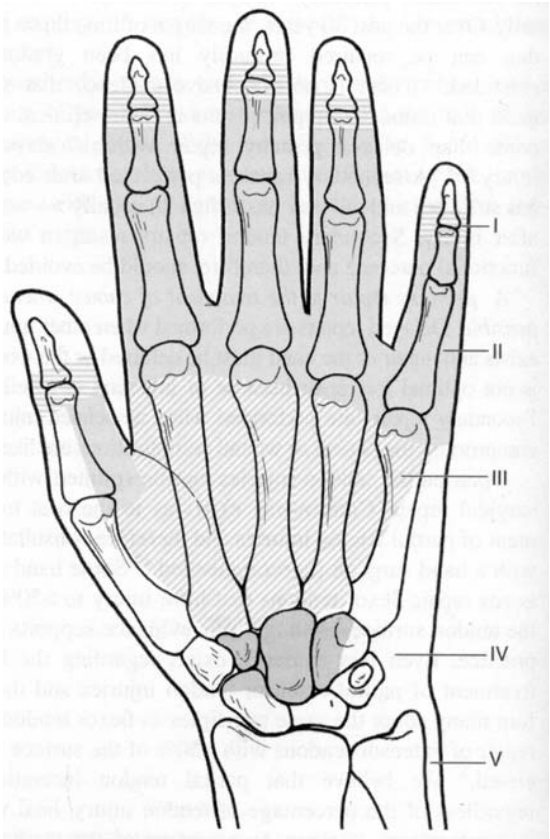

Zone classifications for flexor tendon injuries of the hand. Reproduced with permission from The McGraw-Hill Companies. Simon RR. *Emergency Orthopedics : The Extremities* (5th ed.) New York: McGraw-Hill; 2007:1162.

Figure 3. Zone Classifications – Extensor Tendon Injuries of the Hand

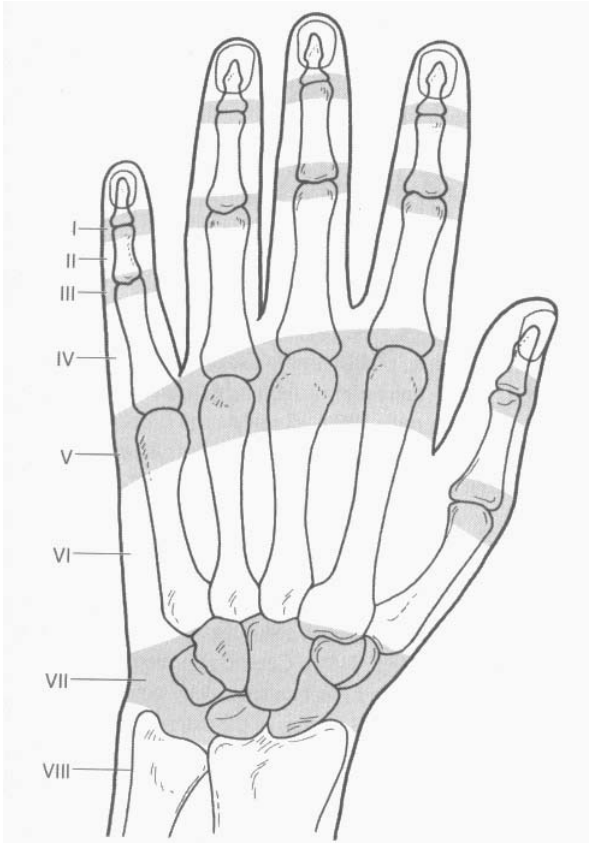

Zone classifications for extensor tendon injuries of the hand. Reproduced with permission from The McGraw-Hill Companies. Simon RR. *Emergency Orthopedics : The Extremities* (5th ed.) New York: McGraw-Hill; 2007:1163.

needs to be diagnosed so that proper consultation and follow-up can be arranged. Explore all lacerations of the hand carefully, with adequate light and anesthesia to ensure that the entire depth is visualized. The exploration should note any foreign bodies as well as joint, bone, nerve, tendon, or vascular injury. Because tendons move and retract, examine them through the fingers' entire range of motion.

Flexor tendon injuries are divided into five zones *(see Figure 2),* and require careful exploration by a hand surgeon because of the risk of associated injuries and the difficulty of repair. They are often associated with joint, nerve, or vascular injury.

Flexor zone III injuries extend from the distal edge of the carpal bones to the proximal edge of the flexor sheath near the MCP joint. This is the only zone that does well with primary repair, though it is usually recommended that all flexor tendon injuries be repaired by a hand surgeon, owing to the high rate of complications that can occur even after an optimal repair.

Extensor tendon injuries are divided into eight zones over the proximal phalanx and distal hand. *(See Figure 3.)* They can be repaired primarily by an ED physician who has the experience to do so. These are repaired with a figure-of-eight or the complex Bunnell stitch using non-absorbable 4.0 or 5.0 suture material.[10] The tendon fibers in the hand are thin and flat, with longitudinal fibers that do not hold sutures well; a successful repair can be accomplished after a delay of up to seven days.[25,26] Therefore, it is recommended that a hand surgeon make the repairs, being better equipped to handle any associated complications that might occur.

Because of the complexity of tendon injuries, it is acceptable to loosely reapproximate the wound edges and splint the hand until follow-up can be obtained. The proper position should be confirmed through consultation with a hand specialist while the patient is still in the ED. General recommendations are presented here:

For flexor tendon injuries, place the patient in a dorsal splint to prevent extension of the wrist and fingers. Typically, place the wrist in 30° of flexion and the MCP joints in 50° to 70° of flexion. For zone IV lacerations, splint the wrist in neutral position and the MCP joints in 75° to 90° of flexion. When the flexor pollicis longus is injured, flex the wrist at 50° and the MCP and DIP at 15° to 20°.[27]

Figure 4. Boxer's Fracture

Figure 5. Bennett's Fracture

Splint the PIP and DIP joints in partial flexion at 10° and 5°, respectively. This is different from the typical position of function (the "wine glass" position) that has the wrist extended at 25° and the MCP, PIP, DIP joints flexed at 60°, 10°, and 5°, respectively.

Immobilize extensor tendon injuries with a volar splint to prevent flexion. Injuries in zones I and II are treated with the DIP joint held in extension with a dorsal splint; the PIP and MCP joints are allowed to move freely. Open zone III and IV injuries are splinted with the PIP joint in neutral position, the MCP joint at 15° to 30° of flexion, and the wrist in 30° of extension. Zone V injuries, over the MCP joint, should be splinted with the MCP joint in neutral position and the wrist in 45° of extension. Zone VI, VII, and VII injuries are typically treated with the MCP joint in neutral position and the wrist in 20° of extension.[10,26,28]

Hand Fractures

Boxer's Fracture. The boxer's fracture is one of the most common fractures seen in the ED. *(See Figure 4.)* This is the common name for a fracture through the neck of the fifth metacarpal, which typically results from striking a closed fist against a hard immovable object. This fracture is associated with volar angulation. On physical examination, patients complain of tenderness over the distal metacarpal and may have a palpable depression or loss of the normal "knuckle."

After radiographs are obtained to confirm the diagnosis, the fracture should be reduced. Anesthesia can be provided with procedural sedation, local anesthetic, or hematoma block, though a wrist block is an easier and safer option. Place the hand in finger traps and hang a weight from the arm to disimpact the bone ends and reduce the fracture. If finger traps are not available, use rolled gauze to wrap around the fifth finger and then hang the hand from an IV pole. One can also attempt to reduce these fractures manually. When doing so, first attempt to disimpact the bone ends by applying some longitudinal traction on the finger, and then move the distal fragment dorsally to obtain proper alignment. The volar angulation often cannot be reduced completely; however, because of the large amount of moment in this finger, a volar angulation of less than 40° will usually have no appreciable loss of function. Place the hand in an ulnar gutter splint, with the MCP joints flexed to 90° and the wrist at 20° of extension.

Fourth metacarpal neck fractures can be treated the same as boxer fractures. Fractures of the second and third metacarpal necks can be treated with a radial gutter splint. The amount of volar angulation that is acceptable is less than 10°.

Bennett's Fracture. Bennett's fracture, also associated with fights, is an intra-articular fracture dislocation of the first metacarpal at the carpometacarpal joint. *(See Figure 5.)* The usual mechanism is a direct blow that results in an axial load on the thumb with a partially flexed metacarpal. A Bennett's fracture is a two-part fracture: the main body of the first metacarpal is typically displaced radially and dorsally due to the pull of thumb extensors. A palmar-ulnar piece of the base of the first metacarpal remains in its correct anatomic location because of an intact palmar oblique ligament. This fracture can be treated conservatively with a thumb spica splint if adequate reduction can be achieved with both fragments in contact and in good alignment.[29] However, this fracture typically requires operative repair to

Figure 6. Rolando Fracture

Figure 7. Scaphoid Fracture

ensure good alignment and reduce the risk of osteoarthritis and permanent disability.

Rolando Fracture. A close relative to Bennett's fracture is the Rolando fracture. *(See Figure 6.)* This is a three-part intra-articular fracture at the base of the first metacarpal. This fracture has the same ulnar fragment as Bennett's fracture but typically has a large dorsal fragment that gives the fracture lines a "Y" or "T" shape. The Rolando fracture fares worse than the Bennett's fracture and almost always requires operative repair to obtain good anatomic alignment. Initial treatment can consist of a thumb spica splint, with a hand surgeon's evaluation as soon as possible.

Metacarpal Shaft Fracture. The significance of these fractures often is not fully appreciated, nor is the fact that less angulation is permitted with shaft fractures than with metacarpal neck fractures. These fractures can lead to significant long-term disability if not reduced properly. Reduction can be done with longitudinal traction and then gentle movement of the distal finger into the correct position. Another technique is to flex the MCP joint to 90° and then push the proximal phalanx dorsally to reduce the fracture. Ensure that there is no rotational deformity and that any significant angulation is reduced. Anesthesia can be provided with a wrist block.

Non-displaced transverse fracture can be treated by placing the patient in a radial or ulnar gutter splint, similar to treatment of a boxer's fracture. The wrist should be extended 30°, with the MCP joints at 90° and the DIP and PIP joints extended.

Patients with displaced, angulated, comminuted, spiral, or oblique fractures of the metacarpal shafts should be referred to a hand surgeon for definitive treatment. If the hand needs to be splinted temporarily, remember that no angulation is permitted in the second and third metacarpals (the index and middle fingers, respectively). Ten degrees of angulation is permitted in the fourth metacarpal (the ring finger) and up to 20° in the fifth metacarpal. These patients are typically placed in a dorsal and volar "sandwich" splint that encompasses the entire metacarpal but not the MCP joint. Oblique, spiral, and comminuted fractures are difficult to treat in a closed manner and are often associated with significant angulation or rotation. Place the patient in a bulky compressive dressing until he or she can be seen by a hand surgeon.[10]

Phalanx Fracture. Proximal and middle phalanx fractures are often not treated with the respect they deserve. Many of these fractures are unstable and can result in significant angulation or rotational deformities that may ultimately result in diminished function. Scar tissue formation in the extensor and flexor mechanisms, which are closely approximated to the bone, may also be associated with the injury, resulting in additional complications and functional decline.

For treatment purposes, proximal and middle phalanx fractures are typically divided into categories such as intra-articular, extra-articular, non-displaced, displaced, angulated, spiral, and comminuted. However, the two options that are typically recommended are a dynamic splint for stable fractures and a gutter splint for unstable fractures. For the sake of simplicity, it is recommended that all of these fractures be placed into a radial or ulnar gutter splint, with the MCP flexed at 90° and the PIP joint extended. This will provide the greatest stability until the patient can follow up with a hand surgeon within a few days. Finger splints do not provide adequate stabilization and should be avoided.

Distal phalanx fractures can be treated with a dorsal splint, except when there is an intra-articular fracture along the volar surface. Volar intra-articular fractures should be treated with a volar splint. Any patient with a fracture that is intra-articular needs to be referred to a hand surgeon to determine if surgical correction is warranted.

The Wrist

Scaphoid Fracture. The scaphoid bone is the most commonly fractured bone in the wrist. *(See Figure 7.)* This injury typically occurs in young adult males and is associated with gymnastics and contact sports.[30-33] It accounts for 10% of all hand fractures and 60% to 70% of all carpal fractures. Unfortunately, it is also one of the most frequently misdiagnosed fractures. Missing this diagnosis predisposes the patient to significant complications, including chronic arthritis, diminished strength, and loss of function.

The scaphoid acts as the connecting bone between the proximal carpal row, the radius, and the distal carpal row. It is the primary bone for the radiocarpal joint and assists in both flexion and extension of the wrist. With any instability in the connection provided by the scaphoid, the wrist joint will become unstable and prone to collapse. Due to a large articular surface with the other bones in the radiocarpal joint, there is only a small area for the entry of its vascular supply. This supply arises mainly from the radial artery and enters near the most distal portion of the scaphoid bone, predisposing the scaphoid to a higher incidence of avascular necrosis and nonunion when injured.

The mechanism of injury typically involves either direct axial compression of the first metacarpal against the scaphoid or, more commonly, hyperextension of the radially deviated wrist, as in a fall on an outstretched hand (FOOSH) injury, which forces the waist of the bone against the distal radius. Sixty-five percent of these fractures occur at the waist of the scaphoid.[30]

Clinically, patients complain of pain on the radial portion of the wrist. They may also experience loss of function in the hand, such as decreased grip strength. They may exhibit signs of swelling, specifically in the anatomic snuffbox, which may be a sign of joint effusion. Anatomic snuffbox tenderness does not guarantee a fracture, but its absence makes a fracture significantly less likely. Maneuvers that have more specificity include tenderness to palpation of the scaphoid tubercle and axial compression of the first metacarpal against the scaphoid. The tubercle can be palpated along the volar-radial surface of the distal wrist crease while holding the wrist in extension.[33] All three signs separately have low specificity, but their specificities double when combinations of the signs are present.[34]

Obtain radiographs; standard posteroanterior (PA) and lateral radiographs are often insufficient and miss 10% to 20% of these fractures.[30] Therefore, obtain a dedicated scaphoid view, which is a partial oblique view of the wrist. This displays the scaphoid in its longitudinal axis and often reveals a fracture that was missed on the PA and lateral views.

Traditionally, clinicians treat patients with anatomic snuffbox tenderness, in whom they have a high clinical suspicion for a scaphoid fracture, despite negative radiographs, as having an occult fracture. The approach consists of placing the injured wrist in a thumb spica splint and repeating the radiographs in one to two weeks, at which time the fracture should be more evident. This subjects the patient to immobilization and loss of work and often is unnecessary, as most injuries with these characteristics prove to involve the soft tissue. For patients who are not amenable to immobilization, computed tomography (CT) scans can be used to confirm the diagnosis. CT scans are nearly 90% sensitive and highly specific for scaphoid fractures and should be used to make a definitive diagnosis when appropriate.[35-37] If patients can be immobilized for short periods of time, referring them for outpatient MRI or bone scintigraphy in 3–5 days is another option that has shown to be highly specific for an occult fracture.[37-41]

Splint nondisplaced distal fractures in a long-arm thumb spica splint for 6–10 weeks and refer the patient for outpatient follow-up. Fractures that are displaced >1 mm, involve disruption of the scapholunate ligament, or are located in the proximal third of the bone are unstable until proven otherwise. Splint patients with these fractures in a long-arm thumb spica and refer them for urgent orthopedic evaluation, as they may require operative repair.

Triquetrum Fracture. The triquetrum is the second most commonly fractured carpal bone. This injury is commonly misdiagnosed and, fortunately, is not classically associated with significant complications like an undiagnosed scaphoid fracture. Unlike the scaphoid, the triquetrum has a vast blood supply with multiple anastomoses that make nonunion almost nonexistent. However, triquetral fractures, especially midbody fractures, commonly occur with a concomitant injury of another carpal bone or ligament, such as a perilunate dislocation.

There are two types of triquetral fractures: the chip or flake fracture, which is on the dorsal side of the triquetrum, and the midbody fracture, which is through the body of the bone and five times less frequent than the chip fracture. The mechanism of injury frequently involves a FOOSH injury with the wrist in ulnar deviation. This usually causes the ulnar styloid to "chisel" into the triquetrum.[42,43]

Patients complain of pain on the ulnar side of the wrist. Examination reveals point tenderness over the ulnar aspect of the wrist dorsally, which can be much easier to elicit by deviating the wrist radially. Chip fractures are commonly easy to diagnose on the lateral wrist film but are frequently misdiagnosed as ossicles. Midbody fractures can be difficult to see on standard PA and lateral films and often require an oblique film to view the bone on its longitudinal axis. Take extra care to identify concomitant injuries to other carpal bones.

Immobilize triquetrum fractures with a volar splint or an ulnar gutter splint. Isolated nondisplaced triquetral fractures often do not require emergent orthopedic referral since they usually do not require operative fixation or have significant complications.[44] If displacement is greater than 1 mm or if the fracture is associated with coexistent injuries, refer the patient to a hand surgeon urgently for operative management.

Hamate Fracture. The hamate is the most frequently injured

Figure 8. Scapholunate Dissociation

Scapholunate dissociation, evident by "Terry Thomas" sign.

Figure 9. Perilunate Dislocation

bone in the distal carpal row, but fortunately is fairly rare, accounting for only 2% of all carpal bone fractures. Significant complications may result with delays in diagnosis. The difficulty is that most patients delay presentation because they believe the injury is minor. The population mostly affected by hamate fractures is athletes who play sports associated with swinging equipment, such as a baseball bat or golf club.

The hamate lies beneath the hypothenar eminence. There are two main types of fracture: a midbody fracture and a fracture through the hook of the hamate. Midbody fractures occur either as a fall directly onto the hypothenar eminence or as axial loading of the fourth or fifth metacarpal, such as by punching a wall. The hook fracture is usually the result of a gripped object striking a hard surface and transmitting force into the hamate hook.[45] Patients describe pain on the ulnar side of the palmar surface, which is worsened by gripping an object. Hamate fractures often displace into Guyon's canal, which houses the ulnar artery and ulnar nerve, so patients can exhibit signs and symptoms of neurovascular compromise.

Standard radiographs often miss the diagnosis; therefore, supplementary views are needed. The most useful is the "carpal tunnel view," in which the hand is dorsiflexed and the beam is shot directly into the cup of the palm. This view shows the hamate in its longitudinal axis. Complications involve avascular necrosis and nonunion of the hook, which often leads to operative excision of the hook.[46] Splint nondisplaced fractures in an ulnar gutter splint and refer the patient for outpatient management. Displaced fractures greater than 1 mm and fractures with neurovascular compromise warrant urgent referral to a hand specialist.

Carpal Ligamentous Injury. Numerous ligaments surround the carpal bones, providing the majority of the stabilization of the wrist. Ligamentous injuries are fairly common and often secondary to a FOOSH mechanism of injury. These injuries are often difficult to diagnose correctly; patients are often misdiagnosed as having a simple sprain and treated conservatively. Misdiagnosis leads to significant morbidity due to chronic arthritis and loss of function. Patients often require multiple surgical corrections if the injury is not repaired in a timely fashion.

Scapholunate Ligament Injury. The scapholunate ligament (SCL) is the most commonly injured ligament in the wrist. This ligament connects the scaphoid and the lunate. There are four types of SCL injuries. Scapholunate dissociation is the most benign. This is usually caused by a FOOSH injury and forces the scaphoid radially. SCL injuries are a common complication of scaphoid and distal radius fractures.[47] Patients with this injury clinically present similar to someone with a scaphoid fracture. PA radiographs reveal subtle signs that are indeed pathologic but often missed. The space between the scaphoid and the lunate is widened more than 3 mm (the "Terry Thomas sign") *(see Figure 8)*, and pathologic rotation of the scaphoid reveals a ring representing the distal pole of the scaphoid bone (the "signet ring sign"). A better view can be obtained by having the patient make a fist and ulnar deviate the wrist while shooting the film to accentuate the space (the "clenched fist PA" view).[48,49]

Perilunate dislocation is the next category of SCL injury. *(See Figure 9.)* The mechanism is commonly a FOOSH injury, but usually requires a more significant force. Patients with this injury have severe wrist pain and significantly diminished flexion and extension of the wrist. Lateral radiographs are usually the best view for these injuries, revealing the capitate displaced dorsally

with respect to the lunate, which remains articulated with the radius in its normal position. PA views show an overlap of the distal carpal row over the proximal carpal row. These injuries are usually associated with another carpal bone fracture.[50]

The third category of SCL injury involves a perilunate dislocation associated with a triquetral dislocation. The fourth, and most severe form, is a lunate dislocation, which is associated with the most complications. The lunate is the most commonly dislocated carpal bone, and this injury usually requires a significant force such as a fall from distance or a motor vehicle collision. Patients with this injury describe severe wrist pain and occasionally paresthesias to the thumb and forefinger. They exhibit marked restrictions of flexion and extension. The lateral view reveals the lunate displaced in the volar direction (the "spilled-teacup sign") and sometimes the capitate articulates with the distal radius. The PA view shows the lunate, which normally has a quadrangular configuration, in a more triangular configuration (the "piece-of-pie sign"). The lunate often encroaches on the carpal tunnel, causing median nerve compression. Lunate fractures are often associated with other fractures.

Many of these injuries are not amenable to closed reduction, with a failure rate of up to 60%. Success is more plausible with perilunate dislocations than with lunate dislocations.[49] Open reduction/internal fixation is the most successful treatment modality for these injuries. Apply a volar splint and refer the patient to a hand specialist for urgent management. If the median nerve is involved, emergent hand specialist consultation is necessary for operative management to decompress the nerve space and repair the injury.[49]

Conclusion

Though hand and wrist injuries can be fraught with hidden dangers, a systematic examination and approach can avoid missing most injuries. Look for additional injuries if one injury is found. When in doubt, treat the patient conservatively and refer the patient to a hand surgeon.

(The authors extend their appreciation to Linda J. Kesselring, MS, ELS, technical editor/writer, Department of Emergency Medicine at the University of Maryland School of Medicine, for editorial assistance with the manuscript.)

References

1. Hainline B. Nerve injuries. *Med Clin North Am* 1994;78:327-343.
2. Newman DH. Truth, and epinephrine, at our fingertips: unveiling the pseudoaxioms. *Ann Emerg Med* 2007;50:476-477.
3. Thomson CJ, Lalonde DH. Randomized double-blind comparison of duration of anesthesia among three commonly used agents in digital nerve block. *Plast Reconstr Surg* 2006;118:429-432.
4. Waterbrook AL, Germann CA, Southall JC. Is epinephrine harmful when used with anesthetics for digital nerve blocks? *Ann Emerg Med* 2007;50:472-475.
5. Altinyazar HC, Ozdemir H, Koca R, et al. Epinephrine in digital block: Color Doppler flow imaging. *Dermatol Surg* 2004;30(4 Pt 1):508-511.
6. Sonmez A, Yaman M, Ersoy B, et al. Digital blocks with and without adrenalin: A randomised-controlled study of capillary blood parameters. *J Hand Surg Eur* 2008;33:515-518.
7. Thomson CJ, Lalonde DH, Denkler KA, et al. A critical look at the evidence for and against elective epinephrine use in the finger. *Plast Reconstr Surg* 2007;119:260-266.
8. Denkler K. A comprehensive review of epinephrine in the finger: To do or not to do. *Plast Reconstr Surg* 2001;108:114-124.
9. Food and Drug Administration. Warning: Procaine solution. *JAMA* 1948;138:599.
10. Simon RR, Sherman SC, Koenigsknecht SJ. *Emergency Orthopedics: The Extremities*. 5th ed. New York: McGraw-Hill; 2007.
11. Hogan CJ, Ruland RT. High-pressure injection injuries to the upper extremity: A review of the literature. *J Orthop Trauma* 2006;20:503-511.
12. Perron AD, Miller MD, Brady WJ. Orthopedic pitfalls in the ED: fight bite. *Am J Emerg Med* 2002;20:114-117.
13. Harrison BP, Hilliard MW. Emergency department evaluation and treatment of hand injuries. *Emerg Med Clin North Am* 1999;17:793-822.
14. Perron AD, Brady WJ, Keats TE, et al. Orthopedic pitfalls in the emergency department: Closed tendon injuries of the hand. *Am J Emerg Med* 2001;19:76-80.
15. Brzezienski MA, Schneider LH. Extensor tendon injuries at the distal interphalangeal joint. *Hand Clin* 1995;11:373-386.
16. Massengill JB. The boutonniere deformity. *Hand Clin* 1992;8:787-801.
17. Loosemore MJ, Ansdell ML, Charalambous CP, et al. Traumatic extensor hood rupture. *Hand* (NY) 2009;4:177-179.
18. Posner MA, Ambrose L. Boxer's knuckle–dorsal capsular rupture of the metacarpophalangeal joint of a finger. *J Hand Surg Am* 1989;14(2 Pt 1):229-236.
19. Arai K, Toh S, Nakahara K, et al. Treatment of soft tissue injuries to the dorsum of the metacarpophalangeal joint (Boxer's knuckle). *J Hand Surg Br* 2002;27:90-95.
20. De Maeseneer M, Marcelis S, Osteaux M, et al. Sonography of a rupture of the tendon of the extensor pollicis longus muscle: Initial clinical experience and correlation with findings at cadaveric dissection. *AJR Am J Roentgenol* 2005;184:175-179.
21. Swen WA, Jacobs JW, Hubach PC, et al. Comparison of sonography and magnetic resonance imaging for the diagnosis of partial tears of finger extensor tendons in rheumatoid arthritis. *Rheumatology* (Oxford) 2000;39:55-62.
22. Middleton WD, Teefey SA, Boyer MI. Hand and wrist sonography. *Ultrasound Q* 2001;17:21-36.
23. Soni P, Stern CA, Foreman KB, Rockwell WB. Advances in extensor tendon diagnosis and therapy. *Plast Reconstr Surg* 2009;123:727-728.
24. Posner MA, Retaillaud JL. Metacarpophalangeal joint injuries of the thumb. *Hand Clin* 1992;8:713-732.
25. Rockwell WB, Butler PN, Byrne BA. Extensor tendon: Anatomy, injury, and reconstruction. *Plast Reconstr Surg* 2000;106:1592-1603.
26. Newport ML. Extensor tendon injuries in the hand. *J Am Acad Orthop Surg* 1997;5:59-66.
27. Neumeister M, Wilhelmi BJ. Flexor tendon laceration. www.eMedi-

cine.com, 2007. Available at emedicine.medscape.com/article/1238823-overview. Accessed on July 21, 2009.
28. Hart RG, Uehara DT, Kutz JE. Extensor tendon injuries of the hand. *Emerg Med Clin North Am* 1993;11:637-649.
29. Foster RJ, Hastings H 2nd. Treatment of Bennett, Rolando, and vertical intraarticular trapezial fractures. *Clin Orthop Relat Res* 1987; 214:121-129.
30. Perron AD, Brady WJ, Keats TE, et al. Orthopedic pitfalls in the ED: scaphoid fracture. *Am J Emerg Med* 2001;19:310-316.
31. Grover R. Clinical assessment of scaphoid injuries and the detection of fractures. *J Hand Surg Br* 1996;21:341-343.
32. Geissler WB. Carpal fractures in athletes. *Clin Sports Med* 2001;20: 167-188.
33. Freeland P. Scaphoid tubercle tenderness: A better indicator of scaphoid fractures? *Arch Emerg Med* 1989;6:46-50.
34. Pillai A, Jain M. Management of clinical fractures of the scaphoid: results of an audit and literature review. *Eur J Emerg Med* 2005;12: 47-51.
35. Ty JM, Lozano-Calderon S, Ring D. Computed tomography for triage of suspected scaphoid fractures. *Hand* (NY) 2008;3:155-158.
36. Welling RD, Jacobson JA, Jamadar DA, et al. MDCT and radiography of wrist fractures: radiographic sensitivity and fracture patterns. *AJR Am J Roentgenol* 2008;190:10-16.
37. Memarsadeghi M, Breitenseher MJ, Schaefer-Prokop C, et al. Occult scaphoid fractures: Comparison of multidetector CT and MR imaging–initial experience. *Radiology* 2006;240:169-176.
38. Tiel-van Buul MM, van Beek EJ, Borm JJ, et al. The value of radiographs and bone scintigraphy in suspected scaphoid fracture: A statistical analysis. *J Hand Surg Br* 1993;18:403-406.
39. Chakravarty D, Sloan J, Brenchley J. Risk reduction through skeletal scintigraphy as a screening tool in suspected scaphoid fracture: A literature review. *Emerg Med J* 2002;19:507-509.
40. Phillips TG, Reibach AM, Slomiany WP. Diagnosis and management of scaphoid fractures. *Am Fam Physician* 2004;70:879-884.
41. Beeres FJ, Hogervorst M, Rhemrev SJ, et al. Reliability of bone scintigraphy for suspected scaphoid fractures. *Clin Nucl Med* 2007; 32:835-838.
42. Levy M, Fischel RE, Stern GM, et al. Chip fractures of the os triquetrum: The mechanism of injury. *J Bone Joint Surg Br* 1979;61-B:355-357.
43. Garcia-Elias M. Dorsal fractures of the triquetrum-avulsion or compression fractures? *J Hand Surg Am* 1987;12:266-268.
44. De Beer JD, Hudson DA. Fractures of the triquetrum. *J Hand Surg Br* 1987;12:52-53.
45. Lacey JD, Hodge JC. Pisiform and hamulus fractures: Easily missed wrist fractures diagnosed on a reverse oblique radiograph. *J Emerg Med* 1998;16:445-452.
46. Whalen JL, Bishop AT, Linscheid RL. Nonoperative treatment of acute hamate hook fractures. *J Hand Surg Am* 1992;17:507-511.
47. Mudgal CS, Jones WA. Scapho-lunate diastasis: A component of fractures of the distal radius. *J Hand Surg Br* 1990;15:503-505.
48. Woolfrey KG, Eisenhauer MA. Chapter 48: Wrist and forearm. In: Marx JA, Hockberger RS, Walls RM, et al, eds. *Rosen's Emergency Medicine: Concepts and Clinical Practice*. 6th ed. Philadelphia, PA: Mosby/Elsevier; 2006:3 v (xxxix, 3179, cv p.).
49. Perron AD, Brady WJ, Keats TE, et al. Orthopedic pitfalls in the ED: Lunate and perilunate injuries. *Am J Emerg Med* 2001;19: 157-162.
50. Ritchie JV, Munter DW. Emergency department evaluation and treatment of wrist injuries. *Emerg Med Clin North Am* 1999;17: 823-842.

CME/CNE Objectives

Upon completing this program, the participants will be able to:

a.) discuss conditions that should increase suspicion for traumatic injuries;
b.) describe the various modalities used to identify different traumatic conditions;
c.) cite methods of quickly stabilizing and managing patients; and
d.) identify possible complications that may occur with traumatic injuries.

CME/CNE Questions

1. High-pressure injection injuries require prompt referral to a hand specialist for definitive treatment; which of the following actions is not recommended?
   A. Administering broad-spectrum antibiotics
   B. Elevating the hand/arm
   C. Irrigating with an organic solvent
   D. Obtaining radiographs of the affected area
   E. Administering tetanus prophylaxis

2. Fight bites are associated with polymicrobial infections; a broad-spectrum antibiotic recommended for outpatient use is:
   A. Amoxicillin
   B. Amoxicillin-clavulanic acid
   C. Cephalexin
   D. Doxycycline
   E. Sulfamethoxazole and trimethoprim

3. Which of the following is NOT acceptable when reducing a phalanx fracture?
   A. Displacement
   B. Dorsal angulation
   C. Rotation
   D. Subluxation
   E. Volar angulation

4. A mallet finger should be treated with the distal interphalangeal joint splinted in full extension with a dorsal splint for:
   A. 1–2 weeks.
   B. 3–4 weeks.
   C. 5–6 weeks.
   D. 6–8 weeks.
   E. 10 weeks.

5. Bennett's or Rolando's fractures can be stabilized using a:
   A. Radial gutter splint
   B. Short arm splint
   C. Thumb spica splint
   D. Ulnar gutter splint
   E. Volar splint

6. A professional football player sustains a FOOSH (fall on an outstretched hand) injury to his right (dominant) hand. He is complaining of pain on the radial side of his wrist, and a scaphoid fracture is suspected. Plain radiographs are negative, but suspicion remains high. What is the next step in definitively making the diagnosis?
   A. Diagnosis him with a sprain and allow him to return to active play.
   B. Discharge him from the ED in a thumb spica splint with a prescription for an outpatient bone scan.
   C. Discharge him from the ED in a thumb spica splint and have him follow up with the team physician in a week for repeat radiographs.
   D. Obtain a CT scan of his wrist while he is in the ED.
   E. Place him in a thumb spica splint and advise him not to play for six weeks.

7. A patient presents to the ED complaining of right wrist pain after a fall on an outstretched hand. He also complains of paresthesia in his thumb and forefinger. The neurovascular exam is unremarkable. Radiographs are obtained, and he is diagnosed with a lunate dislocation. What is the next step in the management of this patient?
   A. Splint in a thumb spica and advise the patient to see a hand specialist in one week.
   B. Sedate the patient and attempt closed reduction of the dislocation.
   C. Consult a hand specialist urgently while the patient is in the ED.
   D. Splint in a volar splint and advise the patient to see a hand specialist in one week.

8. Radiographs of a patient you are treating with wrist pain demonstrate a nondisplaced triquetrum fracture. What is the appropriate management of this patient?
   A. Splint him in a thumb spica and discharge home, with follow-up with a hand specialist in a week.
   B. Discharge him home with a wrist cock-up splint and advise follow-up with his primary care physician.
   C. Consult a hand specialist for immediate intervention.
   D. Apply an ulnar gutter splint and advise follow-up with his primary care physician.

9. The "clenched-fist PA" radiograph is an optimal view for viewing what type of injury?
   A. Lunate dislocation
   B. Perilunate dislocation
   C. Scaphoid fracture
   D. Scapholunate dissociation
   E. Triquetral fracture

10. A patient comes to the ED complaining of wrist pain after a motor vehicle collision. After a set of radiographs is obtained, the radiologist calls and says the patient has a lunate dislocation. What finding did the radiologist see to make the diagnosis?
   A. "Chip sign" on lateral view
   B. "Piece-of-pie sign" on lateral view
   C. "Signet-ring sign" on PA view
   D. "Spilled-tea-cup sign" on lateral view
   E. "Terry Thomas sign" on PA view

Answers: 1. c, 2. b, 3. c, 4. d, 5. c, 6. d, 7. c, 8. d. 9. d, 10. d

In Future Issues: **Genitourinary Trauma**

Dear *Trauma Reports* Subscriber:

This issue of your newsletter marks the start of a new continuing medical education (CME) or continuing nursing education (CNE) activity and provides us with an opportunity to review the procedures.

Trauma Reports, sponsored by AHC Media LLC, provides you with evidence-based information and best practices that help you make informed decisions concerning treatment options and physician office practices. Our intent is the same as yours - the best possible patient care.

Upon completing this program, the participants will be able to:

1. discuss conditions that should increase suspicion for traumatic injuries
2. describe the various modalities used to identify different traumatic conditions
3. cite methods of quickly stabilizing and managing patients
4. identify possible complications that may occur with traumatic injuries

Each issue of your newsletter contains questions relating to the information provided in that issue. After reading the issue, answer the questions at the end of the issue to the best of your ability. You can then compare your answers with the correct answers provided in an answer key in the newsletter. If any of your answers were incorrect, please refer back to the source material to clarify any misunderstanding.

Each issue also includes an evaluation form to complete and return in an envelope we have provided. Please make sure you sign the attestation verifying that you have completed the activity as designed. Once we have received your completed evaluation form we will mail you a letter of credit. This activity is valid 24 months from the date of publication. The target audience for this activity is emergency medicine physicians and nurses, trauma surgeons and nurses.

If you have any questions about the process, please call us at (800) 688-2421, or outside the U.S. at (404) 262-5476. You can also fax us at (800) 284-3291, or outside the U.S. at (404) 262-5560. You can also email us at: customerservice@ahcmedia.com.

On behalf of AHC Media, we thank you for your trust and look forward to a continuing education partnership.

Sincerely,

Cynthia Molnar
Director of Continuing Education
AHC Media, LLC

Evidence-Based Medicine for the ED
Trauma Reports

TR010110TM

PLEASE NOTE: If your correct name and address do not appear below, please complete the section at right.

Please make label address corrections here or PRINT address information to receive a certificate.

Account #_____

Name: _____

Company: _____

Address:_____

City: _____

State:_____ Zip _____

Fax: _____

Phone: _____

E-mail: _____

CNE/CME Evaluation — Hand and Wrist Trauma

Please take a moment to answer the following questions to let us know your thoughts on the CNE/CME program. Fill in the appropriate space and return this page in the envelope provided. **You must return this evaluation to receive your letter of credit. ACEP members — Please see reverse side for option to mail in answers.** Thank you.

CORRECT ● **INCORRECT** ◐ ✓ ✗ ⚠

1. In which program do you participate? ○ CNE ○ CME
2. If you are claiming physician credits, please indicate the appropriate credential: ○ MD ○ DO ○ Other _____
3. If you are claiming nursing contact hours, please indicate your highest credential: ○ RN ○ NP ○ Other _____

After participating in this program, I am able to:	**Strongly Disagree**	**Disagree**	**Slightly Disagree**	**Slightly Agree**	**Agree**	**Strongly Agree**
4. Discuss conditions that should increase suspicion for traumatic injuries.	○	○	○	○	○	○
5. Describe the various modalities used to identify different traumatic conditions.	○	○	○	○	○	○
6. Cite methods of quickly stabilizing and managing patients.	○	○	○	○	○	○
7. Identify possible complications that may occur with traumatic injuries.	○	○	○	○	○	○
8. The test questions were clear and appropriate.	○	○	○	○	○	○
9. I detected no commercial bias in this activity.	○	○	○	○	○	○
10. This activity reaffirmed my clinical practice.	○	○	○	○	○	○
11. This activity has changed my clinical practice.	○	○	○	○	○	○

If so, how?_____

12. How many minutes do you estimate it took you to complete this activity? Please include time for reading, reviewing, answering the questions, and comparing your answers with the correct ones listed. _____ minutes.
13. Do you have any general comments about the effectiveness of this CNE/CME program?

_____

I have completed the requirements for this activity.

Name (printed) _____ **Signature**_____

Nursing license number ***(required for nurses licensed by the state of California)***_____

Optional for ACEP members: In accordance with ACEP requirements, below we provide the option for ACEP members to submit their answers for this CME activity. If you wish to submit answers for this activity, please refer to this issue (Vol. 11, No. 1) and circle the correct responses.

1. A
   B
   C
   D
   E

2. A
   B
   C
   D
   E

3. A
   B
   C
   D
   E

4. A
   B
   C
   D
   E

5. A
   B
   C
   D
   E

6. A
   B
   C
   D
   E

7. A
   B
   C
   D

8. A
   B
   C
   D

9. A
   B
   C
   D
   E

10. A
    B
    C
    D
    E

AHC Media LLC

AHC Media's Message to Subscribers about Copyright Law

Your newsletter is a copyrighted publication. It is protected under federal copyright law.

It is against the law to reproduce your newsletter in any form without the written consent of AHC Media's publisher. Prohibited under copyright law is:

- making "extra" copies of our publication for distribution in your office;
- posting newsletter articles on your facility or practice web site;
- downloading material to an electronic network;
- photocopying, e-mailing, or faxing newsletter articles.

Site licenses, which allow you to e-mail, fax, photocopy, or post electronic versions of your newsletter and allow additional users to access the newsletter online, are available for facilities or companies seeking wider distribution of your newsletter.

High-quality reprints of articles also are available at reasonable prices.

To get information about site license or multiple copy arrangements, contact Tria Kreutzer at (800) 688-2421, ext. 5482 (tria.kreutzer@ahcmedia.com); or for reprints, contact Steve Vance at (800) 688-2421, ext. 5511 (stephen.vance@ahcmedia.com).

Thank you for your cooperation,



Donald R. Johnston
Senior Vice President/Group Publisher
AHC Media LLC

N #4005

3525 Piedmont Road NE
Building Six, Suite 400
Atlanta, Georgia 30305-1515
Tel (404) 262-7436
Fax (404) 262-7837
www.ahcmedia.com