Emergency Medicine Reports
The Practical Journal for Emergency Physicians

Volume 32, Number 7 / March 14, 2011 www.emreports.com

Authors:

Angela M. Mills, MD, Assistant Professor of Emergency Medicine, Department of Emergency Medicine, University of Pennsylvania, Philadelphia.

Esther H. Chen, MD, Associate Professor of Emergency Medicine, Department of Emergency Medicine, University of California–San Francisco, San Francisco General Hospital.

Peer Reviewer:

Catherine A. Marco, MD, FACEP, Professor, Emergency Medicine, Program Director, Emergency Medicine Residency, University of Toledo College of Medicine, OH.

Statement of Financial Disclosure

To reveal any potential bias in this publication, and in accordance with Accreditation Council for Continuing Medical Education guidelines, we disclose that Dr. Schneider (editor) serves on the editorial board for Logical Images. Dr. Farel (CME question reviewer) owns stock in Johnson & Johnson. Dr. Mills (author) has received research support from Aspen BioPharma and served as a consultant for Becker & Associates Consulting Inc. Dr. Stapczynski (editor), Dr. Chen (author), Dr. Marco (peer reviewer), Ms. Mark (executive editor), and Ms. Hamlin (managing editor) report no relationships with companies related to the field of study covered by this CME activity.

AHC Media

Abdominal Pain in Special Populations

Introduction

A common presenting complaint for patients seeking emergency medical care is acute abdominal pain. Although difficult to diagnose in healthy patients, it is even more challenging in special populations. This article will focus on three distinct populations: patients with altered immunologic function, pregnant women, and post-procedural patients. In immunocompromised patients, the detection of life-threatening abdominal disease may be delayed because of atypical presentations. Atypical symptoms in late pregnancy (as the intra-abdominal contents are displaced) also may delay diagnosis. Furthermore, the anchoring effect of focusing on obstetrical causes of pain in pregnant women also may delay the diagnosis of non-obstetrical, surgical causes of abdominal pain. In post-procedural patients, understanding the complications specific to the individual procedures is necessary for the emergency physician to prioritize the differential diagnosis and order the appropriate diagnostic studies. This article will highlight the abdominal pain characteristics and diagnoses that are unique to these populations and review the clinical presentation, diagnostic evaluation, and management in these patients.

Patients with Altered Immunologic Function

Patients with altered immunologic function range from those with mild immunologic dysfunction (e.g., elderly, diabetic, uremic) to those with moderate to severe immunologic compromise (e.g., acquired immunodeficiency syndrome [AIDS], transplanted patients, active malignancy undergoing chemotherapy). While the differential diagnosis of abdominal pain is similar to that in the general population, these patients may exhibit delayed or atypical presentations of these conditions. Furthermore, transplanted organs lack native innervation, so pain may not even be a reliable sign of pathology in these patients.[1] Patients may lack the classic signs of peritonitis and, instead, present with altered mental status and tachycardia.[2] Abdominal pain in the moderate to severely immunocompromised group may be caused by opportunistic infections, such as cytomegalovirus (CMV) infection, neutropenic enterocolitis (typhlitis), and intra-abdominal abscesses. Finally, because they are challenging and more likely to have life-threatening disease means that immunosuppressed patients will often receive advanced imaging with abdomen-pelvis computed tomography (CT) as part of their emergency department (ED) evaluation.

HIV/AIDS. Patients with human immunodeficiency virus (HIV) and CD4 counts greater than 200/mm^3 are typically considered to have mild to moderate immunologic dysfunction, whereas those with CD4 counts less than 200/mm^3, defined as having AIDS, are severely compromised and have a high risk of opportunistic infection and the resultant complications. Highly active antiretroviral therapy (HAART) has greatly diminished the incidence of opportunistic and AIDS-related gastrointestinal infections. In a retrospective study of

Executive Summary

- While patients with HIV can have opportunistic infections, most patients with abdominal pain will have typical causes such as appendicitis, acute cholecystitis, or obstruction.
- While CT can be used, MRI is preferred for the evaluation of abdominal pain in patients in the first trimester of pregnancy
- Feeding-tube dislodgement is a common cause for an ED visit. If the tube has been present for more than 2 weeks, it should be promptly replaced using a Foley catheter, if necessary.
- Patients with biliary drains may present with abdominal pain. If the drain is capped, first uncap the drain to relieve any obstruction.

108 patients with HIV and undifferentiated abdominal pain (84% on HAART, 44% with AIDS),[3] only 7% of patients (10% of those with AIDS) were diagnosed with an opportunistic infection, compared to rates of 41-86% of patients with abdominal pain in the pre-HAART era.[4-6] Disseminated mycobacterial disease was the most common diagnosis in this study population; other opportunistic infections included Candidal esophagitis, AIDS cholangiopathy, lymphoma, and intra-abdominal tuberculosis. Well-described causes of abdominal pain in the HIV population, such as cryptosporidiosis, CMV colitis, and Kaposi's sarcoma, were not found in this study group. Moreover, only 9 patients (8%) required operative intervention. Of these, one patient had an abscess caused by Mycobacterium, the only HIV-associated infection. A more recent study of opportunistic gastrointestinal diseases in HIV patients confirmed these findings, demonstrating that 26% of patients on HAART (vs. 80% in the non-HAART group) had an opportunistic infection as the etiology of their pain, most commonly Candidal esophagitis and CMV esophagitis or colitis.[7] Lymphoma and Kaposi's sarcoma were less common than expected.

The principal causes of abdominal pain in HIV patients that require operative intervention are appendicitis, cholecystitis, bowel obstructions, and intestinal perforation.[8] While the incidence of these conditions is similar in HIV patients on HAART compared to non-HIV patients, the underlying pathology may differ between these groups.[7,9] For example, CMV infection in the terminal ileum and colon may cause vasculitis of the bowel wall, which can lead to gastrointestinal hemorrhage, bowel perforation, or toxic megacolon.[10] CMV infection also may cause appendicitis, but with more indolent symptoms. Bowel obstruction and intussusception in HIV patients may be due to lymphoma or Kaposi's sarcoma.[8,9] While gallstone cholecystitis occurs with similar frequency among HIV and non-HIV patients, acalculous cholecystitis is more frequently found among those with HIV. Patients with HIV also may develop cholangiopathy as an adverse effect of antiretroviral medications or from biliary duct infiltration by opportunistic pathogens leading to biliary obstruction.[9]

In addition to cholangiopathy, nonspecific abdominal pain is an adverse effect of the same antiretroviral medications that have so successfully decreased gastrointestinal disease in this population. HAART can cause nausea, vomiting, and diarrhea, sometimes severe enough to cause acute dehydration or hemodynamic instability. Certain medications also are associated with specific causes of abdominal pain. Didanosine (Videx) is known to cause acute pancreatitis, and indinavir (Crixivan) may cause nephrolithiasis because it can precipitate in the kidneys.[8] These side effects can make the medication regimens so intolerable that some patients discontinue the treatment entirely. Unfortunately, these lapses in treatment also increase the patient's risk of opportunistic infections.

Malignancy. Approximately 40% of ED visits by patients with active cancer are for the evaluation of abdominal pain.[11] Possible causes of abdominal pain include conditions directly related to the malignancy in addition to complications from the treatment of the malignancy.[12] While intra-abdominal malignancies may mechanically cause small or large bowel obstructions depending on their size and location,[13] extra-abdominal malignancies (i.e., breast, melanoma) complicated by diffuse peritoneal carcinomatosis can also cause intestinal obstruction.[14] Detection of a gastric outlet or large bowel obstruction in a patient who is otherwise healthy or with a prior cancer history should raise the suspicion of an undiagnosed underlying or recurrent cancer.[11,13] Moreover, an uncommon condition in healthy adults, such as intussusception, may be a result of a solid tumor acting as a lead point.[15] Intestinal perforation may be caused by the transmural erosion of gastrointestinal cancers, metastatic lesions to the bowel, and atypical infections. Pneumoperitoneum from bowel perforation may be challenging to diagnose in these patients because they may not exhibit peritonitis.[2] Other causes of abdominal pain include malignant ascites and Budd-Chiari syndrome, a constellation of symptoms due to hepatic venous outflow obstruction secondary to

thrombosis.[12]

Advanced imaging often is necessary for diagnosis in this patient population. Abdominal CT enables the emergency physician to more accurately identify closed-loop or strangulation obstruction, detect an intestinal transition point, and demonstrate vascular thrombosis or bowel pneumatosis.[12] By contrast, plain radiography has a sensitivity of 66% in detecting small-bowel obstruction[16] and is unable to detect conditions such as strangulated bowel and vascular thrombosis.[17]

Cancer treatments have well-documented adverse effects. Radiation therapy to the abdomen or pelvis may produce localized intestinal luminal narrowing and progressive occlusive vasculitis. Radiation enteritis comprises a spectrum of diseases, ranging from acute bowel perforation and gastrointestinal hemorrhage to chronic fistulas and strictures.[18] Chemotherapeutic agents frequently cause abdominal pain associated with nausea, vomiting, and/or diarrhea and also may cause profound neutropenia. The most common cause of an acute abdomen in neutropenic patients is neutropenic enterocolitis (NEC), also known as typhlitis.[19] NEC is a severe necrotizing inflammation of the cecum and adjacent small bowel occurring in profoundly immunocompromised patients, most commonly with chemotherapy-induced neutropenia or bone-marrow transplantation. NEC also has been described in other patient groups with altered immunologic function, including those with AIDS, aplastic anemia, and organ transplantation. In addition, patients exposed to cytotoxic agents, such as vinorelbine (Nabelbine) and the taxanes, have an increased risk of developing NEC.[20]

Patients with NEC may present with fever, nausea, vomiting, diarrhea, abdominal distension, and right lower-quadrant abdominal pain. They also may present acutely with hypotension and other signs of sepsis. Although these symptoms can be similar to the routine side effects of the chemotherapeutic agents themselves, NEC is more likely to be associated with bowel wall thickening on CT of more than 4 mm; wall thickening of greater than 10 mm portends a very poor prognosis.[21,22] Treatment for NEC includes fluid resuscitation, broad-spectrum antibiotics (against enteric gram-negative bacilli, Enterococcus spp., and anaerobes), bowel rest, and parenteral nutrition.[20] Surgery is indicated for bowel ischemia and perforation.[23] Mortality rates are high (30-50%),[24] so prompt recognition may be life-saving.

Solid Organ Transplantation. Like many postsurgical patients, patients who have received a solid organ transplant frequently visit the ED for abdominal pain (31%), associated gastrointestinal symptoms (e.g., nausea, vomiting, diarrhea), and infectious symptoms (17%) such as fever or abnormal wound drainage.[1] Regardless of the time lapsed since transplantation, infection (36%) and gastrointestinal or genitourinary pathology (20%) are the most common ED diagnoses. Organ rejection, infection, and drug toxicity must be considered in the post-transplant patient who presents with acute abdominal pain.

The differential diagnosis is dependent upon the time elapsed since transplantation. In the early post-transplant period (< 1 month), post-surgical complications and infections are most common.[1] The surgical anastomosis may constrict or leak, causing intestinal obstruction or peritonitis, respectively. Graft injury, such as bile duct ischemia, can develop into a liver abscess. Viral or candidal infections may be derived from the donor organ or a complication of the surgery itself. *Clostridium difficile* colitis is common during this period, whereas opportunistic infections typically are absent.[25] Finally, although graft rejection could occur at any period post-transplant, patients have a slightly higher risk of graft rejection within the first month than in the intermediate or late post-transplant period.[1]

In the intermediate post-transplant period (1-6 months), viral infections and graft rejection are frequently seen and are the most common reasons for fever.[25] During this period, patients suffer from the full effect of immunosuppressants and may develop opportunistic infections, such as CMV colitis and intra-abdominal abscesses caused by fungal (e.g., *Candida albicans*, Cryptococcus) and bacterial infections (e.g., Nocardia, Legionella). These patients should be considered to be severely immunodeficient and should undergo a thorough search for the source of infection.

Immunosuppressive therapy is routinely tapered down after 6 months in transplant patients with good graft function. The risk of infection declines slightly in this late post-transplant period, although patients continue to be at risk for developing chronic rejection as a result of chronic viral infections.[25] In addition, acute diverticulitis is a common gastrointestinal infection seen during this period. This population also may develop post-transplantation lymphoproliferative disorder (PTLD), a lymphoproliferative disorder thought to be associated with Epstein-Barr virus infection and similar to disorders occurring in patients with AIDS. Patients may present with fever, a mononucleosis-like syndrome, gastrointestinal obstruction, bleeding or perforation, and have significant hepatic or pancreatic dysfunction. Disease regression may occur simply by decreasing immunosuppressant therapy, although this disease often requires additional chemotherapy or immunotherapy.[25]

Pregnancy

Abdominal pain in the pregnant patient poses a unique challenge to the clinician. The differential diagnosis is much broader in pregnant patients than non-pregnant patients. Although both obstetrical and non-obstetrical diseases must be considered, anchoring bias can delay the diagnosis of non-obstetrical surgical conditions by focusing attention only to the potential obstetrical causes of the pain, such as ectopic pregnancy, ovarian torsion, and labor.

The clinical presentation and natural progression of many diseases that cause abdominal pain may be altered in pregnancy. CT, now a routine diagnostic tool to evaluate abdominal pain in non-pregnant patients, is often avoided in pregnant women because of the radiation risk to the fetus. This next section of the article will focus on common non-obstetrical etiologies of the acute abdomen in pregnancy and the unique characteristics of disease presentation and progression in this distinct population.

The normal physiologic changes that occur during pregnancy can make diagnosing and managing these patients very challenging. For example, blood plasma volume increases out of proportion to red blood cell mass and creates a state of "physiologic" anemia. Therefore, pregnant women may not exhibit signs of shock (i.e., tachycardia, hypotension) until they have lost a significant amount of blood. In addition, leukocytosis becomes an unreliable sign of infection because it can be normally elevated in pregnancy.[26] Gastrointestinal symptoms that typically are associated with some surgical conditions such as nausea, vomiting, anorexia, and constipation can be normal in pregnancy. Particularly in late pregnancy, signs of peritonitis (i.e., abdominal guarding, rigidity, rebound tenderness) can be obscured by a laxity of the abdominal musculature.[27] All of these factors may contribute to the diagnostic delay in surgical conditions and increased morbidity in this population.

General Management. The most important concept for the emergency physician to remember in managing the pregnant patient is how to interpret the symptoms, signs, and laboratory values that can change during pregnancy. Whereas the diagnosis of the acute abdomen can be challenging, the management of pregnant patients with abdominal pain is similar to that for non-pregnant patients, with a few exceptions. For pregnancies greater than 24 weeks gestation, or the time at which the fetus is considered to be viable, fetal heart-rate monitoring is recommended during the patient's evaluation.[28] In addition, early obstetrical consultation is recommended for severely injured patients (gestation > 24 weeks), while mildly injured patients can receive their trauma evaluation in the ED and then be sent for fetal heart-rate monitoring by Obstetrics. Medications such as analgesia and antibiotics should not be withheld unnecessarily in pregnant patients, although specific drugs should be checked for potential teratogenicity and adverse perinatal effects. Opioid analgesia (parenteral or oral) is considered to be safe during pregnancy, whereas aspirin and nonsteroidal anti-inflammatory drugs should be avoided. Likewise, antibiotics such as penicillins, cephalosporins, clindamycin, ertapenem, and metronidazole may be safely administered to pregnant patients, unlike fluoroquinolones or tetracyclines.

Imaging. The diagnostic use of CT for pregnant women is a controversial issue. Although ultrasonography and magnetic resonance imaging (MRI) are safe alternatives to CT, ultrasound is more limited in its diagnostic accuracy for certain conditions and MRI is often not as readily available. In pregnant patients with acute abdominal pain, MRI has been found to have a high negative predictive value (98%) in excluding diagnoses requiring surgical or interventional therapy.[29] In addition to excluding disease, both MRI and CT often are able to provide an alternative diagnosis. Some physicians believe that CT should be used if the benefits outweigh the risk of imaging, particularly when delaying the diagnosis increases the morbidity or mortality for the patient. A recent retrospective study of abdomen-pelvis CTs performed between 1998 and 2005 showed that CT utilization increased more in pregnant women compared to the general population (about 22%/year/1,000 deliveries vs. 13%/year), although this was not statistically significant.[30] The most common indication for CT was suspected appendicitis. In a survey of radiology residency programs in the United States, 96% of respondents indicated that they will perform CT in pregnant patients with abdominal pain when the benefit/risk ratio is high.[31] Respondents also preferred CT to MRI in the second and third trimesters for the evaluation of appendicitis, nephrolithiasis, and abscess; MRI was preferred for the detection of appendicitis and abscess in the first trimester. Most radiology departments have policies regarding the use of imaging in the pregnant patient. However, there is no consensus for an imaging algorithm for evaluating pregnant women with abdominal pain.

Appendicitis. Acute appendicitis is the most common non-obstetric surgical disease in the pregnant population, with an incidence of approximately 1 in 750 to 3000 pregnancies, similar to the non-pregnant population.[28] While appendicitis may occur at any time during pregnancy, it occurs more frequently in the second trimester.[32,33] The differential diagnosis includes ectopic pregnancy, ovarian torsion, and labor. The rate of appendiceal rupture also has been reported to be higher in the pregnant population, in part because of the diagnostic challenges mentioned previously.[32,34] Both early delivery and fetal loss are more common in complicated appendicitis, although fetal loss still occurs with negative appendectomy, stressing the importance of accurate diagnosis.[35] Maternal mortality from appendicitis has decreased significantly in recent decades.[28]

Although the classic teaching is that the pain of appendicitis moves from the right lower quadrant to the right upper quadrant as the uterus displaces the intra-abdominal contents, right lower-quadrant abdominal pain is still the most common presenting symptom regardless of gestational age.[32,36] As in the non-gravid patient, fever and leukocytosis are unreliable indicators of appendicitis.

In the first trimester, ultrasonography is the initial study of choice because the radiation risk

to organogenesis is highest in early pregnancy. Ultrasound is more available than MRI. In pregnant patients, ultrasound has been shown to have a sensitivity of 67% to 100% and a specificity of 83% to 96%.[37] The sonographic finding for appendicitis is a noncompressible tubular, multilayered structure greater than 6 mm in diameter. (*See Figure 1.*) A positive study requires no further testing. A negative or indeterminate study may be followed by MRI, CT (if more advanced gestational age), or inpatient observation with serial abdominal exams. Ultrasound can be technically difficult in the third trimester, so its utility in late pregnancy is more limited. A comparison of CT and MRI after prior normal/inconclusive ultrasound showed a sensitivity and specificity of 85.7% and 97.4%, respectively, for CT and 80% and 99%, respectively, for MRI.[38] (*See Figure 2.*) When available, MRI is the preferred imaging study in evaluating pregnant patients with suspected appendicitis. Like CT, it can detect other surgical causes of abdominal pain, with an overall sensitivity of 89% and specificity of 95% for detecting surgical causes of abdominal pain in pregnancy.[29] All imaging modalities have limitations and may be indeterminate if the appendix is not visualized.

Treatment for appendicitis is the same in pregnant and non-pregnant patients: intravenous hydration, symptomatic relief with analgesia and antiemetics, antibiotic administration, and operative intervention. Early surgical consultation is recommended.

Acute Biliary Disease. The second most common non-obstetric surgical emergency in pregnancy is acute cholecystitis. Biliary disease is already more common in females, with gallstones present in almost 20% of women by 40 years of age.[39] Estrogen increases cholesterol synthesis and progesterone impairs gallbladder emptying and promotes cholestasis.[40] However, despite the higher risk of cholestasis, the incidence of acute cholecystitis is no different in pregnant patients compared to non-pregnant patients.

The symptoms of biliary disease in pregnancy are similar to those in the non-pregnant population. They include mid-epigastric or right upper-quadrant abdominal pain, nausea and vomiting, anorexia, and intolerance of fatty foods. Physical examination often reveals right upper-quadrant tenderness and Murphy's sign; jaundice suggests choledocholithiasis and obstruction.

Laboratory values must be interpreted differently in pregnant women. As mentioned previously, the white blood cell count may be

Figure 1: Appendicitis on Ultrasound

Ultrasound image in the short axis plane of an inflamed appendix (outlined by arrows). It is often described as a "target" sign when viewed in short axis. (Image provided by Nova L. Panebianco, MD, University of Pennsylvania, Philadelphia, PA, published with permission.)

Figure 2: Appendicitis on MRI

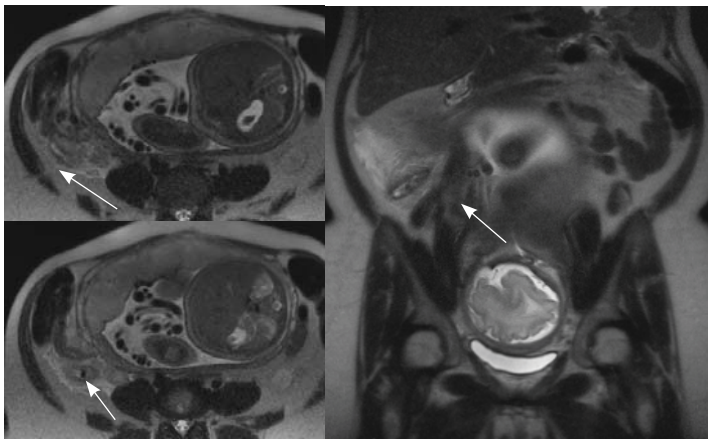

Axial (left) and coronal (right) T2 weighted MRI images through the right lower quadrant in a pregnant patient at 24 weeks gestation demonstrating a distended, thick-walled appendix with periappendiceal fluid (arrows). There is a low signal structure within the appendix, likely an appendicolith or focus of gas. (Image provided by Elizabeth M. Hecht, MD, University of Pennsylvania, Philadelphia, PA, published with permission.)

Figure 3: Cholecystitis on Ultrasound

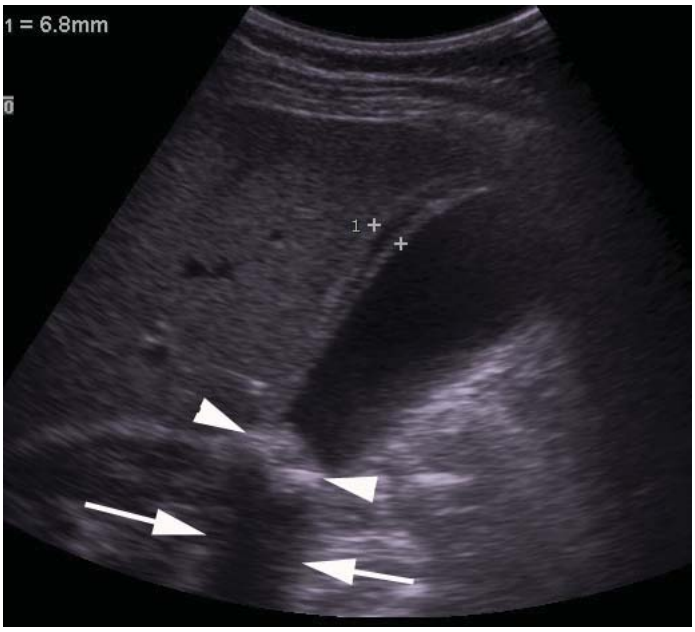

Ultrasonography in longitudinal view demonstrating cholecystitis, specifically gallstones (arrowheads) impacted in the gallbladder neck with posterior shadowing (arrows), and a thickened gallbladder wall with intramural edema (calipers). (Image provided by Anthony J. Dean, MD, University of Pennsylvania, Philadelphia, PA, published with permission.)

normally elevated in pregnancy, as well as alkaline phosphatase. Elevated lipase and amylase suggest associated pancreatitis.

Similar to non-pregnant patients, the differential diagnosis for right upper-quadrant pain is broad and should include pyelonephritis, renal colic, peptic ulcer disease, pancreatitis, appendicitis, viral hepatitis, right lower lobe pneumonia, myocardial infarction, and herpes zoster. Specific conditions to consider in pregnancy are acute fatty liver of pregnancy and hemolytic anemia/elevated liver enzymes/low platelet count (HELLP syndrome).

Ultrasonography is the diagnostic test of choice. Sonographic findings of acute cholecystitis include gallstones (especially if present in the gallbladder neck), pericholecystic fluid, thickened gallbladder wall, common bile duct dilatation, and sonographic Murphy's sign. (*See Figure 3.*) For more than a decade, emergency physicians have been performing bedside ultrasonography, and the American College of Emergency Physicians (ACEP) formally endorses and supports this modality for right upper-quadrant ultrasonography.[41] The sensitivity for gallstone detection by emergency physicians is 90-96%, with a specificity of 88-96%. In addition, pregnant patients with choledocholithiasis and pancreatitis may undergo endoscopic retrograde cholangiography (ERCP) with sphincterotomy, which may be performed successfully with little to no radiation exposure.[42]

Treatment with intravenous hydration, analgesia, antiemetics, and antibiotics is appropriate in the ED. Early surgical consultation is recommended. Historically, the management of pregnant patients with acute biliary disease, particularly symptomatic cholelithiasis, favored conservative treatment; more recently, however, early surgical intervention has been advocated. Delayed cholecystectomy for the pregnant patient with biliary disease has been shown to have increased short- and long-term morbidity, including symptomatic recurrence, longer hospital stays, preterm labor, premature delivery, and fetal loss.[43-45] Laparoscopic cholecystectomy has been shown to be safe during pregnancy.[44]

Bowel Obstruction. Small-bowel obstruction occurs in approximately 1 in 3000 pregnancies, and as in non-pregnant patients, is most commonly caused by adhesions (60-70%).[46] Volvulus is significantly more common in pregnancy, accounting for 25% of intestinal obstruction in pregnant patients, compared to 3-5% in non-pregnant patients.[47] Volvulus is more likely to occur during times of rapid change in uterine size, such as the early second trimester and the post-partum period. Other less common causes of intestinal obstruction include intussusception, hernia, and malignancy. In pregnant patients who receive operative intervention for obstruction, fetal mortality has been documented at 26% and maternal mortality at 6%.[48]

The clinical diagnosis of bowel obstruction may be especially challenging in pregnancy. The usual symptoms of crampy abdominal pain, nausea, vomiting, and constipation may be attributed to the normal pregnancy-related symptoms. A large gravid uterus may obscure the physical examination findings of abdominal distension and tenderness. Laboratory tests are often unhelpful in making the diagnosis. Plain abdominal radiography may demonstrate the typical air-fluid levels, progressive bowel dilatation in serial films, or the coffee-bean deformity found with volvulus. (*See Figure 4.*) However, plain films have a limited sensitivity and specificity for the diagnosis of small-bowel obstruction and may appear normal with closed-loop or strangulated obstructions. If the clinical suspicion is high, more advanced imaging, such as CT or MRI, is better than plain radiography at detecting obstruction. There is a paucity of studies comparing the diagnostic accuracy of CT and MRI. One small prospective study of 28 confirmed bowel obstructions showed a sensitivity and specificity for MRI of 95% and 100%, respectively, and 71% and

71% for helical CT.[49]

Management of intestinal obstruction is similar in pregnant and non-pregnant patients. Fluid resuscitation, electrolyte replacement, bowel rest, and gastric decompression with a nasogastric tube are the mainstays of initial therapy. Operative intervention is indicated for intestinal perforation, gangrenous bowel, or failure of medical management.

Patients Who Undergo Percutaneous Interventions

Percutaneous interventions are minimally invasive procedures performed by both interventional radiologists and non-interventionalists. Abdominal pain and other gastrointestinal symptoms are common reasons for ED visits post-procedure. This portion of the article will focus on the gastrointestinal complications of several common procedures.

Vena Cava Filters. Potential complications of inferior vena cava (IVC) filters include malposition, fracture, infection, access-site thrombosis, IVC thrombosis, and recurrent deep vein thrombosis (DVT). As such, a device-related complication may cause acute abdominal or flank pain in a patient with an IVC filter. Compared to filters placed within the prior six years, older permanent filters are more likely to migrate or fracture (5-30% [migration] and 2% [strut fracture] vs. 0.3-3% and 0%, respectively).[50-52] While IVC filter or strut migration may be asymptomatic, patients may also sustain ischemic or hemorrhagic end-organ dysfunction due to vessel obstruction or vessel perforation, respectively. Through-and-through perforation of the IVC is rare. Newer filters have improved anchoring and are less likely to migrate.[50,52] When filter migration or significant IVC penetration does occur, patients may present with sharp, tearing flank or groin pain and may have fever or signs of organ damage, such as small-bowel obstruction, duodenal perforation, or gastrointestinal bleeding. CT imaging confirms diagnosis, and urgent consultation with interventional radiology for filter removal is recommended.

Figure 4: Volvulus on Plain X-ray

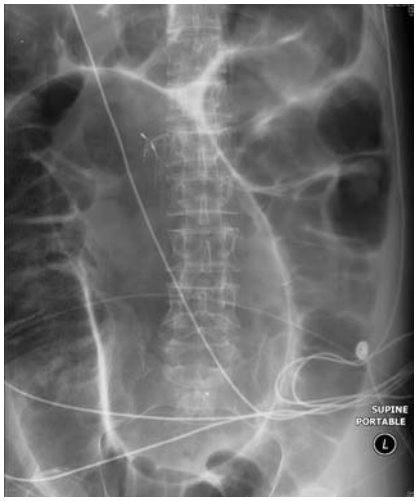

Plain abdominal radiograph demonstrating diffuse distension of the large colon with a "coffee bean" sign suggestive of sigmoid volvulus. (Image provided by Angela M. Mills, MD, University of Pennsylvania, Philadelphia, PA, published with permission.)

Percutaneous Gastrostomy Tubes. Gastrostomy, gastrojejunostomy, and jejunostomy tubes placed percutaneously may be complicated by both major and minor conditions. Major complications occur in approximately 6% of patients and include gastric perforation or hemorrhage, peritonitis due to pericatheter leakage of gastric contents, deep stomal infection or abscess, and unintentional injury to adjacent organs.[53,54] These complications occur within a few days following the intervention, and patients may present with acute abdominal pain associated with fever or signs of severe sepsis. A case series of 370 patients post-gastrostomy-tube placement demonstrated four major complications in patients with significant co-morbidities. Minor complications, occurring in about 8% of patients, include peristomal leakage with skin excoriation, superficial wound infection, and tube malfunction (e.g., dislodgement, balloon rupture, blockage).[53,54] Patients with a suspected major complication of a percutaneous gastrostomy tube often require CT for diagnosis. Early consultation with surgery or interventional radiology is indicated for treatment.

Patients also may present to the ED to have a dislodged tube replaced. As feeding tube tracts can narrow or close within hours of removal, tubes should be replaced in a timely fashion unless the tube was recently inserted. A percutaneous endoscopic gastrostomy (PEG) tube requires approximately one to two weeks after placement (up to four weeks in a patient with altered immunologic function) to form a tract.[55] Replacement of the tube in an immature tract can lead to misplacement into the peritoneal cavity. Information on the type of tube (e.g., gastrostomy, jejunostomy) and the date of placement can help guide ED management. Partially dislodged tubes may need removal prior to replacement; while most tubes may be removed easily, some may require endoscopic removal. If there is doubt, the provider who placed the tube should be contacted to guide management. Tube replacement may be confirmed by obtaining a plain supine abdominal radiograph after injecting water-soluble contrast through the tube. If a feeding tube is not available, a Foley catheter may be used temporarily to prevent closure

Figure 5A: Perihepatic Hematoma on Ultrasound

This ultrasound image demonstrates perihepatic hematoma (H) following transvenous hepatic biopsy. (Image provided by Angela M. Mills, MD, University of Pennsylvania, Philadelphia, PA, published with permission.)

Figure 5B: Perihepatic Hematoma on CT

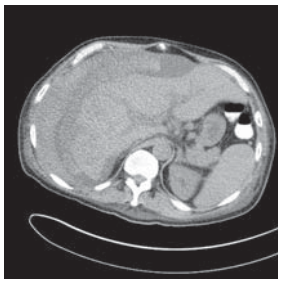

Computed tomography (CT) of the same patient showing perihepatic hematoma post transvenous hepatic biopsy. (Image provided by Angela M. Mills, MD, University of Pennsylvania, Philadelphia, PA, published with permission.)

of the tract.[56]

Transvenous Hepatic and Renal Biopsy. Transvenous hepatic and renal biopsies are most commonly performed when there is a contraindication to or failed percutaneous biopsy. The majority of complications from transhepatic biopsies are detected prior to discharge from the procedure and require no intervention.[57] Delayed development of a perihepatic hematoma may occur post liver biopsy. Patients present to the ED with abdominal pain radiating to the right shoulder. Right upper-quadrant ultrasonography may be performed to make the diagnosis. (*See Figures 5A and 5B.*) Acute intervention is indicated for hemodynamic instability or a life-threatening decrease in the hematocrit level. While transient fever may be commonly seen up to 24 hours after the procedure,[58] persistent fever associated with gastrointestinal symptoms is concerning for possible intra- or peri-hepatic abscess and needs further evaluation.

Complications of transjugular renal biopsies also do not necessitate acute intervention. The majority of patients (66%) develop gross hematuria due to a perinephric hematoma or calyceal hemorrhage, which resolves spontaneously.[59,60] Significant hematuria and symptomatic anemia may be caused by an arterio-venous or arterio-calyceal fistula in patients post transvenous biopsy of the kidney.[61] These patients may complain of abdominal pain and distension due to clot retention or urethral obstruction. Manual bladder irrigation through a large-bore (20 French or larger) Foley catheter is indicated for these patients. Continuous bladder irrigation may be used, as clots may cause obstruction of the catheter, leading to bladder perforation. Patients with asymptomatic anemia in the absence of hematuria also may present with abdominal or flank pain due to a retroperitoneal hematoma.[62] Patients with intractable bleeding or a retroperitoneal bleed warrant urgent consultation with interventional radiology for vessel embolization.

Transjugular Intrahepatic Portosystemic Shunts. In liver failure patients with portal hypertension and its complications, transjugular intrahepatic portosystemic shunts (TIPS) redirect blood from the abnormally high-pressure portal system to the low-pressure caval system.[63] Complications from the procedure include inadvertent puncture of the liver capsule (5-30%), gallbladder or bile ducts (5-10%), and right kidney (< 2%).[64] These patients may present with acute abdominal or flank pain due to an expanding perihepatic hematoma, acute cholangitis, or perinephric hematoma, respectively. CT may be indicated to detect intra-abdominal sources of bleeding or infection. The ED treatment of TIPS-related complications includes hemodynamic stabilization and treatment of specific findings such as antibiotics for infection and correction of coagulopathies and blood transfusion for significant bleeding.

Uterine Artery Embolization. Patients often seek emergency care post uterine artery embolization (UAE) for abdominal or pelvic pain and vaginal discharge or bleeding.[65-67] In addition to these complaints, patients may also develop fever, hot flashes, mood swings, abdominal bloating, dysuria, and fibroid passage. The compilation of these symptoms is known as post-embolization syndrome and is thought to be caused by fibroid infarction.[67] Severe post-procedural pain and pelvic infection are the two most common indications for hospitalization.[67] In addition to post-embolization syndrome, fibroid passage, and fibroid necrosis, abdominal pain may also be due to the more serious etiology of pelvic infection, including endometritis, myometritis, pelvic abscess, and infected necrotic leiomyoma. MRI with gadolinium is considered the most sensitive imaging study to differentiate a pelvic infection from post-embolization syndrome.[68] (*See Figure 6.*) If MRI is not readily available, CT is the next study of choice.

Percutaneous Biliary Drains. Percutaneous biliary drains may be external (the catheter is upstream from obstruction and bile is drained externally into a drain bag), internal (a metallic or plastic stent crosses obstruction and drains into the bowel with no drain exiting the body), and internal-external (an external catheter crosses the obstruction with side holes both upstream and downstream).[69] Patients with these biliary drains may present to the ED with acute abdominal pain caused by intraperitoneal bile leakage or obstruction of the drain, which

Figure 6: Endometritis on MRI

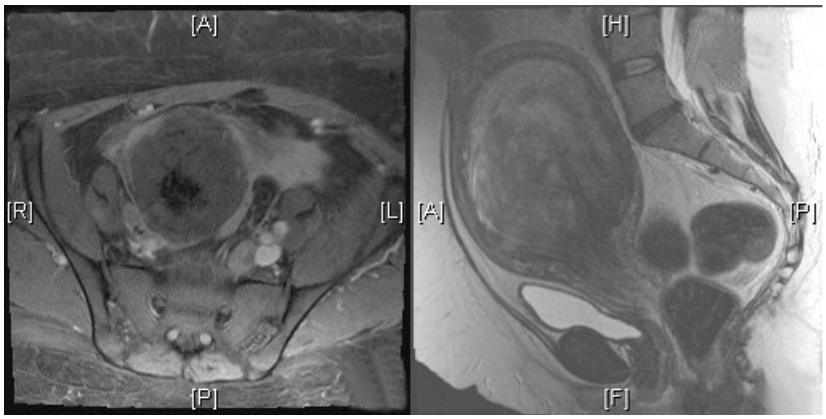

6A. Magnetic resonance imaging (MRI) of the uterus demonstrating gas and inflammation within the endometrium characteristic of endometritis. 6B. MRI of the uterus demonstrating uterine fibroid extrusion. (Image provided by Esther H. Chen, MD, University of California San Francisco, San Francisco, CA, published with permission.)

can lead to ascending cholangitis and intrahepatic abscess, particularly in those with malignant biliary obstruction.[70] CT is recommended for the identification of these complications. In the ED, uncapping the external portion of the biliary drain may alleviate an obstruction and the patient's pain.

Conclusions

The ED evaluation and management of abdominal pain in the three distinct populations discussed in this issue can be challenging because atypical and delayed presentations increase their risk of complications compared to the general population. It is helpful to understand the underlying conditions and specific characteristics to prioritize certain diseases in the broad differential diagnosis of abdominal pain. In immunocompromised hosts, the risk of a serious intra-abdominal infection is high, particularly for HIV patients with low CD4 counts not on HAART, transplant patients in the intermediate post-transplantation period, or cancer patients undergoing active chemotherapy with neutropenia. The underlying opportunistic infection can present as surgical processes such as bowel perforation, acute appendicitis, or intestinal obstruction. Pregnant patients undergo physiologic changes that can make interpreting symptoms, physical examination findings, and even laboratory results more difficult. To avoid the radiation risk of CT, physicians can rely on ultrasound and MRI, the latter of which is diagnostically similar to CT for many surgical conditions. CT may be used in the later stages of pregnancy when the benefit of imaging outweighs the radiation risk. For these distinct populations, the reliance on imaging for diagnosis is difficult to avoid because the benefit of making an accurate diagnosis often outweighs the risks associated with the imaging study.

References

1. Unterman S, Zimmerman M, Tyo C, et al. A descriptive analysis of 1251 solid organ transplant visits to the emergency department. *West J Emerg Med* 2009;10:48-54.
2. Scott-Conner CE, Fabrega AJ. Gastrointestinal problems in the immunocompromised host. A review for surgeons. *Surg Endosc* 1996;10:959-964.
3. Yoshida D, Caruso JM. Abdominal pain in the HIV infected patient. *J Emerg Med* 2002;23:111-116.
4. Barone JE, Gingold BS, Arvanitis ML, et al. Abdominal pain in patients with acquired immune deficiency syndrome. *Ann Surg* 1986;204:619-623.
5. Parente F, Cernuschi M, Antinori S, et al. Severe abdominal pain in patients with AIDS: Frequency, clinical aspects, causes, and outcome. *Scand J Gastroenterol* 1994;29:511-515.
6. O'Keefe EA, Wood R, Van Zyl A, et al. Human immunodeficiency virus-related abdominal pain in South Africa. Aetiology, diagnosis and survival. *Scand J Gastroenterol* 1998;33:212-217.
7. Monkemuller KE, Lazenby AJ, Lee DH, et al. Occurrence of gastrointestinal opportunistic disorders in AIDS despite the use of highly active antiretroviral therapy. *Dig Dis Sci* 2005;50:230-234.
8. Slaven EM, Lopez F, Weintraub SL, et al. The AIDS patient with abdominal pain: A new challenge for the emergency physician. *Emerg Med Clin North Am* 2003;21:987-1015.
9. Saltzman DJ, Williams RA, Gelfand DV, et al. The surgeon and AIDS: Twenty years later. *Arch Surg* 2005;140:961-967.
10. Davidson T, Allen-Mersh TG, Miles AJ, et al. Emergency laparotomy in patients with AIDS. *Br J Surg* 1991;78:924-926.
11. Swenson KK, Rose MA, Ritz L, et al. Recognition and evaluation of oncology-related symptoms in the emergency department. *Ann Emerg Med* 1995;26:12-17.
12. Ilgen JS, Marr AL. Cancer emergencies: The acute abdomen. *Emerg Med Clin North Am* 2009;27:381-399.
13. Hirst B, Regnard C. Management of intestinal obstruction in malignant disease. *Clin Med* 2003;3:311-314.
14. Ripamonti CI, Easson AM, Gerdes H. Management of malignant bowel obstruction. *Eur J Cancer* 2008;44:1105-1115.
15. Takeuchi K, Tsuzuki Y, Ando T, et al. The diagnosis and treatment of adult intussusception. *J Clin Gastroenterol* 2003;36:18-21.
16. Maglinte DD, Kelvin FM, Sandrasegaran K, et al. Radiology of small bowel obstruction: Contemporary approach and controversies. *Abdom Imaging* 2005;30:160-178.
17. Sarr MG, Bulkley GB, Zuidema GD. Preoperative recognition of intestinal strangulation obstruction. Prospective evaluation of diagnostic capability. *Am J Surg* 1983;145:176-182.
18. Yeoh E. Radiotherapy: Long-term effects on gastrointestinal function. *Curr Opin Support Palliat Care* 2008;2:40-44.
19. Hill A, Balkin A. Risk factors for gastrointestinal adverse events in HIV treated and untreated patients. *AIDS Rev* 2009;11:30-38.
20. Rolston KV. Neutropenic enterocolitis associated with docetaxel therapy in a patient with breast cancer. *Clin Adv Hematol Oncol* 2009;7:527-528.
21. Gorschluter M, Mey U, Strehl J, et al. Neutropenic enterocolitis in adults: Systematic analysis of evidence quality. *Eur J Haematol* 2005;75:1-13.
22. Spencer SP, Power N, Reznek RH. Multidetector computed tomography of the acute abdomen in the immunocompromised host: A pictorial review. *Curr Probl Diagn Radiol* 2009;38:145-155.
23. Blijlevens NM. Neutropenic enterocolitis: challenges in diagnosis and treatment.

Clin Adv Hematol Oncol 2009;7:528-530.

24. Ullery BW, Pieracci FM, Rodney JR, et al. Neutropenic enterocolitis. *Surg Infect (Larchmt)* 2009;10:307-314.
25. Fishman JA. Infection in solid-organ transplant recipients. *N Engl J Med* 2007;357:2601-2614.
26. Branch DW. Physiologic adaptations of pregnancy. *Am J Reprod Immunol* 1992;28:120-122.
27. Martin C, Varner MW. Physiologic changes in pregnancy: Surgical implications. *Clin Obstet Gynecol* 1994;37:241-255.
28. Challoner K, Incerpi M. Nontraumatic abdominal surgical emergencies in the pregnant patient. *Emerg Med Clin North Am* 2003;21:971-985.
29. Oto A, Ernst RD, Ghulmiyyah LM, et al. MR imaging in the triage of pregnant patients with acute abdominal and pelvic pain. *Abdom Imaging* 2009;34:243-250.
30. Goldberg-Stein S, Liu B, Hahn PF, et al. Body CT during pregnancy: Utilization trends, examination indications, and fetal radiation doses. *AJR Am J Roentgenol* 2011;196:146-151.
31. Jaffe TA, Miller CM, Merkle EM. Practice patterns in imaging of the pregnant patient with abdominal pain: A survey of academic centers. *AJR Am J Roentgenol* 2007;189:1128-1134.
32. Mourad J, Elliott JP, Erickson L, et al. Appendicitis in pregnancy: New information that contradicts long-held clinical beliefs. *Am J Obstet Gynecol* 2000;182:1027-1029.
33. Tracey M, Fletcher HS. Appendicitis in pregnancy. *Am Surg* 2000;66:555-559; discussion 559-560.
34. Mazze RI, Kallen B. Appendectomy during pregnancy: A Swedish registry study of 778 cases. *Obstet Gynecol* 1991;77:835-840.
35. McGory ML, Zingmond DS, Tillou A, et al. Negative appendectomy in pregnant women is associated with a substantial risk of fetal loss. *J Am Coll Surg* 2007;205:534-540.
36. Andersen B, Nielsen TF. Appendicitis in pregnancy: Diagnosis, management and complications. *Acta Obstet Gynecol Scand* 1999;78:758-762.
37. Williams R, Shaw J. Ultrasound scanning in the diagnosis of acute appendicitis in pregnancy. *Emerg Med J* 2007;24:359-360.
38. Basaran A, Basaran M. Diagnosis of acute appendicitis during pregnancy: A systematic review. *Obstet Gynecol Surv* 2009;64:481-488; quiz 499.
39. Ramin KD, Ramsey PS. Disease of the gallbladder and pancreas in pregnancy. *Obstet Gynecol Clin North Am* 2001;28:571-580.
40. Gilo NB, Amini D, Landy HJ. Appendicitis and cholecystitis in pregnancy. *Clin Obstet Gynecol* 2009;52:586-596.
41. Emergency ultrasound guidelines. *Ann Emerg Med* 2009;53:550-570.
42. Shelton J, Linder JD, Rivera-Alsina ME, et al. Commitment, confirmation, and clearance: New techniques for nonradiation ERCP during pregnancy (with videos). *Gastrointest Endosc* 2008;67:364-368.
43. Dhupar R, Smaldone GM, Hamad GG. Is there a benefit to delaying cholecystectomy for symptomatic gallbladder disease during pregnancy? *Surg Endosc* 2010;24:108-112.
44. Jelin EB, Smink DS, Vernon AH, Brooks DC. Management of biliary tract disease during pregnancy: A decision analysis. *Surg Endosc* 2008;22:54-60.
45. Lu EJ, Curet MJ, El-Sayed YY, et al. Medical versus surgical management of biliary tract disease in pregnancy. *Am J Surg* 2004;188:755-759.
46. Dietrich CS, 3rd, Hill CC, Hueman M. Surgical diseases presenting in pregnancy. *Surg Clin North Am* 2008;88:403-419, vii-viii.
47. Augustin G, Majerovic M. Non-obstetrical acute abdomen during pregnancy. *Eur J Obstet Gynecol Reprod Biol* 2007;131:4-12.
48. Perdue PW, Johnson HW, Jr., Stafford PW. Intestinal obstruction complicating pregnancy. *Am J Surg* 1992;164:384-388.
49. Beall DP, Fortman BJ, Lawler BC, et al. Imaging bowel obstruction: A comparison between fast magnetic resonance imaging and helical computed tomography. *Clin Radiol* 2002;57:719-724.
50. Berczi V, Bottomley JR, Thomas SM, et al. Long-term retrievability of IVC filters: Should we abandon permanent devices? *Cardiovasc Intervent Radiol* 2007;30:820-827.
51. Chung J, Owen RJ. Using inferior vena cava filters to prevent pulmonary embolism. *Can Fam Physician* 2008;54:49-55.
52. Ray CE, Jr., Kaufman JA. Complications of inferior vena cava filters. *Abdom Imaging* 1996;21:368-374.
53. Given MF, Hanson JJ, Lee MJ. Interventional radiology techniques for provision of enteral feeding. *Cardiovasc Intervent Radiol* 2005;28:692-703.
54. Wollman B, D'Agostino HB, Walus-Wigle JR, et al. Radiologic, endoscopic, and surgical gastrostomy: An institutional evaluation and meta-analysis of the literature. *Radiology* 1995;197:699-704.
55. Minchff TV. Early dislodgement of percutaneous and endoscopic gastrostomy tube. *J S C Med Assoc* 2007;103:13-15.
56. Kadakia SC, Cassaday M, Shaffer RT. Prospective evaluation of Foley catheter as a replacement gastrostomy tube. *Am J Gastroenterol* 1992;87:1594-1597.
57. Kalambokis G, Manousou P, Vibhakorn S, et al. Transjugular liver biopsy — indications, adequacy, quality of specimens, and complications — a systematic review. *J Hepatol* 2007;47:284-294.
58. Gamble P, Colapinto RF, Stronell RD, et al. Transjugular liver biopsy: A review of 461 biopsies. *Radiology* 1985;157:589-593.
59. Cluzel P, Martinez F, Bellin MF, et al. Transjugular versus percutaneous renal biopsy for the diagnosis of parenchymal disease: Comparison of sampling effectiveness and complications. *Radiology* 2000;215:689-693.
60. Misra S, Gyamlani G, Swaminathan S, et al. Safety and diagnostic yield of transjugular renal biopsy. *J Vasc Interv Radiol* 2008;19:546-551.
61. See TC, Thompson BC, Howie AJ, et al. Transjugular renal biopsy: Our experience and technical considerations. *Cardiovasc Intervent Radiol* 2008;31:906-918.
62. Fine DM, Arepally A, Hofmann LV, et al. Diagnostic utility and safety of transjugular kidney biopsy in the obese patient. *Nephrol Dial Transplant* 2004;19:1798-1802.
63. Haskal ZJ, Martin L, Cardella JF, et al. Quality improvement guidelines for transjugular intrahepatic portosystemic shunts. *J Vasc Interv Radiol* 2003;14:S265-270.
64. Freedman AM, Sanyal AJ, Tisnado J, et al. Complications of transjugular intrahepatic portosystemic shunt: A comprehensive review. *Radiographics* 1993;13:1185-1210.
65. Ganguli S, Faintuch S, Salazar GM, et al. Postembolization syndrome: Changes in white blood cell counts immediately after uterine artery embolization. *J Vasc Interv Radiol* 2008;19:443-445.
66. Marshburn PB, Matthews ML, Hurst BS. Uterine artery embolization as a treatment option for uterine myomas. *Obstet Gynecol Clin North Am* 2006;33:125-144.
67. Pron G, Mocarski E, Bennett J, et al. Tolerance, hospital stay, and recovery after uterine artery embolization for fibroids: The Ontario Uterine Fibroid Embolization Trial. *J Vasc Interv Radiol* 2003;14:1243-1250.
68. Kitamura Y, Ascher SM, Cooper C, et al. Imaging manifestations of complications associated with uterine artery embolization. *Radiographics* 2005;25 Suppl 1:S119-132.
69. Covey AM, Brown KT. Palliative percutaneous drainage in malignant biliary obstruction. Part 2: Mechanisms and postprocedure management. *J Support Oncol* 2006;4:329-335.
70. Wu SM, Marchant LK, Haskal ZJ. Percutaneous interventions in the biliary tree. *Semin Roentgenol* 1997;32:228-245.

Physician CME Questions

61. A 35-year-old man with HIV on HAART presents with diffuse abdominal pain, nausea, vomiting, and diarrhea for 3 days. No recent travel history or antibiotic use. He is dehydrated and has a diffusely tender abdomen without peritoneal signs.

His rectal exam shows bright red blood mixed with stool. He most likely has:

A. AIDS cholangiopathy
B. CMV colitis
C. intestinal lymphoma
D. known side effects of the HAART medications

62. Which of these is more common in cancer patients than healthy adults?

A. acute cholecystitis
B. intestinal obstruction
C. intestinal perforation
D. intussusception

63. A 43-year-old woman with breast cancer received chemotherapy 2 days ago. She presents with fever, nausea, vomiting, and diarrhea. Which of the following will be most helpful?

A. blood cultures
B. white blood cell count
C. lipase level
D. liver function tests

64. A 50-year-old man with a history of liver transplantation 2 years ago presents with lower abdominal pain, nausea, and vomiting. No fever or chills. He has left lower-quadrant abdominal tenderness, no distension, and no peritoneal signs. The mostly likely cause of his pain is:

A. acute diverticulitis
B. acute graft rejection
C. CMV colitis
D. post-transplantation lymphoproliferative disorder

65. Which of the following statements is true?

A. Elevated white blood cell counts and alkaline phosphatase levels may be normal in pregnancy.
B. Peritonitis is a reliable sign of surgical disease even in late pregnancy.
C. Pregnant patients will exhibit signs of hypovolemic shock after losing the same amount of blood as non-pregnant patients.
D. Right upper-quadrant abdominal pain is the most common presenting symptom of acute appendicitis in the third trimester.

66. A 30-year-old woman presents with diffuse abdominal pain, nausea, and vomiting. She is 8 weeks pregnant. On exam she appears uncomfortable, with a distended diffusely tender abdomen and no bowel sounds. Her pelvic exam is unremarkable. A pelvic ultrasound showed an intra-uterine pregnancy. The best test to order to diagnose the etiology of her pain is:

A. abdomen-pelvis CT
B. abdomen-pelvis MRI
C. plain abdominal radiography
D. urinanalysis

67. A 57-year-old woman presents with sharp tearing flank pain and hematuria. She had an IVC filter placed 2 weeks ago. On exam she has a non-tender, non-distended abdomen and no costovertebral angle tenderness. Her workup is most likely to show:

A. IVC filter in the renal pelvis on plain radiography
B. acute nephrolithiasis
C. positive nitrite and leukocyte esterase levels on urinalysis
D. acute diverticulitis

68. A 70-year-old man presents with fever, hypotension, altered mental status, and abdominal pain 3 days after percutaneous placement of a gastrostomy tube. His abdomen is distended and diffusely tender. The gastrostomy tube site is clean and intact. In addition to resuscitating the patient, you should:

A. Inject saline into the gastrostomy tube to look for leakage around the tube.
B. Lavage the gastrostomy tube with saline to check for hemorrhage.
C. Obtain an abdomen-pelvis CT with contrast to detect peristomal leakage or gastric perforation.
D. Order a stat plain abdominal radiograph after injecting gastrograffin into the tube to look for obstruction.

69. A 65-year-old woman presents with fever, chills, abdominal bloating and pain, and nausea. She underwent uterine artery embolization 5 days ago for uterine fibroids. She is writhing in pain with a diffusely tender, non-distended abdomen. Her pelvic exam shows a tender, enlarged uterus without purulent discharge. In addition to giving analgesia, you should:

A. Obtain an amylase and lipase level.
B. Discharge the patient with a diagnosis of post-embolization syndrome.
C. Obtain an abdomen-pelvis MRI to exclude endometritis.
D. Perform a bedside ultrasound to evaluate for cholecystitis.

70. A 75-year-old man with hepatic carcinoma presents with fever and vomiting. He has had an internal-external biliary drain in place and capped for several months without any problems. He has tenderness in the right upper quadrant and no obvious signs of skin infection around the drain. You should:

A. Administer antibiotics for ascending cholangitis.
B. Obtain an abdomen-pelvis CT to exclude a perihepatic abscess.
C. Obtain an ultrasound to look for dilated intrahepatic biliary ducts.
D. Uncap the external biliary drain and relieve the obstruction.

CME Answer Key

61. B; 62. D; 63. B; 64. A; 65. A; 66. B; 67. A; 68. C; 69. C; 70. D

CME Instructions

Physicians participate in this continuing medical education program by reading the article, using the provided references for further research, and studying the questions at the end of the article. Participants should select what they believe to be the correct answers, then refer to the list of correct answers to evaluate their knowledge. To clarify confusion surrounding any questions answered incorrectly, please consult the source material. *After completing this activity, you must complete the evaluation form that will be provided at the end of the semester and return it in the reply envelope provided to receive a credit letter.* When your evaluation is received, a credit letter will be mailed to you.

Emergency Medicine Reports

CME Objectives

Upon completion of this educational activity, participants should be able to:

- recognize specific conditions in patients presenting to the emergency department;
- apply state-of-the-art diagnostic and therapeutic techniques to patients with the particular medical problems discussed in the publication;
- discuss the differential diagnosis of the particular medical problems discussed in the publication;
- explain both the likely and rare complications that may be associated with the particular medical problems discussed in the publication.

Emergency Medicine Reports™ (ISSN 0746-2506) is published biweekly by AHC Media, a division of Thompson Media Group LLC, 3525 Piedmont Road, N.E., Six Piedmont Center, Suite 400, Atlanta, GA 30305. Telephone: (800) 688-2421 or (404) 262-7436.

Executive Editor: Shelly Morrow Mark

Managing Editor: Leslie Hamlin

GST Registration No.: R128870672

Periodicals Postage Paid at Atlanta, GA 30304 and at additional mailing offices.

POSTMASTER: Send address changes to Emergency Medicine Reports, P.O. Box 105109, Atlanta, GA 30348.

Back issues: $31. Missing issues will be fulfilled by customer service free of charge when contacted within one month of the missing issue's date.

Multiple copy prices: One to nine additional copies, $359 each; 10 to 20 additional copies, $319 each.

Subscriber Information

Customer Service: 1-800-688-2421

Customer Service E-Mail:
customerservice@ahcmedia.com

Editorial E-Mail:
shelly.mark@ahcmedia.com

World Wide Web page:
http://www.ahcmedia.com

Subscription Prices

1 year *with* 60 ACEP/60 AMA/60 AAFP Category 1/Prescribed credits: $544

1 year *without* credit: $399
Add $17.95 for shipping & handling

Resident's rate $199

Discounts are available for group subscriptions, multiple copies, site-licenses or electronic distribution. For pricing information, call
Tria Kreutzer at 404-262-5482.

All prices U.S. only.
U.S. possessions and Canada, add $30 plus applicable GST. Other international orders, add $30.

Accreditation

AHC Media is accredited by the Accreditation Council for Continuing Medical Education to provide continuing medical education for physicians.

AHC Media designates this educational activity for a maximum of 60 *AMA PRA Category 1 Credits™*. Each issue has been designated for a maximum of 2.30 *AMA PRA Category 1 Credits™*. Physicians should only claim credit commensurate with the extent of their participation in the activity.

Approved by the American College of Emergency Physicians for 60 hours of ACEP Category 1 credit.

Emergency Medicine Reports has been reviewed and is acceptable for up to 39 Prescribed credits by the American Academy of Family Physicians. AAFP accreditation begins 01/01/11. Term of approval is for one year from this date. Each issue is approved for 1.50 Prescribed credits. Credit may be claimed for 1 year from the date of each issue. The AAFP invites comments on any activity that has been approved for AAFP CME credit.

Please forward your comments on the quality of this activity to cmecomment@aafp.org.

This is an educational publication designed to present scientific information and opinion to health professionals, to stimulate thought, and further investigation. It does not provide advice regarding medical diagnosis or treatment for any individual case. It is not intended for use by the layman. Opinions expressed are not necessarily those of this publication. Mention of products or services does not constitute endorsement. Clinical, legal, tax, and other comments are offered for general guidance only; professional counsel should be sought for specific situations.

This CME activity is intended for emergency and family physicians. It is in effect for 24 months from the date of the publication.

AHC Media

Emergency Medicine Reports
The Practical Journal for Emergency Physicians

Abdominal Pain in Special Populations

Appendicitis on Ultrasound

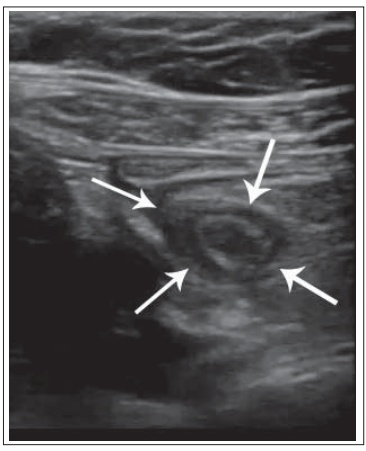

Ultrasound image in the short axis plane of an inflamed appendix (outlined by arrows). It is often described as a "target" sign when viewed in short axis. (Image provided by Nova L. Panebianco, MD, University of Pennsylvania, Philadelphia, PA, published with permission)

Appendicitis on MRI

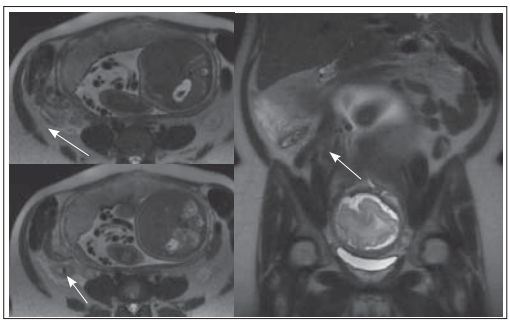

Axial (left) and coronal (right) T2 weighted MRI images through the right lower quadrant in a pregnant patient at 24 weeks gestation demonstrating a distended, thick-walled appendix with periappendiceal fluid (arrows). There is a low signal structure within the appendix, likely an appendicolith or focus of gas. (Image provided by Elizabeth M. Hecht, MD, University of Pennsylvania, Philadelphia, PA, published with permission)

Cholecystitis on Ultrasound

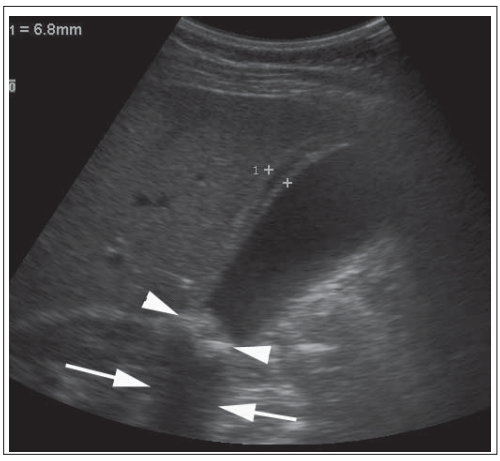

Ultrasonography in longitudinal view demonstrating cholecystitis, specifically gallstones (arrowheads) impacted in the gallbladder neck with posterior shadowing (arrows), and a thickened gallbladder wall with intramural edema (calipers). (Image provided by Anthony J. Dean, MD, University of Pennsylvania, Philadelphia, PA, published with permission)

Volvulus on Plain X-ray

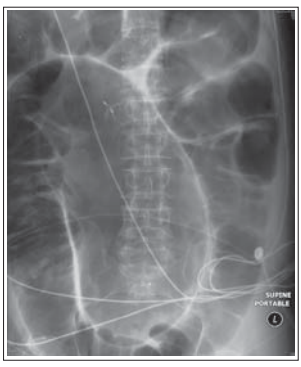

Plain abdominal radiograph demonstrating diffuse distension of the large colon with a "coffee bean" sign suggestive of sigmoid volvulus. (Image provided by Angela M. Mills, MD, University of Pennsylvania, Philadelphia, PA, published with permission.)

Endometritis on MRI

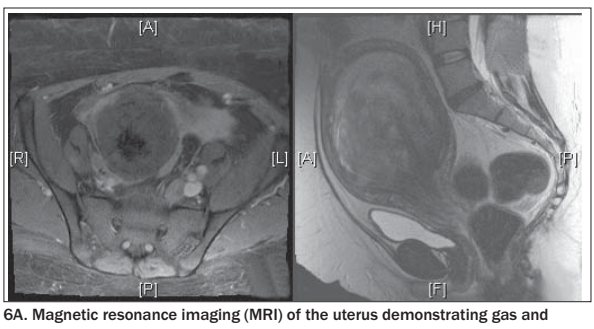

6A. Magnetic resonance imaging (MRI) of the uterus demonstrating gas and inflammation within the endometrium characteristic of endometritis. 6B. MRI of the uterus demonstrating uterine fibroid extrusion. (Image provided by Esther H. Chen, MD, University of California San Francisco, San Francisco, CA, published with permission.)

Perihepatic Hematoma on Ultrasound

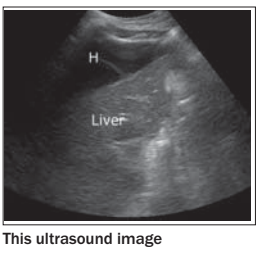

This ultrasound image demonstrates perihepatic hematoma (H) following transvenous hepatic biopsy. (Image provided by Angela M. Mills, MD, University of Pennsylvania, Philadelphia, PA, published with permission.)

Perihepatic Hematoma on CT

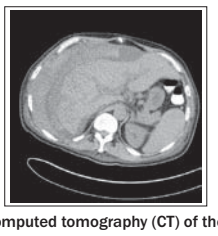

Computed tomography (CT) of the same patient showing perihepatic hematoma post transvenous hepatic biopsy. (Image provided by Angela M. Mills, MD, University of Pennsylvania, Philadelphia, PA, published with permission.)

Supplement to *Emergency Medicine Reports*, March 14, 2011: "Abdominal Pain in Special Populations." *Authors:* **Angela M. Mills, MD,** Assistant Professor of Emergency Medicine, Department of Emergency Medicine, University of Pennsylvania, Philadelphia; and **Esther H. Chen, MD**, Associate Professor of Emergency Medicine, Department of Emergency Medicine, University of California–San Francisco, San Francisco General Hospital.

Trauma Reports

EVIDENCE-BASED MEDICINE FOR THE ED

Volume 12, Number 2 **Mar/Apr 2011**

Authors:

Alisa Gibson, MD, DMD,
Visiting Instructor, Department of Emergency Medicine, University of Maryland, Baltimore, MD

Kimberly Boswell, MD,
Resident III, Department of Emergency Medicine, University of Maryland, Baltimore, MD

Peer Reviewer:

Howard A. Werman, MD,
Medical Director, MedFlight; and Professor of Clinical Emergency Medicine, The Ohio State University, Columbus, OH

Statement of Financial Disclosure

To reveal any potential bias in this publication, and in accordance with Accreditation Council for Continuing Medical Education guidelines, we disclose that Dr. Dietrich (editor in chief), Drs. Gibson and Boswell, (authors), Dr. Werman (peer reviewer), and Ms. Behrens (nurse reviewer) report no relationships with companies related to this field of study. Mr. McKagen (executive editor), and Ms. Coplin (managing editor) report no relationships with companies related to the field of study covered by this CME activity.

AHC Media

Facial Trauma: Challenges, Controversies, and Therapeutic Options

Our faces play a role in almost every part of our lives. The structure and components of the face are involved in our ability to eat, speak, and see, and often are the features first noticed when we meet someone. Trauma involving the face is fairly common: More than 3 million facial injuries occur in the United States each year. More than 50 percent of patients with maxillofacial injuries have multisystem trauma, requiring coordination between emergency physicians and surgical specialists.[1] Young men between the ages of 20 and 30 years are the individuals who most commonly sustain facial trauma, and the primary cause is assault.[2] Alcohol is frequently involved.[3] Other common causes of facial trauma include motor vehicle collisions (MVC), sports injuries, penetrating trauma, and falls. The ability to manage these injuries efficiently and expertly is crucial for the emergency physician.
— Ann Dietrich, MD, FAAP, FACEP, Editor

Initial Assessment and Examination

The initial assessment of the patient with facial trauma is identical to that of any trauma patient. Airway patency is paramount, and intervention may be required. Concomitant intracranial injury, significant facial bleeding, bilateral mandibular fractures, or massive trauma to the lower two-thirds of the face (such as that caused by a gunshot wound) all may necessitate intubation. If there is any concern regarding airway protection, particularly in patients who will be immobilized for other injuries, patients should have a definitive airway placed. With the airway secured, a thorough evaluation of facial injuries typically can be delayed until other major injuries have been assessed and stabilized.

Patients with facial trauma should be placed in a cervical collar and presumed to have a cervical injury until proven otherwise. The reported incidence of cervical spine fractures among patient with facial trauma varies widely, from as low as 0.3% to as high as 24%.[4,5] Not surprisingly, higher percentages of cervical spine injuries are found in patients with multiple facial fractures as well as among those whose injuries result from MVCs.

General Facial Injury Assessment

The presence of any facial trauma should prompt a complete systematic examination for other facial injuries. Assess lacerations and wounds for active bleeding, depth of penetration, foreign bodies, and transection of nerves or ducts. Carefully evaluate areas of ecchymosis and hematomas. Periorbital edema and ecchymosis may indicate underlying orbital rim or zygomaticomaxillary complex (ZMC) fracture. Battle's sign, or bruising behind the ear, should raise concern for a basilar skull fracture. Hematomas in the maxillary buccal vestibule often are seen in patients with ZMC fracture, while ecchymosis on the floor of the mouth suggests an anterior mandibular fracture. The neurologic examination should include evaluation of all cranial nerves, paying special attention to the trigeminal and facial nerves, as these may be damaged by lacerations or fractures.

Executive Summary

- The initial priority when treating patients with facial trauma is the ABCs (airway, breathing, and circulation), paying particular attention to airway, major bleeding, and associated brain injury.
- Emergency physicians should assess lacerations and wounds for active bleeding, depth of penetration, foreign bodies, and transection of nerves or ducts.
- CT scans are highly accurate for the diagnosis of fractures and are more beneficial in the setting of multiple facial injuries.
- Frontal sinus fractures can be complicated by cerebrospinal fluid leak, thus increasing the risk for infection.
- Dental trauma frequently accompanies facial fractures: one study found that 64% of patients with bilateral mandibular condylar fractures had damage to the dentition.

Any trauma to or around the eye mandates a complete ophthalmologic assessment, including visual acuity, extraocular motion, and a slit lamp examination. Palpate all bony areas for step-off deformities. Assess midface stability by placing one hand on the forehead and then grasping the anterior maxilla with the other hand. Look for trismus, as well as any objective or subjective malocclusion. The intraoral examination should include a careful search for lacerations and loose, fractured, or missing teeth.[6,7]

Midfacial Fractures

Midfacial fractures involve the zygoma, maxilla, and nasoorbital ethmoid complex. Although fractures of isolated bones do occur, it is more common to see fracture patterns involving more than one bone. Midface fractures often occur in conjunction with other injuries, as was the case in 54.8% of soldiers in one series.[8] Other facial bone fractures, facial lacerations, limb fractures, skull fractures, and intracranial injuries usually are present depending on the mechanism of injury. Diagnosis typically is confirmed by computed tomography (CT) scan. General management in the emergency department (ED) consists of making the diagnosis, controlling bleeding, and initiating referral to a surgeon.

ZMC fractures, also known as trimalar or tripod fractures, involve the zygoma, lateral orbit, and maxilla. Fractures of the zygomatic arch may occur in isolation, typically caused by a direct blow. Their management is the same as mid-facial fractures, so they are discussed together. Because of the amount of facial swelling, these fractures are easy to miss. If left untreated, they may lead to a cosmetic deformity. They also can cause difficulty with mouth opening as a result of impingement of fracture segments on the coronoid process of the mandible. Therefore, a low threshold for CT scan is critical. On examination, these patients often have periorbital edema and ecchymosis as well as subconjunctival hemorrhage. Palpate for step-off deformities and compare the zygomatic arches for symmetry (best done by looking from behind the patient's head). Assess for range of mouth opening (normal is > 30 mm). On intraoral examination, a hematoma may be found in the buccal vestibule. Careful documentation of paresthesias is crucial—injury to the maxillary branch of the trigeminal nerve is present in 70%–90% of patients with this fracture[9] and may be permanent. Surgery frequently is required but often is delayed 7–10 days to allow time for the swelling to decrease.

LeFort fractures are more complex. (*See Figure 1.*) A LeFort I fracture is a horizontal fracture of the maxilla, above the roots of the teeth. A LeFort II fracture separates the entire maxilla and nasal complex from the rest of the face and the cranial base. A LeFort III fracture is a total disarticulation of the midface, and extends through the orbits to separate the maxilla, nasoorbital ethmoid complex, and zygomatic arch away from the cranial base. These fractures often are evident on exam, when testing for maxillary mobility (by grasping and gently pulling on the anterior maxilla). The fracture may be unilateral, so mobility should be tested on the right and left as well as at the midline. Alternatively, different LeFort fractures can be seen on each side. Intraorally, there may be a visible split through the palate,

Figure 1. LeFort Fractures

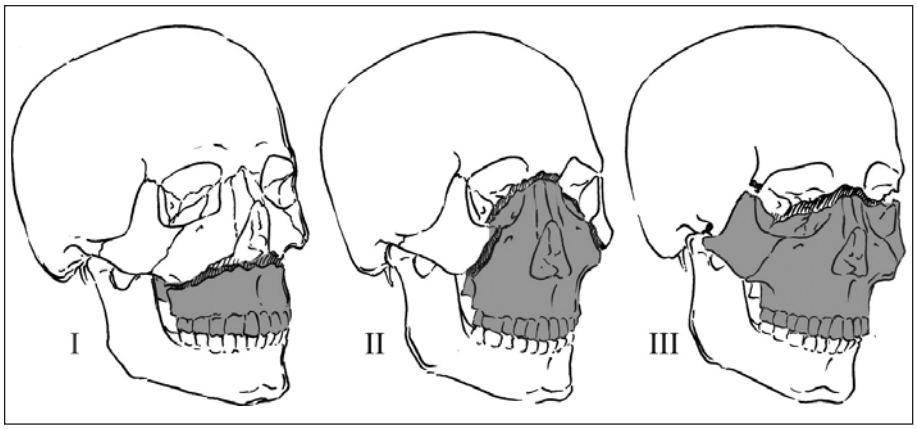

bruising of the palate, or an anterior open bite. Significant bleeding can be seen with all of these fracture patterns, and cerebrospinal fluid (CSF) leak may complicate LeFort type II and III.[6,7,10]

Bleeding related to facial fractures can be extensive. Life-threatening hemorrhage occurs in 1.2%–11.5% of patients with maxillofacial injuries, most commonly in those with LeFort or midface fractures.[11,12] Severe bleeding is usually attributable to disruption of the maxillary artery (which passes within the LeFort fracture borders). It is difficult, if not impossible, to locate the precise origin of the bleeding since it frequently involves both the hard and soft tissues of the midface. In addition, since the fractures tend to track in a posterior direction, the damaged vessel may be located in an area too deep to be accessible to the emergency physician. For example, the pterygomaxiallary fossa, involved in LeFort fractures, contains the third segment of the internal maxillary artery—a common culprit in severe bleeding.[4,12] Nasal packing, the treatment of choice, can be lifesaving. Although anterior packing typically is sufficient for epistaxis, posterior packing generally is required for severe bleeding related to midface fractures. It is important to consult facial surgeons early, because if the maxilla is mobile, packing may cause further displacement and worsen the bleeding. In these cases, urgent reduction and intermaxillary fixation or even ligation of the external carotid artery is required.[4,11,13] An alternative management strategy that increasingly is being used is transcatheter arterial embolization. The current literature is limited to case reports, but success rates of 87.5%–100% are reported when treating intractable hemorrhage in patients with maxillofacial trauma.[11,14,15]

Midface fractures that extend into the anterior cranial base put patients at risk for CSF leak. The leak most commonly occurs at the cribriform plate of the ethmoid bone, associated with nasoorbitoethmoid fractures or LeFort fractures.[13] Detection of CSF rhinorrhea or otorrhea is not always simple when the presence of blood obscures other fluids; therefore, a high level of suspicion and a careful examination are critical. A simple procedure for detection of CSF is the "halo" test. CSF separates from blood when it is placed on filter paper, resulting in a central area of blood with an outer ring or halo. However, this sign does not clinch the diagnosis, because water, saline, and nasal secretions also will produce a halo when mixed with blood.[16] Analysis of the fluid's glucose content (using glucose oxidase paper) is another common test, but it is extremely unreliable because nasal secretions contain reducing substances that will produce a false-positive result. The current "gold standard" for identification of CSF is the β-2 transferrin assay.[17-19] If CSF rhinorrhea is confirmed (or highly suspected), a neurosurgical consultation is warranted, as surgical repair of the dura may be required.[18,20] Once the diagnosis is made, the biggest management issue facing the emergency physician is the use of prophylactic antibiotics. The reported incidence of meningitis varies widely, from 0%–50%,[13,19-21] and the ability of prophylactic antibiotics to convey benefit to the patient is debatable. Some studies documented lower rates of meningitis if antibiotics were given,[20] but most published reports do not support their use.[19,22] In fact, some studies actually showed a *higher* incidence of meningitis when patients received prophylactic antibiotics.[21,23] The decision should be discussed with the neurosurgeons if possible, as they will be providing definitive management.

Nasoorbital ethmoid complex fractures typically occur after significant force to the bridge of the nose. The medial canthal ligaments usually are disrupted, resulting in traumatic telecanthus (widening of the intercanthal distance). This gives the patient the appearance of having wide-set eyes and results in a significant cosmetic deformity if it is not repaired. Because these fractures often extend through the cribriform plate, examine the patient for CSF leak and anosmia. If a CSF leak is present, management is similar to that for LeFort fractures as discussed above.[6,7]

Orbital Fractures

Orbital fractures may be isolated or part of other injury complexes, such as nasoorbital ethmoid, orbitozygomatic, and LeFort III fractures. In one series of soldiers with 1,142 blowout fractures, other facial fractures occurred in 50.9% and ocular injuries were found in 29.8%.[8] Because of the high incidence of ocular injuries among patients with orbital fractures, a complete eye examination is mandatory. Isolated fractures that involve the orbital floor or medial wall are referred to as "blowout fractures." The mechanism is usually a direct blow to the orbit or globe leading to sudden pressure elevation and disruption of the weakest part of the orbit. Patients usually have periorbital edema and ecchymosis and subconjunctival hemorrhage and may complain of diplopia, cheek numbness (relationship to infraorbital nerve), and swelling that worsened after they blew their nose. Extraocular movements should be tested carefully. Restriction of superior gaze is the most common finding and usually indicates entrapment of the inferior rectus muscle. Enophthalmos usually is not seen until the swelling has decreased. The presence of exophthalmos should raise concern for retrobulbar hematoma, a true emergency.[7,24]

The ED management of most orbital fractures involves making the diagnosis, making appropriate surgical referral, and providing good discharge instructions. Most of these fractures are repaired 7–10 days later if the patient has persistent diplopia or enophthalmos. Patients should be discharged with sinus precautions and advised not to drive until the diplopia has resolved.[7] However, two conditions associated with orbital fractures mandate immediate intervention and consultation by a surgeon in the ED—muscle entrapment and retrobulbar hematoma.

If an extraocular muscle becomes entrapped by tissue edema, immediate operative repair may not be necessary. Orbital floor fractures that lie in a longitudinal anterior-posterior direction can result in a hinged "trapdoor" phenomenon that traps the soft tissues and can cause muscle necrosis. The fracture itself, as well as the amount of tissue herniation, may not be very impressive on CT scan, so the clinical examination is key in this diagnosis. If there is any question of entrapment in an unresponsive patient, a forced duction test should be performed.[25] The distinction between these two types of fractures should be made in conjunction with a facial surgeon, since the first is relatively benign while the other can lead to permanent paresis.

Retrobulbar hematoma is a vision-threatening emergency. A small amount of blood behind the eye can significantly increase the pressure in this small space with bony walls, causing ischemia and death of the optic nerve. Patients may have exophthalmos, visual loss, an afferent pupillary defect, extraocular movement restriction, and increased intraocular pressure. This is a clinical diagnosis, and although it can be seen on CT scan, imaging should never delay treatment. Urgent decompression with lateral canthotomy can be vision saving. Medical treatment with topical β-blockers, intravenous (IV) mannitol, or IV carbonic anhydrase inhibitor can be used as an adjunct to decrease intraocular pressure but should not delay or substitute for surgical treatment (lateral canthotomy).[24,26,27] The patient should be referred urgently to an ophthalmologist to perform if possible, but this procedure is within the scope of the emergency physician.

Mandibular Fractures

Mandibular fractures are one of the most common facial fractures despite the significant force required to fracture the jaw. The most common cause of mandibular fracture is blunt force, usually a result of assault, MVCs, falls, and sports incidents. Pathologic fractures also can occur in the mandible. Penetrating injuries resulting in mandibular fracture usually are caused by shootings.

The common teaching is that mandibular fractures are multifocal. This is based on the understanding that the mandible is a closed ring-like structure, so compromise to a single aspect of the structure must be paralleled by compromise to the opposing side. However, recent research by Escott and Branstetter found that up to 42% of mandibular fractures occur as an isolated fracture to one side of the structure; the majority of unifocal fractures were minimally displaced simple fractures.[28] The multiple types of mandibular fractures are classified primarily based on their anatomic location but also on characteristics common to all fractures, including the degree of angulation and complexity of the fracture itself (open vs. closed and simple vs. comminuted). The majority of fractures involve the condyle, angle, or symphysis of the mandible.

A patient with an isolated mandibular fracture, like many fractures, has pain and swelling at the site of injury, usually caused by a traumatic event. Bleeding from lacerations, ecchymosis, or edema may cause asymmetry of the face. In the presence of multiple fractures, swelling of the whole lower face can produce generalized deformity. Many patients with these injuries are unable to open their mouth more than 5 cm and may have significant malocclusion of the teeth. The teeth may be loose or missing, and lacerations may be present inside or outside the mouth. Special attention should be paid to intraoral lacerations, because they may indicate an open fracture of the mandible or suggest an injury to Wharton's duct (the submandibular duct) or Stensen's duct (which drains the parotid gland into the mouth). The opening of Stensen's duct in the mouth lies adjacent to the second upper molar. Evaluate the duct by compressing the parotid gland externally while looking at the duct's outlet in the mouth. If blood is expressed from the duct, consultation for surgical repair is required to

Figure 2. Mandibular Fracture

Figure 3. Mandibular Fracture

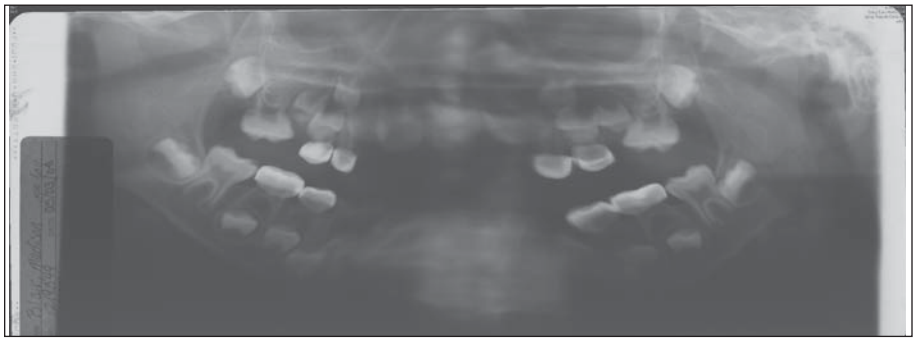

prevent fistula formation.

In the past, plain radiographs were the diagnostic test used most commonly to assess mandibular fractures; however, it is nearly impossible to visualize the entire mandible on plain film. Today, a panorex or panoramic radiograph, allows accurate identification of fractures of the mandible, teeth, and alveolar ridge. (*See Figures 2 and 3.*) CT scans also are highly accurate for the diagnosis of fractures and may be more beneficial in the setting of multiple facial injuries.

The alveolar ridge of the mandible contains the dental sockets. Fractures of this ridge must be diagnosed in a timely manner, as they are considered open fractures, with a significantly increased risk of infection and complication. Additional information about alveolar fractures is presented in the section on dental trauma.

As for all trauma patients, management of the airway and other life-threatening injuries precedes diagnosis and treatment of facial fractures. Repair of a mandibular fracture can be deferred until the patient is stable and all other significant injuries have been treated sufficiently.

When a mandibular fracture is identified, pain management should be employed for the patient's comfort and to facilitate a thorough oral examination. Consultation with an oral or plastic surgeon should be requested, because reduction of the fracture will be necessary. The emergency physician should contact treatment centers on controlling pain and obtain proper radiographic studies in preparation for consultation.

The stability of the fracture can determine the need for urgent or delayed follow-up. The emergency physician should be able to recognize the difference and formulate a disposition based on this information. Open fractures and unstable fractures of any kind require evaluation by a consultant in addition to antibiotics and likely inpatient hospitalization for definitive treatment. Fractures of the mandible that are closed in nature can be stable or unstable depending on the direction of the fracture line. Downward running fractures from posterior to anterior typically are stable, given the location of the musculature that helps pull the body together across the fracture line. Fractures that run downward from the anterior to posterior of the mandibular body are considered unstable because the musculature causes stress and displacement of the fracture. Edentulous patients with mandibular fractures are considered unstable, unless the patient has dentures that continue to fit comfortably. The dentures act as a splint, stabilizing the fracture until further treatment can be obtained. Any patients who are deemed to have an isolated stable, closed fracture can be discharged home safely with outpatient follow-up. These patients should be given pain control in the form of nonsteroidal anti-inflammatory drugs and a short course of narcotics if appropriate. Antibiotics are not necessary. Patients should be encouraged to adhere to a soft or pureed diet until further evaluation.

Most mandibular fractures are managed surgically with one of two options. Open reduction and fixation, involving the use of plates and screws, is undertaken in the operating room. Mandibulomaxillary fixation and closed reduction ("wiring the jaw") is used when open reduction is not an option or when a simple minimally displaced fracture is being treated. The choice is influenced by the patient's disposition and the potential for complications. Follow-up is mandatory for patients who undergo definitive fixation to ensure the injury is healing properly.

Nasal Fractures

The nose consists of two bones that join to form a pyramid-like structure as well as cartilage and soft tissue. Its anterior location on the face places it at higher risk for injury. The nose often is injured in MVCs, sports incidents, falls, and assaults. The nasal bones are probably the most commonly fractured facial structure.[29]

Patients with nasal fractures typically present with pain, swelling, and deformity of the nose. Infraorbital ecchymosis is also a common finding. Epistaxis may or may not be present by the time the patient presents to the ED. Evaluate the septum thoroughly to look for a septal hematoma, which is associated with septal necrosis and ultimately a saddle-nose deformity if it is not treated appropriately. Evaluate the nasal passages for any evidence of open nasal or septal fracture; the presence of open fractures will alter management requiring antibiotics and evaluation by a consultant for open reduction of the fracture.

If an isolated nasal fracture is suspected, plain radiographs are sufficient for the diagnosis; however, if concern exists about the possibility of additional facial fractures, a CT scan of the facial bones is warranted. (*See Figure 4.*) It is important to exclude any involvement of the nasoorbitoethmoid complex. Most isolated nasal bone fractures are managed based on external appearance once the swelling has resolved and management at that time is dictated by a surgeon.

Initial management in the ED centers on symptom management. Epistaxis should be stopped using traditional techniques and pain should be controlled. If a septal hematoma is identified, incise it and remove the clot, then pack the nose anteriorly to prevent reaccumulation of the hematoma. Prescribe a course of antibiotics for anyone who receives nasal packing to prevent toxic shock syndrome and sinusitis. Antibiotics also are indicated in the presence of an open nasal bone fracture and should be aimed at

Figure 4. Nasal Fracture

treating organisms expected in the nasopharynx. If deformity (lateral or depressed) of the nose is obvious and severe, closed reduction may be necessary. Closed reduction was once the mainstay of treatment for most nasal fractures. Today, it remains common, but open reduction is more frequently employed. Open reduction is used to correct significant fracture and dislocation of the nasal bone and to close an open septum.

For most patients with nasal bone fractures, outpatient follow-up with a plastic surgeon 3 or 4 days following the injury is imperative. At that time, any swelling that obscured deformities will have subsided, so that the need for further repair can be assessed.[30]

Frontal Sinus Fractures

The frontal sinus bone consists of an anterior and a posterior table, one or both of which can be fractured. In actuality, fracture of this bone is uncommon because it is highly resilient. When frontal sinus fractures do occur, they can be complicated by CSF leak, increasing the risk for infection.

Patients with frontal sinus fractures tend to present with swelling, pain, ecchymosis, and deformity. They might have pain only with palpation of the frontal sinus. A step-off deformity may be detected. Rhinorrhea in these patients should be considered a CSF leak, and the need for further evaluation for a definitive diagnosis should be assumed.

CT scan is the primary radiographic technique used in the diagnosis. In most patients with facial trauma, more than one fracture is present, making plain radiographs inadequate and thus outdated. Thin CT cuts of the frontal sinus should be requested if a fracture is suspected.

Frontal sinus fractures are diagnosed and categorized based on location (anterior table, posterior table, or both) as well as the amount of displacement. Fractures of the anterior table are most common, followed by fracture of both tables; isolated fractures of the posterior table are relatively uncommon, accounting for < 6% of these injuries.[31] Fractures involving the posterior table increase the risk of CSF leak, because of the proximity of the dura and the risk of tear with fracture.

The repair of frontal sinus fractures typically is based on two factors: the degree of comminution or displacement and the presence of a CSF leak. A 1–2 mm displacement can be managed nonoperatively. Patients with a frontal sinus fracture who are stable enough for discharge should be made aware of the possibility of CSF leak and instructed to return to the ED for repeat evaluation if they suspect one. Greater than 2 mm displacement, significant comminution, or a CSF leak mandates consultation with a neurosurgeon for evaluation and possible surgical repair. Fractures with more than 2 mm displacement and without a CSF leak can be repaired electively in 7–10 days. Antibiotics are not necessary. If a CSF leak occurs before the repair, the patient should be reevaluated for possible hospital admission and antibiotics should be considered in consultation with a neurosurgeon. It is not uncommon for CSF leaks to resolve spontaneously in 5–7 days.

Patients rarely have isolated frontal bone fractures, and thus disposition often is obvious based on the extent of their other injuries. Perioperative antibiotics are a standard of care in hospitals. A recent study by Lauder et al found that additional antibiotics before or after the perioperative period do not change the rates of infection secondary to facial fractures. It was suggested, however, that the greater the severity and number of facial fractures, the higher the rates of infection, thus a likely benefit of using antibiotics outside the perioperative window.[32]

Ocular/Globe Trauma

In the setting of facial trauma, the globes and visual acuity should be evaluated carefully. The anatomy of the orbit is highly protective of the globe and often prevents globe injury, but orbital fractures are a common finding in patients with facial trauma. The injury that causes the most concern when facial trauma involves the region of the eye is globe rupture, which is typically the result of blunt trauma. The most common site of globe rupture is where the sclera is thinnest (at the insertion of the extraocular muscles, at the site of a previous injury, or in a surgical scar).[33] Pressure placed on the globe by a penetrating or blunt force causes tears within the sclera, defining "globe rupture."

An open globe, which is usually caused by a penetrating injury, requires emergent ophthalmologic intervention. This injury needs to be diagnosed rapidly, and the eye must be protected from further injury as soon as the diagnosis is made.

Patients with globe injuries will present with obvious injuries to the face and may have obvious trauma to the orbital region. Periorbital edema or ecchymosis may be present and may increase the difficulty of performing a good examination. Subconjunctival hemorrhage may be present as well, and the anterior chamber needs to be examined for hyphema and lens dislocation. The patient may have blurred vision or might not be able to see. He or she might describe a foreign body sensation. Of course, if the patient is unconscious, he or she will not be able to assist the emergency physician with the ophthalmic evaluation.

Evaluate the visual acuity in both eyes using a Snellen chart (use a bedside chart if necessary). Test the patient's extraocular movements; consider any deficit an indication of possible orbital fracture with muscle entrapment. Test the peripheral vision as well. The application of fluorescein in conjunction with a Wood's lamp or slit lamp can be used to diagnose a corneal abrasion or an open globe injury. Uptake of fluorescein in a given spot on the cornea indicates abrasion and a Seidel test can be performed to determine the possibility of open globe injury. A Seidel test is positive when fluorescein, applied to the site of suspected injury, streams down into a bright green pool, giving the appearance of a running waterfall.[34]

Measurement of intraocular pressures is imperative and can be done at the bedside with a Tono-Pen® tonometer. Elevated pressures in one or both eyes should cause concern and lead to an ophthalmology consult.

If a globe rupture or open globe injury is suspected at any point in the evaluation or actually is confirmed, no further examination should take place. An eye shield should be placed over the eye immediately, with care being taken to place *no* pressure on the globe. An immediate ophthalmology consult should be obtained. Globe rupture has a poor prognosis, but expeditious diagnosis and treatment can improve the patient's likelihood of retaining vision.[35]

Dental Trauma

Dental trauma is extremely common: One-fourth of the U.S. population has experienced injury to one or more of their permanent incisors.[36] The worldwide prevalence of dental trauma seen in the ED is high, estimated to affect 4%–10% of patients. The overwhelming majority of these patients are under 15 years of age.[36]

Dental trauma often accompanies facial fractures. While the fractures may demand more immediate treatment, documenting the dental trauma (and informing the patient of it) is imperative. One study of 273 patients with facial fractures examined the rate of coincident dental trauma. Among patients with fractures to non-tooth-bearing bones, 10% experienced dental trauma. For those with trauma to the mandible, that rate increased to 39%.[37] Another study found that 64% of patients with bilateral mandibular condylar fractures had damage to the dentition.[36]

A thorough assessment of dental trauma mandates cleaning all of the blood and debris away from the mouth. The easiest way to accomplish this is to have the patient swish and spit several times; local anesthesia or parenteral pain medication may be required. Exploring lacerations should include a careful search for foreign bodies, particularly fragments of broken teeth. Take note of areas of bleeding from the gum, which may indicate damage to the underlying bony structures. Assess the temporomandibular joint for range of motion, since limited mouth opening or asymmetry often indicates a fracture or dislocation. Any malocclusion calls for imaging to look for fracture. If the patient is missing a tooth, assume that it has been aspirated, swallowed, or impaled in the soft tissue.

Crown fractures are the most common injury to teeth, accounting for 65%–75% of all injuries to the permanent dentition. They range from enamel involvement only (Ellis class I), which usually causes minimal pain, to a fracture through the enamel, dentin, and pulp, which carries a much worse prognosis. If the fracture involves enamel and dentin only (Ellis class II), a temporary filling that covers the dentin generally does not affect whether or not the tooth will die, so emergent dental treatment is not necessary.[38] In contrast, if the pulp is exposed (Ellis class III), there is a much higher rate of healing (72%–100%) if the tooth is restored by a dentist within 3 hours.[36]

Root fractures are relatively rare. Treatment delays of up to several days have no influence on healing.[38]

Luxation injuries occur when a tooth is displaced from its socket. They can be intrusive (tooth pushed further into the jaw), extrusive (tooth pulled partially out of the jaw), or lateral. The injuries often involve fractures of the alveolar bone as well. When dealing with luxation injuries, the tooth should be repositioned into its anatomic location and splinted, if possible. However, clinical trials have not been able to demonstrate a benefit on healing between this method of treatment vs. no treatment.[38] Also, although antibiotics generally have been recommended to prevent bacterial invasion of the injured periodontium and pulp, some research suggests this treatment actually may have a negative impact on healing.[38]

Tooth avulsion injuries are rare (accounting for 0.5%–3% of all injuries affecting permanent teeth) but are among the injuries most likely to be seen in the ED. Minimizing extraoral time is the most important factor in healing. Immediate reimplantation by the patient leads to the highest success rate. While gross contamination of the root surface has been shown to increase root resorption, so has rinsing of the root surface. Antibiotics have not been shown to improve healing, but since this is an open fracture, the patient's tetanus status should be updated. When replanting the tooth, hold it by the crown, minimizing contact with the root (which could further damage the periodontal ligament). If a clot has formed in the socket, remove it only if it interferes with seating the tooth. The tooth should be pushed firmly into the socket (local anesthesia is usually required); once in place, have the patient bite onto a gauze roll. The patient should see a dentist that day and should be advised that even if the tooth reattaches, it almost certainly will require a root canal. Teeth that have been avulsed longer than 1 hour or have been stored dry have a very poor prognosis. Reimplantation can be considered on an individual basis, with the patient understanding that even with expensive and lengthy dental follow-up, there is a high chance that he or she will still lose the tooth. While no discussion of avulsed teeth would be complete without including the preferred transport mediums (in order of preference: Hank's balanced salt solution, saliva, saline, milk, water), this is generally a moot point once the patient is seen in the ED.[36,38-40]

Alveolar bone fractures occur in 5%–9% of all patients with dentoalveolar injuries and usually are associated with other injuries to the teeth.[36] If they involve only one tooth (typically seen in conjunction with a luxation injury), no additional immediate treatment usually is required other than prompt referral to a dentist. However, if the fracture is segmental (involving multiple teeth), an oral surgeon should be consulted while the patient is in the ED. Segmental fractures should be

Table 1. Laceration Repair Chart

	Suture, Size	Anesthesia or Block	Important points to remember
Face	Deep: 3-0 or 4-0 absorbable Superficial: 4-0 or 5-0 non-absorbable Skin glue	Dependent on location Blocks may be necessary only if wound distortion may complicate closure and cosmetic outcome Lidocaine with epinephrine	Consider using Langer's lines to ensure a good cosmetic outcome Only use skin glue for linear, small, and superficial lacerations that are NOT under tension
Eyelid or Eyebrow	Deep: 4-0 absorbable Superficial: 5-0 or 6-0 non-absorbable	Lower Lid: Infraorbital block Upper lid or eyebrow: Supraorbital block Lidocaine with epinephrine	Colored suture (blue or purple) within the eyebrow makes removal easier
Lip	Deep: 4-0 absorbable Superficial: 5-0 non-absorbable or Prolene	Upper lip: Infraorbital block Lower lip: Mental nerve block Lidocaine with epinephrine	Always align the vermilion border first Avoid using local infiltration anesthetic
Intraoral	Deep: 3-0 or 4-0 absorbable Superficial: 3-0 chromic gut	Buccal Mucosa: Long buccal block OR Local infiltration Lidocaine with epinephrine	Closure of wounds > 1-2 cm decreases risk of infection Antibacterial mouth rinse should be prescribed
Ear	Perichondrium: 4-0 or 5-0 absorbable Skin: 4-0 or 5-0 non-absorbable or Prolene	Pre-auricular block using lidocaine (NO epinephrine)	Align cartilage well, then suture over skin; pressure dressing is imperative to prevent hematoma
Scalp	Staples Deep or galea: 3-0 absorbable Superficial: 2-0 or 3-0 non-absorbable	Local infiltration Lidocaine with epinephrine	Shaving hair increases the risk of infection

For any laceration, always remember to update the tetanus if necessary!

suspected when multiple teeth move while one is checking the mobility of a single tooth. They should be confirmed by imaging. Dental x-ray films are certainly adequate; however, since they are not widely available in the ED, a panorex or CT scan is reasonable. Treatment usually involves a rigid splint.[36,39]

Lacerations/Burns

Many trauma patients sustain lacerations to the face and head. The primary goals of repair are wound healing, preventing infection, and achieving good functional and cosmetic outcomes. Cosmetic repair of lacerations to the eye, lip, and ear is of utmost importance, given the need to maintain symmetry. (*See Table 1.*) In the evaluation of how to repair a laceration for the best cosmetic appearance, use Langer's lines to determine if deep suturing is needed. Anatomically important structures are located close to the aforementioned parts and are easily damaged by trauma.

The head is an extremely vascular part of the body; therefore, injuries can result in substantial bleeding and unrecognized blood loss, making control of bleeding an important focus of initial treatment. All lacerations of the head and face should be anesthetized adequately to facilitate thorough irrigation and closure. Anesthesia can be induced in several ways, including nerve blocks and subcutaneous infiltration. Nerve blocks should be considered in situations in which subcutaneous injection of anesthesia may distort the tissue and compromise accurate approximation, as in the assessment and repair of lacerations involving the eyebrow or vermilion border of the lip. Some of the more commonly used nerve blocks in the face include the supraorbital, infraorbital, and submental blocks. These three blocks cover the majority of the face in different distributions and are easily performed. Lacerations close to the midline may require bilateral blocks as sensory fibers can, and do cross the midline. Irrigation should be done using standard techniques. The wound should be evaluated fully in a clean and bloodless field so that all foreign bodies can be identified and removed. Devitalized tissue should be debrided carefully, and the wound should be closed with sutures sized appropriately for the location of the wound. When required, deep sutures should be placed with absorbable suture material to prevent deformity of the area once healing and scar formation occur. Lacerations to the scalp are treated with proper irrigation and closure, often using staples, rather than sutures, for ease and expediency. Tissue adhesive can be used for lacerations on the face and usually are very effective in closing low tension, straight lacerations. All patients should be educated about

signs and symptoms of infection and instructed when to return for suture removal or a wound recheck.

Lacerations that involve the eye or eyelid or that are close to the lateral or medial canthus may need to be evaluated and closed by an ophthalmologist. The concern revolves around possible damage to the lacrimal apparatus. The lacrimal gland is located within the upper eyelid in the lateral position and has an excretory duct that empties into the superolateral eyelid. Comparatively, the lacrimal canals join in the medial canthus to form the nasolacrimal duct, which drains into the ipsilateral nare. Disruption of the lacrimal apparatus has several possible consequences, including dacryocystitis and ectropion formation, if it is not diagnosed and repaired properly. In most cases, isolated damage to the lacrimal apparatus can be repaired within 48 hours following the injury. Injuries secondary to animal bites should be evaluated immediately by an ophthalmologist, because they tend to be heavily contaminated wounds. These patients should be placed on antibiotics. Antibiotic choice should be based on the type of animal bite and whether the antibiotics are for prophylaxis (5 days) or to treat an active infection (14 days). Antibiotic choices include amoxicillin clavulanate, clindamycin, or doxycycline.

As mentioned above, lacerations that cross the upper or lower vermilion border present important and difficult wound repairs because of the cosmetic outcome. It is important that the margins of the vermilion border be approximated exactly, as misalignment of less than 1 mm is easily noticed once the laceration is healed. The nerve supply to the lower lip is through the mental nerve and to the upper lip through the infraorbital nerve, which can both be anesthetized using regional nerve block techniques.

Intraoral lacerations may not always require closure, because the mucosa heals very quickly and very well on its own. There are two specific indications in which an intraoral laceration should be closed: 1) if the laceration exceeds 1 or 2 cm, increasing the likelihood that food particles may be entrapped and become a nidus for infection, and 2) if the laceration interferes with the patient's ability to chew. All teeth should be evaluated for stability and injury. The oral cavity, especially any intraoral lacerations, should be examined for pieces of broken tooth. Wounds within the mouth potentially are exposed to significant contamination, which makes proper irrigation essential. Intraoral lacerations may require deep suturing with 4-0 or 5-0 absorbable sutures. The superficial laceration can be closed using absorbable sutures as well. The use of prophylactic antibiotics is controversial and has not been sufficiently studied to allow a definite conclusion to be made. The limited evidence suggests antibiotics may be of benefit for some oral lacerations.[41] Through-and-through lacerations are considered higher risk for infection, so some clinicians prescribe antibiotics. If a wound is particularly contaminated or has been caused by an animal, antibiotics are appropriate.[42] Otherwise, antibiotics are not necessary. A simple oral antibiotic rinse (e.g., Peridex) is beneficial and can be prescribed if desired.

Lacerations to the ear pose a potentially difficult situation. Repair of these lacerations is challenging because of the anatomy. The stiff nature and deep grooves present a complex suturing surface. Specific attention to detail is required to ensure a good cosmetic outcome and long-term survival of the tissue. The shape of the ear and the presence of a symmetric partner make a good cosmetic outcome crucial. Being a primarily cartilaginous structure, the ear is avascular in nature, which can complicate tissue survival if a wound is not repaired correctly.

Lacerations to the ear should be irrigated in a standard fashion, with special effort made to not over-irrigate or to irrigate too forcefully, which could devitalize and damage the perichondrium. Approximation of the cartilage is imperative for healing and must be done well prior to closure of the skin. Although suturing of the cartilage is not necessary (assuming good approximation occurs), it can be helpful in the repair process. If the cartilage is sutured, 4-0 or 5-0 absorbable sutures should be used. Once the cartilage has been approximated adequately, closure of the skin finishes the repair. If significant cartilage or skin loss prevents closure with a good cosmetic outcome, surgical consultation should be sought. After repair, vaseline gauze can be used over the sutures and within the crevices of the ear. Apply a pressure dressing to prevent continued bleeding and hematoma formation, which would compromise the ear's minimal vascular supply. A gauze dressing can be placed between the ear and the scalp to prevent pressure necrosis.[43]

Facial Burns

The American Burn Association estimates that approximately 500,000 people seek medical treatment for burn injuries each year and that approximately 40,000 of them are admitted to the hospital as a result of their injuries.[44] More than half of those admitted are treated in burn centers across the country.

Facial burns are serious injuries and are commonly present in conjunction with burns of other areas of the body. Fortunately, the majority of patients who present to emergency departments for treatment of burns have superficial wounds affecting a small percentage of total body surface area (TBSA).

Burns are categorized based on the cause (e.g., thermal, electrical, fire) and then further classified based on depth (superficial thickness, partial thickness, or deep) and the layers of tissue that are involved. TBSA can be estimated quickly using the Rule of 9s. Fluid resuscitation with lactated Ringer's solution should be initiated immediately and is based on the TBSA burned. The most commonly accepted formula for calculating fluid requirement is the Parkland formula.

Inhalation injuries should be one of the initial concerns in a patient who has facial burns. The presence

of stridor, wheezing, soot in the airway, or singeing of the eyelashes, brows, or hair should prompt the physician to assume early control of the airway.[45]

Carbon monoxide (CO) and cyanide poisoning also should be early concerns. The carboxyhemoglobin level should be measured. Treatment is based on symptoms (including headache, vomiting, and mental status), ECG findings, and CO level; however, all burn patients with or without suspected CO poisoning should receive 100% oxygen. Treatment for cyanide poisoning should be initiated empirically if a patient has unexplained metabolic acidosis, a normal CO level, and an elevated venous oxygen level.[46]

Patients who have significant burns (> 10%–20% of TBSA) or airway involvement should be stabilized and transferred to the closest burn center for further treatment. If transfer to a burn unit is imminent, wrapping the patient in a clean, dry sheet is all that is necessary. If transfer is delayed, wound care should be initiated. First, clean the wounds with sterile saline; then, using sterile technique, debride all blisters, except those on the palms of the hands and soles of the feet. A topical antibiotic dressing should be applied.[46]

All patients who have sustained a burn injury, regardless of percentage of TBSA involved or depth of the burn, should receive a tetanus booster, cleaning, debridement of any blisters, and dressing of the burn with antibiotic ointment. Close follow-up for the development of complications is important.[47]

The decision to admit a burned patient to the hospital is based on recommendations by the American Burn Association. Any adult who sustains partial-thickness burns over 10%–20% of TBSA, any child younger than 10 years old with partial-thickness burns covering 5%–10% of TBSA, or any partial- or full-thickness burns to the face, genitalia, hands, feet, or crossing any major joints should be transferred immediately to a burn center for evaluation and treatment.

Conclusion

Facial trauma is a common complaint in the emergency department, and management can be challenging. As with any trauma patient, the initial priority is always the ABCs, with particular attention to airway, major bleeding, and associated brain injury. It is important to remember that although the facial injuries may be the most obvious, these patients often have concomitant injuries. Once initial stabilization has occurred, a thorough, systematic examination will guide the remainder of evaluation and management. Given the highly visible nature of these injuries, special attention must be paid to the cosmetic repair techniques. Surgical consultation may be required for many of these patients. Most facial trauma is not life-threatening, although significant morbidity is possible. Careful examination, judicious imaging, and appropriate consultation will ensure the best outcomes for these patients.

References

1. Parsa T, et al. Inital evaluation and management of maxillofacial injuries. *eMedicine* 2010.
2. Thoren H, et al. Occurrence and types of associated injuries in patients with fractures of the facial bones. *J Oral Maxillofac Surg* 2010;68:805-810.
3. Ceallaigh PO, et al. Diagnosis and management of common maxillofacial injuries in the emergency department. Part 1: Advanced trauma life support. *Emerg Med J* 2006;23:796-797.
4. Lynham AJ, et al. Emergency department management of maxillofacial trauma. *Emerg Med Australas* 2004;16:7-12.
5. Elahi MM, et al. Cervical spine injury in association with craniomaxillofacial fractures. *Plast Reconstr Surg* 2008;121: 201-208.
6. Tucker M. Management of facial fractures. In: Peterson L, ed. *Oral & Maxillofacial Surgery*. 3rd ed. St. Louis: Mosby; 1998.
7. McKay MM. Facial trauma. In: Marx JA, ed. *Rosen's Emergency Medicine: Concepts & Clinical Practice*. 7th ed. Philadelphia: Mosby Elsevier; 2009.
8. Shere JL, et al. An analysis of 3599 midfacial and 1141 orbital blowout fractures among 4426 United States Army Soldiers, 1980-2000. *Otolaryngol Head Neck Surg* 2004;130:164-170.
9. Ceallaigh PO, et al. Diagnosis and management of common maxillofacial injuries in the emergency department. Part 3: Orbitozygomatic complex and zygomatic arch fractures. *Emerg Med J* 2007;24: 120-122.
10. Ceallaigh PO, et al. Diagnosis and management of common maxillofacial injuries in the emergency department. Part 4: Orbital floor and midface fractures. *Emerg Med J* 2007;24:292-293.
11. Wu SC, et al. Angioembolization as an effective alternative for hemostasis in intractable life-threatening maxillofacial trauma hemorrhage: Case study. *Am J Emerg Med* 2007;25:988.e1-5.
12. Ardekian L, et al. Life-threatening complications and irreversible damage following maxillofacial trauma. *Injury* 1998;29:253-256.
13. Ellis E 3rd, Scott K. Assessment of patients with facial fractures. *Emerg Med Clin North Am* 2000;18:411-448.
14. Cogbill TH, et al. Management of maxillofacial injuries with severe oronasal hemorrhage: A multicenter perspective. *J Trauma* 2008;65:994-999.
15. Liu WH, et al. Transarterial embolization in the management of life-threatening hemorrhage after maxillofacial trauma: A case report and review of literature. *Am J Emerg Med* 2008;26:516.e513-e515.
16. Dula DJ, Fales W. The 'ring sign': Is it a reliable indicator for cerebral spinal fluid? *Ann Emerg Med* 1993;22:718-720.
17. Welch KC SJ. CSF Rhinorrhea. *EMedicine* 2009.
18. Abuabara A. Cerebrospinal fluid rhinorrhoea: Diagnosis and management. *Med Oral Patol Oral Cir Bucal* 2007;12:E397-E400.
19. Bell RB, et al. Management of cerebrospinal fluid leak associated with craniomaxillofacial trauma. *J Oral Maxillofac Surg* 2004;62:676-684.
20. Friedman JA, et al. Post-traumatic cerebrospinal fluid leakage. *World J Surg* 2001;25:1062-1066.
21. Choi D, Spann R. Traumatic cerebrospinal fluid leakage: Risk factors and the use of prophylactic antibiotics. *Br J Neurosurg* 1996;10:571-575.
22. Daudia A, et al. Risk of meningitis with cerebrospinal fluid rhinorrhea. *Ann Otol Rhinol Laryngol* 2007;116:902-905.
23. Clemenza JW, et al. Craniofacial trauma and cerebrospinal fluid leakage: A retrospective clinical study. *J Oral Maxillofac Surg* 1995;53:1004-1007.
24. Bord SP, Linden J. Trauma to the globe and orbit. *Emerg Med Clin North Am* 2008;26:97-123.
25. Mathur N. Orbital Fractures. *eMedicine* 2009.
26. Shek KC, et al. Acute retrobulbar haemorrhage: An ophthalmic emergency. *Emerg Med Australas* 2006;18:299-301.
27. Winterton JV, et al. Review of management options for a retrobulbar hemorrhage. *J Oral Maxillofac Surg* 2007;65:296-299.
28. Escott EJ, Branstetter BF. Incidence and characterization of unifocal mandible fractures on CT. *AJNR Am J Neuroradiol* 2008;29:890-894.
29. Hwang K, et al. Outcome analysis of sports-related multiple facial fractures. *J Craniofac Surg* 2009;20:825-829.
30. Mondin V, et al. Management of nasal bone fractures. *Am J Otolaryngol* 2005;26:181-185.
31. Tollefson TT, Strong EB. Frontal Sinus Fractures. *eMedicine* 2009.

32. Lauder A, et al. Antibiotic prophylaxis in the management of complex midface and frontal sinus trauma. *Larygoscope* 2010;120:1940-1945.
33. Golden D. Globe rupture. In: Marx JA, ed. *Rosen's Emergency Medicine: Concepts & Clinical Practice*. 6th ed. Philadelphia: Mosby Elsevier; 2008.
34. Pokhrel PK, Loftus SA. Ocular emergencies. *Am Fam Physician* 2007;76: 829-836.
35. Kuhn F. Ocular traumatology and the ocular trauma specialist. *Graefes Arch Clin Exp Ophthalmol* 2008;246:169-174.
36. Dale RA. Dentoalveolar trauma. *Emerg Med Clin North Am* 2000;18:521-538.
37. Lieger O, et al. Dental injuries in association with facial fractures. *J Oral Maxillofac Surg* 2009;67:1680-1684.
38. Andreasen JO, et al. Contradictions in the treatment of traumatic dental injuries and ways to proceed in dental trauma research. *Dent Traumatol* 2010;26:16-22.
39. Ceallaigh PO, et al. Diagnosis and management of common maxillofacial injuries in the emergency department. Part 5: Dentoalveolar injuries. *Emerg Med J* 2007;24:429-430.
40. Flores MT, et al. Guidelines for the management of traumatic dental injuries. II. Avulsion of permanent teeth. *Dent Traumatol* 2007;23:130-136.
41. Steele MT, et al. Prophylactic penicillin for intraoral wounds. *Ann Emerg Med* 1989;18:847-52
42. Mark DG, Granquist EJ. Are prophylactic oral antibiotics indicated for the treatment of intraoral wounds? *Ann Emerg Med* 2008;52:368-372.
43. Brown DJ, et al. Advanced laceration management. *Emerg Med Clin North Am* 2007;25:83-99.
44. 2007 Fact Sheet. American Burn Association. Available at: www.ameriburn.org/resources_factsheet.php. Accessed August 26, 2010.
45. Griffin JE, Johnson DL. Management of the maxillofacial burn patient: Current therapy. *J Oral Maxillofac Surg* 2005;63:247-252.
46. Singer AJ, et al. Thermal burns. In: Marx JA, ed. *Rosen's Emergency Medicine: Concepts & Clinical Practice*. 7th ed. Philadelphia: Mosby Elsevier; 2009.
47. Gomez R, Cancio LC. Management of burn wounds in the emergency department. *Emerg Med Clin North Am* 2007;25:135-146.

CME Questions

1. Which of the following regarding zygomaticomaxillary complex fractures is correct?
   A. They rarely lead to a cosmetic deformity if untreated.
   B. They may cause difficulty with mouth opening.
   C. Injury to the facial nerve occurs frequently.
   D. Surgery generally needs to be done the same day as the injury.

2. Which of the following statements is **true**?
   A. A LeFort I fracture is a total disarticulation of the midface.
   B. A LeFort III fracture is a horizontal fracture of the maxilla only.
   C. LeFort fractures cannot be unilateral.
   D. CSF leak may complicate a LeFort I fracture.
   E. Raccoon eyes and Battle's sign may be seen with LeFort fractures.

3. Facial fractures often cause bleeding. Which of the following is **true**?
   A. Life-threatening bleeding usually is attributable to the superior labial artery.
   B. Life-threatening bleeding usually can be managed easily by the emergency physician by simply tying off the damaged vessel.
   C. Anterior nasal packing generally is sufficient to control severe bleeding related to midface fractures.
   D. If maxillary mobility is present, nasal packing may worsen bleeding by further disrupting the damaged vessel.
   E. Transcatheter arterial embolization has no role in the management of bleeding related to facial fractures.

4. Cerebrospinal fluid (CSF) leaks may complicate facial fractures. Which of the following is **true**?
   A. CSF rhinorrhea is quite obvious and easily diagnosed when present.
   B. The "halo" test is highly specific for CSF.
   C. The glucose oxidase test is the gold standard for diagnosing CSF leaks.
   D. The β-2 transferrin assay is the gold standard for diagnosing CSF leaks.

5. Which of the following statements regarding patients with orbital fractures is **true**?
   A. Orbital fractures that involve the superior wall are termed "blowout" fractures.
   B. Most orbital fractures can be repaired 7-10 days after the initial injury.
   C. Ocular injuries are extremely rare in patients with orbital fractures.
   D. Presence of enophthalmos may indicate retrobulbar hematoma.

6. Which of the following statements regarding mandibular fractures is **true**?
   A. Most mandibular fractures are caused by penetrating trauma.
   B. Most mandibular fractures are unifocal.
   C. Most mandibular fractures are multifocal.
   D. Trismus rarely occurs in patients with mandibular fractures.

7. In the setting of frontal sinus fractures, patients are at risk for _____ .
   A. post-nasal drip.
   B. tear duct leak.
   C. CSF leak.
   D. aqeuous humor leak.

8. Which of the following statements is **true**?
   A. Dental trauma is an extremely infrequent complaint in the ED.
   B. Avulsed teeth frequently can be reimplanted successfully up to 24 hours.
   C. Root fractures are the most common dental injury.
   D. Luxation injuries occur when a tooth is displaced from its socket.

9. Healed lacerations through the vermilion border can be noticed with less than ____ of misalignment.
   A. 0.5 mm
   B. 2 mm
   C. 1 mm
   D. 4 mm

10. What is the most commonly used formula for determining fluid resuscitation volume in a burn patient?
   A. Henderson Hasselbach Equation
   B. Winter's Formula
   C. Indeterminate Equation
   D. Parkland Formula

CNE/CME Objectives

Upon completing this program, the participants will be able to:
a.) discuss conditions that should increase suspicion for traumatic injuries;
b.) describe the various modalities used to identify different traumatic conditions;
c.) cite methods of quickly stabilizing and managing patients; and
d.) identify possible complications that may occur with traumatic injuries.

CNE/CME Instructions

Physicians and nurses participate in this continuing medical education/continuing education program by reading the article, using the provided references for further research, and studying the questions at the end of the article. Participants should select what they believe to be the correct answers, then refer to the list of correct answers to evaluate their knowledge. To clarify confusion surrounding any questions answered incorrectly, please consult the source material. *After completing this activity, you must complete the evaluation form that will be provided at the end of the semester and return it in the reply envelope provided to receive a credit letter.* When your evaluation is received, a credit letter will be mailed to you.

Answers: 1. B, 2. E, 3. D, 4. D, 5. B, 6. C, 7. C, 8. D, 9. C, 10. D.

Trauma Reports™ (ISSN 1531-1082) is published bimonthly by AHC Media, a division of Thompson Media Group, LLC, 3525 Piedmont Road, N.E., Six Piedmont Center, Suite 400, Atlanta, GA 30305. Telephone: (800) 688-2421 or (404) 262-7436.

Vice President / Group Publisher: Donald R. Johnston
Executive Editor: Coles McKagen
Managing Editor: Leslie Coplin

POSTMASTER: Send address changes to Trauma Reports,
P.O. Box 740059, Atlanta, GA 30374.

Subscriber Information

Customer Service: 1-800-688-2421

Customer Service E-Mail:
customerservice@ahcmedia.com

Editorial E-Mail:
leslie.coplin@ahcmedia.com

World Wide Web page:
http://www.ahcmedia.com

FREE to subscribers of *Emergency Medicine Reports* and *Pediatric Emergency Medicine Reports*

Subscription Prices

United States

$249 per year. Add $17.95 for shipping & handling

Multiple Copies

Discounts are available for group subscriptions, multiple copies, site-licenses or electronic distribution. For pricing information, call Tria Kreutzer at 404-262-5482.

All prices U.S. only. U.S. possessions and Canada, add $30 postage plus applicable GST.

Other international orders, add $30.

Accreditation

AHC Media is accredited by the Accreditation Council for Continuing Medical Education to provide continuing medical education for physicians.

AHC Media designates this educational activity for a maximum of 2.5 *AMA PRA Category 1 Credits*™. Physicians should only claim credit commensurate with the extent of their participation in the activity.

Approved by the American College of Emergency Physicians for a maximum of 2.5 hours of ACEP Category 1 credit.

AHC Media is accredited as a provider of continuing nursing education by the American Nurses Credentialing Center's Commission on Accreditation.

This activity has been approved for 1.5 nursing contact hours using a 60-minute contact hour.

Provider approved by the California Board of Registered Nursing, Provider # 14749, for 1.5 Contact Hours.

This is an educational publication designed to present scientific information and opinion to health professionals, to stimulate thought, and further investigation. It does not provide advice regarding medical diagnosis or treatment for any individual case. It is not intended for use by the layman. Opinions expressed are not necessarily those of this publication. Mention of products or services does not constitute endorsement. Clinical, legal, tax, and other comments are offered for general guidance only; professional counsel should be sought for specific situations.

This CME/CNE activity is intended for emergency, family, osteopathic, trauma, surgical, and general practice physicians and nurses who have contact with trauma patients.

It is in effect for 24 months from the date of publication.

In Future Issues | **Amputations**