Trauma Reports

EVIDENCE-BASED MEDICINE FOR THE ED

Volume 14, Number 3 **May/June 2013**

Authors:

Ashika Jain, MD, RDMS, Assistant Professor, Trauma Critical Care, Emergency Ultrasound, Director, Critical Care Ultrasound, Department of Emergency Medicine, Kings County Hospital Center, SUNY Downstate Medical Center, Brooklyn, NY.

Jay Menaker, MD, Associate Professor, Department of Surgery, Associate Professor, Department of Emergency Medicine, University of Maryland School of Medicine, Baltimore; Physician Director of Quality Management, R Adams Cowley Shock Trauma Center, Baltimore, MD.

Peer Reviewer:

Perry W. Stafford, MD, FACS, FAAP, FCCM, Professor of Surgery, UMDNJ Robert Wood Johnson Medical School, New Brunswick, NJ.

Statement of Financial Disclosure

To reveal any potential bias in this publication, and in accordance with Accreditation Council for Continuing Medical Education guidelines, we disclose that Dr. Dietrich (editor in chief), Dr. Jain (author), Dr. Menaker (author), Dr. Stafford (peer reviewer), and Ms. Behrens (nurse reviewer) report no relationships with companies related to this field of study. Ms. Mark (executive editor), and Ms. Hamlin (managing editor) report no relationships with companies related to the field of study covered by this CME activity.

AHC Media

Ultrasound for Trauma

Traumatic injury remains one of the most important and persistent causes for morbidity and mortality in the United States. The establishment of a trauma team that is available to evaluate and manage trauma quickly and efficiently during the very critical first minutes after the injured patient arrives at the hospital has significantly improved survival and dramatically reduced sequelae from these injuries. An important component of this expedited evaluation has been the recognition of the utility of ultrasound to augment the imaging and triage of the injured patient. In this well-researched monograph, the authors describe this rapidly growing modality and its many applications. All members of the trauma team should be familiar with the indications and limitations of this important trauma tool.

— Ann M. Dietrich, MD, Editor

Introduction

Injury-related visits to the emergency department (ED) account for 34.2% of all visits.[1] Rapid evaluation, management, and disposition are important steps in ED throughput. Bedside ultrasonography has rapidly changed the timeline to ultimate disposition, whether it is to the operating room, the floor, or home. The ability to confidently and noninvasively evaluate a trauma patient at the bedside has revolutionized the algorithm for initial examination, diagnostic evaluation, and management.

As ultrasound has gained importance in the initial evaluation of the trauma patient and made its presence at the bedside routine, the applications for utilization have expanded and now include line placement, vascular injury evaluation, fracture diagnosis, and expansion of the original Focused Assessment with Sonography for Trauma (FAST) exam to include the thorax.

As a bedside adjunct with immediate results, the ultrasound machine has become a vital tool for the evaluation of the trauma patient. A FAST exam can be performed during the primary survey, making the diagnosis of free fluid in the peritoneum, pericardium, or thorax instantaneous. In a patient with unstable vital signs, the information gained from the FAST exam can decrease time to definitive management and improve efficiency and time to the operating room.[2-4] Furthermore, localizing the free fluid can help to direct the operative management. For example, lack of fluid in the abdomen with a fluid strip in the pericardium may assist with operative approaches. Not only is the time to the operating room decreased, but time to injury control/repair is decreased by early and efficient evaluation. Bedside ultrasound is noninvasive and reduces the need for diagnostic peritoneal lavage (DPL), and can be integrated into the primary and secondary survey as well as be repeated as needed. Additionally, it is safe in children and pregnant patients, as it has a significantly lower radiation profile than other imaging techniques.

History

Ultrasound found its place in science in the 1820s when Jean-Daniel Colladon, a Swiss physicist, successfully used an underwater bell to determine

Executive Summary

- The traditional FAST exam allows for a rapid evaluation of hemoperitoneum and hemopericardium.
- The traditional FAST exam has four views: the subxiphoid view, looking at the pericardium; the right upper quadrant view, looking at Morison's pouch and the right paracolic gutter; the left upper quadrant, looking at the splenorenal interface and the left paracolic gutter; and the suprapubic view, looking at the intraperitoneal pelvic space.
- Contrast-enhanced sonography does not identify solid-organ injuries with high enough sensitivity to replace CT scans in the complete evaluation of blunt trauma injuries.
- A negative FAST examination does not exclude abdominal injury, such as a diaphragm or hollow viscus injury, and further investigation or serial exams are required.

the speed of sound in the waters of Lake Geneva.[5] However, it wasn't until 1942 that doctor Karl Theodore Dussik of Austria published the first medical paper on ultrasonics describing his research on transmission ultrasound investigation of the brain. Since then, the utilization of ultrasound in medicine has grown tremendously. In Europe in the 1970s, ultrasound was recognized as a noninvasive, rapid, safe, accurate, and repeatable bedside assessment tool and was included in the trauma evaluation. Eventually, ultrasound made its way to America in the 1990s, displacing DPL as the initial diagnostic test in a trauma patient.[6,7] The use of ultrasound for trauma has continued to expand and includes diagnosis and management of thoracic trauma and serves as a valuable adjunct for vascular access. This issue of *Trauma Reports* will review some of the old applications as well as many of the new applications for ultrasound.

Figure 1. Normal FAST Exam, Subxiphoid View

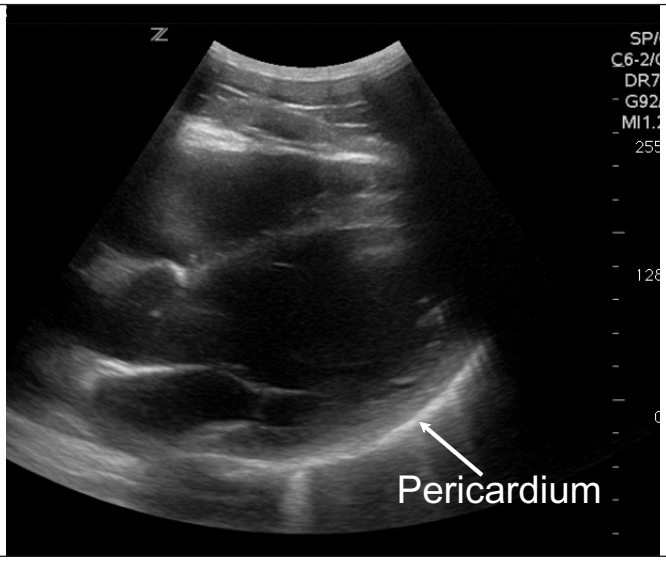

Table 1. FAST Exam

The traditional FAST exam has four views:
- **Subxiphoid view, looking at the pericardium**
- **Right upper quadrant view, looking at Morison's pouch and the right paracolic gutter**
- **Left upper quadrant view, looking at the splenorenal interface and the left paracolic gutter**
- **Suprapubic view, looking at the intraperitoneal pelvic space**

Focused Assessment with Sonography for Trauma

The traditional FAST exam allows for a rapid evaluation of hemoperitoneum and hemopericardium. The test can be performed quickly at the patient's bedside and does not require moving the patient from the resuscitation bay or emergency department. Additionally, it can be repeated rapidly and easily as needed, especially when vital signs change. The traditional FAST exam has four views: the subxiphoid view, looking at the pericardium; the right upper quadrant view, looking at Morison's pouch and the right paracolic gutter; the left upper quadrant, looking at the splenorenal interface and the left paracolic gutter; and the suprapubic view, looking at the intraperitoneal pelvic space. (*See Figures 1-5, normal FAST exam.*)

While at the bedside, the probe of choice is one that allows for evaluation of deep structures while maintaining optimum resolution. The

Figures 2-3. Normal FAST Exam, Right Upper Quadrant

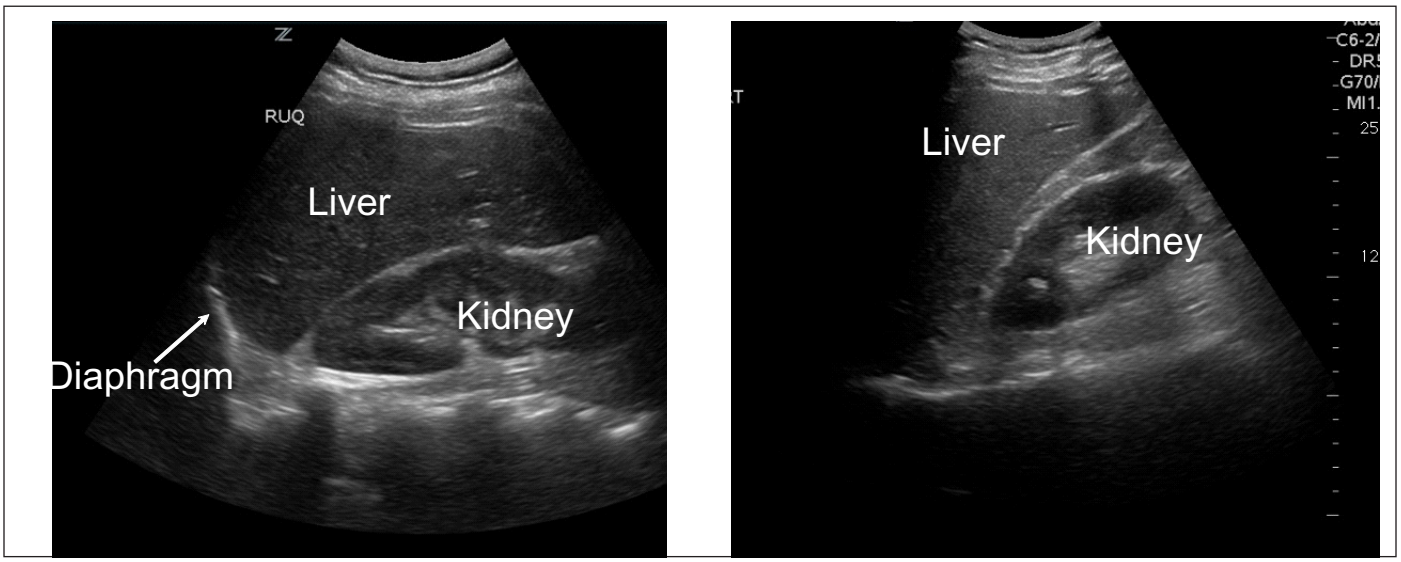

Figures 4-5. Normal FAST Exam, Left Upper Quadrant and Suprapubic View

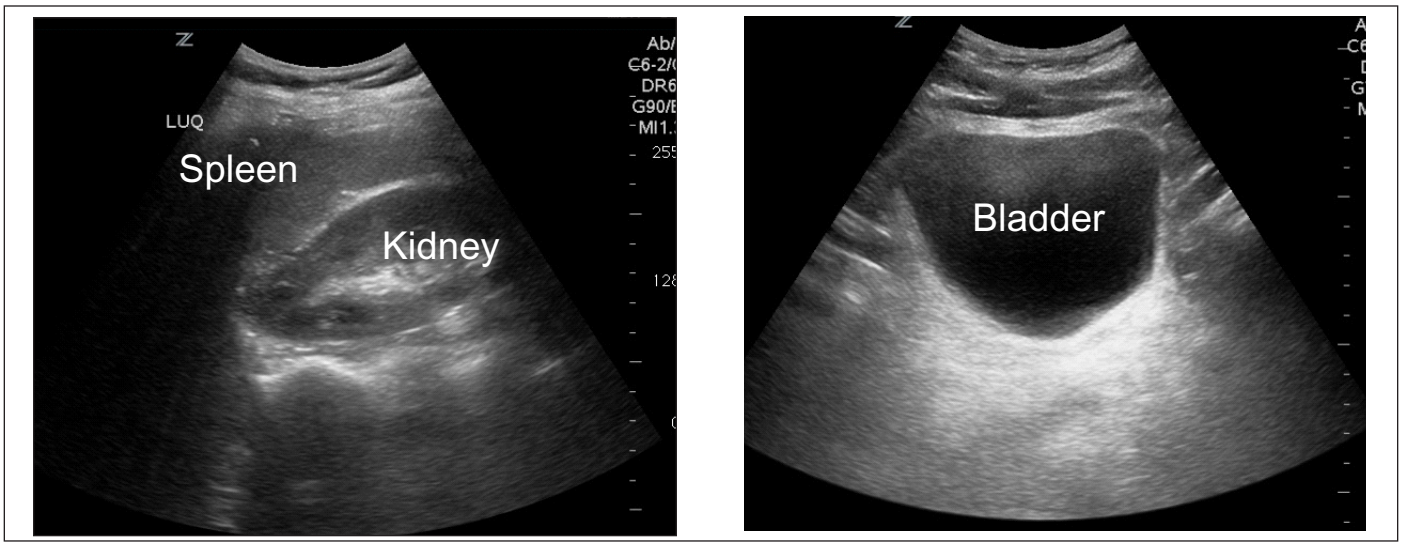

large footprint, low-frequency curvilinear probe is the probe of choice. This probe gives the most information without compromising information gained for depth. Alternatively, the smaller footprint phased array probe can be used. This probe allows for access between the ribs while still allowing for evaluation of the deep structures.

A positive exam is one in which fluid is noted in any of the four views. Fluid appears dark and anechoic. The subxiphoid view is used to evaluate the pericardium. The presence of a dark, anechoic stripe between the myocardium and the pericardium represents pericardial fluid concerning for hemopericardium. It is important when visualizing the pericardium to make note of the posterior pericardium. Since this is the most dependent portion of the pericardium, this is where fluid initially settles. Most significant is the presence of fluid in the anterior pericardium, as this implies enough fluid has accumulated in the less dependent portion of the sac. A stripe of fluid between the liver and the kidney or the liver and the spleen represents fluid in the abdomen. The FAST exam is unable to specify which organ is injured, only identifying the presence of fluid, which indicates underlying pathology. The

Figures 6-7. FAST Exam with Free Fluid

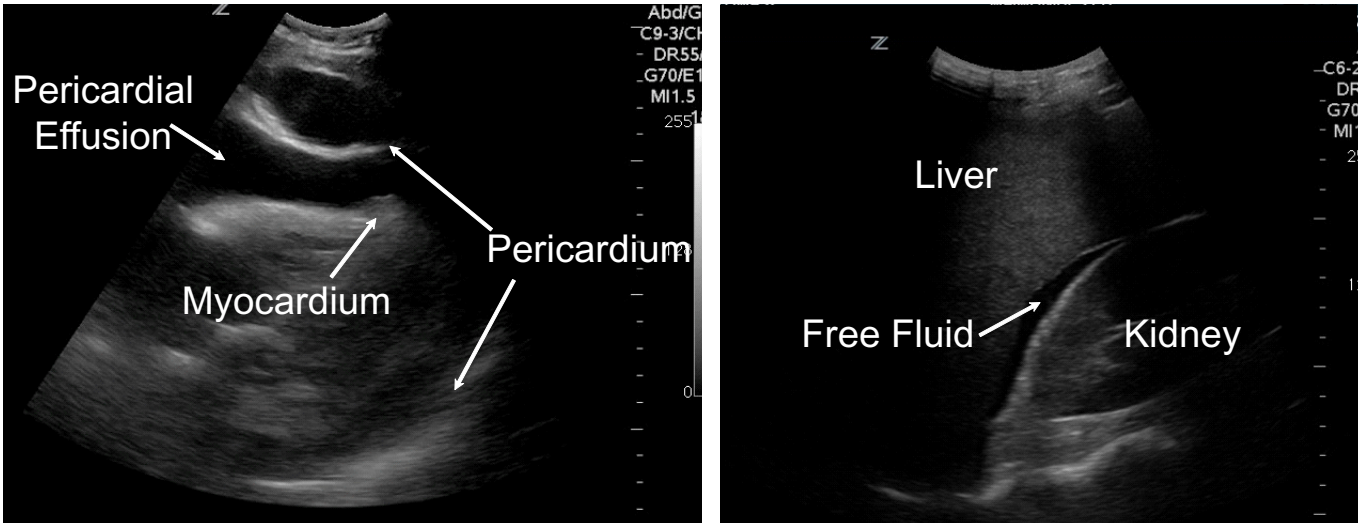

Figures 8-9. FAST Exam with Free Fluid

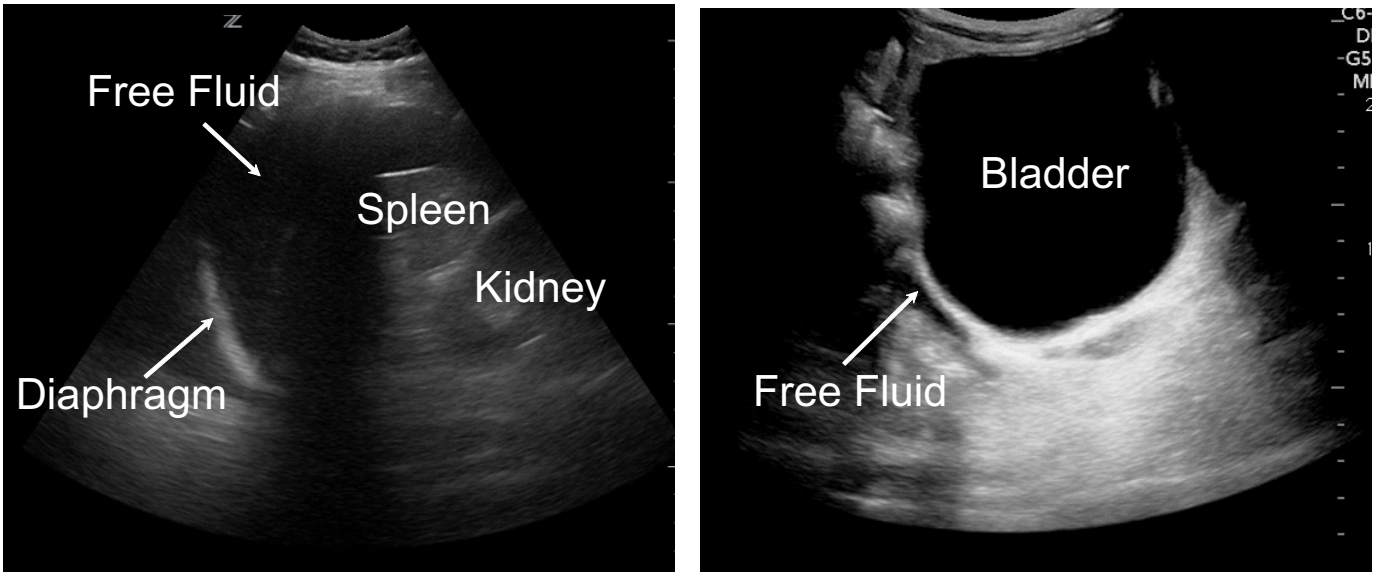

fourth view in the pelvis looks at the vesiculo-uterine space (pouch of Douglas) in females, and the rectovesicular space in males. A dark, anechoic, freeform stripe that does not configure to a wall either behind the bladder or behind the uterus (females) is indicative of injury. (*See Figures 6-9, FAST exam with free fluid.*)

Unfortunately, a negative FAST exam does not exclude an intra-abdominal injury. Reported sensitivity of ultrasound for detection of free intraperitoneal fluid varies, ranging from 62% to 99%, with negative predictive values of 89% to 99%.[7-9] Combinations of clinical and ultrasound findings may be most useful to determine which patients do not require further evaluation.[10,11] There has been some discussion about the usefulness of doing a FAST exam in the setting of a stable patient. In most trauma management algorithms, if a patient is stable and needs further imaging, a CT scan is most likely the test of choice; it gives specific information about the hollow viscus and solid organs, as well as the

Figure 10. A Lines Indicating Normal Lung Function (left image)
Figure 11. Stratosphere Sign (right image)

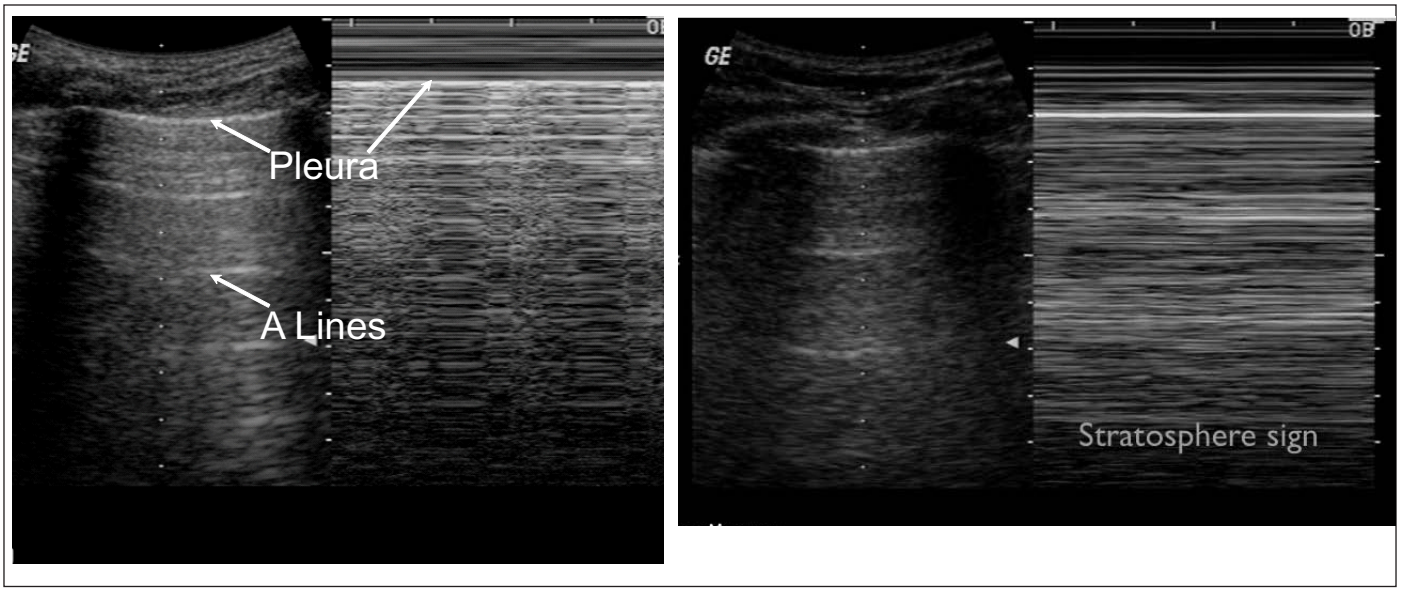

retroperitoneum, which the FAST exam is unable to evaluate. However, this requires the patient to be able to leave the emergency department and travel to the CT scanner and remain hemodynamically stable.

There have been many attempts to use contrast-enhanced sonography to better evaluate solid organ injury. Mihalik et al used contrast-enhanced sonography to confirm CT scan findings of solid organ injury. They were able to identify liver injuries with 62.5% sensitivity, splenic injuries with 100% sensitivity, and renal injuries with 50% sensitivity. The overall sensitivity was 79%, with a positive predictive value of 100% and negative predictive value of 20%.[12] Contrast-enhanced sonography does not identify solid organ injuries with high enough sensitivity to replace CT scans in the complete evaluation of a patient with a blunt traumatic injury. It can be used to identify and follow splenic pseudoaneurysms, which may help to reduce radiation exposure in those patients who require serial evaluations.[13-15] When this modality is used, the contrast is injected twice, once just prior to the left upper quadrant scan and then again just prior to the right upper quadrant scan. While injury to the parenchyma of the liver or spleen would appear hypoechoic, with the use of contrast-enhanced sonography, injury with vessel damage would appear as hyperechoic extravasation.[13,15]

The FAST exam has been shown to be most useful in unstable trauma patients.[10,16,17] A FAST exam should be considered in hemodynamically unstable patients, especially when the cause of hypotension is unclear; in cases of penetrating trauma with multiple wounds or unclear trajectory; in patients with a concerning mechanism of injury but no indication for CT; and in intoxicated patients who can be observed and re-examined. (*See Table 2.*) Since transporting the patient to the CT scanner may not be an option, but a clear indication for operative management may not yet be evident, bedside ultrasound can be used for the initial evaluation and can be repeated for deteriorating or not improving vital signs.

In the case of penetrating trauma, routine use of ultrasound is beneficial; the detection of pericardial or peritoneal fluid is clinically useful. However, the FAST exam is limited in that it cannot give information about the retroperitoneum, localize hollow and viscus injury, nor definitely identify solid organ injury. Therefore, a negative FAST examination does not exclude abdominal injury, such as a diaphragm or hollow viscus wound, and further diagnostic investigation or serial exams are indicated for any patient with a concerning exam.[18]

Localizing the compartment of injury can be used to direct operative management. For example, a gunshot wound in the thoraco-abdominal region could lead to an injury in the thorax, the abdomen, or both. The presence of fluid in Morison's pouch may help the surgeon to direct the first incision and exploration in the abdomen.

EFAST

The added application of thorax evaluation to the FAST, dubbed the EFAST, has broadened the spectrum of bedside sonography. Using ultrasound to detect and diagnose pneumothorax at the bedside is more sensitive and specific than plain radiographs. The sensitivity of thoracic ultrasound was found to be 81.8% and the specificity was found to be 100%. The sensitivity of chest X-ray was found to be 31.8% and the specificity was found to be 100%.[19] Garofalo et al found ultrasound

Figures 12-13. Pleural Effusion

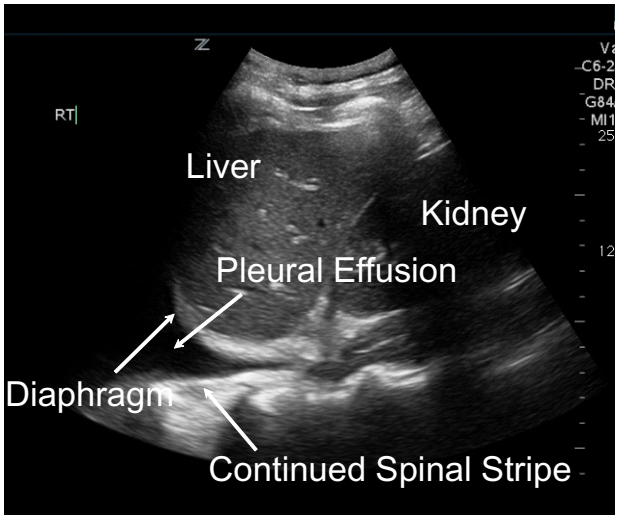

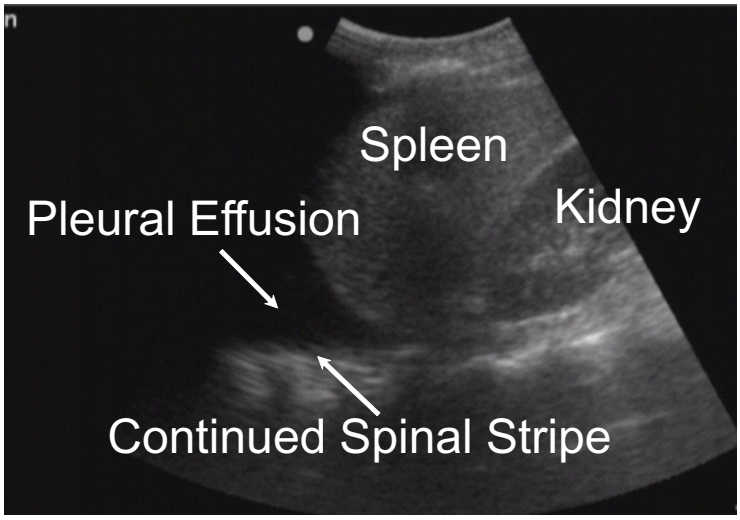

sensitivity was 95.65%, specificity 100%, and diagnostic effectiveness 98.91%. Prompt and accurate diagnosis of a pneumothorax in the assessment of a critical patient can prevent the progression to a life-threatening situation.[20] Recently, Husain et al have confirmed sonographic signs, including "lung sliding," "B-lines" or "comet-tail artifacts," "A-lines," and the "lung point sign" can help in the diagnosis of a pneumothorax.[21] "A lines" are parallel horizontal lines representing an artifact of the pleura. (*See Figure 10.*) The presence of these lines implies normal lung. "B lines" are a comet-tail artifact of vertical lines representing the interface between aerated and compressed lung. The lung point is the interface between a pneumothorax and the lung. Using these sonographic findings can help to quickly direct care.

Chest ultrasound views consist of four locations of each hemithorax, an eight-point exam in total. The four views are: anterior second intercostal space at the midclavicular line; fourth intercostal space at the anterior axillary line; sixth intercostal space at the midaxillary line; and sixth intercostal space at the posterior axillary line. (*See Table 3.*) The linear high-frequency probe allows for evaluation of superficial structures and is therefore the probe of choice to assess for the presence of a sliding lung sign to exclude pneumothorax. In the normal lung, the parietal and visceral surfaces can be visualized by ultrasound as bright interfaces or echogenic lines. With respiration, these two bright lines slide past each other. This phenomenon has been described as ants marching on a log or, simply, the pleural sliding sign. This sliding is seen on ultrasound deep to the ribs. If air, as in the case of a pneumothorax, were to seep in between the parietal and visceral pleura, the deeper pleural layer would not be visualized due to the inability of medical ultrasound to penetrate through air. Thus, since half of the sliding component is invisible, no sliding lung sign is seen. The edge of the collection of air where it meets the lung is the lung point. Air usually rises and can be found in the least dependent aspect of the chest cavity; therefore, the exam should start in this area. However, if a patient has had any sort of lung process previously, the possibility of adhesions may cause air to be trapped in an area other than the zenith of the chest space. Therefore, the protocol includes looking around the chest space.[22,23] Once the pleura have been identified, the ultrasound should be done in B mode as well as M mode. M mode displays a B mode image and plots it over time. In the pneumothorax study, it allows evaluation of pleural movement over time. In

Table 2. FAST Exam Considerations

A FAST exam should be considered in the following patients:

- **Hemodynamically unstable patients, especially when the cause of hypotension is unclear**
- **Cases of penetrating trauma with multiple wounds or unclear trajectory**
- **Patients with a concerning mechanism of injury but no indication for CT**
- **Intoxicated patients who can be observed and re-examined**

Figures 14-15. Femoral Nerve Block

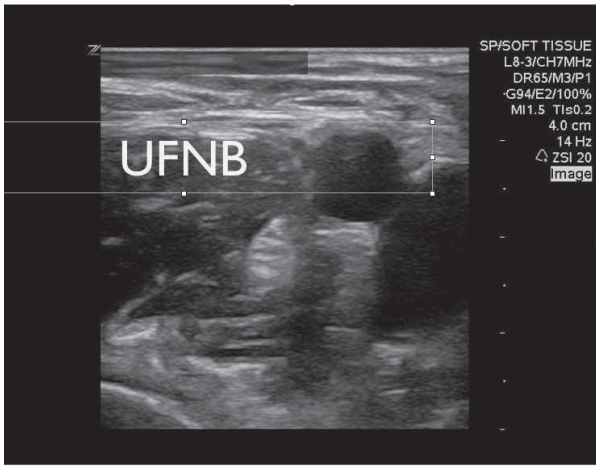

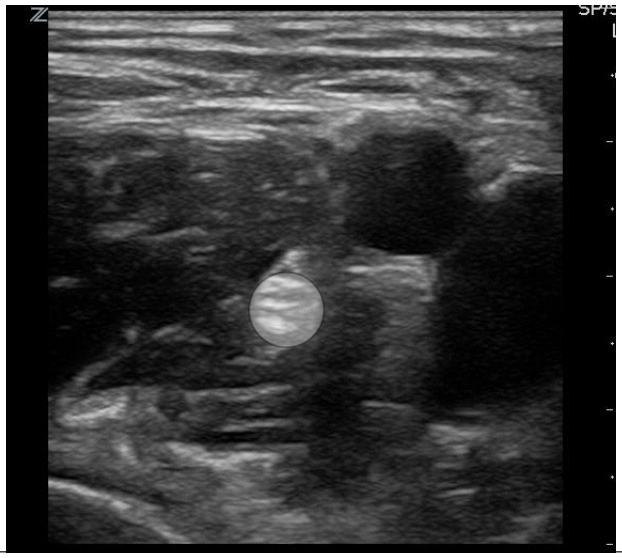

the normal lung, it would appear as sand on the beach with waves in the distance, or the sea shore sign. The sand represents an artifact caused by ultrasound waves hitting the air in the normal lung, which is constantly moving with each breath. If a pneumothorax is present, this appears as a bar code in M mode. The stratosphere sign is seen in M mode, with pleura and lung indistinguishable as linear hyperechogenic lines, and is a reliable sign of pneumothorax. (*See Figure 11.*) Ultrasound can also be used to confirm adequate decompression. In one study, ultrasound was used to confirm decompression after needle thoracostomy for tension pneumothorax.[24]

To evaluate for effusion, the curvilinear probe can be used while it is in the right and left upper abdominal quadrants. The presence of the spinal stripe above the diaphragm is indicative of an effusion; in the traumatic setting, this can be assumed to be blood. The spine appears as a scalloped line that usually stops at the diaphragm. Air prevents ultrasound waves from penetrating deep enough to see such images in the thorax; with the presence of fluid, posterior elements such as the spine can be seen.[25,26] (*See Figures 12-13.*)

Table 3. Chest Ultrasound Views

Chest ultrasound has four views:

- **Anterior second intercostal space at the midclavicular line**
- **Fourth intercostal space at the anterior axillary line**
- **Sixth intercostal space at the midaxillary line**
- **Sixth intercostal space at the posterior axillary line**

Vascular Access

Ultrasound has long been used as an adjunct for central line placement; additionally, it has been shown to reduce time and number of attempts for peripheral line placement.[27] Often, traumatic patients present in shock, making peripheral line placement difficult due to peripheral venous collapse. Patient co-morbidities, such as obesity, drug use, or other medical conditions, may further complicate venous access. Ultrasound has been shown to decrease time to cannulation, as well as the need for central line access due to difficult peripheral access.[28,29] Shokoohi and colleagues describe an 80% decrease in the need for central line access due to successful peripheral line placement with ultrasound.

A liner probe is used, similar to central line placement, with transverse and longitudinal views utilized to optimize visualization. Use of ultrasound gel has not been shown to increase infection rates compared to traditionally placed lines.[29-32]

Bladder Injury

Ultrasound has been used to evaluate for specific intra-abdominal injuries as well. Wu et al describe a case report of diagnosing bladder rupture via bedside ultrasound. While the most extraperitoneal bladder is usually protected by the bony pelvis, the superior portion of the bladder is intraperitoneal. When distended, the dome of the bladder is unprotected from blunt force, leading to intraperitoneal bladder rupture. Wu et al describe a patient with no evidence of urethral injury and

Figure 16. Normal Eye

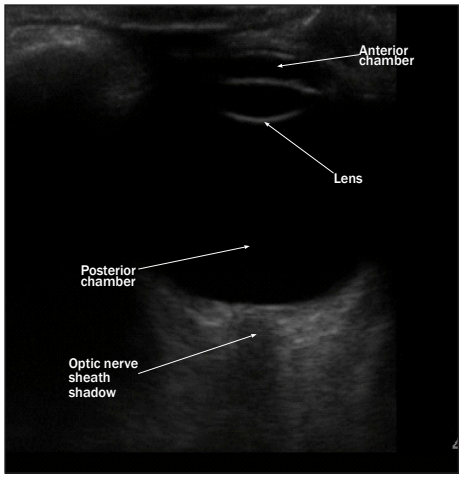

Figure 17. Retinal Detachment

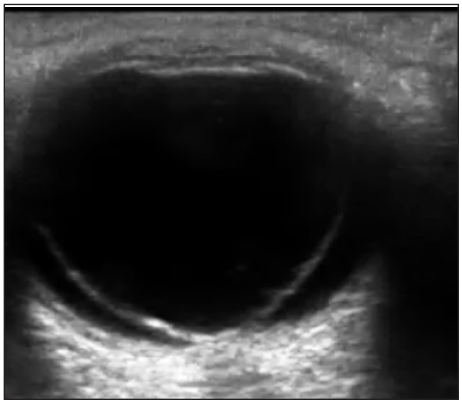

Foley placement with hematuria. The FAST exam showed free fluid in the suprapubic view with an irregular, collapsed bladder. A CT scan confirmed the diagnosis. Isolated bladder injury has up to a 22% mortality, making prompt diagnosis and repair paramount.[33,34]

Pneumopericardium

Bobbia and colleagues describe the diagnosis of pneumopericardium via bedside echocardiography in a patient with respiratory distress. Bright spots were seen rapidly moving along the pericardial layer during diastole, with comet-tail artifacts extending across the whole image of the heart and disappearing during systole, suggesting pneumopericardium. This is a similar artifact that is sought when evaluating the lungs for normal movement vs. pneumothorax.[35]

Femoral Nerve Block

Haines et al describe using ultrasound for hip fractures. Patients with hip fractures are often treated with intravenous opiates, which may cause many adverse effects, particularly in elderly patients. An alternative to systemic opioid analgesia is a nerve blockade. In a study by Haines et al, an ultrasound-guided fascia iliaca compartment block was performed in any patient presenting to the emergency department with a confirmed hip fracture. Patients were randomized to receive either intravenous analgesics or a nerve block. Pain scores were evaluated up to 8 hours, with an overall reduced pain severity score at 120 minutes.[36] (*See Figures 14-15, courtesy of Haines.*)

Special Populations

Resuscitation in Pregnancy. Traditional practices for evaluation of the third trimester pregnant hypotensive patient routinely utilize the left lateral decubitus position. This theoretically relieves the pressure of the uterus on the inferior vena cava (IVC), thereby improving venous return. Fields and colleagues found that while 76% of patients showed an increase in IVC size with left lateral decubitus positioning, the remaining patients showed the largest IVC measurement in the supine position. Utilization of ultrasound to evaluate the IVC during resuscitation may help to appropriately manage positioning for this special patient population.[37]

Fractures. Rib fractures can also be diagnosed using ultrasound, and ultrasound has been shown to be more sensitive than radiographs, especially for fractures in the costal margin or along the costal cartilage. Fractures of the rib, costochondral junction, and costal cartilage appear as a disruption of the anterior echogenic margin of the rib. The costal cartilage normally appears relatively hypoechoic compared with the osseous rib.[38] This is an especially useful tool in children and pregnant women in whom minimizing radiation exposure is an important consideration. Using a linear probe, a fracture would be seen as a disruption of the bony contour as the rib is followed outward.

In addition, ultrasound has been used to diagnose many types of fractures, including the clavicle and elbow, as well as the distal forearm. Ultrasound is particularly useful in the pediatric population, in whom reduction in radiation is an important consideration. Furthermore, bedside evaluation helps to keep these patients calm and reduce the anxiety associated with being moved from the emergency department.[39-41]

Ocular Ultrasound

Emergency bedside ultrasound is highly accurate for excluding and diagnosing ocular pathology. Further, it accurately differentiates between pathology that needs immediate ophthalmologic consultation and that which can be followed up on an outpatient basis.[42] It can be used to evaluated for diagnosis of retinal detachment, foreign body detection, and increased intracranial pressure, as well as to look for pupillary response in the patient with significant periorbital edema/hematoma in which the eyelids cannot be opened.

Ocular ultrasound is performed using a high-frequency linear probe at its lowest setting. On some machines there is an ocular preset that should be used in conjunction with a closed eye technique. Using a clear dressing to cover the closed eye, copious standard water-soluble gel should be applied to prevent direct contact between the probe and the globe. The normal eye appears as a circular hypoechoic structure. The anterior chamber is filled with anechoic fluid and is bordered by the cornea, iris, and anterior reflection of the lens capsule. The iris and ciliary body are seen as echogenic linear structures extending from the peripheral globe toward the lens.

The normal lens is anechoic. The normal vitreous chamber is filled with anechoic fluid. The vitreous is relatively echolucent in a young healthy eye.

Retinal detachment is a true medical emergency. It often is a time-critical, vision-threatening condition. Evaluation for retinal detachments in patients with acute visual change is of particular importance, as immediate identification and treatment of this condition is imperative to prevent deterioration to permanent, complete visual loss. Without treatment, all cases of retinal detachment will spread and involve the macula, causing blindness.[43] Vitreous detachment and hemorrhage can often mimic retinal detachment.[44] A retinal detachment appears as a taut linear opacity within the vitreous chamber that moves in conjunction with eye movements. Vitreous hemorrhage consists of wavy linear or curved strands connecting with the retina that sway as the eye moves from side to side. A vitreous detachment occurs when the vitreous humor detaches from the posterior retina, which results in a mobile "swaying seaweed" appearance on ultrasound, where the vitreous appears separated from the retina.[44] (*See Figures 16 and 17.*)

Ocular trauma is fairly common and should be suspected in patients involved in trauma with airborne material. Ritchie et al found that ultrasound was as sensitive as CT scan in detecting blast injuries.[45] Foreign bodies in the globe can be devastating and require immediate attention. Often this is a subtle finding during the secondary survey, and commonly it is difficult to evaluate given that it is commonly accompanied by periorbital edema. Systematic imaging assessment should include the position, the contour, and volume of the globe, the density within the globe, the contours of the retina and sclera, and the presence of foreign bodies.[46] Ultrasound is contraindicated if globe rupture is suspected, as the slightest amount of pressure can cause expulsion of vitreous. (*See Figure 18.*)

Figure 18. Globe Rupture

Eliciting pupillary responses can be rendered impossible when the eyelid is swollen shut. In these instances, ocular ultrasound to look for consensual response to light can be employed.[47] With light shining in the non-edematous eye, the iris should contract, with movement visible on ultrasound. One limitation to this exam is the inability to measure pupil size.

Ocular ultrasound for increased intracranial pressure has been described extensively. While there is a high normal variant rate, in the correct clinical setting, measurement of the optic nerve sheath diameter using bedside ultrasound has been shown to correlate with clinical and radiologic signs and symptoms of increased intracranial pressure.[48-50] The diameter is measured 3 mm behind the globe using a high-frequency linear probe. Optic nerve sheath diameter measurement correlates with invasive measurements with a sensitivity of 94% and specificity of 76%, thus confirming its usability.[49,51] (*See Figure 19.*)

Foreign Body

Penetrating injury with a retained foreign body is a common problem. Locating the foreign body and performing surgical excision may be difficult for many reasons. It is further complicated when the object is not radio-opaque and is embedded in the deep tissue. Although radiographs have been proven to be ineffective, X-ray is often the first method used. Ultrasound can be a sensitive tool in both the detection and surgical removal of retained foreign bodies in soft tissue.[52,53] Furthermore, ultrasound can be used in real time to guide extraction. (*See Figure 20.*)

Figure 19. Optic Nerve Sheath Diameter Measurement

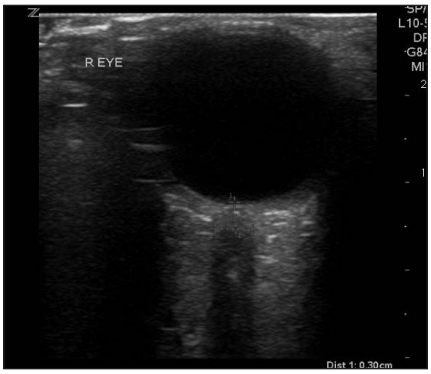

Figure 20. Foreign Body with Reverberation Artifact

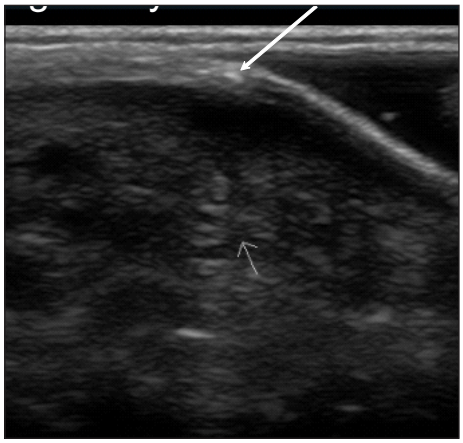

Conclusion

Bedside ultrasound applications are growing rapidly. The information provided leads to early diagnosis and disposition. The FAST exam has expanded to include the thorax as an integral aspect of the exam. Furthermore, ultrasound has earned its position at the bedside not only for diagnosis but as an adjunct for procedures. Proficiency in bedside ultrasound evaluation is of utmost importance as its utility continues to grow.

References

1. Centers for Disease Control and Prevention, CDC/National Center for Health Statistics. http://www.cdc.gov/nchs/fastats/ervisits.htm. Page last updated: May 16, 2012.
2. Rozycki GS, Ballard RB, Feliciano DV, et al. Surgeon-performed ultrasound for the assessment of truncal injuries: Lessons learned from 1540 patients. *Ann Surg* 1998;228(4):557-567.
3. Udobi KF, Rodriguez A, Chiu WC, et al. Role of ultrasonography in penetrating abdominal trauma: A prospective clinical study. *J Trauma* 2001;50(3):475-9.
4. Heyn J, Ladurner R, Ozimek A, et al. Diagnosis and pre-operative management of multiple injured patients with explorative laparotomy because of blunt abdominal trauma. *Eur J Med Res* 2008;13(11):517-524.
5. Woo J. A short history of the development of ultrasound in obstetrics and gynecology. http://www.ob-ultrasound.net/history1.html. 1998-2002.
6. Lee BC, Ormsby EL, McGahan JP, et al. The utility of sonography for the triage of blunt abdominal trauma patients to exploratory laparotomy. *AJR Am J Roentgenol* 2007;188:415–421.
7. Rozycki GS, Ochsner MG, Schmidt JA, et al. A prospective study of surgeon-performed ultrasound as the primary adjuvant modality for injured patient assessment. *J Trauma* 1995;39(3):492-498.
8. Shanmuganathan K, Mirvis SE, Sherbourne CD,et al. Hemoperitoneum as the sole indicator of abdominal visceral injuries: A potential limitation of screening abdominal US for trauma. *Radiology* 1999;212:423–430.
9. Gaarder C, Kroepelien F, Loekke R, et al. Ultrasound performed by radiologists — confirming the truth about FAST in trauma. *J Trauma* 2009;67:323–329.
10. Natarajan B, Gupta P, Cemaj S, et al. FAST Scan: Is it worth doing in hemodynamically stable blunt trauma patient? *Surgery* 2010;148(4):695-700.
11. Nishijima DK, Simel DL, Wisner DH, et al. Does this adult patient have a blunt intra-abdominal injury? *JAMA* 2012;307(14):1517-1527.
12. Mihalik JE, Smith RS, Toevs CC, et al. The use of contrast-enhanced ultrasound for the evaluation of solid abdominal organ injury in patients with blunt abdominal trauma. *J Trauma Acute Care Surg* 2012;73(5):1100-1105.
13. Poletti PA, Platon A, Becker CD, et al. Blunt abdominal trauma: Does the use of a second-generation sonographic contrast agent help to detect solid organ injuries? *AJR Am J Roentgenol* 2004;183(5):1293-1301.
14. Valentino M, Ansaloni L, Catena F, et al. Contrast-enhanced ultrasonography in blunt abdominal trauma: Considerations after 5 years of experience. *Radiol Med* 2009;114(7):1080-1093.
15. McGahan JP, Horton S, Gerscovich EO, et al. Appearance of solid organ injury with contrast-enhanced sonography in blunt abdominal trauma: Preliminary experience. *AJR Am J Roentgenol* 2006;187(3):658-666.
16. Kendall JL, Kestler AM, Whitaker KT, et al. Blunt abdominal trauma patients are at very low risk for intra-abdominal injury after emergency department observation. *West J Emerg Med* 2011;12(4):496-504.
17. Miller MT, Pasquale MD, Bromberg WJ, et al. Not so FAST. *J Trauma* 2003;54(1):52-59.
18. Boulanger BR, Kearney PA, Tsuei B, et al. The routine use of sonography in penetrating torso injury is beneficial. *J Trauma* 2001;51(2):320-325.
19. Nagarsheth K, Kurek S. Ultrasound detection of pneumothorax compared with chest X-ray and computed tomography scan. *Am Surg* 2011;77(4):480-484.
20. Garofalo G, Busso M, Perotto F, et al. Ultrasound diagnosis of pneumothorax. *Radiol Med* 2006;111(4):516-525. .
21. Husain LF, Hagopian L, Wayman D, et al. Sonographic diagnosis of pneumothorax. *J Emerg Trauma Shock* 2012;5(1):76-81.
22. Alrajhi K, Woo MY, Vaillancourt C. Test characteristics of ultrasonography for the detection of pneumothorax: A systematic review and meta-analysis. *Chest* 2012;141(3):703-708.
23. Blaivas M, Lyon M, Duggal S. A prospective comparison of supine chest radiography and bedside ultrasound for the diagnosis of traumatic pneumothorax. *Acad Emerg Med* 2005;12(9):844-849.
24. Ball CG, Wyrzykowski AD, Kirkpatrick AW, et al. Thoracic needle decompression for tension pneumothorax: Clinical correlation with catheter length. *Can J Surg* 2010;53(3):184-188.
25. Koeze J, Nijsten MW, Lansink AO, et al. Bedside lung ultrasound in the critically ill patient with pulmonary pathology: Different diagnoses with comparable chest X-ray opacification. *Crit Ultrasound J* 2012;4(1):1.
26. Rozycki GS, Pennington SD, Feliciano DV. Surgeon-performed ultrasound in the critical care setting: Its use as an extension of the physical examination to detect pleural effusion. *J Trauma* 2001;50(4):636-642.
27. Randolph AG, Cook DJ, et al. Ultrasound guidance for placement of central venous catheters: A meta-analysis of the literature. *Crit Cr Med* 1996;24:2053-2058.
28. Gregg SC, Murthi SB, Sisley AC. Ultrasound-guided peripheral intravenous access in the intensive care unit. *J Crit Care* 2010;25:514-519.
29. Shokoohi H, Boniface K, McCarthy M, et al. Ultrasound-guided peripheral intravenous access program is associated with a marked reduction in central venous catheter use in noncritically ill emergency department patients. *Ann Emerg Med* 2012;pii: S0196-0644.
30. Constantino TG, Parikh AK, Satz WA, et al. Ultrasonography-guided peripheral intravenous access versus traditional approaches in patients with difficult intravenous access. *Ann Emerg Med* 2005;46:456-461.
31. Dargin JM, Rebholz CM, Lowenstein RA, et al. Ultrasonography-guided peripheral intravenous catheter survival in ED patients with difficult access. *Am J Emerg Med* 2010;28:1-7.
32. Adhikari S, Blaivas M, Morrison D. Comparison of infection rates among ultrasound-guided versus traditionally placed peripheral intravenous lines. *J Ultrasound Med* 2010;29:741-747.
33. Wu T, Pearson T, Meiners S, et al. Bedside ultrasound diagnosis of a traumatic bladder rupture. *J Emerg Med* 2011;41(5):520-523.
34. Sezhian N, Rimal D, Suresh G. Isolated intraperitoneal bladder rupture following minor trauma after alcohol ingestion. *South Med J* 2005;98:573–574.
35. Bobbia X, Claret PG, Muller L Pneumopericardium diagnosis by point-of-care ultrasonography. *J Clin Ultrasound* 2012 May 15. Epub ahead of print.
36. Haines L, Dickman E, Ayvazyan S, et al. Ultrasound-guided fascia iliaca compartment block for hip fractures in the emergency department. *J Emerg Med* 2012;43:692-697.
37. Fields JM, Catallo K, Au AK. Resuscitation of the pregnant patient: What is the effect of patient positioning on inferior vena cava diameter? *Resuscitation* 2013;84:304-308.
38. Turk F, Kurt AB, Saglam S. Evaluation by ultrasound of traumatic rib fractures missed by radiography. *Emerg Radiol* 2010;17(6):473-477.
39. Rabiner JE, Khine H, Avner JR, et al. Accuracy of point-of-care ultrasonography for diagnosis of elbow fractures in children. *Ann Emerg Med* 2012:196-0644.
40. Chien M, Bulloch B, Garcia-Filion P, et al. Bedside ultrasound in the diagnosis of pediatric clavicle fractures. *Pediatr Emerg Care* 2011;27(11):1038-1041.
41. Chaar-Alvarez FM, Warkentine F, Cross K, et al. Bedside ultrasound diagnosis of nonangulated distal forearm fractures in the pediatric emergency department. *Pediatr Emerg Care* 2011;27(11):1027-1032.
42. Blaivas M, Theodoro D, Sierzenski PR. A study of bedside ocular ultrasonography in the emergency department. *Acad Emerg Med* 2002;9(8):791-799.
43. Schott ML, Pierog JE, Williams SR. Pitfalls in the use of ocular ultrasound for evaluation of acute vision Loss. *J Emerg Med* 2013 Mar 19
44. Shinar Z, Chan L, Orlinsky M. Use of ocular ultrasound for the evaluation of retinal detachment. *J Emerg Med* 2011;40:53–57.

45. Ritchie JV, Horne ST, Perry J, et al. Ultrasound triage of ocular blast injury in the military emergency department. *Mil Med* 2012;177(2):174-178.

46. Dunkin JM, Crum AV, Swanger RS, et al. Globe trauma. *Semin Ultrasound CT MR* 2011;32(1):51-56.

47. Chiao L, Sharipov S, Sargsyan AE, et al. Ocular examination for trauma: Clinical ultrasound aboard the International Space Station. *J Trauma* 2005;58(5):885-889.

48. Blaivas M, Theodoro D, Sierzenski PR. Elevated intracranial pressure detected by bedside emergency ultrasonography of the optic nerve sheath. *Acad Emerg Med* 2003;10(4):376-381.

49. Kimberly HH, Shah S, Marill K, et al. Correlation of optic nerve sheath diameter with direct measurement of intracranial pressure. *Acad Emerg Med* 2008;15(2):201-204.

50. Tayal VS, Neulander M, Norton HJ, et al. Emergency department sonographic measurement of optic nerve sheath diameter to detect findings of increased intracranial pressure in adult head injury patients. *Ann Emerg Med* 2007;49(4):508-514.

51. Moretti R, Pizzi B. Optic nerve ultrasound for detection of intracranial hypertension in intracranial hemorrhage patients: Confirmation of previous findings in a different patient population. *J Neurosurg Anesthesiol* 2009;21(1):16-20.

52. Porter MD, Schriver JP. Ultrasound-guided Kopans' needle location and removal of a retained foreign body. *Surg Endosc* 2000;14(5):500.

53. Sidharthan S, Mbako AN. Pitfalls in diagnosis and problems in extraction of retained wooden foreign bodies in the foot. *Foot Ankle Surg* 2010 ;16(2): e18-20.

CME/CNE Questions

1. The acronym FAST stands for:
   A. Focused Abdominal Sonography in Trauma
   B. Focused Assessment with Sonography in Trauma
   C. Fast Assessment with Sonography in Trauma
   D. Fast Abdominal Sonography in Trauma

2. The four views of the FAST exam are:
   A. subxiphoid, right upper quadrant, left upper quadrant, left lower quadrant
   B. subxiphoid, right upper quadrant, Morison's pouch, suprapubic
   C. parasternal long, right upper quadrant, suprapubic, left anterior chest
   D. subxiphoid, right upper quadrant, left upper quadrant, suprapubic

3. The additional views to the EFAST include evaluation of the:
   A. thorax
   B. heart
   C. gallbladder
   D. aorta

4. A negative FAST exam clears a patient of all traumatic injuries.
   A. true
   B. false

5. The order of sensitivity from least to greatest for pneumothorax is:
   A. CT scan, chest X-ray, chest ultrasound
   B. chest X-ray, chest ultrasound, CT scan
   C. chest X-ray, CT scan, chest ultrasound
   D. chest ultrasound, chest X-ray, CT scan

6. A 20-year-old female restrained driver in a motor vehicle collision with no loss of consciousness is brought in. You notice her heart rate is 97, blood pressure is 93/64, O2 saturation is 92%. On exam you cannot confidently hear breath sounds because it is too loud in the trauma bay. You have a high suspicion for a pneumothorax. As you are about to roll the patient, her blood pressure drops to 61/35 and her oxygen saturation is now 83%. You pull over the ultrasound machine and see a lack of pleural sliding and get ready to do a needle decompression. Other evidence that confirms your diagnosis of pneumothorax is the presence of a lung point. The lung point is:
   A. the interface between aerated and compressed lung
   B. the interface between air in the pleura and the lung
   C. reverberation artifact caused by the bright pleura
   D. the interface between fluid and lung

7. A 38-year-old man comes to the emergency department after a gunshot to the right chest. The FAST exam is negative for fluid in the pericardium and peritoneum, but you have a high suspicion for a thoracic injury and perform the EFAST. You confirm a hemothorax by pointing out the presence of fluid in the thorax with a spinal stripe that extends superior to the diaphragm. How does the spine appear in the presence of fluid in the thorax?
   A. as a straight line
   B. as an oyster edge
   C. as a scalloped line
   D. as A lines

8. A 60-year-old female presents after a motor vehicle collision with a blood pressure of 82/54. While you are doing the primary survey, a thrill is noticed in the left forearm, and track marks on the right forearm. You have attempted to place an IV using visual landmarks without success. You decide to use the ultrasound to guide your line placement. The probe of choice for placing peripheral and central lines is the:
   A. curvilinear probe
   B. cardiac probe
   C. linear probe
   D. endocavitary probe

9. What percentage of pregnant patients have an IVC diameter that is larger in the left lateral decubitus position?
   A. 30%
   B. 50%
   C. 70%
   D. 90%

10. A mother brings her 8-year-old son who complains of pain with breathing. She notes that he was playing baseball in the school yard and was hit in the chest with the ball. Mom is concerned about the radiation involved in doing an X-ray. You offer to do an ultrasound of the chest and ribs and identify good pleural sliding, but note a third anterior rib fracture. This fracture would appear as:
   A. disruption of the posterior hyperechoic bony contour
   B. disruption of the anterior hyperechoic bony contour
   C. opaque density in the rib contour
   D. presence of A lines

CNE/CME Instructions

HERE ARE THE STEPS YOU NEED TO TAKE TO EARN CREDIT FOR THIS ACTIVITY:

1. Read and study the activity, using the provided references for further research.

2. Log on to **www.cmecity.com** to take a post-test; tests can be taken after each issue or collectively at the end of the semester. *First-time users will have to register on the site using the 8-digit subscriber number printed on their mailing label, invoice, or renewal notice.*

3. Pass the online tests with a score of 100%; you will be allowed to answer the questions as many times as needed to achieve a score of 100%.

4. After successfully completing the last test of the semester, your browser will be automatically directed to the activity evaluation form, which you will submit online.

5. **Once the completed evaluation is received, a credit letter will be e-mailed to you instantly.** You will no longer have to wait to receive your credit letter.

CNE/CME Objectives

Upon completing this program, the participants will be able to:

- discuss conditions that should increase suspicion for traumatic injuries;
- describe the various modalities used to identify different traumatic conditions;
- cite methods of quickly stabilizing and managing patients; and
- identify possible complications that may occur with traumatic injuries.

Trauma Reports™ (ISSN 1531-1082) is published bimonthly by AHC Media, a division of Thompson Media Group, LLC, 3525 Piedmont Road, N.E., Six Piedmont Center, Suite 400, Atlanta, GA 30305. Telephone: (800) 688-2421 or (404) 262-7436.

Senior Vice President / Group Publisher: Donald R. Johnston

Executive Editor: Shelly Morrow Mark

Managing Editor: Leslie Hamlin

POSTMASTER: Send address changes to Trauma Reports,
P.O. Box 105109, Atlanta, GA 30348.

Subscriber Information

Customer Service: 1-800-688-2421

Customer Service E-Mail:
customerservice@ahcmedia.com

Editorial E-Mail:
shelly.mark@ahcmedia.com

World Wide Web page:
http://www.ahcmedia.com

FREE to subscribers of *Emergency Medicine Reports* and *Pediatric Emergency Medicine Reports*

Subscription Prices

United States

$249 per year. Add $17.95 for shipping & handling

Multiple Copies

Discounts are available for group subscriptions, multiple copies, site-licenses or electronic distribution. For pricing information, call Tria Kreutzer at 404-262-5482.

All prices U.S. only. U.S. possessions and Canada, add $30 postage plus applicable GST.

Other international orders, add $30.

Accreditation

AHC Media is accredited by the Accreditation Council for Continuing Medical Education to provide continuing medical education for physicians.

AHC Media designates this enduring material for a maximum of 2.5 *AMA PRA Category 1 Credits*™. Physicians should claim only the credit commensurate with the extent of their participation in the activity.

Approved by the American College of Emergency Physicians for a maximum of 2.5 hour(s) of ACEP Category I credit.

AHC Media is accredited as a provider of continuing nursing education by the American Nurses Credentialing Center's Commission on Accreditation.

This activity has been approved for 1.5 nursing contact hours using a 60-minute contact hour.

Provider approved by the California Board of Registered Nursing, Provider # 14749, for 1.5 Contact Hours.

This is an educational publication designed to present scientific information and opinion to health professionals, to stimulate thought, and further investigation. It does not provide advice regarding medical diagnosis or treatment for any individual case. It is not intended for use by the layman. Opinions expressed are not necessarily those of this publication. Mention of products or services does not constitute endorsement. Clinical, legal, tax, and other comments are offered for general guidance only; professional counsel should be sought for specific situations.

This CME/CNE activity is intended for emergency, family, osteopathic, trauma, surgical, and general practice physicians and nurses who have contact with trauma patients.

It is in effect for 24 months from the date of publication.

In Future Issues | **Pediatric Burns**

AHC Media

Dear *Trauma Reports* Subscriber:

This issue of your newsletter marks the start of a new continuing medical education (CME) semester and provides us with an opportunity to remind you about **the procedures for earning CME and delivery of your credit lette**r.

Trauma Reports, sponsored by AHC Media, provides you with evidence-based information and best practices that help you make informed decisions concerning treatment options and physician office practices. Our intent is the same as yours — the best possible patient care.

Upon completion of this educational activity, participants should be able to:

- discuss conditions that should increase suspicion for traumatic injuries;
- describe the various modalities used to identify different traumatic conditions;
- cite methods of quickly stabilizing and managing patients; and
- identify possible complications that may occur with traumatic injuries.

The American Medical Association, which oversees the Physician's Recognition Award and credit system and allows AHC Media to award *AMA PRA Category 1 Credit* ™, has changed its requirements for awarding *AMA PRA Category 1 Credit* ™. Enduring materials, like this newsletter, are now required to include an assessment of the learner's performance; the activity provider can award credit only if a minimum performance level is met. AHC Media considered several ways of meeting these new AMA requirements and chose the most expedient method for our learners.

HERE ARE THE STEPS YOU NEED TO TAKE TO EARN CREDIT FOR THIS ACTIVITY:

1. Read and study the activity, using the provided references for further research.
2. Log on to **www.cmecity.com** to take a post-test; tests can be taken after each issue or collectively at the end of the semester. *First-time users will have to register on the site using the 8-digit subscriber number printed on their mailing label, invoice, or renewal notice.*
3. Pass the online tests with a score of 100%; you will be allowed to answer the questions as many times as needed to achieve a score of 100%.
4. After successfully completing the last test of the semester, your browser will be automatically directed to the activity evaluation form, which you will submit online.
5. **Once the completed evaluation is received, a credit letter will be e-mailed to you instantly.** You will not have to wait to receive your credit letter!

This activity is valid 24 months from the date of publication. The target audience for this activity includes emergency medicine and family physicians.

If you have any questions about the process, please call us at (800) 688-2421, or outside the U.S. at (404) 262-5476. You can also fax us at (800) 284-3291, or outside the U.S. at (404) 262-5560. You can also email us at: customerservice@ahcmedia.com.

On behalf of AHC Media, we thank you for your trust and look forward to a continuing education partnership.

Sincerely,



Lee Landenberger
Continuing Education Director
AHC Media