Pediatric Emergency Medicine Reports

Practical, Evidence-Based Reviews in Pediatric Emergency Care

Volume 18, Number 12 / December 2013 www.ahcmedia.com

Authors:

Adam Nicholson, MD, Fellow, Pediatric Emergency Medicine, Northwestern McGaw, Ann & Robert H. Lurie Children's Hospital of Chicago, IL.

Walter Eppich, MD, MEd, Assistant Professor of Pediatrics and Medical Education, Northwestern University Feinberg School of Medicine, Ann & Robert H. Lurie Children's Hospital of Chicago, IL.

Peer Reviewer:

Ghazala Q. Sharieff, MD, MBA, Director of Pediatric Emergency Medicine, Palomar Health, Escondido, CA; Clinical Professor, University of California, San Diego.

Statement of Financial Disclosure

To reveal any potential bias in this publication, and in accordance with Accreditation Council for Continuing Medical Education guidelines, we disclose that Dr. Dietrich (editor), Dr. Skrainka (CME question reviewer), Dr. Nicholson (author), Dr. Eppich (author), Dr. Sharieff (peer reviewer), Ms. Mark (executive editor), and Ms. Hamlin (managing editor) report no relationships with companies related to the field of study covered by this CME activity.

AHC Media

Infections of the Neck in Children

Children frequently present with infections of the neck. A comprehensive understanding of both superficial and deep infections of the neck is essential for clinical practice. Accurate recognition and early definitive management can minimize the risk of subsequent complications.

— Ann M. Dietrich, MD, Editor

Introduction

Pediatric patients with infections of the various structures of the neck are often evaluated in the emergency department. The infections seen range from benign, self-limited viral processes to potentially life-threatening bacterial diseases. Emergency clinicians must be able to efficiently and accurately diagnose and treat these patients. This article will focus on the assessment, evaluation, and treatment of both superficial and deep neck space infections in emergency settings. While the most common causes of acute infection will be emphasized, a framework to help identify atypical infections and noninfectious processes will also be provided.

Superficial Neck Infections

Case 1. An 8-year-old girl presents to the emergency department with a two-day history of progressive left neck swelling, redness, and pain. She is generally well-appearing. Her temperature is 38.0°C. Overlying her left sternocleidomastoid muscle is visible erythema and edema; underlying this area is a 2 cm x 2 cm indurated and tender but nonfluctuant mass.

What evaluation is necessary? Imaging? Laboratory testing? What uncommon infections and noninfectious causes should be considered? Should an antibiotic be started and, if so, which one(s)? Does she require inpatient admission and/or surgical consultation?

Definitions and Epidemiology

Cervical lymphadenopathy, defined as enlarged lymph node(s) of the neck, is the most common cause of a palpable pediatric neck mass.[1,2] Enlarged but non-inflamed lymph nodes are often reactive sequelae of a viral upper respiratory tract infection rather than a focal infectious process. In fact, nearly half of healthy children may have palpable cervical lymphadenopathy and no evidence

Congratulations to *Pediatric Emergency Medicine Reports* editorial board member Michael J. Gerardi, MD, who was recently chosen as president-elect of the American College of Emergency Physicians. Dr. Gerardi is Director of Pediatric Emergency Services at Goryeb Children's Hospital in Morristown, New Jersey, and Assistant Clinical Professor of Medicine at University of Medicine and Dentistry of New Jersey in Newark. He has served on the editorial advisory board for more than 14 years.

Executive Summary

- Viral pathogens cause acute lymphadenitis that is commonly bilateral, non-suppurative, and self-limited.
- Bacterial cervical adenitis, on the other hand, is more often unilateral, progressive if left untreated, and may result in abscess formation.
- Reflecting the increased prevalence of MRSA, a number of studies have demonstrated that approximately 30% of cervical abscesses are due to MRSA, with smaller proportions caused by methicillin-sensitive *S. aureus* (MSSA) and GAS.
- Cat scratch disease, caused by *Bartonella henselae*, occurs following a bite or scratch by an infected cat. Following an incubation period of days to weeks, a cervical lymph node may become inflamed. Systemic symptoms may or may not be present. The initial site of inoculation may be distant from the neck, so a careful history and skin examination is critical.
- Thyroglossal duct cysts are the most common cause of a midline neck mass and are typically located at the level of the thyroid cartilage. Approximately 20% become infected.

of localized or systemic disease.[3] A recent study of 282 pediatric patients who underwent evaluation for cervical adenopathy found that 64% of the cases were of unknown origin.[4]

Cervical lymphadenitis refers to enlarged, inflamed, and tender lymph nodes of the neck. Acute infectious processes are the most common cause in children. Most children with symptomatic lymphadenitis have either a viral or bacterial etiology of their symptoms, while smaller proportions of inflamed neck masses are due to congenital malformations or neoplasm.[1] Focal superficial neck abscesses may occur as the suppurative sequelae of lymphadenitis, direct infiltration of soft tissue, or as a consequence of infected congenital malformations. Consequently, spreading cellulitis and spontaneous purulent drainage may also be seen. The rising incidence of methicillin-resistant *S. aureus* (MRSA) infected cervical abscesses has been demonstrated in a number of studies.[5,6] More recently, a review of the 2009 Kids' Inpatient Database found 3571 MRSA-infected abscesses of the head and neck requiring hospital admission.[7]

Table 1. Anatomic Diagnosis of Neck Masses

Location	Possible Cause
Midline, above thyroid	Thyroglossal duct cyst, dermoid, laryngocele
Midline, near/overlying thyroid	Thyromegaly, thyroid nodule
Lateral, anterior to sternocleidomastoid	Lymph node(s), branchial cleft cysts
Lateral, posterior to sternocleidomastoid	Lymph node(s), cystic hygroma
Supraclavicular	Lymph node(s), malignancy

Anatomy

Defining the location of a neck mass helps formulate an initial differential diagnosis. (*See Table 1.*) Midline masses are more commonly congenital in origin, while lateral masses are more likely infectious. Determining whether a mass is unilateral or bilateral also helps guide whether bacterial or viral causes are more likely. Finally, understanding the lymphatic drainage of the head and neck may help identify the infectious origin of an inflamed or reactive lymph node. (*See Figure 1.*) For example, enlargement of the anterior cervical nodes is common during acute infectious processes of the mouth and pharynx, while posterior cervical and occipital adenopathy may be seen with scalp infections and dermatitis.

Pathophysiology and Etiology

Infectious lymphadenitis is the result of afferent lymphatic drainage of organisms that penetrate the oropharyngeal mucosa or skin of the head and neck into regional lymph nodes. Subsequently, an inflammatory infiltrate ensues within the affected node(s), resulting in either an acute or chronic infectious process.

Viral pathogens cause acute lymphadenitis that is commonly bilateral, non-suppurative, and self-limited. Bacterial cervical adenitis, on the other hand, is more often unilateral, progressive if left untreated, and may result in abscess formation. The most common bacterial pathogens associated with acute suppurative lymphadenitis are group A streptococcus (GAS) and *S. aureus*; anaerobic oral flora also may be isolated, particularly when there is associated periodontal disease.[8] Reflecting the increased prevalence of MRSA, a number of studies have demonstrated that approximately 30% of cervical abscesses are due to MRSA, with smaller proportions caused by methicillin-sensitive *S. aureus* (MSSA) and GAS.[9,10,11] This shift in microbiologic patterns is important

for the emergency provider to consider when either initiating or changing antibiotic therapy in a child with cervical adenitis.

Clinical Features

History. A detailed history about the timing, associated symptoms, and preceding or intercurrent illness should be obtained for all children presenting with cervical lymphadenitis. An acutely inflamed neck mass is likely to be caused by common bacterial and viral pathogens, whereas subacute and chronic lesions tend to be associated with atypical infections, noninfectious inflammatory conditions, and neoplasms. Concurrent or preceding symptoms of upper respiratory tract infection, tonsillitis, pharyngitis, or otitis media are often found in the typical history of acute lymphadenitis. Asking about both cat and tuberculosis exposure, as well as ingestion of unpasteurized milk or uncooked meats, may uncover less common infectious diagnoses. A child with a previous history of a neck mass that has become acutely red, painful, and swollen may have a secondarily infected congenital lesion.

Physical Examination. Assessing vital signs helps to determine the degree of systemic toxicity and associated dehydration from an acute infection. A rapid assessment of the airway is important since some neck masses may cause external compression. The scalp, ears, mouth, and throat should be evaluated as potential primary sources of infection leading to cervical node inflammation. Neck range of motion and signs of meningeal irritation should be elicited.

Visually inspecting the neck will provide information about the degree of associated edema and erythema. Palpating areas of edema and erythema in the neck will identify underlying node mobility, tenderness, induration, and fluctuance. Complete palpation of the neck will reveal the presence of other enlarged or tender cervical nodes. Examination of the heart, lungs, abdomen, skin, and nervous system provides information about the degree of systemic toxicity from a focal neck infection and may uncover other findings suggestive of an illness that would result in an inflamed superficial cervical node (e.g., Kawasaki syndrome).

Figure 1. Lymph Nodes of the Head and Neck

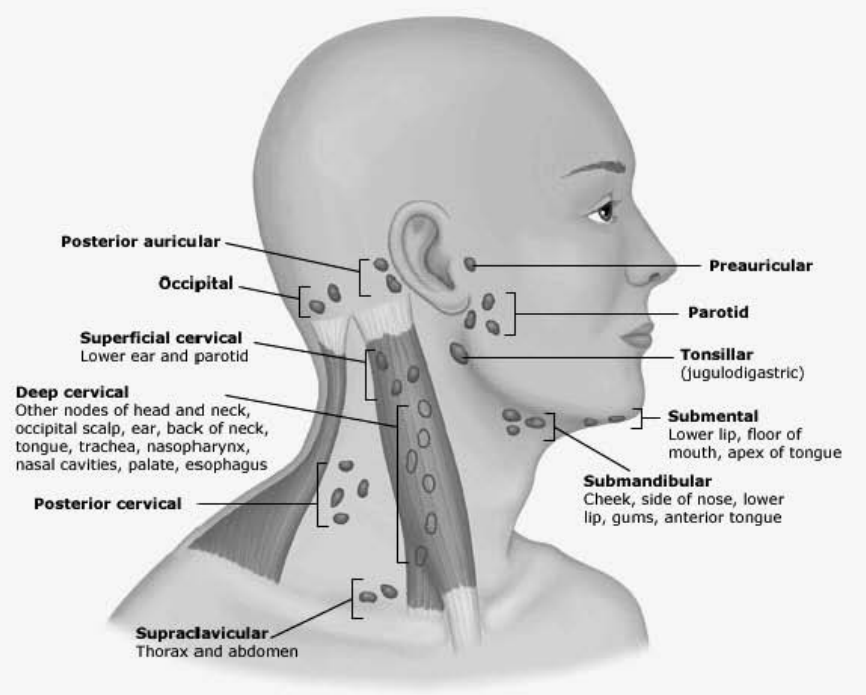

Figure used with permission from: Swanson S. Etiology and clinical manifestations of cervical lymphadenitis in children. In Up-to-Date, Torchia MM (Ed), Up-To-Date, Waltham, MA, 2013.

Table 2. Differential Diagnosis of Pediatric Neck Infections

Location/Timing	Possible Cause(s)
Acute unilateral	Bacterial (GAS, *S. aureus*, anaerobes)
Acute bilateral	Viral, less likely GAS
Subacute/chronic unilateral	Viral (EBV, CMV)
Subacute/chronic bilateral	NTM, tuberculosis, cat scratch, toxoplasmosis

Differential Diagnosis

An initial differential diagnosis of superficial neck infections may be made by considering both the onset and duration of symptoms (acute, subacute, chronic) as well as the anatomic location of the neck mass. A probable diagnosis based on timing and location is provided in Table 2. In the majority of cases, an acutely inflamed neck mass represents bacterial or viral lymphadenitis. Less common causes of neck swelling should be considered for those masses that are subacute or chronic, in a midline location, or have a history suggestive of an atypical infection or systemic inflammatory process.

Figure 2. Infected Branchial Cleft Cyst

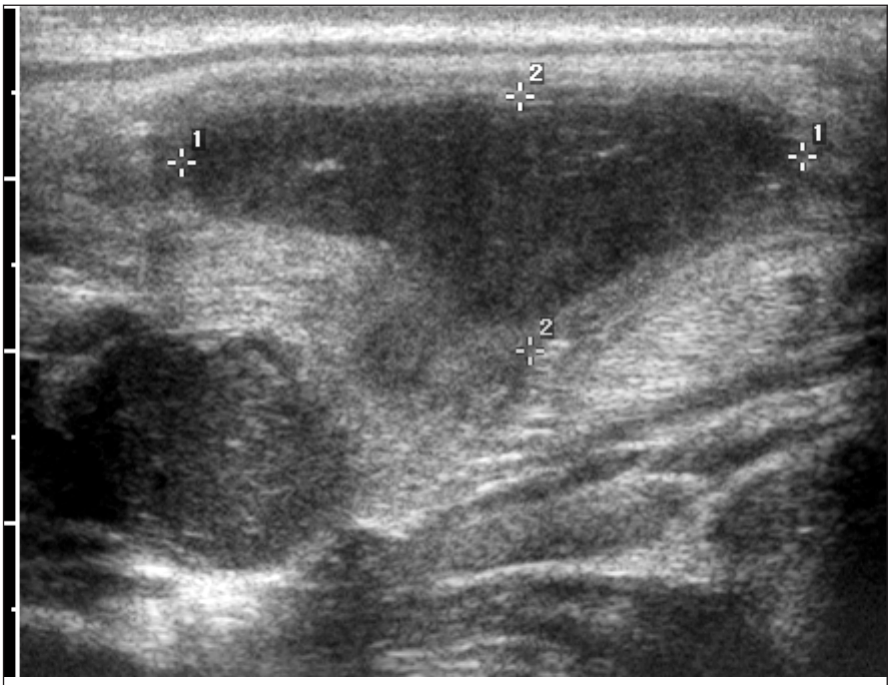

Image courtesy of Dr. Brian Coley

Figure 3. Cervical Adenitis

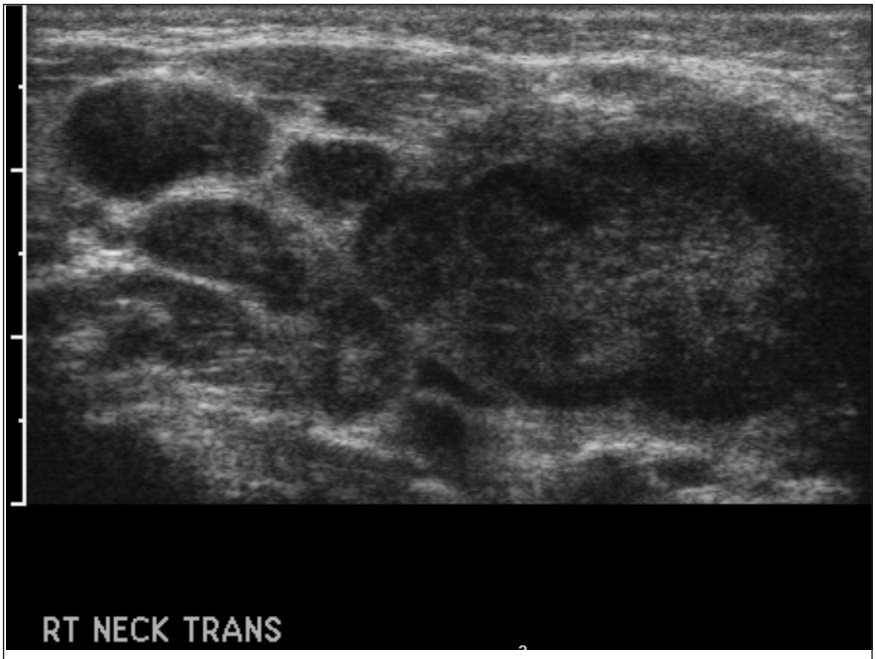

Image courtesy of Dr. Brian Coley

Less Common Infections. Several less common pathogens may cause cervical lymphadenopathy and/or lymphadenitis. Emergency medicine providers should be aware of their presenting signs and historical features, particularly when evaluating a child with a subacute or chronic neck mass.

Tuberculosis is a common cause of cervical adenitis in endemic areas of the world. Cervical node infection occurs via direct spread from the apical pleura or extension from paratracheal nodes. Concurrent symptoms suggestive of tuberculosis infection, as well as exposure risks, should prompt evaluation for this infection.

Nontuberculous mycobacteria (NTM) may cause a slowly growing, non-tender unilateral node. Overlying skin changes and a chronically draining sinus tract may result. This infection is most common in children younger than the age of 5 years and should be considered when a PPD test becomes positive in a child with a neck mass who has no signs or symptoms of active tuberculosis.

Cat scratch disease, caused by *Bartonella henselae*, occurs following a bite or scratch by an infected cat. Following an incubation period of days to weeks, a cervical lymph node may become inflamed. Systemic symptoms may or may not be present. The initial site of inoculation may be distant from the neck, so a careful history and skin examination is critical. *Toxoplasma gondii* may cause chronic tender lymphadenopathy after ingestion of poorly cooked meat. Cats are the definitive host for this organism, so asking about exposure to cats and their litter may lead to this diagnosis. HIV may cause chronic cervical lymphadenitis and should be considered in patients at risk for this infection.

Congenital Malformations. A number of congenital lesions may cause neck masses that may become secondarily infected. An understanding of their typical location in the neck will help inform treatment, imaging, and consultation. The two most common lesions are thyroglossal duct cysts and branchial cleft cysts. Thyroglossal duct cysts are the most common cause of a midline neck mass and are typically located at the level of the thyroid cartilage. Approximately 20% become infected.[2] When infected, initial treatment includes antibiotics,

Figure 4. Management Algorithm for Pediatric Cervical Lymphadenitis

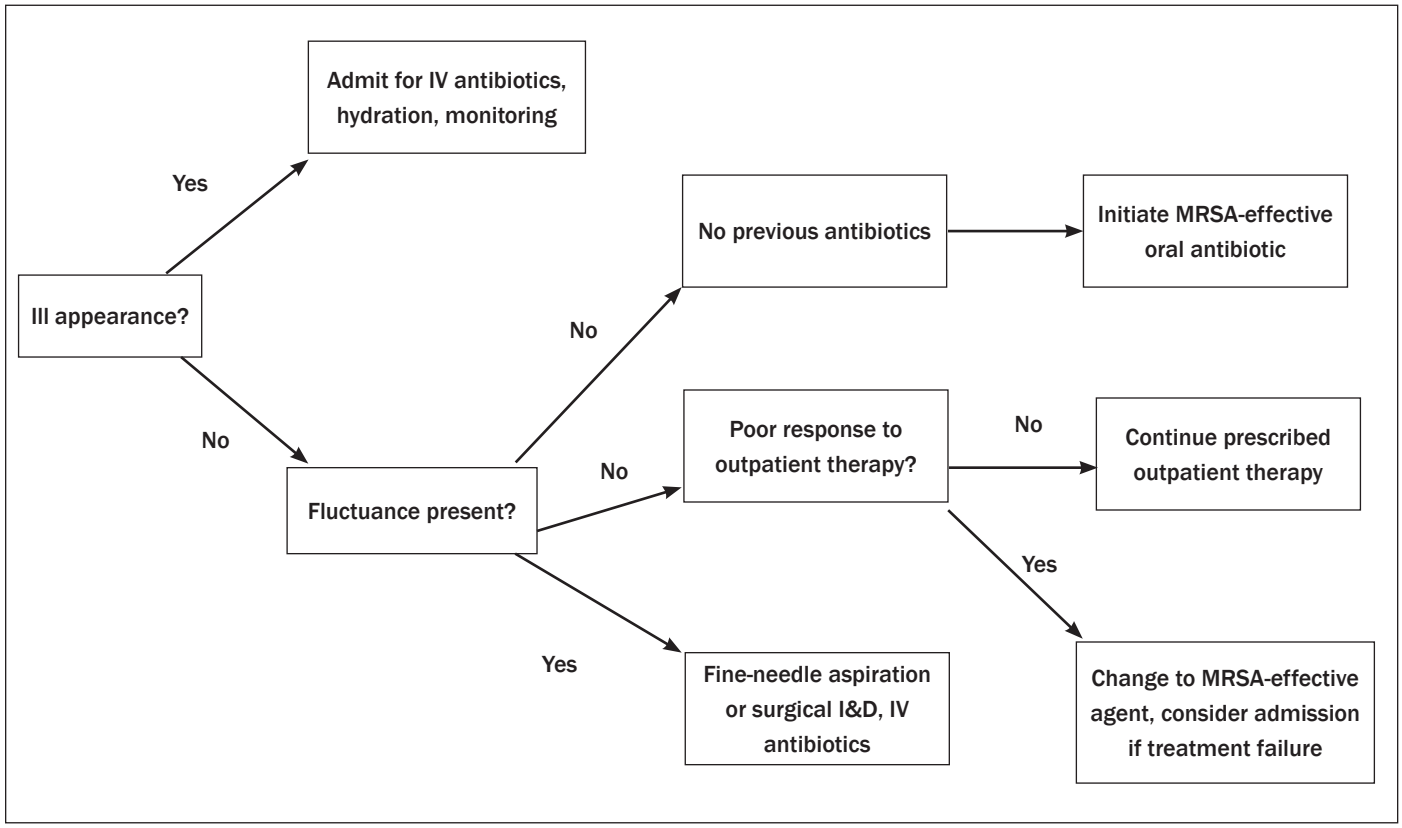

followed by surgical excision.

Branchial cleft cysts, found in the lateral neck, are another common cause of congenital neck masses. (*See Figure 2.*) Second branchial cleft cysts are the most common and appear anterior to the sternocleidomastoid. First, third, and fourth branchial cleft cysts may occur, but much less frequently. Infection of these cysts is not uncommon and may be easily confused with cervical lymphadenitis. A history of a congenital mass in an area of acute inflammation or a recurrent inflammatory mass in the same lateral neck location is helpful. Surgical excision following a period of medical treatment with antibiotics is preferred when these cysts present with acute infection.

Diagnostic Testing

Laboratory Testing. While routine laboratory testing is often unnecessary and nondiagnostic in cases of acute lymphadenitis, elevations in white blood cell count and inflammatory markers may be seen. The presence of atypical lymphocytes on a CBC is suggestive of a viral infection, particularly in the patient with diffuse bilateral lymphadenitis, and may prompt confirmatory testing for Epstein-Barr virus (EBV). For the ill-appearing patient, blood cultures should be collected. If spontaneous purulent drainage is present from a fluctuant neck mass, culturing the purulent fluid will help identify the causative pathogen. When feasible, fine needle aspiration for Gram stain and culture of an infected node can be used to tailor antimicrobial therapy. If the presentation is atypical or if a chronic inflammatory neck mass is present, testing for *Bartonella henselae*, *Toxoplasma gondii,* and/or tuberculosis may be warranted; consultation with an infectious disease expert may be helpful in these cases. Some authors suggest placing a PPD in all pediatric patients presenting with an inflammatory superficial neck mass while monitoring response to antimicrobial treatment.[1,12]

Imaging. In most cases of acute lymphadenitis, the history and physical examination alone are sufficient for diagnosis. However, in cases in which a congenital malformation is suspected, the extent of a neck mass is unclear, or there is a question of whether surgical drainage is needed, imaging may be necessary. Ultrasound is the initial imaging modality of choice for superficial neck masses in children because it lacks radiation and has a high sensitivity for identifying the key structures of the neck. Ultrasonography can accurately identify both normal and inflamed lymph nodes, areas of fluid collection, vascularity of masses, and involvement of other structures of the neck.[13,14] (*See Figure 3.*) In some instances, either when ultrasound is unavailable or non-diagnostic in atypical cases or when there is inadequate response to parenteral antibiotics, computed

Table 3. Antibiotic Treatment for Adenitis

In areas of high MRSA prevalence or if a child has not improved on antibiotic ineffective against MRSA	• Clindamycin 30 mg/kg/day divided every 6-8 hours • Trimethoprim-sulfamethoxazole 10 mg/kg/day for TMP component, divided every 12 hours
If MRSA is not a major concern	• Clindamycin • Cephalexin 25-100 mg/kg/day divided every 6-8 hours • Cefadroxil 30 mg/kg/day divided every 12 hours
If GAS is strongly suspected	Amoxicillin 40 mg/kg/day divided every 12 hours
If periodontal disease is likely culprit	Clindamycin or amoxicillin clavulanate (40 mg/kg/day of amoxicillin component every 12 hours)
If child requires parenteral antibiotics	Clindamycin 40 mg/kg/day divided every 8 hours

tomography (CT) or magnetic resonance imaging may be required. Plain films of the neck are not indicated unless a child has signs of airway compromise and rapid assessment is necessary.

Management

Antibiotics. Since children with diffuse bilateral cervical adenitis are likely to have a viral cause of their presentation, they may be treated expectantly without antibiotics, provided the child is generally well-appearing and there are no signs of associated secondary bacterial infection or superficial skin infection. Children with acute unilateral adenitis or bilateral adenitis with signs of bacterial infection should be treated with an antibiotic that is effective against both GAS and *S. aureus.* In areas where the prevalence of community-acquired MRSA is high or a child has not improved on an antibiotic that is ineffective against MRSA, either clindamycin (30 mg/kg/day divided every 6-8 hours) or trimethoprim-sulfamethoxazole (10 mg/kg/day of the TMP component divided every 12 hours) for 10-14 days would be an ideal choice. If MRSA is not a major concern, clindamycin is still an effective treatment, but cephalexin (25-100 mg/kg/day divided every 6-8 hours) or cefadroxil (30 mg/kg/day divided every 12 hours) may also be used.[12] If GAS is strongly suspected based on concurrent streptococcal pharyngitis, amoxicillin (40 mg/kg/day divided every 12 hours) would be a reasonable alternative. If periodontal disease is present as the likely culprit of adenitis, clindamycin or amoxicillin clavulanate (40 mg/kg/day of the amoxicillin component every 12 hours) are suggested to treat oral flora. Finally, if a child requires parenteral antibiotics, clindamycin (40 mg/kg/day divided every 8 hours) is recommended because of the high incidence of MRSA in cultured aspirates from hospitalized patients; therapy may be subsequently tailored based on culture sensitivities or local MRSA resistance patterns. (*See Table 3.*)

Supportive Care. Since most inflamed superficial neck infections tend to be painful and may cause fever, parents should be instructed on the appropriate use of an analgesic and antipyretic, such as ibuprofen or acetaminophen. Parents may also be instructed to apply warm compresses to areas of induration to help promote infectious accumulation and spontaneous drainage of purulent fluid.

Incision/Drainage. Emergency clinicians must identify those children who are in need of surgical drainage of a superficial neck infection, particularly when adenitis has transformed into a focal abscess. For simple superficial abscesses in older cooperative children, either needle aspiration or incision and drainage may be feasible within the emergency department. However, consultation with a surgeon or otolaryngologist is suggested in the following cases: uncooperative or very timid children who would require procedural sedation; potentially complex abscesses; secondarily infected congenital malformations; and concern about proximity of infection to vital neck structures. A recent retrospective study of 768 pediatric patients evaluated for a superficial neck infection at two tertiary care pediatric emergency departments found that patients without fluctuance on examination, prior antibiotic treatment, or previous emergency room visit had less than a 4% chance of requiring surgical incision and drainage.[9] Based on these findings, it would be reasonable to seek routine consultation in cases in which fluctuance is found on examination or a child has failed to improve or worsened after a trial of appropriate antibiotics.

Disposition. Deciding whether a child requires admission for intravenous antibiotics rather than outpatient oral therapy is largely dependent on clinician judgment and the child's appearance in the emergency department. A child who is generally well-appearing and has no systemic signs of illness may be safely discharged home with oral antibiotics and close outpatient follow-up. Emergency department return criteria should be clearly explained to a patient's guardian(s) and may include increased size and spreading superficial erythema of the neck mass, increased pain and/

or fever, signs of dehydration, and ill appearance. Children who are febrile and exhibiting signs of systemic toxicity, such as dehydration, vomiting, and altered mental status, as well as children requiring surgical drainage of a neck abscess should be admitted for intravenous antibiotics. Figure 4 outlines a management algorithm based on these recommendations.

Summary

Most children presenting to the emergency department with an acutely inflamed superficial neck mass have either a viral or bacterial infection of the cervical lymph nodes. Bacterial adenitis is likely in cases of acute unilateral disease, and GAS and *S. aureus* are the most common pathogens. Initiation of appropriate antibiotic therapy and surgical consultation when incision and drainage is required will often result in complete resolution of infectious symptoms without any complications. Emergency clinicians should be mindful that when a superficial neck mass is midline and/or chronic in nature, alternative diagnoses should be considered.

Deep Neck Space Infections

Case 2. A 4-year-old boy presents with a hoarse voice associated with neck pain and stiffness three days into an illness characterized by nasal congestion, throat pain, and cough. He is non-toxic but appears to be in pain. His temperature is 38.5° Celsius, and he is mildly tachycardic. He has no visible neck swelling or meningeal signs, but he resists passive extension and lateral rotation of his neck.

What clinical features suggest a deep neck space infection? What deep neck spaces/structures may be involved? What mode(s) of imaging should be considered? Is immediate surgical intervention necessary? What antibiotic(s) are most appropriate? What complications may occur?

Definition and Epidemiology

Several deep structures of the neck are prone to infection in children. While these infections are far less common than those in the superficial neck, the potential complications, including airway compromise, mediastinitis, CNS involvement, and sepsis, make them a major concern for emergency practitioners. Since a spectrum of disease severity and location of deep neck infections exist in children, true epidemiologic data about their incidence are difficult to describe.[15] One study demonstrated that children requiring surgical intervention for deep neck space infections tend to be young (average age 4 years), male, and of white or black race. Age is also an important epidemiologic factor, as children younger than 10 years of age are more likely to develop a retropharyngeal or parapharyngeal abscess (mean age 5 years), whereas children and adolescents older than 10 years of age are more likely to present with a peritonsillar abscess.[16]

Anatomy

The deep neck is divided into three layers (superficial, middle, and deep) by fascial planes that extend upward into the cranium and downward into the mediastinum. Several critical structures are within these planes and help create important anatomic spaces. Specifically, the submandibular, parapharyngeal, masticator, buccal, parotid, peritonsillar, retropharyngeal, prevertebral, vascular, and danger spaces are all potential sites of infection. The most common spaces infected in children, in descending order of frequency, are the peritonsillar, retropharyngeal, submandibular, buccal, and parapharyngeal spaces.[15]

Etiology and Pathophysiology

Typically, the microbiologic profile of deep neck infections reflects the bacteria that cause infection of the teeth, tonsils, deep cervical nodes, middle ear, and sinuses.[17] The deep neck spaces contain lymphoid tissue that may become seeded with bacteria arising from concurrent infection in these areas. An inflammatory response follows, leading to development of lymphadenitis and/or cellulitis. Necrosis and breakdown of infected nodes leads to abscess formation and possible spread of infectious material within and through fascial planes. The most common pathogens isolated include *S. aureus*, GAS, and oral anaerobes. In many cases, however, infectious isolates are polymicrobial.

Figure 5. Lateral Radiograph Suggestive of Retropharyngeal Abscess

Image courtesy of: James Heilman, MD
http://en.wikipedia.org

Clinical Features

History. Determining which children have deep neck space infections based on history alone may be challenging. Many children will have a non-specific history of rhinorrhea, cough, fever, poor oral intake, dysphagia, and agitation. A history of voice change, drooling, trismus, and neck pain may be more specific but more difficult to obtain from a young child.[18] Historical factors that may put a child at risk for developing a deep neck infection should be elicited, including premature birth, immunosuppression, previous history of severe infection or sepsis, and recent ear, nose, and throat infection. In general, a thorough history about symptom onset, duration,

Figure 6. Plain Film of Retropharyngeal Abscess

Image courtesy of Dr. Brian Coley

Figure 7. CT of Retropharyngeal Abscess

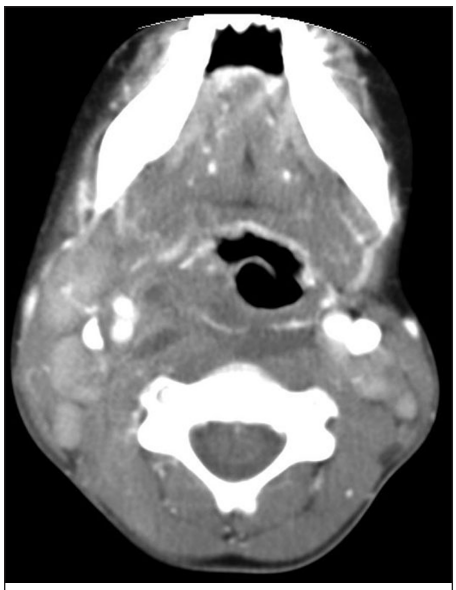

Image courtesy of Dr. Brian Coley

and associated signs of illness is important.

Physical Examination. Immediate assessment of the vital signs and airway patency is extremely important in a child with a suspected deep neck infection. The presence of excessive drooling, stridor, and respiratory accessory muscle use suggests imminent or progressive airway compromise. These findings should prompt urgent consideration of airway management in consultation with an anesthesiologist and/or otolaryngologist, given the potential difficulty and complications of endotracheal intubation. Fever is usually present, and dehydration secondary to odynophagia and poor oral intake is common.

The oropharynx should be examined for signs of concurrent infection. The dentition should be inspected for signs of disease that may lead to spreading infection. The tonsils should be examined for signs of edema, erythema, asymmetry, and fluctuance. A deviated uvula in association with an asymmetrically enlarged and exudative tonsil is seen with a peritonsillar abscess. Medial displacement of the lateral pharyngeal wall and tonsil suggests a parapharyngeal process. The neck should be visually inspected and palpated for associated lymphadenopathy, swelling, and induration. Of these findings, a large retrospective review found induration to be the most common presenting sign in 88% of patients.[19] Neck range of motion is often limited due to pain and inflammation, and torticollis may be present. A complete examination of the patient is necessary to help determine the degree of associated systemic toxicity affecting other organ systems.

Diagnostic Testing

Laboratory Testing. Routine laboratory testing, such as metabolic panels, CBC, and inflammatory markers, is not diagnostic for deep neck infections. Patients with these infections are likely to have an elevation of white blood cell count, but may not have elevations in CRP.[20] Surveillance monitoring of WBC during treatment may be helpful. When there is clinical concern for sepsis, blood cultures should be obtained.

Imaging. Lateral neck radiographs are easily accessible and may be a helpful screening tool for cases of suspected retropharyngeal abscess. With the neck properly extended, an increased width of the prevertebral soft tissues is quite sensitive and specific for detecting the presence of retropharyngeal edema. (*See Figures 5 and 6.*) The presence of air-fluid levels is even more suggestive of a suppurative process. If a parapharyngeal process is suspected or a high nasopharyngeal retropharyngeal abscess is possible, plain radiographs have limited utility.[21]

CT is considered the gold standard for detecting inflammatory processes in the deep neck. (*See Figure 7.*) It provides critical information for the surgical consultant when incision and drainage is anticipated and when the expected response to appropriate parenteral antibiotics is lacking.

One study of 179 children evaluated for deep neck space infection found the duration of symptoms did not impact the rate of abscess identification, making it useful even early in the course of illness.[20] Recent evidence, however, suggests that CT, while having a high positive predictive value, may be overly sensitive for detecting abscesses that may not require surgical drainage.[22] Thus, the emergency provider should understand that not all documented cases of deep neck abscess require immediate surgical intervention. Consultation with an otolaryngologist will help guide conservative medical management and surgical staging.

Ultrasound is an intriguing modality given its availability, low cost, and lack of radiation. Some studies suggest ultrasound may actually be equal to, or even superior to, CT for detecting the presence of neck abscesses.[23,24] However, reliable use of ultrasound is dependent on skilled sonographers and radiologists who feel comfortable diagnosing these infections in children using this imaging modality. Additionally, most surgical consultants will prefer more detailed anatomical information provided by CT before surgical intervention on the neck.

Management

Antibiotics. Initiating antibiotic therapy in the child with a confirmed

or probable deep neck space infection is imperative. Many cases, particularly those with small abscesses or phlegmon, may ultimately be treated conservatively with antibiotics alone.[25,26] Since the majority of cases are caused by GAS, *S. aureus,* or anaerobes, initial empiric therapy often includes either parenteral clindamycin or ampicillin-sulbactam.

Surgical Consultation. Consultation with an otolaryngologist is suggested for all cases of deep neck infection. Recent evidence suggests many cases may be treated solely with antibiotics and never require surgical intervention.[27] One study of 187 pediatric patients with either retropharyngeal or parapharyngeal abscesses found that age younger than 51 months and CT evidence of an abscess greater than 2.2 cm in size was associated with a greater risk of conservative medical failure requiring surgical drainage.[28] Based on most data, three distinct populations exist: children who improve with antibiotics alone, children who fail to respond to conservative management and require surgical intervention, and children who require immediate surgical drainage. Unless a child presents with signs of imminent airway compromise or mediastinitis necessitating immediate surgery, most cases are amenable to a trial of conservative medical therapy before proceeding to the operating room.

Disposition. While no consensus guidelines exist for the management of children with deep neck space infections, the potential for airway compromise, inability to tolerate fluids, and unclear course of illness in most children warrants admission for intravenous antibiotics and hydration, as well as cardiorespiratory monitoring. No studies have examined the effectiveness of outpatient oral antibiotics on outcomes for most deep neck space infections, so this approach is not recommended. The exception would be the well-appearing child with a peritonsillar abscess that has been effectively addressed in the emergency department with fine-needle aspiration. For these patients who are able to tolerate fluids, outpatient oral antibiotic therapy and pain control is appropriate.

Figure 8. CT of Lemierre Syndrome

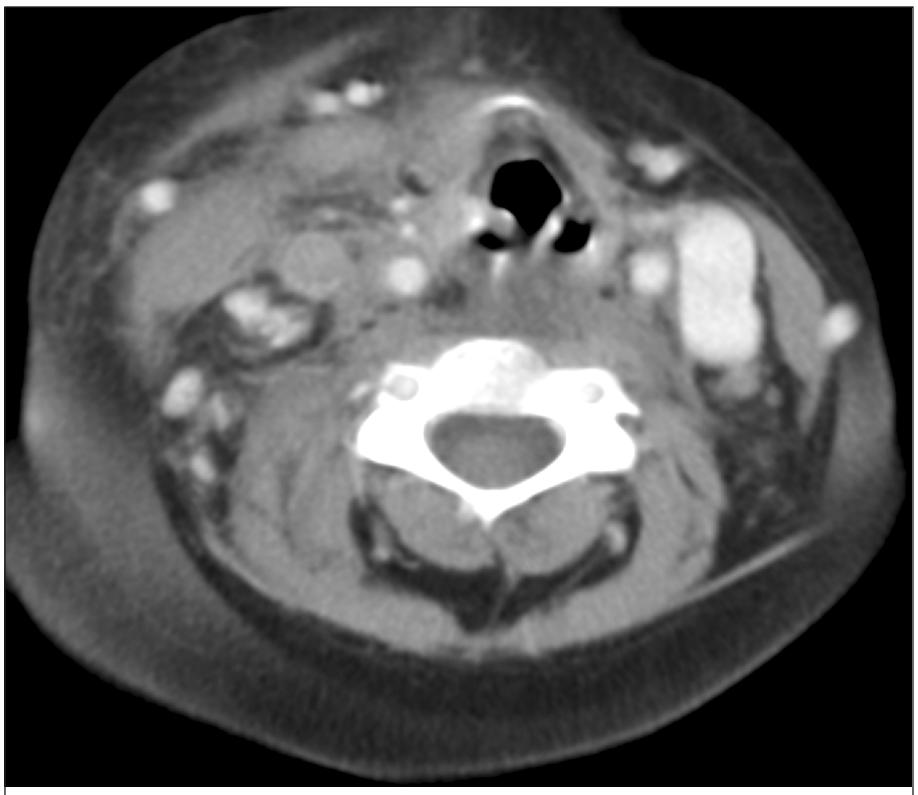

Image courtesy of Dr. Brian Coley

Infectious Complications

Mediastinitis. Since the retropharyngeal space extends into the mediastinum, infection and extension within the space may lead to life-threatening mediastinal infection. This may be a rapidly progressive process and is a surgical emergency when detected. One study found this complication in 6.5% of pediatric patients with retropharyngeal abscess; younger age was the most significant contributing factor.[29]

Lemierre Syndrome. Deep neck infections may cause internal jugular vein thrombosis and subsequent septic embolization. Fusobacterium is the classic pathogen implicated, but others, including MRSA, have also been isolated.[30] Aggressive medical therapy, sometimes including anticoagulation, is necessary. This diagnosis should be considered in the ill-appearing patient, often adolescent, with localized neck pain, high fever, and respiratory distress due to septic emboli.[31] (*See Figure 8.*)

Summary

Deep neck infections are relatively uncommon in children, but their potential consequences, if missed or left untreated, may be devastating. Emergency medicine providers should have a high level of suspicion for these infections in the child with a preceding or concurrent upper respiratory, dental, throat, or ear infection presenting with new or progressive symptoms of fever with neck pain and stiffness. A number of spaces within the deep neck structures may become secondarily infected with cellulitis, lymphadenitis, and abscess formation.

CT is the gold standard imaging modality for diagnosing deep neck space infections, but it may be overly sensitive in detecting phlegmon or abscesses that may not require

surgical drainage.

Initiating antibiotic therapy promptly is important, while consulting an otolaryngologist regarding surgical treatment.

References

1. Harper MB, Fleisher GR. Infectious disease emergencies. In: Fleisher GR, Ludwig S, et al, eds. *Textbook of Pediatric Emergency Medicine*. 6th ed. Philadelphia: Lipincott Williams & Wilkens; 2010: 905-907.
2. Bly RA, Parikj SR. Neck masses and adenopathy. In: Schoem SR, Darrow DH, eds. *Pediatric Otolaryngology*. Elk Grove Village, IL: American Academy of Pediatrics; 2012:251-271.
3. Larrson LO, Bentzon MW, Berg Kelly K, et al. Palpable lymph nodes of the neck in Swedish schoolchildren. *Acta Paediatr* 1994;83:1091-1094.
4. Citak EC, Koku N, Demirci M, et al. A retrospective chart review of evaluation of the cervical lymphadenopathies in children. *Auris Nasus Larynx* 2011;38: 618-621.
5. Naseri I, Jerris RC, Sobol SE. Nationwide trends in pediatric Staphylococcus aureus head and neck infections. *Arch Otolaryngol Head Neck Surg* 2009;135(1):14-16.
6. Walker PC, Karnell LH, Ziebold C, et al. Changing microbiology of pediatric neck abscesses in Iowa 2000-2010. *Laryngoscope* 2013;123(1):249-252.
7. McCormick ME, Chun RH, Lander L, et al. Socioeconomic implications of pediatric cervical methicillin-resistant *Staphylococcus aureus* infections. *JAMA Otolaryngol Head Neck Surg* 2013;139:124-128.
8. Swanson DS. Etiology and clinical manifestations of cervical lymphadenitis in children. In: *UpToDate*, Torchia MM (Ed), UpToDate, Waltham, MA, 2013.
9. Sauer MW, Sharma S, Hirsh DA, et al. Acute neck infections in children: Who is likely to undergo surgical drainage? *Am J Emerg Med* 2013;31:906-909.
10. Neff L, Newland JG, Sykes KJ, et al. Microbioloigy and antimicrobial treatment of pediatric cervical lymphadenitis requiring surgical intervention. *International Journal of Pediatric Otorhinolaryngology* 2013;77:817-820.
11. Duggal P, Naseri I, Sobol SE. The increased risk of community-acquired methicillin-resistant *Staphylococcus aureus* neck abscesses in young children. *Laryngoscope* 2011;121(1):51-55.
12. Healy CM. Diagnostic approach to and initial management of cervical lymphadenitis in children. In: *UpToDate*, Torchia MM (Ed), UpToDate, Waltham, MA, 2013.
13. Friedman ER, John SD. Imaging of pediatric neck masses. *Radiol Clin North Am* 2011;49:617-632.
14. Rosenberg HK. Sonography of pediatric neck masses. *Ultrasound Q* 2009;25(3):111-127.
15. Jaryszak EM, Choi SS. Deep neck space infections. In: Schoem SR, Darrow DH, eds. *Pediatric Otolaryngology*. Elk Grove Village, IL: American Academy of Pediatrics; 2012:273-299.
16. Coticchia JM, Getnick GS, Yun RD, et al. Age-, site-, and time-specific differences in pediatric deep neck abscesses. *Arch Otolaryngol Head Neck Surg* 2004;130:201-207.
17. Chow AW. Deep neck space infection. In: *UpToDate*, Thorner AR (Ed), UpToDate, Waltham, MA, 2013.
18. Elden LM, Potsic WP. Otolaryngologic emergencies. In: Fleisher GR, Ludwig S, et al, eds. *Textbook of Pediatric Emergency Medicine*. 6th ed. Philadelphia: Lipincott Williams & Wilkens; 2010:1556-1558.
19. Eftekharian A, Roozbahany NA, Vaezeafshar R, et al. Deep neck infections: a retrospective review of 112 cases. *Eur Arch Otorhinolaryngol* 2009;266(2): 273-277.
20. Meyer AC, Kimbrough TG, Finkelstein M, et al. Symptom duration and CT findings in pediatric deep neck infection. *Otolaryngol Head Neck Surg* 2009;140(2):183-186.
21. Uzomefuna V, Glynn F, Mackle T, et al. Atypical locations of retropharyngeal abscess: Beware of the normal lateral soft tissue neck X-ray. *Int J Pediatr Otorhinolaryngol* 2010;74(12): 1445-1448.
22. Freling N, Roele E, Schaefer-prokop C, Fokkens W. Prediction of deep neck abscesses by contrast-enhanced computerized tomography in 76 clinically suspect consecutive patients. *Laryngoscope* 2009;119(9):1745-1752.
23. Rozovsky K, Hiller N, Koplewitz BZ, Simanovsky N. Does CT have an additional diagnostic value over ultrasound in the evaluation of acute inflammatory neck masses in children? *Eur Radiol* 2010;20(2):484-490.
24. Mallorie CN, Jones SD, Drage NA, et al. The reliability of high resolution ultrasound in the identification of pus collections in head and neck swellings. *Int J Oral Maxillofac Surg* 2012;41(2): 252-255.
25. Grisaru-Soen G, Komisar O, Aizenstein O, et al. Retropharyngeal and parapharyngeal abscess in children — epidemiology, clinical features and treatment. *Int J Pediatr Otorhinolaryngol* 2010;74(9):1016-1020.
26. Boscolo-rizzo P, Stellin M, Muzzi E, et al. Deep neck infections: A study of 365 cases highlighting recommendations for management and treatment. *Eur Arch Otorhinolaryngol* 2012;269(4): 1241-1249.
27. Wong DK, Brown C, Mills N, Spielmann P, Neeff M. To drain or not to drain — management of pediatric deep neck abscesses: A case-control study. *Int J Pediatr Otorhinolaryngol* 2012;76: 1810-1813.
28. Cheng J, Elden L. Children with deep space neck infections: Our experience with 178 children. *Otolaryngol Head Neck Surg* 2013;148:1037-1042.
29. Baldassari CM, Howell R, Amorn M, et al. Complications in pediatric deep neck space abscesses. *Otolaryngol Head Neck Surg* 2011;144(4):592-595.
30. Bentley TP, Brennan DF. Lemierre's syndrome: Methicillin-resistant *Staphylococcus aureus* (MRSA) finds a new home. *J Emerg Med* 2009;37(2):131-134.
31. Li HY, Grubb M, Panda M, Jones R. A sore throat — potentially life-threatening? *J Gen Intern Med* 2009;24(7):872-875.

CME Questions

1. You are evaluating a patient with a red, swollen, and tender neck mass. What clinical feature is most suggestive of a secondarily infected congenital malformation in this patient?
   A. acute onset of symptoms
   B. recent upper respiratory infection
   C. midline location
   D. no previous history of swelling in the same location

2. You are planning to discharge a 5-year-old girl home with a course of oral

Pediatric Emergency Medicine Reports

CME Objectives

Upon completion of this educational activity, participants should be able to:

- recognize specific conditions in pediatric patients presenting to the emergency department;
- describe the epidemiology, etiology, pathophysiology, historical and examination findings associated with conditions in pediatric patients presenting to the emergency department;
- formulate a differential diagnosis and perform necessary diagnostic tests;
- apply up-to-date therapeutic techniques to address conditions discussed in the publication;
- discuss any discharge or follow-up instructions with patients.

antibiotics for a diagnosis of acute unilateral lymphadenitis. Based on the typical microbiologic profile of this type of infection, which antibiotic would be most appropriate?

A. azithromycin
B. clindamycin
C. penicillin
D. amoxicillin

3. A 4-year-old boy with rhinorrhea and cough has multiple bilateral, slightly enlarged, and mildly tender anterior cervical lymph nodes present on examination. He is otherwise well-appearing and has no other signs of systemic illness. What is the most appropriate management decision at this time?

A. treat for presumptive group A streptococcus-associated lymphadenitis
B. place a PPD and obtain a CXR
C. provide reassurance and encourage appropriate outpatient follow-up
D. obtain a neck soft tissue ultrasound to evaluate for a drainable fluid collection

4. What clinical feature is most strongly associated with a cervical abscess requiring incision and drainage?

A. fluctuance
B. no prior antibiotic treatment
C. elevated WBC count
D. fever

5. A young child presents with an acutely swollen, red, and tender right neck mass just anterior to the sternocleidomastoid. Her parents say that there has been swelling in the same area previously. You suspect a secondarily infected cyst of which most common branchial cleft remnant?

A. first
B. second
C. third
D. fourth

6. A child presents to the emergency department with a lateral neck mass that is tender and indurated. The mass appeared acutely during an upper respiratory infection. He has been on amoxicillin for the past two days without improvement in size of swelling and now has some overlying skin erythema. He has been afebrile and otherwise well-appearing. Which management decision would be most appropriate at this time?

A. admit for IV antibiotics and fluid resuscitation
B. perform a bedside fine needle aspiration for culture and Gram stain
C. change his antibiotic to a MRSA-effective agent and arrange for outpatient follow-up in 1-2 days
D. consult a surgeon for biopsy

7. Which deep neck space is most commonly infected in the pediatric population?

A. parapharyngeal
B. peritonsillar
C. retropharyngeal
D. submandibular

8. You obtain a lateral neck film on a patient with a suspected deep neck space infection. The radiologist calls to report widening of the prevertebral soft tissue with an associated air-fluid level at C2/C3. This finding is suggestive of which deep space infection?

A. retropharyngeal abscess
B. epiglottitis
C. laryngotracheobronchitis
D. peritonsillar abscess

9. Which pathogen is most commonly associated with internal jugular vein thrombosis?

A. MRSA
B. group A streptococcus
C. *Fusobacterium* sp.
D. group B streptococcus

10. While conservative medical therapy is effective for many cases of deep neck space infections, what clinical feature is more likely to require definitive surgical drainage after a period of watchful waiting?

A. elevation of white blood cell count
B. elevation of CRP
C. duration of symptoms > 48 hours prior to seeking treatment
D. abscess > 2 cm on imaging

CME Instructions

HERE ARE THE STEPS YOU NEED TO TAKE TO EARN CREDIT FOR THIS ACTIVITY:

1. Read and study the activity, using the provided references for further research.

2. Log on to **www.cmecity.com** to take a post-test; tests can be taken after each issue or collectively at the end of the semester. *First-time users will have to register on the site using the 8-digit subscriber number printed on their mailing label, invoice, or renewal notice.*

3. Pass the online tests with a score of 100%; you will be allowed to answer the questions as many times as needed to achieve a score of 100%.

4. After successfully completing the last test of the semester, your browser will be automatically directed to the activity evaluation form, which you will submit online.

5. **Once the completed evaluation is received, a credit letter will be e-mailed to you instantly.**

Pediatric Emergency Medicine Reports™
(ISSN 1082-3344) is published monthly by AHC Media LLC, One Atlanta Plaza, 950 East Paces Ferry Road NE, Suite 2850, Atlanta, GA 30326. Telephone: (800) 688-2421 or (404) 262-7436.

Editorial Director: Lee Landenberger
Executive Editor: Shelly Morrow Mark
Managing Editor: Leslie Hamlin

GST Registration No.: R128870672
Periodicals Postage Paid at Atlanta, GA 30304 and at additional mailing offices.

POSTMASTER: Send address changes to *Pediatric Emergency Medicine Reports*, P.O. Box 550669, Atlanta, GA 30355.

Back issues: $65. Missing issues will be fulfilled by customer service free of charge when contacted within one month of the missing issue's date.

Subscriber Information

Customer Service: 1-800-688-2421

Customer Service E-Mail Address:
customerservice@ahcmedia.com
Editorial E-Mail Address: shelly.mark@ahcmedia.com
World-Wide Web page: http://www.ahcmedia.com

Subscription Prices

1 year with 30 ACEP, AMA, or AAP Category 1 credits: $439;
1 year without credit: $389;
Add $17.95 for shipping & handling
Multiple copies:
Discounts are available for group subscriptions, multiple copies, site-licenses or electronic distribution. For pricing information, call Tria Kreutzer at 404-262-5482.
One to nine additional copies: **$350 each;**
10 or more additional copies: **$311 each.**
Resident's Rate: **$194.50**
All prices U.S. only. U.S. possessions and Canada, add $30 postage plus applicable GST.

Accreditation

AHC Media is accredited by the Accreditation Council for Continuing Medical Education to provide continuing medical education for physicians.

AHC Media designates this enduring material for a maximum of 30 *AMA PRA Category 1 Credits™*. Physicians should claim only credit commensurate with the extent of their participation in the activity.

Approved by the American College of Emergency Physicians for a maximum of 30.00 hour(s) of ACEP Category I credit.

This continuing medical education activity has been reviewed by the American Academy of Pediatrics and is acceptable for a maximum of 30.0 AAP credits. These credits can be applied toward the AAP CME/CPD Award available to Fellows and Candidate Members of the American Academy of Pediatrics.

This CME activity is intended for emergency and pediatric physicians. It is in effect for 36 months from the date of the publication.

This is an educational publication designed to present scientific information and opinion to health professionals, to stimulate thought, and further investigation. It does not provide advice regarding medical diagnosis or treatment for any individual case. It is not intended for use by the layman. Opinions expressed are not necessarily those of this publication. Mention of products or services does not constitute endorsement. Clinical, legal, tax, and other comments are offered for general guidance only; professional counsel should be sought for specific situations.

AHC Media

Exclusive to our subscribers

Rapid Access Management Guidelines

Pediatric Emergency Medicine Reports

Practical, Evidence-Based Reviews in Pediatric Emergency Care

Infections of the Neck in Children

Anatomic Diagnosis of Neck Masses

Location	Possible Cause
Midline, above thyroid	Thyroglossal duct cyst, dermoid, laryngocele
Midline, near/overlying thyroid	Thyromegaly, thyroid nodule
Lateral, anterior to sternocleidomastoid	Lymph node(s), branchial cleft cysts
Lateral, posterior to sternocleidomastoid	Lymph node(s), cystic hygroma
Supraclavicular	Lymph node(s), malignancy

Differential Diagnosis of Pediatric Neck Infections

Location/Timing	Possible Cause(s)
Acute unilateral	Bacterial (GAS, *S. aureus*, anaerobes)
Acute bilateral	Viral, less likely GAS
Subacute/chronic unilateral	Viral (EBV, CMV)
Subacute/chronic bilateral	NTM, tuberculosis, cat scratch, toxoplasmosis

Infected Branchial Cleft Cyst

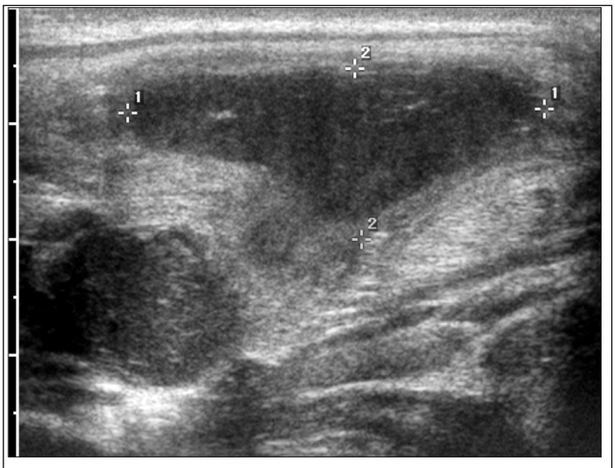

Image courtesy of Dr. Brian Coley

CT of Lemierre Syndrome

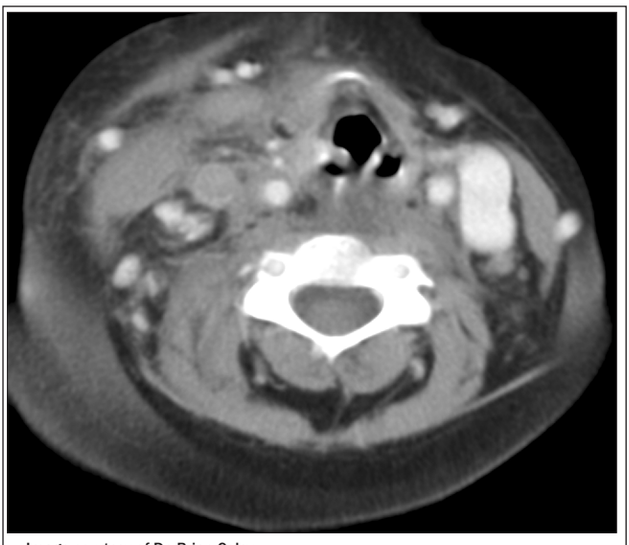

Image courtesy of Dr. Brian Coley

Management Algorithm for Pediatric Cervical Lymphadenitis

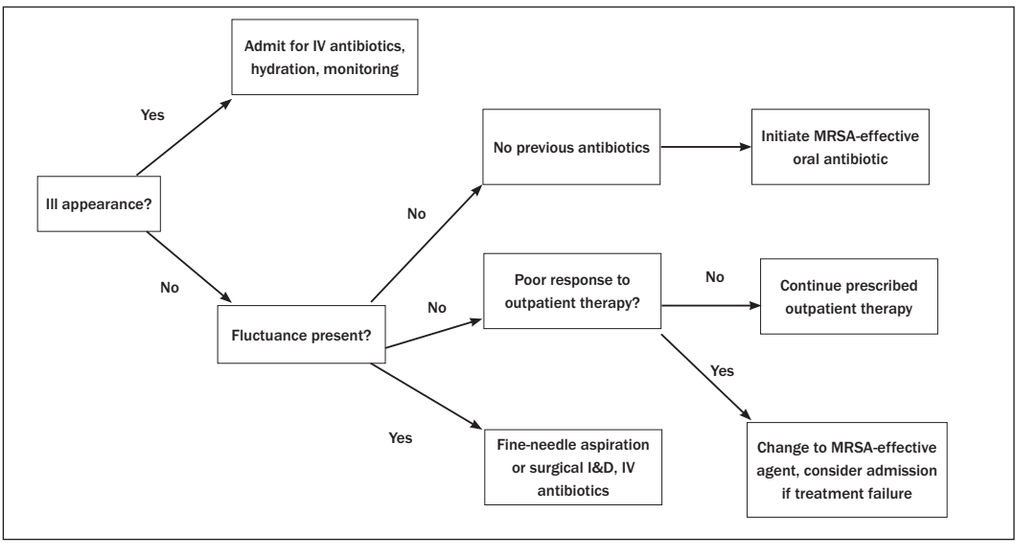

Cervical Adenitis

Image courtesy of Dr. Brian Coley

Plain Film of Retro-pharyngeal Abscess

Image courtesy of Dr. Brian Coley

CT of Retropharyngeal Abscess

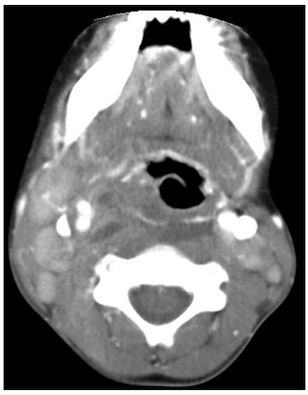

Image courtesy of Dr. Brian Coley

Supplement to *Pediatric Emergency Medicine Reports*, December 2013: "Infections of the Neck in Children." *Authors:* **Adam Nicholson, MD**, Fellow, Pediatric Emergency Medicine, Northwestern McGaw, Ann & Robert H. Lurie Children's Hospital of Chicago, IL; and **Walter Eppich, MD, MEd**, Assistant Professor of Pediatrics and Medical Education, Northwestern University Feinberg School of Medicine, Ann & Robert H. Lurie Children's Hospital of Chicago, IL.

Pediatric Emergency Medicine Reports

Practical, Evidence-Based Reviews in Pediatric Emergency Care

Cumulative Index
Volume 18, Numbers 1-12, Pages 1-156
January–December 2013

AHC Media