AMERICAN HEALTH CONSULTANTS®

Rapid Reference Card Enclosed

The Practical Journal for Emergency Physicians

Emergency Medicine Reports

Volume 23, Number 24 November 18, 2002

Accurate diagnosis and assessment of the acutely injured hand requires a systematic evaluation of the patient's signs, symptoms, and physical findings. Because failure to diagnose severe hand injuries is associated with significant medical legal risk, emergency physicians should access the surgeons specializing in hand injuries whenever the diagnosis or management plan is in doubt. In this article (part two of a three-part series), the author provides a comprehensive review and management strategies for common hand fractures and neurovascular injuries.

—The Editor

The Acute Hand: Assessment, Diagnosis, and Management in the ED Setting

Part II: Fractures and Neurovascular Injuries

Author: **Gary D. Hals, MD, PhD**, Attending Physician, Department of Emergency Medicine, Palmetto Richland Memorial Hospital, Columbia, SC.

Peer Reviewers: **Alasdair K.T. Conn, MD**, Chief of Emergency Services, Massachusetts General Hospital; **Andrew Perron, MD, FACEP**, Assistant Professor of Emergency Medicine, Associate Residency Director, Department of Emergency Medicine, University of Virginia, Charlottesville.

Trauma

Fractures. The bones of the hand are the most commonly fractured of all bones in the body.[1] When not treated appropriately, hand fractures often result in significant disability and loss of function. One study of 110 patients with distal tuft fractures found that at six months after injury, 31% of fractures had not healed as shown by radiograph, and 70% had complications of numbness, pain, and cold intolerance.[2] Consequently, hand fractures make up a large portion of worker's compensation cases that result in permanent disability. Hand fractures are described in terms of the location, angulation, and type of fracture. (*See Figure 1.*) Open fractures will require consultation with a hand specialist because they need expeditious irrigation and reduction in the operating room (OR). Other indications for fixation include intraarticular fractures, rotational deformity, polytrauma to the hand, bone loss, and multiple hand fractures. Fracture/dislocation injuries also require urgent consultation with the hand surgeon. Some hand surgeons may elect to place Kirschner wires (K-wires) in the emergency department (ED) instead of the OR, and at least one study supports that there were no more frequent complications when K-wires were placed in the ED setting.[3] The sections below will focus on treatment of closed injuries that usually can be treated and discharged from the ED and follow-up with the hand surgeon. (*See Table 1.*)

Distal Phalanx. Distal phalanx fractures, specifically tuft fractures, are the most common fractures in the hand. They usually result from crush injuries of the fingertip, but because of the

fibrous nature of the finger pulp and presence of the nail, rarely are displaced. The associated swelling accounts for much of the throbbing pain they cause. Treatment of tuft fractures involves using a short finger splint for several days to protect the fingertip. Be sure that it does not include the proximal interphalangeal (PIP) joint, as unnecessary joint stiffness can result from this immobilization.

Nailbed injuries also are common in ED patients, and deserve special consideration. They commonly result from crush injuries, and up to 50% may be associated with distal tuft fractures.[4] Subungual hematoma is a frequent complication and can produce significant pain. As a general rule, if the hematoma involves greater than 50% of the nail area, it should be drained with a heated paper clip or microcautery device. This only is recommended for the acute phase, because after 24 hours have passed, attempts at drainage of the hematoma are not as likely to reduce pain. Distal tuft fractures associated with subungual hematomas technically are open fractures, although they do not have a high risk for infection.[1]

Another consideration of a large subungual hematoma is laceration of the nailbed. One study found that occult nailbed lacerations were seen in 95% of patients with a hematoma more than 50% of the nail area when distal tuft fracture also was present.[5] Without an associated fracture, the incidence of nailbed laceration requiring repair was only 50% for the same size hematoma. While Green's textbook does recommend repair of nailbed lacerations, two recent prospective studies support that simple trephination alone provides a good outcome in 85% of patients.[5,6] In one of the studies, the authors state that no variables were identified that allowed the ED physician to predict which patients later would experience complications.[6]

When repairing the nailbed laceration, the entire nail first should be removed intact (if possible) by blunt dissection after digital block. The physician should look for any nailbed tissue in the fracture site and remove it to reduce the risk of nonunion. Repair with 6-0 absorbable suture, and then replace the nail in the nail fold to prevent adherence at the germinal matrix and subsequent abnormal nail growth. If the nail is unavailable or unsuitable for replacement, a single layer of petroleum jelly gauze should be used as a stent in the nail fold. The nail should be sutured on both sides to maintain its proper position while healing occurs. However, one study of 90 fingertip injuries found no difference in nail outcome between patients who had the nail replaced and those who did not.[7] They found a direct correlation between the severity of the original injury and future nail growth. When the nail is replaced, most authors recommend also trephinating the replaced nail to allow for drainage. The fingertip should be splinted for protection and left alone for the next 5-7 days unless signs of infection develop. The nail can be left sutured in place for three weeks. As patients with nailbed laceration repair will require care for the next several weeks, referral to a hand surgeon for this follow-up care is recommended. Any patient with a nailbed injury always should be instructed that the nail may fall off and whether or how the nail will grow back cannot be predicted. Most fingernails will take up to three or four months for full growth; therefore, much time will pass before the outcome will be known.

Proximal and Middle Phalanx. These fractures usually present as transverse or oblique fractures. Transverse fractures often are the result of a direct blow, while oblique fractures result from a twisting injury. The physician must be careful to evaluate for injury to digital nerves or vessels, or for tendon disruption when treating these fractures. Most proximal and middle phalanx fractures will be seen easily on radiographs, except for fractures of the neck or intraarticular fractures. Oblique views may be necessary to adequately assess these fractures.

The most important clinical feature of these fractures is a rotational deformity. While this may be apparent on plain films, it is best assessed by physical exam. Rotational deformity of a phalanx fracture will offset the normal relationship between the fin-

Emergency Medicine Reports™ (ISSN 0746-2506) is published biweekly by American Health Consultants, 3525 Piedmont Road, N.E., Six Piedmont Center, Suite 400, Atlanta, GA 30305. Telephone: (800) 688-2421 or (404) 262-7436.

Vice President/Group Publisher: Brenda Mooney
Editorial Group Head: Valerie Loner
Specialty Editor: Shelly Morrow
Marketing Manager: Schandale Kornegay
GST Registration No.: R128870672

Periodicals postage paid at Atlanta, GA. **POSTMASTER:** Send address changes to ***Emergency Medicine Reports***, P.O. Box 740059, Atlanta, GA 30374.

Back issues: $29. Missing issues will be fulfilled by customer service free of charge when contacted within one month of the missing issue's date.

Multiple copy prices: One to nine additional copies, $323 each; 10 to 20 additional copies, $287 each.

Accreditation

Emergency Medicine Reports'™ continuing education materials are sponsored and supervised by American Health Consultants. American Health Consultants designates this continuing education activity for up to 52 hours in Category 1 credit toward the AMA Physician's Recognition Award. Each physician should claim only those hours of credit that he/she actually spent in the educational activity.

This CME activity was planned and produced in accordance with the ACCME Essentials.

Emergency Medicine Reports™ also is approved by the American College of Emergency Physicians for 60 hours of ACEP Category 1 credit and has been approved for 52 Category 2B credit hours by the American Osteopathic Association. Emergency Medicine Reports has been reviewed by the American Academy of Family Physicians as having educational content acceptable for Prescribed credit hours. This volume has been approved for up to 60 Prescribed credit hours. Term of approval covers issues published within one year from the beginning distribution date of 1/02. Credit may be claimed for one year from the date of this issue.

American Health Consultants (AHC) is accredited by the Accreditation Council for Continuing Medical Education (ACCME) to provide continuing medical education for physicians.

This is an educational publication designed to present scientific information and opinion to health professionals, to stimulate thought, and further investigation. It does not provide advice regarding medical diagnosis or treatment for any individual case. It is not intended for use by the layman. Opinions expressed are not necessarily those of this publication. Mention of products or services does not constitute endorsement. Clinical, legal, tax, and other comments are offered for general guidance only; professional counsel should be sought for specific situations.

Subscriber Information

Customer Service: 1-800-688-2421

Customer Service E-Mail: customerservice@ahcpub.com
Editorial E-Mail: shelly.morrow@ahcpub.com

World Wide Web page: http://www.ahcpub.com

Subscription Prices

1 year *with* 60 ACEP/60 AMA/60 AAFP Category 1/Prescribed credits (52 AOA Category 2B credits): $524
1 year *without* credit: $379
Resident's rate $189

All prices U.S. only.
U.S. possessions and Canada, add $30 plus applicable GST. Other international orders, add $30.

For Customer Service and CME questions,

Please call our customer service department at **(800) 688-2421.** For editorial questions or comments, please contact **Shelly Morrow,** Specialty Editor, at shelly.morrow@ahcpub.com or (404) 262-5514.

THOMSON
AMERICAN HEALTH CONSULTANTS

Statement of Financial Disclosure

In order to reveal any potential bias in this publication, and in accordance with Accreditation Council for Continuing Medical Education guidelines, we disclose that Drs. Hals (author), Conn, and Perron (peer reviewers) report no relationships with companies related to the field of study covered by this CME program. Dr. Bosker (editor) is on the speaker's bureau for Pfizer, Aventis, Bayer, and Hoffman-La Roche. Dr. Bosker also acknowledges that he receives or has received royalties, honoraria, commissions, and other compensation relating to the sale of textbooks, consultation services, reprints of articles, and other written materials to the following pharmaceutical companies: Pfizer, Genentech, Aventis, Ortho-McNeil, Pharmacia, Hoffman-La Roche, and Bayer.

Figure 1. Terminology of Various Fractures

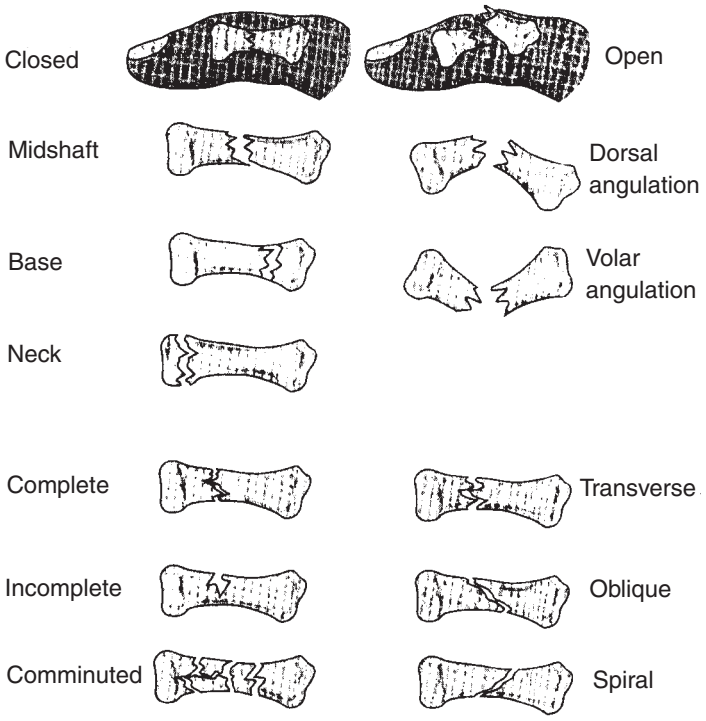

Reprinted with permission: Rosen P, Barkin R, Hockberger R, et. al, eds. *Rosen's Emergency Medicine: Concepts and Clinical Practice*. St. Louis: Mosby; 1999:642.

Table 1. Summary of Hand Fracture Care in the ED

GENERAL PRINCIPLES

- The bones of the hand are fractured more often than any other bones.
- Any open fracture needs to be irrigated in the OR.
- Any significant fracture/dislocation requires consultation with a hand surgeon.

DISTAL TUFT

- The distal tuft fracture is the most common hand fracture.
- Consider removing the nail for subungual hematoma > 50% of nail and repair nailbed laceration.
- Always replace the nail—use gauze stent if the nail is missing.
- Don't immobilize PIP with protective splinting.

PROXIMAL/MIDDLE PHALANX

- Transverse fractures usually are stable and can be buddy taped.
- Oblique fractures usually are unstable and require hand surgeon consult.
- Do not buddy tape unstable fractures.
- Any rotational deformity needs to be corrected.

METACARPAL

- Head fractures are uncommon, intraarticular, and require consultation.
- Any laceration over a metacarpal head should be evaluated as a fight bite.
- Neck fractures are common.
- Up to 40° of angulation can be tolerated in the ring and little fingers, but only 15° for index and middle fingers.
- Shaft fractures only can tolerate 20° for ring and little fingers and 10° for index and middle fingers.
- Any rotational deformity requires correction.

THUMB FRACTURES

- Phalanx fractures in the thumb are less common due to its mobility.
- Treat distal tuft and phalanx fractures as with the other fingers.
- Extraarticular metacarpal fracture can have up to 20° angulation.
- Intraarticular metacarpal base fractures are Bennet's or Rolando's fractures.

BENNET'S FRACTURES

- These are intraarticular base fractures with disruption of CMC joint.
- These are unstable fractures and require consult.
- Abductor pollicis longus pulls radial fragment dorsally.
- Bennet's fractures sometimes can be treated with a splint only, but they often require surgery.

ROLANDO'S FRACTURES

- These are comminuted Bennet's fractures of the metacarpal base.
- A Rolando's fracture has a worse prognosis than a Bennet's fracture.
- Treatment always is surgical, but these fractures can be splinted and followed up.

ger flexors and extensors. This results in rotation of the affected digit from its usual path during movement. Also known as "scissoring" because the fingers cross each other like the blades of scissors, rotational deformity dramatically reduces the ability of the hand to grip effectively. When unsure, the non-injured hand can be used for comparison. If any rotational deformity is present, a hand surgeon should be consulted for potential repair.

Stable fractures make up 75% of phalanx fractures,[1] and these can be buddy taped and discharged safely with follow-up. Buddy taping is referred to as dynamic splinting because the digit is allowed to move as much as possible while healing. Most transverse fractures are stable, while most oblique fractures are unstable. Displaced or unstable fractures require consultation by a hand surgeon and are not suitable for buddy taping. These fractures usually are immobilized with a radial (for index or middle finger fractures) or ulnar (for ring and little finger fractures) gutter splint.

Metacarpal Fractures (Digits 2-5). Fractures of the metacarpal head are relatively rare. They usually result from a direct blow or crush injury and, as a result, generally produce a comminuted fracture. Because these are intraarticular fractures, they will require follow-up with a hand surgeon. Indications for repair are for a greater than 1 mm step-off or for fractures involving greater than 25% of the articular surface. Closed fractures can be splinted in the "safe position," with the wrist in 20° of extension, the metacarpophalangeals (MPs) at 90°, and fully extended distal interphalangeal (DIP) and PIP joints. Any wound over a metacarpal head fracture should raise strong suspicion for a fight bite. (*See the fight bite section in part III.*)

Figure 2. Close-up of Collateral Ligaments and Volar Plate

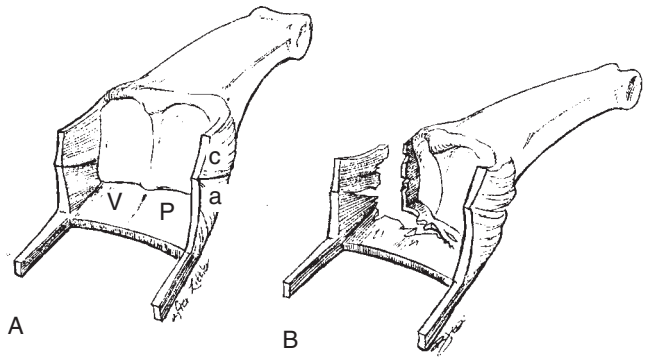

This diagram shows a close-up of collateral ligaments (a and c) and volar plate (VP) surrounding the finger joints. This box-like shape allows for maximum movement and stability of the joint. This figure shows how the ligaments and volar plate can be torn in dislocation.
Reprinted with permission: Rosen P, Barkin R, Hockberger R, et al., eds. *Rosen's Emergency Medicine: Concepts and Clinical Practice*. St. Louis: Mosby;1999:638.

Metacarpal neck fractures are very common because they often result from punching a hard object with a closed fist. Boxer fractures, or fractures of the fifth metacarpal, are probably the most common hand fractures after distal tuft fractures. They typically are unstable, with dorsal angulation and/or rotational deformity. Neck fractures of the ring and little finger can be treated in a similar fashion. These joints may have up to 30° or 40° of angulation before reduction is required, but a rotational deformity should be corrected to prevent scissoring of the fingers when making a fist. If no reduction is needed, neck fractures of the ring and little finger can be immobilized with an ulnar gutter splint. The splint should extend from just distal to the elbow to the PIP joints, but should not include the DIP joints. Reduction of ring and little finger neck fractures can be attempted by an ED physician who is trained adequately and comfortable with these maneuvers. The most common method is the "90-90 method." This is performed by flexing the MP and interphalangeal (IP) joints at 90° with simultaneous pressure in a dorsal direction on the finger and a volar direction on the metacarpal shaft. Neck fractures of the index and middle finger are less common, as they inherently are more stable. Consequently, less angulation is tolerated in these fractures; more than 15° requires reduction, which usually is accomplished by open reduction internal fixation (ORIF). Any neck fracture of the index or middle fingers requires urgent referral to a hand surgeon.

Metacarpal shaft fractures can be thought of in similar fashion to shaft fractures of the phalanx. They can be transverse, oblique, or comminuted. Transverse fractures typically result from a direct blow, are complicated by angulation, and usually are stable enough to be splinted for follow-up evaluation by the hand surgeon. Multiple transverse metacarpal fractures will require ORIF. Oblique fractures tend to shorten and rotate, and any rotational deformity will need to be eliminated. Less angulation and rotation of the index and middle fingers are tolerated, while the ring and little fingers compensate these deformities to a greater degree. Overall, less angulation is tolerated than for neck fractures with only 20° acceptable for ring and little fingers, and only 10° for the index and middle fingers.

Base fractures of the metacarpals are less common and, in general, are stable. They result from a direct blow to the base of the hand or from twisting of the finger. Once identified, they usually can be splinted and referred for follow-up. These fractures can be associated with carpal fractures, and base fractures of the ring and little finger can cause damage to the motor branch of the ulnar nerve. Loss of intrinsic muscles will be evident with injury to this nerve.

Thumb Metacarpal Fractures. Fractures of the shaft of the thumb metacarpal are rare due to its mobility. However, fractures of the base are common, accounting for 25% of all metacarpal fractures.[8] Most thumb metacarpal fractures are injuries of the base that are classed as extraarticular or intraarticular (Bennet's or Rolando's) fractures. Extraarticular fractures are seen more often than intraarticular ones, and can be transverse or oblique. The high degree of mobility of the thumb allows for greater angulation. Fractures with more than 20-30° of angulation should be reduced, immobilized with a thumb spica cast, and referred for follow-up with the consultant. As with other metacarpal fractures, transverse fractures often are stable, and oblique fractures often require fixation to correct rotational deformity.

Bennet's fractures are the most common fracture of the base of the thumb metacarpal. They are defined as an intraarticular fracture of the base of the thumb combined with dislocation of the carpometacarpal (CMC) joint. The most common mechanism of injury is striking an object with a clenched fist and producing an axial load on the partially flexed metacarpal. These fractures are inherently unstable and often require fixation by a hand consultant. The reason for the instability is that the abductor pollicis longus inserts on the radial aspect of the metacarpal base and pulls this fragment dorsally. These fractures also are associated with complete disruption of the CMC ligaments, so maintenance of proper anatomic position is difficult without fixation. Thus, early referral to a hand surgeon is mandatory for proper care of this fracture.

Rolando's fractures are comminuted intraarticular fractures of the base of the thumb metacarpal. Rolando originally described these fractures with a T- or Y-shaped pattern of the base fragments, but now any comminuted fracture of the thumb base is referred to as a Rolando fracture. They are produced by the same mechanism as a Bennet's fracture, but are less common and carry a prognosis that is much worse. Place the patient in a thumb spica splint and consult the hand surgeon for early follow-up. The ultimate treatment depends greatly on the individual injury and varies from plating to K-wire fixation to bone grafting.

Dislocations

Dislocations of the hand bones are common but easily can be missed in the ED. Plain films are necessary before reduction to rule out a significant fracture. Spontaneously reduced dislocations can present only with swelling and have no radiographic

Figures 3A, 3B. Techniques for Reduction of PIP Dislocation

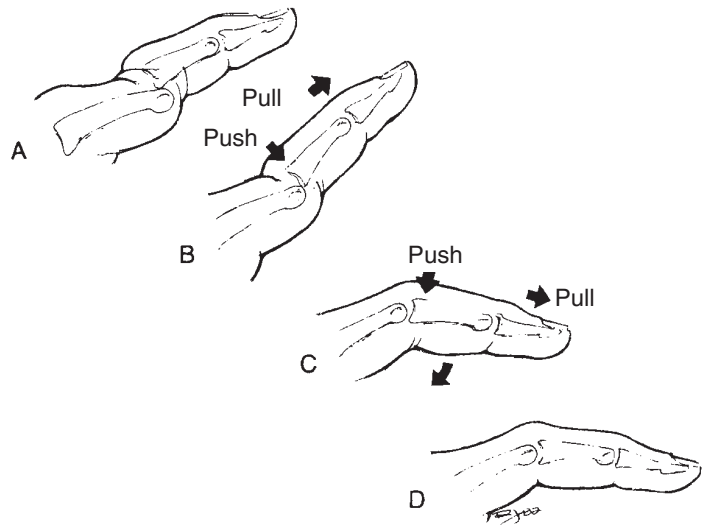

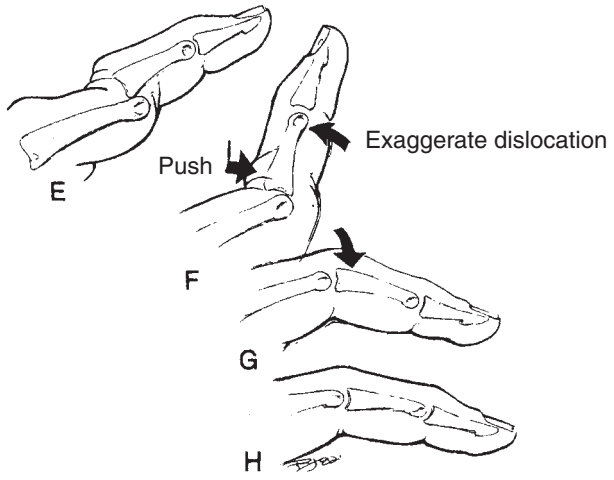

Figure 3A shows the traction method for reduction of PIP dislocation. Figure 3B shows the exaggeration of deformity method. Reprinted with permission: Roberts J, Hedges J, eds. *Clinical Procedures in Emergency Medicine*. Philadelphia: Elsevier Science;1998:838.

abnormality. In some cases, only when the joint is stressed under anesthesia can the instability be detected. Patients who present with joint injuries should have the joint stability assessed under digital block if there is any question about its stability.

Dislocations are described in terms of the distal bone's displacement. If the distal bone is dorsal (most common) to the proximal (normal) bone, it is a dorsal dislocation. Volar displacement of the distal bone is termed a volar dislocation. Dislocations imply a complete disruption of the joint, leaving no portion of the articular surfaces in contact. Subluxation is the proper term for a partial dislocation when there is partial disruption of the joint and partial contact of the articular surfaces. The joints in the hand are stabilized primarily by a strong volar plate (ligament) and collateral ligaments on either side. (*See Figure 2.*) Partial ligament injuries (sprains) present with normal bone alignment and are stable with active and passive stress of the joint. However, significant swelling will be present along with maximal tenderness over the injured ligament. These injuries respond best to short-term immobilization and follow-up with the consultant. Any significant widening of the joint indicates an unstable joint from complete tears of at least two of the three ligaments. These injuries require immobilization with a splint and follow-up with a hand surgeon, as some injuries will be treated with surgical repair.

DIP Joint. DIP dislocations are less common that PIP ones, as the ligament structure is the same but the DIP joints are stabilized further by insertion of the flexor and extensor tendons. The forces that create a DIP dislocation often tear the skin over the joint as well. When the patient presents with a spontaneously reduced injury, care must be taken in obtaining the history of the injury. Do not assume that these are simple lacerations. Patients will describe blunt trauma to the finger, but will present with a laceration over the joint. Instability of the joint easily is identified on exam. In patients who present dislocated, reduction usually can be accomplished after digital block. If open, the skin should be closed after consultation with a hand surgeon for follow-up. Prophylactic antibiotics should be given, according to most authors.[9] Irreducible injuries are often the result of fracture fragments, entrapment of the profundus tendon, or buttonhole tears of the volar plate[10] and require immediate consultation for reduction in the OR. Dislocations of the thumb IP joint are uncommon, often open, and can be treated similarly to DIP dislocations.

PIP Joint. PIP dislocations are the most common form of ligament injuries in the hand. Most dislocations are dorsal and result from forced hyperextension of the finger. Lateral dislocations usually occur in the ulnar direction, and volar dislocations are infrequent. An x-ray should be taken to rule out a fracture. Avulsion fractures are common with these injuries, but only when the fracture involves more than one-third of the articular surface is surgery necessary.[11] Dorsal and lateral dislocations usually can be reduced in the ED. After digital block, traction is applied with some hyperextension of the displaced bone. Moderate pressure is applied to the proximal phalanx, and reduction should follow. (*See Figures 3A and 3B.*) The joint stability then is assessed by both active and passive motion. Minimal displacement with movement supports that the joint is stable, while greater than 20° of instability indicates complete tear of the ligaments. Joints that spontaneously dislocate with active motion also are unstable. Stable injuries can be splinted in 30° of flexion for follow-up with the hand surgeon. Consultation is required on unstable or irreducible dislocations because operative repair is the standard treatment. Treatment of volar dislocations is controversial, with some authors suggesting open reduction for all patients and others advocating closed reduction. The decision should be left to the consultant in these cases.

MP Joint. MP joint dislocations are less common due to the strength of their ligaments. The shape of the bones also makes them more stable in flexion where the ligaments maximally are stretched. Dislocations usually are dorsal, with the index and little fingers most commonly affected. Volar dislocations are rare and require open reduction. Dorsal dislocations result from hyperextension of the finger with tear of the volar plate. Simple dislocations usually can be reduced by flexing the wrist to relax the flexor tendons and then pushing on the proximal end of the finger in a volar direction. Using longitudinal traction or hyperextension will increase the risk of transforming the simple dislocation into a complex one and should not be done. In a simple dislocation, there is no soft tissue in the joint, whereas complex dislocations are complicated by entrapment of the volar plate in the joint. When the volar plate is trapped in the joint, closed reduction cannot be done and the hand surgeon should be consulted for open reduction. Although it may be difficult initially to distinguish simple from complex dislocations, the x-ray provides important clues to the diagnosis. When the volar plate is trapped, the joint will appear widened in comparison to the adjacent joint. Presence of sesamoid bones in the joint is pathognomonic of a complex dislocation.

Gamekeeper's Thumb. Ulnar collateral ligament injuries of the thumb are referred to as gamekeeper's thumb (damaged by frequent twisting of small animals' necks) or skier's thumb (damaged by the ski pole forcing the thumb away from the hand). It also is common in basketball players and grappling sports participants (e.g., martial arts, wrestling). The ulnar collateral ligament is torn when the thumb forcibly is abducted. The dorsal capsule and volar ligament also can be damaged in these injuries but there is no dislocation or subluxation noted on presentation. Patients present with pain and swelling over the ulnar side of the joint and weakened pinch. The distinction between a complete or partial ligament tear is done by clinical exam. Best performed under digital block, the thumb is placed in neutral position (no extension) and tested again in 30° of flexion. The opposite (normal) thumb can be used for comparison, and most authors diagnose a complete tear when 30° of subluxation (joint widening) is present. Distinction of complete vs partial tears can be difficult, and this should be considered a high-risk injury. It commonly is missed in many EDs, and significant disability of the thumb joint can result when a complete tear is misdiagnosed as a simple sprain. Further, complete tears typically are treated with surgery, while partial tears are treated with thumb spica for several weeks. Therefore, all patients with any significant injury to the ulnar collateral ligament should be referred to a hand surgeon for follow-up evaluation. Radial collateral ligament injuries also can occur, but are less common. They can be managed in a similar fashion and are considered equally debilitating injuries.

Tendon Injuries

Tendon injuries cover a wide spectrum of disease that can confront the ED physician. (*See Table 2.*) Tendons can have complete or partial lacerations, and crush or avulsion injuries. Nerves and vessels exist near the tendons and can complicate the diagnosis and treatment. While complete tendon lacerations often can be diagnosed simply by observing the patient's hand at rest, partial lacerations can be much more difficult. The tendon still can have normal motion (but not strength) with a 90% laceration, and most agree that any laceration greater than 50% requires repair. Further, the hand must be examined in the position of the injury to detect many tendon lacerations. The excursion of the tendon during normal movement may move the laceration several centimeters from the skin wound, depending on the position of the hand during examination. When closed tendon injuries are present direct visualization of the tendon is not possible, and the physician must rely on the physical exam. Any patient with abnormal lie of the injured hand in comparison with the unaffected side or with limited/painful range of motion should be considered to have a partial tendon laceration until proven otherwise. In some cases, only under direct evaluation in the OR will the true nature and extent of the injury be apparent. Any open tendon injury associated with an infected wound should be referred to

Table 2. ED Care of Tendon Injuries

GENERAL PRINCIPLES

- Maintain high suspicion for tendon injury in ED patients.
- Explore in bloodless field under good anesthesia to rule out tendon injury.
- Examine hand in position of injury to account for normal tendon excursion.
- Any tendon laceration > 50% should be repaired.
- Tendons can have 90% laceration and still have full range of motion (ROM).
- Significant tendon lacerations will have painful motion and decreased strength.
- The three most common closed injuries in athletes are:
  - Mallet finger or avulsion extensor at DIP;
  - Boutonniere deformity or rupture of central extensor at PIP; and
  - Jersey injury or avulsion of FDP at DIP joint.

EXTENSOR TENDONS

- Injuries to extensor tendons are common due to their exposed nature on the dorsal hand.
- Closed tendon injuries are common in athletes (Mallet finger, boutonniere deformity).
- Any tendon injury over the MP joint is a potential "fight bite."
- Complete tendon lacerations proximal to the juncturae tendinae on the dorsal hand (zone V) still can have preserved ROM.
- Repair can be done by ED physician *if* adequately trained and experienced.

FLEXOR TENDONS

- Flexor tendons are injured less commonly due to their deeper location in the hand.
- Injuries often result from lacerations to the fingers.
- Both FDS (DIP joint) and FDS (PIP joint) function must be tested separately.
- Avulsion of the distal FDP insertion is the common "jersey injury" in athletes.
- Repair requires an experienced hand surgeon and the OR.

Figure 4. Zones of Extensor Tendons

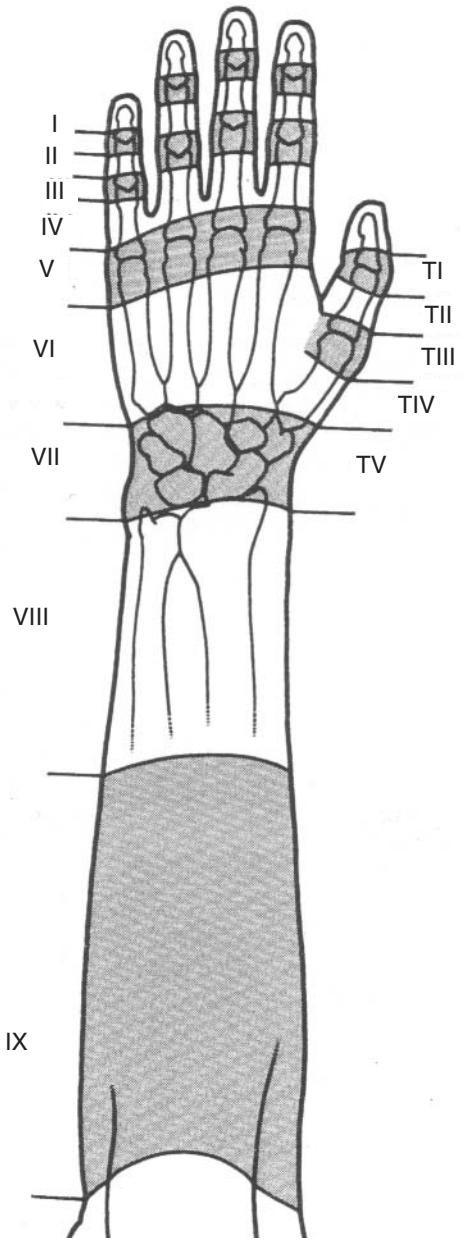

Reprinted with permission: Green DP. *Green's Operative Hand Surgery*, 4th ed. Philadelphia: Elsevier Science;1999:1956.

Figure 5. Example of Mallet Finger Deformity

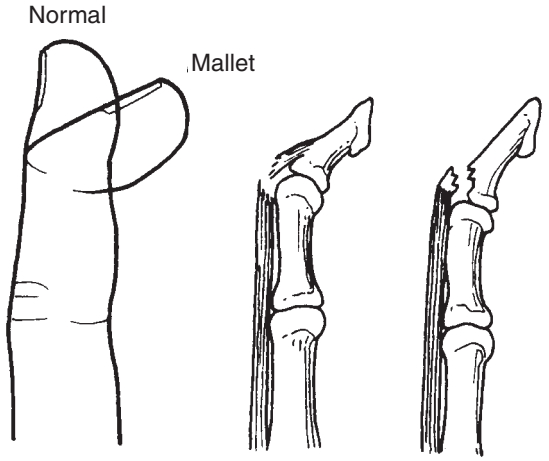

Reprinted with permission: Rosen P, Barkin R, Hockberger R, et. al, eds. *Rosen's Emergency Medicine: Concepts and Clinical Practice*. St. Louis: Mosby; 1999:655.

the hand consultant for admission. Likewise, any open tendon injury from a human or animal bite also should be considered grossly contaminated and referred for admission.

Extensor Tendon Injuries. Extensor tendons often are injured from trauma to the dorsal hand. They are relatively exposed just beneath the surface of the skin, and suffer from crush and abrasion injuries more often than flexor tendons. The lack of a sheath or pulley system like that found with flexor tendons makes their repair more straightforward, and often can be accomplished in the ED. However, only emergency physicians who have had sufficient training and experience with tendon repair should perform this service. Even though this is a relatively simple procedure, the majority of emergency physicians will consult an experienced hand surgeon for extensor tendon injuries. Both extensor and flexor tendons are divided into zones when discussing tendon repair. This division is useful because injuries in different zones are repaired and treated differently. In both classifications, zone I is the most distal, and zones VIII the most proximal. (*See Figure 4.*) Because zone VII and VIII are in the wrist and forearm respectively, they will not be discussed here.

Zone I extensor injuries occur at or distal to the DIP joint. They can be open or closed, partial or complete. Any laceration near the DIP joint should be explored to rule out a tendon injury. A complete tendon laceration will result in the finger resting with 40° of flexion at the DIP joint, where partial injuries may present only with reduced strength or extensor lag. When closed, partial injuries are treated by 6-10 weeks of splinting in mild hyperextension. The tendon is repaired and skin closed in open partial injuries followed by a similar period of immobilization.

A complete closed tendon disruption at this level is termed a "mallet finger" based on its appearance. (*See Figure 5.*) It is one of the most common tendon injuries of the hand seen in athletes.[12] It often results from a direct blow to the extended fingertip, such as a ball striking the end of the finger. A significant problem with this injury is that the extensor lag at the DIP joint may not appear for several days, and the injury typically is not very painful. Also loss of extension at the DIP does not interfere with normal activities as much as other tendon injuries. All of these points lead patients to present later than with other closed tendon injuries, making care more complex. Untreated chronic mallet fingers may progress to a swan-neck deformity. Plain films are necessary to distinguish the three types of injury that can produce this clinical picture. The extensor tendon can be severed with no fracture seen (type 1). A small avulsion of the tendon insertion may be seen (type 2) or a larger (one-third of the articular surface) fracture may been seen (type 3). Types 1 and 2 are treated with splinting only, while the treatment of type 3

injuries can be controversial between open repair and splinting. When treating with a splint, the finger must be kept in extension for up to eight weeks. Patients should be made aware that the splint may be removed briefly for cleaning, but if the DIP joint falls back into flexion, the immobilization period will start over again. Zone II injuries occur in the middle phalanx between the DIP and PIP joints. They usually are the result of a laceration and are treated as open zone I injuries.

Zone III injuries involve the extensor tendon over the PIP joint. Closed zone III injuries are the second most common closed tendon injury in athletes. Forcing an extended finger into flexion is the typical mechanism. Any wound over the PIP not only may injure the central tendon, but also may extend into the joint. Careful sterile exploration of these wounds to ensure the PIP joint capsule is intact is necessary when closing these injuries. Open joint injuries need to be irrigated in the OR by the consultant. Disruption of the extensor tendon in zone III is evident when the patient cannot actively extend the PIP joint. Tendon injury in this zone should be suspected when a patient presents with history of an injury and painful swelling of the PIP joint. Because disruption of the central tendon in zone III distorts the usual balance between flexor and extensor tendons, the finger may present as an acute button-hole or boutonniere deformity. This describes the resting position of the finger when there is flexion of the PIP joint and hyperextension of the DIP and MP joints. It can be thought of as the opposite of a swan-neck deformity. Although seen acutely, the most dramatic examples primarily are seen several weeks after a closed central tendon rupture. Unfortunately, treatment of a chronic boutonniere deformity is one of the most difficult reconstructive problems a hand surgeon can face.[13] Patients with possible closed zone III injuries should be placed in a finger splint immobilizing only the PIP joint. Both active and passive movement of the DIP joint should be performed to avoid unnecessary stiffness. In open zone III injuries, especially those with acute boutonniere deformities, consultation with a hand surgeon should be obtained. Most surgeons will repair the tendon and K-wire the PIP joint for repair. Zone IV injuries occur between the PIP and MP joints over the proximal phalanx, and can produce less pronounced findings similar to zone III injuries. Open injuries are common here and usually respond well to primary repair followed by splinting for up to six weeks.

Zone V injuries occur over the MP joint. Any open injury over the MP joint should be considered high-risk as it could be the result of a fight bite. (*See section on fight bites in part III of this series.*) Any infected wound over the MP should be treated as a fight bite. For injuries not treated as fight bites, metacarpal head fracture and injury to the joint capsule need to be ruled out. The patient will present with the affected finger in flexion and will have limited extension. Because the tendon ends at this level retract little, repair of the tendon can be done in the ED by an adequately trained physician. Immobilization should be done with the wrist in 30° extension and MP joints in a neutral position, and the patient should be referred to the hand consultant for follow-up care.

Zone VI injuries occur over the dorsal aspect of the hand. They occur frequently because the tendons are located just beneath the skin at this level. Very small and benign wounds to the dorsal hand can result in tendon laceration, and a high suspicion for tendon injuries should be maintained in these patients. Further, when the tendon laceration occurs proximal to the juncturae tendinae, the patient still may have full but weakened extension in the affected finger. This results from the transmission of extension forces to the affected tendon from the adjacent normal tendons. As with zone V injuries, the tendon stumps do not retract and easily can be repaired in the ED by an experienced physician. The wrist should be immobilized in 30° of extension and the MP joints held in a neutral position while the patient awaits follow-up with the hand surgeon.

Flexor Tendon Injuries. These tendons are injured less frequently than extensor tendons because they are deeper, more protected structures in the hand. Complete lacerations of the flexor profundus tendon often can be diagnosed simply by observing the natural lie of the patient's affected hand. The unopposed extension will pull the affected digit(s) into near full extension at rest and the patient will be unable to flex the finger adequately. Any deviation from the normal flexion cascade of the hand at rest implies a potential tendon injury. In addition, any painful movement or pain upon strength testing implies a partial tendon injury. Partial lacerations can be as subtle as complete injuries are obvious. Because of their deep location, wounds need to be fully explored under bloodless, sterile conditions with good anesthesia to adequately rule out flexor tendon injury. When testing flexor tendon function, both the flexor digitorum superficialis (FDS) and flexor digitorum profundus (FDP) need to be tested separately. The DIP and PIP joint movements must be isolated to adequately assess for FDP and FDS tendon function, respectively. Failing to perform an adequate exam to look for flexor tendon injuries will ensure that these injuries will be missed, with a potentially poor outcome for the patient.

Closed injuries are less common than open injuries, and their diagnosis also can be problematic. Avulsions of the flexor digitorum profundus are the third most common closed tendon injury in athletes. The classic mechanism is gripping an opponent's clothing in attempted tackle and having the clothing pulled forcefully from the clenched fist (jersey finger). The tendon itself is strong and the majority of injuries are from pulling the tendon loose from its bony insertion. Up to 75% of these injuries involve the ring finger, although the reasoning for this is not clear.[14] It may be because the insertion of the FDP at the ring finger is weaker compared to the other fingers, as shown in a cadaver study.[15] Small avulsion fractures may be present on x-ray, but most films will be normal. It is important to remember that a patient with an FDP injury will have an unstable pinch and may complain of inability to make a complete fist. The patient will have no flexion at the DIP joint when the PIP joint is held in extension. Since these are closed injuries, many patients may not appreciate the severity of the injury and may present days to weeks after the acute event. They also commonly are misdiagnosed as sprains when the patient does present. These patients should be splinted with the wrist in 30° of flexion, MPs at 70° of flexion, and PIPs at 30-45° of flexion.[16] Although not all patients ultimately will undergo surgical repair, all should be referred to a hand surgeon within seven

Figure 6. Zones of Flexor Tendons

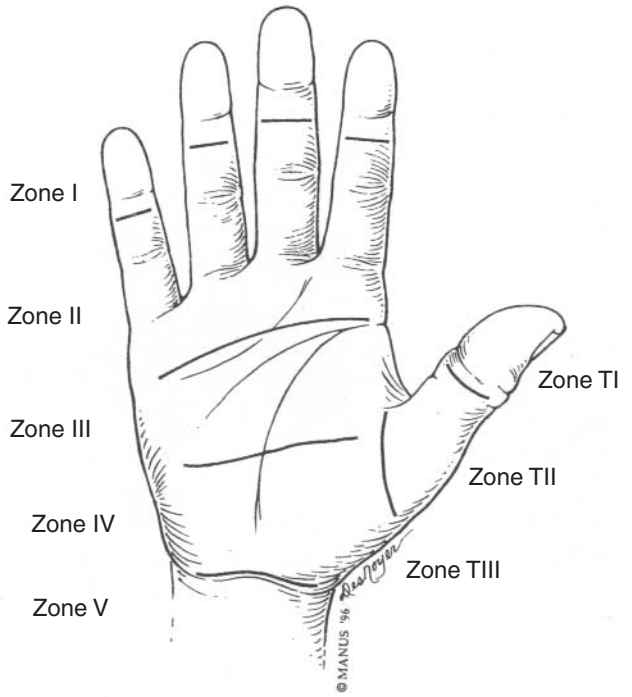

Reprinted with permission: Green DP. *Green's Operative Hand Surgery*, 4th ed. Philadelphia: Elsevier Science; 1999:1857.

days of the injury to ensure a timely evaluation by the consultant.

Definitive treatment of closed flexor tendon injuries often is surgical. Treatment of open flexor tendon injuries always is surgical and requires repair in the OR by an experienced hand surgeon. These are not injuries that the ED physician should attempt to repair. The facts that flexor tendon stumps can retract 4 or 5 cm from the original injury and that they are deeper structures means that the surgeon may need to make an incision from the finger into the palm to adequately evaluate and repair the injuries. These incisions must be made carefully to avoid injury to neurovascular structures and must be made at angles to avoid later scar contractions over the joints. Flexor tendons also have been divided into zones for discussion of injury and repair. The divisions are similar but not exactly the same as for extensor tendons, with the hand being divided into fewer zones (five). (*See Figure 6.*) Zone I is the area distal to FDP insertion and includes only FDP. Zone II ("no man's land") is from the MP joints to DIP and includes both FDP and FDS. Zone III is the mid-palm area, zone IV is from the mid-palm to the wrist, and zone V is the wrist. These will not be discussed in detail because the ED physician will not be involved in flexor tendon repair. One important point is that treatment of flexor tendon injuries has evolved over time. When Bunnell originally described zones of flexor tendons, zone II was termed "no man's land." These injuries almost always are from lacerations, and primary repair was not recommended for many years due to poor outcomes. More recently, some authors report success with primary repair,[17] but not all hand surgeons will elect for primary repair. Knowledge of general repair principles can be useful to the ED physician so that he can present the range of possible treatments to the patient and have more rewarding encounters with the consultant.

Neurovascular Injuries

Vascular injuries to the hand can range from small amounts of devascularized tissue that simply needs to be debrided to promote healing and reduce risk of infection, to major vessel damage and ischemic fingers. Major arteries in the hand most often are injured by direct laceration, but also can be damaged by blunt trauma. Clues to significant arterial trauma are blanched, cool, and pale fingers. The patient may not necessarily complain of ischemic pain as nerves also can be severed since they lie in close proximity to many vessels. The hand surgeon should be consulted immediately upon any suspected arterial injury that presents with obviously underperfused tissue. These types of injuries often require vessel grafting to repair the damaged artery, and time is of the essence. As with replantation, warm ischemia times of greater than six hours correlate with poor outcome. If such services are not available in the area of practice, efforts to transport the patient to a referral center should begin as soon as one is aware of the injury.

Nerve injuries can be devastating to a patient, but fortunately treatment of these injuries does not operate under the same time constraints as arterial injuries do. They are relatively common injuries, as a survey of 21,000 peripheral nerve injuries found that the majority occurred in the hand.[18] The median can be injured at its exit from the carpal tunnel near the wrist. Injury here produces loss of thumb abduction, thumb opposition, and sensation (best found at the volar index fingertip). Laceration in the thenar eminence can injure the recurrent branch and produce the same motor deficit in the thumb without a sensory loss. Radial nerve injury in the hand will produce only a sensory loss best detected over the dorsal hand between the thumb and index metacarpal. Ulnar nerve laceration in the wrist or proximal hand will produce weakness of the ring and little fingers (hypothenar muscles), and weakened finger abduction and adduction (interosseous muscles). The sensory deficit is detected best in the little fingertip. Digital nerve injuries will produce isolated sensory loss on the affected radial or ulnar side of the finger.

Repair of nerve injuries can be primary or delayed, and controversy exists as to which approach is best.[19] Advantages of primary repair are that the patient only undergoes one surgery, and reattachment is technically easier because no shortening of the nerve or fibrosis of the ends has occurred. Delayed repair is promoted as hemorrhage and inflammation of the acute injury have subsided, and is favored when more difficult repairs are being attempted. Delayed repairs are best done in fewer than 10 days from the injury with median and ulnar nerves, as muscles they innervate will begin to atrophy without nerve stimulation. As the radial nerve is purely sensory in the hand, delayed repair can be done up to three months after the injury without affecting the outcome.[19] In general, nerve repair never returns function to preinjury levels, and sensory function recovers better than motor function does. Digital nerve repair often is done for nerves

affecting the grip of the hand (thumb, radial index, and middle finger sides). The ulnar side of the little finger also is repaired to provide sensation when resting the hand on surfaces. In general digital nerves are repaired only when damaged proximal to the DIP, as spontaneous regeneration and overlap from the opposite side usually provide good results with surgery.

Traumatic Amputations

Amputations of the hand can be as minor as a dermal slice from a fingertip to loss of the entire hand. Amputations disproportionally affect the hand and upper extremity. One study found that of 4108 patients with amputation as a diagnosis, 68% involved the upper extremity.[20] Of those patients with an upper extremity amputation, 17% were at the hand level and 78% at the level of the finger. Overall, amputations account for up to 1% of all hand injuries.[21] Men suffer from traumatic amputations more commonly than women do, at a ratio of 4:1, with the peak incidence between the ages of 20 and 40 years.[22] Contrary to what one initially may think, sharp (guillotine) amputations are the least common, while crush injuries account for most traumatic hand amputations.[23] Power saws and lawn mowers are the most common mechanisms for amputation overall, and presses or power saws are the most prevalent in industrial accidents.[24] As would be expected, injury to the non-dominant hand is most common. The instrument in the dominant hand usually is responsible for the injury. Distal amputations are more common than proximal ones, and partial amputations are as common as complete ones. Partial amputations occur when some tissue or a skin bridge still connects the two parts. Under no circumstances should this tissue ever be severed. It often contains arteries and/or nerves because they are the most elastic tissue and often the last to be pulled away.

The first thing that comes to mind when discussing amputations is replantation of the severed part. The proper terminology for these procedures is that complete amputations are replanted, whereas partial amputations are revascularized. Replantation of severed body parts has been performed much longer than most physicians realize. One of the first recorded successes of any body part being replanted was a soldier's nose that was severed by a saber.[25] Surprisingly, reattachment was accomplished only by cleaning the nose in urine and bandaging it back in place. The first reattachment of an amputated finger was in 1814, which also was performed only through careful alignment and bandaging.[26] Although reports of successful replantation of upper extremities and hands had been published before, it was not until 1965 that the operating microscope first was used to reattach a severed thumb.[27] It is with these microscopic techniques that today's surgeons have success rates published from 70-90%.[28] Unfortunately, media attention surrounding dramatic cases of replantation may lead the patient to have unrealistic expectations concerning what can be accomplished. The reality is that vessels of less than 0.3 mm in diameter are too small for successful reanastimosis. The digital arteries trifurcate between the PIP and the DIP, and after this division most United States surgeons will not attempt replantation at this level. It is important to state at the outset that success is not defined just by replanting a viable part. Functional outcome is equally if not more important. Reattachment of a hand or finger that is painful and does not function should not be considered a success. Patients undergoing replantation will be off from work and/or daily activities an average of seven months, and only 50% will develop protective sensation. Common complaints seen in up to 60% of these patients include: cold intolerance, loss of range of motion, pain, anesthesia, paresthesias, malunions, and nonunions.[29] For example, range of motion (ROM) in reattached fingers usually is not greater that 80% of normal.[30] Also, only 50% of patients will have two-point discrimination greater than 7-15 mm.[31]

Every patient who presents to the ED with an amputation involving the hand (or part of the hand) should be considered a candidate for replantation until proven otherwise. Although not all patients ultimately will have reattachment attempted, it may not be clear from the outset what the final decision may be. Because the ED physician may not make the final decision, he should prepare the patient and the part to avoid complicating replantation if the decision is made to proceed. Table 3 reviews indications and contraindications for reattachment of hand amputations.

One of the most important factors and the most significant area in which the ED physician can intervene is ischemia time. It is well established that longer ischemia times are directly correlated with lack of successful replantation. Although reports of successful reattachment with warm ischemia times of more than 20 hours exist,[32] the accepted cut-off for warm ischemia time is between 6-12 hours: 6 hours for amputation proximal to the carpus and 12 hours for the digits.[33] After this time replantation becomes increasingly difficult with higher rates of long-term complications, and Green's text on hand surgery does not recommend attempts with longer times.

As can be seen from these numbers, another important feature is the location of the amputation. The more proximal the injury, the less the acceptable ischemia time will be. This largely is due to ischemic injury and accumulation of toxins from muscle. Once blood flow is established, release of toxic metabolites (lactate, potassium, etc.) can be fatal to the patient. Fortunately, when the temperature of the amputated part can be lowered to 4°C, the acceptable ischemia time can be increased up to 12-24 hours.[34] The recommended method for cooling an amputated part is as follows. Gross contamination and all jewelry should be removed from the part. Care should be taken to minimally handle the part and to avoid freezing it. Wrap it in saline-moistened gauze, place it in a water-tight plastic bag, and immerse the bag in a container of ice water (half ice, half water). This should maintain a temperature of 4°C. The stump can be treated in a similar fashion except for cooling. Gross contamination should be removed by saline irrigation, jewelry should be removed, the stump should be covered with saline-moistened gauze, and it should be splinted for protection. Do **not** clamp bleeding vessels on the stump; rather, elevate the stump and use minimal pressure to control bleeding. Also, do **not** debride any tissue from the stump or amputated part because important structures easily can be injured, which can

Figure 7. Types of Fingertip Amputations and Their Treatments

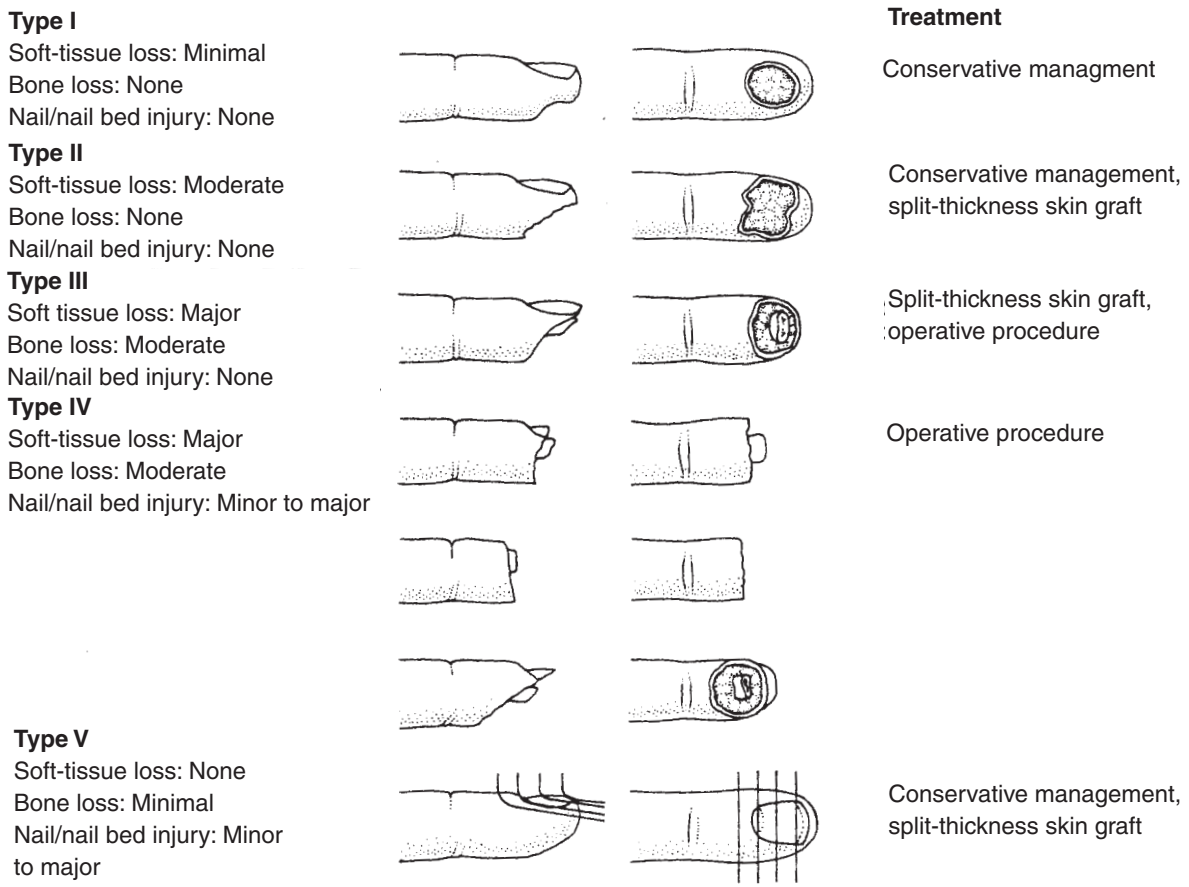

Reprinted with permission: Roberts J, Hedges J, eds. *Clinical Procedures in Emergency Medicine*. Philadelphia: Elsevier Science; 1998:801.

harm replantation attempts. The importance of proper cooling of the part cannot be overstressed. Reports exist of successful (including return of function) replantation of digits after 80 hours of cold ischemia.[35]

Fingertip amputations deserve special mention because they are the most common amputation of the upper extremity seen in the ED,[1] and in some cases the ED physician alone can provide the acute care. Fingertip amputations should be thought of in terms of the amount of tissue removed, the level of the fingertip injured, and involvement of deep structures such as tendon and bone. (*See Figures 7 and 8.*) One of the most important principles is to preserve length of the thumb. The most distal wounds involving only the fingertip or pad of fewer than 10 mm^2, also termed dermal slice injuries, can be covered with non-stick gauze, splinted, and left to heal by secondary intention. These injuries usually can be referred to the hand consultant after discussion. Wounds larger than this often will require skin grafting or some type of flap procedure to cover the fingertip. These injuries do not heal well by secondary intention and produce little padding or protection for the underlying bone. Often the scar tissue will be thin and easily broken down with pressure of normal use, resulting in a chronic ulcer. If bone is exposed by the tissue loss, then the patient requires consultation in the ED. Exposed bone will be at very high risk for osteomyelitis. Because of this risk, an IV dose of cephalosporin (cephazolin, 1 gram in adults) should be given and followed by an oral course. These patients require a procedure for tissue coverage, or shortening of the exposed bone by the consultant. Few ED physicians will be trained sufficiently in closure of these injuries. The bone must be reduced back to allow for proper coverage by soft tissue. Care must be taken to properly round off spikes of bone to reduce risk of ulceration later, and one must avoid damage to tendon insertions. If the tendon insertions cannot be preserved, the injury should be closed by disarticulation at the DIP joint. Those patients not requiring immediate consult by the hand surgeon should have their fingers covered with non-stick gauze, splinted for protection, and referred for a recheck of the injury within 48 hours.

New Advancements in Amputation Treatment

When replantation of an amputated digit or hand is not possible or has failed, further treatment options used to be limited to prosthetic devices that were neither very functional nor aesthetic. Some successful treatment options have developed. In 1968 the first free transfer of a toe to replace a patient's amputated thumb

Figure 8. Classification System for Fingertip Amputations

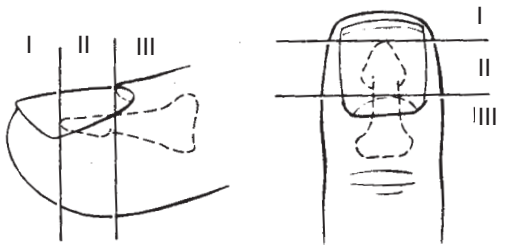

Reprinted with permission: Rosen P, Barkin R, Hockberger R, et al, eds. *Rosen's Emergency Medicine: Concepts and Clinical Practice*. St. Louis: Mosby;1999:658.

Table 3. Indications and Contraindications for Replantation of Amputated Hands[29,44]

ABSOLUTE INDICATIONS
• Pediatric patient
RELATIVE INDICATIONS
• Younger, stable patient
• Thumb amputation
• Multiple digits lost
• Sharp (guillotine) injury
• More proximal injuries
ABSOLUTE CONTRAINDICATIONS
• Associated injuries prevent surgery
• Severe crush injury of amputated tissue
• Comorbid conditions prevent surgery
RELATIVE CONTRAINDICATIONS
• Single finger (not thumb)
• Avulsion injury
• Multilevel amputation
• Prolonged warm ischemia time (> 6-12 hours)
• Prolonged cold ischemia time (> 24 hours)
• Gross contamination
• Previous injury or surgery of part
• Emotionally unstable patients

was performed, with the patient having a good functional outcome to this date.[36] Since then, the toe-to-thumb transfer has been performed with the great toe and the second toe, and has provided treatment options where few existed before. Using the second toe also can be useful for restoring length with partial amputations. Another treatment is the rotation of the index finger to the thumb position, termed pollicization. Both of these treatments successfully will give the patient back a thumb and therefore a functional grip where there was none. However, both involve sacrifice of another digit and require most of the hand to be intact in the first place. Further, there are cosmetic issues with the toe transfer because the great toe is roughly 20% larger than the thumb. In the past few years, a new approach to more extensive hand amputations has evolved: hand transplantation.

The first hand transplant was performed in Ecuador in 1964, but the graft only survived for 14 days.[37] Studies in primates implied that high levels of immunosuppression would be needed to prevent rejection of skin. This level of immunosuppression likely would produce fatal complications in humans. Fortunately, further studies found this not to be the case, and that success could be achieved with immunosuppression levels similar to those used in renal transplants.[38] The first successful hand transplant did not take place until 1998 in France, but the graft was amputated a year later secondary to the recipient's medical non-compliance from "mental issues." The first hand transplant in the United States was performed at the University of Louisville on Jan. 24, 1999, and this patient has retained function. He can perform tasks such as writing, picking up coins, and tying his shoes, but does not have full strength or sensation. Since then, double hand transplants and hand/arm transplants have been performed in France and China.[39] Prosthetic PIP joints also are being used to make up for bone loss and restore function in otherwise debilitated hands.[40]

The Mangled Hand

The mangled hand includes injuries that are extensive and complex, such as degloving injuries. They are combination injuries that include damage to many structures: bones, tendons, soft tissue, nerves, and vessels. Often these wounds are grossly contaminated as well. They can be dramatic in appearance and devastating in outcome. Repair of these injuries can occur on many levels with multiple procedures over time. The first priority is restoration of blood flow, followed by cleaning and debridement, fixation of bones, skin coverage, and nerve/tendon repair.[41] The role of the ED physician is to initiate antibiotic treatment, keep the tissues covered in saline-moistened gauze, and obtain definitive treatment for the patient through urgent consultation or transfer of the patient. It is important not to become preoccupied or distracted with the obviously injured hand and overlook following proper Advanced Trauma Life Support (ATLS) stabilization of the patient first.

Isolated large abrasions of the hand can be referred for follow-up after cleaning, provided it has been ensured that no exposed tendons or bones are present. Crush injuries occur as industrial accidents resulting from metal presses or rollers. These injuries can be deceptive in that a small burst laceration may be the only evident external injury, while extensive damage to deep structures may be present. Crushed tissue will swell considerably in the next days, and decreased perfusion will put this tissue at greater risk of infection. Any patient with history of a crush injury presenting with a burst laceration should have consultation by the hand surgeon.

Degloving injuries of the hand can occur to the dorsal or palmar surface, or involve an entire digit. If skin is completely avulsed from the hand, it is unlikely to be of use but should be saved for evaluation by the hand surgeon. Flaps of skin attached on the proximal side may retain enough blood flow to survive. The ED physician never should trim or debride tissue from the hand in these injuries. This inadvertently may do more harm than good. Tissue bridges often contain nerves and arteries because their elasticity makes them the last tissue to give way in many patients. Dorsal degloving injuries can occur from motor vehicle accidents where the patient's hand is ejected out a window. Pres-

ence or absence of extensor tendon injury usually can be directly visualized, and will guide the hand surgeon's repair. Palmar degloving injuries can occur when a person falls onto an outstretched hand with force and speed (bicycle or motorcycle). Green's hand surgery text suggests that the majority of these injuries will heal as well by secondary intention as with skin grafting.[42] Degloved fingers can occur from ring avulsions where the ring forcibly is pulled and takes the soft tissue with it. Often the tendons and joints are intact, but the skin is devascularized. Some patients will have only soft-tissue injuries, but most of these patients ultimately will require ray amputation, as published salvage rates in these injuries overall are fewer than 50%.[43] Skin grafting or replacement of the degloved tissue often does not produce reasonable function or appearance of the finger.

References

1. Antosia RE, Lyn E. The hand. In: Rosen P, et al eds. *Emergency Medicine: Concepts and Clinical Practice*, 4th Ed. Mosby; 1998: 662-668.
2. DaCruz DJ, Slade RJ, Malone W. Fractures of the distal phalanges. *J Hand Surg* 1988;13B:350-352.
3. Starker I, Eaton RG. Kirschner wire placement in the emergency room. Is there a risk? *J Hand Surg* 1995;20:535-538.
4. Guy RJ. The etiologies and mechanisms of nail bed injuries. *Hand Clin* 1990;6:9-15.
5. Simon RR, Wolgin M. Subungual hematoma: Association with occult laceration requiring repair. *Am J Emerg Med* 1987;5: 302-304.
6. Meeks S, White M. Subungual hematomas: Is simple trephinating enough? *J Accid Emerg Med* 1998;15;269-271.
7. O'Shaughnessy M, McCann J, O'Connor TP, et al. Nail re-growth in fingertip injuries. *Ir Med J* 1990;83;136-137.
8. Lee SG, Jupiter JB. Phalangeal and metacarpal fractures of the hand. *Hand Clin* 2000;16:323-332.
9. Stern PJ, Lee AF. Open dorsal dislocation of the proximal interphalangeal joint. *J Hand Surg* 1985;10:364-370.
10. Ghobadi F, Annapolle DM, Patterson NJ. Irreducible distal interphalangeal joint dislocation of the finger: A new cause. *J Hand Surg* 1994;19A:196-198.
11. Kahler D, McCue F. Metacarpophlanageal and proximal interphlangeal joint injuries of the hand, including thumb. *Clin Sports Med* 1992;11:57-76.
12. Pyne JI, Adams BD. Hand tendon injuries in athletics. *Clin Sports Med* 1992;11:833-850.
13. Scott SC. Closed injuries to the extension mechanism of the digits. *Hand Clin* 2000;16:367-374.
14. Steinberg DR. Acute flexor tendon injuries. *Orthop Clin North Am* 1992;23:125-140.
15. Manske PR, Lesker PA. Avulsion of the ring finger digitorum profundus tendon: An experimental study. *Hand* 1978;10:52-55.
16. Perron AD, Brady WJ, Keats TE, et al. Orthopedic pitfalls in the emergency department: Closed tendon injuries of the hand. *Am J Emerg Med* 2001;19:76-80.
17. Tang JB, Shi D. Subdivision of flexor tendon "no man's land" and different treatment methods in each sub-zone. A preliminary report. *Chin Med J* (Engl) 1992;105:60-68.
18. Kelsey JL, Patides H, Krieger N, et al. Upper extremity disorders: A survey of their frequency and cost in the U.S. St Louis: CV Mosby; 1980:44.
19. Sloan EP. Nerve injuries in the hand. *Emerg Med Clin North Am*

Audio Conference Tackles HIPAA Privacy Concerns

The recently released final privacy rule under the Health Insurance Portability and Accountability Act (HIPAA) makes significant changes to the existing regulations. With the April 14, 2003, compliance deadline fast approaching, is your staff receiving the proper training?

The American Hospital Association says implementing HIPAA will require "sweeping operational changes" and will take "intense education of hospital workers and patients." To help you and your staff prepare, American Health Consultants offers HIPAA's Final Privacy Regulations: What You Must Know to Comply, an hour-long audio conference on Dec. 4, 2002, from 2:30-3:30 p.m., Eastern time. You'll learn detailed information on changes to the privacy rule, as well as practical methods to implement new procedures within your facility. Also learn how to successfully manage privacy issues with business associates, and how to spot and avoid costly HIPAA violations. Do you know what your enforcement priorities are? Do you need real-world examples? Our expert speakers, Debra Mikels and Chris Wierz, BSN, MBA, will help you understand your responsibilities and identify potential liabilities. All this will allow you to develop a HIPAA compliance strategy with a rationale behind it.

Mikels is corporate manager, confidentiality, for Partners Healthcare in Boston. The Partners system includes some of the largest and most respected facilities in the country, including Massachusetts General Hospital, Brigham and Women's Hospital, and Harvard Medical School. Mikels will provide the practical information and guidance you need to implement a comprehensive privacy policy in your organization.

Wierz is vice president of HIPAA and compliance initiatives for Houston-based Healthlink Inc., a health care consulting firm. She has worked with numerous facilities across the country to prepare them for HIPAA compliance, and now she shares many of her ideas with you.

The cost of the conference is $299, which includes free CE or CME for your entire staff, program handouts, and additional reading, a convenient 48-hour replay, and a conference CD. Don't miss out. Educate your entire facility for one low price.

For more information or to register for the HIPAA audio conference, please call American Health Consultants' customer service department at (800) 688-2421. When ordering, please refer to effort code: 65151.

1993;11:651-670.
20. Dillingham TR, Pezzin LE, MacKenzie EJ. Incidence, acute care length of stay, and discharge to rehabilitation of traumatic amputee patients: An epidemiologic study. *Arch Phys Med Rehabil* 1998;79: 279-287.
21. Atroshi I, Rosberg HE. Epidemiology of amputation and severe injuries of the hand. *Hand Clin* 2002;17:343-350.
22. May JW, Gallico GG. Upper extremity replantation. *Curr Probl Surg* 1980;17:634-717.
23. Morrison WA, O'Brian BM, MacLeod AM. Digital replantation and revascularization: A long-term review of 100 cases. *Hand* 1978;10:125-134.
24. Lester B. Amputation. In: *The Acute Hand*. East Norwalk, CT: Appleton & Lange; 1999:287-288.
25. Gibson T. Early free grafting: The restitution of parts completely separated from the body. *Br J Plast Surg* 1965;18:1-9.
26. Balfour W. Two cases, with observations, demonstrative of the powers of nature to reunite parts which have been severed, by accident, totally separated from the animal system. *Edinb Med Surg J* 1814; 10:421.
27. Komatsu S, Tamai S. Successful replantation of a completely cut-off thumb: case report. *Plast Reconstr Surg* 1968;42:374-377.
28. McGee DL, Dalsey WC. The mangled extremity. Compartment syndrome and amputations. *Emerg Med Clin North Am* 1992;10:783-800.
29. Dalsey WC. Management of amputations. In: Roberts JR, Hedges JR, eds. *Clinical Procedures in Emergency Medicine* 3rd Ed. Philadelphia: WB Saunders;1998:798-805.
30. Urbaniak JR, Roth JH, Nunley JA, et al. The results of replantation after amputation of single finger. *J Bone Joint Surg* 1985;67: 611-619.
31. Glickman LT, Mackinnon SE. Sensory recovery following digital replantation. *Microsurgery* 1990;11:236-242.
32. Inoue G, Nakamura R, Imamura T. Revascularization of digits after prolonged warm ischemia. *J Reconstr Microsurg* 1988;4:131-138.
33. Goldner RD, Urbaniak JR. Replantation. In: *Green's Operative Hand Surgery*. Green EP, Hotchkiss RN, Pederson WC, eds. 4th ed. London: Churchill Livingstone; 1993:1139-1156.
34. Boulas HJ. Amputations of the fingers and hand: Indications for replantation. *J Am Acad Orthop Surg* 1998;6:100-105.
35. Wei FC, Chang YL, Chen HC, et al. Three successful digit replantation in a patient after 84, 86 and 94 hours of cold ischemia time. *Plast Reconstr Surg* 1988;82:346-350.
36. Whitworthm IH, Pickford MA. The first toe-to-hand transfer: A thirty-year follow-up. *J Hand Surg* 2000;25:608-610.
37. Gilbert R. Transplant is successful with a cadaver forearm. *Med Trib Med News* 1964;5:20-26.
38. Cendales LC, Breidenbach WC. Hand transplantation. *Hand Clin* 2001;17:499-510.
39. Dubernard JM, Henry P, Parmentier H, et al. First transplantation of two hands: Results after 18 months. *Ann Chir* 2002;127:19-25.
40. Fong SY, Low CK. A case report of total finger joint replacement arthroplasty after traumatic amputation. *Ann Acad Med Singapore* 2000;29:110-113.
41. Gupta A, Wolff TW. Management of the mangled hand and forearm. *J Am Acad Orthop Surg* 1995;3:226-236.
42. Brown PW. Open injuries of the hand. In: *Green's Operative Hand Surgery*. Green EP, Hotchkiss RN, Pederson WC, eds. 4th ed. London: Churchill Livingstone; 1993:1607-1628.
43. Tseng OF, Tsai YC, Wei FC, et al. Replantation of ring avulsion of index, long, and ring fingers. *Ann Plast Surg* 1996;36:625-628.
44. Aldred BN. Amputations. In: *Emergency and Primary Care of the Hand*. Hart RG, Uehara DT, Wagner MJ, eds. The American College of Emergency Physicians 2001:211-218.

Physician CME Questions

101. Which of the following is true concerning treatment of hand fractures?
    A. Rotational deformity of phalanx fractures often will correct itself.

B. Rolando fractures are treated non-surgically.
C. Distal tuft fractures are the most common hand bone fractures.
D. Metacarpal head fractures are common fractures.

102. When treating dislocations in the hand, which is true?
A. DIP dislocations are less common than PIP.
B. Partial vs. complete ulnar collateral ligament injuries (game-keeper's thumb) easily can be identified in the ED.
C. Presence of sesamoid bones in the MP joint space can be a normal variant.
D. After reducing a PIP dislocation, range of motion testing of joint stability serves no purpose in the ED.

103. When treating tendon injuries, which of the following is true?
A. Flexor tendon repair should be attempted by the ED physician.
B. Tendons can have a 90% laceration and still have full range of motion.
C. Any tendon laceration between 20% and 40% should be repaired.
D. Closed tendon injuries will not require surgical intervention for repair.

104. Which of the following is true regarding thumb injuries?
A. It is easy to distinguish between complete and partial ulnar collateral ligament tears.
B. Significant thumb joint disability can result when complete tears of the ulnar collateral ligament are misdiagnosed as simple sprains.
C. Radial collateral ligament tears are more common than ulnar collateral ligament tears.
D. Patients with significant injury to the ulnar collateral ligament do not need referral to a hand surgeon.

105. Mallet finger injuries are:
A. the least common tendon injuries in athletes.
B. known to progress to boutonniere deformity.
C. typically not very painful, leading patients to present later than with other closed tendon injuries.
D. apt to greatly interfere with normal activities as a result of the loss of extension at the DIP.

106. The hand surgeon should be consulted immediately upon any suspected arterial injury that presents with obviously underperfused tissue.
A. True
B. False

107. Relative contraindications for hand replantation after amputation include:
A. a young, stable patient.
B. previous injury or surgery of the part.
C. more proximal injuries.
D. a sharp or guillotine injury.

108. When caring for hand/finger amputations, which of the following statements is true?
A. Warm ischemia time of 12-24 hours is acceptable.
B. Partially amputated parts should be severed to allow for cooling and increased chance of successful replantation.
C. Severe crush injury is an absolute contraindication for replantation.
D. Once reattached, most patient's hands do not experience long-term problems.

109. Which of the following is correct regarding fingertip amputations larger than dermal slice injuries?
A. They often require skin grafting or a flap procedure to cover the fingertip.
B. They do not heal well by secondary intention and produce little padding for underlying bone.

C. If bone is exposed by tissue loss, the bone is at risk for osteomyelitis.
D. Few ED physicians are sufficiently trained in closing these injuries.
E. All of the above

110. Every patient who presents to the ED with an amputation involving the hand should be considered a candidate for replantation until proven otherwise.
A. True
B. False

Emergency Medicine Reports

CME Objectives

To help physicians:

- quickly recognize or increase index of suspicion for specific conditions;
- understand the epidemiology, etiology, pathophysiology, and clinical features of the entity discussed;
- be educated about how to correctly perform necessarydiagnostic tests;
- take a meaningful patient history that will reveal the most important details about the particular medical problem discussed;
- apply state-of-the-art therapeutic techniques (including the implications of pharmaceutical therapy discussed) to patients with the particular medical problems discussed;
- understand the differential diagnosis of the entity discussed;
- understand both likely and rare complications that may occur;
- and provide patients with any necessary discharge instructions.

In Future Issues: **The Acute Hand, Part III**

Emergency Medicine Reports
The Practical Journal for Emergency Physicians

The Acute Hand, Part II

Techniques for Reduction of PIP Dislocation

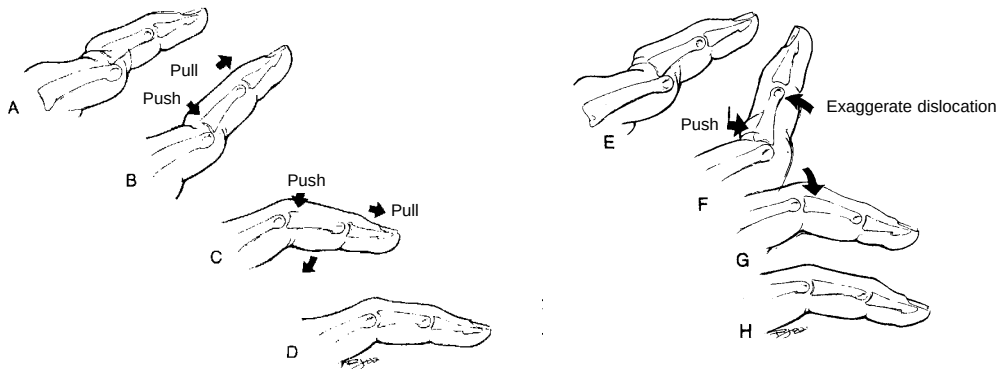

The figure on the left shows the traction method for reduction of PIP dislocation. The figure on the right shows the exaggeration of deformity method.
Reprinted with permission: Roberts J, Hedges J, eds. *Clinical Procedures in Emergency Mediicine*. Philadelphia: Elsevier Science;1998:838.

Terminology of Various Fractures

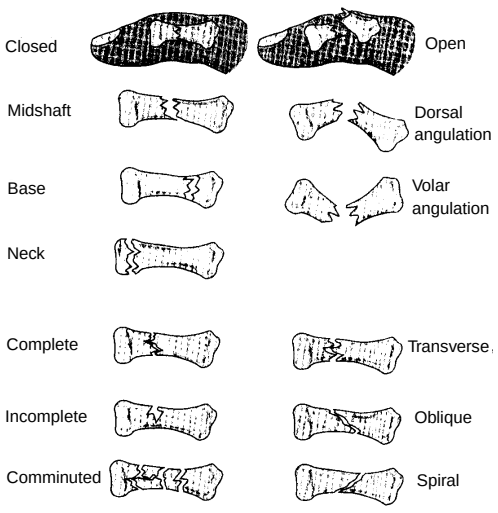

Reprinted with permission: Rosen P, Barkin R, Hockberger R, et. al, eds. *Rosen's Emergency Medicine: Concepts and Clinical Practice*. St. Louis: Mosby; 1999:642.

ED Care of Tendon Injuries

GENERAL PRINCIPLES

- Maintain high suspicion for tendon injury in ED patients.
- Explore in bloodless field under good anesthesia to rule out tendon injury.
- Examine hand in position of injury to account for normal tendon excursion.
- Any tendon laceration > 50% should be repaired.
- Tendon can have 90% laceration and still have full range of motion (ROM).
- Significant tendon lacerations will have painful motion and decreased strength.
- The three most common closed injuries in athletes are:
  – Mallet finger or avulsion extensor at DIP;
  – Boutonniere deformity or rupture of central extensor at PIP; and
  – Jersey injury or avulsion of FDP at DIP joint.

EXTENSOR TENDONS

- Injuries to extensor tendons are common due to their exposed nature on the dorsal hand.
- Closed tendon injuries are common in athletes (Mallet finger, boutonniere deformity).
- Any tendon injury over the MP joint is a potential "fight bite."
- Complete tendon lacerations proximal to the juncturae tendinae on the dorsal hand (zone V) still can have preserved ROM.
- Repair can be done by ED physician *if* adequately trained and experienced.

FLEXOR TENDONS

- Flexor tendons are injured less commonly due to their deeper location in the hand.
- Injuries often result from lacerations to the fingers.
- Both FDS (DIP joint) and FDS (PIP joint) function must be tested separately.
- Avulsion of the distal FDP insertion is the common "jersey injury" in athletes.
- Repair requires an experienced hand surgeon and the OR.

Summary of Hand Fracture Care in the ED

GENERAL PRINCIPLES

- The bones of the hand are fractured more often than any other bones.
- Any open fracture needs to be irrigated in the OR.
- Any significant fracture/dislocation requires consultation with a hand surgeon.

DISTAL TUFT

- The distal tuft fracture is the most common hand fracture.
- Consider removing the nail for subungual hematoma > 50% of nail and repair nailbed laceration.
- Always replace the nail—use gauze stent if the nail is missing.
- Don't immobilize PIP with protective splinting.

PROXIMAL/MIDDLE PHALANX

- Transverse fractures usually are stable and can be buddy taped.
- Oblique fractures usually are unstable and require hand surgeon consult.
- Do not buddy tape unstable fractures.
- Any rotational deformity needs to be corrected.

METACARPAL

- Head fractures are uncommon, intraarticular, and require consultation.
- Any laceration over a metacarpal head should be evaluated as a fight bite.
- Neck fractures are common.
- Up to 40° of angulation can be tolerated in the ring and little fingers, but only 15° for index and middle fingers.
- Shaft fractures only can tolerate 20° for ring and little fingers and 10° for index and middle fingers.
- Any rotational deformity requires correction.

THUMB FRACTURES

- Phalanx fractures in the thumb are less common due to its mobility.
- Treat distal tuft and phalanx fractures as with the other fingers.
- Extraarticular metacarpal fracture can have up to 20° angulation.
- Intraarticular metacarpal base fractures are Bennet's or Rolando's fractures.

BENNET'S FRACTURES

- These are intraarticular base fractures with disruption of CMC joint.
- These are unstable fractures and require consult.
- Abductor pollicis longus pulls radial fragment dorsally.
- Bennet's fractures sometimes can be treated with a splint only, but they often require surgery.

ROLANDO'S FRACTURES

- These are comminuted Bennet's fractures of the metacarpal base.
- A Rolando's fracture has a worse prognosis than a Bennet's fracture.
- Treatment always is surgical, but these fractures can be splinted and followed up.

Close-up of Collateral Ligaments and Volar Plate

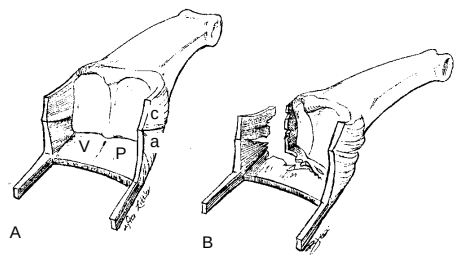

This diagram shows a close-up of collateral ligaments (a and c) and volar plate (VP) surrounding the finger joints. This box-like shape allows for maximum movement and stability of the joint. This figure shows how the ligaments and volar plate can be torn in dislocation.
Reprinted with permission: Rosen P, Barkin R, Hockberger R, et al., eds. *Rosen's Emergency Medicine: Concepts and Clinical Practice*. St. Louis: Mosby;1999:638.

Types of Fingertip Amputations and Their Treatments

Type I
Soft-tissue loss: Minimal
Bone loss: None
Nail/nail bed injury: None

Type II
Soft-tissue loss: Moderate
Bone loss: None
Nail/nail bed injury: None

Type III
Soft tissue loss: Major
Bone loss: Moderate
Nail/nail bed injury: None

Type IV
Soft-tissue loss: Major
Bone loss: Moderate
Nail/nail bed injury: Minor to major

Type V
Soft-tissue loss: None
Bone loss: Minimal
Nail/nail bed injury: Minor to major

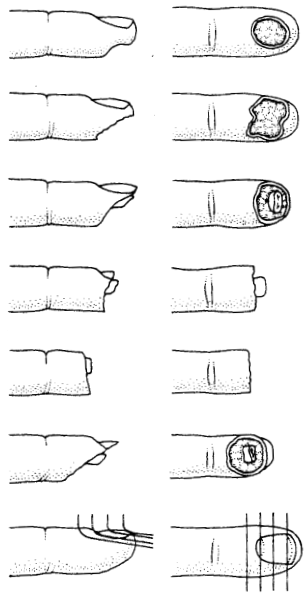

Treatment

Conservative managment

Conservative management, split-thickness skin graft

Split-thickness skin graft, operative procedure

Operative procedure

Conservative management, split-thickness skin graft

Reprinted with permission: Roberts J, Hedges J, eds. *Clinical Procedures in Emergency Medicine*. Philadelphia: Elsevier Science; 1998:801.

Example of Mallet Finger Deformity

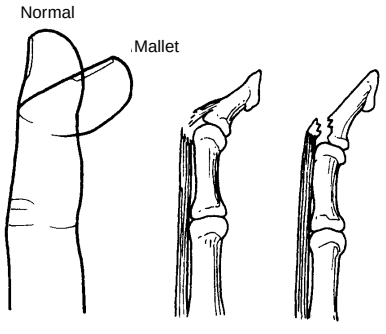

Reprinted with permission: Rosen P, Barkin R, Hockberger R, et. al, eds. *Rosen's Emergency Medicine: Concepts and Clinical Practice*. St. Louis: Mosby; 1999:655.

Zones of Flexor Tendons

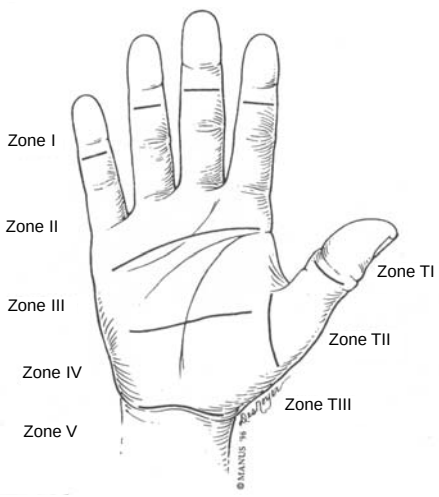

Reprinted with permission: Green DP. *Green's Operative Hand Surgery*, 4th ed. Philadelphia: Elsevier Science; 1999:1857.

Classification System for Fingertip Amputations

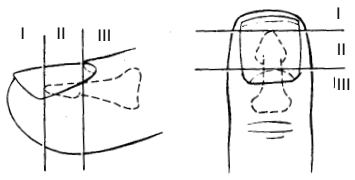

Reprinted with permission: Rosen P, Barkin R, Hockberger R, et al, eds. *Rosen's Emergency Medicine: Concepts and Clinical Practice*. St. Louis: Mosby;1999:658.

Indications and Contraindications for Replantation of Hand Amputations

ABSOLUTE INDICATIONS
- Pediatric patient

RELATIVE INDICATIONS
- Younger, stable patient
- Thumb amputation
- Multiple digits lost
- Sharp (guillotine) injury
- More proximal injuries

ABSOLUTE CONTRAINDICATIONS
- Associated injuries prevent surgery
- Severe crush injury of amputated tissue
- Comorbid conditions prevent surgery

RELATIVE CONTRAINDICATIONS
- Single finger (not thumb)
- Avulsion injury
- Multilevel amputation
- Prolonged warm ischemia time (> 6-12 hours)
- Prolonged cold ischemia time (> 24 hours)
- Gross contamination
- Previous injury or surgery of part
- Emotionally unstable patients

Zones of Extensor Tendons

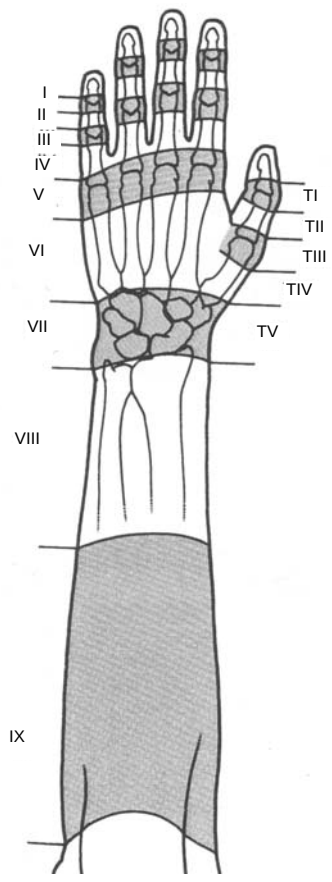

Reprinted with permission: Green DP. *Green's Operative Hand Surgery*, 4th ed. Philadelphia: Elsevier Science;1999:1956.

Supplement to *Emergency Medicine Reports*, November 18, 2002: "The Acute Hand: Assessment, Diagnosis, and Management in the ED Setting. Part II: Fractures and Neurovascular Injuries." *Author:* **Gary Hals, MD, PhD,** Attending Physician, Department of Emergency Medicine, Palmetto Richland Memorial Hospital, Columbia, SC.