AMERICAN HEALTH CONSULTANTS

SPORTS MEDICI REPORTS™

The essential guide to developments in sports medicine and orthopaedics

American Health Consultants Home Page—http://www.ahcpub.com

CME for Physicians—http://www.cmeweb.com

Arthroscopic Rotator Cuff Repair

By Brian J. Cole, MD, MBA, and Stephen J. Lee, BA

With improved understanding of rotator cuff pathology and the availability of arthroscopic instrumentation specifically designed for soft tissue repair techniques, rotator cuff repairs have evolved from a classic open approach to a mini-open (or deltoid-sparing) approach, and finally to an all-arthroscopic technique. Benefits of arthroscopic rotator cuff repair include decreased pain, avoidance of deltoid manipulation, and optimization of the rehabilitation process.

Indications

Indications for arthroscopic repair are similar to those with other approaches. Decision-making must take into account the following:[1,2] (1) Size of tear and degree of retraction. Initially, arthroscopic repair was limited to small to medium tears (< 5 mm) with < 2 cm of retraction.[2,3] With improved arthroscopic techniques for mobilization and suture placement, the indications now include larger tears. (2) Quality of tissue. The cuff tendon must securely hold suture. (3) Quality of bone. Similarly, the bone must allow for secure anchor fixation. The skills of the surgeon must also be taken into consideration, as this is a technically demanding procedure.

Patient Positioning / Portal Placement

Although the lateral decubitus position may be used, I prefer the beach-chair position due to its ease of setup, familiar orientation, and capability to convert to an open procedure. Standard 3-portal arthroscopy is performed. A fourth accessory anterolateral portal is established about 5 mm off the anterolateral corner of the acromion to facilitate anchor placement, suture management, and most importantly, arthroscopic knot tying.

Operative Technique

A systematic evaluation of the glenohumeral joint is followed by subacromial decompression. Accurate recognition of the tear pattern (crescent, "U", "L") helps determine the most effective treatment strategy. Crescent-shaped tears are repaired by reattaching the free margin directly to bone with sutures from laterally placed suture

Volume 5 • Number 3 • March 2003 • Pages 17-28

INSIDE

anchors. For U- and L-shaped tears, side-to-side suture placement from medial to lateral (margin convergence) is followed by securing the lateral tendon edge and anterolateral corner (L-shaped tear) to bone using suture anchors.

Margin Convergence[4] (*see Figure 1*)

Method 1—Anterograde Suture Passage. A soft-tissue penetrator loaded with braided suture is passed through the posterior portal, penetrating both the posterior and anterior leaflets simultaneously. A crochet hook passed through the anterior portal retrieves the suture limb from the penetrator and the trailing limb from the posterior leaflet. The suture is then tied in line through the anterior portal.

Method 2—Anterograde Suture Hand-Off. A soft-tissue penetrator loaded with braided suture is passed through the posterior portal penetrating only the posterior leaflet, and a second penetrator is placed through the anterior portal meeting in the middle of the field of view. The suture is then dropped by the posterior penetrator and picked up by the anterior penetrator and pulled out the anterior portal. The remaining steps are similar to Method 1.

Figure 1.
Four Methods to Achieve Margin Convergence

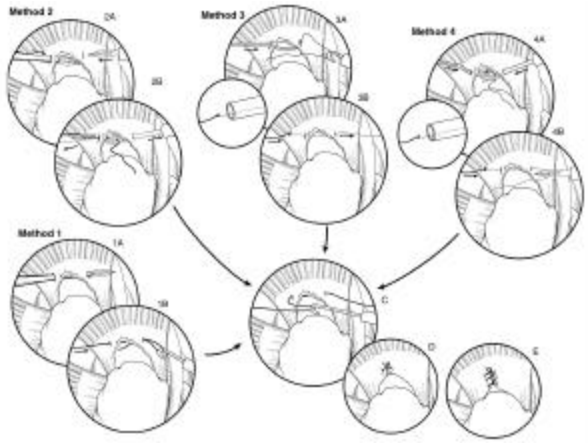

Reprinted from Fu FH, Williams GR, eds. *Operative Techniques in Orthopaedics*, Figure 5, 12:167-175, ©1998 with permission from Elsevier Science.

Method 3—Retrograde Suture Shuttle. A suture shuttling device loaded with a #0 or #1 monofilament suture is used to shuttle a suture through the posterior and anterior leaflet. The monofilament suture is then advanced and retrieved through the anterior portal by the crochet hook. A permanent suture is then tied to the free monofilament suture end outside the anterior portal, and the shuttling device and monofilament are withdrawn through the posterior portal. This effectively "shuttles" the permanent suture through both leaves of the rotator cuff. A crochet hook passed through the anterior portal retrieves the suture limb from the posterior leaflet. The suture is then tied in line through the anterior portal.

Method 4—Retrograde Suture Shuttle Hand-Off. A suture shuttling device loaded with a #0 or #1 monofilament suture is passed through the posterior portal through the posterior leaflet. A straight soft tissue penetrator is placed through the anterior portal and the anterior leaf of the rotator cuff to retrieve the monofilament suture as it is advanced through the shuttle. The remaining steps are identical to Method 3.

Anchor Placement and Suture Management

Anchors are placed from posterior to anterior approximately 5-10 mm lateral to the articular surface of the humerus and at a 45° angle in order to increase resistance to pull-out.[5] Separating each anchor by approximately 5-8 mm will proportionally distribute fixation over the entire insertion site and minimize excessive tension at any single fixation point.[6,7] Optimal suture management is achieved by placing 1 anchor at a time, securing the tendon to the bone with both sutures before plac-

Sports Medicine Reports, ISSN 1524-0991, is published monthly by American Health Consultants, 3525 Piedmont Rd., NE, Bldg. 6, Suite 400, Atlanta, GA 30305.
VICE PRESIDENT/GROUP PUBLISHER: Brenda Mooney.
EDITORIAL GROUP HEAD: Glen Harris.
MANAGING EDITOR: Robin Mason.
ASSISTANT MANAGING EDITOR: Robert Kimball.
SENIOR COPY EDITOR: Christie Messina.
MARKETING PRODUCT MANAGER: Schandale Kornegay.
GST Registration Number: R128870672.
Periodical postage pending at Atlanta, GA.
POSTMASTER: Send address changes to ***Sports Medicine Reports***, P.O. Box 740059, Atlanta, GA 30374.

Back issues: $37. Missing issues will be fulfilled by Customer Service free of charge when contacted within one month of the missing issue's date.

THOMSON
AMERICAN HEALTH CONSULTANTS

Questions & Comments

Please call **Robin Mason,** Managing Editor, at (404) 262-5517; or e-mail: robin.mason@ahcpub.com or **Christie Messina**, Senior Copy Editor, at (404) 262-5416; or e-mail: christie.messina@ahcpub.com between 8:30 a.m. and 4:30 p.m. ET, Monday-Friday.

Subscriber Information
Customer Service: 1-800-688-2421.
Customer Service E-Mail Address: customerservice@ahcpub.com
Editorial E-Mail Address: christie.messina@ahcpub.com
World-Wide Web: http://www.ahcpub.com

Subscription Prices
United States
$269 per year (Student/Resident rate: $108).
Multiple Copies
1-9 additional copies: $197 each. 10-20 copies: $175 each.
Canada
Add GST and $30 shipping.
Elsewhere
Add $30 shipping.

Accreditation

American Health Consultants (AHC) designates this continuing medical education (CME) activity for up to 25 hours of category 1 credit toward the AMA Physician's Recognition Award.

Each physician should claim only those hours of credit that he/she actually spent in the educational activity.
This CME activity was planned and produced in accordance with the ACCME Essentials.
AHC is accredited by the Accreditation Council for Continuing Medical Education (ACCME) to provide continuing medical education for physicians.

Statement of Financial Disclosure

In order to reveal any potential bias in this publication, and in accordance with Accreditation Council for Continuing Medical Education guidelines, we disclose that Dr. Diduch serves as a consultant to DePuy and Mitek. Dr. Cole serves as a consultant to Mitek and Genzyme, serves on the speaker's bureau of Oratec, and does research for Oratec and Mitek. Dr. Schenck does research for Howmedica. Dr. Colman, Dr. Griffin, Dr. Holmes, Dr. Miller, Dr. Perrin, Dr. Safran, Dr. Warner, Dr. McFarland, and Dr. Slauterbeck report no consultant, stockholder, speaker's bureau, research, or other financial relationships with companies having ties to this field of study.

ing the next anchor, and using the accessory anterolateral portal as a dedicated knot-tying portal. Suture tying is always performed through cannulas, but suture-passing devices can be passed directly through skin portals. Sutures are retrieved through soft tissue using penetrating or shuttle devices as depicted in Figure 2.

Results

Early results from arthroscopic repair of full-thickness cuff tears were satisfactory and paralleled the results reported for traditional open repair. Several recent follow-up studies corroborate these results. Gartsman and associates[8] reported on 73 arthroscopic rotator cuff repairs with a mean follow-up of 30 months resulting in 84% good or excellent outcomes. Burkhart and colleagues[9] published results of 59 arthroscopic rotator cuff repairs with an average follow-up of 3.5 years leading to 95% good or excellent results, regardless of tear size. Murray and associates[10] studied 48 arthroscopic repairs with 2-6 year follow-up, which resulted in 46 good or excellent results and 1 failed repair. These medium-term follow-up studies lend further support to the position that arthroscopic rotator cuff repairs can provide outcomes and patient satisfaction similar to or greater than those achieved by open repair in the hands of an experienced shoulder arthroscopist. ■

Figure 2.

Methods of Suture Placement Following Anchor Placement

A. Anchors placed laterally, suture from first set retrieved from posterior using soft tissue penetrating device. Suture mate then retrieved from posterior to prevent suture tangling; B. Second suture set passed similar to first and both limbs retrieved through anterolateral portal for tying. Steps repeated for additional anchors.

Figure 2A Figure 2B

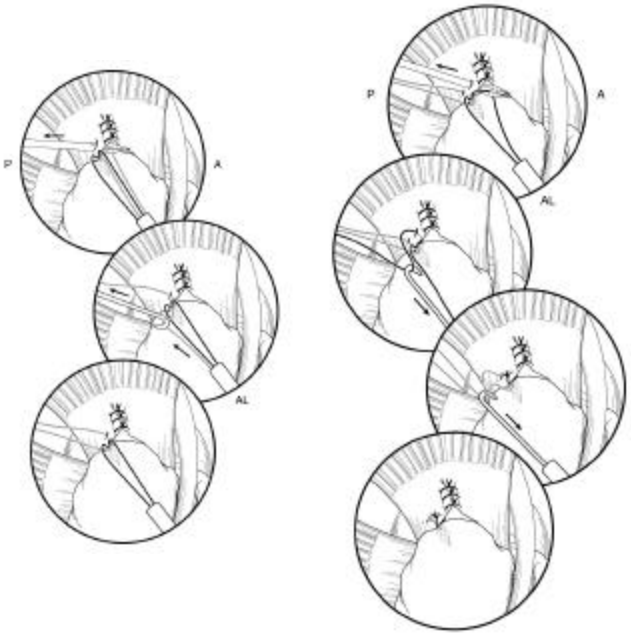

Reprinted from Fu FH, Williams GR, eds. *Operative Techniques in Orthopaedics*, Figures 6 and 7, 12:167-175, ©1998 with permission from Elsevier Science.

References

1. Yamaguchi K, et al. Transitioning to arthroscopic rotator cuff repair: The pros and cons. *J Bone Joint Surg Am*. 2003; 85A:144-155.
2. Stollsteimer GT, Savoie FH 3rd. Arthroscopic rotator cuff repair: Current indications, limitations, techniques, and results. *Instr Course Lect*. 1998;47:59-65.
3. Baker CL, Liu SH. Comparison of open and arthroscopically assisted rotator cuff repairs. *Am J Sports Med*. 1995;23:99-104.
4. Mazzocca AD, Cole BJ, Romeo AA. Arthroscopic repair of full-thickness rotator-cuff tears: Surgical technique. *Op Tech Orthop*. 2002;12:167-175.
5. Burkhart SS. Technical note. The deadman theory of suture anchor: Observations along a South Texas fence line. *Arthroscopy*. 1995;11:119-123.
6. Burkhart SS. A stepwise approach to arthroscopic rotator cuff repair based on biomechanical principles. *Arthroscopy*. 2000;16:82-90.
7. Burkhart SS. Reconciling the paradox of rotator cuff repair versus debridement: A unified biomechanical rationale for the treatment of rotator cuff tears. *Arthroscopy*. 1994;10:4-19.
8. Gartsman GM, Khan M, Hammerman SM. Arthroscopic repair of full-thickness tears of the rotator-cuff. *J Bone Joint Surg Am*. 1998;80:832-840.
9. Burkhart SS, Danaceau SM, Pearce CE Jr. Arthroscopic rotator cuff-repair: Analysis of results by tear size and by repair technique-margin convergence versus direct tendon-to-bone repair. *Arthroscopy*. 2001;17:905-912.
10. Murray TF Jr, et al. Arthroscopic repair of medium to large full-thickness rotator cuff tears: Outcome at 2- to 6-year follow-up. *J Shoulder Elbow Surg*. 2002;11:19-24.

Stephen J. Lee, BA, Northwestern University Feinberg School of Medicine, Chicago, Ill.

Selection and De-Selection of Treatment Options For Massive Cuff Repairs

By Jon J.P. Warner, MD, Edward H. Yian, MD, and Phillipe Clavere, MD

Open repair of rotator cuff tears has been a time-tested technique based on fundamental princi-

ples. Neer originally proposed 4 major objectives: cuff defect closure, elimination of impingement lesions of the coracoacromial arch, deltoid muscle preservation, and early rehabilitation without disrupting the repair.[1] With recent arthroscopic technology advancements, the decision between open and arthroscopic repair has become less clear. The selection of the appropriate mode of treatment, however, is critical in optimizing patient outcome and involves consideration of preoperative, intraoperative, and postoperative factors.

Preoperative

Patient expectations of outcomes must be tempered with associated factors. One must consider the overall disability that includes the quantity of pain, functional limitations, and overall goals. Comorbidities such as muscle spasticity, seizure disorders, and diabetes mellitus can all affect the end result. In addition, both clinical and biomechanical studies have shown that well-compensated function can still remain despite the presence of a large cuff tear.

The quality of both the deltoid and rotator cuff influences the prognosis for success. Deltoid function contributes up to 60% of strength in abduction and elevation. Poor outcome has clearly been associated with deltoid detachment co-existing with a rotator cuff tear. Furthermore, the extent of atrophy and fatty degeneration within the muscle bellies of the torn tendons is associated with the overall tendon quality and elasticity. Overall shoulder function and external rotation strength have been correlated by Goutallier and colleagues with the degree of fatty degeneration and muscle atrophy.[2] This atrophy and fatty degeneration is believed to be irreversible, despite surgical treatment. Similar observations have been made with magnetic resonance imaging, particularly with T1 oblique sagittal images medial to the coracoid process. Evidence of severe atrophy and fatty degeneration indicates that restoration of pre-injury biomechanics will not be possible, and other options, such as tendon transfers, may be needed. In massive tears with decreased acromiohumeral intervals or chronic anterosuperior lesions, arthroscopic subacromial debridement may be an option, primarily for pain relief.

Evaluation of preoperative range of motion is imperative. If passive range of motion is significantly limited in a patient with a large cuff tear, then both adhesive capsulitis and rotator cuff tear must be treated. With massive tears, Warner has had good experience (unpublished data) with staged arthroscopic capsular release and subsequent rotator cuff repair. Smaller tears can be treated with concurrent capsular release, if a strong, stable repair is achieved, to allow for immediate postoperative range of motion. Otherwise, excess strain on the repair can lead to re-tear.

Intra-Operative Considerations

Other factors integral to the success of repair include the quality of the cuff tendon and bone. Patients with chronic tears who have had multiple steroid injections may have poor structural tendon integrity. Gerber and associates have shown that a modified Mason-Allen stitch does not cause tendon necrosis and yields a stronger repair than standard open techniques.[3] Osteoporosis of the proximal humerus can compromise the repair strength regardless of the use of suture anchors or even transosseous tunnels. In this scenario, poor bone quality is the weakest link in the chain. The strongest bone lies distal to the greater tuberosity. It is recommended that sutures exit tunnels at least 1-2 cm distal to the greater tuberosity with more than a 1-cm bone bridge and that a cortical augmentation device be used.[4] Transosseous simple suture repair is the recommended technique in order to maximize repair site area leading to a potentially stronger repair and increased healing.[5]

Tendon mobilization and evaluation of structural integrity is essential to characterizing the tear. Chronic tears often have more retraction, tendon involution, loss of structural integrity, and increased stiffness from scarring and fatty degeneration. Scarred cuff tissue adherent to the acromion underside can be difficult to differentiate from bursal tissue. The inflamed bursal tissue, as well as degenerative tendon edges, must be excised to provide a healthy, vascularized tendon edge. Both intra-articular and extra-articular releases must be performed to maximize tendon mobility, including rotator interval and perilabral releases. The amount of tendon delamination must be recognized and appropriately repaired to restore tendon structure. This can often be very difficult to evaluate arthroscopically. Lamination defects treated either by resection or by interlaminar repair have been shown to fare equally, regardless of repair technique.[6] These defects have been found to be more common in cuff tears less than 5 cm in size. Lastly, deficient cuff tissue can be augmented with surrounding soft tissues (eg, biceps tendon) to reinforce the deficient tissue.

Postoperative Considerations

Patient noncompliance with early active range of motion can lead to failure of the repair, while a lack of early passive range of motion can lead to shoulder stiffness. Overall patient health and comorbidities should be considered in deciding appropriate rehabilitation needs. An elderly patient with limited functional goals would be ill suited for a latissimus tendon transfer, while a young laborer would require more than a cuff debridement.

Conclusion

Proper decision-making requires a consideration of all patient factors. Management options vary from nonsurgical treatment to partial repair to arthroscopic or open repair to tendon transfers. While these patients are often debilitated due to chronic pain and altered shoulder mechanics, a satisfying and predictable functional outcome can be achieved with the appropriate treatment. ■

Dr. Warner is Director at Harvard Shoulder Service, Department of Orthopedic Surgery, Massachusetts General Hospital, Boston, Mass. Drs. Yian and Clavere are Fellows.

References

1. Neer CS. *Cuff Tears, Biceps Lesions, and Impingement In Shoulder Reconstruction*. Philadelphia: WB Saunders; 1990:41-142.
2. Goutallier D, et al. Fatty muscle degeneration in cuff ruptures. *Clin Orthop*. 1994;304:78-83.
3. Gerber C, et al. Experimental rotator cuff repair. A preliminary study. *J Bone Joint Surg Am*. 1999;81:1281-1290.
4. Caldwell GL, et al. Strength of fixation with transosseous sutures in rotator cuff repair. *J Bone Joint Surg Am*. 1997;79(7):1064-1068.
5. Apreleva M, et al. Rotator Cuff Tears: The effect of the reconstruction area on three-dimensional repair site area. *Arthroscopy*. 2002;18(5):519-526.
6. Sonnabend DH, Watson EM. Structural factors affecting the outcome of rotator cuff repair. *J Shoulder Elbow Surg*. 2002;11:212-218.

Maximizing Results of Mini-Open Cuff Repair by Increasing Footprint Contact

By Edward G. McFarland, MD, Tae Kyun Kim, MD, PhD, and Atsushi Yokota, MD, PhD

While arthroscopic rotator cuff repair techniques have received increasing attention over the past decade, there are many options for the surgeon who treats rotator cuff disease. Open repair remains the "gold standard," but combined arthroscopic and mini-open techniques bridge the gap between purely open and purely arthroscopic techniques. There are many variables, involving both patient and surgeon, to consider when discussing any technique for repairing a torn rotator cuff. We believe that open and mini-open techniques remain a reasonable technique for most surgeons, and like many surgeons, in our hands these techniques provide the greatest latitude in treating rotator cuff disease.

Any discussion of the treatment of rotator cuff disease should be tempered by new knowledge in this area. The traditional concept of external or subacromial impingement as popularized by Neer has been questioned, and new concepts of rotator cuff disease include normal tendon senescence, internal impingement of the cuff against the superior glenoid, coracoid impingement, and tension overload. These competing theories reflect the uncertainty over what produces cuff tears and the pain that accompanies cuff disease. There is also increasing appreciation that the coracoacromial ligament is not a vestigial structure and along with the acromion prevents anterior-superior subluxation.[1] Some have suggested that acromioplasty and coracoacromial ligament release are not necessary in all cases. Lastly, the deltoid attaches to the acromion via direct tendinous attachment; thus, arthroscopic acromioplasty releases some deltoid muscle by definition. The amount of deltoid released by any technique is only 1 of many factors influencing the surgical result, but most studies demonstrate that the major factor is the size of the rotator cuff tear. We do not hesitate to use open techniques for any tear due to these factors.

For the surgeon who has the training and experience to perform arthroscopic acromioplasties, there are several options for repairing torn rotator cuff tendons. The first option is to expand the lateral arthroscopy portals either vertically or in line with the skin creases horizontally. We prefer the latter since it is more cosmetically acceptable and can be more easily extended if more exposure is needed. The deltoid is then split in line with its fibers but not detached from the acromion. The cuff tear can be repaired to the tuberosity using either suture anchors, transosseous sutures through the greater tuberosity, or both. A second approach has been called the "advanced mini-open approach," which is promoted as a transition to all arthroscopic techniques. In this case, arthroscopic techniques are used to release adhesions and to place retention sutures in the cuff edges, and then a traditional mini-open repair is performed.[2]

Several studies have demonstrated that mini-open techniques have results similar to open techniques for small, medium, and large tears.[3,4] Mini-open techniques are possible for massive tears, but the limited exposure makes mobilization and repair of tears this size difficult. Mini-open techniques are not indicated for repair of multiple tendons, particularly the subscapularis tendon. Lastly, tendon transfers such as with the pectoralis or latissimus cannot be accomplished with this approach.

There are several advantages to mini-open tech-

niques. First, the surgeon does not need advanced arthroscopic skills except the ability to perform an arthroscopic acromioplasty and coracoacromial ligament release. Secondly, there is some evidence that sutures tied by hand have less creep than arthroscopic knots. Third, mini-open techniques are easily expanded by release of portions of the deltoid. Lastly, the learning curve is shorter and operative time may be shorter for surgeons who do not have the facilities or competent assistants available.

Open and mini-open techniques also offer the surgeon the ability to increase the rotator cuff tendon contact back to the "footprint" of the tendon on the greater tuberosity. Studies have shown that the rotator cuff tendons, particularly the supraspinatus, do not have 1 point of fixation but rather attach to the greater tuberosity over a broad area (*see Figure 3A*).[5] The goal of surgery is to provide secure fixation to as much of the tendon as possible. As a result, several techniques have been devised to increase contact of the rotator cuff to the footprint. The first is to place 2 rows of transosseous sutures, but this increases the possibility of sutures being cut or of sutures losing fixation in the tuberosity. The second is to place a row of suture anchors medially and transosseous sutures laterally (*see Figure 3B*).[3] This technique allows the use of transosseous sutures that have been found to increase contact to the footprint.[6] This is currently our preferred method of repair of rotator cuff tendons whether the repair is performed open or as a mini-open technique. In cases where the tendon contact is still not as good as desired, we will tie the sutures from the lateral side of the humerus to the sutures from the suture anchors, which has the effect of pulling the lateral tendon edge directly into contact with the bone. Optimizing contact of the rotator cuff to the footprint can be easily accomplished with mini-open techniques that are within the technical expertise of most surgeons. ■

Figure 3.

3A. Rotator cuff footprint **3B. Footprint reproduced with repair**

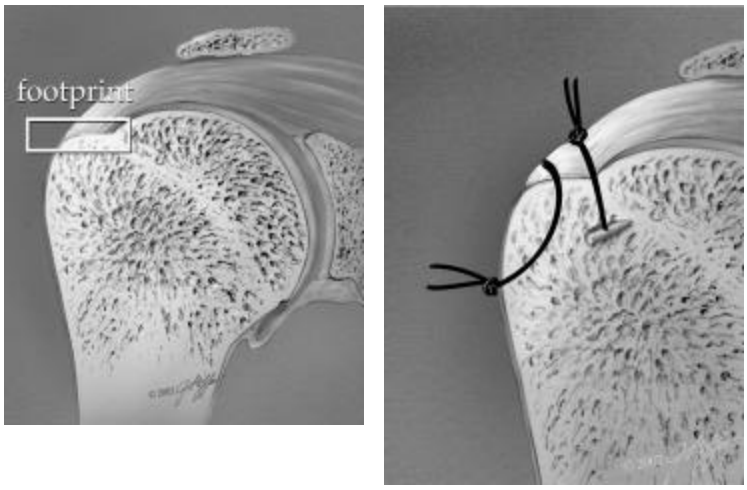

Reprinted from Judith A. Stoffer, MA. © 2002.

Drs. McFarland, Kim, and Yokota, Division of Sports Medicine and Shoulder Surgery, Department of Orthopaedic Surgery, The Johns Hopkins University, Baltimore

References

1. Lee TQ, et al. Release of coracoacromial ligament can lead to glenohumeral laxity: A biomechanical study. *J Shoulder Elbow Surg*. 2001;10:68-72.
2. Yamaguchi K, et al. Arthroscopic rotator cuff repair. Transition from mini-open to all-arthroscopic. *Clin Orthop*. 2001;390:83-94.
3. Fealy S, Kingham TP, Altchek DW. Mini-open rotator cuff repair using a two-row fixation technique: Outcomes analysis in patients with small, moderate, and large rotator cuff tears. *Arthroscopy*. 2002;18:665-670.
4. Shinners TJ, et al. Arthroscopically assisted mini-open rotator cuff repair. *Arthroscopy*. 2002;18:21-26.
5. Dugas JR, et al. Anatomy and dimensions of rotator cuff insertions. *J Shoulder Elbow Surg*. 2002;11:498-503.
6. Apreleva M, et al. Rotator cuff tears: The effect of the reconstruction method on three-dimensional repair site area. *Arthroscopy*. 2002;18:519-526.

Point/Counterpoint: Arthroscopic vs Open Bankart Surgery

Arthroscopic Reconstruction for Shoulder Instability

By COL Patrick St. Pierre, MD

Is it time to recommend arthroscopic shoulder reconstruction for every patient? Arthroscopic techniques have improved significantly and gained in popularity over the past few years, but does the literature support abandoning open reconstruction?

Open shoulder reconstruction has been the accepted surgical intervention for recurrent anterior instability for over a century. Many procedures have been advocated, including labral repair (Bankart), capsular shift (Neer),

capsular and subscapularis shortening (Magnuson-Stack and Putti-Platt), and bone-block tendon transfer (Bristow). Nonanatomic reconstructions initially were thought to produce results similar to the anatomic Bankart repair but were easier to perform. These have fallen out of favor because of higher recurrence rates and complications such as the development of glenohumeral arthritis. Today, most surgeons advocate direct labral repair, retensioning of the lengthened capsular ligaments, and closure of the rotator interval if indicated. This approach has generally been accepted as the "gold standard" for which to compare other techniques. Recurrence rates following open Bankart reconstructions have been thought to be very low, with Bankart reporting 0%,[1] Morrey 11%,[2] and Rowe 3.5%.[3] However, these reports had variable follow-up and did not include recurrent subluxation as failures.

Recent studies have questioned whether the results of open reconstruction are really as good as touted, especially if maintaining external rotation and preventing subluxations are required for success. Chapnikoff and associates[4] recently reported a redislocation rate of 9.5% after 16 years, with a 76% follow-up after open reconstruction. Uhorchak and colleagues[5] reported a 23% redislocation and resubluxation rate in West Point cadets who must return to a very high level of physical activity. Most recently, Magnusson and colleagues[6] reported a 17% recurrence rate at a 4- to 9-year follow-up of 47 of 54 patients.

Early arthroscopic techniques were met with high failure rates and surgeon dependant results. Transglenoid techniques and the arthroscopic use of staples also had high complication rates. This led to the development of bioabsorbable tacks and the use of suture anchors to allow a more anatomic repair and reduce the complications caused by exposed metal in the joint. The higher failure rate of these early arthroscopic reconstructions has been attributed to the failure to restore the labrum to the edge of the glenoid. With both the transglenoid technique and the staple, the point of fixation on the glenoid was medial to the edge, failing to recreate the bumper effect of the labrum and failing to properly tension the inferior glenohumeral ligament.

The most recent technique for arthroscopic Bankart repair is to use suture anchors to repair the labrum to the rim of the glenoid. Early results are mixed, with Koss and associates[7] reporting a 30% recurrence rate. Seven of the 8 patients with recurrence had a traumatic event and there was a higher rate in patients with more than 5 presurgical dislocations. Hoffman and colleagues[8] reported a recurrence of 13%, and Bacilla and associates[9] reported a 7% redislocation rate in athletes and laborers. Cole and associates[10] found no difference between arthroscopic and open reconstructions if the pathology determined the type of treatment. Patients with Bankart lesions and unidirectional instability underwent arthroscopic reconstruction, while those with multidirectional instability underwent open reconstruction.

Current arthroscopic reconstruction techniques advocate the placement of the suture anchor on the articular surface of the glenoid, thus restoring the bumper effect of the labrum and allowing proper retensioning of the ligament. While the labrum does not heal to the articular surface and may remodel with time, its placement there allows the ligament to heal properly along the exposed bone of the freshened medial glenoid. If the ligaments are still lax after Bankart repair, the capsule should be addressed with plication or thermal shrinkage to restore the proper tension of the ligament. This is commonly done with open surgery by adding a capsular repair following the repair of the labrum. Therefore, the goal in either open or arthroscopic reconstruction is to repair the torn labrum and inferior glenohumeral ligament complex to the glenoid to create the most anatomic repair possible.

This review of the literature indicates that we may not have been as good as once thought with open Bankart reconstructions, and we are getting better with our arthroscopic reconstructions. We have to ask why one has been better than the other. Higher arthroscopic recurrence rates initially were likely due to the labrum not being anatomically repaired, and I think we now can achieve that. High recurrence rates, even with anatomic labral repair, may have been due to failure to adequately address increased capsular volume and/or the rotator interval. If the anatomic repair of labrum to the glenoid is the same and we can tension the capsule equally with both methods, then the results should be the same. The key to arthroscopic instability surgery is to do the repair as well, if not better than open surgery. Studies reveal that patients with multidirectional instability, with more than 5 dislocations, and patients returning to contact sports are at higher risk for failure with any reconstruction. This needs to be taken into consideration and an arthroscopic repair must be perfect in these patients. Capsular laxity must be addressed in addition to the Bankart repair.

Therefore, I plan an arthroscopic reconstruction for every instability patient I take to the operating room. I consent every patient to convert to an open repair if necessary. My goal is to restore the labrum and global capsular tension to its original state. If I am not able to do so, especially with a patient returning to a contact sport, I

will convert to an open reconstruction. Every surgeon needs to tailor this to his or her own experience and ability. The decision to reconstruct the shoulder arthroscopically or open is dependent on pathology present and the surgeon's ability to address that pathology by the best method possible. ■

References

1. Bankart AB. The pathology and treatment of recurrent dislocation of the shoulder joint. *Br J Surg*. 1938;26:23-29.
2. Morrey BF, Janes JM. Recurrent anterior dislocation of the shoulder. Long-term follow-up of the Putti-Platt and Bankart procedures. *J Bone Joint Surg Am*. 1976;58A:252-256.
3. Rowe CR, et al. The Bankart procedure: A long-term end-result study. *J Bone Joint Surg Am*. 1978;60A:1-16.
4. Chapnikoff D, et al. Bankart procedure: Clinical and radiological long-term outcome [in French]. *Rev Chir Orthop Reparatrice Appar Mot*. 2000;86:558-565.
5. Uhorchak JM, et al. Recurrent shoulder instability after open reconstruction in athletes involved in collision and contact sports. *Am J Sports Med*. 2000;28:794-799.
6. Magnusson L, et al. Revisiting the open Bankart experience: A four- to nine-year follow-up. *Am J Sports Med*. 2002;30: 778-782.
7. Koss S, et al. Two to five-year followup of arthroscopic Bankart reconstruction using a suture anchor technique. *Am J Sports Med*. 1997;25:809-812.
8. Hoffmann F, Reif G. Arthroscopic shoulder stabilization using Mitek anchors. *Knee Surg Sports Traumatol Arthrosc*. 1995;3:50-54.
9. Bacilla P, Field LD, Savoie FH 3rd. Arthroscopic Bankart repair in a high demand patient population. *Arthroscopy*. 1997;13:51-60.
10. Cole BJ, et al. Prospectively determined arthroscopic versus open shoulder stabilization: A 2-6 year follow-up. *J Shoulder Elbow Surg*. 1998;7:3-13.

Open Repair for Shoulder Instability

By Mark D. Miller, MD

Although shoulder arthroscopy has become very popular and has been advocated for instability, there is often no substitute for an open procedure. There are several reasons for this, including the ability to address associated capsular laxity and to anatomically correct labral avulsions, the capability to visualize and accurately treat rotator interval lesions, and the capacity to address bony defects of both the glenoid and humerus. Perhaps most importantly, open procedures have a better record of success—that is why it remains the gold standard for the treatment of shoulder instability!

Shoulder dislocations, especially repetitive dislocations, are associated with capsular plastic deformation.[1] Capsular laxity is difficult to address arthroscopically, and this may explain higher failure rates in some series. Treatment of associated laxity with thermal devices has been met with mixed results and a variety of complications including tissue necrosis. Arthroscopic plication procedures are in their infancy and are too technically demanding for most surgeons. An open capsulorraphy is a well-established procedure that can reduce capsular volume up to 50%.[2]

Several researchers have demonstrated difficulty with accurate restoration of the normal glenoid-labrum interface with suture anchors. Medial placement of the labrum results in a condition similar to a chronic ALPSA lesion with healing to the neck of the glenoid. Arthroscopic knot tying is a skill that is not easily mastered, and knot slippage is common. Other technical difficulties, including soft tissue entrapment, suture management, and accurate placement of anchors and sutures, can be avoided with open procedures.

Rotator interval lesions are virtually impossible to visualize arthroscopically. Large openings in this region have been associated with recurrent instability.[3] Identification and closure of these lesions (with imbrication) is very easy during open procedures.

Large bony Bankart lesions and Hill-Sachs lesions have been associated with a higher incidence of failure following surgical treatment of shoulder instability. Although a variety of procedures have been described to address these lesions (including osteotomies and bone grafting), none of them are arthroscopic techniques.

A variety of arthroscopic procedures have been described for shoulder instability. The earliest attempts at arthroscopic treatment involved the use of metal staples. Unfortunately, the recurrence rate for these procedures often approached 30%, and pain was present in approximately 50% of the patients.[4] Complications including staple breakage, migration, cartilage injury, and infection contributed further to the abandonment of this procedure. The transglenoid suture technique developed by Morgan and popularized by Caspari was very successful for these investigators but was fraught with complications (including suprascapular nerve injury and tissue necrosis). It was nowhere near as successful when other arthroscopists used this technique, and failure rates as high as 44% have been reported.[5] Next came bioabsorbable tacks, with failure rates of up to 20% and intracapsular synovial reactions in approximately 6% of cases.[6] Current techniques, which typically involve suture anchors, have reduced the failure rates and complications, but double-digit recurrence rates are still

commonly reported. If you look just at comparative studies between arthroscopic and open stabilization procedures, the average recurrence rate for arthroscopic procedures is approximately 15%, and the rate for open procedures is approximately 5%.[7] Which rate would you prefer if it were your shoulder?

In summary, for a variety of reasons, open procedures for recurrent anterior shoulder instability continue to be the gold standard. Open procedures can better address capsular laxity, labral tears, rotator interval lesions, and bony defects. It is difficult to construct a long-term study of arthroscopic stabilization procedures because the procedures constantly change and newer techniques and devices are presented at every meeting and in every exhibitor booth. That is because they are constantly in need of improvement! Techniques for open Bankart repair and capsulorraphy do not change—because they have a long track record of success. To put it simply, they work! ■

References

1. Bigliani L, et al. Tensile properties of the inferior glenohumeral ligament. *J Orthop Res.* 1992;10:187-197.
2. Miller MD, et al. Capsular volume reduction with open capsular shift procedures—A cadaveric study. *J Shoulder Elbow Surg.* In Press.
3. Field LD, et al. Isolated closure of rotator interval defects for shoulder instability. *Am J Sports Med.* 1995;23:557-563.
4. Johnson L. *Diagnostic and Surgical Arthroscopy of the Shoulder.* St Louis, MO: Mosby-Year Book; 1993:276-364.
5. Grana WA, et al. Arthroscopic Bankart suture repair. *Am J Sports Med*. 1993;21:348-353.
6. Edwards D, et al. Adverse reactions to an absorbable shoulder fixation device. *J Shoulder Elbow Surg*. 1994;30:230-233.
7. Cole BJ, Warner JJ. Arthroscopic versus open bankart repair for traumatic anterior shoulder instability. *Clin Sports Med.* 2000;19(1):19-48.

SLAP Lesions and Instability

By David R. Diduch, MS, MD

Slap (superior labrum anterior to posterior) lesions involve injuries to the superior labrum with varying degrees of avulsion of the long head of the biceps attachment. SLAP lesions can be difficult to diagnose, difficult to treat, and difficult to determine in importance. A commonly accepted classification system includes 4 types. Type I lesions involve degenerative fraying of the superior labrum, which may be a normal consequence of aging. Simple arthroscopic debridement is sufficient for what may be a diagnosis that is overdone. Type III lesions involve a bucket handle tear of the labrum that mechanically catches while the biceps anchor is preserved. Simple debridement of the impinging labrum is sufficient. Lesions that compromise the biceps anchor, including Type II and Type IV lesions, are most important clinically and the focus of this review.

SLAP lesions generally occur by either traction or compression.[1] Compression injuries can involve a fall onto an outstretched, partially abducted arm. Traction injuries may occur from a sudden longitudinal pull on the arm, such as a water skiing injury or trying to catch oneself from a fall. In addition, overhead throwing athletes can create or worsen a superior labral detachment through torsion on the biceps anchor that has been termed the "peel-back mechanism."[2] When the arm is brought into the cocking phase for throwing, the biceps anchor is torqued and the labrum can be "peeled-back" over the glenoid rim.

The diagnosis is frequently both difficult and delayed. The most common physical findings are pain with forward elevation (Neer maneuver) and palpable popping or snapping with shoulder motion, or pain in the same abducted, externally rotated position that is provocative for anterior stability.[1] Additional tests that may be helpful may include the Speed test and O'Brien test for the anterior variant of Type II lesions, and posterior pain on the Jobe relocation test for posterior Type II variants.[3] More often than not, however, the examiner has just a suggestion of biceps involvement prompting an MRI. The sensitivity of the MRI may be enhanced by the use of intra-articular contrast. The diagnosis is never certain until diagnostic arthroscopy is performed. Even then, the anatomic variability encountered at arthroscopy can make the diagnosis difficult.

What to do with SLAP lesions hinges upon what problems they cause. It is important to understand that the entire labrum and biceps anchor attachment circling the glenoid work together to preserve shoulder stability. Unlike Bankart lesions anteriorly that result in full dislocations, detachment of the labrum superiorly never manifests in gross instability because the acromion prevents upward dislocation. Instead, the subtle increased laxity results in abnormal translation in the shoulder that can be manifested as tension overload on the rotator cuff. Articular-sided partial thickness cuff tears should alert the surgeon to the possibility of subtle instability. Going straight to an acromioplasty may not improve the patient's symptoms or solve the underlying problem. This is especially true in throwing athletes or young patients that present with partial thickness cuff tears. Indeed, Morgan and colleagues demonstrated that there

were lesions specific to partial thickness cuff tears associated with SLAP lesions.[3] More posterior SLAP lesions resulted in slightly posterior partial thickness cuff tears, while anterior variants of Type II SLAPs resulted in more anterior cuff tears. The recent addition to the shoulder alphabet soup, SLAC (superior labrum anterior cuff), also demonstrates this concept.

Unless one is addressing an acute SLAP lesion, there is at least a 70% chance there will be other significant pathological conditions in the shoulder (40% rotator cuff tears, 20% associated labral pathology).[1] The surgeon should not confuse the normal anatomic variants found in the anterior superior labrum from 1 o'clock to 3 o'clock with pathologic conditions. The sublabral hole or the absent labrum in this area often associated with a thickened middle glenohumeral ligament (Buford complex) have been noted in 12-18% of shoulders.[4] An interesting finding in a recent study by Ilahi was that those patients with a Buford complex or sublabral foramen were at a 5- to 7-fold greater risk than other patients to have a SLAP lesion.[4] Because many patients with a Buford complex or sublabral foramen also had absent superior glenohumeral ligaments, it has been suggested that a deficient anterior superior labrum puts more stress on the biceps attachment, thereby putting it at risk to avulse with trauma or repetitive throwing. However, the sublabral foramen should never be reattached as it is in itself not pathologic, and attachment where it has never been could restrict external rotation.

If the surgeon appreciates the importance of the biceps attachment and the circle concept of the labrum, it will aid in determining the proper treatment for the patient. A good exam under anesthesia and looking for a "drive-through sign" at arthroscopy may alert the surgeon to occult instability. If the diagnosis is correct, fixing the SLAP lesion will correct the problem.

Fixation choices for SLAP lesions involve absorbable tacks or suture anchors. A common problem with absorbable PLA tacks is fragmentation of the head with loose body symptoms necessitating a second arthroscopy. This is obviously not desirable. More rapidly absorbing PGA tacks can be used but require strict immobilization until healing occurs at 6-8 weeks. Particulate synovitis has been described as these break down. Suture anchors offer the ability to tension the repair while avoiding intraarticular debris. Both absorbable and metal anchors have been used with good success. The tricks are in passing the suture and working under the acromion. More posterior lesions may be accessed with a posterolateral "Port of Wilmington."[2] Superior and anterior SLAPs are best accessed through an anterior superior portal with a separate anterior working portal for shuttling suture. The Bioknotless anchor (Mitek Worldwide, Norwood, Mass) offers the added benefits of an absorbable implant without the need to tie knots in a difficult location.

Once the biceps anchor is effectively secured, any "drive-through sign" should be eliminated and excess tension on the cuff relieved. Simple debridement of a partial thickness cuff tear should suffice unless a surgeon has some other evidence of outlet impingement. If further subtle instability exists, suture plication of the rotator interval or limited thermal capsulorraphy (stripes only, never paint) can be performed to better balance the shoulder. ■

References

1. Mileski RA, Snyder SJ. Superior labral lesions in the shoulder: Pathoanatomy and surgical management. *J Am Acad Orthop Surg*. 1998;6:121-131.
2. Burkhart SS, Morgan CD. The peel-back mechanism: Its role in producing and extending posterior type II SLAP lesions and its effect on SLAP repair rehabilitation. *Arthroscopy*. 1998;14(6):637-640.
3. Morgan, CD, et al. Type II SLAP lesions: Three subtypes and their relationships to superior instability and rotator cuff tears. *Arthroscopy*. 1998;14(6):553-565.
4. Ilahi OA, Labbe MR, Cosculluela P. Variants of the anterosuperior glenoid labrum and associated pathology. *Arthroscopy*. 2002;18(8):882-886.

Valgus Instability of the Elbow Due To Ulnar Collateral Ligament Injury

By Marc R. Safran, MD

Valgus instability of the elbow is characterized by pain and instability at the medial aspect of the elbow due to the sprain, attenuation, or rupture of the ulnar collateral ligament (UCL). As more is being learned about this ligament, it appears that there may be a spectrum of asymptomatic laxity, especially in athletes who perform overhead throwing maneuvers. Thus, instability should be characterized by symptomatic laxity. The UCL may be injured by a sudden, excessive valgus stress applied to the elbow acutely or with dislocation of the elbow. However, it more commonly is the result of repetitive valgus stress in overhead sports such as baseball, tennis, javelin, or water polo.

The athlete with a UCL injury may complain of medial elbow pain that started with a single "pop" or giving

away of the elbow during a throw. This may indicate acute rupture of the UCL or acute rupture of a chronically attenuated UCL. More often, many athletes experience low-grade medial elbow pain worsening with continued throwing with no history of 1 single throw as the initiating event and often note they are able to throw to 75% without problem, but are unable to throw harder than 75-80%. Pain is frequently described during the late cocking or early acceleration phase of throwing, a sensation of the elbow "opening" during throws, and/or decreased velocity or distance of throws.

They may also complain of multiple secondary problems, including ulnar nerve symptoms, medial epicondylitis, valgus extension overload syndrome (VEOS), or radiocapitellar overload syndrome (RCOS). With continued activity in the presence of persistent laxity of the UCL, the subject may develop ulnar nerve symptoms. This is usually due to excessive traction on the nerve as a result of the medial laxity, though it may also be the result of compression from scarring of the injured ligament, abrasion from osteophytes and/or the inflammation that occurs with acute injury. Furthermore, the nerve is susceptible to nerve subluxation at the cubital tunnel. Medial epicondylitis symptoms result from attempts at dynamic medial stabilization or overuse of the flexor pronator muscles. VEOS occurs due to the excessive shearing of the olecranon within the fossa when there is increased medial joint laxity. RCOS may occur as the radiocapitellar joint serves as a secondary restraint to valgus stress. When the UCL is incompetent, valgus stress results in radiocapitellar degeneration. Symptoms of loose bodies resulting in lateral elbow pain and locking may result from RCOS or VEOS.

Physical exam of the UCL begins with inspection and palpation of the elbow. There may be pain on palpation 2 cm distal to the medial epicondyle at the insertion of the UCL on the ulna. This pain may be worsened by valgus stress applied to the elbow. Valgus stress test to detect medial elbow instability may be performed several ways. The key is to not have the ulna engaged within the olecranon (flex more than 20°). One classic method is to firmly lock the athlete's hand and wrist between the examiner's elbow and trunk. Bend the athlete's elbow 30° and with the heel of the examiner's hand, gently apply valgus stress to the elbow. Palpate the medial joint line with a finger over the UCL feeling for laxity. Increased laxity as compared with the other elbow and/or no firm end point indicates incompetence of the UCL due to rupture or attenuation. Of note, humeral rotation may confound the examination. Other methods to examine the elbow include the patient grabbing the thumb of the arm to be examined with the other arm brought underneath the arm being examined. The joint line is palpated while the patient pulls down on the thumb, imparting a valgus stress to the elbow. Recently, a dynamic stress test has been identified where the arm is held in abduction and external rotation, and the elbow taken through flexion-extension. This should reproducibly cause pain in the arc between 80° and 120°.

Due to the small amount of laxity necessary to cause instability, diagnosis of this injury may be underestimated, missed, or misdiagnosed. Success of clinically determining laxity on physical examination ranges between 26% and 82%.[1, 4]

Plain radiographs cannot diagnose acute UCL injury but can identify chronic injury (traction spurs, calcification within the ligament) and help rule out osteophytes, loose bodies, avulsion fractures, and degenerative joint disease. Stress radiographs may be of value, as a 2-3 mm increase in medial joint opening compared with the normal elbow is consistent with a UCL tear. This may be done with the gravity stress test, a commercially available stress device, or with manual stress. Each has their benefits and drawbacks. Stress tests have been shown to be 45-88% sensitive.

MRI can show partial or full-thickness tears of the UCL in addition to other intra-articular pathology. The sensitivity of MRI in the diagnosis of UCL injury ranges from 57-79% without contrast and 97% sensitive when intra-articular contrast is added.

Treatment of UCL injuries begins with icing the elbow (to protect the ulnar nerve), taking nonsteroidal anti-inflammatory medications as needed, and short-term immobilization with sling as needed. Relative rest for 2- 4 weeks is followed by active range of motion when pain-free. Physical therapy modalities can be used to aid healing. Once pain-free, a strengthening program is initiated followed by a throwing program when range of motion is full and strength equal to the contralateral side. One study noted 42% return to sports with nonoperative treatment of nearly half a year.[3]

Surgical reconstruction is indicated for the complete rupture of the UCL in a thrower, or failed nonsurgical treatment after 3 months in the athlete who desires a return to high-level competitive throwing or overhead sports. Acute UCL avulsions may be repaired with suture anchors to bone, though this is not as common as with lateral UCL injuries because lateral UCL injuries tend to be avulsions off the humerus with a sliver of bone, which are quite amenable to suture anchor repair as opposed to midsubstance UCL injuries. The gold standard for reconstruction of the UCL is use of a free autogenous graft.[2] This traditionally has been done through a 'Y'-shaped tunnel on the humeral side and

straight tunnel on the ulnar side in a 3-ply figure-of-8 technique. However, newer techniques, including a single blind-ended tunnel on the humerus for a 2-ply reconstruction (docking procedure), a blinded tunnel on both the ulnar and humeral sides fixed with an interference screw, or an onlay technique fixed with suture anchors have been performed with reduced morbidity perhaps due to muscle sparing. However, long-term studies are still needed to confirm the success of these reconstruction modifications. Postoperative rehabilitation programs vary, but most incorporate hand and wrist exercises immediately with transfer from a posterior splint to a functional brace at 2 weeks. Full elbow range of motion is expected by about 6 weeks. Throwing generally can begin by 4 months with return to competitive throwing between 6 months and 1 year. The success rate of surgery is reported as 79-96% in recent studies for return to sports at the same level. ■

References

1 Azar FM, et al. Operative treatment of ulnar collateral ligament injuries of the elbow in athletes. *Am J Sports Med.* 2000;28:16-23.

2. Conway JE, et al. Medial instability of the elbow in throwing athletes. Treatment by repair or reconstruction of the ulnar collateral ligament. *J Bone Joint Surg Am.* 1992;74A:67-83.

3. Rettig AC, et al. Non-operative treatment of ulnar collateral ligament injuries throwing athletes. *Am J Sports Med.* 2001;29(1):15-17.

4. Thompson WH, et al. Ulnar collateral ligament reconstruction in athletes: Muscle splitting approach without transposition of the ulnar nerve. *J Shoulder Elbow Surg.* 2001;10:152-157.

CME Questions

Effective with this issue, Sports Medicine Reports *is changing its testing procedure. You will no longer need to return a Scantron answer sheet to earn credit for the activity. Please review the text, answer the following questions, check your answers against the key on the following page, and then review the materials again regarding any questions answered incorrectly.* ***To receive credit for this activity, you must return a CE/CME evaluation at the end of the testing term.*** *For further information, refer to the "CE/CME Instructions" below.*

This testing procedure has proven to be an effective learning tool for adults. If you have any questions about the new testing method, please contact Customer Service at 1-800-688-2421.

15. Which of the following factors are important in determining treatment options for a rotator cuff repair?
a. Tendon tissue quality and delamination
b. Location of tear
c. Amount of fatty degeneration
d. Bone quality
e. All of the above

16. The footprint of the supraspinatus tendon is which of the following:
a. The void left by tendon that has retracted
b. The area of the muscle in the supraspinatus fossa
c. The area of the attachment of the tendon on the greater tuberosity
d. The portion of the tendon not repairable with mini-open techniques

17. Failure of early arthroscopic Bankart reconstructions was due to:
a. too aggressive rehabilitation.
b. metal wear in the glenohumeral joint.
c. medial placement of the labrum on the glenoid.
d. the development on glenohumeral arthritis due to lack of external rotation.

18. Open procedures for shoulder instability, when compared to arthroscopic procedures:
a. do not allow the surgeon to address capsular laxity and labral tears as well as arthroscopic procedures.
b. have higher recurrence rates in long-term studies.
c. are associated with numerous complications that make their use out-dated.
d. have lower recurrence rates and other advantages over arthroscopic techniques.

19. SLAP lesions may be associated with:
a. partial thickness cuff tears due to tension overload.
b. a Buford complex or sublabral foramen.
c. subtle instability.
d. either traction or compression as a mechanism of injury.
e. All of the above

20. The best test to diagnose ulnar collateral ligament injury in the athlete is:
a. history.
b. valgus stress test at 30°.
c. milking maneuver.
d. MRI with contrast.
e. stress radiographs.

21. Margin convergence closes the cuff defect in which direction?
a. Anterior to posterior
b. Posterior to anterior
c. Medial to lateral
d. Lateral to medial

Answers: 15(e); 16(c); 17(c); 18(d); 19(e); 20(d); 21(c)

In Future Issues:

Diagnosing a SLAP Tear

PHARMACOLOGY WATCH

Smallpox Vaccination Guidelines Published by CDC

The CDC published "Smallpox Vaccination and Adverse Reactions—Guidance for Clinicians" in the Jan. 24th edition of *Morbidity and Mortality Weekly Report.* The guidance is a thorough review of the smallpox vaccine with a well-illustrated compendium of complications. Some of the highlights include:

Inoculation is administered using a multiple-puncture technique with the bifurcated needle. The inoculation site progresses from papule to vesicle, eventually becoming a pustule within 10 days. The pustule scabs over within 2-3 weeks usually leaving a pitted scar. Development of a pustular lesion is considered a major reaction and a successful vaccine take. Lesser reactions are considered equivocal and are nontakes. Large vaccination reactions may occur in 10% of first-time vaccinees. Systemic reactions are common in all vaccinees and include fatigue, headache, myalgias, chills, nausea, and fever. The vaccine is made from live vaccinia virus (it does not contain variola virus) and transmission is possible from the vaccination site up to 3 weeks after vaccination. The shedding period may be less for revaccination. The inoculation site is generally considered infectious from the time just after vaccination until the scab separates from the skin. Vaccinia is transmitted by close contact and can lead to the same adverse events in an infected contact as in the vaccinee. The inoculation sites should remain covered and vaccinees should wash their hands immediately after touching vaccination sites or changing dressings. The smallpox vaccination is generally considered safe, but is contraindicated in patients who have, or are in close contact with, those who have atopic dermatitis (eczema) regardless of the severity, skin diseases that disrupt the epidermis, pregnant women or women who plan on becoming pregnant within 1 month after vaccination, and immunocompromised patients. Others who should not receive the vaccine include those who have an allergy to a component of the vaccine, are breast-feeding, are using ocular steroids, have moderate-to-severe intercurrent illness, or are younger than 18 years of age.

The CDC has an excellent web site for health-care providers who wish to learn more about the smallpox vaccine: www.bt.cdc.gov/training/smallpox-vaccine/reactions/default.htm

Nurses: Delay Vaccination Program

Meanwhile, not everyone is happy with the national smallpox vaccination program. Recently the American Nurses Association (ANA) requested that the Bush administration delay the smallpox vaccination program until certain safety issues can be addressed. Specifically, the ANA is seeking information regarding potential transmission of vaccinia virus to family members of vaccinated nurses, coverage of medical costs related to vaccination, safety of the vaccination materials, adequate educational materials and staffing issues, and job security issues related to the vaccination program. Others such as Thomas Mack, MD, MPH, argue in the Jan. 30 edition of the *New England Journal of Medicine* that

This supplement was written by William T. Elliott, MD, FACP, Chair, Formulary Committee, Kaiser Permanente, California Division; Assistant Clinical Professor of Medicine, University of California-San Francisco. Telephone: (404) 262-5517. E-mail: robin.mason@ahcpub.com. In order to reveal any potential bias in this publication, we disclose that Dr. Elliott reports no consultant, stockholder, speaker's bureau, research, or other financial relationships with companies having ties to this field of study.

smallpox is overrated as a bioterrorist weapon. His view is that the current vaccination policy would provide little protection and the cost from vaccine complications would outweigh any benefit (*N Engl J Med*. 2003;348:460-463). However, a special article in the same issue developed scenarios of smallpox attacks and reviewed possible outcomes of control policies. Their analysis favors a program of prior vaccination of health care workers but favors vaccination of the public only in the likelihood of a national attack, or multiple attacks is very high (*N Engl J Med*. 2003;348:416-425).

Viagra Effective for Depression Treatment

Sildenafil (Viagra) is an effective treatment for antidepressant-associated sexual dysfunction in men. The drug was tested in a multicenter randomized double-blind placebo-controlled trial. Ninety men with major depression in remission on SSRI antidepressants were randomly assigned to take sildenafil (50 to 100 mg) or placebo for 6 weeks. Men who were most affected by antidepressant-associated sexual dysfunction were significantly more likely to improve with sildenafil (24/44, 54.5% response rate) vs placebo (2/45, 4.4% response rate) ($P < .001$). Erectile function, arousal, ejaculation, orgasm, and overall satisfaction measures improved significantly with sildenafil compared with placebo (*JAMA*. 2003;289:56-64). This study is important because sexual dysfunction is a common cause of noncompliance with serotonin reuptake inhibitors, and use of sildenafil may improve compliance with antidepressant treatment.

Finisteride/Doxazosin no Better than Placebo for Urinary Obstruction

Finisteride (Proscar) is no better than placebo when used in combination with doxazosin for the treatment of urinary obstruction due to benign prostatic hypertrophy, according to the recently published Prospective European Doxazosin and Combination Therapy (PREDICT) trial. These findings come in contradiction to the Medical Therapy of Prostatic Symptoms (MTOPS) trial published in May 2002, which showed a benefit of the combination of finasteride and doxazosin. In the current study, more than 1000 men were randomized to doxazocin, finisteride 5 mg per day, the combination of both, or placebo. The groups receiving doxazocin alone or in combination with finisteride had significant improvements in total maximal urinary flow rates and International Prostate Symptoms Score compared to the finisteride alone group and placebo group ($P < .05$). There was no significant difference between treatment with finisteride and placebo. Doxazosin was initiated at 1 mg per day and titrated to a maximum of 8 mg per day. All treatments were well tolerated (*Urology*. 2003;61:119-126).

Sildenafil, however, may be effective of relieving obstructive urinary symptoms in men who use the drug on a regular basis. British researchers looked at 112 men with erectile dysfunction at 1 and 3 months after taking sildenafil as needed before sexual intercourse. Only 20 of the 112 men complained of lowered urinary tract symptoms, but of those men, improved urinary scores at 3 months strongly correlated with improvement in sexual function. The authors suggest that an increase in nitric oxide associated with the resumption of normal sexual activity may be responsible for the improvement in urinary symptoms (*Br J Urol Int*. 2002;90: 836-839).

Serevent Receives 'Dear Doctor' Letter

GlaxoSmithKline has issued a "Dear Doctor" letter regarding its asthma bronchodilator salmeterol (Serevent). The warning is based on interim results from a large study of salmeterol that was initiated in 1996. The Salmeterol Multi-center Asthma Research Trial (SMART) was a postmarketing study designed to investigate reports of several asthma deaths associated with use of salmeterol. Analysis of the interim results showed a trend "toward a greater increase in asthma deaths and serious asthma episodes" with the largest increase in African-American patients. Data on almost 26,000 patients were available for analysis. While there was no significant difference for the primary end point of combined respiratory related deaths and respiratory related life-threatening experiences including incubation and mechanical ventilation between salmeterol and placebo, a higher, but not statistically significant number of asthma related life-threatening experiences including deaths occurred in the salmeterol group. The number of adverse events reached statistical significance in African-Americans who represented 17% of the study. No other ethnic group drew any conclusions. The use of inhaled corticosteroids reached only 47% in the entire population of the SMART study. Because of these findings, GlaxoSmithKline has decided to discontinue the study and continue reviewing data from the interim analysis. The FDA is involved in this process and will likely require label changes for Serevent that will reinforce guidance on appropriate and safe prescribing. ■