THOMSON
AMERICAN HEALTH CONSULTANTS

Rapid Reference Card Enclosed

Trauma Reports included with this issue.

The Practical Journal for Emergency Physicians

Emergency Medicine Reports

Volume 24, Number 15 July 14, 2003

Users of intravenous drugs are at risk for complications related to the agents they are injecting as well as other conditions related primarily to transmission of infectious agents. At some urban institutions, especially in the New York and San Francisco metropolitan areas, complications associated with intravenous drug injection are among the most common entities managed in the emergency department (ED) setting.

As experienced emergency physicians (EPs) know, infections associated with intravenous injection encompass a wide range of conditions, from viral hepatitis and bacterial endocarditis to wound botulism and spinal epidural abscess. Frequently, benign-appearing conditions such as soft-tissue cellulitis may be a manifestation of more serious underlying conditions that are systemic in nature. Compromised host response observed in patients with HIV infection may predispose them to opportunistic infections. Many of these conditions not only are life-threatening to the individual patient, but if carriers are not recognized, transmission to other individuals may be accelerated.

The evaluation of fever is especially problematic, since it may be difficult to determine whether the fever is a manifestation of a circumscribed local infection, or whether the patient has a serious underlying infection such as pneumonia or endocarditis. In the final analysis, optimal treatment of this patient population requires a systematic evaluation based on physical, historical, laboratory, radiologic, and bacteriological findings to confirm a suspected diagnosis or exclude it. The authors of this review, who have experience managing this patient population on a day-to-day basis, present an evidence-based strategy for assessment and management of individuals who are intravenous drug users.

—The Editor

Infectious Complications of Injection Drug Use

Authors: **Brad Frazee, MD, FACEP**, Department of Emergency Medicine, Alameda County Medical Center, Assistant Clinical Professor, Department of Medicine, University of California, San Francisco; and **Ralph Wang, MD**, Department of Emergency Medicine, Alameda County Medical Center, Oakland, CA.

Peer Reviewers: **Robert Powers, MD, MPH, FACP, FACEP**, Chief and Professor, Emergency Medicine, University of Connecticut School of Medicine, Farmington; and **Steven M. Winograd, MD, FACEP**, Attending Physician, Emergency Department, The Uniontown Hospital, Uniontown, PA.

Introduction

It is estimated that 3 million Americans have used heroin in their lifetimes, and that there were 400,000 active users in the United States in the year 2000. There are about half as many cocaine and

methamphetamine injection drug users.[1] Because most heroin users inject the drug, and because EDs serve as a regular source of medical care for this patient population, many EPs will encounter patients who engage in injection drug use (IDU). At some urban hospitals, as many as 10% of admissions are related to IDU.[2]

Injection drug users are at risk for a set of unique and well-defined problems, both social and medical in nature: addiction and related crime; overdose; withdrawal; and infections directly resulting from drug injection. Among these problems, infections account for the most ED visits and hospitalizations.[1,3,4] In fact, infections related to IDU were reported to be the most frequent admitting diagnosis from the San Francisco General Hospital ED during the late 1990s.[5]

The list of infections resulting from IDU reported in the literature virtually spans the entire spectrum of infectious disease—from viral infections like hepatitis C that are ubiquitous in this population, to bizarre bacterial infections such as pyo-pneumothorax,[6] to malaria. Diagnosis of the infections commonly encountered in the ED often is challenging. Soft-tissue infections encompass not only the obvious subcutaneous abscess and simple cellulitis, but also occult necrotizing fasciitis, which may be fatal if not diagnosed and treated rapidly. Wound botulism related to IDU easily is misdiagnosed, and failure to initiate specific therapy can lead to respiratory failure. Similarly, delayed diagnosis of spinal epidural abscess —a notorious complication of IDU that may present simply as back pain—can result in irreversible paralysis. Underlying HIV and associated opportunistic infections must be considered. The issue of appropriate disposition of injection drug users who are febrile often is surprisingly difficult because even an exhaustive ED workup cannot exclude the possibility of bacteremia and endocarditis.

The following article discusses the major bacterial infections associated with IDU. The contents can be divided roughly into three sections: 1) endocarditis and the approach to fever without an obvious source; 2) soft-tissue and skeletal infections; and 3) infections due to neurotoxins such as botulism and tetanus. The emphasis is on occult presentation of serious disease, strategies for accurate and timely diagnosis, and important treatments that should be initiated in the ED.

Injection Drug Use with Fever

During the past three decades, the terminology used to indicate injection drug use (IDU) has changed. "Intravenous drug abuse" (IVDA) and "intravenous drug use" (IVDU) largely have been discarded for the more accurate, inclusive, and less pejorative IDU.

When faced with a febrile IDU patient, the EP should proceed with a strong suspicion that an identifiable, serious infection exists. Approximately 60% of injection drug users who present to the ED with a fever have an apparent serious infection that requires admission.[7] In studies that examined source of fever in injection drug users, soft-tissue infections and bacterial pneumonia were the leading etiologies.[7,8] Infectious endocarditis (IE) was found in only 5-10% of patients, and in about half of the cases, it was evident upon initial ED evaluation that a serious infection requiring admission existed. Other common infections included pyelonephritis, pelvic inflammatory disease, HIV-related opportunistic infections, and skeletal infections, all of which can be diagnosed in the ED with a careful workup. Hence, the source of fever should be sought aggressively during the history and physical exam. The exam should not focus simply on whether there is a murmur or other stigmata of endocarditis. Patients should be undressed and the skin carefully examined for signs of a soft-tissue infection. Any musculoskeletal or neurologic complaint should be viewed as a possible sign of infection. Likewise, findings such as decreased range of motion, weakness, or numbness may point to the source of infection. The chest x-ray has a high yield in this patient population because pneumonia and HIV-related diseases like tuberculosis are common, and because endocarditis frequently produces chest x-ray abnormalities. Occasionally, more aggressive diagnostic testing, such as

Emergency Medicine Reports™ (ISSN 0746-2506) is published biweekly by Thomson American Health Consultants, 3525 Piedmont Road, N.E., Six Piedmont Center, Suite 400, Atlanta, GA 30305. Telephone: (800) 688-2421 or (404) 262-7436.

Vice President/Group Publisher: Brenda Mooney
Editorial Group Head: Valerie Loner
Specialty Editor: Shelly Morrow Mark
Marketing Manager: Schandale Kornegay
GST Registration No.: R128870672

Periodicals postage paid at Atlanta, GA. **POSTMASTER:** Send address changes to ***Emergency Medicine Reports***, P.O. Box 740059, Atlanta, GA 30374.

Back issues: $31. Missing issues will be fulfilled by customer service free of charge when contacted within one month of the missing issue's date.

Multiple copy prices: One to nine additional copies, $359 each; 10 to 20 additional copies, $319 each.

Subscriber Information

Customer Service: 1-800-688-2421

Customer Service E-Mail: customerservice@ahcpub.com
Editorial E-Mail: shelly.morrow@ahcpub.com

World Wide Web page: http://www.ahcpub.com

Subscription Prices

1 year *with* 60 ACEP/60 AMA/60 AAFP Category 1/Prescribed credits (52 AOA Category 2B credits): $544
1 year *without* credit: $399
Resident's rate $199

All prices U.S. only.
U.S. possessions and Canada, add $30 plus applicable GST. Other international orders, add $30.

Accreditation

Emergency Medicine Reports'™ continuing education materials are sponsored and supervised by Thomson American Health Consultants. Thomson American Health Consultants designates this continuing education activity for up to 60 hours in Category 1 credit toward the AMA Physician's Recognition Award. Each physician should claim only those hours of credit that he/she actually spent in the educational activity.

This CME activity was planned and produced in accordance with the ACCME Essentials.

Emergency Medicine Reports™ also is approved by the American College of Emergency Physicians for 60 hours of ACEP Category 1 credit and has been approved for 52 Category 2B credit hours by the American Osteopathic Association. Emergency Medicine Reports has been reviewed by the American Academy of Family Physicians as having educational content acceptable for Prescribed credit hours. This volume has been approved for up to 60 Prescribed credit hours. Term of approval covers issues published within one year from the beginning distribution date of 1/03. Credit may be claimed for one year from the date of this issue.

Thomson American Health Consultants (AHC) is accredited by the Accreditation Council for Continuing Medical Education (ACCME) to provide continuing medical education for physicians.

For Customer Service and CME questions,

Please call our customer service department at **(800) 688-2421.** For editorial questions or comments, please contact **Shelly Morrow Mark,** Specialty Editor, at shelly.morrow@ahcpub.com or (404) 262-5514.

THOMSON AMERICAN HEALTH CONSULTANTS™

Statement of Financial Disclosure

In order to reveal any potential bias in this publication, and in accordance with Accreditation Council for Continuing Medical Education guidelines, we disclose that Drs. Frazee, Wang (authors), and Powers and Winograd (peer reviewers) report no relationships with companies related to the field of study covered by this CME program. Dr. Bosker (editor) is on the speaker's bureau for Pfizer, Rhone-Poulenc Rorer, and Parke-Davis. Dr. Bosker also acknowledges that he receives royalties, commissions, and other compensation relating to the sale of textbooks, reprints of articles, and other written materials to the following pharmaceutical companies: Pfizer, Genentech, Aventis, Pharmacia, and Bayer.

Table 1. Classification of Endocarditis Based on Organism, Location, and Clinical Characteristics

TYPE	ORGANISM	VALVE LOCATION	CHARACTERISTICS
Subacute	*Streptococcus viridans*	Mitral or aortic valve	Indolent course; immune or vascular symptoms
Acute	*Staphylococcus aureus*	Mitral or aortic valve	Rapid course; heart failure; arterial embolic disease; highest mortality; more frequently requiring surgery
Right-sided (classic IDU form)	*Staphylococcus aureus*	Tricuspid valve	Indolent course; septic pulmonary emboli; murmur often absent
Prosthetic valve	*Streptococcus viridans* Coag. negative Staphylococcus	Mitral or aortic prosthetic valve	**Early:** likely surgical complication with high mortality. **Late:** similar to subacute native valve

IDU = Injection drug use

magnetic resonance imaging (MRI) for spinal epidural abscess, is required to make the correct diagnosis in the ED.

Roughly 40% of febrile IDU patients who present to the ED have no apparent source of fever and seem well enough to be discharged.[7] Unfortunately, a significant proportion of these patients harbor an occult serious infection, particularly IE. The issue of proper disposition of febrile but well-appearing IDU patients with no apparent source of fever has been examined in three prospective studies involving a total of approximately 500 patients. Six to 13% of such patients eventually were diagnosed with IE. Furthermore, these studies consistently found that the subgroup with occult bacteremia could not be separated initially from those with, for example, a viral illness or a pyrogen reaction to injected material.[7-9] This finding, together with the notion that injection drug users, as a group, are prone to becoming lost to follow-up, forms the basis for the recommendation that all febrile injection drug users without an obvious source of fever, even if they appear well, should have two blood cultures drawn and be admitted to the hospital until cultures remain negative for 48 hours.[7-9] This approach remains the standard of practice at urban teaching hospitals that serve large IDU populations. Some authors have allowed that febrile but well-appearing injection drug users who can be reached by phone and seem reliable could be discharged after blood cultures are drawn.[8] A system would need to be in place to follow the blood culture results and contact the patient immediately if they become positive.

Infectious Endocarditis

IE, defined as fungal or bacterial infection of the heart valves and perivalvular tissue, is a well-recognized and notorious complication of IDU. In large case series of IE, the proportion of patients who injected drugs ranged from 4% to as high as 67%.[10] Yet even among active injection drug users, IE is fairly uncommon, with an incidence of 1-20 per 10,000 users per year,[11] accounting for 5-15% of hospitalizations for an IDU-related infection.[2] Patients who are HIV positive or who inject cocaine are at an increased risk for IE.[12,13] In non-injection drug users, IE occurs almost exclusively in patients with underlying valvular pathology, such as congenital heart malformations, rheumatic heart disease, and prosthetic valves. In contrast, such underlying valvular pathology is present in only 10-26% of injection drug users who develop IE.[2,14] The pathophysiology leading to the majority of IE cases in injection drug users is not well understood. Injected material may cause subtle endocardial damage and turbulent flow in the absence of frank valvular pathology. The bacteremia associated with IDU appears to result largely from introduction of skin flora more often than from contaminated drugs or syringes.[15]

Staphylococcus aureus causes 51-82% of cases of IE in injection drug users in contrast to non-IDU-related cases, where *Streptococcus viridans* is the predominant pathogen.[2,11,16-19] The rate of methicillin-resistant *S. aureus* varies from approximately 10% to 26%, depending on locale, with the highest rates reported in the upper Midwest and northeastern United States.[20] Other organisms found in IDU-related IE include Streptococcal species, enterococcus, and enteric Gram-negatives.[17] Pseudomonas, a frequent pathogen in some early case series, was found in only 5-10% of cases in contemporary studies.[11] Culture-negative IE, usually caused by the Haemophilus species, *Actinobacillus actinomycetemcomitans*, *Cardiobacterium hominis*, *Eikenella corrodens*, and *Kingella kingae* (HACEK) organisms, typically accounts for 5-10% of cases.[21] Use of antibiotics prior to presentation also is associated with culture-negative endocarditis.[7]

Endocarditis is classified on the basis of location of the vegetation, route of infection, etiologic organism, and whether the valve is native or prosthetic. (*See Table 1.*) The pattern of valvular involvement in IDU-related IE differs from that in non-injection drug users in that vegetations more commonly are located on the tricuspid valve. (*See Tables 1 and 2.*) Right-sided endocarditis has a distinctive pathophysiology and clinical presentation. Whereas valvular regurgitation from left-sided endocarditis usually causes a significant murmur and may lead to pump failure, tricuspid regurgitation is of lesser hemodynamic consequence and may be silent both clinically and on auscultation. Left-sided IE classically is associated with prominent vascular and immune phenomena, such as splinter hemorrhages. Such findings usually are absent in isolated, right-sided disease. *S. aureus* endocarditis of the aortic or mitral valve is another fairly common pattern among injection drug users. In contrast to tricuspid disease, aortic valve vegetations are associated with a high morbidity and

Table 2. Frequency of Valve Involvement in IDU-Related IE[2,11,18]

VALVE LOCATION	FREQUENCY OF INVOLVEMENT
Tricuspid	40-70%
Mitral	20-30%
Aortic	20-30%
Right- and left-sided	5-15%

Table 3. Duke Diagnostic Criteria for Endocarditis[25]

DEFINITE ENDOCARDITIS

1. Histopathologically proven vegetation or intracardiac abscess found post-mortem or during surgery
2. Clinical criteria are any of: two major criteria*; one major and three minor criteria**; five minor criteria (see below for definitions)

***MAJOR CRITERIA**

1. Multiple positive blood cultures
2. Evidence of endocardial involvement—positive echocardiogram findings, such as oscillating valvular mass, valvular dehiscence, or new valvular regurgitation

****MINOR CRITERIA**

1. Fever
2. Predisposing heart condition or IDU
3. Vascular phenomenon
4. Immunological phenomenon
5. Echocardiogram consistent with IE but not meeting above criteria

IDU = Injection drug use
IE = Infectious endocarditis

mortality, with up to 40% of cases resulting in death or heart failure that requires valve replacement. Septic embolization to the brain, coronary arteries, or kidneys can occur. IE presenting with altered mental status or heart failure is considered an ominous sign, indicating likely infection of the aortic valve. A study that underscores the differences between *S. aureus* IE in injection drug users and non-injection drug users found that the former group on average was younger, had a majority (76%) of right-sided heart involvement, and had a case mortality about one-tenth that of non-injection drug users.[16]

Endocarditis typically presents with nonspecific symptoms such as arthralgias, malaise, back pain, and weight loss. Pulmonary symptoms such as cough, dyspnea, and chest pain are more common in tricuspid disease. Fever is a cardinal sign of IE, present in 97-100% of cases.[2,10,19,22] Classically, IE causes a new or changing murmur; however, a murmur is heard at the time of presentation in only 30-50% of IDU-related IE patients, and in even fewer of those with isolated right-sided disease.

Various diagnostic criteria have been developed to assist in arriving objectively at this difficult diagnosis. In the early 1990s, the Duke criteria were introduced, which emphasized echocardiography in addition to blood culture results and the presence of risk factors.[23,24] The Duke criteria are summarized in Table 3.

Blood cultures are a cornerstone of diagnosis in IE. Endocarditis produces a continuous bacteremia, and blood cultures are positive in more than 95% of cases. In patients presenting to the ED with potential IE, it is the responsibility of the EP to ensure proper blood culture collection prior to the administration of antibiotics. Ideally, 2 or 3 separate cultures should be obtained, each containing 10 mL of blood. The recommendation that they be separated in time by as much as one hour may be difficult to adhere to in the ED setting. Factors associated with reduced blood culture yield include sample volume of less than 10 mL, recent antibiotic therapy, and prosthetic valve disease.[15] In the setting of a prosthetic valve, it is recommended that three cultures be obtained to improve sensitivity.[15]

The chest x-ray is an essential diagnostic study in all febrile IDU patients for two reasons: 1) community-acquired pneumonia is a far more common cause of fever than IE; and 2) the chest x-ray is abnormal in up to 72% of injection drug users with IE, probably because of the high proportion of right-sided disease. Septic pulmonary emboli classically appear on chest x-ray as multiple round infiltrates that may show evidence of cavitation. Other findings on chest x-ray include nonspecific infiltrates, pleural effusions, and pulmonary edema. Laboratory abnormalities that support the diagnosis of IE include hematuria, proteinuria, and anemia.[7,8] Conduction abnormalities, particularly AV block, may be seen on electrocardiogram (ECG) due to an associated valve ring abscess that erodes into the His-Purkinji system.

Echocardiography, now considered nearly as important as blood cultures in the workup of IE, is used both for definitive diagnosis and to assess complications and prognosis. Although by no means always present, the finding of an oscillating intracardiac mass attached to a valve is considered definitive. Other possible echocardiographic findings include valvular incompetence, reduced ventricular function, perivalvular abscess, or new dehiscence of a prosthetic valve. For the diagnosis of IE, transthoracic echo is 60-80% sensitive and approximately 90% specific.[26,27] Transesophageal echocardiogram is better overall (sensitivity 85-95%, specificity ~95%), and it better visualizes the aortic valve and prosthetic valves. The tricuspid valve is not well visualized by either modality.[26,27] Echocardiogram findings that place patients with IE into a higher risk category include: vegetations greater than 1 cm in size, left-sided valvular involvement, severe regurgitation, and ring abscess. Vegetations greater than 1 cm may indicate the need for surgery. In the setting of isolated tricuspid valve involvement, a vegetation greater than 1 cm represents a contraindication to short-course antibiotics.[11,26]

Appropriate antibiotic choice for suspected IE depends on whether it is classified as native valve non-IDU, IDU-associated endocarditis, or prosthetic valve endocarditis. Empiric treatment of suspected IE related to IDU should cover *S. aureus* and Streptococcal species. The regimen of choice is nafcillin plus gentamicin.[28] (*See Table 4.*) Vancomycin is used in patients with proven penicillin allergy; however, vancomycin has been shown to be less effective than nafcillin in eradicating *S. aureus*. The addition of gentamicin shortens the time to negative blood cultures.[18] In well-

appearing patients, treatment can be delayed until culture results are known; however, empiric treatment should be begun in the ED for all ill-appearing patients and those in heart failure. A two-week course of nafcillin and gentamicin has been shown to effectively treat isolated tricuspid valve IE in IDU, provided the vegetation is small and there is no evidence of pulmonary emboli.[29]

Intracardiac complications include valvular destruction and incompetency, resultant heart failure, intracardiac abscess, purulent pericarditis, and septic embolization to the coronary arteries.[11] Embolic complications also can be devastating, and are more frequent with left-sided *S. aureus* IE. Septic cerebral emboli may present with delirium or focal neurological findings. Meningitis may occur in association with IE and is thought to result from microemboli to the meningeal arteries. Some form of neurologic complication is found in up to 50% of left-sided IE cases.[11] Spinal epidural abscess is a feared, albeit rare, complication of IE. Renal sequelae include glomerulonephritis as well as renal infarction. Right-sided IE causes downstream pulmonary complications such as septic pulmonary embolism, pneumonia, empyema, and pyopneumothorax.[6,11]

Mortality due to IDU-related IE ranges from 2% to 39%.[10,16] Isolated right-sided disease has a mortality of less than 10%.[11,18,19,28] The effect of HIV on the course of IDU-related IE has been examined in several studies. Overall, AIDS confers a 2.5-fold increase in case mortality, and mortality is inversely related to CD4 count.[13,30-32]

Abscess

Although the actual incidence is unknown, subcutaneous abscess is clearly the most common bacterial complication of IDU.[33-35] A recent study conducted in San Francisco reported a 32% prevalence of abscess among active injection drug users.[36] At San Francisco General Hospital in 1998, IDU-related soft-tissue infection (abscess or cellulitis) was the most common admitting diagnosis from the ED. The practice of subcutaneous injection, or "skin popping," has been shown to increase the risk of abscess approximately five-fold.[36,37] Skin popping also is associated with necrotizing soft-tissue infections, tetanus, and wound botulism. It is believed that injection of bacteria-laden material beneath the skin, a relatively anaerobic environment, creates a nidus where both aerobic and anaerobic organisms may proliferate. Skin popping is more common in female injection drug users and those who have used up superficial veins. Needle licking, another common practice, probably accounts for the high percentage of oral flora found in IDU-related abscesses. Other risk factors for abscess formation include the following: cocaine injection, lack of skin preparation, and use of dirty needles.[33,37]

Despite the fact that surgical drainage is all that usually is required for treatment, the bacteriology of IDU abscesses has been well elucidated in several studies,[34,35,38] as outlined in Table 5. Skin flora and oral flora account for the majority of pathogens. *S. aureus* and Streptococcal species are the predominant aerobes. Eikenella, a gram-negative aerobe and notorious pathogen in human fight bites, was cultured from 25% of abscesses in one series.[34] Peptostreptococcus and fusobacterium are the predominant anaerobes. *Bacteroides fragilis*, an antibiotic-resistant gut anaerobe, rarely was isolated from upper extremity abscesses.[34]

Table 4. Empiric Treatment for IDU-Related Infectious Endocarditis[18,28]

TYPE	ANTIBIOTIC REGIMEN	DURATION
Right-sided and low risk (see text)	Nafcillin *plus* gentamicin	2 weeks
Left-sided or high risk	Nafcillin *plus* gentamicin	4-6 weeks
Penicillin allergic patient	Vancomycin *plus* gentamicin	4-6 weeks

The diagnosis of IDU-related abscess usually is straightforward, with most patients complaining of a painful mass at a previous injection site. Erythema, fluctuance, and drainage are confirmatory physical findings, present in a majority of cases. However, abscesses that present without specific physical findings, particularly without fluctuance, easily are misdiagnosed as cellulitis. Often these are deep subcutaneous or intramuscular collections. In such cases, ED ultrasound can be indispensable in revealing the correct diagnosis. Using a high frequency transducer, abscess cavities are visualized as a hypoechoic mass with acoustic enhancement in the far field.[39] An alternative to ultrasound is blind needle aspiration. Plain x-rays are recommended because they may reveal a subcutaneous needle, tissue gas suggestive of a necrotizing infection, or bony involvement.

Most of the case series describing IDU-related abscesses consist of patients requiring admission, and therefore the literature on this topic is skewed toward severe disease. Forty to 60% of these patients were febrile, and the incidence of bacteremia among febrile patients was 17-24%.[33,34,40] Despite the selection bias, these data underscore the fact that abscesses alone can cause fever, and suggest that such cases are associated with an approximately 20% rate of bacteremia. In contrast, a study of 50 abscess cases (13 IDU-related) that excluded febrile patients drew blood cultures before and after incision and drainage, and in every case found no cases of bacteremia.[41]

Incision and drainage is the primary treatment for IDU-related abscess. In most cases, this can be performed in the ED. Achieving adequate anesthesia often is a challenging issue for the EP. Options include local anesthesia, a regional block, a parenteral narcotic combined with a short-acting sedative (conscious sedation), or deep procedural sedation with an agent such as methohexital or propofol. The best choice depends on the size, number, and location of abscesses, availability of intravenous (IV) access, and patient preference. For large abscesses, deep procedural sedation usually is the best solution. In patients who otherwise have no peripheral IV access, ultrasound-guided cannulation of the deep brachial or basilic vein offers a rapid and less invasive alternative to a central line.[42]

A generous incision should be made and the abscess cavity explored with a hemostat or other instrument. Exploration with a gloved finger is to be avoided, especially without a preoperative

Table 5. Bacteria Associated with IDU Abscesses[34,35,44,45]

AEROBES (MAJORITY-97%)	
Staphylococcus aureus	19-71%
Streptococcus species, incl. Milleri	14-50%
Eikenella	Up to 25%
ANAEROBES (20%)	
Peptostreptococcus	17%
Fusobacterium	22%
Bacteroides	19%
Prevotella	17%

x-ray proving there is no subcutaneous needle. In the case of deep procedural sedation, preoperative injection of local anesthetic is unnecessary, but 10-20 cc of bupivacaine is injected into the surrounding tissue after drainage to provide local anesthesia when the patient awakens. To achieve hemostasis, the cavity is packed tightly for the first 24 hours. A four-inch gauze roll can be used to pack large abscesses. Patients are instructed to return at least once, at 24 hours, for wound check, dressing change, and to review wound care procedures.

The need for prophylactic antibiotics prior to incision and drainage to suppress bacteremia and prevent endocarditis is controversial. American Heart Association guidelines list abscess incision and drainage among the procedures for which preoperative antibiotics should be considered in patients with high-risk cardiac abnormalities. However, there is very little evidence to suggest that abscess incision and drainage causes bacteremia in the absence of fever.[41] Pre-incision and drainage antibiotics can be limited to patients at highest risk for endocarditis: those with prosthetic valves, congenital cardiac abnormalities, or a prior history of endocarditis.

The decision about whether to treat patients with a course of antibiotics following incision and drainage of an uncomplicated abscess also deserves mention. Although conventional wisdom states that uncomplicated abscesses are cured with drainage alone, there are almost no research data to support this. In a case series of 133 patients with abscesses treated in an outpatient setting (a small proportion of whom were injection drug users), antibiotics were withheld in 74%, and all patients did well.[38] Antibiotics should be given when there appears to be significant surrounding cellulitis and should be considered in patients with diabetes or HIV infection. If the abscess is accompanied by fever or if the patient appears ill, parenteral antibiotics and admission to the surgical service is indicated. Adequate staphyloccocal and streptococcal coverage can be achieved with a first-generation cephalosporin, dicloxacillin, or clindamycin. Gram-negative and anaerobic coverage, such as with amoxicillin/clavulanate or a quinolone, usually is unnecessary.[33,43]

When faced with an IDU-related abscess, the EP must be vigilant for associated complications and less obvious coexisting infections such as necrotizing soft-tissue infection, septic arthritis, osteomyelitis, and epidural abscess. Such complications were discovered in 15-19% of patients admitted for IDU-related abscess.[34,44] Endocarditis also is a consideration. However, we do not routinely obtain blood cultures or otherwise pursue this diagnosis, provided the soft-tissue infection appears sufficient to explain the fever.

Necrotizing Soft-Tissue Infections

Since Joseph Jones first coined the term "hospital gangrene" after the Civil War, a number of terms have been proposed to describe necrotizing soft-tissue infections (NSTI): necrotizing fasciitis, pyomyositis, "gas gangrene," and "flesh-eating bacterial infection." These terms describe a life-threatening soft-tissue infection, often involving muscle and fascial planes, associated with systemic toxicity.[46] A definitive diagnosis is made when friable, necrotic fascia associated with vascular thrombosis is found intra-operatively.

Well-known risk factors for NSTI include IDU, diabetes mellitus, and peripheral vascular disease.[47-50] In most cases, an inciting infection or breach of the skin barrier can be identified, such as drug injection, trauma, perineal infection, or post-operative wound infection. In community-acquired cases of NSTI (as opposed to hospital-acquired or postoperative cases), by far the most prevalent risk factor and inciting cause is IDU. In two recent case series of predominantly community-acquired NSTI from northern California, 55-64% of patients with NSTI were active injection drug users.[49,51,52] These studies describe a sharp increase in the incidence of NSTI between 1994 and 1997. The pathophysiology of NSTI classically involves compromised or frankly devitalized tissue from trauma, surgery, diabetes, or long-standing IDU that becomes infected by a synergistic combination of aerobes and anaerobes, particularly *Clostridium perfringens*. Virulent strains of group A strep, however, appear to be capable of causing NSTIs in normal hosts in the absence of an obvious inciting cause or compromised tissue. Bacteriology studies reveal that 60-85% of NSTIs are polymicrobial. Aerobes include *S. aureus* and group A beta-hemolytic streptococcus (GABHS); anaerobes include gas forming Clostridium species, peptostreptococcus, and other so-called oral anaerobes.[51,53,54] Although arising from various etiologies, NSTIs can be viewed as a common final pathway in terms of pathophysiology, rapid progression, and need for rapid recognition and surgical treatment.

The timely diagnosis of NSTIs is critical, yet often difficult. Patients may present with a variety of nonspecific symptoms and signs that may lead to initial misdiagnosis. Pain, warmth, edema, and fever commonly are present but are obviously nonspecific. Findings more specific for NSTI include: pain out of proportion to skin findings; signs of skin necrosis such as bullae or blisters; or crepitus representing subcutaneous gas. In IDU-related NSTIs, tense circumferential edema of an extremity, often spreading onto the trunk, is highly characteristic. Such findings should be sought in any soft-tissue infection presenting to the ED, and their significance needs to be recognized. A recent prospective trial identified several objective criteria useful in differentiating necrotizing from non-necrotizing skin infections: white blood cell (WBC) count greater than 14,000; gas on plain soft-tissue x-ray; elevated blood urea nitrogen (BUN); and sodium greater

than 135.[55] Similarly, previous case series have reported that a WBC count greater than 20,000 is seen in about 50% of NSTIs. While a marked leukocytosis should raise concern for NSTI, its absence by no means excludes the diagnosis. Signs of shock or organ dysfunction are found at the time of presentation in only 0-40% of cases.[49,51,55]

Various forms of imaging have been evaluated for their ability to differentiate NSTI from less severe skin infections. Plain films demonstrate subcutaneous gas in a stippled pattern in 20-60% of cases.[47,49,51,55] Computed tomography (CT) scan is likely somewhat more sensitive than plain film in demonstrating gas in the tissue, and may reveal unsuspected pockets of pus. The typical CT finding in NSTI is asymmetric thickening of deep fascia associated with gas. Of note, IV contrast should be avoided in patients with signs of shock or incipient renal dysfunction.[38,56] MRI, although costly and more difficult to obtain, has proven useful in one study in differentiating NSTI from non-necrotizing infections.[38,56] MRI should not delay definitive diagnosis and debridement in the operating room.

Various quasi-invasive bedside tests to identify NSTIs have been described. Rapid antigen testing for group A streptococcus has been used to identify NSTIs due to this organism.[53] In a single report, bedside frozen section was touted to prevent delay in diagnosis, but this approach has not been widely adopted.[57] Finally, bedside exploration and fascial inspection can be performed. The ability to pass a blunt instrument along fascial planes without resistance is considered diagnostic of necrotizing fasciitis. This is a realistic option only in intubated, heavily anaesthetized patients, such as in a surgical intensive care unit.

While a positive result from a confirmatory test is extremely useful in establishing the diagnosis of NSTI and need for immediate surgery, a negative result cannot be relied upon to exclude the diagnosis. Indeed, a false negative result tends to delay definitive treatment. Rather, the proper approach to diagnosis combines the following: an extremely high index of suspicion on the part of the EP, prompt surgical consultation when any suspicion of NSTI arises, and a low threshold for operative exploration on the part of the surgeon—analogous to the traditional approach to appendicitis. Studies looking at risk factors for mortality in NSTI consistently find that delay to operation is the lone modifiable risk factor.[51,54,58] In one study, the mortality in the group of patients brought to the operating room 24 hours after presentation was quadruple that of patients undergoing early operation. Of particular importance to EPs was the finding that delay in surgery was associated with admission to a medical service and negative bedside aspiration.[58]

Initial management of NSTI includes aggressive fluid resuscitation and early broad-spectrum antibiotics. Laboratory and imaging studies should be performed promptly and early surgical consultation expedited. Systemically ill patients will not improve without debridement. If surgical consultants are unfamiliar with NSTI, transfer of the patient to another facility experienced in its management should be considered. Hyperbaric oxygen has been suggested as an adjunct to the treatment of NSTI and has been shown to offer the advantage of early wound closure.[59] However, other studies have shown no benefit of hyperbaric oxygen in terms of mortality or number of debridements.[46]

Reports of mortality in NSTIs range widely from 6% to greater than 70%. In a recent review summarizing 660 cases from several case series, overall mortality was 26%.[52] Comparison of IDU-related NSTI vs. non-IDU NSTI at one institution revealed a lower mortality among injection drug users (10% vs 21%), which may be explained by the younger age and lack of co-morbidities in injection drug users.[49]

Table 6. Treatment of IDU Abscesses

Imaging	Ultrasound, plain x-ray
Local anaesthetic	Bupivacaine preferred. Local field block or regional nerve block. Inject post-incision and drainage in deep sedation cases.
Procedural sedation	Preferred: propofol or methohexital, combined with fentanyl. (Remember to ask about last meal.)
Incision and drainage	Caution: subcutaneous needle possible. Generous incision. Irrigation not recommended. For hemostasis, pack tightly.
Antibiotics	High-risk and febrile patients. Significant surrounding cellulitis. Antibiotic of choice is first-generation cephalosporin.
Follow-up	24 hours, then as needed. Wound check, dressing change, reinforce wound care education.

Septic Arthritis and Osteomyelitis

Both septic arthritis (SA) and osteomyelitis (OM) may complicate IDU. The incidence of these infections has not been well established, but in one report they jointly accounted for 4% of IDU-related hospital admissions. SA appears to be more common, occurring five times as often as OM in one case series.[60]

Both SA and IDU-related OM result from hematogenous seeding during bacteremia. Bacteremia may occur transiently after drug injection or may be due to IE. Of 180 IDU-related bacteremias described in one report, 6% were associated with SA.[2,61] In another series of 104 cases of IE, 15% of cases were complicated by SA or OM.[61] In a series of 36 cases of SA, four were associated with IE.[62] These findings underscore the need to consider IE in all cases of IDU-related SA or OM, and vice versa. Joint infections only rarely result from a contiguous spread of a cellulitis.

In early reports from Los Angeles totaling 180 IDU patients with bone and joint infections, 66-78% of cases were due to *Pseudomonas aeruginosa*.[51,63,64] In more recent studies, *S. aureus* has been the predominant pathogen, isolated in 53-75% of cases whereas only 11% involved Pseudomonas.[60,62] *Eikenella corrodens* also has been isolated in cases of OM.[65]

Bone and joint infections related to IDU typically affect the axial skeleton. In two case series of IDU-related SA, the sacroiliac, costochondral, hip, and sternoclavicular joints were involved in 61-80% of cases. The remainder involved extremity joints, of which the knee was the most common.[62,63] OM in IDU usually occurs in the spine. The lumbar region most commonly is affected, followed by the cervical spine.[61] In one case series involving patients who frequently injected into the groin, lower extremity infections predominated, suggesting that both SA and OM may occur distal to the site of injection.[60]

SA usually presents as an acute infection, with rapid onset of pain, tenderness, and decreased range of motion. Fever occurs in 67-73% of patients; leukocytosis occurs in 50-61%.[60,62] By contrast, OM often is indolent, with patients presenting as late as three months after the onset of infection.[64] Back pain is the most common chief complaint in OM. In one case series of 67 patients, fever was seen in 42% of patients, transient neurological deficits in 15%, and leukocytosis in 35%.[64]

The workup of both SA and OM includes an erythrocyte sedimentation rate (ESR), blood cultures, and x-rays of the symptomatic area. The ESR, while non-specific, is elevated above 20 mm in greater than 90% of SA and OM cases.[62,64] Blood cultures, although positive in only 20-30% of cases, are particularly important in OM because they may establish the etiology and obviate bone biopsy. As mentioned above, a positive blood culture in the setting of SA or OM generally mandates a search for IE.

Plain x-rays are insensitive for acute OM. There is a lag period of 10 days to three weeks or more before the lytic and demineralizing effects of infection become apparent radiographically.[60,64] In one study, fewer than 5% of plain films were positive upon presentation, whereas radiographic signs of OM were present in 90% of cases after 3-4 weeks.[66] Radionuclide scintigraphy, using technecium-, gallium-, or indium-tagged WBCs to visualize areas of infection, has a sensitivity of 50% for chronic infections and as high as 90% in acute infection.[67] Compared with scintigraphy, MRI can better differentiate soft-tissue infection from OM. The sensitivity and specificity of MRI for OM range from 60-100% and 50-90%, respectively.[67]

Arthrocentesis remains the main diagnostic test for suspected SA. Synovial fluid WBC greater than 50,000 or positive Gram stain generally indicates SA. Synovial fluid culture reveals the etiology in approximately 75% of cases, provided that arthrocentesis is performed prior to antibiotics.[62] In the case of a suspected septic hip, ultrasound guidance may permit successful arthrocentesis in the ED.

Treatment of both OM and SA involves IV antibiotics and immobilization. Suspected OM, and to a lesser degree SA, represents deep-seated infection requiring prolonged antibiotics, in which the results of culture may be critical. For this reason, antibiotics should be administered only after appropriate cultures are obtained, unless the patient is clinically unstable. Recommended empiric therapy for OM and SA is the combination of nafcillin and ciprofloxacin, which covers both Staphylococcus and Pseudomonas.[61] In addition to antibiotic therapy, SA generally requires therapeutic arthrocentesis. The benefit of irrigating the joint with an antibiotic solution is unproven.[63] The role of surgery in the treatment of OM remains unclear.

Spinal Epidural Abscess

Spinal epidural abscess (SEA) is a rare but feared complication of IDU. Difficulty arises from the facts that SEA may present simply as back pain, MRI generally is required for diagnosis, and diagnostic delay can be associated with sudden and irreversible neurological damage. The incidence of SEA in the general population is estimated at 0.2-1.0/10000 hospital admissions and is thought to be rising.[69,70] While IDU is considered a major risk factor for SEA, no study specifically has addressed the incidence in this patient population.

Most SEAs are due to hematogenous seeding of the vertebrae or epidural space. Common sources of bacteremia include skin and soft-tissue infections, dental infections, and urinary tract infections, as well as IDU.[68,69] Interestingly, in a series of 18 cases of IDU-related SEA, no co-existing endocarditis was found.[69] *S. aureus* is the predominant pathogen in SEA, and is implicated in 50-65% of SEA cases overall and an even higher percentage of IDU-related cases.[68,69,71] Pseudomonas and tuberculosis also have been isolated in IDU-related SEA. Epidural abscesses were associated with adjacent OM, diskitis, or psoas abscess in 14 of 18 cases, all involving IDU.[69]

There are two proposed mechanisms of cord injury in SEA, which may explain the wide variation in the time of onset of neurological deficits: direct compression and vascular ischemia. Compression due to mass effect is postulated to produce a subacute course, whereas thrombosis and vascular injury may result in a rapid paralysis.

While the classic presentation of SEA includes back pain, fever, and neurological symptoms, the presence of this triad is far from universal. Back pain is present in greater than 90% of patients, whereas fever is present in 60-76%, and neurological deficits are found at presentation in 57-70%.[68,71] Neurologic findings include radicular pain, urinary incontinence, leg weakness, and paraplegia or quadraplegia. Patients occasionally may present with sepsis or encephalitis, further confounding and delaying the diagnosis.[68]

When faced with an IDU patient whose presentation is at all concerning for SEA, emergent imaging is required to exclude or establish the diagnosis. MRI now is the test of choice. With a sensitivity of 90%, it has come to replace the equally sensitive but more invasive CT-myelogram.[68] In addition to revealing an abscess, MRI provides images of the cord itself, and may uncover an alternative diagnosis accounting for the patient's symptoms.[72] Plain x-rays cannot be relied upon to exclude the diagnosis of SAE, although they may be abnormal if there is associated vertebral OM. In such cases, end plate destruction or a narrowed disc space may be evident.

An ESR greater than 30 mm, while nonspecific, almost always is found in SEA. ESR also may be used to follow treatment efficacy. Some authors advocate ESR as a screening test for SEA in at-risk patients, such as injection drug users, who present with unexplained back pain.[68,71] No prospective data exist to sup-

port this approach. Blood cultures are positive in greater than 60% of cases of SEA, and may provide an etiologic diagnosis if surgical cultures are unrevealing.[68,69] Therefore, it is critical that blood cultures be obtained prior to beginning empiric antibiotics whenever the diagnosis of SEA is being entertained.

Treatment of SEA involves both surgical decompression and appropriate antibiotic therapy. While conservative, non-operative management has been described, surgical drainage remains the treatment of choice in most cases.[68-70] Indications for surgery include neurological deficits, negative blood cultures, and failure of conservative therapy. Antibiotic therapy optimally is guided by the results of operative cultures or blood cultures. The combination of nafcillin and an anti-pseudomonal antibiotic such as ciprofloxacin is the recommended initial empiric regimen.[73]

Mortality from SEA is approximately 15%.[70,74] In one series of IDU-related SEA, permanent neurological damage occurred in 25% of cases.[75] The only modifiable determinant of neurological outcome is time from presentation to operative decompression. In one study, all patients with pre-operative neurological deficits for fewer than 36 hours showed some degree of recovery, whereas recovery occurred in only two of 11 in patients with greater than 36 hours of pre-operative neurological deficits.[75]

Tetanus

While tetanus now is a rare disease in the United States, injection drug users remain at significant risk for developing the disease. Of 124 cases reported in the United States between 1995 and 1997, 11% occurred in injection drug users. In California, 40% of cases were related to IDU.[76,77] IDU-related tetanus in California tended to occur in Hispanics in whom under-vaccination against tetanus was documented in every case. The practice of skin popping also appears to be associated with the development of tetanus—of the 14 patients who were questioned about injection technique, all admitted to skin popping.[76,77] EPs who regularly see injection drug users must not only remain vigilant for this uncommon disease, but must attend compulsively to the tetanus immunization status in these patients.

The pathophysiology of tetanus begins with the introduction of *C. tetani* spores into a wound. Similar to botulism, subcutaneous injection of heroin is thought to produce favorable conditions for the growth of *C. tetani*.[78] Spores then germinate and begin to produce the exotoxin tetanospasmin. Tetanospasmin is transported in retrograde fashion to the spinal cord and into inhibitory neurons, where the toxin prevents release of neurotransmitter and ultimately results in muscle spasm.[78,79]

Presenting symptoms are due to muscle spasm, which may be localized—so-called cephalic tetanus—or generalized. Trismus and neck or back pain are the initial symptoms in 85% of cases.[80] Other findings include opisthotonos, risus sardonicus, dysphagia, and drooling. Physical exam reveals palpable muscle rigidity and hyperreflexia.[78-80]

Complications of tetanus include respiratory failure, severe autonomic dysfunction, and rhabdomyolysis. Muscle spasm may involve the airway and respiratory musculature. Asphyxia, apnea, and pneumonia were common in both case series of IDU-related tetanus.[78-80] Autonomic dysfunction, manifesting as tachycardia, blood pressure lability, and hyperpyrexia occurs in the majority of patients. Rhabdomyolysis should be anticipated in cases of severe, generalized muscle spasm.[79,80] Mortality ranges from 70% in early reports to 25% in a recent case series of 18 patients.[79]

The diagnosis of tetanus is made on clinical grounds. Disorders that may present similar to generalized tetanus include the following: seizures, meningitis/encephalitis, drug withdrawal, sepsis, and strychnine poisoning. The differential diagnosis of localized tetanus includes peritonsillar abscess, mandibular disorders, and dystonic reactions.[73,80,81] A history and physical consistent with tetanus in an injection drug user, combined with negative results on CT scan and lumbar puncture, is sufficient to establish the diagnosis. Wound cultures for *C. tetani* are insensitive.[81] Antibody titers against tetanus toxoid should be ordered, although results will not be available to assist with ED diagnosis.

The treatment of tetanus primarily involves three strategies: 1) Elimination of all potential sources of toxin production is accomplished by drainage of skin abscesses and administration of antibiotics active against Clostridium. Metronidazole appears to be the antibiotic of choice;[73] 2) Clearance of extraneuronal tetanospasm toxin is achieved by administration of tetanus immunoglobulin (TIG). Intrathecal plus IV administration of TIG probably offers an advantage over the IV route alone.[79] Passive immunization with tetanus toxoid also should be initiated immediately;[76,79] 3) Aggressive and scrupulous supportive care is critical to prevent associated morbidity and mortality. Patients with muscle spasm that is severe, generalized, or rapidly progressing should be intubated, deeply sedated, and paralyzed if necessary. Long-term ventilatory support and tracheostomy often are required.[79,80] Muscle spasm is controlled with benzodiazepines or propofol. Labetolol, a combined beta- and alpha-adrenergic blocker, can be used to manage autononomic instability.[79]

Table 7. Parenterally Transmitted Viral Infections[82-84]

PARENTERALLY TRANSMITTED VIRAL INFECTION	PREVALENCE
HCV	50-90%
HBV	70%
HIV	1-20% (varies by location)

Viral Seroprevalence and Transmission

IDU has been known for decades to be a major risk factor for a variety of parenterally transmitted viral infections. While a full discussion of IDU-associated viral infections is beyond the scope of this paper, providers who care for injection drug users need to be aware of the high prevalence of viral infections in these patients.

Practices such as needle and paraphernalia sharing readily transmit hepatitis C (HCV), hepatitis B (HBV), as well as HIV. Overall prevalence of HCV and HBV in IDU is 50-90% and 70%, respectively. (*See Table 7.*) There is a linear relationship between the number of years of IDU and seroprevalence of both HCV and

HBV, with a 10-30% incidence of acquiring the infection per year of drug use.[82] After 15 years, seroprevalence of HCV reaches 100%. Approximately 10% of HBV positive patients are HB surface antigen positive, and thus considered infectious.[83,84]

IDU is the second most frequently reported risk behavior leading to HIV infection. Approximately 25% of U.S. AIDS cases reported to the CDC are IDU-related, and as many as 10,000 injection drug users are believed to acquire HIV every year.[32] Nevertheless, infection with HIV is far less common than the hepatitis viruses. HIV seroprevalence among injection drug users varies substantially by geographic location, from 1-3% in California to 23-27% in some northeastern cities such as Newark, NJ.[84,85]

Summary

Every EP should be able to recognize and manage the major bacterial infections that complicate IDU.

References

1. Schoener EP, Hopper JA, Pierre JD. Injection drug use in North America. *Infect Dis Clin North Am* 2002;16:535-551.
2. Levine DP, Lawrence RC, Zervos MJ. Bacteremia in narcotic addicts at the Detroit Medical Center. Infectious endocarditis: A prospective comparative study. *Rev Infect Dis* 1986;8:374-395.
3. Cherubin CE, Sapira JD. The medical complications of drug addiction and the medical assessment of the intravenous drug user: 25 years later. *Ann Intern Med* 1993:119:1017-1028.
4. Stein MD. Injected-drug use: Complications and costs in the care of hospitalized HIV-infected patients. *J Acquir Immune Defic Syndr* 1994;7:469-473.
5. Harris HW, Young DM. Care of injection drug users with soft tissue infections in San Francisco, California. *Arch Surg* 2002;137:1217.
6. Zorc TG, O'Donnell AE, Holt RW, et al. Bilateral pyopneumothorax secondary to intravenous drug abuse. *Chest* 1988;93:645-647.
7. Samet JH, Shevitz A, Fowle J, et al. Hospitalization decisions in febrile intravenous drug users. *Am J Med* 1990;89:53-57.
8. Marantz PR, Linzer M, Feiner CJ, et al. Inability to predict diagnosis in febrile intravenous drug abusers. *Ann Intern Med* 1987;106:823-828.
9. Weisse AB, Heller DR, Schimenti RJ, et al. The febrile parenteral drug user: A prospective study in 121 patients. *Am J Med* 1993;94:274-280.
10. Bouza E, Menasalvas A, Munoz P, et al. Infective endocarditis—a prospective study at the end of the twentieth century: New predisposing conditions, new etiologic agents, and still a high mortality. *Medicine* 2001;80:298-307.
11. Roberts R, Slovis CM. Endocarditis in intravenous drug abusers. *Emerg Med Clin North Am* 1990;8:665-681.
12. Chambers HF, Morris DL, Tauber MG, et al. Cocaine use and the risk for endocarditis in intravenous drug users. *Ann Int Med* 1987;106:833-836.
13. Spijkerman IJ. Human immunodeficiency virus and other risk factors for skin abscesses and endocarditis among injection drug users. *J Clin Epidemiol* 1996;49:1149-1154.
14. Levitt MA, Snoey ER, Tamkin GW, et al. Prevalence of cardiac valve abnormalities in afebrile injection drug users. *Acad Emerg Med* 1999;6:911-915.
15. Delaney KA. Endocarditis in the emergency department. *Ann Emerg Med* 1991;20:405-414.
16. Chambers HF, Korzeniowski OM, Sande MA. *Staphylococcus aureus* endocarditis: Clinical manifestations in addicts and nonaddicts. *Medicine* 1983;62:170-177.
17. Mathew J, Addai T, Anand A, et al. Clinical features, site of involvement, bacteriologic findings, and outcome of infective endocarditis in intravenous drug users. *Arch Intern Med* 1995;155:1641-1648.
18. Chambers HF, Miller RT, Newman MD. Right-sided *Staphylococcus aureus* endocarditis in intravenous drug abusers: Two-week combination therapy. *Ann Intern Med* 1988;109:619-624.
19. Hecht SR, Berger M. Right-sided endocarditis in intravenous drug users. Ann Intern Med 1992;117:560-566.
20. Crane LR, Levine DP, Zervos MJ, et al. Bacteremia in narcotic addicts at the Detroit Medical Center. I. Microbiology, epidemiology, risk factors, and empiric therapy. *Rev Infect Dis* 1986;8:364-373.
21. Brouqui P, Raoult D. Endocarditis due to rare and fastidious bacteria. *Clin Microbiol Rev* 2001;14:177-207.
22. Mathew J, Addai T, Anand A, et al. Clinical features, site of involvement, bacteriologic findings, and outcome of infective endocarditis in intravenous drug users. *Arch Intern Med* 1995;155:1641-1648.
23. Durack DT, Lukes AS, Bright DK. New criteria for diagnosis of infective endocarditis: Utilization of specific echocardiographic findings. *Am J Med* 1994;96:200-209.
24. Bayer AS, Ward JI, Ginzton LE, et al. Evaluation of new clinical criteria for the diagnosis of infective endocarditis. *Am J Med* 1994;96:211-219.
25. Cecchi E, Parrini I, Chinaglia A, et al. New diagnostic criteria for infective endocarditis. A study of sensitivity and specificity. *Eur Heart J* 1997;18:1 149-1156.
26. Mortara LA, Bayer AS. *Staphylococcus aureus* bacteremia and endocarditis. New diagnostic and therapeutic concepts. *Infect Dis Clin North Am* 1993; 7:53-68.
27. Mugge A, Daniel WG. Echocardiographic assessment of vegetations in patients with infective endocarditis: prognostic implications. *Echocardiography* 1995;12:651-661.
28. DiNubile MJ. Short-course antibiotic therapy for right-sided endocarditis caused by *Staphylococcus aureus* in injection drug users. *Ann Intern Med* 1994;121:873-876.
29. Dinubile MJ. Surgery in active endocarditis. *Ann Intern Med* 1982;96: 650-659.
30. Cicalini S, Forcina G, De Rosa FG. Infective endocarditis in patients with human immunodeficiency virus infection. *J Infect* 2001;42:267-271.
31. Ribera E, Miro JM, Cortes E, et al. Influence of HIV 1 infection and degree of immunosuppression in the clinical characteristics and outcome of infective endocarditis in intravenous drug users. *Arch Intern Med* 1998;158: 2043-2050.
32. Cohn JA. HIV-1 infection in injection drug users. *Infect Dis Clin North Am* 2002;16:745-770.
33. Bergstein JM, Baker EJ 4th, Aprahamian C, et al. Soft tissue abscesses associated with parenteral drug abuse: Presentation, microbiology, and treatment. *Am Surg* 1995;12:1105-1108.
34. Orangio GR, Pitlick SD, Della Latta P, et al. Soft tissue infections in parenteral drug abusers. *Ann Surg* 1984;199:97-100.
35. Schnall SB, Holtom PD, Lilley JC. Abscesses secondary to parenteral abuse of drugs. A study of demographic and bacteriological characteristics. *Am J Bone Joint Surg* 1994;76:1526-1530.
36. Binswanger IA, Kral AH, Bluthenthal RN, et al. High prevalence of abscesses and cellulitis among community-recruited injection drug users in San Francisco. *Clin Infect Dis* 2000;30:579-581.
37. Murphy EL, DeVita D, Liu H, et al. Risk factors for skin and soft-tissue abscesses among injection drug users: A case-control study. *Clin Infect Dis* 2001;33:35-40.
38. Meislin HW, Lerner SA, Graves MH, et al. Cutaneous abscesses. Anaerobic and aerobic bacteriology and outpatient management. *Ann Intern Med* 1977;87:145-149.
39. Struk DW, Munk PL, Lee MJ, et al. Imaging of soft tissue infections. *Radiologic Clin North Am* 2001;39:277-303.
40. Gonzalez MH, Garst J, Nourbash P, et al. Abscesses of the upper extremity from drug abuse by injection. *J Hand Surg* 1993;18A:868-870.
41. Bobrow BJ, Pollack CV, Gamble S, et al. Incision and drainage of cutaneous abscess is not associated with bacteremia in afebrile adults. *Ann Emerg Med* 1997;29:404-408.
42. Keyes LE, Frazee BW, Snoey ER, et al. Ultrasound-guided brachial and basilic vein cannulation in emergency department patients with difficult intravenous access. *Ann Emerg Med* 2000;36:399.
43. Simmen HP, Giovanoli P, Battaglia H, et al. Soft tissue infections of the upper extremities with special consideration of abscesses in parenteral drug abusers. A prospective study. *J Hand Surg* 1995;20:797-800.
44. Henriksen BM, Albrektsen SB, Simper LB, et al. Soft tissue infections from drug abuse. A clinical and microbiological review of 145 cases. *Acta Orthop Scand* 1994;65:625-628.
45. Summanen PH, Talan DA, Strong C, et al. Bacteriology of skin and soft-tissue infections: Comparison of infections in intravenous drug users and individuals with no history of intravenous drug use. *Clin Infect Dis* 1995; 20(suppl 2): s279-s282.
46. Quirk W F, Sternbach G. Joseph Jones: Infection with flesh eating bacteria.

J Emerg Med 1996;14:747-753.
47. Sudarsky LA, Laschinger JC, Coppa GF, et al. Improved results from a standardized approach in treating patients with necrotizing fasciitis. *Ann Surg* 1987;206:661-665.
48. Francis KR, Lamaute HR, Davis JM, et al. Implications of risk factors in necrotizing fasciitis. *Am Surg* 1993;59:304-308.
49. Chen JL, Fullerton KE, Flynn NM. Necrotizing fasciitis associated with injection drug use. *Clin Infect Dis* 2001;1:6-15.
50. Gonzalez MH, Kay T, Weinzweig N, et al. Necrotizing fasciitis of the upper extremity. *J Hand Surg* 1996;21:689-692.
51. Bosshardt TL, Henderson VJ, and Organ CH Jr. Necrotizing soft-tissue infections. *Arch Surg* 1996;131:846-854.
52. Callahan TE, Schecter WP, Horn JK. Necrotizing soft tissue infections masquerading as cutaneous abscess following illicit drug injection. *Arch Surg* 1998;133:812-818.
53. Ault MJ, Geiderman J, Sokolov R. Rapid identification of group A Streptococcus as the cause of necrotizing fasciitis. *Ann Emerg Med* 1996;28: 227-230.
54. McHenry CR, Piotrowski JJ, Petrinic D, et al. Determinants of mortality for necrotizing soft-tissue infections. *Ann Surg* 1995;221:558-565.
55. Wall DB, de Virgilio C, Black S, et al. Objective criteria may assist in distinguishing necrotizing fasciitis from non-necrotizing soft tissue infection. *Am J Surg* 2000;179:17-21.
56. Rahmouni A, Chosidow O, Mathieu D, et al. MR imaging in acute infectious cellulitis. *Radiology* 1994;192:493-496.
57. Stamenkovic I, Lew PD. Early recognition of potentially fatal necrotizing fasciitis. The use of frozen-section biopsy. *N Engl J Med* 1984;310: 1689-1693.
58. Lillie ST, Sato TT, Engrav LH, et al. Necrotizing soft tissue infections: Obstacles in diagnosis. *J Am Coll Surg* 1996;182 7-11.
59. Elliot DC, Kufera JA, Myers RA. Necrotizing soft tissue infections. Risk factors for mortality and strategies for management. *Ann Surg* 1996;224: 672-683.
60. Chandrasekar PH, Narula AP. Bone and joint infections in intravenous drug abusers. *Rev Infect Dis* 1986;8:904-911.
61. Sapico FL, Liquete JA, Sarma RJ. Bone and joint infections in patients with infective endocarditis: Review of a 4-year experience. *Clin Infect Dis* 1996; 22: 783-787.
62. Brancos MA, Peris P, Miro JM, et al. Septic arthritis in heroin addicts. *Semin Arthritis Rheum* 1991;21:81-87.
63. Roca RP, Yoshikawa TT. Primary skeletal infections in heroin users: A clinical characterization, diagnosis and therapy. *Clin Orthop* 1979;144: 238-248.
64. Sapico FL, Montgomerie JZ. Vertebral osteomyelitis in intravenous drug abusers: Report of three cases and review of the literature. *Rev Infect Dis* 1980;2:196-206.
65. Swisher LA, Roberts JR, Glynn MJ. Needle licker's osteomyelitis. *Am J Emerg Med* 1994;12:343-346.
66. Schauwecker DS, Braunstein EM, Wheat LJ. Diagnostic imaging of osteomyelitis. *Infect Dis Clin North Am* 1990;4:441-463.
67. Tehranzadeh J, Wong E, Wang F, et al. Imaging of osteomyelitis in the mature skeleton. *Radiologic Clin North Am* 2001;39:223-250.
68. Hlavin ML, Kaminski HJ, Ross JS, et al. Spinal epidural abscess: A ten-year perspective. *Neurosurgery* 1990;27:177-184.
69. Koppel BS, Tuchman AJ, Mangiardi JR, et al. Epidural spinal infection in intravenous drug abusers. *Arch Neurol* 1988;45:1331-1337.
70. Reihsaus E, Waldbaur H, Seeling W. Spinal epidural abscess: A meta-analysis of 915 patients. *Neurosurg Rev* 2000;23:175-204.
71. Del Curling O Jr, Gower DJ, McWhorter JM. Changing concepts in spinal epidural abscess: A report of 29 cases. *Neurosurgery* 1990;27:185-192.
72. Stabler A, Reiser MF. Imaging of spinal infection. *Radiol Clin North Am* 2001;39:115-135.
73. Tunkel AR, Pradhan SK. Central nervous system infections in injection drug users. *Infect Dis Clin North Am* 2002;16:589-605.
74. Martin RJ, Yuan HA. Neurosurgical care of spinal epidural, subdural, and intramedullary abscesses and arachnoiditis. *Orthop Clin North Am* 1996; 27:125-136.
75. Danner RL, Hartman BJ. Update of epidural abscess: 35 cases and a review of the literature. *Rev Infect Dis* 1987;9:265.
76. Talan DA, Moran GJ. Tetanus among injecting drug users-California,1997. *Ann Emerg Med* 1998;32:385-386.
77. Bardenheier B, Prevots DR, Khetsuriani N. Tetanus surveillance—United States, 1995-1997. *MMWR CDC Surveill Summ* 1998;47:1-13.
78. Francois MP, Roberts JR, Hewlett D. Tetanus in a parenteral drug abuser: Report of a case. *J Natl Med Assoc* 1994; 86:223-225.
79. Sun KO, Chan YW, Cheung RTF, et al. Management of tetanus: A review of 18 cases. *J R Soc Med* 1994;87:135-137.
80. Brust JC, Richter RW. Tetanus in the inner city. *N Y State J Med* 1974;74: 1735-1742.
81. Abrahamian FM, Pollack CV Jr, LoVecchio F, et al. Fatal tetanus in a drug abuser with "protective" antitetanus antibodies. *J Emerg Med* 2000;18: 189-193.
82. Hagan H, Des Jarlais DC. HIV and HCV infection among injecting drug users. *Mt Sinai J Med* 2000;67:423-428.
83. Garfein RS, Vlahov D, Galai N, et al. Viral infections in short-term injection drug users: The prevalence of the hepatitis C, hepatitis B, human immunodeficiency, and human T-lymphotropic viruses. *Am J Public Health* 1996;86: 655-661.
84. Zeldis JB, Jain S, Kuramoto IK, et al. Seroepidemiology of viral infections among intravenous drug users in northern California. *West J Med* 1992; 156:30-35.
85. [No Author Listed.] AIDS associated with injecting drug use. *Morb Mortal Wkly Rep* 1996;45:392-398.

Physician CME Questions

141. Which of the following statements is true about treatment of possible IDU-associated endocarditis?
    A. Empiric treatment of suspected IE related to IDU should cover *S. aureus* and Streptococcal species.
    B. Empiric treatment should be started in the ED for ill-appearing patients.
    C. Empiric treatment should be started in the ED for patients with heart failure.
    D. All of the above

In Future Issues: **B-type Natriuretic Peptide**

Emergency Medicine Reports
CME Objectives

To help physicians:

- quickly recognize or increase index of suspicion for specific conditions;
- understand the epidemiology, etiology, pathophysiology, and clinical features of the entity discussed;
- be educated about how to correctly perform necessary diagnostic tests;
- take a meaningful patient history that will reveal the most important details about the particular medical problem discussed;
- apply state-of-the-art therapeutic techniques (including the implications of pharmaceutical therapy discussed) to patients with the particular medical problems discussed;
- understand the differential diagnosis of the entity discussed;
- understand both likely and rare complications that may occur;
- and provide patients with any necessary discharge instructions.

142. Blood cultures are used in IDU-associated osteomyelitis for all of the following reasons *except*:
   A. near-perfect sensitivity.
   B. to obviate the need for bone biopsy.
   C. suspected OM represents deep-seated infection requiring prolonged antibiotics.
   D. to detect possible co-existent endocarditis.

143. Treatment of SEA involves surgical decompression and appropriate antibiotic therapy.
   A. True
   B. False

144. X-rays may be obtained in the workup of abscesses to detect the complications of IDU and soft-tissue infections. Findings may include all of the following *except*:
   A. tissue gas.
   B. osteomyelitis.
   C. foreign bodies.
   D. abscess.

145. The rationale for admission of febrile injection drug users without a source includes which of the following?
   A. The majority of febrile injection drug users ultimately are diagnosed with endocarditis.
   B. Physicians generally are able to distinguish endocarditis from other sources of fever.
   C. Endocarditis is rapidly fatal.
   D. Injection drug users are regarded in general as patients who may fail to return to the hospital if blood cultures become positive.

146. A 20-year-old injection drug user presents with a painful right arm two days after skin-popping, T=101. The patient is hemodynamically stable. Physical exam signs that support the diagnosis of NSTI include all of the following *except*:
   A. pain out of proportion to exam.
   B. bullae.
   C. crepitus.
   D. induration.
   E. well-demarcated erythema and fluctuance.

147. The sole modifiable determinant of mortality in patients with necrotizing fasciitis is:
   A. time to administration of antibiotics.
   B. adequacy of fluid resuscitation.
   C. time to operative debridement.
   D. time to definitive diagnosis in the ED.
   E. ability to isolate the causative organism.

148. IDU endocarditis differs from native valve endocarditis in which of the following ways?
   A. Duke criteria do not apply to patients with IDU endocarditis.
   B. IDU patients have more left-sided and immunologic sequelae.
   C. Non IDU-related endocarditis generally has a lower mortality.
   D. Choice of empiric antibiotics is different.

149. In the setting of IDU-related soft-tissue infections, EP operated ultrasound is used to detect which of the following?
   A. Cellulitis
   B. Abscess cavities
   C. Foreign bodies
   D. Necrotizing process

150. Treatment of tetanus includes administration of antibiotics active against Clostridium, with metonidazole appearing to be the antibiotic of choice.
   A. True
   B. False

CME Instructions

Physicians participate in this continuing medical education program by reading the article, using the provided references for further research, and studying the questions at the end of the article. Participants should select what they believe to be the correct answers, then refer to the list of correct answers to evaluate their knowledge. To clarify confusion surrounding any questions answered incorrectly, please consult the source material. *After completing this activity, you must complete the evaluation form that will be provided at the end of the semester and return it in the reply envelope provided to receive a certificate of completion.* When your evaluation is received, a certificate will be mailed to you.

Correction

The June 16, 2003, issue of *Emergency Medicine Reports* contained an incorrect statement on page 181, column 2. The correct statement should read, "For example, pesticides containing cholinesterase inhibitors may require pralidoxime chloride (2-PAM) and significant amounts of atropine; conversely, intoxications from pesticides containing anticholinergic agents may be distinguished and treated with IV physostigmine (with due regard for the possibility of serious side effects, including bradycardia, asystole, bronchospasm, increased secretions, aspiration, and seizures)."

Answer Key

141. D	146. E
142. A	147. C
143. A	148. D
144. D	149. B
145. D	150. A

Emergency Medicine Reports
The Practical Journal for Emergency Physicians

Infectious Complications of Injection Drug Use

Classification of Endocarditis Based on Organism, Location, and Clinical Characteristics

TYPE	ORGANISM	VALVE LOCATION	CHARACTERISTICS
Subacute	*Streptococcus viridans*	Mitral or aortic valve	Indolent course; immune or vascular symptoms
Acute	*Staphylococcus aureus*	Mitral or aortic valve	Rapid course; heart failure; arterial embolic disease; highest mortality; more frequently requiring surgery
Right-sided (classic IDU form)	*Staphylococcus aureus*	Tricuspid valve	Indolent course; septic pulmonary emboli; murmur often absent
Prosthetic valve	*Streptococcus viridans* Coag. negative Staphylococcus	Mitral or aortic prosthetic valve	**Early:** likely surgical complication with high mortality. **Late:** similar to subacute native valve

IDU = Injection drug use

Frequency of Valve Involvement in IDU-Related IE

VALVE LOCATION	FREQUENCY OF INVOLVEMENT
Tricuspid	40-70%
Mitral	20-30%
Aortic	20-30%
Right- and left-sided	5-15%

Empiric Treatment for IDU-Related Infectious Endocarditis

TYPE	ANTIBIOTIC REGIMEN	DURATION
Right-sided and low risk (see text)	Nafcillin *plus* gentamicin	2 weeks
Left-sided or high risk	Nafcillin *plus* gentamicin	4-6 weeks
Penicillin allergic patient	Vancomycin *plus* gentamicin	4-6 weeks

Bacteria Associated with IDU Abscesses

AEROBES (MAJORITY-97%)	
Staphylococcus aureus	19-71%
Streptococcus species, incl. Milleri	14-50%
Eikenella	Up to 25%

ANAEROBES (20%)	
Peptostreptococcus	17%
Fusobacterium	22%
Bacteroides	19%
Prevotella	17%

Parenterally Transmitted Viral Infections

PARENTERALLY TRANSMITTED VIRAL INFECTION	PREVALENCE
HCV	50-90%
HBV	70%
HIV	1-20% (varies by location)

Duke Diagnostic Criteria for Endocarditis

DEFINITE ENDOCARDITIS

1. Histopathologically proven vegetation or intracardiac abscess found post-mortem or during surgery
2. Clinical criteria are any of: two major criteria*; one major and three minor criteria**; five minor criteria (see below for definitions)

***MAJOR CRITERIA**

1. Multiple positive blood cultures
2. Evidence of endocardial involvement—positive echocardiogram findings, such as oscillating valvular mass, valvular dehiscence, or new valvular regurgitation

****MINOR CRITERIA**

1. Fever
2. Predisposing heart condition or IDU
3. Vascular phenomenon
4. Immunological phenomenon
5. Echocardiogram consistent with IE but not meeting above criteria

IDU = Injection drug use
IE = Infectious endocarditis

Treatment of IDU Abscesses

Imaging	Ultrasound, plain x-ray
Local anaesthetic	Bupivacaine preferred. Local field block or regional nerve block. Inject post-incision and drainage in deep sedation cases.
Procedural sedation	Preferred: propofol or methohexital, combined with fentanyl. (Remember to ask about last meal.)
Incision and drainage	Caution: subcutaneous needle possible. Generous incision. Irrigation not recommended. For hemostasis, pack tightly.
Antibiotics	High-risk and febrile patients. Significant surrounding cellulitis. Antibiotic of choice is first-generation cephalosporin.
Follow-up	24 hours, then as needed. Wound check, dressing change, reinforce wound care education.

Summary of Management for Infectious Complications of IDU

INFECTIOUS ENDOCARDITIS

- IE is found in 6-13% injection drug users with fever.
- *S. aureus* infection of tricuspid valve is the most common form.
- Pulmonary complaints may predominate; chest x-ray is abnormal in 70% of cases.
- *S. aureus* infection of aortic valve is associated with severe morbidity and mortality.
- Blood cultures are the key to diagnosis and must be carefully obtained in the ED prior to antibiotics.
- Nafcillin plus gentamicin is first-line empiric therapy.

CUTANEOUS ABSCESS

- Cutaneous abscess is the leading reason for IDU ED visits.
- ED ultrasound can aid in evaluation and drainage.
- Deep procedural sedation with a short-acting agent is recommended for I & D of large abscesses.
- Parenteral antibiotics and admission generally are indicated for febrile or ill-appearing patients.

NECROTIZING SOFT-TISSUE INFECTIONS

- IDU is the most common risk factor for community-acquired NSTI.
- Consider NSTI in any IDU patient with a soft-tissue infection.
- Very elevated WBC, skin signs, and gas on x-ray are helpful if present, but diagnosis is surgical.
- Early recognition and prompt surgical management reduce mortality.

SEPTIC ARTHRITIS

- EPs should exclude this diagnosis in any IDU patient with acute arthritis.
- Arthrocentesis is both diagnostic and therapeutic.
- ESR is considered a sensitive but nonspecific diagnostic adjunct.
- Diagnosis of SA (and OM) generally mandates a workup for IE.

OSTEOMYELITIS AND SPINAL EPIDURAL ABSCESS

- Consider these diagnoses in any IDU patient with neck or back pain.
- The axial skeleton is the most common site of OM in injection drug users.
- Back pain plus neurologic findings in an injection drug user suggests SEA, which is a surgical emergency.
- MRI usually is required for diagnosis of SEA.
- ESR is elevated in more than 90% of OM and SEA cases.
- Mortality and disability from SEA are decreased with early surgery.

WOUND BOTULISM

- A mini-epidemic of wound botulism is occuring in western states, related to black tar heroin use.
- It is a syndrome of descending paralysis, with often subtle bulbar findings.
- Respiratory involvement is the rule and often requires intubation and prolonged mechanical ventilation.
- Intravenous antitoxin reduces the rate of respiratory failure.
- Treatment also includes wound debridement and antibiotics.

TETANUS

- IDU soft-tissue infections are tetanus-prone, and tetanus immunization status should be addressed routinely.
- Signs include trismus, muscle spasms, and autonomic lability.
- Most cases require intubation and ICU level care.

Supplement to *Emergency Medicine Reports*, July 14, 2003: "Infectious Complications of Injection Drug Use." *Authors:* **Brad Frazee, MD, FACEP,** Department of Emergency Medicine, Alameda County Medical Center, Assistant Clinical Professor, Department of Medicine, University of California, San Francisco; and **Ralph Wang, MD,** Department of Emergency Medicine, Alameda County Medical Center, Oakland, CA.

THOMSON
AMERICAN HEALTH CONSULTANTS

Evidence-Based Medicine for the ED

Trauma Reports®

Vol. 4, No. 4

Supplement to *Emergency Medicine Reports*, *Pediatric Emergency Medicine Reports*, *ED Management*, and *Emergency Medicine Alert*

July/August 2003

Pediatric Cervical Spine Injuries: Avoiding Potential Disaster

Author: **William A. Woods, MD, FAAP,** Assistant Professor of Emergency Medicine and Pediatrics, University of Virginia Health System, Charlottesville.

Peer Reviewer: **Larry B. Mellick, MS, MD, FAAP, FACEP,** Chairman and Professor, Section Chief, Pediatric Emergency Medicine, Department of Emergency Medicine, Medical College of Georgia, Augusta.

Although cervical spine injuries (CSIs) are uncommon in children, a missed or delayed diagnosis may have devastating consequences for the patient. A thorough understanding of normal pediatric anatomy, injury patterns, and children who are at increased risk for injury is critical for the physician caring for the acutely injured child. The author provides an overview of the unique features of the pediatric spine, and fracture patterns that occur commonly in children. The author also offers guidelines on instances when a child is at increased risk for sustaining a CSI.

—The Editor

Introduction

The diagnoses of CSIs in children deserves special attention and distinction from injuries in adults. The anatomy, biomechanics, and injury pattern of the infant are different than those of the school-age child and the adolescent. By adolescence, the cervical spine has assumed the same mechanical response as the adult spinal column. This review will describe the anatomy of the cervical spine from infancy through adolescence and discuss the varying injury patterns that may occur through childhood. A general sense of the biomechanical tolerance of the pediatric spine will be developed through a review of injury-producing impacts. Additionally, limitations of data will be acknowledged that will necessitate practical management recommendations.

Anatomy of the Cervical Spine

The cervical spine is composed of seven vertebrae, each separated by an intervertebral disc. The cranium rests upon the atlas (C_1) while C_7 rests upon the first thoracic vertebra (T_1). See Figure 1 for the landmarks of the lower cervical vertebrae.

Tethering ligaments and their associated attachments are listed in Table 1. The transverse ligament is unique to C_1 and maintains the relationship between C_1 and C_2. This ligament attaches to the posterior dens (odontoid process of C_2) from the inner, lateral aspect of C_1. The other tethering ligaments, as well as the facets and interfacet joints, limit horizontal motion between the vertebral bodies. Additionally, the tethering ligaments limit axial, or vertical, elongation of the spinal column. When the mechanical properties of these structures are overcome by the forced neck motion of impact, an injury will result.

Developmental Biology of the Cervical Spine

The ossification centers of the vertebral bodies appear during the second month of gestation as sclerodermal mesoderm

migrates and thickens into the vertebral column. The vertebral bodies are formed by two lateral neural arches and a centra. The centra and the anterior portion of the lateral arches fuse to form the vertebral body. The posterior portions of the neural arches fuse to form the transverse processes, facets, and spinous process. The anterior and posterior arches are radiographically evident at birth, while the spinous, articular, and transverse processes do not fuse until approximately 8 years of age.

Ossification of the dens is not complete until 6-8 years of age. The dens is formed by union of two lateral globular masses, achieving a conical shape at an age of viability.[1] This ossified dens retains a cartilaginous association with the body of C_2 until fusion occurs at age 6-8 years. The tip of the dens is formed by a separate ossification center. The superior portion of the dens is calcified by age 4 years.

In the newborn cervical spine, the facet joints are flatter than those in the mature teenage spine, therefore, anterior-posterior relative motion is not limited in the newborn's cervical spine as well as it is in the mature spine. One study found that the facet joint angle does not assume an adult angle until age 10 years.[2] Additionally, potential voluntary anterior-posterior motion of one vertebral body upon another is increased until age 12 years.

Figure 1. Anatomy of the Cervical Vertebra

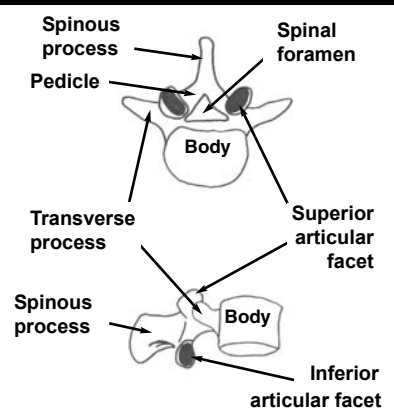

Although no biomechanical data exist to quantify the difference, the musculature supporting the pediatric cervical spine is assumed to be laxer than in adults. In addition to a weaker neck, infants have a relatively larger head, per body weight, than adults do. In summary, in young children, a weaker neck that has less restriction to mechanical motion must support a heavier head. Being at an anatomic disadvantage, the cervical spine in infants and children may be at risk for injury at lower impact energies than would cause injury in adults.

Cervical Spine Malformations and Anomalies. As described above, embryologic formation of the vertebral column starts during the third to fourth week of gestation. Additionally, the major structures of the face and neck develop between weeks 4 and 12.[3] Children who have abnormal embryologic development of facial or neck features are at risk for abnormal cervical spine development as embryologic development of these two structures occurs simultaneously.[4] See Table 2 for a list of associated abnormalities. While the emergency physician often will not be able to identify the specific malformation syndrome, patients with face and neck anomalies should be considered at risk of having a congenitally abnormal cervical spine.

When examining cervical spine radiographs, it is necessary to look for any signs of congenital abnormality. Fusion of adjacent posterior elements commonly is associated with fusion of the vertebral bodies. Identification of the posterior fusion will appear earlier, as the complete ossification of the vertebral bodies is delayed in children. Fusions are most common above C_4, yet can occur throughout the cervical spine. Other common abnormalities include occiptoatlantal fusion, hypoplastic or anomalous portions of the atlas, ligamentous laxity, and malformations of the dens.[3,5]

Studies of U.S. football players have demonstrated that congenital cervical stenosis commonly is detected in athletes with transient neuropraxias. However, this anomaly does not predispose athletes to catastrophic neurological injury.[6]

Trauma Reports™ (ISSN 1531-1082) is published bimonthly by Thomson American Health Consultants, 3525 Piedmont Road, N.E., Six Piedmont Center, Suite 400, Atlanta, GA 30305. Telephone: (800) 688-2421 or (404) 262-7436.

Vice President/Group Publisher: Brenda Mooney
Editorial Group Head: Valerie Loner
Managing Editor: Allison Mechem
Marketing Manager: Schandale Kornegay

Periodicals postage paid at Atlanta, GA. (GST registration number R128870672.)

POSTMASTER: Send address changes to ***Trauma Reports***, P.O. Box 740059, Atlanta, GA 30374.

Subscriber Information

Customer Service: 1-800-688-2421

Customer Service E-Mail: customerservice@ahcpub.com
Editorial E-Mail: allison.mechem@ahcpub.com

World Wide Web page: http://www.ahcpub.com

Subscription Prices

FREE to subscribers of *Emergency Medicine Reports, Pediatric Emergency Medicine Reports, Emergency Medicine Alert*, and *ED Management.*

For nonsubscribers, the price is $199.

U.S. possessions and Canada, add $30 plus applicable GST. Other international orders, add $30.

Back issues: $66. One to nine additional copies, $159 each; 10-20 additional copies, $119 each.

Accreditation

Trauma Reports™ continuing education materials are sponsored and supervised by Thomson American Health Consultants. Thomson American Health Consultants designates this continuing education activity for up to 2.5 hours in Category 1 credit toward the AMA Physician's Recognition Award. Each physician should claim only those hours of credit that he/she actually spent in the educational activity. This CME activity was planned and produced in accordance with the ACCME Essentials. Approved by the American College of Emergency Physicians for 2.5 hours of CEP Category 1 credit.

Thomson American Health Consultants (AHC) is accredited by the Accreditation Council for Continuing Medical Education (ACCME) to provide continuing medical education for physicians.

Trauma Reports® is approved for approximately 2.5 nursing contact hours. This offering is sponsored by Thomson American Health Consultants, which is accredited as a provider of continuing education in nursing by the American Nurses' Credentialing Center's Commission on Accreditation. Provider approved by the California Board of Registered Nursing, Provider Number CEP 10864, for approximately 2.5 contact hours. This program (#0105-1) has been approved by an AACN Certification Corp.-approved provider (#10852) under established AACN Certification Corp. guidelines for 2.5 contact hours, CERP Category A.

This is an educational publication designed to present scientific information and opinion to health professionals, to stimulate thought, and further investigation. It does not provide advice regarding medical diagnosis or treatment for any individual case. It is not intended for use by the layman. Opinions expressed are not necessarily those of this publication. Mention of products or services does not constitute endorsement. Clinical, legal, tax, and other comments are offered for general guidance only; professional counsel should be sought for specific situations.

The intended audience for this publication is emergency, family, osteopathic, and general practice physicians and nurses who have contact with trauma patients.

THOMSON™
AMERICAN HEALTH CONSULTANTS

For Customer Service,
Please call our customer service department at **(800) 688-2421.** For editorial questions or comments, please contact **Allison Mechem**, Managing Editor, at allison.mechem@ahcpub.com.

Conflict of Interest Disclosure

In order to reveal any potential bias in this publication, and in accordance with Accreditation Council for Continuing Medical Education guidelines, Drs. Dietrich (editor in chief), Bowman, Diebel, Falcone, Hanlon, Jones, Mahadevan, Perkin, Santanello, Savitsky, and Stafford (editorial board members), Woods (author), and Mellick (peer reviewer) report no relationships with companies related to the field of study covered by this CME program.

Table 1. Tethering Ligaments in the Cervical Spine

Vertebral bodies and discs	Anterior and posterior longitudinal ligaments
Facets	Interfacet capsular ligaments
Spinous processes	Interspinous and supraspinous ligaments
Transverse processes	Intertransverse ligaments
Adjacent lamina	Ligamentum flavum

Even though it would seem logical, neuromuscular disorders typically do not affect the cervical spine. Instead, neuromuscular disorders tend to result in thoracolumbar scoliosis.[7] Examples of these disorders include cerebral palsy, muscular dystrophy, spinal muscular atrophy, and Rett's syndrome.

Cervical Spine Injury Distribution (Age/Location)

CSIs are less common in pediatric trauma patients than in adult patients. The NEXUS group found 30 injuries in 3065 (1%) pediatric patients, compared to injuries in 2.5% of adult patients (788/31,004).[8] Approximately two-thirds of pediatric CSI occur in patients older than 8 years of age.[9] These data reflect patients who arrived to emergency departments, and do not include those who died prior to transport. In a series of 102 patients, 42% of those younger than 10 years of age arrived neurologically intact, 42% had an incomplete spinal cord injury and 16% had a complete lesion.[10] Of those between 10 and 16 years, 41% (26 of 64 patients) arrived neurologically intact, 47% had partial spinal cord lesions, and 12% had complete spinal cord injury on arrival.

Types of injuries to the pediatric cervical spine include fractures, dislocations, or SCIWORA (Spinal Cord Injury Without Radiographic Abnormality). In one review of the National Pediatric Trauma Registry, 25-30% of all CSI were SCIWORA in children younger than 11 years.[11] In patients between 11 and 18 years, 15-20% of all CSI were SCIWORA. Fractures accounted for 35-40% of CSI in children younger than 7 years, 45-50% between 7 and 11 years, 60-70% from 12 to 16 years, and 70-75% in those older than 16 years. Dislocations caused 30-40% of the injuries in those younger than 7 years, 20-30% in those 7-11 years, and 15-25% in those 12-16 years. In summary, fractures are the most common injury seen and increase in frequency through childhood. Dislocations also are more common in younger children, but the difference between young and old is not as dramatic. SCIWORA is common in younger children, but may occur in any age group.

Younger children with CSI most commonly are injured in the upper cervical spine. *(See Figure 2.)* By the end of the teenage years, injuries are distributed more evenly between the upper and lower cervical spine. In children younger than 11 years of age, 15-20% of all CSI are below C_4. In the ages 11-15, 35-40% of CSI are below C_4. Upper and lower CSI are equally as likely in the child older than 15 years.[11] Series published through individual institutions have presented differing distribution of injuries, but one paper[11] included 408 children, the largest data set of pediatric CSI.[12-22]

Some data exist regarding the prevalence of CSI as an isolated injury. In a group of 72 children with CSI from Utah, one study notes that the median Glasgow Coma Score (GCS) was 15.[22] Fourteen percent of the children had a GCS less than 13. The mean injury severity score was 15, with a range of 4-54.[22] In another series, 37 children younger than 9 years had a mean injury severity score of 26, while the 36 children older than 8 years had a mean injury severity score of 12.1.[18] These data suggest that children may sustain an isolated CSI .

Combining the data presented in two studies allows some description of outcomes in children with CSI.[12,19] Eleven of 18 children younger than 5 years with CSI died. Fourteen of 19 children between the ages of 5 and 10 died. Of those older than 10 years, four of 42 children died. In one of the two studies, all children survived if they had an isolated cervical spine fracture. One child out of nine with a fracture/subluxation died. All 15 children with distraction injuries died (eight of which were occipito-cervical injuries).

Injury Etiology

CSI in young children tends to result from motor vehicle collisions (MVCs), falls, pedestrian injuries, or child abuse. Older children are more active in sports and activities and may endure a CSI due to MVCs, sports, falls or bicycle accidents.[9-12,16-18,20-22]

To further clarify the force of impact necessary to cause CSIs in children, it is tempting to read injury reports regarding specific mechanisms of trauma. Many authors have published series of papers dealing with the injuries seen after specific types of trauma, including falls,[24-27] crashes,[28-31] and animal attacks.[32] These data series tend to reinforce to the clinician that a specific impact may be an injury-producing impact. Potentially more useful are series that emphasize mechanisms that did not result in a CSI from a specific type of trauma. CSI did not occur in any child in a series of 432 falls down stairs reported in two series.[33,34] One child died after a fall down stairs in a walker after suffering a CSI, skull fracture, and subdural hematoma.[35,36]

Similarly, a CSI did not occur in any child after falling from bed (207 children),[37] high chairs (103 children),[38] or shopping carts (62 children).[39] One author reported 151 falls from heights, none resulted in CSI.[40] Another group reported a series of 101 children admitted to the hospital with a skull fracture. None of these children had a concurrent CSI.[41]

One author published a series of eight children who sustained CSI after short falls.[42] All were symptomatic at the time of presentation (although the time from injury to symptom onset is not reported). In this series, a 4-year-old had a C_1-C_2 subluxation after falling out of bed. A 9-month-old fell while pulling herself up and suffered a subluxation of C_1-C_2 with an odontoid fracture. A 3½-year-old fell while running and suffered a fracture of the neural arch of C_2 with subluxation of the inferior articulating facet. The other children had rotary subluxations after falling or somersaulting.

Table 2. Malformation Syndromes with Associated Cervical Spine Abnormalities

SYNDROME	SIGNS	CERVICAL SPINE ABNORMALITIES
Klippel-Feil	Short, webbed neck; low posterior hairline; sensorineural hearing loss	Cervical fusion, cervical ribs
Turner Syndrome	Female; short stature; webbed neck; low posterior hairline; small mandible; epicanthal folds; high arched palate; broad chest, cardiac abnormalities	Cervical hypoplasia
Goldenhar Syndrome	Hyperplasia of malar, maxillary, and mandibular face; ear abnormalities; hearing loss; cleft lip or palate	Cervical fusion, vertebral malformations (including posterior fusion); Chiari malformation
Crouzon Syndrome	Premature craniosynostosis; hypoplasia of maxilla; hypertelorism; proptosis; cleft lip and palate	Cervical fusion; foramen magnum stenosis w/Chiari malformation
Apert's Syndrome	Asymmetric face; proptosis; syndactyly of hands and feet; hypoplastic midface; beak nose; cleft palate	Cervical fusion; progressive calcifications; foramen magnum stenosis
VATER*	Anal atresia; tracheo-esophageal fistula; radial side malformations; renal defects	Cervical defects
Larsen's	Prominent forehead; flat face; hypertelorism; multiple dislocations; cleft palate; kyphosis	
Mucopolysaccharidosis	Coarse features; corneal clouding and other ophthalmologic abnormalities; short stature; hirsutism; hydrocephalus; macroglossia	Joint laxity with cervical instability-(especially MPS type IV); vertebral anomalies
Ehlers-Danlos	Skin hyperelasticity; fragile skin and blood vessels	Cervical ligament instability
Fetal Alcohol Syndrome	Short palpebral fissures; epicanthal folds; maxillary hypoplasia; micrognathia; thin upper lip; cardiac defects; delayed cognitive development	Cervical fusion

* VATER = Vertebral defects, Anal atresia, Tracheo-esophageal fistula with Esophageal atresia, and Radial and renal anomalies.

A general summary of the above data is necessary to give the clinician a sense of the type of impact that may cause a spine injury. Collisions in which a child impacts an object with a closing speed faster than a child can run or more than twice the child's height are greater-risk impacts. This is especially true in situations where the child may initiate contact with the skull, as is common in sports injuries. While falls can result in CSI, the injury-producing falls tend to be higher, or there are extenuating circumstances. One such circumstance occurs when a child falls down stairs with the extra weight of a walker attached. Unfortunately, as demonstrated by one group,[42] these guidelines are not completely reliable, and CSI may result from minimal trauma.

Diagnostic Evaluation

After understanding the epidemiology of CSI and the pertinent anatomy, it is necessary to discuss the appropriate evaluation of the potentially injured child. The evaluation of a child with a potential neck injury involves a clinical and radiographic evaluation.

Clinical Evaluation. When faced with a child who has sustained a traumatic impact, the clinician must determine whether the child is at risk for having sustained a CSI. The clinician must make a decision regarding the need for immobilization of the child and the need to pursue diagnostic radiographic evaluation of the cervical spine. Recent work has narrowed the focus of physical examination findings that are present in adults with CSI.[43,44] Two published series identify low-risk criteria that include a normal physical examination of the neck and no history from the patient of neck complaints. The Canadian group characterized low-risk clinical criteria as being the victim of a low-speed rear end crash, being ambulatory prior to transport, or sitting in the department. The U.S. group included criteria requiring a clear sensorium and absence of a distracting injury (as defined by the treating physician). These clinical criteria did well in excluding the likelihood of an unstable cervical spine fracture in adults.

Unfortunately, there are no data in children to identify low-risk patients who do not require cervical spine radiographic evaluation. The Canadian study did not enroll children. The U.S. study identified 30 children with CSI (none younger than 2 years old, and four children younger than 9 years), and thus, lacks the power to support clinical guidelines. Therefore, while these clinical criteria are very similar to published guidelines and recommendations made after retrospective study of injured children, there are no prospective data to validate these recommendations.[15,25,26,45]

Emergency physicians continuously are faced with injured children and must make decisions regarding immobilization, imaging, and management, despite a paucity of clear criteria to use to evaluate these patients. Therefore, careful clinical judgment and evaluation are required. It is hoped that the emergency physician can refine clinical judgment by reviewing the aggregate of clinical presentations of published series of children with CSIs.

In the 30 pediatric patients with CSI from the U.S. trial, all

Figure 2. Severe Upper Cervical Spine Injury (AO and C_1-C_2)

were not low-risk by clinical criteria.[8] Twenty-one of 25 (five were unable to be evaluated for this criterion) patients had midline neck tenderness. Eleven of 28 had a distracting injury. Only eight of 27 had neurologic findings, while none had SCIWORA.

A retrospective review of 72 patients included information on the neck examination of 61.[22] Thirty had radiographically apparent CSI (RACSI) and 30 had SCIWORA. Sixteen of the 31 (51%) with RASCI reported midline neck tenderness, while 24 of 30 (80%) of those with SCIWORA had midline neck tenderness documented.

One review of 50 children with CSI noted that all 30 of the children awake at the time of ED arrival had neck pain or tenderness.[12] Another author reported the retrospective review of 25 children with CSIs.[23] She reported that the criteria of any history of neck pain or vehicle crash with head injury identified all children with CSI.

The retrospective review of children with low falls described eight children who had CSI after a low fall.[42] All eight patients had neck symptoms at the time of diagnosis. Unfortunately, the time of onset of these symptoms was not reported in the series.

Additionally, the data on SCIWORA reveal that any neurologic symptoms can be markers of SCIWORA. The data from one group report that all 32 patients in that series with SCIWORA had symptoms upon initial presentation, although some were isolated sensory deficits.[22] The data by another author note a percentage of children with SCIWORA that had a normal examination on presentation yet had neurologic deterioration days later.[46,47]

Table 3. Suggestions for Radiographic Evaluation

PRE-VERBAL OR PRE-COOPERATIVE CHILD AT RISK OF CSI

High Risk

- Fall in which the body weight lands on the head
- Head-on motor vehicle crash with child in a forward-facing seat
- Abnormal posture of the head and neck
- Anomaly of the face, head, or neck
- Any suspicion of non-accidental trauma
- Evidence of intracranial injury or significant facial trauma
- High speed, rear-end impact with an infant in a rear-facing seat
- Risky mechanism with distracting pain
- Neck tenderness
- Neurologic deficit
- Fall while in an infant walker

Low Risk

- Head-on motor vehicle crash with child in a rear-facing seat
- Short fall in which impact is evenly distributed between trunk and head
- Unwitnessed short fall with no scalp hematoma or soft-tissue injury
- Lateral impact motor vehicle crash with the child in appropriate restraint and no evidence of intracranial injury or concussion

VERBAL AND COOPERATIVE CHILD AT RISK FOR CSI

- Neck tenderness
- Neurologic abnormality
- Distracting pain with adequate mechanism
- Altered mental status
- High-energy impact involving a child younger than 8 years

In summation, a review of all the significant published series of children with CSI does not identify any criteria or criterion that will assure that a child, especially a pre-verbal or pre-cooperative child, is at low risk of an unstable CSI. Because SCIWORA exhibits a spectrum of presentations, the clinician must maintain diagnostic vigilance in any child with any neurologic symptoms. This is in contrast to the adult, in which one may consider transient, painful, radicular symptoms to be markers of peripheral nerve injury due to neck loading (i.e., the football player with a "stinger").

While noting from the above information that neck tenderness and possibly pain suggest a high-risk group, the converse is not true. How shall the clinician identify a high-risk group deserving radiographic evaluation among those without neck symptoms, those without neurologic symptoms, or those who are pre-verbal or pre-cooperative? The clinician must have a rough idea of the type of impact necessary to cause CSI, especially in the infant and toddler. Table 3 combines an arbitrary definition of high impact with somewhat arbitrary clinical criteria to produce guidelines for identifying children who may need radiographic evaluation of the cervical spine.

Radiographic Evaluation. Once the decision is made to obtain radiographic imaging, what are the appropriate studies to obtain? Authors vary on the routine studies for evaluation of the

Figure 3. C_6-C_7 Ligamentous Injury

Figure 4. C_5 Fracture with Subluxation

A lateral cervical spine radiograph identifies a C_5 fracture with subluxation.

cervical spine. Some authors recommend a lateral view that visualizes the atlanto-occipital joint to the C_7-T_1 joint, an antero-posterior (AP) view, and an open-mouth odontoid in the cooperative patient.[12,48] Others advocate the three-view series for all patients.[10] A recently published survey of 432 pediatric radiologists notes that 40% of responders do not obtain the odontoid view in children younger than 5 years of age.[49] Another 25% only make one attempt at obtaining that view. Older recommendations suggested a five-view series for all patients, which included oblique views in addition to the standard three views.[50]

New data are available that suggest that computed tomography (CT) scanning of the cervical spine may be faster than obtaining plain films, especially in the patient who is to have a post-traumatic CT scan of another body region.[51-53] However, the role and accuracy of this technique have not been defined outside the multiple trauma patient.

The use of flexion-extension (FE) radiographs in evaluating alert trauma patients remains controversial. The FE views are imaging techniques that are used to delineate the endpoints of the patient's active neck flexion and extension that would radiographically identify any ligamentous injury. *(See Figure 3.)* The concern with FE views is that the patient will injure his or her spinal cord during performance of the test. Therefore, the utility of and indications for FE views are not clear. Data by two authors demonstrate that static radiography is adequate to diagnose CSI in 95% of patients.[12,22] *(See Figure 4.)* Three retrospective series suggest that FE films do not identify injuries in patients with normal static radiographic series.[48,54,55] In patients with subtle spine abnormalities, there was some diagnostic value to performing FE radiographs. In the only study of injury caused during FE studies, one patient of 129 had transient tingling in the upper extremities during positioning that resolved spontaneously after relaxation.[48]

When ordering FE radiographs in the trauma patient, it is important to clarify whether the patient demonstrated adequate neck motion (FE) during the study.[56] In case of an inadequate study, a patient should be immobilized pending repeat radiographic evaluation in five days. Providing time for pain and muscle spasm to resolve should allow for a repeat, adequate radiographic study. However, it is unclear how often an FE study is inadequate. Up to one-third of FE radiographs ordered in adults acutely after trauma may be inadequate.[57] These data note that angular motion of approximately 40º is necessary between C_2 and C_7 for an adequate study. There is no clear definition of adequate motion on pediatric FE films. Specifically, the normal degree of tilting and relative motion between vertebral bodies changes throughout childhood. One author has demonstrated that tilting angles during flexion decrease with age at the $C_{2\text{-}3}$ and $C_{3\text{-}4}$ junctions.[2] Extension tilting increases with age at the $C_{4\text{-}5}$ and $C_{5\text{-}6}$ joints. These tilting changes are changes of approximately 3-5º throughout childhood. Sliding motion during flexion decreases with age at the $C_{2\text{-}3}$, $C_{3\text{-}4}$, and

Figure 5. Calculating Powers Ratio

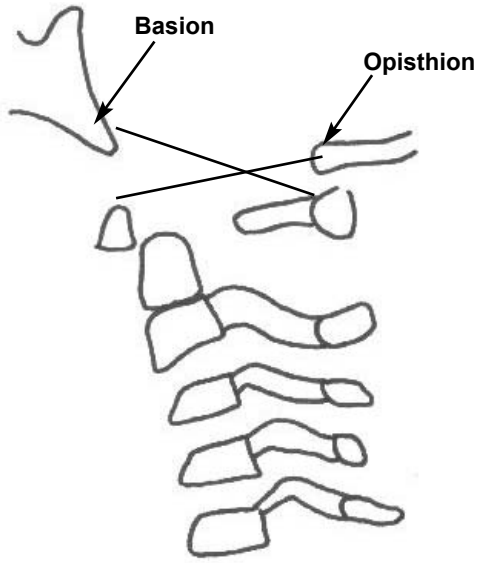

Powers ratio is determined by the ratio of distance from the basion to posterior arch of C_1 to the distance from the opisthion to the anterior arch of C_1.

Figure 6. An AO Injury Diagnosed by Powers Ratio

$C_{4\text{-}5}$ joints. This motion decreases from 18-25% down to 5-10% of vertebral width.

Acute FE magnetic resonance imaging (MRI) may have a role in identifying pediatric operative candidates sustaining ligamentous injury.[58]

Specific Injuries that Occur in Children

Occipitoatlantal Dislocation. The outcome of children with occipitoatlantal dislocation is uniformly poor.[12] This injury usually results from a high-energy impact, as seen in motor vehicle crashes. Examination of the cervical spine radiographs must include assurance of an appropriate relationship between the occiput and the atlas. The distance between the basion and the dens should not exceed 10 mm in children and 5 mm in adults.[59] It is not uncommon for normal patients to exceed these criteria.[60] The Powers ratio can be calculated. The ratio of the distance from the basion to the anterior edge of the posterior arch of the atlas divided by the distance from the opisthion to the posterior portion of the anterior arch of the atlas should be less than 0.9. A ratio greater than 1.0 is abnormal. The Wackenheim clivis line is another technique to inspect for integrity of the atlanto-occipital joint. In this test, a line drawn along the posterior clivus should intersect or be tangential to the odontoid.[61-63] *(See Figures 5 and 6.)*

Atlas Fractures. Burst fractures of the C_1 ring can occur in children, just as in adults. The fracture may occur through the synchondroses, which may remain unfused until age 7.[64] CT scan may assist in securing the diagnosis.

Atlantoaxial Injuries. Authors differ over the relative frequency of transverse ligament injuries compared to dens fractures. Although fractures through the base of the dens do occur at the synchondrosis, transverse ligament tears also are commonly seen. An atlantodens interval of 5 mm may suggest injury to the transverse ligament.

Surprisingly, children with dens fractures frequently are neurologically intact upon presentation. One series quotes seven of 15 children without weakness on presentation. Four of 15 had thoracic level symptoms, and three had low cervical symptoms (C_6 and C_7).[65] Thirteen of the 15 had anterior displacement ranging from 10-100% (mean 40%). One patient had a fracture, C_2 tetraplegia, and no displacement of the dens. Two patients with 20% displacement had a delay in diagnosis of four and six months. Tomograms may show widening of the growth plate not evident on plain radiographs.[7] CT scans require coronal and sagittal plane reconstruction because axial scanning may miss fractures.[66,67] As the growth plates close, it is important not to confuse the epiphyseal scar at the base of the dens with an acute fracture.

Os Odontoideum. Os odontoideum refers to an oval or round ossicle of variable size with a smooth cortical border located in the position of the odontoid process. Authors differ, but suspect that this is an acquired lesion after an undiagnosed odontoid fracture. These lesions commonly are unstable.[68,69]

Hangman's Fracture. Hangman's fracture, or C_2 pedicle fractures, can occur in children with a hyperextension injury, just as with adults. *(See Figure 7.)* The diagnosis of a hangman's fracture may be confused with physiologic subluxation of C_2 on C_3. Evaluating the alignment of the posterior laminar line can assist with clarifying the diagnosis.

Atlantoaxial Rotary Subluxation. Atlantoaxial rotary subluxation may occur spontaneously (Grisel's syndrome) or after minor trauma. The classic clinical presentation is torticollis in the "cock-robin" position, with the head rotated to one side and tilted

Figure 7. Hangman's Fracture

Figure 8. Apparent Anterior Vertebral Wedging

to the other, like a bird listening for a worm.[70] This usually stable injury is truly a pediatric injury, as up to 80% of these injuries occur in children younger than 13 years of age.[71,72] This type of rotary subluxation occurs most frequently at the C_1-C_2 joint, where most of the rotation of the neck occurs. The facets are flatter at this joint than at any other joint.

The diagnosis of rotary subluxation is difficult to secure with plain films alone. The abnormalities seen can be present in patients with torticollis not due to subluxation and in volunteers holding their head in the "cock-robin" position.[7,73,74] CT scanning, with 3D reconstruction, often is necessary to make the diagnosis.

Normal Radiographic Variants Simulating Injury

There are several common variations in the pediatric cervical spine radiograph that may simulate injury. This section will describe the pattern of variation and describe how to distinguish it from pathology.

Pseudosubluxation. Anterior displacement of C_2 on C_3 of up to 4 mm is common in children younger than 7 years, but frequently can be noted in children up to 16 years of age. A line drawn from the anterior cortex of the spinous process of C_1 to C_3 should come within 1.5 mm of the anterior spinous process of C_2. This misalignment may improve with FE views, but certainly isn't exaggerated by FE study. Pseudosubluxation also can occur at the level of C_3-C_4.

Apparent Anterior Vertebral Wedging. Anterior wedging of the vertebral body may be seen on pediatric radiographs. This wedging represents non-uniform calcification of the vertebral body, not an asymmetric shape. Wedging is most common at C_3 and may account for up to 3 mm difference between the anterior and posterior height of the vertebral body. The vertebral bodies should assume an adult shape by age 8. This variant can be noted in Figure 8 at C_3 and C_4.

Overriding Anterior Arch of C_1. Up to two-thirds of the anterior arch of C_1 may override the tip of the dens. This occurs in up to 20% of children younger than 7 years.[75]

Increased Predental Space. The predental space in children can be up to 5 mm. Ligamentous laxity (of the transverse and anterior atlanto-axial ligaments) may allow for an increased gap compared to the adult measurement of 3 mm.

Apical Odontoid Epiphysis. The odontoid tip has an epiphysis that usually is present at age 7, but may persist through age 16.[75,76]

Persistent Synchondrosis of the Dens. The growth plate at the base of the dens persists beyond age 7. This linear scarring may be confused with a fracture. This line is typically linear, occurs in a predictable location, and may have associated sclerosis. A fracture more commonly presents in an unpredictable location without sclerosis and with irregular edges.

Non-uniform Angulation During Flexion. There may be non-uniform angulation between adjacent vertebral bodies during flexion. This may appear as marked flexion at a single joint. Although this can be a normal variant, it is difficult to distinguish from acute trauma in the correct clinical setting.[75]

Asymmetric Odontoid. The odontoid may be centered asymmetrically between the lateral masses of C_1. Ligamentous laxity may cause this variant. While this can be a normal variant, it may be difficult to distinguish from an acute fracture in the correct clinical setting.[77]

Delayed Calcification of Anterior Arch of Axis. The anterior arch of C_1 frequently is not visible on plain film radiographs until 6 months of age. Before this, the axis is calcified insufficiently to be visible radiographically.

Treatment and Disposition

When treating patients with CSIs, emergency medicine physicians must remain focused on three goals. First, the emergency medicine physician must identify all significant injuries, including the CSI. The emergency physician, as the initial physician contact, must keep the complete patient clinical picture in mind to allow subspecialists to concentrate on specific injuries. Second, the emergency medicine physician must take steps to prevent worsening of any neurologic function associated with the spinal cord injury. Basic fundamentals must be addressed to complete this goal. Spinal immobilization of unstable injuries is imperative. Care must be taken during intubation to prevent further cord injury. Identification and treatment of shock is important to maintain adequate perfusion to the injured spinal cord. Finally, the emergency physician must expedite therapy for any CSI and associated spinal cord injury. Adult data suggest that urgent release of spinal cord compression may improve outcome. Urgent MRI may be necessary to identify cord compression. Intravenous steroids may be indicated for treatment of a spinal cord injury.

Steroids in Children. The use of steroids has been advocated for the treatment of patients with acute spinal cord injuries.[78,79] The indication for treatment in the quoted NASCIS trials was "having a spinal cord injury" as defined by study physicians. Approximately 8% of patients had normal neurologic function on enrollment in NASCIS 3.[79] No patient younger than age 14 was enrolled in this series. Patients with gunshot wounds were excluded, but patients with other forms of penetrating trauma were not excluded from study. Outcomes were not reported according to the type of cord injury sustained.

While steroid dosing in adults with acute spinal cord injuries may or may not provide benefit, the benefit and indications of this therapy in young children has not been proven. Centers should establish a consensus for the treatment of children after spinal trauma. Communication between emergency physicians and accepting subspecialists should be done so that all members of the treatment team will have a common understanding when a patient arrives in the ED. Controversy may arise about the treatment of a child with sensory deficits of an isolated cervical level or the treatment of a very young child with an apparently normal neurological examination with an abnormal cervical spine radiograph.

Conclusion

Evaluation of the pediatric patient with a potential CSI is a complicated process. The emergency physician must exercise thoughtful clinical judgment in evaluating a pre-cooperative patient at a low risk of a potentially catastrophic injury. A complete understanding of the pertinent anatomy, radiographic features, and biomechanical tolerance of the pediatric spine is necessary to provide this care.

References

1. Castellana C, Kosa F. Morphology of the cervical vertebrae in the fetal-neonatal human skeleton. *J Anat* 1999;194:147-52.
2. Kasai T, Ikata T, Katoh S, et al. Growth of the cervical spine with special reference to its lordosis and mobility. *Spine* 1996;21: 2067-2073.
3. Manaligod JM, Bauman NM, Menezes AH, et al. Cervical vertebral anomalies in patients with anomalies of the head and neck. *Ann Otol Laryngol* 1999;108:925-933.
4. Ugar DA, Semb G. The prevalence of anomalies of the upper cervical vertebrae in subjects with cleft lip, cleft palate, or both. *Cleft Palate-Craniofacial Journal* 2001;38:498-503.
5. Guille JT, Sherk HH. Congenital osseous anomalies of the upper and lower cervical spine in children. *J Bone Joint Surg* 2002;84: 277-288.
6. Torg JS, Naranja RJ, Pavlov H, et al. The relationship of developmental narrowing of the cervical spinal canal to reversible and irreversible injury of the cervical spinal cord in football players: An epidemiological study. *J Bone Joint Surg* 1996;78:1308-1314.
7. Weinstein SL, ed. *The Pediatric Spine: Principles and Practice.* 2nd ed. Baltimore: Lippincott Williams & Wilkins; 2001:1.
8. Viccellio P, Simon H, Pressman BD, et al. A prospective multicenter study of cervical spine injury in children. *Pediatrics* 2001;108:e20.
9. Brown RL, Brun MA, Garcia VF. Cervical spine injuries in children: A review of 103 patients treated consecutively at a level 1 pediatric trauma center. *J Pediatr Surg* 2001;36:1107-1114.
10. Eleraky MA, Theodore N, Adams M, et al. Pediatric cervical spine injuries: Report of 102 cases and review of the literature. *J Neurosurg* 2000;92:12-17.
11. Kokoska ER, Keller MS, Rallo MC, et al. Characteristics of pediatric cervical spine injuries. *J Pediatr Surg* 2001;36:10-105.
12. Dietrich AM, Ginn-Pease ME, Barkowski HM, et al. Pediatric cervical spine fractures: Predominately subtle presentation. *J Pediatr Surg* 1991;26:995-1000.
13. Bohn D, Armstrong D, Becker L, et al. Cervical spine injuries in children. *J Trauma* 1990;30:463-469.
14. Ruge JR, Sinson GP, McLone DG, et al. Pediatric spinal injury: The very young. *J Neurosurg* 1988;68:25-30.
15. Patel JC, Tepas III JJ, Mollitt DL, et al. Pediatric cervical spine injuries: Defining the disease. *J Pediatr Surg* 2001;36:373-376.
16. Hill SA, Miller CA, Kosnik EJ, et al. Pediatric neck injuries: A clinical study. *J Neurosurg* 1984;60:700-706.
17. Hadley MN, Zabramski JM, Browner CM, et al. Pediatric spinal trauma: Review of 122 cases of spinal cord and vertebral column injuries. *J Neurosurg* 1988;68:18-24.
18. Orenstein JB, Klein BL, Gotschall CS, et al. Age and outcome in pediatric cervical spine injury: 11-year experience. *Pediatr Emerg Care* 1994;10:132-137.
19. Givens TG, Polley KA, Smith GF, et al. Pediatric cervical spine injury: A three-year experience. *J Trauma* 1996;41:310-314.
20. Apple JS, Kirks DR, Merten DF, et al. Cervical spine fractures and dislocations in children. *Pediatr Radiol* 1987;17:45-49.
21. Orenstein JB, Klein BL, Ochsenschlager DW. Delayed diagnosis of pediatric cervical spine injury. *Peds* 1992;89:1185-1188.
22. Baker C, Kadish H, Schunk JE. Evaluation of pediatric cervical

spine injuries. *Am J Emerg Med* 1999;17: 230-234.
23. Rachesky I, Boyce WT, Duncan B, et al. Clinical predictors of cervical spine injuries in children. *Am J Dis Child* 1987;141:199-201.
24. Tarazi F, Dvorak MF, Wing PC. Spinal injuries in skiers and snowboarders. *Am J Sports Med* 1999;27:177-180.
25. Floyd T. Alpine skiing, snowboarding, and spinal trauma. *Arch Orthop Trauma Surg* 2001;121:433-436.
26. Lee KS, Doh JW, Bae HG, et al. Delayed central cord syndrome after a handstand in a child: Case report. *Paraplegia* 1996;34: 176-178.
27. Brown PG, Lee M. Trampoline injuries of the cervical spine. *Pediatr Neurosurg* 2000;32:170-175.
28. Wolfe JM, Anderson R. Human body surfing: A new way to incur injury at spectator events. *Am J Emerg Med* 1997;15:97-98.
29. Schmitt H, Gerner HJ. Paralysis from sport and diving accidents. *Clin J Sports Med* 2001;11:17-22.
30. all-Sebai M, al-Zahrani S. Cervical spinal injuries caused by collision of cars with camels. *Injury* 1997;28:191-194.
31. Russell A, Boop FA, Cherny WB, et al. Neurologic injuries associated with all-terrain vehicles and recommendations for positive measures for the pediatric population. *Pediatr Emerg Care* 1998; 14:31-35.
32. Kadesky KM, Manery C, Blair GK, et al. Cougar attacks on children: Injury patterns and treatment. *J Pediatr Surg* 1998;33:863-865.
34. Joffe M, Ludwig S. Stairway injuries in children. *Pediatrics* 1988; 82:457
35. Chiaviello CT, Christoph RA, Bond GR. Stairway-related injuries in children. *Pediatrics* 1994;94:679-681.
36. Chiaviello CT, Christoph RA, Bond GR. Infant walker-related injuries: a prospective study of severity and incidence. *Pediatrics* 1994;93:974-976.
37. Lyons TJ, Oats RK. Falling out of bed: A relatively benign occurrence. *Pediatrics* 1993;92:125-127.
38. Mayr JM, Seebacher U, Schimpl G, et al. Highchair accidents. *Acta Paediatrica* 1999;88:319-322.
39. Smith GA, Dietrich AM. Garcia CT, et al. Injuries to children related to shopping carts. *Pediatrics* 1996;97:161-165.
41. Greenes DS. Schutzman SA. Clinical indicators of intracranial injury in head-injured infants. *Pediatrics* 1999;104:861-867.
42. Schwartz GR, Wright SW, Fein JA, et al. Pediatric cervical spine injury sustained in falls from low heights. *Ann Emerg Med* 1997;30: 249-252.
43. Hoffman JR, Mower WR, Wolfson AB, et al. Validity of a set of clinical criteria to rule out injury to the cervical spine in patients with blunt trauma. *N Engl J Med* 2000;343:94-99.
44. Stiell IG, Wells GA, Vandemheen KL, et al. The Canadian c-spine rule for radiography in alert and stable trauma patients. *JAMA* 2001; 286:1841-1848.
45. Dormans JP. Evaluation of children with suspected cervical spine injury. *J Bone Joint Surg* 2002;84:124-132.
46. Pang D, Wilberger JE. Spinal cord injury without radiographic abnormalities in children. *J Neurosurg* 1982;57:1114-1129.
47. Pang D, Pollack IF. Spinal cord injury without radiographic abnormality in children—The SCIWORA syndrome. *J Trauma* 1989; 29:654-664.
48. Ralston ME, Chung K, Barnes PD, et al. Role of flexion-extension radiographs in blunt pediatric cervical spine injury. *Acad Emerg Med* 2001;8:237-245.
49. Swischuk LE, John SD, Hendrick EP. Is the open-mouth odontoid view necessary in children under 5 years? *Pediatr Radiol* 2000;30: 186-189.
50. Freemyer B, Knopp R, Piche J, et al. Comparison of five-view and three-view cervical spine series in the evaluation of patients with cervical trauma. *Ann Emerg Med* 1989;18:818-821.
52. Barba CA, Taggart J, Morgan AS, et al. A new cervical spine clearance protocol using computed tomography. *J Trauma* 2001;51: 652-657.
53. Keenan HT, Hollingshead MC, Chung CJ, et al. Using CT of the cervical spine for early evaluation of pediatric patients with head trauma. *Am J Roentgenol* 2001;177:1405-1409.
54. Woods, WA, Brady WJ, Pollock G, et al. Flexion-extension cervical spine radiography in pediatric blunt trauma. *Emerg Radiol* 1998;5: 381-384.
55. Dwek JR, Chung CB. Radiography of cervical spine injury in children: Are flexion-extension radiographs useful for acute trauma? *Am J Roentgenol* 2000;174:1617-1619.
56. Kuhns LR, Strouse PJ. Cervical spine standards for flexion radiograph interspinous distance ratios in children. *Acad Radiol* 2000; 7:615-619.
57. Wang, JC, Hatch JD, Sandhu HS, et al. Cervical flexion and extension radiographs in acutely injured patients. *Clin Orthoped Rel Res* 1999;364:111-116.
58. Weng MS, Haynes RJ. Flexion and extension cervical MRI in a pediatric population. *J Pediatr Orthoped* 1996;16:359-363.
59. Wholey MH, Bruwer AJ, Baker HL. The lateral roentgenogram of the neck. *Radiol* 1958;71:350-356.
60. Powers B, Miller MD, Kramer RS, et al. Traumatic anterior atlanto-occipital dislocation. *Neurosurg* 1979;4:12-17.
61. Abroms IF, Bresnan MJ, Zuckerman JE, et al. Cervical cord injuries secondary to hyperextension of the head in breech presentation. *Obstet Gynecol* 1973;41:369-378.
62. Allen BL, Ferguson RL. Cervical spine trauma in children. In: Bradford DS, Hensinger RN, eds. *The Pediatric Spine.* New York: Thieme Medical Publishers;1985:1.
63. Kewalramani LS, Tori JG. Spinal cord trauma in children, neurologic patterns, radiologic features, and pathomechanics of injury. *Spine* 1980;5:11-18.
64. Galindo MJ, Francis WR. Atlantal fracture in a child through congenital anterior and posterior arch defects: A case report. *Clin Orthop* 1983;178:220-222.
65. Lebwohl NH, Eismont FJ. Cervical spine injuries in children. In: Weinstein SL, ed. *The Pediatric Spine: Principles and Practice.* 2nd ed. Baltimore: Lippincott Williams & Wilkins;2001:1.
65. Odent T, Langlais J, Glorion C, et al. Fractures of the odontoid process: A report of 15 cases in children younger than 6 years. *J Ped Ortho* 1999;19:51-54.
66. Murphey MD, Batnitzky S, Bramble JM. Diagnostic imaging of spinal trauma. *Radiol Clin North Am* 1989;27:855-872.
67. Pathria MN, Petersilge CA. Spinal trauma. *Radiol Clin North Am* 1991;29:847-865.

68. Harris JH Jr, Mirvis SE. *The Radiology of Acute Cervical Spine Trauma* 3rd ed. Baltimore: Williams & Wilkins;1996:421-474.
69. Fielding JW, Hensinger Rn, Hawkins RJ. Os odontoideum. *J Bone Joint Surg Am* 1980;62:376-383.
70. Roche C, Carty H. Spinal trauma in children. *Pediatr Radiol* 2001; 31:677-700.
71. Lukhelc M. Atlanto-axial rotatory fixation. *S Afr Med J* 1996;86: 1549-1552.
72. Mathern G, Batzdorf U. Grisel's syndrome. *Clin Orthop Rel Res* 1989;244:131-146.
73. Kowalski M, Cohen W, Cooper P, et al. Pitfalls in the CT diagnosis of atlantoaxial rotatory subluxation. Am J Neuroradiol 1987;8: 697-702.
74. Kawabe N, Hirotani M, Tanaka O. Pathomechanism of atlantoaxial rotatory fixation in children. *J Pediatr Orthop* 1989;9:569-574.
75. Cattell HS, Filtzer DL. Pseudo-subluxation and other normal variations in the cervical spine in children. *J Bone Joint Surg Am* 1965; 47:1295-1309.
76. Bonadio WA. Cervical spine trauma in children. I. General concepts, normal anatomy, radiographic evaluation. *Am J Emerg Med* 1993;11:158-165.
77. Lee S, Joyce S, Joachim S. Asymmetry of the odontoid-lateral mass interspaces: a radiographic finding of questionable clinical significance. *Ann Emerg Med* 1986;15:1173-1177.
78. Bracken MB, Shepard MJ, Collins WF, et al. A randomized, controlled trial of methylprednisolone or naloxone in the treatment of acute spinal-cord injury. *N Engl J Med* 1990;322:1405-1411.
79. Bracken MB, Shepard MJ, Holford TR, et al. Administration of methyprednisolone for 24 or 48 hours or tirilazad mesylate for 48 hours in the treatment of acute spinal cord injury. *JAMA* 1997; 277:1597-1604.

CE/CME Questions

1. At what age is ossification of the dens usually complete in a pediatric patient?
   A. 1 year
   B. 3 years
   C. 4 years
   D. 5 years
   E. 6-8 years

2. Which of the following increases a child's risk for abnormal cervical spine development?
   A. Neuromuscular diseases
   B. Cerebral palsy
   C. Apert's syndrome
   D. Muscular dystrophy
   E. Rett's syndrome

3. A 4-year-old child presents after falling off a horse and landing on his head. The child has midline cervical pain with a normal neurologic examination. What would be your radiographic recommendation?
   A. No radiographs are necessary
   B. Flexion extension views only
   C. MRI of the spine
   D. Lateral cervical spine radiograph

4. Significant CSI does not occur as an isolated injury.
   A. True
   B. False

5. Which of the following is true regarding occipitoatlantal dislocations?
   A. Outcome usually is poor.
   B. The injury usually results from a high-energy impact.
   C. The Powers ratio is useful for assessing the existence of this type of injury.
   D. The Wackenheim clivus line also may be used to diagnose this injury.
   E. All of the above

6. An atlantodens interval of 5 mm may suggest injury to the transverse ligament.
   A. True
   B. False

7. Which of the following is *not* true regarding flexion extension films in pediatric patients?
   A. There is no clear definition of adequate motion of pediatric flexion extension films.
   B. Up to one-third of adult flexion extension films may be inadequate.
   C. In adults, approximately 40 degrees of motion between C_6 and C_7 is necessary for an adequate film.
   D. Flexion extension films may result in spinal cord injury.
   E. The normal degree of tilting and relative motion between vertebral bodies changes through childhood.

8. A Powers ratio of greater than 1.0 is abnormal.
   A. True
   B. False

9. Which of the following is true regarding Os odontoideum?
   A. It usually is a rectangular-shaped, irregularly margined bone fragment.

CE/CME Instructions

Physicians and nurses participate in this continuing medical education/continuing education program by reading the article, using the provided references for further research, and studying the questions at the end of the article. Participants should select what they believe to be the correct answers, then refer to the list of correct answers to test their knowledge. To clarify confusion surrounding any questions answered incorrectly, please consult the source material. **After completing this activity, you must complete the evaluation form provided and return it in the reply envelope provided in order to receive a certificate of completion.** When your evaluation is received, a certificate will be mailed to you.

B. It usually is located in the position of the odontoid process.
C. It is a congenital lesion.
D. These lesions commonly are stable.

10. Which of the following is *not* true regarding atlantoaxial rotary subluxation?
    A. It usually is associated with major trauma.
    B. Patients classically present with torticollus.
    C. Up to 80% of these injuries occur in children younger than 13 years of age.
    D. The injury most frequently occurs at the C_1-C_2 joint.
    E. The diagnosis may be difficult to make with plain radiographs.

Answer key:

1. E	6. A
2. C	7. D
3. D	8. A
4. B	9. B
5. E	10. A

CME Objectives

Upon completing this program, the participants will be able to:

a.) Quickly recognize or increase index of suspicion for occult spinal trauma in pediatric patients;
b.) Be educated about how to correctly and quickly stabilize, and then to manage, cervical spine trauma;
c.) Understand various diagnostic modalities for cervical spine injuries; and
d.) Understand both likely and rare complications that may occur.

In Future Issues: **Recognizing Child Abuse**