THOMSON
AMERICAN HEALTH CONSULTANTS

Rapid Access Card Enclosed

PEDIATRIC
Emergency Medicine Reports™

The Practical Journal of Pediatric Emergency Medicine

Volume 8, Number 8 August 2003

Emergency department (ED) physicians are inundated with wheezing children, especially as the incidence of asthma increases. It becomes very easy to place all these children into the same category and approach them diagnostically and managerially in the same manner. As ED physicians, our first instinct is to act, but certain children should provoke a careful evaluation for an underlying process and a concern that all is not as it seems. Children with atypical histories, concerning physical examinations, or unusually protracted or recurrent disease should provoke an initial evaluation for underlying pathology and close follow-up. Although the final definitive diagnosis may not be ascertained in the ED, the recognition of a high-risk child may avert disaster if the child has a previously undiagnosed congenital abnormality. ED physicians are experts at differentiating the expected from the unusual, and this skill is important when evaluating the young child with first-time, persistent, or protracted wheezing.

— The Editor

Wheezing in Children Younger than 3: Differential Diagnosis and Initial Approach to Management

Authors: **Karin M. Hillenbrand, MD,** Assistant Professor, General Pediatrics, Department of Pediatrics, Brody School of Medicine at East Carolina University, Greenville, NC; and **Ronald M. Perkin, MD, MA,** Professor and Chairman, Department of Pediatrics, Brody School of Medicine at East Carolina University, Greenville, NC.

Peer Reviewer: **Mark S. Mannenbach, MD,** Division Head, Pediatric Emergency Medicine, Mayo Medical Center, Rochester, MN.

Wheezing is a common presenting complaint for the ED physician. The most frequent etiology of wheezing in childhood is asthma, which is estimated to account for 16.9% of annual ED visits by children.[1] The evaluating physician must, however, consider a broad array of diagnoses in the wheezing pediatric patient. *(See Table 1.)* This particularly is true when faced with the child younger than 3 years of age, who is more likely than the older child to be wheezing for the first time and for whom congenital anomalies gain relative importance in the differential diagnosis. The approach to the young, wheezing child begins with a thorough history and physical, that in many cases will narrow the differential diagnosis to several etiologies. Appropriately selected studies further can elucidate the diagnosis. Regardless of the etiology, wheezing may be associated with respiratory distress, and the emergency medicine physician must be prepared to rapidly stabilize and provide definitive management of these children.

Pathophysiology

Wheezing is a high-pitched, continuous, adventitious lung sound. The net positive pressure in the chest during expiration compresses the intrathoracic airways; therefore, wheezing is initially an expiratory phenomenon. The wheezing sound is generated as the walls of the airways oscillate in response to the acceleration of gas flow through a narrowed lumen.[2] Wheezing implies obstruction of the intrathoracic airways, and should be distinguished from stridor, a primarily inspiratory sound that occurs with diseases that affect the extrathoracic airway.[3]

Wheezes can be described as monophonic (sounding the same everywhere) or polyphonic (having a variety of pitches). Monophonic wheezes emanate from the large, central airways, while polyphonic wheezes are characteristic of small and medium-sized airway obstruction. Polyphonic wheezes are placed more peripherally and vary in pitch, depending on location.

A common misconception is that wheezing occurs only with obstruction of the bronchioles and peripheral airways. However, obstruction of the intrathoracic trachea or bronchi also can result in wheezing because the expiratory compression forces are generated throughout the chest cavity.[2] Intrathoracic airway diseases that result in wheezing can therefore be thought of as falling into two physiologically distinct groups: diseases of the large airways and diseases of the small airways.[3,4] Uncomplicated large airway obstruction usually does not cause hypoxemia; the wheezing patient with a new oxygen requirement is likely to have a small airway component that induces hypoxemia through ventilation-perfusion mismatch. Table 2 differentiates common causes of large vs. small airway obstruction.

Airflow through the airway lumen may be impeded by intraluminal obstruction or extrinsic compression of the airway. In infants, intraluminal obstruction is more common. This intraluminal obstruction can result from bronchoconstriction, airway collapse, edema, or accumulation of mucus, depending upon the underlying disease.

Inflammation plays a central role in the development of intraluminal obstruction in many wheezing disorders, including asthma, infection, irritant or hypersensitivity reaction, and disorders related to aspiration. The release of inflammatory mediators leads to edema of the airway and bronchial smooth muscle contraction. Early mediators are those released from the mast cell, including histamine, leukotrienes, and platelet-activating factor, as well as proteases.[5] Chemotactic factors, which recruit additional inflammatory cells to the site, include the interleukins, RANTES (regulated upon activation, normal T-cell expressed and secreted), and eotaxin.[3] Activated helper T-cells in the airway release a variety of cytokines that enhance the inflammatory response. Late mediators are those released by inflammatory cells such as macrophages, lymphocytes, and eosinophils.

Infants and young children are at higher risk for obstruction of the tracheobronchial tree and wheezing than older children and adults.[3] One reason for this is the small caliber of the infantile airway. Poiseuille's law states that resistance to airflow varies inversely with the fourth power of the lumen radius. Thus, equal narrowing, whether by intraluminal or extraluminal factors, leads to a greater degree of resistance in the smaller airway of the young child.

Another factor that places infants and young children at increased risk for wheezing is the ultracompliant bronchial cartilage of their airways, which tends to collapse, resulting in premature closure of the intrathoracic airways with expiration. Additionally, histopathologic studies of infant lungs have revealed the absence of pores of Kohn and canals of Lambert.[2] These structures, found in mature lungs, help maintain ventilation of the alveoli via collateral routes. The absence of these structures contributes to the susceptibility of infantile airways to obstruction and explains why apparently small alterations in an

Pediatric Emergency Medicine Reports™ (ISSN 1082-3344) is published monthly by Thomson American Health Consultants, 3525 Piedmont Road, N.E., Six Piedmont Center, Suite 400, Atlanta, GA 30305. Telephone: (800) 688-2421 or (404) 262-7436.

Vice President/Group Publisher: Brenda Mooney
Editorial Group Head: Valerie Loner
Managing Editor: Allison Mechem
Marketing Manager: Schandale Kornegay

GST Registration No.: R128870672

Periodicals Postage Paid at Atlanta, GA 30304.

POSTMASTER: Send address changes to ***Pediatric Emergency Medicine Reports***, P.O. Box 740059, Atlanta, GA 30374.

Back issues: $60.
Missing issues will be fulfilled by customer service free of charge when contacted within one month of the missing issue's date.

Subscriber Information

Customer Service: 1-800-688-2421
Customer Service E-Mail Address:
customerservice@ahcpub.com
Editorial E-Mail Address: allison.mechem@ahcpub.com
World-Wide Web page: http://www.ahcpub.com

Subscription Prices

1 year *with* 30 ACEP, AMA, or AAP Category 1 credits: $359.

Multiple copies:
One to nine additional copies: **$323 each;**
10 or more additional copies: **$287 each.**

Resident's Rate: **$179.50**

All prices U.S. only. U.S. possessions and Canada, add $30 postage plus applicable GST. Other international orders, add $30.

Accreditation

Pediatric Emergency Medicine Reports™ continuing education materials are sponsored and supervised by Thomson American Health Consultants. Thomson American Health Consultants (AHC) designates this educational activity for a maximum of 30 hours in category 1 credit toward the AMA Physician's Recognition Award. Each physician should claim only those credits that he/she actually spent in the activity.

This CME activity was planned and produced in accordance with the ACCME Essentials.

Pediatric Emergency Medicine Reports is also approved by the American College of Emergency Physicians for 30 hours of ACEP Category 1 credit. This continuing medical education activity has been reviewed by the American Academy of Pediatrics and is acceptable for 30 AAP Credit hours. These credits can be applied toward the PREP Education Award available to Fellows and Candidate Fellows of the American Academy of Pediatrics.

Thomson American Health Consultants is accredited by the Accreditation Council for Continuing Medical Education to sponsor continuing medical education for physicians.

THOMSON
AMERICAN HEALTH CONSULTANTS

Questions & Comments
Please call **Allison Mechem,** Managing Editor, at (404) 262-5589, or E-mail allison.mechem@ahcpub.com.

Statement of Financial Disclosure

Thomson American Health Consultants does not receive material commercial support for any of its continuing medical education publications. In order to reveal any potential bias in this publication, and in accordance with Accreditation Council for Continuing Medical Education guidelines, we disclose that Drs. Hillenbrand and Perkin (authors), and Mannenbach (peer reviewer) report no consultant, stockholder, speaker's bureau, research, or other financial relationships with companies having ties to this field of study. Dr. Dietrich, editor-in-chief, also reports no consultant, stockholder, speaker's bureau, research, or other financial relationships with companies having ties to this field of study.

Table 1. Differential Diagnosis of Wheezing in Infants and Young Children

REACTIVE AIRWAY DISEASE	
• Atopic asthma	• Recurrent, virally mediated wheezing
INFECTION	
• Viral bronchiolitis	• Pneumonia (viral, chlamydia)
IRRITANT OR HYPERSENSITIVITY	
• Environmental toxin	• Environmental allergen
• Food- or drug-induced hypersensitivity	• Infection (visceral larva migrans, allergic bronchopulmonary aspergillosis)
ASPIRATION	
• Dysfunctional swallowing	• Tracheoesophageal fistula
• Laryngeal cleft	• Gastroesophageal reflux disease
• Foreign body aspiration	
DEVELOPMENTAL ABNORMALITY	
• Tracheobronchomalacia	• Tracheal or bronchial stenosis
• Laryngeal web	
CHRONIC LUNG DISEASE	
• Bronchopulmonary dysplasia	• Cystic fibrosis
IMMUNODEFICIENCY	
• Ciliary dyskinesia	• Primary humoral immunodeficiency
• Human immunodeficiency virus	
EXTRINSIC COMPRESSION	
• Vascular ring, aberrant vessel	• Mediastinal mass, lymph nodes
	• Pulmonary cyst
CARDIAC ABNORMALITY	
• Congestive heart failure	• Cardiomegaly

Table 2. Intrathoracic Large Airway Obstruction vs. Small Airway Obstruction

LARGE AIRWAY OBSTRUCTION	SMALL AIRWAY OBSTRUCTION
Tracheal Obstruction	• Asthma
• Tracheomalacia	• Bronchiolitis
• Repaired tracheoesophageal fistula	• Cystic fibrosis
• Complete tracheal rings	• Bronchopulmonary dysplasia
• Tracheal hemangioma	• Primary ciliary dyskinesia
• Mediastinal mass	• Bronchiolitis obliterans
• Tracheal stenosis	• Aspiration
Bronchial Obstruction	- Gastroesophageal reflux disease
• Bronchomalacia	- Swallowing dysfunction
• Bronchial stenosis	- Malformations
• Foreign body	◦ Tracheoesophageal fistula
• Hilar adenopathy	◦ Laryngeal cleft
• Vascular slings	
• Bronchogenic cyst	
• Cardiomegaly	
• Pulmonary artery dilatation	
• Mediastinal mass	

infant's lung mechanics can lead to wheezing and respiratory distress.

Lung hyperinflation is a common finding in the wheezing, distressed infant or child. Increased airway resistance results in prolongation of the time necessary for the lung to empty. The tachypneic infant inspires before the lungs have returned to functional residual capacity (FRC), thus "stacking" breaths and resulting in air trapping. This air trapping leads to hyperinflation, which can be detected by physical examination and radiography.

Lung hyperinflation causes displacement of the diaphragm away from the chest wall. Though usually described as a "sheet of muscle," the diaphragm more accurately is described as a piston. The costal fibers, which perform most of the work of the diaphragm, run parallel to the chest wall. With the diaphragm in its normal position, the net vector of force is parallel to the chest wall and the chest does not experience inward traction. However, hyperinflated lungs push the diaphragm away from the chest wall (a "flattened diaphragm"); when the costal fibers now shorten, they pull inward on their insertion at the bottom of the ribcage and cause a perceptible indrawing of the lower edge of the compliant ribcage of infants. In this situation, much of the diaphragmatic work goes to chest wall distortion and not to tidal ventilation. The infant diaphragm is more susceptible to fatigue than the diaphragm of an older child or adult, because the growth and development of the skeletal muscles of infants is incomplete, especially in infants born prematurely, and the proportion of fatigue-resistant fibers is less than that found in the adult diaphragm.[6,7]

Differential Diagnosis

Although the differential diagnosis of wheezing in young children is extensive, most wheezing in young children is attributable to asthma. *(See Table 1.)* The 1997 Expert Panel Report of the National Asthma Education and Prevention Program describes asthma as a chronic inflammatory disorder that presents with recurrent episodes of wheezing, breathlessness, and coughing, particularly at night or in the early morning; episodes are associated with variable degrees of airflow obstruction that is reversible spontaneously or with treatment.[8] More than half of all cases of persistent asthma begin before the age of 3 years, and 80% have symptoms before the age of 5 years.[9-11] Features consistent with asthma include the presence of an identifiable trigger such as upper respiratory infection (URI), a family history of asthma or allergies, and a response to bronchodilators and to corticosteroids.[9]

In infants and young children, the distinction between asthma and transient, virally induced wheezing may be difficult to make. The term "reactive airway disease" is sometimes used to refer to the collection of wheezing diseases in young children who are

Figure 1. Pneumonia.

Radiograph of a child with a lobar consolidation most likely of a bacterial etiology.

responsive to bronchodilator therapy, but for which a clear diagnosis of asthma has not yet been made. The term generally encompasses both atopic asthma and wheezing that is associated with viral illness. Further difficulty in distinguishing the entities occurs because viral infection is a frequent trigger for acute exacerbations of asthma both in children and adults. The presence of other atopic disease in the child or family, and evidence of sensitization to allergens, favors a diagnosis of asthma that is likely to persist. In most cases, children with recurrent wheezing have asthma; delay in making the diagnosis may lead to inadequate or inappropriate preventative therapy.

Bronchiolitis is a very common cause of wheezing in infants younger than 18 months of age; the peak incidence is between 1 month and 6 months. The etiology is viral, with respiratory syncytial virus (RSV) causing more than half of cases; other causes include parainfluenza virus and adenovirus.[12-14] Symptoms result from obstruction of the small airways due to edema, accumulation of mucus, and bronchospasm.[12] RSV-induced wheezing occurs most commonly in winter and early spring, and begins as a mild URI with rhinorrhea and sneezing. Fever is not uncommon early in the illness. Symptoms progress to involve the lower airways, with gradually worsening respiratory distress, wheezing, cough, irritability, and poor feeding. The physical examination typically reveals tachypnea with scattered fine rales and expiratory wheezing. Intercostal and subcostal retractions are common, and infants may be hypoxemic. Serious secondary bacterial infections are rare, but otitis media may occur. In very young infants, bronchiolitis may be complicated by apneic spells early in the course of the disease, particularly in children younger than 1 month. Chest radiographs, if done, usually reveal hyperinflation and scattered areas of atelectasis. The causative viral agent can be detected in nasopharyngeal secretions by antigen detection tests or by culture. Infants with underlying chronic illnesses, including congenital heart disease, bronchopulmonary dysplasia, immunodeficiency disorders, or cystic fibrosis (CF), are likely to have more serious illness than previously healthy term infants.[12]

Pneumonia in the infant or young child typically is a diffuse process that is viral in etiology.[14] The most common etiologic agents are influenza, parainfluenza, and adenovirus. Classic lobar pneumonia, which usually is bacterial in origin, does not commonly cause wheezing.[15] *(See Figure 1.)* Atypical organisms like *Chlamydia pneumoniae* and *Mycoplasma pneumoniae* may cause wheezing and diffuse pneumonia in school-age children, but these infections are uncommon in children younger than 3 years of age. Regardless of etiology, fever, cough, and rales often are more prominent findings than wheezing in children with pneumonia. An important etiology of pulmonary infection in very young infants is *Chlamydia trachomatis*. Infants acquire this infection perinatally from infected mothers, and may have a history of conjunctivitis within several weeks of birth. Up to 20% of perinatally infected infants develop pneumonia between 3 weeks and 3 months of age. Infection of the lower respiratory tract with *C. trachomatis* results in an afebrile pneumonia characterized by a repetitive "staccato" cough, tachypnea, and rales or occasionally wheezing.[16]

Environmental irritants such as tobacco smoke, smoke from heating sources, and fumes from cleaners and pesticides are an important and often overlooked cause of wheezing in infants and young children.[17] Affected infants may display symptoms that wax and wane as they move between home and other environments. Environmental tobacco smoke exposure is not only a trigger for recurrent episodes of wheezing in predisposed infants and children, but also may be associated with an increased prevalence of asthma.[18]

Hypersensitivity is a more common cause of wheezing in adults than children, but may occur as a result of an IgE-mediated food allergy (most commonly to milk, soy, peanuts, fish, or shellfish), or in association with environmental molds or cockroach antigen. Symptoms typically occur immediately after exposure to the offending allergen. Hypersensitivity to an infectious agent occurs with visceral larva migrans and with allergic bronchopulmonary aspergillosis. Though hypersensitivity as a primary cause of wheezing is uncommon in young children, allergens frequently are implicated as the trigger for recurrent episodes of wheezing in young children with asthma and other chronic pulmonary diseases.

Figure 2. Aspiration Pneumonia

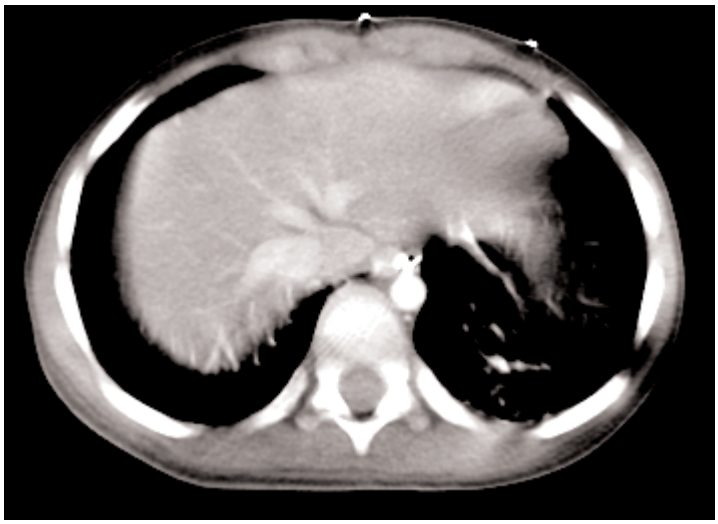

Computed tomography scan of the chest of a child with aspiration pneumonia.

Table 3. Clinical Symptoms of Patients with Foreign Body Aspiration

SYMPTOM	PERCENTAGE
Choking	90
Paroxymal cough	81
Tachypnea	81
Stridor	71
Decreased air entry	67
Wheezing	50
Fever	29
Cyanotic episode	11

Modified from: Sehgal A, Singh V, Chandra J, et al. Foreign body aspiration. *Indian Pediatrics* 2002;39:1006-1010.

Aspiration of food, stomach contents, or foreign objects represents an important cause of wheezing in infants and young children. Respiratory symptoms associated with feeding and that began soon after birth suggest dysfunctional swallowing, gastroesophageal reflux disease (GERD), or rarely, an H-type tracheoesophageal fistula (TEF) or laryngeal cleft. Dysfunctional swallowing with associated aspiration occurs with increased frequency in children with developmental delays, neuromuscular abnormalities, and cleft palate. *(See Figure 2.)*

Of the many disorders associated with mucosal inflammation of the lower airway, GERD is one of the most common.[19,20] GERD is thought to produce wheezing through two different mechanisms. Reflux of gastric contents into the esophagus leads to stimulation of vagal nerve endings in the distal esophagus, and results in cholinergic-mediated bronchoconstriction. Wheezing may also occur secondary to recurrent microaspiration of gastric contents, with resultant mucosal inflammation.[9] Affected infants often have a history of spitting or emesis following feeds, and may be irritable because of chronic esophagitis. Many investigators report an increased incidence of GERD in patients with chronic wheezing, although it is difficult to decide whether GERD is the cause or consequence of wheezing.[19,20] Aggressive treatment of GERD in patients with persistent wheezing often improves their respiratory status, suggesting that GERD at least partially is responsible for the wheezing.[20]

In the mobile infant or toddler, sudden onset of coughing, choking, or wheezing without associated viral symptoms should raise suspicion for foreign body aspiration (FBA), which is a common cause of morbidity and mortality in children between 18 months and 3 years.[21-23] Inhalation of a foreign body into the respiratory tract may result in an acute life-threatening obstruction. More than 300 deaths per year in the United States occur as a result of FBA. Undiagnosed, retained foreign bodies may cause serious complications, including pneumonia, wheezing, bronchiectasis, and atelectasis. A high index of suspicion generally is required to avoid significant morbidity and mortality. The symptoms and signs can be confused with those of asthma, and the roentgenographic findings with those of asthma or pneumonia. Common clinical features of FBA are listed in Table 3. The triad of wheezing, paroxysmal cough, and decreased air entry, considered to be highly suggestive of FBA, is seen in only 35-40% of cases.[21]

Nuts are the most frequently inhaled foreign bodies in the United States, but seeds, including watermelon and sunflower seeds, also commonly are reported.[21,24] Aspiration of an organic foreign body typically results in a worse clinical outcome than aspiration of an inorganic foreign body for a number of reasons. The elapsed time from aspiration to diagnosis is significantly shorter for children with inorganic vs. organic FBA. Aspirated organic foreign bodies may swell with bronchial secretions causing increasing obstruction, and they are known to initiate surrounding tissue reactions, which may cause inflammatory changes in the airways.[23] During bronchoscopy, organic foreign bodies may be dispersed as smaller fragments in distal branches of the airway.[24,25] One-fourth of patients who are not diagnosed within the first 24 hours develop respiratory symptoms such as cough or wheezing that are persistent following bronchoscopic removal of the organic foreign body. Duration of symptoms varies from 1 month to 3 years.[24]

Tracheomalacia and bronchomalacia are disorders commonly seen in tertiary pediatric respiratory practice.[26-28] These disorders are characterized by a defect in the amount or composition of the airway cartilage. The affected segment(s) of the airway tend to collapse during exhalation, resulting in wheezing and air trapping. The defect can be congenital, or acquired from an infectious, mechanical, or other insult to the airway.[4] The lesion often is diffuse and best described as tracheobronchomalacia (TBM).

These disorders of the large airways are associated with varying combinations of cough, wheeze, and stridor. Patients with malacia disorders tend to be noisy breathers early in life and have prominent chest congestion with colds. The parents of

Table 4. Common Mediastinal Masses, by Anatomic Location

ANTERIOR MEDIASTINUM
- Thymic hyperplasia
- Hemangioma
- Lymphangioma
- Teratoma
- Lymphoma

MIDDLE MEDIASTINUM
- Lymphoma
- Lymphadenopathy
- Bronchogenic cyst

POSTERIOR MEDIASTINUM
- Neuroblastoma
- Ganglioneuroblastoma
- Duplication cyst

patients with tracheomalacia and bronchomalacia often describe their infants as being "born with a cold," because the infants have chronic airway noisiness that mimics the congestion heard in URIs.

The spectrum of disease in tracheomalacia and bronchomalacia ranges from that which is life-threatening and requires major diagnostic and surgical intervention to mild cases that can be managed with observation and parental reassurance.[26,27] The typical course for an infant with TBM is gradual improvement over time, with complete resolution of symptoms between the ages of 1 and 5 years. Rarely, newborns or infants with TBM will develop a life-threatening pattern of "dying spells" in which complete airway obstruction takes place. These infants require intubation and positive pressure ventilation.[3]

Important chronic lung diseases that present as wheezing in infancy and early childhood include bronchopulmonary dysplasia (BPD) and CF. BPD typically occurs in premature infants with prolonged exposure to mechanical ventilation and oxygen.[29] Symptoms are exacerbated during viral infections. The disease gradually improves with increasing age and size of the infant. CF may present as wheezing and/or tachypnea that is persistent or recurrent in infancy. The presentation of CF is extremely variable and may include respiratory symptoms, poor growth, recurrent infections, or gastrointestinal symptoms with malabsorption.

Infants with recurrent episodes of wheezing in association with pneumonia, sinusitis, or other infections may have an immunodeficiency. Considerations include human immunodeficiency virus (HIV), humoral immunodeficiencies, and ciliary dyskinesia (the immotile cilia syndrome).

Although airway narrowing related to intraluminal obstruction is the most frequent cause of wheezing in infants and young children, extrinsic compression of the airways by adjacent structures requires mention. Important sources of extrinsic compression include vascular malformations, mediastinal masses, and cardiac disease. The specific source can be acquired, or may be present at birth.

Vascular malformations are potentially life-threatening causes of wheezing in infancy. An aberrant innominate/subclavian artery is a common vascular anomaly resulting in airway compression.[30,31] Malformation of the aortic arch can result in a complete or partial ring that constricts the trachea.[32] A double aortic

Figure 3a and 3b. Mediastinal Mass

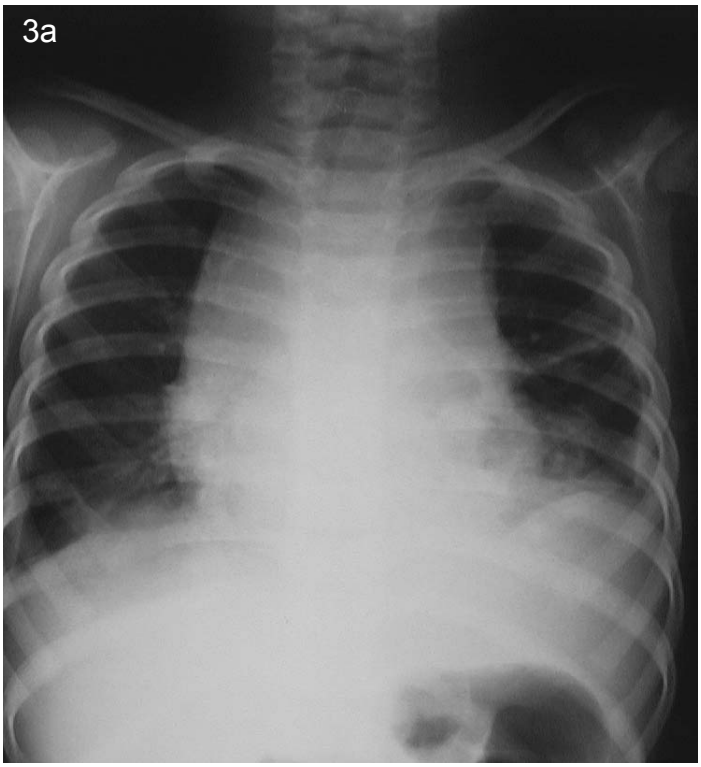

Chest radiographs of a child who presented with stridor and was diagnosed with a mediastinal mass.

Figure 4. Infant with Cardiomegaly

Radiograph of a 7-week-old who presented to the emergency department with wheezing and cyanosis. Chest x-ray shows hyperinflation, pulmonary edema, and cardiomegaly.

Figure 5. Echocardiogram of a Child with an Anomalous Left Coronary Artery

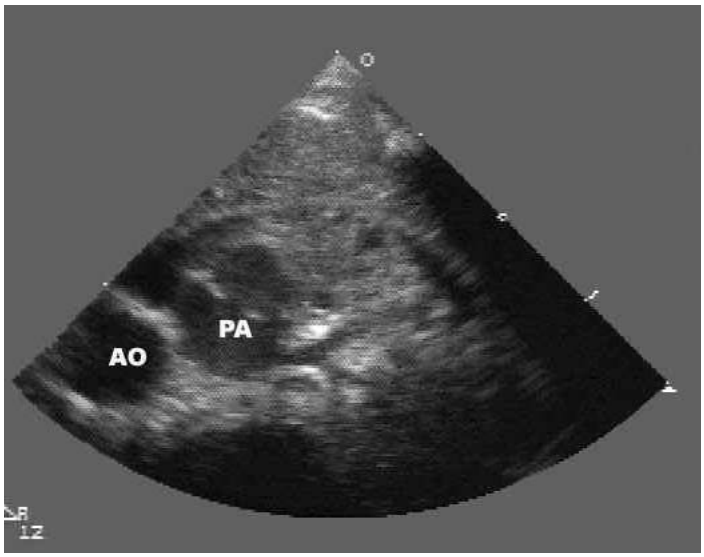

Echocardiogram done on admission shows the origin of the left coronary artery from the pulmonary artery (PA). AO indicates the aorta.

arch is the most common type of complete vascular ring. Infants with vascular rings usually present with respiratory symptoms in the first six months of life.

Extraluminal intrathoracic airway narrowing may result from mediastinal sources.[33] Masses that occur in the mediastinum of infants and children include a heterogeneous group of congenital, neoplastic, and infectious causes. *(See Table 4.)* The mediastinum is divided into anterior, middle, and posterior compartments; most masses arise from normal mediastinal structures within a compartment, and there is a remarkable predilection for the mass to remain localize in the compartment of the structure from which it arose. Therefore, when a mediastinal mass is identified, localization to one of the three compartments aids in the differential diagnosis. *(See Figure 3a and 3b.)*[33]

The vast majority of children with mediastinal masses are symptomatic, and the frequency of symptoms is increased in children younger than 2 years and in those with malignant tumors. The clinical presentation is related to the patient's age and the nature and anatomic location of the mass. Cough, respiratory distress, and neurologic manifestations are among the most commonly reported symptoms. In patients who are asymptomatic, many of the lesions are discovered incidentally during radiographic evaluation for other purposes.

Cardiac disease is an uncommon but important cause of wheezing in infancy. Wheezing may be the presenting symptom of congenital heart disease for infants with congestive heart failure, or may occur in association with cardiomegaly because of external compression of the airways by an enlarged heart. The infant usually has other signs of cardiac dysfunction, such as sweating, pallor, difficulty with feedings, and poor weight gain. In addition to wheezing, the physical examination may reveal crackles, a heart murmur, and hepatosplenomegaly. Cardiomegaly may be demonstrated with chest radiography. *(See Figure 4.)* The definitive diagnosis, however, usually results from echocardiography *(See Figure 5.)*.[34]

Clinical Features

A careful history and physical examination can provide clues to the most likely diagnoses and clarify priorities for evaluation. Characteristic clinical findings for selected diagnoses in the differential are presented in Table 5.

• **Clarify the age at onset and the pattern of wheezing.** Recurring or persistent wheezing starting at or soon after birth suggests a diagnosis other than asthma or bronchiolitis; considerations include congenital abnormalities, perinatal infections, CF, or chronic lung disease of prematurity (e.g., BPD).[9,35,36] Congenital abnormalities affecting the respiratory tract include TBM, TEF, vascular rings, airway stenosis, and webs. Wheezing associated with congenital heart defects also frequently presents in the newborn period, especially in children younger than 8 weeks of age. Recurrent aspiration from GERD or dysfunctional swallowing also might present at this time. Wheezing from CF may be present from birth and most commonly persists during the first year of life.[36] Wheezing associated with prematurity and BPD usually is present at discharge from the nursery, and gradually improves with age and size, though infants may have wors-

Table 5. Clinical Features and Diagnostic Studies for the Wheezing Child

DIAGNOSTIC CONSIDERATION	CLINICAL CLUES	DIAGNOSTIC TESTS TO CONSIDER
Asthma	• Presence of other atopic disease, especially eczema • Family history of asthma, atopic disease	• Peripheral blood eosinophilia, elevated serium IgE, positive skin prick tests are consistent but not diagnostic.
Bronchiolitis	• Infants < 18 months • Fall or winter • URI symptoms, rales	• Nasopharyngeal (NP) washing for rapid antigen tests or viral culture
Pneumonia	• Usually viral • Fever, cough, rales • Tachypnea	• Chest radiograph • Complete blood count • NP—rapid antigen test or culture
Hypersensitivity or irritant	• Environmental exposure to tobacco smoke, mold, cockroach antigen, dust, fungi, others	
Dysfunctional swallowing	• Developmental disability; neuromotor weakness; craniofacial abnormality • Choking, coughing with feeds • Recurrent pneumonia	• Videofluoroscopic evaluation of swallow
Tracheoesophageal fistula	• Cough, cyanosis during feeding • Recurrent wheeze or pneumonia	• Barium esophagram/fluoroscopy • Endoscopy/bronchoscopy
Gastroesophageal reflux	• Emesis or irritability with feeds	• pH probe • Radionuclide milk scan • Endoscopy
Foreign body aspiration	• More common in toddlers than in infants • Sudden onset of choking, wheezing, or cough followed by recurrent wheezing, persistent cough, or recurrent pneumonia • May have asymmetric wheeze or decreased breath sounds	• Inspiratory/expiratory chest radiographs • Bilateral decubitus chest radiographs • Chest exam under fluoroscopy • Bronchoscopy
Tracheobronchomalacia	• May have associated stridor • Symptoms may increase with agitation and when supine	• Airway fluoroscopy • Laryngoscopy/bronchoscopy
Bronchopulmonary dysplasia	• History of prematurity and intubation/ventilation	
Cystic fibrosis	• Gastrointestinal, respiratory, infectious, and/or growth problems	• Sweat chloride analysis
Vascular ring/aberrant vessel	• Presents in early infancy • Stridor, cough are prominent symptoms • Symptoms increase with feeding, agitation, position change • Minimal response to bronchodilators	• Barium esophagram
Mediastinal mass	• Progressively worsening cough, dyspnea, chest pain, or stridor • Systemic symptoms: fever, malaise, weight loss	• Chest radiograph • Computed tomography, magnetic resonance imaging
Cardiac abnormality	• Tires with feeding • Abnormal cardiac exam • Hepatomegaly; rales; tachycardia, tachypnea	• Radiograph • Echocardiogram

Adapted with permission from Fausnight TB, Gentile DA, Skoner DP. Determining the cause of recurrent wheezing in infants. *Journal of Respiratory Diseases for Pediatricians* 2002;4:126-131.

ening symptoms associated with viral infections, especially in the first year of life. Viral bronchiolitis is most common in the first year of life, and is especially common in infants 1-6 months of age who present with a first episode of wheezing. Wheezing from bronchiolitis rarely lasts longer than four weeks. Sudden onset of first-time wheezing in an older infant or toddler should prompt investigation for aspiration of a foreign body.

Recurrent episodes of wheezing in the first 3 years may represent multiple isolated episodes of virally mediated bronchospasm, or may herald a diagnosis of asthma. An attempt should be made to distinguish between recurrent episodes of wheezing triggered by repeated acute URIs, and chronic wheezing associated with underlying pathology. Examinations of previous ED records over time, including during times when the child is asymptomatic, may clarify the severity and chronicity of lung disease.[36]

• **Identify other pulmonary complaints besides wheezing.** Cough may be a more prominent symptom than wheeze with aspiration syndromes, including FBA, as well as with chlamydial pneumonia and CF.[35] The presence of inspiratory stridor suggests an upper airway extrathoracic component of obstruction and is often noted with laryngomalacia, TBM, or a vascular ring.

• **Investigate the association of symptoms with feeding.** An infant with congestive heart failure becomes increasingly breathless or tires easily when fed. Infants with airway abnormalities such as TBM or a vascular ring may have worsening stridor or wheeze during a feed. Coughing, choking, or noisy breathing during or soon after a feed suggests aspiration from dysfunctional swallowing, a TEF, or GERD. Infants with GERD also may have a history of frequent emesis or irritability, especially after feeding or when laid down. Wheezing after food ingestion may also be a clue to allergen-induced food allergy, which can occur with or without gastrointestinal or skin symptoms.[37]

• **Ask about symptoms of current or recurrent infection.** Recent symptoms of a URI in an infant with a first-time wheeze suggests bronchiolitis; URI also may trigger recurrent wheezing in children with asthma. The presence of fever suggests an acute infection; viral infection is more common than bacterial in this age group, but fever should prompt a search for a coexisting bacterial infection. In the majority of cases, a coexisting bacterial disease will not be identified. Fever may accompany bronchiolitis or pneumonia, but absence of rales makes viral or bacterial pneumonia less likely. A history of recurrent pneumonia or other infections should raise a concern for immunodeficiency diseases, including HIV. Children with recurrent pneumonia also should be evaluated, initially by history and physical exam, for recurrent aspiration.[38] A history of neonatal conjunctivitis increases the possibility of perinatal infection with chlamydia.

• **Identify the trigger for the current episode of distress, especially for children with a known history of asthma or recurrent wheezing.** URI is the most common precipitant of wheezing in children younger than 5 years.[8] Environmental factors that may trigger wheezing include environmental tobacco smoke, fumes from household cleaners, airborne allergens (e.g., animal dander, molds, cockroach antigen, dust mites, and pollen), wood burning stoves, unvented heaters, and pesticides. Exercise, which may include giggling or crying in the young child, can exacerbate wheezing; children with exercise-induced worsening of symptoms are more likely to have asthma than other causes of wheezing.[37]

• **Review the family history.** Children with asthma often are found to have close relatives with asthma, allergic rhinitis, eczema, or recurrent sinusitis. CF is inherited as an autosomal recessive trait.

• **Begin the physical examination by evaluating for signs of respiratory distress.** Indications of respiratory distress include use of accessory muscles, chest wall retractions, nasal flaring, paradoxical breathing, cyanosis, respiratory rate in excess of 60, and oxygen saturation less than 91%.[8]

• **Listen to breath sounds.** The quality of air entry and the inspiratory to expiratory ratio (I:E ratio) should be assessed. The normal I:E ratio is 2:1 or 3:1; extrathoracic causes of obstruction may result in prolonged inspiration and inspiratory stridor, while intrathoracic obstruction is more likely to produce wheezing, prolonged expiration, and use of accessory muscles.[38] When bronchiolar obstruction is almost complete, wheezing and breath sounds may become inaudible. Asymmetry of breath sounds may be a clue to consolidation or atelectasis. The presence of rales may imply pneumonia, CF, BPD, or pulmonary edema.[35]

For children with respiratory distress, initiate therapy, then complete the physical exam. Additional clues from the physical exam include:

Poor growth—may be a clue to chronic disease, especially CF and immunodeficiencies;

Nasal polyps—associated with CF;

Dennie lines (double folds of the lower lids), allergic shiners (dark circles under the eyes), pale boggy nasal mucosa, and a nasal crease—indications of allergic rhinitis, which supports a diagnosis of asthma;

Deviated trachea—caused by unilateral volume loss or severe air trapping and should lead to investigation for an FBA or a space-occupying lesion;

Increased anteroposterior diameter of the chest—consistent with severe or prolonged chronic obstructive lung disease;

Palpable liver—usually related to lung hyperinflation, which is common with bronchiolitis and asthma; true hepatomegaly may indicate congestive heart failure;

Clubbing—rarely seen in asthma; should prompt a search for CF or other chronic pulmonary, cardiac, or gastrointestinal condition; and

Eczema—atopic skin disease is highly correlated with persistent asthma symptoms.

Diagnostic Studies

Pulse Oximetry. Pulse oximetry should be obtained on all wheezing children; hypoxemia cannot be recognized adequately

Figure 6. Pleural Effusion

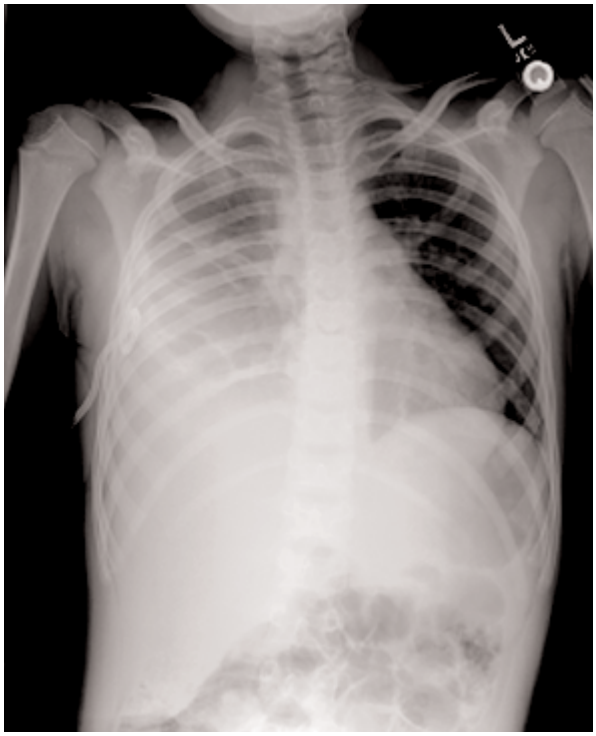

Radiograph of a child with pneumonia and a pleural effusion.

by clinical examination alone. An accurate pulse oximetry reading requires adequate peripheral perfusion with pulsatile blood flow. A reliable tracing is important and may be challenging to obtain, especially in younger children.

Blood Gas Analysis. Blood gas exchange is evaluated most accurately by the direct measurement of arterial partial pressure of oxygen (PO_2), partial pressure of carbon dioxide (PCO_2), and pH. Noninvasive monitoring with pulse oximetry has eliminated the need for blood gas analysis in some circumstances, but pulse oximetry does not provide information about ventilation. Blood gas analysis is necessary to evaluate PCO_2 in patients with suspected hypoventilation or severe distress.[8] Except in neonates, a PO_2 less than 85 mmHg is abnormal in a child breathing room air; arterial PCO_2 greater than 45 mmHg usually indicates hypoventilation or a severe ventilation-perfusion mismatch, unless it results from respiratory compensation for metabolic alkalosis.[38] Care is necessary in interpreting the PCO_2 in a tachypneic child. Hyperventilation associated with respiratory distress should result in a respiratory alkalosis; a "normal" or rising PCO_2 in a tachypneic infant, especially when associated with acidosis, suggests significant respiratory compromise. Children with chronic lung diseases like BPD require special consideration. Over time, these children may develop a compensated state with elevated PCO_2 balanced by an increased serum value of bicarbonate; respiratory deterioration is reflected by a rise of PCO_2 above the child's baseline or in association with acidosis.[39]

Pulmonary Function Testing. Tests of pulmonary function are useful in defining the type of pulmonary process (obstructive vs restrictive), the degree of impairment, and changes during treatment.[32] Bedside measurement of expiratory flow rate has become standard in the older child with pulmonary disease. However, devices for pulmonary function assessment require cooperation and are not useful outside of research settings in children younger than 3 years old.

Chest Radiograph. Though chest radiographs have been advocated in the past for all children who present with wheezing for the first time, the utility of this study currently is in question. Although chest radiographs may provide clues helpful in diagnosing recurrent aspiration, CF, foreign body aspiration, pneumonia *(See Figure 6)*, congestive heart failure, vascular ring with a right-sided aortic arch, or a mediastinal mass,[37] the overwhelming majority of children with first-time wheezing have asthma or bronchiolitis. Chest radiographs in these children may be normal or may reveal hyperinflation, peribronchial cuffing or thickening, interstitial infiltrates, or areas of atelectasis—findings that do not alter management.[40] Prospective studies are limited; retrospective studies and case series suggest that radiographs can be performed in a selected population of wheezing children.[41-44] Chest radiographs should be considered for an infant or child who presents with wheezing and any of the following:

- persistently asymmetric lung findings, such as decreased breath sounds or localized rales or wheezing;
- low oxygen saturation;
- first episode of wheezing without URI symptoms or other identifiable trigger; or
- first episode of wheezing in the absence of a family history of asthma in a child younger than 6 months of age.

Diagnostic imaging also is indicated for newborns with respiratory distress, and for infants or children with chronic cough or neurologic symptoms. When chest radiographs are ordered, both anteroposterior and lateral views should be obtained.

Imaging for children with suspected FBA deserves special comment. Most foreign bodies are radiolucent and unlikely to be evident on routine chest radiographs. Paired inspiratory and expiratory chest films *(See Figures 7a and 7b)* may reveal an area of lung which fails to empty appropriately with expiration, or a shift of the mediastinum away from the side with an obstructing foreign body; however, these films may be difficult to obtain in the uncooperative toddler. Bilateral decubitus chest films may reveal failure of the dependent lung to deflate.[9] Observation of respiration under fluoroscopy is a particularly sensitive method of evaluating for abnormal movement of the diaphragm or mediastinum that may occur in the presence of a foreign body, but this study may not be widely available. Bronchoscopy is indicated whenever the suspicion for a foreign body is high, even if the radiographs are normal.

Viral Studies. Efforts to identify the viral etiologic agent in bronchiolitis and pneumonia generally are unnecessary. Identifi-

cation of a specific organism may be useful for isolation and cohorting of hospitalized children. Tests for *C. trachomatis* should be obtained in appropriate clinical settings, since the diagnosis requires systemic treatment not only of the infected infant, but also of the mother and her contacts.

Other studies which may be useful in diagnosing specific entities are listed in Table 5.

Management—General Principles

• **Begin with stabilization of the respiratory status.** In the child in respiratory distress, therapy should be initiated after a brief, focused history and exam; a more detailed evaluation including laboratory or radiologic studies should be done only after therapy has been started.

• **Ensure a patent airway.** Alert children should be allowed to determine their own position of comfort. The airway should be cleared of secretions; this is particularly important for infants with bronchiolitis. Humidification is helpful in preventing obstruction of small airways by dried sections.[39] Children with significant respiratory distress should not be given anything to eat or drink (NPO).[12]

Provide oxygen and monitor oxygen saturation.[8] Most children with wheezing and any degree of respiratory distress will benefit from oxygen, even if pulse oximetry values are normal.[39] Oxygen should be provided in a nonthreatening manner, since anxiety and agitation increase metabolic demand and oxygen consumption. Alert children with respiratory distress should be allowed to remain with their parents, who may be able to position oxygen on the child's face or blow it near the nose and mouth without causing agitation.

• **Provide a trial of beta-agonist therapy.** Many, though not all, children with wheezing will benefit from the bronchodilating effect of a beta-agonist such as albuterol. Exceptions include infants with bronchiolitis, who typically show no response to bronchodilating medications, and children with wheezing associated with a suspected cardiac lesion, for whom beta-agonist therapy is contraindicated.[12,13] The patient should be evaluated carefully prior to the administration of the beta-agonist medication and shortly following its completion. Young infants who show no improvement should not be given additional doses. For patients who demonstrate improvement with beta-agonist therapy and persistent respiratory distress, the medication may be repeated every 20-30 minutes until the child has resolution of symptoms or is clinically breathing comfortably. See Table 6 for drug dosages.

The best method for delivering beta-agonist therapy has been studied extensively. Nebulizers do not require coordination and are easy to use; however, they are relatively inefficient, contain significant dead space in the tubing, and are time-consuming and expensive.[45] A mask must be used in conjunction with a nebulizer; the use of blow-by (holding the tube or mask in front of the face) significantly reduces the pulmonary delivery of medication.[45] Equivalent bronchodilation can be achieved when

Figures 7a and 7b. Inspiratory/Expiratory Films in a Child with Suspected FBA

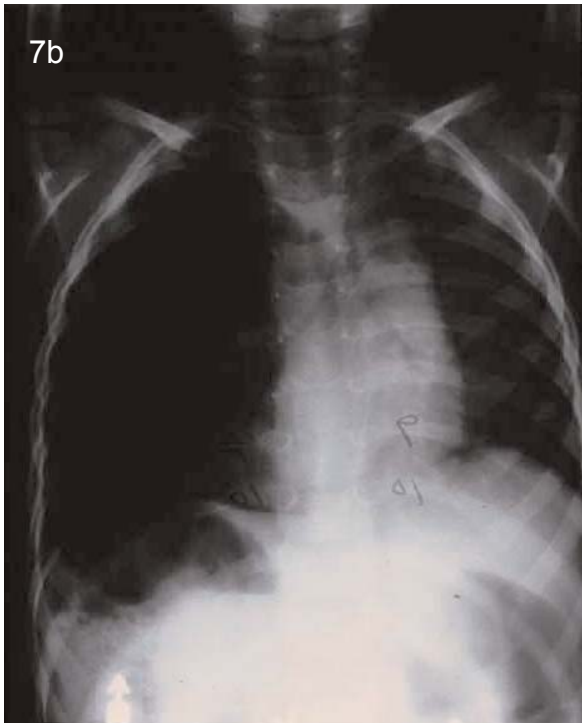

Radiographs of a child with suspected foreign body aspiration, whose inspiratory/expiratory films showed a right-sided foreign body.

Table 6. Medications Used for the Wheezing Child

MEDICATION	DOSAGE	COMMENTS
Inhalational agents		
Albuterol	0.15mg/kg every 20 minutes for three doses	Aerosols should be diluted to minimum
- nebulizer solution	(min dose = 2.5 mg; max dose = 10 mg)	of 4 mL at gas flow of 6-8 L/min
- metered-dose inhaler (90 mcg/puff)	4-8 puffs every 20 minutes for three doses	As effective as nebulized therapy if patient is able to coordinate inhalation maneuver. Use spacer device.
Racemic epinephrine (2.25%)	0.25-0.50 cc nebulized	Dilute in 3 mL normal saline
Anticholinergics		
Ipratropium bromide nebulizer solution	0.25 mg every 20 minutes for three doses	Should not be used as first-line therapy; should be added to beta2-agonist therapy. May mix in same nebulizer with albuterol.
Steroids		
Prednisone	Dose for "burst" at discharge: 1-2 mg/kg/day, in a single or two divided doses, for 3-10 days. (max dose = 60 mg/day)	

Adapted from National Asthma Education and Prevention Program. *Guidelines for the Diagnosis and Management of Asthma*. Bethesda, MD; National Institutes of Health pub 97-4051: 1997.

a beta-agonist is given by metered-dose inhaler (MDI) with a spacer and holding chamber.[8,11,46-48] MDIs should never be used without an appropriate spacer device; an appropriate spacer maximizes drug delivery to the lungs while minimizing oropharyngeal deposition and swallowed drug, and therefore, side effects.[45] Spacer devices for infants and young children should include masks, since they are nasal breathers.[45]

• **Consider steroid therapy early for children with conditions known to benefit from their use, including asthma and BPD.** Oral administration of prednisone is equally efficacious to parenteral administration, and is preferred.[8,11] The onset of action is typically greater than four hours. For children who receive corticosteroids in the ED and will be discharged home, a course of 3-10 days of oral steroids at discharge is useful.[8] Corticosteroids have not been shown to be beneficial in the treatment of bronchiolitis. *(See Table 6.)* Reassess frequently; a slowing respiratory rate in a tachypneic infant may represent improvement, or may be an ominous sign that the infant is tiring and respiratory failure is imminent. For children with severe intrathoracic airway narrowing or obstruction, treatment initially may result in increased wheezing as air exchange improves. With continued improvement, wheezing is heard later and later in expiration until the airways are dilated enough that no wheezing is heard.

• **Provide a discharge plan for children sent home from the ED.** The discharge plan should include instructions on frequency of beta-agonist therapy, and dose and duration of oral steroids or other medications recommended. The written plan also should include indications for returning to the ED if needed. Discharge teaching must include instruction and demonstration of the proper use of inhaler and spacer devices.

• **Recommend or arrange follow-up with a primary care medical home within 3-5 days.** A primary care provider is best suited to coordinate a work-up if the diagnosis is in question, and to follow the child for recurrent episodes of wheezing. Ongoing education and supervision for children who require chronic medications and treatment plans also are provided best in the primary care setting.

• **Avoid the following therapies,** which have been employed in the past but are not currently recommended:

— subcutaneous bronchodilator medications (e.g., epinephrine and terbutaline), which are less effective than inhaled bronchodilators and have significantly greater adverse effects;

— theophylline/aminophylline, which adds little or no therapeutic benefit and risks potentially significant adverse effects for most wheezing children receiving bronchodilators and steroids;[8,49]

— antibiotics, unless a specific concurrent bacterial infection (e.g., lobar pneumonia, sinusitis, or otitis media) is identified. Because of the overwhelming predominance of viral etiology for pneumonia in this age group, antibiotics rarely are warranted. Pneumonia caused by *C. trachomatis* is treated with oral erythromycin (50 mg/kg per day in four divided doses) for 14 days;[16]

— anxiolytics and hypnotic drugs, which increase the risk for hypoventilation;

— chest physiotherapy, which may increase bronchospasm in wheezing disorders with a hypersensitivity component, and

which has not been shown to be beneficial in bronchiolitis;[50] and

— hydration, unless a child is clinically dehydrated, since overhydration may worsen respiratory distress.

Management—Specific Entities

Because of the overwhelming predominance of asthma and bronchiolitis as causes of wheezing in this age group, additional management guidelines for these entities follow.

Bronchiolitis. *Provide cardiopulmonary monitoring as needed.* Monitoring for apneic and bradycardic spells may be necessary during the acute stage of illness, particularly in very young infants (younger than 6 weeks of age) or infants with underlying cardiopulmonary diseases.

Consider a trial of bronchodilator therapy. Although studies have shown variable degrees of response of children with bronchiolitis to bronchodilator therapy, the response generally has not been clinically significant.[51-53] Nebulized epinephrine has been shown to be more beneficial than albuterol in some studies.[51,54] A one-dose trial of albuterol or epinephrine is reasonable, provided the child is evaluated immediately before and after administration. A response should be evident within 15-30 minutes; if there is not a clear, significant benefit, the dose should not be repeated. Deterioration associated with inhalation therapies for bronchiolitis is well-described; infants should be observed closely.[50] *(See Table 6.)*

Provide supportive care and hospitalize infants with significant respiratory distress or who are unable to maintain oxygenation or hydration.

The following therapies are controversial or are ***not*** recommended:

- Corticosteroid use is controversial; most studies have failed to demonstrate benefit, and they are not currently recommended for previously healthy infants with RSV bronchiolitis.[55] Studies that have shown benefit have not excluded infants with probable asthma, and corticosteroid therapy may be beneficial in the subset of infants with bronchiolitis who are predisposed to developing asthma.[56-58] Further study is needed to clarify the use of corticosteroids for this disease.
- Antibiotics rarely are indicated, as associated bacterial pneumonia is very uncommon.[55] Appropriate antibiotic therapy is warranted for infants with concomitant otitis media.
- Ribavirin, an antiviral agent with in vitro activity against RSV, is controversial, and generally not recommended because of its high cost, difficult administration, potential toxicity to health care providers, and questionable efficacy.[55]

Asthma. *Provide steroids early.* Steroids have been shown to speed recovery and reduce the likelihood of recurrence. Early use of oral steroids particularly is important in young children, as well as for children with moderate to severe exacerbations, and patients who will be admitted to the hospital.[8] For patients taking oral steroids long-term, supplemental doses of steroids should be given, even if the current exacerbation is mild.[8]

Consider the addition of anticholinergic therapy to albuterol nebulizer therapy. Ipratropium bromide has been shown to improve lung function and decrease hospitalization in some, though not all, studies.[8,11] Benefit is most evident in children with severe exacerbations of asthma and is less well-documented in moderate disease or in children younger than 2 years.[59-61] *(See Table 6.)*

Hospitalize children in whom respiratory distress or low oxygen saturation persist despite therapy with bronchodilators, steroids, and anticholinergic medication. Children with risk factors for asthma-related death should be managed especially cautiously.[8] *(See Table 7.)*

Recommend long-term control therapies for children with persistent or frequently recurring asthma symptoms. Long-term control therapy with inhaled corticosteroids is recommended for even very young children if wheezing is frequent, severe, or associated with risk factors for asthma. Children who are already on long-term control medications should be encouraged to continue them during their exacerbation. Although control therapies most often are prescribed and monitored by primary care physicians, the emergency medicine physician must be familiar with the standards of current asthma care.

Table 7. Risk Factors for Asthma-Related Death

- Past history of sudden severe exacerbation
- Prior intubation for asthma
- Prior admission to an intensive care unit for asthma
- Two or more hospitalizations in the past year
- Three or more emergency care visits in the past year
- Hospitalization or emergency visit in the past month
- Use of more than two canisters per month of a short-acting beta-agonist
- Current use of oral steroids or recent withdrawal from oral steroids
- Comorbidity such as congenital heart disease
- Low socioeconomic status and urban residence

Adapted from National Asthma Education and Prevention Program. *Guidelines for the Diagnosis and Management of Asthma*. Bethesda, MD; National Institutes of Health pub 97-4051:1997.

Outcomes

The parent of a wheezing child often will ask whether the child has asthma. While asthma is the single most common cause of wheezing in the first 3 years of life, half or more of children who wheeze do not go on to have asthma.[62,63] Defining which children who wheeze are at risk for persistent asthma could allow for better management and, potentially, for reduced morbidity and mortality.[10]

Children with recurrent wheezing in the first years of life who do not have an underlying anatomic abnormality or disease generally can be divided into two groups: those with transient early wheezing and those with atopic asthma. Transient early wheez-

ing typically resolves by age 3 and generally is not associated with a family history of asthma or allergic sensitization.[10]

Although there is not a specific test or single clinical indicator to identify asthma, a number of risk factors and associations have been identified which help to define the subset of wheezing infants who most likely will become children with asthma. The most significant risk factors seem to be eczema in the patient or asthma in a parent; other risk factors and associations include allergic rhinitis in the first year of life, close family members with other atopic disease, recurrence of wheezing without an associated URI, perinatal passive smoke exposure, eosinophilia greater than 4%, elevated serum IgE level at 9 months of age, and positive allergy skin testing.[9,10,35,37]

The role of RSV infection during infancy as a risk factor for asthma is unclear. Infants who have had RSV infection tend to have an increased risk of recurrent wheezing during childhood, but their wheezing tends to decrease with age and often no longer is significant by adolescence; RSV infection alone does not appear to be a risk factor for atopic asthma.[10,64]

Summary

Wheezing is common in children during the first years of life. While the differential diagnosis is broad, a significant number of children with wheezing have asthma; a substantial proportion may have viral bronchiolitis or virally-mediated wheezing that resolves as the child ages.

Understanding the basic mechanisms of wheezing and using a systematic approach to diagnosis helps to institute the proper treatment in an efficient manner. Although bronchiolitis and asthma predominate, maintain a high index of suspicion for the "mimics of asthma" in infants and young children.

References

1. Crain EF, Weiss KG, Fagan MJ. Pediatric asthma care in U.S. emergency departments. *Arch Pediatr Adolesc Med* 1995;149:893-901.
2. Shah PD, Ludemann JP, Holinger LD. Wheezing in children: Is obstruction the cause? *Journal of Respiratory Diseases for Pediatricians* 1999;1:10-15.
3. Finder JD. Understanding airway disease in infants. *Curr Probl Pediatr* 1999;29:65-81.
4. Sagy M, Silver P, Nimkoff L, et al. Pediatric intrathoracic large airway obstruction: Diagnostic and therapeutic considerations. *Pediatr Emerg Care* 1994;10:351-358.
5. Lemanske RF. Inflammation in childhood asthma and other wheezing disorders. *Pediatrics* 2002;109:368-372.
6. Dimitriou G, Greenough A, Moxham J, et al. Influence of maturation on infant diaphragm function assessed by magnetic stimulation of phrenic nerves. *Pediatr Pulmonol* 2003;35:17-22.
7. Keens TG, Bryan AL, Levison H, et al. Developmental pattern of muscle fiber types in human ventilatory muscles. *J Appl Physiol* 1978;44:909-913.
8. National Asthma Education and Prevention Program. *Guidelines for the Diagnosis and Management of Asthma.* National Institutes of Health pub 97-4051. Bethesda, MD, 1997.
9. Fausnight TB, Gentile DA, Skoner DP. Determining the cause of recurrent wheezing in infants. *Journal of Respiratory Diseases for Pediatricians* 2002; 4:126-131.
10. Martinez FD. Development of wheezing disorders and asthma in preschool children. *Pediatrics* 2002;109:362-367.
11. National Asthma Education and Prevention Program. Expert Panel Report: Guidelines for the diagnosis and management of asthma—update on selected topics 2002. *J Allergy Clin Immunol* 2002;110:S141-219.
12. Orenstein DM. Bronchiolitis. In: Behrman RE, Kliegman RM, Jenson HB, eds. *Nelson Textbook of Pediatrics.* 16th ed. Philadelphia: WB Saunders; 2000;1285-1287.
13. Linzer JF. Managing a winter season risk: Bronchiolitis in children. *Pediatric Emergency Medicine Reports* 2002;8:13-24.
14. Klig JE, Chen L. Lower respiratory infections in children. *Curr Opin Pediatr* 2003;15:121-126.
15. Tunnessen WW. Wheezing. In: *Signs and Symptoms in Pediatrics.* 3rd ed. Philadelphia:Lippincott Williams & Wilkins;1999:407-412.
16. American Academy of Pediatrics. *Chlamydia trachomatis*. In: Pickering LK, ed. *2000 Red Book: Report of the Committee on Infectious Diseases*. 25th ed. Elk Grove Village, IL: American Academy of Pediatrics; 2000:208-212.
17. Triche EN, Belanger K, Beckett N, et al. Infant respiratory symptoms associated with indoor heating sources. *Am J Respir Crit Care Med* 2002;166: 1105-1111.
18. Gergen PJ, Fowler JA, Maurer KR et al. The burden of environmental tobacco smoke exposure on the respiratory health of children 2 months through 5 years of age in the United States: Third National Health and Nutrition Examination Survey, 1988 to 1994. *Pediatrics* 1998;101:e8.
19. Sheikh S, Stephen T, Howell L, et al. Gastroesophageal reflux in infants with wheezing. *Pediatr Pulmonol* 1999;28:181-186.
20. Eid NS, Shepherd RN, Thomson MA. Persistent wheezing and gastroesophageal reflux in infants. *Pediatr Pulmonol* 1994;18:39-44.
21. Sehgal A, Singh V, Chandra J, et al. Foreign body aspiration. *Indian Pediatrics* 2002;39:1006-1010.
22. Muniz AE, Joffe MD. Foreign bodies: Ingested and inhaled. *Contemp Pediatr* 1997;14:78-103.
23. Friedmann EM. Tracheobronchial foreign bodies. *Otolaryngol Clin North Am* 2000;33:179-115.
24. Karakoc F, Karaday B, Akbenlioglu C, et al. Foreign body aspiration: What is the outcome? *Pediatr Pulmonol* 2002;34:30-36.
25. Baharloo F, Veyckemas F, Francis C, et al. Tracheobronchial foreign bodies: Presentation and management in children and adults. *Chest* 1999;115: 1357-1362.
26. Masters IB, Chang AB, Patterson L, et al. Series of laryngomalacia, tracheomalacia, and bronchomalacia disorders and their associations with other conditions in children. *Pediatr Pulmonol* 2002;34:189-195.
27. Finder JD. Primary bronchomalacia in infants and children. *J Pediatr* 1997; 130:59-66.
28. Shaffer TH, Wolfson MR, Panitch HB. Airway mechanics in health and disease. *New Horizons* 1999;7:276-286.
29. Jube AH, Bancalari E. Bronchopulmonary dysplasia. *Am J Respir Crit Care Med* 2001;163:1723-1729.
30. Alpern ER, Stevens MN. An offbeat wheezer. *Pediatr Ann* 2000;29:97-101.
31. Cheung YF, Lee SL, Leung MP, et al. Tracheobronchography and angiocardiography of pediatric cardiac patients with airway disorders. *J Paediatr Child Health* 2002;38:258-264.
32. Amirav I, Rotschild M, Bar-Yishay E. Pulmonary function tests leading to the diagnosis of vascular ring in an infant. *Pediatr Pulmonol* 2003;35:62-66.
33. Pratilas CA, Turcios NL. Mediastinal masses in children: From thymic lesions to lymphomas. *J Respir Dis Pediatrician* 2003;5:22-29.
34. Franklin WH, Dietrich AM, Hicky RW. Anomalous left coronary artery masquerading as infantile bronchiolitis. *Pediatr Emerg Care* 1992;8:338-341.
35. Kumar R. The wheezing infant: Diagnosis and treatment. *Pediatr Ann* 2003; 32:30-36.
36. Boat TF, Orenstein DM. Chronic or recurrent respiratory symptoms. In: Behrman RE, Kliegman RM, Jenson HB, eds. *Nelson Textbook of Pediatrics.* 16th ed. Philadelphia: WB Saunders; 2000:1311-1315.
37. Strunk RC. Defining asthma in the preschool-aged child. *Pediatrics* 2002;109: 357-361.

38. Haddad GG, Palazzo RM. Diagnostic approach to respiratory disease. In: Behrman RE, Kliegman R, Jenson HB eds., *Nelson Textbook of Pediatrics.* 16th ed. Philadelphia: WB Saunders, 2000;1253-1258.
39. American Heart Association. Airway, ventilation, and management of respiratory distress and failure. In: Hazinski MF, Zaritsky AL, Nadkarni VM, et al, eds. *PALS Provider Manual*. Dallas, TX: American Heart Association; 2002: 81-121.
40. Sly M. Asthma. In: Behrman RE, Kliegman RM, Jenson HB, eds. *Nelson Textbook of Pediatrics.* 16th ed. Philadelphia: WB Saunders; 2000;664-680.
41. Roback MG, Dreitlein DA. Chest radiograph in the evaluation of first time wheezing episodes: Review of current clinical practice and efficacy. *Pediatr Emerg Care* 1998;14:181-184.
42. Mahabee-Gittens EM, Bachman DT, Shapiro ED et al. Chest radiographs in the pediatric emergency department for children ≤ 18 months of age with wheezing. *Clin Pediatr* 1999;38:395-399.
43. Mahabee-Gittens EM, Dowd MD, Beck JA, et al. Clinical factors associated with focal infiltrates in wheezing infants and toddlers. *Clin Pediatr* 2000; 39:387-393.
44. Farah MM, Padgett LB, McLario DJ et al. First-time wheezing in infants during respiratory syncytial virus season: Chest radiograph findings. *Pediatr Emerg Care* 2002;18:333-336.
45. Pongracic JA. Asthma delivery devices: Age-appropriate use. *Pediatr Ann* 2003;32:50-54.
46. Leversha AM, Campanella SG, Aickin RP, et al. Costs and effectiveness of spacer versus nebulizer in young children with moderate and severe acute asthma. *J Pediatr* 2000;136:497-502.
47. Ploin D, Chapuis FR, Stamm D et al. High-dose albuterol by metered-dose inhaler plus a spacer device versus nebulization in preschool children with recurrent wheezing: A double-blind, randomized equivalence trial. *Pediatrics* 2000;106:311-317.
48. Delgado A, Chou KJ, Silver EJ, et al. Nebulizers vs metered-dose inhalers with spacers for bronchodilator therapy to treat wheezing in children aged 2 to 24 months in a pediatric emergency department. *Arch Pediatr Adolesc Med* 2003;157:76-80.
49. Strauss RE, Wertheim DL, Bonagura VR et al. Aminophylline therapy does not improve outcome and increases adverse effects in children hospitalized with acute asthmatic exacerbations. *Pediatrics* 1994;93:205-210.
50. Perlstein PH, Kotagal UR, Bolling C, et al. Evaluation of an evidence-based guideline for bronchiolitis. *Pediatrics* 1999;104:1334-1341.
51. Kellner JD, Ohlsson A, Gadomski AM, et al. Efficacy of bronchodilator therapy: A meta-analysis. *Arch Pediatr Adolesc Med* 1996;150:1166-1172.
52. Dobson JV, Stephens-Groff SM, McMahon SR et al. The use of albuterol in hospitalized infants with bronchiolitis. *Pediatrics* 1998;101:361-368.
53. Flores G, Horwitz RI. Efficacy of beta2-agonists in bronchiolitis: A reappraisal and meta-analysis. *Pediatrics* 1997;100:233-239.
54. Menon K, Sutcliffe T, Klassen TP. A randomized trial comparing the efficacy of epinephrine with salbutamol in the treatment of acute bronchiolitis. *J Pediatr* 1995;126:1004-1007.
55. American Academy of Pediatrics. Respiratory syncytial virus. In: Pickering LK, ed. *2000 Red Book: Report of the Committee on Infectious Diseases.* 25th ed. Elk Grove Village, IL: American Academy of Pediatrics;2000:483-487.
56. Roosevelt G, Sheehan K, Grupp-Phelan J, et al. Dexamethasone in bronchiolitis: A randomized controlled trial. *Lancet* 1996;348:292-295.
57. Garrison MM, Christakis DA, Harvey E, et al. Systemic corticosteroids in infant bronchiolitis: A meta-analysis. *Pediatrics* 2000;105:e44.
58. Schuh S, Coates AL, Binnie R et al. Efficacy of oral dexamethasone in outpatients with acute bronchiolitis. *J Pediatr* 2002;140:27-32.
59. Zorc JJ, Pusic MV, Ogborn CJ, et al. Ipratropium bromide added to asthma treatment in the pediatric emergency department. *Pediatrics* 1999;103:748-752.
60. Everard ML, Bara A, Kurian M, et al. Anticholinergic drugs for wheeze in children under the age of two years. *Cochrane Database Syst Rev* 2002;4: CD001279.
61. Qureshi F, Pestian J, Davis P, et al. Effect of nebulized ipratropium on the hospitalization rates of children with asthma. *N Engl J Med* 1998;339:1030-1035.
62. Wennergren G. Prediction of outcome after wheezing in infancy. *Acta Paediatr* 2001;90:840-842.
63. Clough JB, Keeping KA, Edwards JC, et al. Can we predict which wheezy infants will continue to wheeze? *Am J Respir Crit Care Med* 1999;160: 1473-1480.
64. Stein RT, Sherrill D, Morgan WJ, et al. Respiratory syncytial virus in early life and risk of wheeze and allergy by age 13 years. *Lancet* 1999;354:541-545.

CME Objectives

The CME objectives for *Pediatric Emergency Medicine Reports* are to help physicians:

a.) Quickly recognize or increase index of suspicion for specific conditions;

b.) Understand the epidemiology, etiology, pathophysiology, historical and physical examination findings associated with the entity discussed;

c.) Be educated about how to correctly formulate a differential diagnosis and perform necessary diagnostic tests;

d.) Apply state-of-the-art therapeutic techniques (including the implications of pharmacologic therapy discussed) to patients with the particular medical problems discussed;

e.) Provide patients with any necessary discharge instructions.

Physician CME Questions

71. Which of the following is the most common cause of wheezing in children?
    A. Mediastinal mass
    B. Foreign body aspiration
    C. Pneumonia
    D. Asthma
    E. Congenital airway anomaly

72. Which of the following findings, on physical exam of a wheezing child, suggests a diagnosis other than asthma?
    A. Clubbing
    B. Allergic shiners
    C. Increased anteroposterior diameter of the chest
    D. Pale, boggy nasal mucosa
    E. Dennie lines

73. Which of the following is most consistent with aspiration of a foreign body?
    A. Bilateral wheezing
    B. Deflation of the right lung field in a right lateral decubitus radiograph
    C. Wandering areas of atelectasis on serial radiographs
    D. Mediastinal shift to one side on expiratory chest radiograph
    E. Bilateral hyperinflation with peribronchial cuffing

74. Classic lobar pneumonia does not commonly cause wheezing.
    A. True
    B. False

75. Wheezing from which of the following etiologies is most likely to improve following an inhaled bronchodilator medication?
   A. Congestive heart failure
   B. Bronchopulmonary dysplasia
   C. Tracheoesophageal fistula
   D. Tracheomalacia
   E. Vascular ring

76. Which of the following statements is true regarding the increased risk for wheezing in infancy?
   A. Poiseuille's law defines the increased risk of collapse due to ultracompliant airway structures.
   B. The infant diaphragm is more resistant to fatigue than the diaphragm of an adult.
   C. Similar amounts of intraluminal edema have more effect on airflow resistance in the infant than in the older child or adult.
   D. Pores of Kohn and Canals of Lambert result in distal airway overinflation in the very young child.
   E. Easy deformation of the compliant chest wall increases functional residual capacity of the infant lung.

77. Which of the following is a cause of wheezing in infants and young children that results from extrinsic compression to the airway?
   A. Aberrant subclavian artery
   B. Laryngeal cleft
   C. Tracheomalacia
   D. Pneumonia with effusion
   E. Tracheoesophageal fistula

78. Which of the following typically is not associated with obstruction of the large, central airways?
   A. Monophonic wheezing
   B. Hypoxemia
   C. Stridor
   D. Bronchomalacia
   E. Wheezing

79. Which of the following statements is true regarding wheezing in infants?
   A. Infants with congestive heart failure have decreased distress during feedings.
   B. Respiratory distress with tracheobronchomalacia is worst in the prone position.
   C. Infants with cystic fibrosis often have a component of stridor.
   D. Giggling or crying may trigger wheezing in an infant with asthma.
   E. Neonatal conjunctivitis is a precursor of mycoplasma pneumonia.

80. Which one of the following conditions may be associated with wheezing?
   A. Foreign body aspiration
   B. Congestive heart failure
   C. Mediastinal mass
   D. Bronchomalacia
   E. All of the above

Answer Key:

71. D	75. B	78. B
72. A	76. C	79. D
73. D	77. A	80. E
74. A		

CME Instructions

Physicians participate in this continuing medical education program by reading the article, using the provided references for further research, and studying the questions at the end of the article. Participants should select what they believe to be the correct answers, then refer to the list of correct answers to test their knowledge.

To clarify confusion surrounding any questions answered incorrectly, please consult the source material. After completing this activity, you must complete the evaluation form that will be provided at the end of the semester and return it in the reply envelope provided to receive a certificate of completion. When your evaluation is received, a certificate will be mailed to you.

In Future Issues: **Status Epilepticus**

PEDIATRIC Emergency Medicine Reports

The Practical Journal of Pediatric Emergency Medicine

Wheezing in Children Younger than 3

Differential Diagnosis of Wheezing in Infants and Young Children

REACTIVE AIRWAY DISEASE
- Atopic asthma
- Recurrent, virally mediated wheezing

INFECTION
- Viral bronchiolitis
- Pneumonia (viral, chlamydia)

IRRITANT OR HYPERSENSITIVITY
- Environmental toxin
- Food- or drug-induced hypersensitivity
- Environmental allergen
- Infection (visceral larva migrans, allergic bronchopulmonary aspergillosis)

ASPIRATION
- Dysfunctional swallowing
- Laryngeal cleft
- Foreign body aspiration
- Tracheoesophageal fistula
- Gastroesophageal reflux disease

DEVELOPMENTAL ABNORMALITY
- Tracheobronchomalacia
- Laryngeal web
- Tracheal or bronchial stenosis

CHRONIC LUNG DISEASE
- Bronchopulmonary dysplasia
- Cystic fibrosis

IMMUNODEFICIENCY
- Ciliary dyskinesia
- Human immunodeficiency virus
- Primary humoral immunodeficiency

EXTRINSIC COMPRESSION
- Vascular ring, aberrant vessel
- Mediastinal mass, lymph nodes
- Pulmonary cyst

CARDIAC ABNORMALITY
- Congestive heart failure
- Cardiomegaly

Inspiratory/Expiratory Films in a Child with Suspected Foreign Body Aspiration

Radiographs of a child with suspected foreign body aspiration, whose inspiratory/expiratory films showed a right-sided foreign body.

Infant with Cardiomegaly

Radiograph of a 7-week-old who presented to the emergency department with wheezing and cyanosis. Chest x-ray shows hyperinflation, pulmonary edema, and cardiomegaly.

Risk Factors for Asthma-Related Death

- Past history of sudden severe exacerbation
- Prior intubation for asthma
- Prior admission to an intensive care unit for asthma
- Two or more hospitalizations in the past year
- Three or more emergency care visits in the past year
- Hospitalization or emergency visit in the past month
- Use of more than two canisters per month of a short-acting beta-agonist
- Current use of oral steroids or recent withdrawal from oral steroids
- Comorbidity such as congenital heart disease
- Low socioeconomic status and urban residence

Adapted from National Asthma Education and Prevention Program. *Guidelines for the Diagnosis and Management of Asthma*. Bethesda, MD; National Institutes of Health pub 97-4051:1997.

Pneumonia

Radiograph of a child with a lobar consolidation most likely of a bacterial etiology.

Clinical Symptoms of Patients with Foreign Body Aspiration

SYMPTOM	PERCENTAGE
Choking	90
Paroxymal cough	81
Tachypnea	81
Stridor	71
Decreased air entry	67
Wheezing	50
Fever	29
Cyanotic episode	11

Modified from: Sehgal A, Singh V, Chandra J, et al. Foreign body aspiration. *Indian Pediatrics* 2002;39:1006-1010.

Medications Used for the Wheezing Child

MEDICATION	DOSAGE	COMMENTS
Inhalational agents		
Albuterol		
- nebulizer solution	0.15mg/kg every 20 minutes for three doses (min dose = 2.5 mg; max dose = 10 mg)	Aerosols should be diluted to minimum of 4 mL at gas flow of 6-8 L/min
- metered-dose inhaler (90 mcg/puff)	4-8 puffs every 20 minutes for three doses	As effective as nebulized therapy if patient is able to coordinate inhalation maneuver. Use spacer device.
Racemic epinephrine (2.25%)	0.25-0.50 cc nebulized	Dilute in 3 mL normal saline
Anticholinergics		
Ipratropium bromide nebulizer solution	0.25 mg every 20 minutes for three doses	Should not be used as first-line therapy; should be added to beta2-agonist therapy. May mix in same nebulizer with albuterol.
Steroids		
Prednisone	Dose for "burst" at discharge: 1-2 mg/kg/day, in a single or two divided doses, for 3-10 days. (max dose = 60 mg/day)	

Adapted from National Asthma Education and Prevention Program. *Guidelines for the Diagnosis and Management of Asthma*. Bethesda, MD; National Institutes of Health pub 97-4051: 1997.

Clinical Features and Diagnostic Studies for the Wheezing Child

DIAGNOSTIC CONSIDERATION	CLINICAL CLUES	DIAGNOSTIC TESTS TO CONSIDER
Asthma	• Presence of other atopic disease, especially eczema • Family history of asthma, atopic disease	• Peripheral blood eosinophilia, elevated serium IgE, positive skin prick tests are consistent but not diagnostic.
Bronchiolitis	• Infants < 18 months • Fall or winter • URI symptoms, rales	• Nasopharyngeal (NP) washing for rapid antigen tests or viral culture
Pneumonia	• Usually viral • Fever, cough, rales • Tachypnea	• Chest radiograph • Complete blood count • NP—rapid antigen test or culture
Hypersensitivity or irritant	• Environmental exposure to tobacco smoke, mold, cockroach antigen, dust, fungi, others	
Dysfunctional swallowing	• Developmental disability; neuromotor weakness; craniofacial abnormality • Choking, coughing with feeds • Recurrent pneumonia	• Videofluoroscopic evaluation of swallow
Tracheoesophageal fistula	• Cough, cyanosis during feeding • Recurrent wheeze or pneumonia	• Barium esophagram/fluoroscopy • Endoscopy/bronchoscopy
Gastroesophageal reflux	• Emesis or irritability with feeds	• pH probe • Radionuclide milk scan • Endoscopy
Foreign body aspiration	• More common in toddlers than in infants • Sudden onset of choking, wheezing, or cough followed by recurrent wheezing, persistent cough, or recurrent pneumonia • May have asymmetric wheeze or decreased breath sounds	• Inspiratory/expiratory chest radiographs • Bilateral decubitus chest radiographs • Chest exam under fluoroscopy • Bronchoscopy
Tracheobronchomalacia	• May have associated stridor • Symptoms may increase with agitation and when supine	• Airway fluoroscopy • Laryngoscopy/bronchoscopy
Bronchopulmonary dysplasia	• History of prematurity and intubation/ventilation	
Cystic fibrosis	• Gastrointestinal, respiratory, infectious, and/or growth problems	• Sweat chloride analysis
Vascular ring/ aberrant vessel	• Presents in early infancy • Stridor, cough are prominent symptoms • Symptoms increase with feeding, agitation, position change • Minimal response to bronchodilators	• Barium esophagram
Mediastinal mass	• Progressively worsening cough, dyspnea, chest pain, or stridor • Systemic symptoms: fever, malaise, weight loss	• Chest radiograph • Computed tomography, magnetic resonance imaging
Cardiac abnormality	• Tires with feeding • Abnormal cardiac exam • Hepatomegaly; rales; tachycardia, tachypnea	• Radiograph • Echocardiogram

Adapted with permission from Fausnight TB, Gentile DA, Skoner DP. Determining the cause of recurrent wheezing in infants. *Journal of Respiratory Diseases for Pediatricians* 2002;4:126-131.

Intrathoracic Large Airway Obstruction vs. Small Airway Obstruction

LARGE AIRWAY OBSTRUCTION

Tracheal Obstruction
- Tracheomalacia
- Repaired tracheoesophageal fistula
- Complete tracheal rings
- Tracheal hemangioma
- Mediastinal mass
- Tracheal stenosis

Bronchial Obstruction
- Bronchomalacia
- Bronchial stenosis
- Foreign body
- Hilar adenopathy
- Vascular slings
- Bronchogenic cyst
- Cardiomegaly
- Pulmonary artery dilatation
- Mediastinal mass

SMALL AIRWAY OBSTRUCTION
- Asthma
- Bronchiolitis
- Cystic fibrosis
- Bronchopulmonary dysplasia
- Primary ciliary dyskinesia
- Bronchiolitis obliterans
- Aspiration
  - Gastroesophageal reflux disease
  - Swallowing dysfunction
  - Malformations
    - Tracheoesophageal fistula
    - Laryngeal cleft

Common Mediastinal Masses, by Anatomic Location

ANTERIOR MEDIASTINUM
- Thymic hyperplasia
- Hemangioma
- Lymphangioma
- Teratoma
- Lymphoma

MIDDLE MEDIASTINUM
- Lymphoma
- Lymphadenopathy
- Bronchogenic cyst

POSTERIOR MEDIASTINUM
- Neuroblastoma
- Ganglioneuroblastoma
- Duplication cyst

Pleural Effusion

Radiograph of a child with pneumonia and a pleural effusion.

Mediastinal Mass

Chest radiographs of a child who presented with stridor and was diagnosed with a mediastinal mass.

Supplement to *Pediatric Emergency Medicine Reports*, August 2003: "Wheezing in Children Younger than 3: Differential Diagnosis and Initial Approach to Management." *Authors:* **Karin M. Hillenbrand, MD,** Assistant Professor, General Pediatrics, Department of Pediatrics, Brody School of Medicine at East Carolina University, Greenville, NC; and **Ronald M. Perkin, MD, MA,** Professor and Chairman, Department of Pediatrics, Brody School of Medicine at East Carolina University, Greenville, NC.