THOMSON
AMERICAN HEALTH CONSULTANTS

Rapid Reference Card Enclosed

Take our new poll—visit EMRonline.com.

The Practical Journal for Emergency Physicians

# Emergency Medicine Reports®

Volume 24, Number 20 September 22, 2003

## Management of Acute Foot and Ankle Disorders in the Emergency Department: Part I—The Ankle

*Authors:* **Gary D. Hals, MD, PhD,** Attending Physician, Department of Emergency Medicine, Palmetto Richland Memorial Hospital, Columbia, SC; **Matt Logan, MD,** Resident Physician, Department of Emergency Medicine, Palmetto Richland Memorial Hospital, Columbia, SC; and **John Cory, MD,** Resident Physician, Department of Orthopedics, Palmetto Richland Memorial Hospital, Columbia, SC.

*Peer Reviewers:* **Jeff Druck, MD,** Emory University Department of Emergency Medicine, Atlanta, GA; and **Andrew O. Perron, MD, FACEP,** Attending Physician, Maine Medical Center, Portland.

*It has been estimated that each of us takes an average of one million steps per year. As a result of such use, it comes as no surprise that patients presenting with injuries of the foot and ankle are a common occurrence in the emergency department (ED). The ankle is one of the most common sites for musculoskeletal injury, with an estimated 1 million patients presenting with ankle sprain each year.[1] One recent survey of 5 million adults during a 10-year period found that while bones of the hands and hip are the most commonly fractured overall, foot and ankle fractures were the most common bony injuries in young adults.[2] While many injuries are obvious on plain films, others like Lisfranc fractures or fractures of the talar dome easily can be missed. These injuries have a high rate of complications, many of which may be prevented by early diagnosis and proper treatment. It is imperative that emergency physicians be aware of these injuries to avoid their misdiagnosis. Foot and ankle fractures often are sports-related, as one survey found that ankle injuries alone make up 25% of sports-related injuries.[3] Basketball, football, soccer, skating, skiing, skateboarding, and snowboarding are all popular sports associated with a significant risk of injury. One survey of sports-related injuries found that sprains/strains and fractures accounted for 62% of injuries reported, and the ankle/foot was the third most common site for injury.[4]*

*The complexity of foot and ankle biomechanics is easily underappreciated. The foot alone has 28 bones with 57 articulations, and recovery from injury can be more complicated than one would like. One survey of ankle sprains in military cadets with a supervised rehabilitation program found that 40% of these patients still demonstrated residual dysfunction six months after their injury.[5] Because foot and ankle injuries are seen so often, physicians easily may fall into a routine of treatment with splint, crutches, and follow-up that puts them at risk of missing a more*

*serious injury when it presents. For example, in the same study of military cadets, patients with syndesmosis strains were shown to be at higher risk for prolonged disability.[5] The practicing emergency physician needs to know the difference between injuries that require orthopedic consultation in the ED and those that can wait for follow-up. It is the emergency physician's job to sort the less common and potentially dangerous cases from the routine and benign. As the majority of these injuries occur in younger, working-age individuals, the potential for disability through loss of income is high. This paper will cover the diagnosis and management spectrum of foot and ankle injuries. Besides injury, other common emergencies affecting the foot, including diabetic infections, puncture wounds, burns and frostbite, will be discussed in Part II.*

*—The Editor*

***Emergency Medicine Reports™*** (ISSN 0746-2506) is published biweekly by Thomson American Health Consultants, 3525 Piedmont Road, N.E., Six Piedmont Center, Suite 400, Atlanta, GA 30305. Telephone: (800) 688-2421 or (404) 262-7436.

**Vice President/Group Publisher:** Brenda Mooney
**Editorial Group Head:** Valerie Loner
**Specialty Editor:** Shelly Morrow Mark
**Marketing Manager:** Schandale Kornegay
**GST Registration No.:** R128870672

Periodicals postage paid at Atlanta, GA. **POSTMASTER:** Send address changes to ***Emergency Medicine Reports***, P.O. Box 740059, Atlanta, GA 30374.



**Back issues: $31.** Missing issues will be fulfilled by customer service free of charge when contacted within one month of the missing issue's date.

**Multiple copy prices:** One to nine additional copies, $359 each; 10 to 20 additional copies, $319 each.

### Accreditation

***Emergency Medicine Reports'™*** continuing education materials are sponsored and supervised by Thomson American Health Consultants. Thomson American Health Consultants designates this continuing education activity for up to 60 hours in Category 1 credit toward the AMA Physician's Recognition Award. Each physician should claim only those hours of credit that he/she actually spent in the educational activity.

This CME activity was planned and produced in accordance with the ACCME Essentials.

***Emergency Medicine Reports™*** also is approved by the American College of Emergency Physicians for 60 hours of ACEP Category 1 credit and has been approved for 52 Category 2B credit hours by the American Osteopathic Association. Emergency Medicine Reports has been reviewed by the American Academy of Family Physicians as having educational content acceptable for Prescribed credit hours. This volume has been approved for up to 60 Prescribed credit hours. Term of approval covers issues published within one year from the beginning distribution date of 1/03. Credit may be claimed for one year from the date of this issue.

Thomson American Health Consultants (AHC) is accredited by the Accreditation Council for Continuing Medical Education (ACCME) to provide continuing medical education for physicians.

This is an educational publication designed to present scientific information and opinion to health professionals, to stimulate thought, and further investigation. It does not provide advice regarding medical diagnosis or treatment for any individual case. It is not intended for use by the layman. Opinions expressed are not necessarily those of this publication. Mention of products or services does not constitute endorsement. Clinical, legal, tax, and other comments are offered for general guidance only; professional counsel should be sought for specific situations.

**Subscriber Information**

**Customer Service: 1-800-688-2421**

**Customer Service E-Mail:** customerservice@ahcpub.com
**Editorial E-Mail:** shelly.morrow@ahcpub.com

**World Wide Web page:** http://www.ahcpub.com

**Subscription Prices**

1 year *with* 60 ACEP/60 AMA/60 AAFP Category 1/Prescribed credits (52 AOA Category 2B credits): $544
1 year *without* credit: $399
Resident's rate $199

All prices U.S. only.
U.S. possessions and Canada, add $30 plus applicable GST. Other international orders, add $30.

**For Customer Service and CME questions,**

Please call our customer service department at **(800) 688-2421.** For editorial questions or comments, please contact **Shelly Morrow Mark,** Specialty Editor, at shelly.morrow@ahcpub.com or (404) 262-5514.

THOMSON™
AMERICAN HEALTH CONSULTANTS

### Statement of Financial Disclosure

In order to reveal any potential bias in this publication, and in accordance with Accreditation Council for Continuing Medical Education guidelines, we disclose that Drs. Hals, Logan, and Cory (authors), Perron, and Druck (peer reviewers) report no relationships with companies related to the field of study covered by this CME program. Dr. Bosker (editor) is on the speaker's bureau for Pfizer, Rhone-Poulenc Rorer, and Parke-Davis. Dr. Bosker also acknowledges that he receives royalties, commissions, and other compensation relating to the sale of textbooks, reprints of articles, and other written materials to the following pharmaceutical companies: Pfizer, Genentech, Aventis, Pharmacia, and Bayer.

## Evaluation of the Ankle

**Clinical History.** While initially it may seem that the history of an ankle injury may be reduced to "I twisted it," several aspects of the history and exam will provide useful clues that suggest to the emergency physician what injuries to suspect and which to rule out. The patient should be asked what activity he or she was involved in when the ankle was injured. Specific sports put the participant at a higher risk for certain injury patterns. For example, basketball and soccer are a risk for ankle sprain; football causes tibiofibular ligament injuries; and dancing produces stress fractures.[6] Differences even exist among similar sports. Snow skiing traditionally has been associated with high incidence of ankle fracture, but snowboarders actually have a higher overall risk for ankle injury (16% for boarders, 6% for skiers).[7] Signs of more serious injury include: rapid swelling, severe pain, inability to bear weight immediately after the injury, and hearing a "pop" or "crack" in association with the event. Most ankle injuries are inversion injuries, putting stress on the lateral malleolus and ligaments. Patients who describe eversion injuries are at higher risk for deltoid ligament injuries.

**Physical Exam.** The physical exam begins with simple observation of the ankle, looking for obvious deformity, swelling, ecchymosis, and evidence of vascular compromise. When a serious ankle injury with obvious deformity and/or vascular compromise is evident upon presentation, the physician should not become distracted by the injury. It may seem superfluous, but the physician always should remember to rule out life-threatening injuries first in a patient who has a serious ankle injury among other injuries. Some dangerous injuries initially can be occult, and it is easy to be distracted by an extremity amputation or serious vascular injury. Adherence to Advanced Trauma Life Support (ATLS) principles should be the focus at first until higher-priority problems have been ruled out. Do not forget to fully examine the rest of the patient and adhere to ABCs (airway, breathing, circulation) in every case to avoid unnecessary risk for the patient.

The entire lower leg from knee to toe should be exposed to ensure adequate exam and detection of associated injuries. If no obvious trauma is evident, the patient should identify the sites of maximal pain. As with a good abdominal exam, the physician should begin palpation of the ankle away from areas of reported pain and slowly move toward the affected areas. Several areas where bony and ligamentous injury tend to occur more frequently always should be checked: the lateral and medial malleoli, deltoid ligament, talofibular ligaments, syndesmotic ligaments, the calcaneus, and Achilles tendon. The entire tibia and fibula (especially the proximal fibula), and base of the fifth metatarsal also should be examined, as injuries to the "ankle" also can include these areas. Capillary refill should be observed, as well as palpation of dorsalis pedis and posterior tibial pulses. Range of motion can be assessed, and the following are considered normal values: 30-50° of plantarflexion, 20° dorsiflexion, and 25° of inversion and eversion.[6] The patient's ability to bear weight can be tested if the patient is willing and suspicion of serious injury is minimal. The ability to take two unassisted steps with each foot is necessary to state that the patient is able to bear weight.

Finally, ankle injuries in the context of multi-trauma easily can be overlooked. Unconscious or intubated patients are unable to direct the emergency physician with complaints of pain. In completion of the secondary ATLS survey, clinicians should pay attention to notice ankle swelling or deformity that may not have been so apparent on initial presentation. Vascular compromise of the foot or tenting of the skin around the ankle are two indications for immediate reduction of ankle fractures/dislocations. Re-establishment of blood flow is important for obvious reasons, but protection of skin over the ankle also is vital in terms of future ankle repair. Swelling of the ankle can make closure of surgical incisions difficult, and unnecessary loss of this skin only will increase risk of wound dehiscence and infection.

**Stress Tests.** Several specific testing maneuvers exist and are used by orthopedists to evaluate stability of specific ligaments. As with similar tests of the knee, their usefulness to the emergency physician is limited when the patient presents just after the injury. Patients who present several days after an injury are more likely to tolerate the procedures, and therefore, give the examiner useful data. Positive anterior drawer or talar tilt tests are diagnostic of a grade 2 or 3 ankle sprain. (See section on sprains.)

**Anterior Drawer.** The anterior drawer test examines the integrity of the anterior talofibular ligament (ATFL). To perform, place the foot in a relaxed, neutral position while the patient sits with the knee at 90°. Cup the heel with one hand and draw the heel forward by applying a posterior force to the distal tibia with the other hand. A positive test is when the foot can be significantly displaced forward on the distal tibia. This is evident by a difference of 2 mm subluxation compared with the opposite side or a visible dimpling of the anterior skin of the affected ankle.

**Talar Tilt.** The talar tilt test assesses integrity of the ATFL and calcaneofibular ligament (CFL). With the patient in the same position as the anterior drawer test, forced inversion of the foot is performed. A positive test occurs when there is obvious joint laxity compared to the other side, or no passive resistance to forced motion is noted, and indicates rupture of both the ATFL and CFL. The talar tilt test also can be performed with forced eversion, testing the stability of the deltoid ligament.

**Squeeze or Fibular Compression.** The squeeze or fibular compression test assesses integrity of the tibiofibular syndesmotic ligament. To perform, have the patient positioned as before, but with dorsiflexion of foot. The examiner's hands are placed 6-8 inches below the knee and the tibia and fibula are squeezed together. Pain felt in the ankle is considered a positive test and is indicative of injury to the syndesmotic ligaments.[8]

**Thompson's Test.** Thompson's test evaluates the patient for complete Achilles tendon rupture. Place the patient prone with the foot off the end of the stretcher, or with the knee flexed. Squeezing the gastrocnemius and soleus muscles in the mid calf should produce noticeable plantarflexion of the foot. Absences of plantarflexion correlates well with acute (< 1 week) complete Achilles tendon rupture.

**Ottawa Ankle Rules.** The decision process for ordering ankle x-rays has been studied, producing the Ottawa ankle rules in 1993.[9] The Ottawa ankle rules were designed to help the emergency physician improve the efficiency of ankle films. Ankle films make up 10% of all x-rays ordered in the ED.[10] Up to 95% of patients presenting to the ED will have an x-ray done, but only 15% will have identifiable fractures.[11] The Ottawa ankle rules apply only to patients between the ages of 18 and 55 years suffering from acute blunt ankle trauma (e.g., twists, falls, direct blows). The original study found a 28% reduction in ordering of ankle films.[9] The rules specifically were designed to identify fractures of the ankle and midfoot and do not apply to the hindfoot, forefoot, subacute or chronic injuries, other mechanisms of trauma, or pediatric patients. However, recent work suggests Ottawa ankle rules also may be applicable to younger patients, as a study of 1400 patients age 1-15 years found a sensitivity of 98%.[12]

There are three Ottawa ankle rules, and the presence of any one item constitutes grounds for x-ray. *(See Table 1.)* In the first, look for bony tenderness along the posterior edge of the distal 6 cm of either malleolus. In the second, examine for bony tenderness of the navicular or base of the 5th metatarsal. The third rule is met if the patient is unable to bear weight for at least two steps with each foot immediately after the injury and at the time of evaluation. The original study recommended follow-up in 5-7 days for re-examination, as 0.5% of patients not x-rayed were found to have minor fractures on follow-up x-ray.[13] Interestingly, a study by the same authors on cost-effectiveness of applying the Ottawa ankle rules to the United States concluded that use of the rules was still cost-effective even if one factored in dollars lost in expected lawsuits.[14] Given that missed fracture is a common reason for a successful malpractice suit, it seems prudent to make the patient aware that a minor fracture could be present when applying these rules to practice.

**Table 1. Ottawa Ankle Rules**

**THE RULES**

Ankle x-rays are ordered when there is:

- Bony tenderness along the posterior edge or distal 6 cm of either malleolus
- Inability to bear weight for at least two steps with each foot immediately after the injury and at the time of evaluation

Foot x-rays are ordered when there is:

- Bony tenderness over the navicular or at the base of the fifth metatarsal

**THE EXCEPTIONS/LIMITATIONS**

- Rules were developed only for patients age 18-55 years.
- Does not apply to pediatric patients.
- Mechanism of injury only applies to acute blunt trauma.
- Does not apply to subacute or chronic injuries
- Does not apply to injuries of hindfoot, forefoot

## Ankle Imaging

The standard series of plain films obtained for an ankle x-ray includes three views: the AP, lateral, and mortise views. The AP allows identification of fractures of both malleoli, distal tibia and fibula, as well as fractures of the talus and calcaneus. Injuries of

**Table 2. Classification of Ankle Sprains**

| GRADE | SYMPTOMS | SIGNS | EXAMINATION | TREATMENT |
|---|---|---|---|---|
| I | Mild pain, swelling<br>Able to bear weight | Mild swelling | Negative stress test | RICE*<br>Follow-up in < 7 days |
| II | Moderate pain, swelling<br>Difficulty bearing weight | Moderate swelling and echymosis | Anterior drawer (4-14 mm)<br>Talar tilt (5-15°) | Rigid splint<br>Follow-up in < 7 days |
| III | Severe pain, swelling<br>Unable to bear weight | Severe swelling and echymosis | Anterior drawer (>15 mm)<br>Talar tilt (> 15°) | Rigid splint<br>Follow-up in < 7 days |

* Rest, Ice, Compression, Elevation

the syndesmotic ligament also will be evident as widening between the tibia and fibula.

The lateral view shows fractures of the anterior and posterior tibia, talar neck, and calcaneus. Displacement of the talus in relation to the tibia can best be appreciated on the lateral view. Any disruption of the joint space between the talus and tibia indicates an unstable ankle, particularly when narrowing of the anterior joint space is seen.[15] Ankle effusions also best can be seen on the lateral view. Presence of an effusion suggests a subtle intra-articular fracture, such as an osteochondral fracture of the talar dome, may be present.[16] The larger the effusion is, the greater the risk of occult fracture. One study of over 1100 patients found an 82% sensitivity for occult fracture (45% of which were talus fractures) when the effusion measured 13 mm or more of capsular distention.[18] Computed tomography (CT) of the ankle is recommended when subtle fracture is suspected with ankle effusion as misdiagnosis of these fractures can contribute to poor outcome and loss of function of the ankle joint.[17] Rupture of the Achilles tendon also can be seen outlined by soft tissue on the lateral view.

The mortise view is the best view to assess ankle joint spaces. It clearly shows alignment of the articular surface of the tibia and the talus, and also provides isolated views of both malleoli. In general, the width of the space between the articular surfaces (i.e., tibiotalar, talofibular) on the mortise view should be equal and uniform. Unequal joint spaces indicate ligamentous rupture and instability of the ankle joint. Specifically, the medial clear space (the space between the medial malleolus and the medial aspect of the tibia) should be equal to the superior clear space (the space between the talar dome and distal tibia). The ankle joint also is considered unstable if the medial clear space exceeds 4 mm.

Both CT scan and magnetic resonance imaging (MRI) also recently have been advocated for ankle imaging. These imaging techniques have largely replaced bone scans for evaluation after plain films. CT has advantages for bone imaging, is cheaper, and more readily available from the ED. MRI is superior for imaging of soft tissues, including ligaments, tendons, and muscles. MRI now is considered the gold standard by orthopedic texts for evaluation of ankle soft tissue trauma,[18] especially for the injured athlete.[19] Drawbacks of MRI for ED patients include that it is costlier and less readily available than CT. Recently, ultrasound has been used to evaluate soft tissue ankle injuries, including Achilles tendon rupture and other ligament injuries.[20] Advantages of ultrasound are lower cost and ease of access for ED patients, but MRI still provides a greater level of detail for ligament injuries and most authors suggest use of ultrasound only if MRI is unavailable.

## Ankle Sprains

Acute ankle trauma is a common sports-related injury comprising 25% of all sports-related injuries,[3] with up to 75% of these injuries being ankle sprains.[1] Certain sports, notably basketball, volleyball, and soccer, have an especially high incidence of ankle injury, as they involve frequent jumping and sharp cutting maneuvers.[21] Obesity is also a risk factor for ankle injury because it increases joint stress.[22] The true incidence of ankle sprain is impossible to calculate, as many patients self-treat and never present for care. Estimates on the incidence of ankle sprain range from 1 million per year[1] to 23,000 per day (more than 8 million per year).[23] Risk of complication can be high, as up to 40% of ankle sprains may have potential to cause chronic problems.[1]

The vast majority of sprains are inversion injuries of a plantarflexed ankle. As discussed in the anatomy section, stability of the mortise joint is provided by the malleoli when the foot is flat. Plantarflexion maximally reduces the bony support, leaving primarily the lateral ligaments providing protection against lateral motion of the talus in the ankle joint. The ATFL is the most commonly involved ligament and is injured in approximately 80% of inversion injuries.[24] The CFL will be damaged next if deforming forces are strong enough and about 20% of patients will have both ATFL and CFL injuries.[6] The posterior talofibular ligament (PTFL) is the strongest of the three lateral ligaments and is thought to be involved less often in ankle sprain. Injury of PTFL may be underappreciated, as a recent study of 630 ankle sprains found PTFL involved in 30% of cases.[24]

Eversion injuries can tear the deltoid ligament, but isolated tears are rare and seen in only 5% of ankle sprains.[25] The deltoid ligament is not torn as often, because it is one of the strongest ligaments in the body. Most deltoid ligament injuries are avulsion fractures of the medial malleolus. Syndesmotic sprains may be more common than deltoid ligament injuries, and can be missed more easily.

**Classification of Ankle Sprains.** Ankle sprains are divided into the grades I-III, depending on the severity of the injury. *(See Table 2.)* Grade I sprains are mild injuries with minimal pain, swelling, or ecchymosis, and preservation of the ability to bear

weight. Ligaments are stretched without evidence of tearing or joint instability. Grade II sprains are moderate injuries resulting from partial ligament tears. Moderate pain, swelling, and ecchymosis are found, and patients can bear weight with difficulty. Stress tests of the ankle will reveal mild joint instability. Grade III sprains are from complete ligament tears and produce severe pain, swelling, and ecchymosis. Patients are unable to bear weight and marked evidence of joint instability is present. While this grouping is of some use to the ED physician, this system does not apply to sprains involving more than one set of ligaments. Another method is to divide ankle sprains into surgical and non-surgical treatment groups. Grade I and II sprains are treated with brief immobilization until weight-bearing is tolerated, followed by rehabilitation. Grade III sprains can be treated surgically or conservatively followed by surgical intervention for chronic ankle instability.

**Ankle Sprain Assessment.** Plain x-rays should be ordered using the Ottawa ankle rules as a guide. *(See Table 1.)* As mentioned above, the rules are designed to make ordering plain x-rays for ankle injury more accurate and efficient. X-rays are ordered if any of the following three conditions are met: bony tenderness over either malleoli, navicular or proximal fifth metatarsal, or inability to bear weight. X-ray findings consistent with ankle sprain include chip avulsion fractures at the base of either malleolus; at the lateral process of the talus, lateral calcaneus, or lateral aspect of the distal tibia; or at the base of the fifth metatarsal. Widening or asymmetric appearance of the ankle joint (especially on the mortise view) is a sign of significant ligament tear. The medial clear space should be equal to the superior clear space, and the ankle joint also is considered unstable if the medial clear space exceeds 4 mm.

Stress x-rays also can be done, but normally are not ordered in the ED. They may be useful in evaluating a chronic or subacute injury in consultation with the orthopedist. Talar tilt may be measured on x-ray when lateral or medial stress films are taken. Typically, a 4 kg weight is applied to force the ankle into inversion and plantar flexion or eversion (less common). An x-ray is taken and a line drawn across the talar dome and end of the tibia. If the degree of lateral opening is greater than 5 mm, or twice that of the normal ankle, talar tilt is present. The same angle applies to inversion stress to test the stability of the deltoid ligament.

Dynamic stress testing of ankle ligaments can be done to further evaluate for ligament damage. Most patients presenting to the ED with acute ankle sprains will not benefit from stress testing in the ED. It can be very painful and is unlikely to alter ED management. Patients whose diagnosis of an acute ligament injury will alter early management represent exceptions to this statement. Examples include: a competitive athlete who may undergo primary repair; complete rupture of multiple ligaments; syndesmotic ligament rupture; or ankle fracture where addition of a ligament rupture will prompt surgical intervention.[6] A positive anterior drawer test indicates ATFL rupture, a positive talar tilt test indicates ruptures of both ATFL and CFL, and a positive squeeze test indicates damage of the syndesmotic ligament.

**Avoiding Misdiagnosis.** The term "ankle sprain" is a generalized term typically used by patients to describe inversion injuries of the ankle. Most patients and some physicians may only think of ligament injuries in association with an ankle sprain. While ligament injury is common, many other ankle structures can be affected by a "sprain." *(See Table 3.)* A study of 639 patients presenting with complaint of a sprain found 15% had identifiable fractures.[24] Of the remaining patients, 83% had lateral ligament injuries, but other important injuries were not rare. The authors also found 33% with joint capsule injuries, 20% with tendon injuries (extensor digitorum brevis and peroneal tendons), 12% with Achilles tendon injury, and 5% with syndesmosis injury.[24]

Although not possible in every case, it is important for the emergency physician to try to avoid misdiagnosing patients with only ligament injury when other, more serious damage is detectable though a careful physical exam. Isolated ligament trauma typically produces pain and tenderness only over the lateral or medial aspect of the ankle. Most patients are unable to provide details about the position of the ankle at the time of injury, but when available, this information can direct the ED physician to injuries besides lateral ligament tears. Complaints of pain or findings of tenderness on exam in other locations should raise strong suspicions of other injuries. Location of pain or tenderness on the posterior aspect of the ankle is a strong clue for Achilles tendon damage. Forced dorsiflexion followed by a "pop" may indicate a peroneal tendon injury or displacement. (See tendon injury section.)

Eversion mechanisms suggest deltoid ligament injury or syndesmotic ligament injury. Location of pain over the anterior ankle further implicates a syndesmotic injury. Suspicion of a syndesmotic injury also can be heightened by the squeeze or fibular compression test. Production of pain along the fibula by this maneuver suggests syndesmotic ligament injury or fibular fracture. Tenderness on palpation of the deltoid ligament requires full examination of the length of the fibula to ensure detection of a proximal fracture (Maisonneuve's fracture). Finally, careful exam of the foot and leg also is recommended to detect associated injuries (proximal fifth metatarsal fracture, proximal fibula fracture, etc.).

Perhaps the most potential devastating injury masquerading as a sprain is an occult fracture of the talar dome. Initially, these fractures often are managed with a simple short leg cast and non-

**Table 3. Differential Diagnosis of Ankle Sprain**

**COMMON, MORE EASILY DIAGNOSED AND TREATED**

- Lateral collateral ligament injury
- Fracture of base of the fifth metatarsal
- Achilles tendon injury

**LESS COMMON, MORE DIFFICULT TO DIAGNOSE AND TREAT**

- Medial collateral (deltoid) ligament injury
- Syndesmosis ligament injury
- Talar dome fracture
- Talar neck fracture
- Fracture of posterior process of the talus
- Fracture of lateral process of the talus
- Fracture of anterior process of the calcaneus
- Tendon injury

weight-bearing instructions for only four weeks.[28] Unfortunately, delays in treatment can lead the patient to surgical treatment and potential long-term disability instead. Even more unfortunately, numerous difficulties exist with ED diagnosis of talar dome fractures. To begin with, talar dome fractures in general are not common.[27] While major fractures are highly associated (86%) with multiple trauma and less likely to be missed,[28] this is not the case with minor fractures. Many subtle talar fractures can be difficult to detect clinically, as tenderness on exam is located around either malleoli, which are common sites for ligament injury. Further, defects seen on plain films can be trivial or even non-existent on initial evaluation in the ED. Ultimately, many subtle talar fractures will be diagnosed only on follow-up with CT or MRI imaging. Thus, the ED physician is left with the unsatisfying reality that detection of these fractures may not be possible in many cases. Consistent splinting of every patient who cannot bear weight or who has significant swelling and pain on initial exam combined with follow-up, currently is the best method to deal with this problem. (See sprain treatment section.) Alternatively, orthopedic consultation for outpatient or ED CT scans in select patients with high suspicion may help make this difficult diagnosis.

Ultimately, unless an MRI is obtained on every ankle sprain, no one can attain 100% accuracy in ED evaluation of ankle sprains. The take-home message is that physicians should recognize which patients are at higher risk for an occult injury and be careful not to miss easily diagnosable injuries (i.e., Achilles tendon rupture) due to a lack of a thorough history and physical exam. Any patient with significant symptoms on presentation should be told there is a risk for fracture or other more serious injury that only can be detected and treated on follow-up with the orthopedist. The importance of follow-up should be stressed, the risk of long-term disability underscored, and brief document of this discussion added to the chart. Hopefully, patients given this information will remember the ED visit with "my doctor told me something else could be wrong" instead of "the first doctor missed the diagnosis" when an occult fracture or other serious injury is found on follow-up.

**Treatment of Ankle Sprain.** *Lateral Sprains.* Fortunately the majority of ankle sprains will heal well without residual problems with simple treatment. The mainstays of ED treatment for lateral ankle sprains are NSAIDs and RICE (Rest, Ice, Compression, and Elevation). General rules for treatment can be based on the grade of the sprain. *(See Table 2.)* Grade I sprains, where the patient can tolerate weight bearing and has mild symptoms, should respond well to NSAIDs and RICE. They can be referred to their primary care physician or instructed to follow up with an orthopedist if symptoms do not improve as expected. It is important to instruct these patients on performance of daily range of motion exercises to promote proper healing and maintenance of proprioception. Dispersal of edema, maintenance of muscle tone, and the prevention of adhesions will result if exercises are employed.

Grade III sprains often are difficult to differentiate from severe Grade II sprains because swelling, ecchymosis, and pain can significantly limit the exam. Fortunately, Grade II and III lateral sprains are treated in a similar fashion in the ED, although it is crucial to stress to the patient that Grade II and III lateral sprains are approached differently by the orthopedist. Unless the ED physician has made a firm diagnosis (i.e., by MRI), he or she should refrain from specific predictions concerning the care by the follow-up orthopedist. While Grade I and II injuries are treated in similar fashion by the orthopedist, some authors use surgical approaches to Grade III injuries.[29] Surgical treatment of acute lateral ankle sprains remains controversial, with the latest reviews still unable to clearly distinguish which patients may benefit from surgical intervention.[30] Most authors state that 80-90% of grade III injuries do well when treated non-operatively.[31] Further complication is shown by studies indicating delayed surgical repair has been shown to have functional results similar to primary repair.[31] The only patients in whom repair is considered are athletes with severe unstable sprains, defined by greater than 10 degrees talar tilt, clinical drawer sign, complete tears of both ATLF and CLF, presence of an osteochondral fracture, or a widened mortise.

Immobilization and crutch use for the first 48-72 hours of any ankle sprain where the patient has difficulty bearing weight in conjunction with crutch use is recommended for the first 48-72 hours after the injury. Use a fiberglass or plaster splint, or a pneumatic brace (air cast) could be used. These patients all should have orthopedic referral within one week for further evaluation and treatment. It is important that the patient understand he or she should not keep a splint or air cast on for more than seven days unless instructed by the orthopedist. Longer periods of immobilization are associated with increased stiffness and disability.[32] The time each patient will need to be non-weight bearing is highly variable. Some patients may do well with a few days of crutch use, while others may need several weeks. In general, early mobilization and functional treatment of these injuries has been shown to get the patient back to work and normal activities.[33] This also has been confirmed by a meta-analysis of available data.[34] Once the patient can bear weight, they should begin strengthening exercises to help return to full function.

**Medial and Syndesmotic Sprains.** Medial and syndesmosis sprains are important exceptions to the above discussion. Though these ankle injuries are less common than the typical lateral ankle sprain, it is important not to overlook them. Their treatment is more complicated and prolonged compared to lateral sprains, and the potential for disability is much higher. Many of these injuries have delayed diagnosis and are significant sources of chronic ankle pain and instability. It is these patients who should be kept in mind when evaluating "just another ankle sprain" in the ED.

Isolated medial ankle or deltoid sprains are rare, as most patients with these injuries also have lateral ligament, fibular fractures, or syndesmotic injuries as well.[32] Treatment of a deltoid sprain depends on the associated injury. The deltoid ligament may be surgically repaired if surgery is performed on an associated fibular fracture or syndesmotic ligament injury, but this is controversial. Most authors recommend braces/crutches for Grade I deltoid injuries like lateral sprains, but the recovery time usually is longer than for lateral sprains. Grade II and III deltoid sprains are immobilized for 6-8 weeks in a walking cast,

which is very different from treatment of similar lateral sprains.

Syndesmotic sprains (a.k.a. "high ankle sprains") have been estimated to occur in 1-10% of all ankle sprains,[35,36] but produce more disability and greater lost playing time for athletes than lateral ankle sprains.[37] The incidence of syndesmotic sprains may be much higher for contact sport participants than for the general population. One study found 32% of professional football players attending a training camp had calcification of the distal tibiofibular syndesmosis, suggesting previous injury.[38] As another study of 60 college athletes with known syndesmotic sprains found that, after six months, only one of the 60 had ossification of the syndesmotic ligament,[39] the incidence in profession athletes could be even higher than 32%. Thus, any participant in a high-impact sport complaining of ankle injury should prompt an evaluation for syndesmotic injury. The mechanism of injury most likely to cause syndesmotic injury is external rotation. Inversion can produce injury as well, but only after the deltoid ligament has failed. Diagnosis of deltoid ligament injury should raise the possibility of syndesmotic sprain, as well. Some patients may be ambulatory after injury but complain of pain on pushoff or dorsiflexion.

Although much is written about syndesmotic ligament injuries in connection with ankle fractures, relatively little exists in the literature about syndesmotic sprains. The syndesmotic complex is composed of three tibiofibular ligaments (anteroinferior tibiofibular [AITF], posteroinferior tibiofibular [PITF], and transverse tibiofibular), and an interosseous ligament. The AITF ligament provides the greatest stability to the syndesmosis and is the most frequently injured. On physical exam, the squeeze test (squeezing the fibula at mid calf) is positive if pain is elicited at the syndesmosis. Even severe sprains may have little swelling. Evidence of diastasis on plain films may be present when the medial clear space (space between lateral aspect of medial malleolus and medial aspect of the talus) is greater than 4 mm, but MRI is the gold standard for diagnosis.

Treatment depends on the degree of injury, something that may not be well defined during the ED visit. Syndesmotic injuries are graded on the degree of diastasis, and patients with obvious diastasis on plain films are treated surgically as soon as the soft-tissue swelling allows. Thus, even when the need for surgical repair is evident on the ED visit, most patients will be splinted, given RICE recommendations without weight bearing, and referred to the orthopedist. Patients treated conservatively usually are made non-weight bearing and casted for four weeks. Complete recovery and return to full sports participation may take up to 12 weeks for mild sprains and six months for complete tears, which is twice as long as for return following lateral ankle sprains.[5]

**Outcome of Ankle Sprains.** Even with proper treatment and rehabilitation, chronic complications from ankle sprains are not unusual. Estimates quoted for chronic symptoms are usually in the 10-30% range.[40] The rates increase to 40% of patients for the six-month period immediately following the injury.[5] Interestingly, the grade of ankle sprain does not always predict the risk of chronic problems, as one author found no difference between Grade I and II sprain complications in a population of young healthy adults.[5] Common complications include the following: chronic pain, ankle stiffness, recurrent swelling, tendonitis, and mechanical and functional instability. Unusual complications also can occur, including false aneurysms of the peroneal artery,[41] peroneal nerve injury,[42] and talar dome necrosis.[43] With the high number of ankle sprains per year (up to 8 million), patients may present to the ED with sub-acute or chronic ankle pain and without having undergone previous evaluation for their injury. Although treatment of ankle sprain complications will be done by the consultant, it is important to be aware of the general approach to ankle sprain complications.

Chronic ankle pain can result from soft-tissue problems, such as synovial impingement (anterior impingement syndrome), loose bodies in the joint, and peroneal tendon subluxation. Bony problems include osteochondral fractures of talar dome or fractures of lateral or posterior process of the talus (see section on talus fractures), and fractures of the anterior process of the calcaneus (see section on calcaneus fractures). CT scan or MRI often is needed to accurately diagnose subtle talar or calcaneal process fractures, and should be ordered in consultation with the orthopedist. MRIs, especially, are expensive and should not be routinely ordered by the ED physician, as the reading likely will not be available at time of patient disposition. Loose bodies require MRI or even arthroscopic surgery for diagnosis and treatment. These patients will complain of intermittent "catching and locking" of the ankle joint with normal activity. Unfortunately, removal of the loose body does not always solve the clinical complaints. Symptoms can persist due to degenerative or post-traumatic arthritis caused by the loose body prior to removal.

Ankle impingement syndromes actually can occur at five different locations: anterior, medial, posterior, anteriolateral, and syndesmotic. While often caused by trauma, they also can occur from infection, arthritis, rheumatic disorders, or even be congenital in origin. All syndromes are similar in that, following ankle sprain/injury, repetitive motion of an incompletely healed ligament produce inflammation of the ligament ends. This produces scar tissue at the ligament end. Hypertrophy of the soft tissue leads to entrapment/impingement of this soft tissue between two bones. The two bones can be the tibia and fibula or between a bony process on one of these bones. Simple synovitis also can occur after sprain and can produce similar symptoms to impingement syndrome. The ED physician will not be able to differentiate these two entities, but the example is given to show how complicated evaluation of chronic ankle can become.

Anterior impingement syndrome refers to soft-tissue impingement of tissue around the ATFL, and can develop after ATFL sprain. It is the most common of the ankle impingement syndromes, as lateral sprains are the most common type of sprain. Posterior impingement results from entrapment of soft tissue by the os trigonum or an accessory ossification centre in the posterior border of the talar bone. These accessory ossification centers actually can occur in a number of sites of the foot and ankle, and may not cause a problem in most patients. Up to 50% of normal ankles have an os trigonum. Patients will be tender over the site of impingement and have limited range of motion. Injection of local anesthetic over the area of impingement with complete relief of

**Table 4. Orthopedic Consultation of Ankle Fractures**

| |
|---|
| **EMERGENT (PATIENT NEEDS TO BE SEEN QUICKLY IN THE ED)*** |
| • Open fracture |
| • Fracture/dislocation with vascular compromise |
| • Fracture/dislocation with tenting of skin |
| **RECOMMENDED (PATIENT OFTEN IS ADMITTED FOR REPAIR)** |
| • Tillaux and triplane fractures |
| • Intra-articular fractures with displacement |
| • Pilon fractures* |
| • Trimalleolar fractures |
| • Maisonneuve fractures |
| • Any fracture with significant disruption of the mortise |
| **RECOMMENDED (PHONE CONSULTATION MAY SUFFICE)** |
| • Bimalleolar fractures |
| • Minimally displaced medial or lateral malleolar fractures* |

* Reduction by ED physician advised if orthopedist not immediately available.

symptoms is said to be diagnostic. MRI may or may not show evidence of impingement,[44] but arthroscopy is both diagnostic and therapeutic. Non-surgical treatments include NSAIDs, steroid injection, and casting to reduce soft-tissue swelling. Arthroscopic surgery to remove the accessory ossification center and/or inflamed soft tissue is recommended when non-surgical techniques fail and has been shown to be successful in more than 85% of cases.[45]

Functional instability refers to the patient's feeling that the ankle "gives out" during normal activity and can be associated with repeated sprains.[46] While the patient may complain of the same symptoms, functional instability is not the same as mechanical instability. Mechanical instability occurs when the ligaments permit ankle joint movements beyond normal physiologic limits. In contrast to mechanical instability, where actual ligamentous laxity can be demonstrated by stress tests or stress x-rays, patients with functional instability will have normal tests. Although not fully understood, most authors propose that functional instability is caused by neuromuscular deficits that occur in some patients from ankle sprain. These deficits include loss of proprioception, muscle strength, muscle reaction time, and postural control,[47] which combine to produce the patient's feeling of ankle instability. Unfortunately, the perception of ankle instability can produce repeat injury in the same fashion that actual mechanical instability will. Functional instability is treated by a combination of muscle strengthening, ankle tilt boards to re-establish muscle coordination, and use of ankle braces. The ED physician needs to be aware that functional instability exists so that patients are properly referred even if stress test and x-rays are normal for patients complaining of chronic ankle instability.

**Prevention of Ankle Sprain.** Ultimately, prevention of injury is the best treatment for ankle sprain. Multiple approaches have been proposed and used including: ankle taping, commercial ankle supports or orthotics, strengthening exercises, and functional rehabilitation. A review for the Cochrane Database of more than 8000 patients from 14 randomized studies found that use of external ankle support provided the greatest decrease in number of ankle sprains.[48]

While certainly not all people make use of these devices, patients who are being treated for an ankle sprain while playing a sport should be reminded of several facts. First, they are at risk for re-injury. An analysis of 113 studies supported the intuitive fact that the number one risk factor for an ankle sprain in sports is history of a previous sprain.[21] While seemingly obvious, it is important to point out that re-injury especially can be dangerous when the joint has not yet completely healed. The patient should be reminded that depending on the injury, the ankle may take up to six months to fully recover, and that use of preventative measures during that time will allow the athlete to play while potentially protecting the ankle at the same time.

## Ankle Fracture

Ankle fractures are one of the most common fractures orthopedic surgeons treat,[49] and therefore are common occurrences in the ED. Of the estimated 8 million ankle injuries per year,[31] up to 15% (1.2 million) will be ankle fractures. The ankle joint is highly susceptible to injury, as it is a relatively mobile joint, but at the same time must support the entire body weight. The ankle joint actually supports more weight per unit area than any other joint in the body. During exercise, the stress on the ankle joint may be up to five times the body weight. It comes as no surprise, then, that obesity is now recognized as a risk factor for ankle injury. A recent article found a relationship between higher body mass index and severity of ankle fracture from low-velocity injuries.[22] Another article found that smoking also was a risk factor for fracture in peri-menopausal women.[50] Other risk factors for ankle fracture include participation in sports (i.e., basketball, football, soccer), sports where the foot is fixed in a boot (i.e., skating, snowboarding), and being a post-menopausal woman or a pre-adolescent. In general, males experience a higher incidence of ankle fracture, 2:1 compared to females. It is important to remember that ankle fractures are not just bony injuries, but also injuries of the ankle ligaments and other soft tissues.

In general, treatment of ankle fractures is determined by whether the fracture is open or closed, displaced or non-displaced. A non-displaced closed fracture with an intact mortise usually is casted for six weeks. Disruption of the mortise alignment is treated by open reduction internal fixation (ORIF) to achieve anatomic reduction. The relationship of the talus to the tibia and fibula is sensitive to even 1-2 mm shifts, and lateral alignment appears to be more critical than medial alignment. One study on cadavers found that a 1 mm lateral shift of the talus results in reduction of the contact area of the ankle by 42%.[51] Table 4 summarizes when orthopedic consultation for ankle fracture is recommended. Only truly emergent conditions and cases where reduction is required necessitate that the orthopedic surgeon come to the ED for patient evaluation/treatment. In many other cases (stable non-displaced malleolar fracture, etc.), phone

consult is enough to get the consultant's recommendations and to ensure timing of follow-up. Patients also should be discharged with appropriate pain medications. A suggestion is to give NSAIDs in combination with narcotics. Narcotic tablets (i.e., Percocet, Vicodin) have the option of being cut in half, giving the patient maximal control by having a variety of medication combinations to choose from.

**Classification of Ankle Fracture.** Ankle fractures typically are classified by one of two systems: Lauge-Hansen and Danis-Weber schemes. The Lauge-Hansen system was developed in 1950 and divides ankle fractures into five different types based on the position of the foot during injury and the forces involved. This system is useful because the opposite force that produced the injury must be used to reduce it. The Lauge-Hansen system divides ankle fractures into the follow categories: supination/eversion (Weber type B), supination/adduction (Weber type A), pronation/eversion (Weber type C), pronation/abduction, and pronation/dorsiflexion.

The Danis-Weber system was introduced in 1988 and divides fractures based on the level of the fibular fracture and the level of syndesmotic disruption. *(See Figure 1.)* The higher the fracture, the more likely it is to be unstable. Type A fractures have fibular fractures at or below the joint line without syndesmotic involvement. Type B fractures have fibular fractures at the joint level with partial syndesmotic ligament injury. In Type C fractures, the fibular fracture is above the joint level and there is complete syndesmotic disruption. Type C fractures can be further subdivided into diaphyseal fractures of the fibula (Dupuytren fracture) or proximal fibular fractures (Maisonneuve fracture).

**ED Treatment—Emergent Conditions.** When treating an ankle fracture in the ED, the physician must be aware of several key points. Once life-threatening injuries have been addressed, open fractures, dislocated ankles, tenting of skin, and vascular compromise are situations in which urgent action is required of the ED physician. All of these situations require emergent consultation by the orthopedist, but the reduction should be performed by the ED physician if the orthopedist is not urgently available. Unless being moved to the operating room for reduction, the patient should not leave the ED for films or other tests without reduction first. Likewise, patients should have attempts at reduction before transfer to trauma centers. As some injuries will not be reducible outside the operating room (OR), it is important to document and communicate to the consultant that attempts at reduction were performed.

*Vascular Compromise.* Severe fractures and dislocations of the ankle easily can produce vascular compromise by vessel injury and compression. A foot with inadequate perfusion is a true surgical emergency. Reductions should be performed with adequate anesthesia/sedation immediately after addressing life-threats (i.e., after finishing secondary survey). Plain films taken before reduction may be helpful, but should not significantly delay reduction when vascular compromise is present.[52] Reduction of the ankle will restore adequate blood flow in most cases. If perfusion still is not sufficient after reduction, or if reduction is not possible, emergent intervention by the consultant may avoid an amputation.

**Figure 1. Danis-Weber Ankle Fracture Classification**

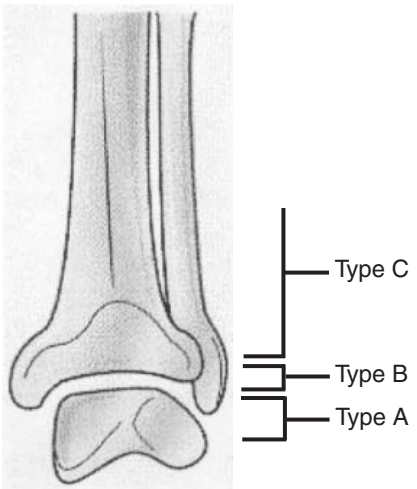


**Type A** fibular fractures are below the joint line and usually are treated with casting alone. **Type B** fractures are at the joint line and may or may not have associated syndesmotic ligament injury. **Type C** fractures occur above the joint line and do have associated syndesmotic ligament damage requiring surgical repair.

Adapted from Pemdatabase.org. Foot and ankle fractures, Power Point presentation. www.pemdatabase.org/files/Foot_and_Ankle_Fractures2.ppt. Accessed 9/15/2003.

Attempts at restoration of blood flow should be thought of in terms of minutes after presentation so the need for surgical restoration of perfusion can be recognized as soon as possible.

*Skin Tenting.* Injuries in which displaced bone causes tenting of skin should be considered the next critical issue after addressing blood flow. Unnecessary injury to skin over the ankle results from continued tension on the skin from underlying bone. Preventable ischemic skin damage over an ankle fracture can drastically alter the orthopedist's surgical plan by delaying definitive treatment because surgical incisions cannot be closed. Reduction usually restores normal bone position and stops tenting of skin. One should achieve reduction or notify the consultant to have this accomplished in two hours or less from presentation to prevent further skin damage.

*Open Fractures.* Open ankle fractures are not rare occurrences, and are another example of when the ED physician needs to take immediate action. Up to 60% of these injuries result from motor vehicle accidents (MVAs) and another 10% from gunshot wounds.[53] The most common laceration seen with an ankle fracture is at the level of the medial malleolus combined with posteriorlateral displacement of the foot.[49] The medial malleolus usually is avulsed and the articular surface of the tibia protrudes from the wound. Open fractures generally are classified into one of three types.[54] This classification is based on contamination and the extent of soft-tissue injury. The most important prognostic feature of an open fracture is amount of energy absorbed by the soft tissues surrounding the fracture.

Type I open fractures have clean wounds smaller than 1 cm and minimal soft-tissue injury. These are the most common type

of open fracture, accounting for 60% of these injuries.[55] Type II open fractures have moderately contaminated wounds larger than 1 cm but smaller than 10 cm and moderate soft-tissue injury. Type III open fractures have grossly contaminated wounds greater than 10 cm with either severe soft-tissue damage (Type IIIa), soft-tissue loss (Type IIIb), or soft-tissue loss combined with vascular injury (Type IIIc). Fortunately, Type III fractures account for only 10% of open fractures. The type of open fracture will predict the risk of infection. Type I open fractures carry a 2% risk of infection, Type II an 8% risk, and in Type III open fractures the risk is 29%.[55]

Before reducing an open fracture, first quickly but effectively irrigate the exposed bone and remove any gross contamination. If not being reduced immediately, the open wound still should be irrigated with removal of gross debris and then covered with a moist, sterile dressing. Tetanus immunization should be given when indicated. All patients with open fractures should receive appropriate antibiotics in the ED. The combination of antibiotics used depends on the degree of soft-tissue injury and contamination. Type I open fractures should be given a broad spectrum cephalosporin such as cefazolin (1 gram IV for average adult). Type II or III open fractures should have addition of an aminoglycoside (gentamycin 5 mg/kg IV adult loading dose). Penicillin G (4 million units for average adult) should be added for triple coverage in soil/farm contamination to treat for *Clostridium perfringens*.[56] In general, once the patient leaves the ED, the consultant will clean and debride in the OR, perform an ORIF, and close the soft tissue after infection has cleared. Type I and II open fractures often do well with this regimen. Surgery combined with early, appropriate antibiotic therapy leads to good to excellent results in 87% of grades 1 and 2 fractures. Grade 3 fractures have poor results because of extensive bone and soft-tissue injury with resulting articular damage, vascular compromise, and deep infection.

*Lateral Malleolar Fractures.* Lateral malleoli fractures are the most common type of ankle fracture in the United States.[25] Reasons for this include that the fibula provides the primary resistance to external rotation forces in the ankle, and that inversion injuries that stress the fibula are the most common type of ankle injury. Patients usually have clear findings on physical exam (point tenderness, swelling, ecchymosis over lateral malleolus) and plain ankle films are sufficient for diagnosis in most cases.

The key feature in these fractures is the location of the fracture relative to the tibiotalar joint. Fractures distal to the joint usually do not have any associated ligament or bony injury, and therefore, do not affect the stability of the ankle joint. These fractures can be treated with splinting in the ED and 6-8 weeks in a cast. Even with these relatively benign fractures, most orthopedists will recommend non-weight bearing for the first three weeks. The importance of non-weight bearing always should be documented and stressed to the patient.

When the fracture line is at or near the joint level, one should be very careful to assess for associated injuries, as 50% of cases have syndesmotic injury.[57] Any medial or anterior findings of tenderness, swelling, or ecchymosis are important evidence of a more serious fracture. Even if the plain films are negative for bony injury, swelling and tenderness over the medial side indicates a deltoid ligament injury. When medial injuries are present, biomechanical disruption of both malleoli, a condition that often requires surgical repair, is likely.

When the fibular fracture is above the tibiotalar joint line, the syndesmosis and medial ligaments almost always are involved (Danis-Weber Type C). A recent series of 32 Type C injuries underscores the severity of these injuries. Many cases did not heal easily, with 19% requiring grafting for non-union, and fully 29% only had fair or poor results from surgical treatment at the end of the study.[58] Consultation with the orthopedist is recommended in cases where associated injuries are evident. Surgical repair is essential to provide anatomic reduction of these fractures. A cadaver study found that when the fibula was shifted only 1 mm laterally, this translated to a 42% decrease in tibiotalar contact.[51]

*Medial Malleolar Fractures.* Isolated medial malleolar fractures are relatively rare, and usually occur with another injury (see Bimalleolar fractures). Injury is produced from pull of the talus laterally on the medial malleolus during forced eversion or external rotation. It also can occur from direct impact of the talus on the medial malleolus. The deltoid ligament is so strong that the medial malleolus usually is fractured before the ligament tears. Because of the force involved and the fact that isolated medial malleolar injuries are rare, one should diligently seek another area of injury in these patients. Distal fibular fractures (Bimalleolar fractures), proximal fibular fractures (Maisonneuve fractures), and talar fractures commonly are seen. The treatment of isolated medial malleolar fractures is controversial. Non-displaced fractures usually are treated with closed reduction and casting for six weeks. Unfortunately, high non-union rates (up to 15%) are seen in patients treated with closed reduction.[59] Any displacement of the mortise is treated with ORIF.

*Bimalleolar Fractures.* While unimalleolar fractures can be stable, bimalleolar fractures are by definition unstable. There can be two fractures or a single malleolar fracture combined with complete ligament rupture on the other side. Thus, the ED physician carefully should evaluate a patient with an isolated malleolar fracture to rule out an additional ligament rupture on the opposite side. Look for soft-tissue swelling, bruising, or tenderness over the uninjured malleolus. Also, look carefully for signs of a widened mortise on plain films. Any patient with pain/swelling of the opposite side of a malleolar fracture should be considered a bimalleolar equivalent until cleared by the consultant. Further, syndesmotic injury also is common with bimalleolar fractures. Some isolated malleolar fractures may be treated closed, but most bimalleolar fractures will require surgery for proper healing.[60] The orthopedic surgeon should be consulted in treating a patient with a bimalleolar fracture or equivalent injury. Patients who do not need reduction should be stable for discharge after splinting and made non-weight bearing.

*Trimalleolar Fractures.* The trimalleolar fracture first was described by Henderson in 1932,[61] and is among the more severe closed ankle fractures. The medial and lateral malleoli are fractured, as well as the "posterior" or third malleolus, the posterior

lip of the distal tibia. The fractures result from severe external rotation or abduction forces. The posterior lip fractures result from avulsion of the posterior-inferior tibiofibular ligament or from direct pressure of the rotating talus. Only when this fracture involves 25% or more of the tibial articular surface or when greater than 2 mm displacement is seen on lateral plain film will the posterior lip fracture itself require pinning. While patients often will be splinted and sent home with adequate analgesia and no weight-bearing instructions, all cases of trimalleolar fracture at least should have phone consult by the orthopedist while the patient is in the ED.

*Pilon Fractures.* The term pilon is French for "hammer," and Desot first coined the term "hammer fracture" in a description of the talus being driven into the tibial plafond to produce a pilon fracture.[6] On plain films, the tibial plafond (flat area between the malleoli over the talus) will be fractured and often displaced. The actual fracture pattern may vary depending on if the foot was in dorsiflexion, neutral, or plantarflexion at the time of injury. Pilon fractures constitute 1-10% of all tibial fractures,[62] and 25% are open fractures.[63] They often are caused by high-energy mechanisms, including MVAs or falls from height. When detected in these patients, be aware that associated injuries, such as calcaneal, talar dome, tibial plateau, femoral neck, acetabular, and lumbar vertebral fractures often are present. High-energy pilon fractures are associated with significant soft-tissue damage, comminution, loss of ankle joint architecture, and leg shortening.[6] The fibula is commonly fractured as well. Low-energy pilon fractures also occur, and are spiral in nature with little comminution and few intra-articular fragments. The fibula may not be fractured. Sports in which the ankle is fixed in a boot, such as skiing or roller blading, can produce these injuries.

Emergent orthopedic consultation is required for pilon fractures, and if stable, some patients may need to be transferred to a referral center for definitive care. Several approaches exist for pilon fractures, including external fixation, percutaneous plating, combined internal and external fixation, and formal ORIF.[64] Unfortunately, even with early and appropriate intervention, many high-energy pilon fractures do poorly. The complication rate following ORIF for pilon fractures is 10-55%.[65] Soft-tissue complications include skin necrosis leading to grafting and flap coverage, and infection leading to osetomyelitis. Nonunion rates vary from 25% to 100% with the most severe fractures,[66] and require bone grafting to salvage ankle function. Malunion rates are also high, up to 42% in some series.[67] If anatomic reduction of the fracture fragments is not possible, it is expected that 100% of these patients will experience post-traumatic arthritis.[68] Cartilage damage and avascular necrosis of subchondral bone are also common in pilon fractures and cause post-traumatic arthritis in many patients who achieve good reduction. Patients with severe swelling are at increased risk for compartment syndrome. Pilon fractures are among the most severe ankle fractures, and the ED physician should take extra time to explain the severity of this injury to these patients.

*Maisonneuve Fracture .* The Maisonneuve fracture is a combined injury of a medial malleolar fracture (or complete deltoid ligament tear), tear of the syndesmotic ligament and interosseus membrane complex, and proximal fibular fracture. Typically, the injury begins with the medial malleolus, and the plane of force then travels through the interosseus membrane and up the leg to the proximal fibula instead of going transversely across the ankle. They are named for the French surgeon who used cadavers to demonstrate how rotational forces applied to the ankle could disrupt the interosseus membrane and fracture the proximal fibula. Such an extensive injury often carries a bad prognosis without proper surgical intervention. The mortise architecture is lost as the fibula shifts laterally without the support of the syndesmotic ligament. Proximal fibular fractures also can damage the common peroneal nerve that supplies the tibialis anterior (foot dorsiflexion) and sensation to the first web space. Patients with Maisonneuve fractures should have documentation of a good neurovascular exam, with attention to dorsiflexion and sensation.

Unfortunately, Maisonneuve fractures are relatively easy to miss and they are not rare. In one series, Maisonneuve fractures accounted for 1 of 20 ankle fractures.[69] The patient typically presents complaining only of ankle pain, and the proximal fibula can have few, if any, findings on physical exam.[70] The initial ankle film may only show the medial malleolar injury if diastasis is either not yet present or subtle. Any disruption of the syndesmotic ligament (diastasis) noted on plain films is a strong clue for Maisonneuve fracture. As isolated medial malleolar or deltoid ligament injuries are rare, most authors recommend a tib-fib x-ray to examine the proximal fibula for fractures when isolated medial injuries are diagnosed. Likewise, diagnosis of a spiral proximal fibula fracture should prompt evaluation of the ankle for the other half of the injury. Maisonneuve fractures can be treated without surgery if the mortise is intact, but most will require syndesmotic screw(s) for repair.[71] Any diastasis noted on initial plain films means the mortise is unstable, and surgical repair is indicated.

**Ankle Fracture Complications.** There are many complications that may follow an ankle fracture. Examples include malunion, nonunion, chronic pain, traumatic arthritis, avascular necrosis, chronic instability, fracture blisters and skin necrosis from swelling, compartment syndrome, etc. Patients who undergo surgical repair also face possible post-surgical complications such as wound infection and osteomyelitis. In general, the more damage done to the bones and soft tissues, the more likely complications will develop. For example, high-energy pilon fractures are very high risk for soft-tissue healing problems and arthritis. Fractures in older patients do not heal well, as expected. Unlike hip fractures, ankle joints are not routinely replaced to restore function. Ankle fractures in elderly patients often result in social complications, including loss of independence and mobility.

Traumatic arthritis is probably the most common complication, and results from damage to cartilage and other soft tissues that occur at the time of injury. Osteochondral disruption of the talar dome or tibial plafond articular surfaces often occurs in association with ankle fractures, but will not be detected without MRI or arthroscopy. Damaged cartilage does not repair itself, and once its original shape is altered, bones grind against each other. Friction

**Figure 2a-b. Two-Part Triplane Fracture (2a) and Three-Part Triplane Fracture (2b)**

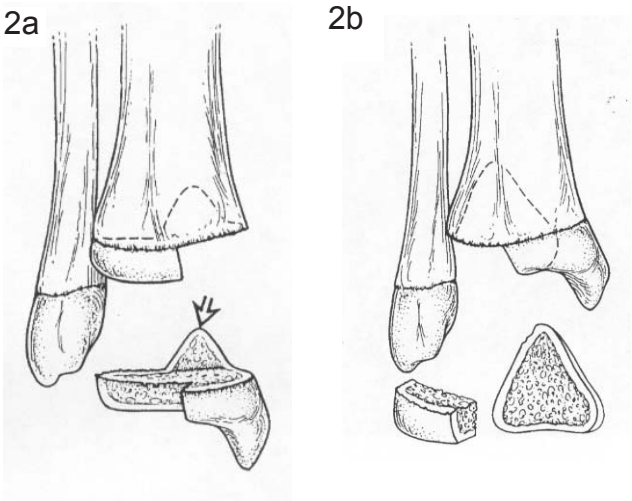


2a. Note the three different planes of fracture: transverse (growth plate), sagittal (epiphysis), and coronal (distal tibial metaphysis). 2b. The difference from the two-part fracture is that the distal tibial fragment is broken into two (or more) parts.

Used with permission from Heckman JD. Fractures and dislocations of the foot. In: Rockwood CA, Green DP, Bucholz RW, eds. *Rockwood and Green's Fractures in Adults*. 3rd ed. Philadelphia: JB Lippincott; 1995:1342-1346.

breaks away more cartilage, which can float free in the joint and produce damage at other sites. Inflammation and pain produce hypertrophy of synovial tissue, resulting in chronic swelling and stiffness. As more layers of cartilage are lost, the joint space narrows. Walking on a chronically painfully ankle can alter gait, producing imbalances and problems in knees, hips, back, and neck, as well. Without corrective action, prolonged joint damage even can produce deformities accompanied by severe, disabling pain.

The most serious complication of fracture for the ED physician is compartment syndrome of the foot. Since the dramatic symptoms develop abruptly only hours to days after an acute injury, the ED is a likely place for the patient to present. When pressure in the fascial compartment rises above venous pressure, ischemia begins. Ischemia produces more swelling and a cycle begins that can lead to permanent ischemic damage to muscles and nerves in the affected compartment. Patients present with severe pain, paresthesias, tense swelling in the foot, and have pain on passive stretch of the affected muscles. Emergent surgical decompression is required to prevent permanent damage. When considering the diagnosis, direct measurement of compartment pressures is required. Pressures greater than 30-40 mmHg confirm the diagnosis. *(See "Foot Compartment Syndrome" in Part II of this article, in the next issue of* Emergency Medicine Reports*.)*

## Pediatric Ankle Fractures

Treating children for ankle injury presents a few unique problems. Mechanisms of injury are often unknown. The event often is unwitnessed, and the young child typically is not a good historian. The general rule for pediatric ankle injuries is that children will have more fractures and fewer sprains, while the reverse is true for adults. One author even quotes the adage, "Kids don't get sprains."[72] Children's ligaments and tendons are strong relative to their growing bones, thus nearly all children with ankle injuries will need to have x-rays obtained. When x-rays are obtained, however, the presence of growth plates can confuse interpretation of plain films and lead to under-treatment of occult fractures. To fully complicate the picture, physeal fractures are the most common, as the growth plate is weaker than surrounding calcified bone, ligaments, or tendons. Ankle fractures account for only 5% of pediatric fractures but 15% of physeal injuries.[73] The Salter-Harris classification system should be used when discussing ankle fractures with the consultant.

Open fractures should be treated the same as in adult patients. Be aware that lawnmowers are a very common and preventable source of pediatric foot, ankle, and lower extremity trauma. In 1998, 60,000 patients presented to EDs for lawnmower injuries, with 20% involving children. Often the injury involves severe damage to the child's foot/leg, including open fracture or amputation, and results in prolonged hospitalization, multiple surgeries, infections, and even death. Psychological harm also can be severe, as the parent typically is operating the lawnmower at time of injury. Precautions to keep children away from lawnmowers cannot be overstated.

In general, pediatric ankle fractures can be treated similar to adult fractures. Two specific pediatric ankle fractures bear discussion: Tillaux and Triplane fractures. Both of these fractures are common in older adolescents, whose growth plates are beginning to close. Both are growth plate injuries of the ankle. In both injuries, the average age is 11-15 years. The median age for girls is 12 years, 14 years in boys, as growth plates close on average in girls at younger ages. For reasons that remain unclear, the Tillaux fracture is more common in girls, and the Triplane fracture is more common in boys. Overall, though, boys have a higher incidence of ankle injury and fracture than girls.

**Tillaux Fractures.** The Tillaux fracture is a Salter-Harris Type III that avulses the anterolateral tibial epiphysis (distal to growth plate). In these fractures, the medial and middle sections of the growth plate have already closed and the remaining section is fractured. This injury is produced by external rotation of the leg with the foot fixed, which causes the anterior tibiofibular ligament to avulse its attachment to the distal tibia. Typically, the mechanism is low energy, such as skateboarding or sliding into a base in baseball. Patients will present with similar complaints and findings as with adult ankle fracture: pain, swelling, ecchymosis, and inability to bear weight. Oblique ankle films are needed at times to distinguish the Tillaux fracture from the more common triplane fracture. *(See Figures 2a-b.)* Orthopedic consultation in the ED is recommended, as more than 2 mm of displacement after attempts at reduction will require surgical intervention. Fortunately, as most of the growth plate has closed before this fracture occurs, leg length discrepancies and rotational deformities rarely are seen.

**Triplane Fracture.** Triplane fractures are more common than Tillaux fractures and are a more serious injury. The term "triplane fracture" was first coined in 1972 by Lynne.[74] They are so named because there are fractures in three separate anatomic planes: transverse (growth plate), sagittal (epiphysis), and coronal (distal tibial metaphysis). *(See Figure 2a.)* These fractures are relatively common and account for up to 10% of all pediatric ankle fractures. The right ankle is injured more commonly, fractures are more prevalent in males, and nearly 50% of these fractures result from falls.[75] The mechanism of injury is a combination of external rotation and axial loading of a foot in plantarflexion. As with Tillaux fractures, these are injuries of adolescence and occur about one year prior to growth plate closure. Triplane fractures can be two-part, three-part or four-part fractures. The distal fibula may be fractured in any of these types, but it is not counted as a component of the triplane fracture. CT scan may be required to adequately define the fractures.

The two-part fracture is a Salter-Harris Type IV fracture. *(See Figure 2a.)* The first fracture line is in the transverse (horizontal) plane thorough the tibial epiphysis (growth plate). The medial portion of the plate already is closed, therefore, the fracture does not extend simply as a complete fracture through the plate. The medial portion stays attached to the tibia, and the second fracture plane extends up the tibia (coronal plane, through the metaphysis). The third fracture line (sagittal) extends distally into the joint. *(See Figure 2a.)* It is called a two-part fracture because the tibia is fractured into only two pieces—the proximal and distal parts. The three-part and four-part triplane fractures are similar in that fractures exist in all three planes, but the difference is that the distal part of the tibia is in more than one piece. *(See Figure 2b.)* The three-part and four-part fractures actually are combinations of Salter-Harris Type II and III fractures.

The orthopedist may be able to treat the two-part fracture with closed reduction if less than 2 mm of displacement is achieved. Be aware that when treated with a cast, significant swelling often is associated with these fractures. Unfortunately, if there is enough room in the cast for this swelling, the reduction can slip out of place after swelling subsides. Most three- or four-part fractures will be treated with ORIF. As with Tillaux fractures, growth arrest is uncommon, as the growth plate is near closure at time of injury.

## Ankle Dislocation

Ankle dislocations are relatively common, but pure dislocations without associated fractures are not,[76] due to the stabilizing nature of the bones in the mortise joint. Dislocations are described in terms of the distal part; i.e., the position of the talus and foot relative to the tibia. Posterior, anterior, medial, or lateral dislocations are possible, but medial are the most common. Open ankle dislocations should be cared for as open ankle fractures. Ankle films are useful, but should not delay reduction attempts when skin tenting or neurovascular compromise of the foot is present. Early reduction for any dislocation is advised (i.e., ideally less than 2-4 hours after presentation), although pure ankle dislocations may not be easy to reduce. When unable to reduce an injury, be sure to document that attempts were made. Tendons, other soft tissue, and small undetected fracture fragments can become entrapped and prevent stable reduction without exploration in the OR. After suitable analgesia/sedation, the knee is flexed to 90°, the foot is distracted (pulled distally), and gentle force is applied opposite to the mechanism of injury. Post-reduction films should be obtained, and orthopedic consult in the ED is advised. As dislocation of the ankle will tear multiple ligaments and result in an unstable joint, many patients do not return to premorbid function.

**Figure 3. Location and Incidence of Achilles Rupture**

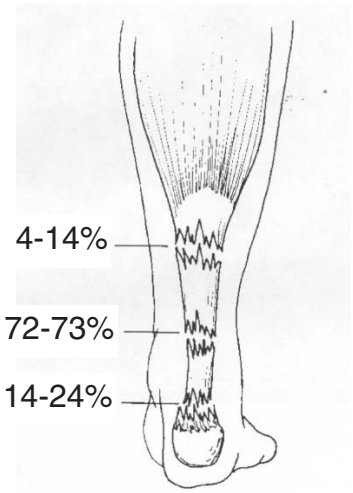


Used with permission from Caughlin MJ. Disorders of tendons. In: Mann RA, Caughlin MJ, eds. *Surgery of the Foot and Ankle.* 7th ed. Philadelphia: Mosby; 1999:786-861.

## Tendon Injuries

**Achilles Tendon.** Pathology and rupture of the Achilles tendon has been documented from the time of Hippocrates and the ancient Greeks. The Achilles tendon draws its name from the Greek demigod Achilles, son of Thetas. It is said that Thetas wished to make Achilles immortal so she dipped him in the river Styx to make him impervious to human weapons. The sole place on his body he was vulnerable was the heel by which he was dipped into the river by his mother.

Rupture of the Achilles tendon is the third most common major tendon disruption, though the cited overall incidence is less than 1% of the population.[77] Achilles tendon rupture has been documented in the second through eighth decades of life, though is classically described in the fifth decade. There is a striking male predominance. While lacerations and partial tears do occur, acute complete rupture is the most common scenario.[78] Acute traumatic rupture of a healthy Achilles tendon requires extreme force, most commonly a rapid deceleration injury. Examples include: fall from a height, or an MVA that dorsiflexes the ankle and stretches the tendon. While blunt force trauma to the posterior heel as well as acute lacerations do occur, more commonly rupture of the Achilles tendon represents an acute event predated by a chronic tendonitis. The mechanism of these injuries can seem very benign, such as just stepping off a curb.

## Table 5. Mechanisms of Injury in Achilles Tendon Rupture

- Dorsiflexion of the ankle against a contracting triceps surae muscle (i.e., stepping in a hole, tripping into a curb)
- Pushing off of the weighted foot with the knee fully extended (i.e., lunging for a tennis shot)
- Violent dorsiflexion against a plantarflexed ankle (i.e., fall from or jumping from a height)

## Figure 4. The Thompson Test

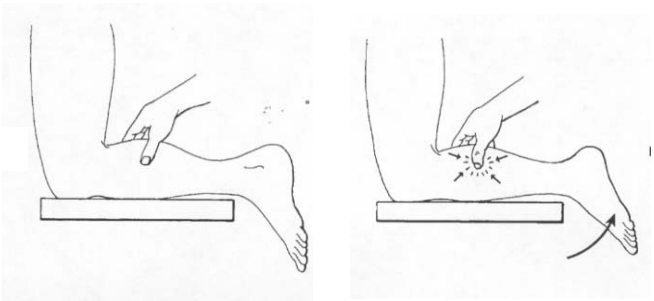

In patients with intact Achilles tendons, squeezing the calf should produce visible plantarflexion of the foot. Compare with the opposite (normal) side. The test is not sensitive for cases of partial rupture.

Used with permission from Caughlin MJ. Disorders of tendons. In: Mann RA, Caughlin MJ, eds. *Surgery of the Foot and Ankle.* 7th ed. Philadelphia: Mosby; 1999:786-861.

Usually, careful history is needed to elicit the history of tendonitis, and in some cases it will be asymptomatic. Ruptures most frequently occur at 2-6 cm proximal to the insertion site of the tendon on the tuberosity of the calcaneus. *(See Figure 3.)*[79] They are thought to occur here because this site represents an area of poor vascularity and marginal healing potential.[80]

Risk factors for rupture include middle age, diabetes, inflammatory arthridites (i.e., systemic lupus erythematosis, rheumatoid arthritis, etc.), endocrine abnormalities (i.e., chronic renal insufficiency, hypothyroidism), renal failure, chronic tendonitis, and obesity. Two medications often prescribed in the ED also are risk factors. Corticosteroid use is associated with risk of rupture, although it is much higher for local injection than for oral use. Lastly, although the mechanism is not clear, fluoroquinolone use recently has been shown to be a risk factor for rupture.[81]

*Anatomy.* The Achilles is the terminal tendon representing the confluences of the gastrocnemius and the soleus muscles. The gastrocnemius arises from the posterior femoral condyles, while the soleus arises from the posterior tibia, fibula, and interosseus membrane. Both are innervated by the tibia nerve. Therefore, the gastroc is an effective ankle plantar flexor with the knee extended, while the soleus is the more effective plantar flexor with the knee flexed. The Achilles tendon inserts over a broad area (2×2 cm) on the superior and posterior aspect of the calcaneal tuberosity. The Achilles tendon has two associated bursa, the retrocalcaneal bursa (between the Achilles and calcaneus) and the Achilles tendon bursa (between the skin and the Achilles tendon). The tendon twists 90° on itself over the terminal 6 cm before the insertion, and this area of the tendon has been shown to have very poor blood supply, rendering the area most susceptible to injury and degenerative changes.[80]

*History and Physical Exam.* Table 5 lists the common mechanisms of injury for acute Achilles tendon rupture. Care must be taken, as these mechanisms are similar to those that cause ankle sprain. Indeed, the chief complaint in many cases of rupture is "sprained ankle,"[82] so the ED physician must remain vigilant for clues that suggest tendon rather than ligament injury. Patients often describe a "pop" or "snap" that can be heard by bystanders, and even described as a gunshot. They may describe the sensation of being hit or kicked in the heel, followed by a sharp pain that fades into a dull ache. Most commonly, the patient is a 40- to 50-year-old male (a weekend warrior) with acute severe pain in the lower posterior leg after a misstep during recreational sports (i.e., basketball and racquet sports). This is followed by difficulty walking or in plantarflexing the foot. Additionally, feeling uncoordinated, inability to run or jump on the affected limb, and swelling or discoloration may be noted. The left ankle most frequently is involved.

Fortunately, physical findings in acute rupture can be very helpful in making the diagnosis. Before obscured by swelling, a defect may be noted within the body of the tendon itself 2-6 cm from the insertion of the tendon on the heel. As the tendon is subcutaneous, the defect usually is easily palpable. The normal lie of the foot when the patient is placed prone with feet hanging over the end of the stretcher also will be altered (pronounced passive plantar flexion). The Thompson test is very useful, but may not be abnormal with partial tears or subacute (> 1 week) injuries. *(See Figure 4.)* The patient can be placed prone with feet hanging over the end of the stretcher, or kneeling on both knees on a chair facing away from the examiner with his feet free in space. The examiner then squeezes the calf muscle belly of the noninjured side first, to elicit passive plantar flexion of the foot. Next, the examiner repeats the maneuver on the affected side and compares the result. If no plantar flexion of the foot occurs, the test is positive for an acute Achilles tendon rupture. Confusion can arise if one only relies on active plantarflexion to rule out a rupture. While most patients cannot plantarflex against resistance, many have some preserved flexion resulting from other toe flexors. Theoretically, the patient should have retained movement but not strength, but reports of patients still being able to toe stand after rupture exist.[82]

**Imaging.** With careful attention to history and physical examination, the great majority of cases can be diagnosed without x-rays or special imaging studies. A positive Thompson test is enough for orthopedic consultation. When plain films are done, they may reveal calcification within the tendon, or merely soft-tissue swelling. Lateral radiographs of the ankle may reveal disruption of normally sharp contours of the Achilles tendon. Kager's triangle is an area bounded by the soft-tissue shadows of the Achilles tendon, the deep flexor tendons (FHL and FDL), and the posterior superior margin of the calcaneus. *(See Figure 5.)*

The triangle normally is sharply defined, but in the case of Achilles tendon rupture, its borders are blunted from soft-tissue swelling, hemorrhage, and edema. One study of 60 patients with complete rupture showed a 100% correlation of blunting of the triangle and rupture.[83] If any doubt exists, both ultrasound and MRI have shown very high sensitivity and specificity for Achilles tendon rupture. MRI has the best overall accuracy in diagnosis and is used for planning surgical repair.[84]

**Differential Diagnosis.** Acute Achilles tendon rupture is misdiagnosed by the initial examiner in 25% of cases.[82] Ankle fractures also can be present with higher energy mechanisms of injury and can distract from the diagnosis. Achilles tendonitis, ankle sprain, and flexor hallucis longus (Dancer's) tendonitis may be confused with rupture as well, but typically don't mimic the total or near total loss of plantar flexion power seen with Achilles tendon rupture. Most cases that are missed probably result from the physician not considering the diagnosis, not examining the patient specifically for rupture, or because the exam can be misleading. Patients often can plantarflex, but should not be able to plantarflex against resistance, an important distinction to make. The key to diagnosis is to keep rupture in the back of one's mind when examining ankle sprain, and perform Thompson tests regularly in evaluation of high-risk patients (e.g., weekend warriors). As the rupture only can be visualized by MRI or ultrasound, the examiner has to be suspicious of the diagnosis to order these tests. Lacerations over the area often do involve the tendon. The tendon has no real sheath and is located subcutaneously. One must assume any full thickness laceration over the tendon involves it. The wound should be explored under a sterile, bloodless field with good lighting and anesthesia. Partial (< 25%) lacerations often can be left to heal with just skin closure,[85] but an orthopedic surgeon should be consulted for larger injuries or any questions on repair of the tendon.

**Treatment.** Management of Achilles tendon ruptures can be either conservative or surgical, and many debates have been waged about the merits of both in the orthopedic literature.[86] Advantages of surgery are that the patient returns to activities faster, less muscle atrophy occurs, and most importantly as the proper tendon length and tension is preserved the incidence of re-rupture is dramatically lower. Recent data still support a re-rupture rate of 20-30% for non-surgical vs. 1-2% for surgical repair.[87,88] Non-operative repair also has the disadvantage of increased tendon length after healing, which leads to decreased push-off strength. Disadvantages of surgery are postoperative skin complications and infection. In general, patients older than 50 years and non-athletic patients still are treated non-surgically.[86] Regardless of treatment, patients can expect an average of 2-4 months before return to work[82] and up to six months before full participation in sports.[89]

Unless the patient is to be admitted for repair, ED management is straightforward regardless of whether the patient will be treated surgically or not. The initial management is splint or cast immobilization, with the foot in gravity equines (i.e., not with the ankle at 90°, but at position of rest). The patient must have a well-padded, long leg cast or splint, with the knee flexed (20-30°). Short leg splints or casts are neither long enough to hold the foot adequately plantarflexed, nor can a short leg cast keep the knee flexed to relax the gastrocnemius muscle, which originates on the femur. Non-surgical treatment involves ice, elevation, and non-weight bearing, followed by serial cast changes with progressively more dorsiflexion.

**Figure 5. Loss of Kager's Triangle with Acute Rupture of Achilles Tendon**

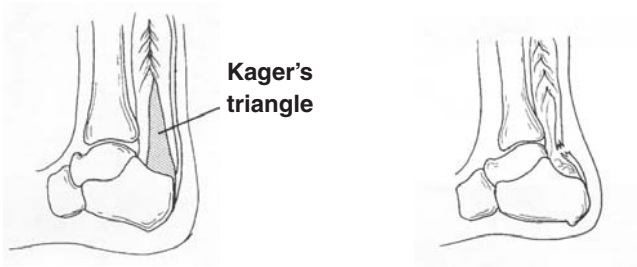


The triangle is seen on lateral plain films with intact Achilles tendons. Acute rupture causes loss of the triangle's normally clear borders.

Used with permission from Caughlin MJ. Disorders of tendons. In: Mann RA, Caughlin MJ, eds. *Surgery of the Foot and Ankle*. 7th ed. Philadelphia: Mosby; 1999:786-861.

**Peroneal Tendon Injury.** A variety of peroneal tendon injuries can present in the ED, including longitudinal rupture; tenosynovitis; rupture, fracture, or avulsion of the os perineum; subluxation/dislocation of the peroneal tendons; and avulsion fracture of the base of the fifth metatarsal.[90] The peroneus longus originates from the lateral condyle of the tibia and the midlateral portion of the head of the fibula. It inserts on the inferior portion of the medial cuneiform and on the plantar lateral aspect of the first metatarsal, arriving at its insertion by traversing the plantar surface of the cuboid, across the sole of the foot. It plantarflexes the foot as well as the first metatarsal, is an active everter of the foot, and is a static and dynamic stabilizer of the longitudinal arch of the foot. The muscular portion of the peroneus longus lies posterolateral to the peroneus brevis and becomes entirely tendinous above lateral malleolous. The peroneus brevis originates from the midlateral portion of the proximal one-third of the fibula. It inserts on the base of the fifth metatarsal. Importantly, the brevis tendon passes directly across the peroneal tubercle on its course to its insertion. It acts as a dynamic everter of the foot. It runs posterior to the fibula and behind the lateral malleolous anterior to the peroneus longus. Both tendons maintain their individual tendon sheaths, though both are contained in a common sheath that runs posteriolateral to the distal one-third of the fibula. At the tip of the fibula, the tendons are held in their proper position by a bony ridge, a fibro-osseous ridge, and the superior peroneal retinaculum.

While most of the pathology of the peroneal tendons represents long-standing chronic degenerative processes, acute traumatic injuries do occur. Acute traumatic rupture of the peroneal tendons is quite rare. However, injuries to the peroneal tendons

and tendon complex are relatively frequent and underdiagnosed with injuries to the lateral ankle, often being misdiagnosed as lateral ankle sprains. As with lateral ankle sprains, violent inversion/supination injuries to the ankle can result in fractures and avulsion fractures of the os perineum, traumatic subluxation or dislocation of the peroneal tendons (when chronic can be "snapping peroneal tendon syndrome"), and tendon rupture, whether transverse or longitudinal. Acute or chronic ruptures most frequently are seen in ballet dancers, after multiple ankle sprains, and following other activities that stress the lateral ankle repetitively.

Most commonly, the history is identical to that of lateral ankle sprain, an inversion/supination injury, often with an immediate sensation of a painful pop on the lateral side of the ankle. Careful history may even elicit a history of recurrent inversion injuries to the ankle; pain localized behind the distal fibula, just distal to the tip of the fibula; or pain between the tip of the fibula and the base of the fifth metatarsal and under the sole of the foot. Swelling can be localized, but more commonly is generalized to the entire lateral and anterior side of the ankle. Point tenderness over the base of the fifth metatarsal may indicate an injury to the os perineum or the base of the fifth metatarsal. The patient may complain of a painful snapping sensation at the tip of the fibula with dorsiflexion or eversion of the ankle.

Anteroposterior, lateral, and oblique radiographs of the foot and ankle usually are necessary to rule out fractures of the ankle and metatarsals, fracture or proximal subluxation of the os perineum, and soft-tissue swelling. MRI can be utilized to image the peroneal tendon, though special soft-tissue sequences and an expert knowledge of imaging of the local area is necessary due to the small caliber of the peroneal tendons.

Initial management also is similar to the treatment of a significant lateral ankle sprain. Immobilization of the ankle with a splint, cast, removable boot, or air cast is beneficial in minimizing swelling, resting the ankle, and allowing more comfort in weight bearing. Ice, elevation, compression, and NSAIDs also are indicated. Initial management of immobilization is appropriate for os perineum fractures, base of the fifth metatarsal fracture, and subluxating tendons. Acute rupture of the peroneal tendons will require orthopedic referral and operative management. Chronic snapping peroneal tendons, representing an injury to the fibrocartilaginous or bony ridge of the posterior distal fibula, may necessitate prolonged immobilization or operative repair of the superior peroneal retinaculum or the ridge.

**Extensor Tendon Injuries.** Injuries of the extensor tendon are uncommon, though can occur from penetrating injuries to the foot or ankle, lacerations, and crush injuries to the foot. The extensor digitorum longus originates on the lateral tibial condyle, anterior crest of the fibula, and interosseus membrane and inserts on the terminal phalanges. It is responsible for extension of the second thru fifth metatarsal phalangeal joints. Just distal to the ankle mortise and extensor retinaculum, the tendons are subcutaneous and easily subject to injury. The extensor hallucis longus originates on the anterior middle fibula and interosseus membrane, inserts on the base of the distal phalanx of the great toes, and is responsible for extension of the great toe and foot eversion. Like the extensor digitorum longus, the extensor hallucis longus is subcutaneous from the level of the ankle distally and subject to direct trauma. The tibialis anterior originates form the proximal tibia, tibial plateau, and interosseus membrane and inserts on the medial cuneiform and plantar aspect of the first metatarsal. It acts in foot dorsiflexion, inversion, and helps control plantar flexion at heel strike. All three of these muscle tendon units are innervated by the deep peroneal nerve. Penetrating injuries to the anterior ankle or foot (dorsum), lacerations, or crush injuries require not only direct inspection for tendinous injury, but also careful examination of tendon function to document these injuries. Lack of ability to extend the great or lesser toes, abnormally flexed cascade of the toes, or a positive push-up test is indicative of injury to these tendons. To perform the push-up test, the examiner presses a thumb under the plantar aspect of the first metatarsalphalangeal joint. A positive test occurs when this pressure causes flexion of the great toe. This results from extensor hallucis longus discontinuity causing unopposed pull of the flexor hallucis longus.

Injuries to the tibialis anterior are very rare but, again, can be from lacerations, penetrating injuries, or from distal tibia fractures. On physical exam, the foot may be seen to be in excessive plantar flexion and there may be a visible defect in the tendon either near the ankle or just distal to the extensor retinaculum. Lacerations and puncture wounds require sterile exploration in a bloodless field just as is done to rule out tendon injuries in the hand. Presence of a tendon laceration requires orthopedic consultation. Repair of the extensor tendons is necessary to prevent permanent loss of function and deformity and usually is performed by the consultant. If the wound is to be closed and the patient seen in follow-up, irrigate and suture the wound, give prophylactic antibiotics (cephalexin 500 mg QID for 3-5 days), and give tetanus prophylaxis if indicated.

**Flexor Tendon Injuries.** The flexor digitorum longus originates on the proximal posterior tibia, runs down the posterior aspect of the tibia behind the posterior tibialis muscle and passes under the plantar surface of the foot to insert on the plantar aspect of the distal phalanges of the lesser toes. It acts to flex the lesser toes and is a secondary plantar flexor of the foot. The flexor hallucis longus originates on the posterior proximal tibia travels along the posterior tibia behind the flexor digitorum to insert on the plantar aspect of the distal phalanx of the great toe. The flexor hallucis longus acts to plantar flex the great toe particularly in push off. Traumatic ruptures of these tendons would be extremely rare except in cases of significant trauma of the foot and ankle. Lacerations either of the posterior medial ankle or to the inferomedial portion of the first metatarsal can predispose to these injuries. With lacerations of the flexor digitorum longus distal to the knot of Henry (at the middle of the first metatarsal) the patient will exhibit inability to flex the distal phalanges of the lesser toes. With lacerations of the flexor digitorum longus proximal to this level, the patient may still be able to flex the distal phalanges due to an interconnection between the flexor hallucis longus and the flexor digitorum longus. Paresthesias of the medial border of the foot or the medial toes may be associated with

these lacerations from injury of nearby sensory nerves.

Like in the hand tendons, zones of injury have been described for flexor hallucis longus tendon lacerations. In the foot there are only three zones compared to the five zones of hand flexors. ED physicians need to be aware that lacerations in Zone 3 (proximal to the knot of Henry, or the middle of the first metatarsal) will show proximal retraction and total loss of flexor function if not repaired.[92] Proper evaluation for possible tendon lacerations in ED patients with foot/ankle lacerations is essential to not miss these relatively uncommon injuries when they do occur. ED treatment is the same as with extensor tendon injuries: consultation, irrigation, wound closure, antibiotic prophylaxis, and tetanus booster if needed.

Acute tendonitis of the flexor hallucis longus also can be seen in the ED. It is caused by frequent forceful hyperplantarflexion of the foot, and thus usually occurs in ballet dancers (dancer's tendonitis). Careful history may elicit a long prodrome of pain under the first metatarsal or in the posterior ankle with extreme plantar flexion of the foot. Patients may complain of an acute "pop" followed by decrease pressure pushing off the great toe and pain. Treatment consists of rest, NSAIDs, and a short course of immobilization.

## References


1. Wolfe MW. Management of ankle sprains. *Am Fam Physician* 2001;63:93-104.
2. Van Staa TP, Dennison, EM, Luefkens HG, et al. Epidemiology of fractures in England and Wales. *Bone* 2001;6:517-522.
3. Puffer JC. The sprained ankle. *Clin Cornerstone* 2001;3:38-49.
4. Taylor BL, Attia MW. Sports-related injuries in children. *Acad Emerg Med* 2000;12:1376-1382.
5. Gerber JP, Williams GN, Scoville CR, et al. Persistent disability associated with ankle sprains: A prospective examination of an athletic population. *Foot Ankle Int* 1998;10:653-660.
6. Ho K, Abu-Laban RB. Ankle and Foot. In: Rosen P, Barkin R, eds. *Emergency Medicine: Concepts and Clinical Practice.* 4th ed. St. Louis: Mosby; 1998:821-860.
7. Davidson, TM, Laliotis, AT. Snowboarding injuries, a four-year study with comparison with alpine ski injuries. *West J Med* 1996;164:231-237.
8. Liu SH, Jason WJ. Lateral ankle sprains and instability problems. *Clin Sports Med* 1994;13:793-809.
9. Stiell IG, Greenberg GH, McKnight RD, et al. Decision rules for the use of radiography in acute ankle injuries: Refinement and prospective validation. *JAMA* 1993;269:1127-1132.
10. de Lacey G, Bradbrooke S. Rationalizing requests for x-ray examination of acute ankle injuries. *BMJ* 1979;1:1597-1598.
11. Stiell I. Ottawa ankle rules. *Can Fam Physician* 1996;42:478-480.
12. Libetta C, Burke D, Brennan, et al. Validation of the Ottawa ankle rules in children. *J Accid Emerg Med* 1999;16:342-344.
13. Stiell I, Wells G, Laupacis A, et al. Multicentre trial to introduce the Ottawa ankle rules for use of radiography in acute ankle injuries. Multicentre Ankle Rule Study Group. *BMJ* 1995;311:594-597.
14. Anis AH, Stiell I G, Stewart DG, et al. Cost-effectiveness analysis of the Ottawa ankle rules. *Ann Emerg Med* 1995;26:422-428.
15. Shaffer JJ, Johnson RG. The antiglide plate for distal fibular fixation. A biomechanical comparison with fixation with a lateral plate. *J Bone Joint Surg Am* 1987;69:596-604.
16. Clark TW, Janzen DL, Ho K, et al. Detection of radiographically occult ankle fractures following acute trauma: Positive predictive value of an ankle effusion. *Am J Roentgenol* 1995;164:1185-1189.
17. Ho K, Clark TW, Janzen DL, et al. Occult ankle fracture detection by an ankle effusion on plain radiography: A case report. *J Emerg Med* 1996;14: 455-459.
18. Traughber PD. Imaging of the foot and ankle. In: Mann RA, Caughlin MJ, eds. *Surgery of the Foot and Ankle*. 7th ed. St. Louis: Mosby; 1999:51-114.
19. Lazarus ML. Imaging of the foot and ankle in the injured athlete. *Med Sci Sports Exerc* 1999;31:S412-S420.
20. Rawool NM, Nazarian LN. Ultrasound of the ankle and foot. *Semin Ultrasound CT MR* 2000;21:275-284.
21. Thacker SB, Stroup DF, Branche CM. The prevention of ankle sprains in sports: A systematic review of the literature. *Am J Sport Med* 1999;27:753-760.
22. Spaine LA, Bollen SR. 'The bigger they come ...': the relationship between body mass index and severity of ankle fractures. *Injury* 1996;27:687-689.
23. Kannus P, Renstrom P. Treatment for acute tears of the lateral ligaments of the ankle. Operation, cast, or early controlled mobilization. *J Bone Joint Surg Am* 1991;73:305-312.
24. Fallat L, Grimm DJ, Saracco JA. Sprained ankle syndrome: Prevalence and analysis of 639 acute injuries. *J Foot Ankle Surg* 1998;37:280-285.
25. Wedmore IS, Charette J. Orthopedic emergencies: Emergency department evaluation and treatment of ankle and foot injuries. *Emerg Med Clin North Am* 2000;18:86-113.
26. Judd DB, Kim DH. Foot fractures frequently misdiagnosed as ankle sprains. *Am Fam Physician* 2002;66:785-794.
27. Fortin PT, Balazsy JE. Talus fractures: Evaluation and treatment. *J Am Acad Orthop Surg* 2001;9:114-127.
28. Elgafy H, Ebraheim NA, Tile M, et al. Fractures of the talus: Experience of two level 1 trauma centers. *Foot Ankle Int* 2000;21:1023-1029.
29. Lynch SA, Renstrom PA. Treatment of acute lateral ankle ligament rupture in the athlete: Conservative versus surgical treatment. *Sports Med* 1999;27:61-71.
30. Kerkhoffs GM, Handoll HH, de Bie R, et al. Surgical versus conservative treatment for acute injuries of the lateral ligament complex of the ankle in adults. *Cochrane Database Syst Rev* 2002;3:CD 000380.
31. Kannus P, Renstrom P: Current concepts review: Treatment for acute tears of the lateral ligaments of the ankle. *J Bone Joint Surg* 1991;73:305-312.
32. Clanton TO. Athletic injuries to the soft tissues of the foot and ankle. In: Mann RA, Caughlin MJ, eds. *Surgery of the Foot and Ankle*. 7th ed. St. Louis: Mosby; 1999:1090-1209.
33. Eiff MP, Smith AT, Smith GE. Early mobilization versus immobilization in the treatment of lateral ankle sprains. *Am J Sports Med* 1994;22:83-88.
34. Kerhoffs GM, Rowe BH, Assendelft WJ, et al. Immobilization for acute ankle sprain. A systematic review. *Arch Orthop Trauma Surg* 2001;121:462-471.
35. Hopkinson, WJ, St Pierre P, Ryan JB, et al. Syndesmosis sprains of the ankle. *Foot Ankle* 1990;10:325-330.
36. Cedell C. Ankle lesions. *Acta Orthop Scand* 1975;46:425-445.
37. Title CI, Katchis SD. Traumatic foot and ankle injuries in the athlete: Acute athletic trauma. *Orthop Clin North Am* 2002;33:587-598.
38. Vincelette P, Laurin CA, Levesque HP. The footballer's ankle and foot. *Can Med Assoc J* 1972;107:872-875.
39. Nussbaum ED, Hosea TM, Sieler SD, et al. Prospective evaluation of syndesmotic ankle sprains without diastasis. *Am J Sports Med* 2001;29:31-35.
40. Karlsson J, Lansinger O. Lateral instability of the ankle joint. *Clin Orthop* 1992;276:253-261.
41. Brandy WD, Strong L, Roberts T, et al. False aneurysm—a complication following an inversion ankle sprain: A case report. *J Orthop Sports Phys Ther* 1996;23:272-279.
42. Acus RW III, Flanagan JP. Perineural fibrosis of superficial peroneal nerve complicating ankle sprain: A case report. *Foot Ankle* 1991;11:233-235.
43. Espeio BA, Lopez AR, Moro RJA, et al. Partial necrosis of the neck of the talus treated with arthroscopy. *Arthroscopy* 1997;13:245-247.

44. Bureau NJ, Cardinal E, Hobden R, et al. Posterior ankle impingement syndrome: MR imaging findings in seven patients. *Radiology* 2000;215: 497-503.
45. Ferkel RD. Arthroscopy of the Foot and Ankle. In: Mann RA, Caughlin MJ, eds. *Surgery of the Foot and Ankle*. 7th ed. St. Louis: Mosby; 1999: 1257-1299.
46. Hertel J. Functional instability following lateral ankle sprain. *Sports Med* 2000;29:361-371.
47. Richie DH Jr. Functional instability of the ankle and the role of neuromuscular control: A comprehensive review. *J Foot Ankle Surg* 2001;40:240-251.
48. Handoll HH, Rowe BH, Quinn KM, et al. Interventions for preventing ankle ligament injuries. *Cochrane Database Syst* 2001;3:CD000018.
49. Nunley JA. Fractures and fracture-dislocations of the calcaneus. In: Mann RA, Caughlin MJ, eds. *Surgery of the Foot and Ankle.* 7th ed. St. Louis: Mosby; 1999:1398-1421.
50. Valtola A, Honeanen R, Kroger H, et al. Lifestyle and other factors predict ankle fractures in perimenopausal women: a population-based prospective cohort study. *Bone* 2002;30:238-242.
51. Ramsey PL, Hamilton W. Changes in tibiotalar area of contact caused by lateral talar shift. *J Bone Joint Surg* 1976;58:356-357.
52. de Souza LJ. Fractures and dislocations about the ankle. In: Gustilo RB, Kyle RF, Templeman DC, eds. *Fractures and Dislocations, Vol 2*. St. Louis: Mosby; 1993.
53. Franklin JL, Johnson KD, Hansen ST Jr, et al. Immediate internal fixation of open ankle fractures. Report of 38 cases treated with a standard protocol. *J Bone Joint Surg Am* 1984;66:1349-1356.
54. Gustilo RB, Anderson JT. Prevention of infection in the treatment of 1025 open fractures of long bones. *J Bone Joint Surg* 1976;58:453-458.
55. Chapman MW, Mahoney M. The place of immediate internal fixation in the management of open fracture. *Clin Orthop* 1979;138:120-131.
56. Sanders R, Swiontkowski MF, Nunley JA II. The management of fractures with soft-tissue disruptions. *J Bone Joint Surg* 1993;75:778-789.
57. Walling AK. Classification of ankle fractures: which system to use? *Instr Course Lect* 1988;37:251-256.
58. Ebraheim NA, Mekhail AO, Gargasz SS. Ankle fractures involving the fibula proximal to the distal tibiofibular syndesmosis. *Foot Ankle Int* 1997;18:513-521.
59. Phillips WA, Schwartz HS, Heller CS, et al. A prospective randomized study of the management of severe ankle fractures. *J Bone Joint Surg Am* 1985; 67:67-78.
60. Wilson FC. Fractures of the ankle: Pathogenesis and treatment. *J South Orthop Assoc* 2000;9:105-115.

## *Emergency Medicine Reports*
## CME Objectives

*To help physicians:*

- quickly recognize or increase index of suspicion for specific conditions;
- understand the epidemiology, etiology, pathophysiology, and clinical features of the entity discussed;
- apply state-of-the-art diagnostic and therapeutic techniques (including the implications of pharmaceutical therapy discussed) to patients with the particular medical problems discussed;
- understand the differential diagnosis of the entity discussed;
- understand both likely and rare complications that may occur.

61. Henderson MS. Trimalleolar fractures of the ankle. *Surg Clin North Am* 1932;12:867-872.
62. Ovadia DN, Beals RK. Fractures of the tibial plafond. *J Bone Joint Surg* 1986;68:543-551.
63. Karas EH, Weiner LS. Displaced pilon fractious: An update. *Orthop Clin North Am* 1994;25:651-663.
64. Borrelli J Jr, Ellis. E. Pilon fractures: Assessment and treatment. *Orthop Clin North Am* 2002;33:321-245.
65. McFerran M, Smith S, Boulas HJ, et al. Complications encountered in the treatment of pilon fractures. *J Orthop Trauma* 1992;6:195-200.
66. Sirkin M, Sanders R, DiPasquale T, et al. A staged protocol for soft tissue management in treatment of complex pilon fractures. *J Orthop Trauma* 1999;13:78-84.
67. Picanz J. Poor results mark ORIF of tibial plafond fractures. *Orthop Today* 1990;10:1-2.
68. Reüdi TP. Fractures of the lower end of the tibia into the ankle joint: Results 9 years after open reduction and internal fixation. *Injury* 1973;5:130-134.
69. Pankovich AM. Maisonneuve fracture of the fibula. *J Bone Joint Surg* 1976; 58A:333-342.
70. Lock TR, Schaffer JJ, Manoli A II. Maisonneuve fracture: Case report of a missed diagnosis. *Ann Emerg Med* 1987;16:805-807.
71. Duchesneau S, Fallat LM. The Maisonneuve fracture. *J Foot Ankle Surg* 1995;34:422-428.
72. Marsh JS, Daigneault JP. Ankle injuries in the pediatric population. *Cur Opin Pediatr* 2000;12:52-60.
73. Kay RM, Matthys GA. Pediatric ankle fractures: Evaluation and treatment. *J Am Acad Orthop Surg* 2001;9:268-278.
74. Lynn MD. The triplane distal tibial epiphyseal fractures. *Clin Orthop* 1972; 86:187-190.
75. Karrholm J. The triplane fracture: Four years of follow-up of 21 cases and review of the literature. *J Pediatr Orthop* 1997;6:91-102.
76. Rivera F, Bertone C, De Martino M, et al. Pure dislocation of the ankle: Three case reports and a review of the literature. *Clin Orthop* 2001;382:179-184.
77. Mazzone MF, McCue T. Common conditions of the Achilles tendon. *Am Fam Physician* 2002;1:1805-1810.
78. Leppilahti J, Ovara S. Total Achilles tendon rupture. A review. *Sports Med* 1998;25:79-100.
79. Schepsis AA, Jones H, Haas AL. Achilles tendon disorders in athletes. *Am J Sports Med* 2002;30:287-305.
80. Saxena A, Bareither D. Magnetic resonance and cadaveric findings of the "watershed band" of the Achilles tendon. *J Foot Ankle Surg* 2001;40:132-136.
81. McGarvey WC, Singh D, Trevino SG. Partial Achilles tendon ruptures associated with fluoroquinolone antibiotics: A case report and literature review. *Foot Ankle Int* 1996;17:496-498.
82. Roberts JR. Diagnosing Achilles tendon rupture. In: Roberts JR. *Robert's Practical Guide to Common Medial Emergencies*. Philadelphia: Lippincott-Raven; 1996;211-215.
83. Cetti R, Andersen I. Roentgenographic diagnosis of ruptured Achilles tendons. *Clin Orthop* 1993;286:215-221.
84. Ferkel RD, Flannigan BD, Elkins BS. MRI imaging of the foot and ankle: Correlation of normal anatomy with pathologic conditions. *Foot Ankle* 1991; 11:289-305.
85. Floyd D, Heckman J, Rockwood C. Tendon lacerations of the foot and ankle. *Foot Ankle* 1983;4:8-14.
86. Bhandari M, Guyatt GH, Siddiqui F, et al. Treatment of acute Achilles tendon ruptures: A systematic overview and metaanalysis. *Clin Orthop* 2002; 400:190-200.
87. Moller M, Movin T, Granhed H, et al. Acute rupture of tendon Achilles. A prospective randomized study of comparison between surgical and non-sur-

gical treatment. *J Bone Joint Surg Br* 2001;83:843-848.
88. Moller M, Lind K, Movin T, et al. Calf muscle function after Achilles tendon rupture. A prospective, randomized study comparing surgical and non-surgical treatment. *Scand J Med Sci Sports* 2002;12:9-16.
89. Cetti R et al. Christensen SE, Ejsted R, et al. Operative vs nonoperative treatment of Achilles tendon rupture: a prospective randomized study and review of the literature. *Am J Sports Med* 1993;21:791-799.
90. Coughlin MJ. Disorders of tendons. In: Mann RA, Caughlin MJ, eds. *Surgery of the Foot and Ankle.* 7th ed. St. Louis: Mosby; 1999:786-861.

## Physician CME Questions

191. Which of the following is involved in approximately 80% of inversion injuries?
    A. Posterior talofibular ligament
    B. Anterior talofibular ligament
    C. Tibiocalcaneal ligament
    D. Deltoid ligament
    E. Calcaneofibular ligament

192. Which of the following is/are limitations of the Ottawa ankle rules?
    A. Five percent of patients not x-rayed in the ED will be found to have fracture on follow-up.
    B. The rules were not designed to detect fractures of the midfoot.
    C. Rules were not developed for use with pediatric or elderly (> 55 years) patients.
    D. All of the above.

193. Regarding ankle dislocation:
    A. Reduction should never be attempted in the ED due to the likelihood of associated fracture.
    B. It is relatively common with associated fracture.
    C. The dislocation is described in terms of the proximal part, i.e., the position of the tibia relative to the talus and the foot.
    D. Ankle films always should be acquired before a reduction is attempted.
    E. All of the above

194. Deltoid ligament injury is important to recognize in the ED because:
    A. isolated deltoid ligament injuries are common, and there is little risk of associated injuries.
    B. torn deltoid ligaments always are surgically repaired.
    C. Grade II and III deltoid ligament injuries require longer immobilization periods (6-8 weeks).
    D. All of the above

## CME Instructions

Physicians participate in this continuing medical education program by reading the article, using the provided references for further research, and studying the questions at the end of the article. Participants should select what they believe to be the correct answers, then refer to the list of correct answers to evaluate their knowledge. To clarify confusion surrounding any questions answered incorrectly, please consult the source material. *After completing this activity, you must complete the evaluation form that will be provided at the end of the semester and return it in the reply envelope provided to receive a certificate of completion.* When your evaluation is received, a certificate will be mailed to you.

195. Which of the following are ankle fractures that require orthopedic consult in the ED?
   A. Maisonneuve fracture
   B. Trimalleolar fracture
   C. Pilon fracture
   D. All of the above

196. The "gold standard" imaging technique for ankle soft-tissue trauma is:
   A. CT.
   B. plain x-ray.
   C. MRI.
   D. bone scan.

197. Which of the following is *false* concerning Achilles tendon rupture?
   A. Ruptures typically occur in middle-aged men (weekend warriors).
   B. The tendon tends to rupture at the insertion of the calf muscles.
   C. Treatment can be surgical or non-surgical.
   D. The Thompson test is clinically reliable to diagnose acute complete rupture.

198. One survey of ankle sprains in military cadets found what percent still demonstrated residual dysfunction after six months?
   A. 10%
   B. 20%
   C. 30%
   D. 40%

199. The anterior drawer test examines the integrity of which ligament?
   A. Calcaeofibular ligament
   B. Anterior talofibular ligament
   C. Posteriortalofibular ligament
   D. All of the above

200. Functional instability refers to:
   A. proven ligament tear.
   B. the patient's feeling that the ankle gives out during normal activity.
   C. the patient's feeling that the ankle gives out with exertion.
   D. proven tendon rupture.

## Answer Key:

| | |
|---|---|
| 191. B | 196. C |
| 192. C | 197. B |
| 193. B | 198. D |
| 194. C | 199. B |
| 195. D | 200. B |

**In Future Issues:**

**Foot and Ankle Injuries, Part II: The Foot**

## Audio Conference Clarifies Final EMTALA Regulations

The final version of the recently proposed changes to the Emergency Medical Treatment and Labor Act (EMTALA) takes effect on Nov. 10.

To provide you with critical information on the updated regulations from the Centers for Medicare and Medicaid Services, Thomson American Health Consultants offers *New EMTALA Regulations: Are They Too Good to be True?*—an audio conference on Tuesday, Oct. 21, from 2:30-3:30 p.m., EST.

While the new rule is intended to ease restrictions for hospitals, it's only good news if you implement it correctly. You still could face violations, hefty fines, and misinterpretation.

* How do you provide emergency treatment during a national emergency?
* How does EMTALA apply to inpatients, including those admitted through the ED?
* What should be procedure regarding on-call lists?
* What's the new rule regarding hospital-owned ambulances?
* How are off-campus clinics affected?

Ensure that you and your staff are prepared with straightforward advice from a panel of EMTALA experts. The program will be presented by **James R. Hubler, MD, JD, FACEP, FAAEM, FCLM**, attending physician and clinical assistant professor of surgery, Department of Emergency Medicine, OSF Saint Francis Hospital and University of Illinois College of Medicine in Peoria, IL; and **Robert A. Bitterman, MD, JD, FACEP**, director of risk management and managed care, Department of Emergency Medicine, Carolinas Medical Center in Charlotte, NC.

Our expert advice will help you steer clear of potential pitfalls. At the end of this audio conference, participants will be able to:

* Compare previous EMTALA regulations with the final regulations;
* Identify several legal issues for a facility that might arise based on the final rule;
* Discuss at least three provisions of the final EMTALA regulation;
* Identify ways in which to initiate the required mandates of the final revisions.

Each participant can earn FREE CE or CME for one low facility fee. Invite as many participants as you wish to listen to the audio conference for $249, and each participant will have the opportunity to earn 1 nursing contact hour or 1 AMA Category 1 CME credit. The conference package also includes handouts, additional reading, a free 48-hour replay of the live conference, and a CD recording of the program.

For more information, or to register, call Thomson American Health Consultants' customer service department at (800) 688-2421 or (404) 262-5476, or e-mail customerservice@ahcpub.com. When ordering, reference effort code: 83941.

Emergency Medicine Reports®
The Practical Journal for Emergency Physicians

# Acute Foot and Ankle Disorders, Part I: The Ankle

## Ottawa Ankle Rules

**THE RULES**

Ankle x-rays are ordered when there is:
- Bony tenderness along the posterior edge or distal 6 cm of either malleolus
- Inability to bear weight for at least two steps with each foot immediately after the injury and at the time of evaluation

Foot x-rays are ordered when there is:
- Bony tenderness over the navicular or at the base of the fifth metatarsal

**THE EXCEPTIONS/LIMITATIONS**
- Rules were developed only for patients age 18-55 years.
- Does not apply to pediatric patients.
- Mechanism of injury only applies to acute blunt trauma.
- Does not apply to subacute or chronic injuries
- Does not apply to injuries of hindfoot, forefoot

## Differential Diagnosis of Ankle Sprain

**COMMON, MORE EASILY DIAGNOSED AND TREATED**
- Lateral collateral ligament injury
- Fracture of base of the fifth metatarsal
- Achilles tendon injury

**LESS COMMON, MORE DIFFICULT TO DIAGNOSE AND TREAT**
- Medial collateral (deltoid) ligament injury
- Syndesmosis ligament injury
- Talar dome fracture
- Talar neck fracture
- Fracture of posterior process of the talus
- Fracture of lateral process of the talus
- Fracture of anterior process of the calcaneus
- Tendon injury

## Classification of Ankle Sprains

| GRADE | SYMPTOMS | SIGNS | EXAMINATION | TREATMENT |
|---|---|---|---|---|
| I | Mild pain, swelling<br>Able to bear weight | Mild swelling | Negative stress test | RICE*<br>Follow-up in < 7 days |
| II | Moderate pain, swelling<br>Difficulty bearing weight | Moderate swelling and echymosis | Anterior drawer (4-14 mm)<br>Talar tilt (5-15°) | Rigid splint<br>Follow-up in < 7 days |
| III | Severe pain, swelling<br>Unable to bear weight | Severe swelling and echymosis | Anterior drawer (>15 mm)<br>Talar tilt (> 15°) | Rigid splint<br>Follow-up in < 7 days |

* Rest, Ice, Compression, Elevation

## Orthopedic Consultation of Ankle Fractures

**EMERGENT (PATIENT NEEDS TO BE SEEN QUICKLY IN THE ED)***
- Open fracture
- Fracture/dislocation with vascular compromise
- Fracture/dislocation with tenting of skin

**RECOMMENDED (PATIENT OFTEN IS ADMITTED FOR REPAIR)**
- Tillaux and triplane fractures
- Intra-articular fractures with displacement
- Pilon fractures*
- Trimalleolar fractures
- Maisonneuve fractures
- Any fracture with significant disruption of the mortise

**RECOMMENDED (PHONE CONSULTATION MAY SUFFICE)**
- Bimalleolar fractures
- Minimally displaced medial or lateral malleolar fractures*

* Reduction by ED physician advised if orthopedist not immediately available.

## Two-Part Triplane Fracture (A) and Three-Part Triplane Fracture (B)

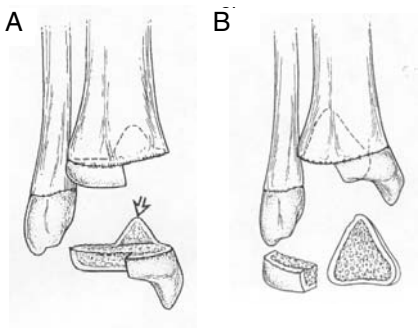


A. Note the three different planes of fracture: transverse (growth plate), sagittal (epiphysis), and coronal (distal tibial metaphysis). B. The difference from the two-part fracture is that the distal tibial fragment is broken into two (or more) parts.

Used with permission from Heckman JD. Fractures and dislocations of the foot. In: Rockwood CA, Green DP, Bucholz RW, eds. *Rockwood and Green's Fractures in Adults.* 3rd ed. Philadelphia: JB Lippincott; 1995:1342-1346.

## Mechanisms of Injury in Achilles Tendon Rupture

- Dorsiflexion of the ankle against a contracting triceps surae muscle (i.e., stepping in a hole, tripping into a curb)
- Pushing off of the weighted foot with the knee fully extended (i.e., lunging for a tennis shot)
- Violent dorsiflexion against a plantarflexed ankle (i.e., fall from or jumping from a height)

## Loss of Kager's Triangle with Acute Rupture of Achilles Tendon

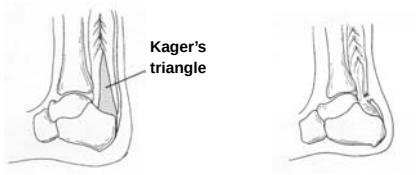


The triangle is seen on lateral plain films with intact Achilles tendons. Acute rupture causes loss of the triangle's normally clear borders.

Used with permission from Caughlin MJ. Disorders of tendons. In: Mann RA, Caughlin MJ, eds. *Surgery of the Foot and Ankle.*7th ed. Philadelphia: Mosby; 1999:786-861.

## Danis-Weber Ankle Fracture Classification

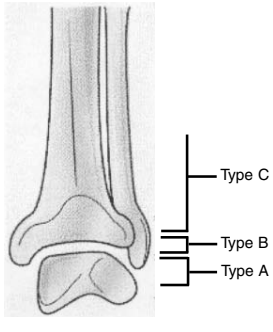


**Type A** fibular fractures are below the joint line and usually are treated with casting alone. **Type B** fractures are at the joint line and may or may not have associated syndesmotic ligament injury. **Type C** fractures occur above the joint line and do have associated syndesmotic ligament damage requiring surgical repair.

Adapted from Pemdatabase.org. Foot and ankle fractures, Power Point presentation. www.pemdatabase.org/files/Foot_and_Ankle_Fractures2.ppt. Accessed 9/15/2003.

## Location and Incidence of Achilles Rupture

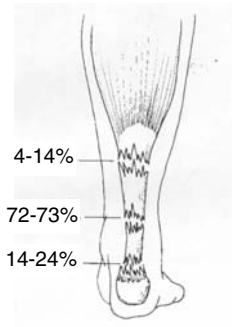


Used with permission from Caughlin MJ. Disorders of tendons. In: Mann RA, Caughlin MJ, eds. *Surgery of the Foot and Ankle.*7th ed. Philadelphia: Mosby; 1999:786-861.

## The Thompson Test

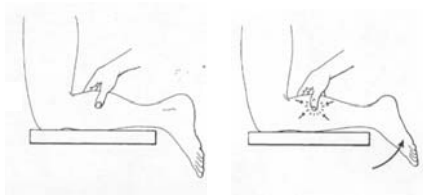

In patients with intact Achilles tendons, squeezing the calf should produce visible plantarflexion of the foot. Compare with the opposite (normal) side. The test is not sensitive for cases of partial rupture.

Used with permission from Caughlin MJ. Disorders of tendons. In: Mann RA, Caughlin MJ, eds. *Surgery of the Foot and Ankle.*7th ed. Philadelphia: Mosby; 1999:786-861.

Supplement to *Emergency Medicine Reports*, September 22, 2003: "Management of Acute Foot and Ankle Disorders in the Emergency Department: Part I—The Ankle." *Authors:* **Gary D. Hals, MD, PhD,** Attending Physician, Department of Emergency Medicine, Palmetto Richland Memorial Hospital, Columbia, SC; **Matt Logan, MD,** Resident Physician, Department of Emergency Medicine, Palmetto Richland Memorial Hospital, Columbia, SC; and **John Cory, MD,** Resident Physician, Department of Orthopedics, Palmetto Richland Memorial Hospital, Columbia, SC.