THOMSON
AMERICAN HEALTH CONSULTANTS

Rapid Access Card Enclosed

PEDIATRIC
Emergency Medicine Reports™

The Practical Journal of Pediatric Emergency Medicine

Volume 9, Number 4 April 2004

*Emergency department (ED) physicians always are looking for ways to enhance clinical care, especially diagnostic tests that provide critical clinical information in a timely, cost-effective manner. Bedside ultrasound (US) is a relatively new clinical tool with many practical and valuable applications. Although the operator (i.e., radiologist or ED physician) may vary depending on the skills and training of the physician and the individual facility where the clinician practices, the value of bedside US in certain clinical scenarios should not be underestimated. Emergency US may be a valuable adjunct to the diagnostic evaluation of the patient. Certain US examinations may be rapidly performed (e.g., focused assessment with sonography for trauma, or FAST), and the ED physician with education, practice, and verification of accuracy may become very comfortable performing this test. Other applications of US are more challenging (e.g., testicular US) and may take longer to master. Advantages to the use of US include portability, the non-invasive nature of the test, and the lack of ionizing radiation and contrast exposure. Even if the ED physician personally does not perform bedside US, an awareness of the diagnostic strides of this modality, particularly in pediatrics, allows for utilization of a noninvasive, non-ionizing test as a screening tool for common pediatric diagnostic challenges. The medical literature supports the expanding application of emergency US to answer focused clinical questions and provide an alternative to more invasive testing. This article provides a comprehensive overview of how bedside US may help answer focused clinical questions in pediatric and adolescent patients.*

*—The Editor*

# Advances in Pediatric Ultrasound

## Part 1: Focused Applications in the Adolescent Female with Abdominal Pain and the Male with Testicular Pain

*Authors:* **Anthony J. Weekes, MD, RDMS,** Associate Medical Director, Emergency Ultrasound Director, Montefiore Medical Center, Bronx, NY; and **Resa E. Lewiss, MD,** Director, Division of Emergency Ultrasound, St. Luke's/Roosevelt Hospital Center, Columbia University College of Physicians and Surgeons, New York, NY.

*Peer Reviewer:* **Michael Blaivas, MD, RDMS,** Associate Professor of Emergency Medicine, Chief, Section of Emergency Ultrasound, Department of Emergency Medicine, Medical College of Georgia, Augusta.

## Introduction

Bedside US has been identified as a diagnostic procedure of integral clinical importance to emergency medicine.[1] It is a particularly useful imaging modality for emergency physicians working in a hospital with limited off-hour radiology resources. Numerous studies have supported the ability of the ED physician

to perform bedside US studies, interpret the results accurately, and answer clinical questions, and in doing so decrease patient length of stay in the ED.[2-7] The American Academy of Emergency Medicine, American College of Emergency Physicians, and Society for Academic Emergency Medicine have issued policies on the application of sonography by emergency physicians.[8-10] At this time, emergency US is an integral part of emergency medicine training programs in North America, but it is not currently a training requirement for those pursuing a pediatric emergency medicine fellowship. Although currently the majority of medical literature supporting bedside US in the ED relates to adult patients, US currently is widely used by pediatric subspecialists in the evaluation of ill or injured children.

This article provides an overview of the emergency ultrasound applications available to the emergency physician when treating the pediatric patient. Part 1 of this article addresses the applications of US for pediatric and adolescent patients with pelvic or testicular complaints. Part 2 will discuss bedside sonography applied to cardiac, abdominal, and renal complaints.

## Pelvic Complaints

**Epidemiology.** The evaluation of female adolescents with abdominal pain and/or vaginal bleeding is a common part of pediatric emergency medicine practice. In either of these situations, the emergency physician must consider the possibility of a pregnancy-related condition. The availability of quick, highly sensitive and specific urine qualitative pregnancy tests makes this a vital part of the initial ED triage assessment of females with these complaints. The cause of the symptoms can be due to a normal intrauterine pregnancy (IUP), an abnormal IUP, or an extrauterine (ectopic) pregnancy. Ectopic pregnancy (EP) is the leading cause of maternal first-trimester pregnancy related deaths, accounting for 9-13% of all pregnancy-related deaths.[11,12] Early detection of an EP in a symptomatic patient is critical. Tubal rupture can compromise fertility and lead to maternal death from hemorrhage. Between 1970 and 1992, there was a 90% decrease in mortality from EP.[11-13] Earlier detection of EPs, before the complications of tubal rupture set in; reduced surgical risks with laparoscopic surgery; and the efficacy of early medical treatment with methotrexate all have contributed to a decrease in EP-related mortality. The Centers for Disease Control and Prevention's National Hospital Discharge Survey looked at the number of women, 15-44 years of age, hospitalized for a diagnosis of EP between 1980 and 2000. After a peak in 1988, there has been a downward trend in the numbers. Unfortunately, the incidence of EP has steadily increased from 0.5% of all pregnancies to about 2% in 1992.[11-13] This most likely is influenced by an increased clinical vigilance and improved US technology, especially in patients taking fertility-stimulating medications or undergoing fertilization and implantation procedures. EPs have presentations that vary from benign to dramatic. The emergency physician must maintain vigilance for the early detection of an EP in the ED. Use of pelvic sonography at the bedside, in the ED, provides accurate and clinically important diagnostic and decision-making information to the emergency physician. A patient's disposition, especially when clinically stable with an IUP, is expedited.[14-16]

**ED Assessment.** Any female patient of reproductive age presenting to the ED with a diversity of symptoms including, but not limited to, abdominal pain, amenorrhea, vaginal bleeding, altered mental status, syncope, relative hypertension or hypotension, nausea, or vomiting should have a pregnancy test. A history of a previous EP, tubal surgery, use of fertility-stimulating medications and procedures, pelvic inflammatory disease, or use of an intrauterine device are well accepted risk factors for an EP. Unfortunately, close to half of the patients diagnosed with EPs have no risk factors.[17] A low severity of pain should not stop the

***Pediatric Emergency Medicine Reports™*** (ISSN 1082-3344) is published monthly by Thomson American Health Consultants, 3525 Piedmont Road, N.E., Six Piedmont Center, Suite 400, Atlanta, GA 30305. Telephone: (800) 688-2421 or (404) 262-7436.

**Vice President/Group Publisher:** Brenda Mooney
**Editorial Group Head:** Valerie Loner
**Managing Editor:** Allison Mechem
**Marketing Manager:** Schandale Kornegay
**GST Registration No.:** R128870672

Periodicals Postage Paid at Atlanta, GA 30304.

**POSTMASTER:** Send address changes to ***Pediatric Emergency Medicine Reports***, P.O. Box 740059, Atlanta, GA 30374.



**Back issues: $57.** Missing issues will be fulfilled by customer service free of charge when contacted within one month of the missing issue's date.

**Subscriber Information**

**Customer Service: 1-800-688-2421**
**Customer Service E-Mail Address:**
customerservice@ahcpub.com
**Editorial E-Mail Address:** allison.mechem@thomson.com
**World-Wide Web page:** http://www.ahcpub.com

**Subscription Prices**

1 year *with* 30 ACEP, AMA, or AAP Category 1 credits: $389;
1 year without credit: $339;

**Multiple copies:**
One to nine additional copies: **$305 each;**
10 or more additional copies: **$271 each.**

Resident's Rate: **$169.50**

All prices U.S. only. U.S. possessions and Canada, add $30 postage plus applicable GST. Other international orders, add $30.

**Accreditation**

***Pediatric Emergency Medicine Reports'™*** continuing education materials are sponsored and supervised by Thomson American Health Consultants. Thomson American Health Consultants (AHC) designates this educational activity for a maximum of 30 hours in category 1 credit toward the AMA Physician's Recognition Award. Each physician should claim only those credits that he/she actually spent in the activity. This CME activity was planned and produced in accordance with the ACCME Essentials.

***Pediatric Emergency Medicine Reports*** is also approved by the American College of Emergency Physicians for 30 hours of ACEP Category 1 credit. This continuing medical education activity has been reviewed by the American Academy of Pediatrics and is acceptable for 30 AAP Credit hours. These credits can be applied toward the PREP Education Award available to Fellows and Candidate Fellows of the American Academy of Pediatrics.

Thomson American Health Consultants is accredited by the Accreditation Council for Continuing Medical Education to sponsor continuing medical education for physicians.

This is an educational publication designed to present scientific information and opinion to health professionals, to stimulate thought, and further investigation. It does not provide advice regarding medical diagnosis or treatment for any individual case. It is not intended for use by the layman. Opinions expressed are not necessarily those of this publication. Mention of products or services does not constitute endorsement. Clinical, legal, tax, and other comments are offered for general guidance only; professional counsel should be sought for specific situations.

This CME activity is intended for emergency and pediatric physicians. It is in effect for 36 months from the date of the publication.

THOMSON
AMERICAN HEALTH CONSULTANTS

**Questions & Comments**
Please call **Allison Mechem,** Managing Editor, (404) 262-5589,or e-mail allison.mechem@thomson.com

**Statement of Financial Disclosure**

Thomson American Health Consultants does not receive material commercial support for any of its continuing medical education publications. In order to reveal any potential bias in this publication, and in accordance with Accreditation Council for Continuing Medical Education guidelines, we disclose that Drs. Weekes, Lewiss, (authors), and Blaivas (peer reviewer) report no consultant, stockholder, speaker's bureau, research, or other financial relationships with companies having ties to this field of study. Dr. Dietrich, editor-in-chief, also reports no consultant, stockholder, speaker's bureau, research, or other financial relationships with companies having ties to this field of study. This publication does not receive commercial support.

emergency physician from continuing with the evaluation for a possible EP. The primary goal is to determine if the pregnancy is potentially dangerous to the mother now or in the near future.

The history and physical examination have limitations as screening tools for the diagnosis of EP.[18] The history should focus on eliciting any irregularity in the vaginal bleeding pattern: changes in regularity, associated discomforts, duration and amount of bleeding.

A prospective study evaluated 486 patients presenting to the ED with first-trimester pregnancy complaints. Although one of every 12 patients in this study had an EP, only 23% had any of the classic risk factors. Other series substantiate this finding, reporting that 40-50 % of patients with EPs were without the common risk factors.[12,17,19,20] Severe pain may elevate an emergency physician's concern for a possible EP and/or rupture, but the absence or mildness of reported pain should not dissuade the physician from thinking of EP.[13,18,19] Although vaginal bleeding in pregnancy, scant to profuse, may be associated with an EP, a lack of vaginal bleeding does not exclude an EP from the differential.[21]

The physical examination should be focused on the patient's vital signs, and abdominal and pelvic exams. The goal is to exclude or confirm the diagnosis of an EP prior to rupture. Normal vital signs often occur with EPs and abnormal IUPs. Although pregnancy may alter a patient's vital signs, abnormal vital signs should suggest hemodynamic instability secondary to hemorrhage. Physical examination findings may be helpful, but a normal examination does not exclude an EP. Ten to 25% of patients with a diagnosis of EP had no positive physical examination findings of palpable masses or tenderness.[12,18,19] In another series, one in 10 patients with an EP had a finding of a palpable adnexal mass and in one-third of the cases, the EP was located intraoperatively on the opposite side suggested by the physical examination.[22-25]

## Ultrasound in Pregnancy

Ultrasound is safe in pregnancy and may be quickly performed. It provides the most reliable and direct evidence of the location and viability of a pregnancy. Both still and dynamic real time imaging are available for immediate interpretation. Early pregnancy evaluation is best performed using the transvaginal (TV) approach. ED patient evaluation with bedside sonography usually is initiated after the qualitative urine pregnancy test result is positive. The vital role of quantitative serum hormonal pregnancy markers will be discussed in detail later in this text.

TV sonography is performed best when the patient's bladder is completely empty. A full bladder occupies too much of an already limited field of view and even can compress key embryonic landmarks. A full bladder also can introduce technical aberrations or artifacts such as scatter and posterior acoustic enhancement (a brighter appearance of the pelvic structures posterior to a fluid-filled area), that can impair proper sonographic visualization of key structures and features of the pelvis such as a fluid collection in the posterior cul de sac. Apply gel into a condom or a finger of an examining glove. This will cover the TV probe and prevent direct contact between the probe and the endovaginal surface. Displace any air bubbles and insert the TV transducer into this covering. Apply gel to the covered transducer tip. Insert the TV probe into the vaginal canal after the patient is in the lithotomy position on a pelvic examining table. TV probes emit US waves at high frequencies of 5-8 MHz. This provides better detailing (resolution) of small embryonic structures. The anatomic orientation tends to be more challenging to the novice. A simple guide to orientation is this: The top of the monitor screen marks where the US waves are emitted. In the case of TV scanning, this is the caudal aspect of the patient. The bottom of the screen shows structures toward the patient's head (cephalad). Longitudinal scans (with the transducer's marker pointing to the room's ceiling) will have anterior structures to the left of the monitor's screen. Posterior structures are to the screen's right. Make slow sweeps of the transducer head from left to right. Coronal scans are obtained by turning the marker from its 12 o'clock position to a 9 o'clock position. Gently moving the probe handle up and down provides a visual sweep of pelvic structures above and below the coronal plane.

Transabdominal (TA) scanning is performed with a 3.5-5.0 MHz obstetrical probe. The wider footprint (transducer surface) and lower frequency of the emitted US waves provide a wider and deeper visual field than that obtained with a TV probe. TA scanning provides a better view of structures outside of the pelvis, but the resolution is not as good as with the TV probe. The urinary bladder should be full while doing a TA pelvic scan. The fluid-filled bladder serves as an acoustic window (i.e., it enhances the transmission of ultrasonic waves). Oral or intravenous hydration can expedite the filling of the bladder. In some centers, the bladder is filled with 0.9% saline solution using a urinary catheter. This is uncomfortable for the patient. In the majority of early pregnancy scans, the TV scan alone was able to yield all the diagnostic information needed clinically.[25,26] A very important advantage of TV scan is that it allows visualization of the structures that confirm the presence of an early IUP at earlier gestational dates (1-1.5 weeks earlier ) than the TA scan. The benefits of a full bladder TA scan are debatable. In one study, the TA scan with a full bladder simply allowed visualization of enlarged uteri and high-riding ovaries. This also was easily accomplished by more transducer pressure during the empty bladder TA scan. Others have stated that an over-distended bladder may displace high riding ovaries and compress the internal cervical os, elongating it and thwarting the diagnosis of an incompetent cervix. In early pregnancy scanning, TV scan offers better resolution images of the gestational sac (GS) contents and the fetal cardiac activity; and better evaluation of the endometrial stripe and the retroverted uterus. With TV scan, there is less patient discomfort and quicker acquisition of clinically pertinent information. A patient's large body habitus may adversely affect TA scan image quality, but TV scan pelvic image quality is unaffected.[26-28]

The TA probe is placed just above the symphysis pubis of the supine patient. Let the marker point to the patient's head. The longitudinal view of the uterus is seen posterior to the full blad-

der. The gray appearance of the uterus contrasts to the echolucent fluid in the bladder. Slowly make a sweep from one end of the uterus to the other. Small, echolucent arcuate blood vessels can be seen on the periphery of the uterus. Gently rock the probe to view the entire uterus from the fundus to the cervix. In the supine patient, any fluid collection is found posterior to the uterus on the screen. A transverse scan of the uterus is done when the probe is rotated 90° counterclockwise from its longitudinal position. Angling the US transducer allows the transmitted sector to slowly sweep the pelvis from a cephalad to caudal direction. The normal uterus tapers as scanned from the fundus to the cervix.

The landmark pelvic organ is the uterus. The non-gravid normal uterus measures between 5-7 cm longitudinally and 4-5 cm transversely. The rectum is posterior, and the bladder is anterior to the uterus. The uterus most commonly is anteflexed, and most easily is seen when the TV probe tip is angled above the horizontal plane. To get a better view of a retroflexed uterus, point the transducer below the horizontal plane. The myometrium has a medium (gray) echogenicity—greater than echolucent bladder fluid. The arcuate vessels located within the periphery of the uterus are also hypoechoic. A young female with no previous pregnancies can have a rather small uterus that may appear elongated.

The endometrial lining appears as an echogenic (white) stripe extending from the mid-uterus down to the cervical os. The endometrial lining thickens and thins during the normal menstrual hormonal cycle. Estrogen stimulation during any pregnancy, intra- or extra-uterine, also thickens the endometrial lining. The endometrial stripe should be scanned from side to side and followed down to the cervix. The cervix may have a few echolucent areas that are benign Nabothian cysts.

The adnexal landmark structures are the ovaries. Ovaries are not fixed in location. The ovaries usually are anterior and medial to the internal iliac arteries. Ovaries, however, may be positioned high in the pelvis, beyond the focal length of the TV probe but within the purview of TA scanning. The typical ovary is oval in shape measuring about $2 \times 2 \times 3$ cm. The ovaries have peripheral echolucent follicles. This gives the ovary a "chocolate chip cookie" appearance. Simple ovarian cysts are circular, thin walled, have no contents (completely echolucent). Tissue immediately posterior to the cyst has an increased echogenicity (posterior acoustic enhancement). An ovarian follicle's diameter should not be larger than 2-2.5 cm and anything larger than that is a cyst. Corpus luteal cysts, remnants of a Graafian follicle, can be found in the later half of a menstrual cycle and during the first 8-10 weeks of a pregnancy. The corpus luteal cyst usually is larger and has thicker walls than regular ovarian follicles or may have a solid appearance.

The cul-de-sac is a region of peritoneal reflection that is posterior to the uterus- a potential space for fluid accumulation. A small amount of fluid may be benign normal physiologic fluid, especially mid-menstrual cycle; moderate to large amounts in another clinical context may represent blood from EP or corpus luteal rupture, or ascitic fluid. Clotting blood has a gray to white echogenicity.

Bowel structures show peristaltic movement when observed closely, but this may take time and patience.

The earliest sonographic finding of a pregnancy is the chorionic or GS. This is a small echolucent (black) area in the uterine cavity and within the endometrial stripe. Because of differences in resolution, the sac is detected earlier (4.5 weeks) with TV scan, compared to 6 weeks with TA scanning.

The normal intrauterine GS is surrounded by two distinct echogenic rings: the inner decidua capsularis and the outer decidua vera. A thin layer of echolucent fluid is sandwiched between these decidual linings. This is referred to as the Double Decidual Sac (DDS) sign. Improvements in US technology have led to further observations that the normal GS is embedded in one of the apposed inner walls of the uterus. An important feature is that the intrauterine GS is eccentric to the endometrial stripe when the uterus is viewed longitudinally. Eccentricity of a GS, on its own, is a not a reliable way to distinguish an ectopic implantation from an intrauterine implantation.

Echolucent areas in the uterus are not always due to a normal early pregnancy and may even be found in an EP. An echolucent area centrally located within a single layer of endometrial echogenicity must not be considered a normal IUP. An EP can hormonally stimulate limited endometrial proliferation (thin white appearance) but central decidual breakdown appears as the central echolucent (black) area. These are the findings of a pseudogestational sac. A pseudogestational sac may be seen in EPs. To add to the diagnostic uncertainty, many early GSs of actual intrauterine pregnancies do not have the hallmark double decidual sign. TV scanning and stricter criteria for diagnosing an IUP help avoid diagnostic mistakes. The GS usually is seen on TV scan when its diameter is greater than 3 mm. The normal GS is oval or round in shape, has a smooth contour, and is located in the fundal or middle portion of the uterus.

GS measurements can provide useful clinical information to the emergency physician. The mean GS inner diameter (taken in three planes) plus 30 gives the gestational age in days. The GS diameter increases at a rate of 1-1.2 millimeters per day. During the first few weeks, the GS is empty. By the time the mean GS diameter reaches 10 mm, the first embryonic structure, the yolk sac (YS), should have been seen already. The YS is the initial source of nutrition for the embryo. The YS is located immediately adjacent to the fetal pole or embryonic plate. A YS is the first feature that reliably and definitively determines the presence and location of a pregnancy. The YS usually is seen on TV scan by the 5th week (6-6.5 weeks with TA scanning) and lasts until week 10-12. It shows up on the monitor as a thin echogenic circle with an echolucent center. The diameter of the normal YS is 3-5 mm. It stays like this until the 10th week, when it regresses. The placenta takes over to become the main vehicle of maternal nutrients to the fetus. Finding an intrauterine YS confirms the diagnosis of an IUP.

The fetus first becomes evident on bedside sonography as a fetal pole by 5.5 weeks with TV scan (seven weeks by TA scan-

## Table 1. Indictors of Fetal Demise

- Poorly formed decidua
- Large subchorionic hemorrhage
- Sac too small or too large ( > 25 mm without an embryo, or 20 mm without yolk sac)
- Distortion of gestational sac shape or contour (angulated or collapsed)
- Gestational sac located low in uterus
- Yolk sac is abnormal:
  - calcified
  - > 10mm
  - < 2 mm between 8-12 weeks
- Bradycardia (fewer than 90 beats per minute)
- No fetal heart activity when crown-rump length is greater than 7 mm
- Discrepancy in size and dates

## Figure 1. Ectopic Pregnancy

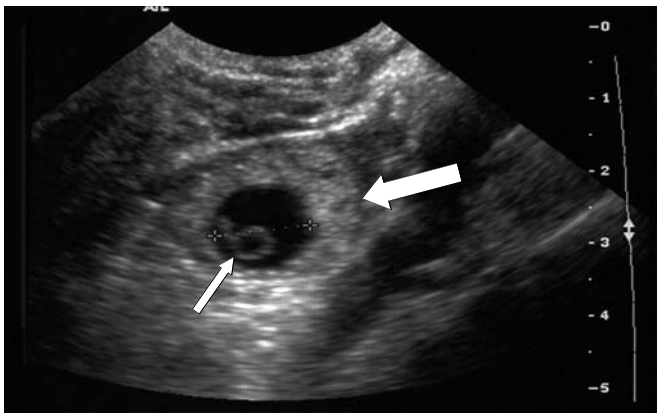

Image shows a pelvic adnexal transverse view of a thick-walled tubal ring (thick arrow) and an inner yolk sac (thin arrow). The empty uterus (not shown) was separate from this structure.

ning). At the earliest point of TV scan detection, the fetal pole is a small (as little as 2 mm), amorphous, but distinct echogenic mass located next to the YS. Eventually, features of a head (crown) and rump appear. The crown-rump length (CRL) is the most accurate indicator of gestational age until the end of the first trimester. Do not include the YS when measuring the CRL. When the fetal pole is greater than 5 mm, the rapid flickering of fetal cardiac activity can be seen. This usually occurs at six weeks using TV scan and at seven weeks by TA scan.

The presence of cardiac activity within the fetal pole confirms the diagnosis of a live pregnancy. *(See Table 1.)* A pseudogestational sac also may have clotted blood. Blood clots may appear as gray to white on the monitor. This may be misinterpreted as a fetal pole. This potential mistake can be avoided by identifying the adjacent YS and/or cardiac activity within the fetal pole.

The clinical question may arise: At what point is absence of fetal cardiac activity consistent with fetal demise in the symptomatic patient? If the fetal pole is no more than 4 mm and no cardiac activity is noted, then the patient should have a repeat US in a few days. The cardiac heart rate can be checked accurately with M-mode tracing. Heart rates between 100 and 170 beats per minute are considered the normal range. It also offers a better prognosis than a pregnancy without evidence of cardiac activity. Between 5-7 mm fetal pole length, the clinician is between the threshold of requiring follow-up imaging in few days and the threshold for confirming an intrauterine fetal demise.

Intermittent fetal extremity movement is a reliable sign of a live pregnancy.

A very important part of the early pregnancy scan is to evaluate the thickness of the myometrium surrounding the GS. A normal IUP is found within the middle third of the uterus. A myometrial rim that is more that 8 mm, at all areas around a GS, which contains a YS or more advanced embryonic structures, secures the diagnosis of an IUP.[29]

**Ectopic Pregnancy.** An EP is defined as any pregnancy that is implanted at a site outside of the middle third of the uterus. This is a more specific definition that emphasizes that not every uterine implantation site is normal or safe.[12,19] The vast majority, more than 95%, of EPs are located in the fallopian tubes. Fewer than 5% of EPs are in or on the ovary, cervix, abdomen, and interstitium.

The US evaluation should include adnexal views, especially when an IUP is not noted.

The coexistence of intrauterine and extrauterine pregnancies is termed a heterotopic pregnancy. Heterotopic pregnancies once were considered rare, occurring in an estimated 1 in 30,000 patients. They still are rare in non-induced pregnancies, but may occur with a frequency as high as 1-3 of every 100 pregnancies in the select group of patients receiving in-vitro fertilization or fertility agents.[30-33]

A definite EP is confirmed when the uterus shows no evidence of a pregnancy and there is an embryo with cardiac activity outside of the uterus. This may or may not include free fluid in the cul-de-sac. *(See Figure 1.)*

*Features Suggestive of an Ectopic Pregnancy.* The vast majority of EPs are located in the fallopian tubes. The normal fallopian tube can be seen with modern US technology, but also may be missed easily. A fallopian tube that is distended or filled with debris such as blood or purulence is easier to detect, but a distended fallopian tube may be mistaken for an ovarian cyst. Scanning such a structure in various planes will display elongation into a tube when the structure (fallopian tube or blood vessel) is viewed longitudinally, and a circular shape in the transverse scan plane. A spherical cyst maintains a circular appearance in any scan plane. In the pregnant state, an adnexal echogenic ring may represent the trophoblastic tissue of an EP. The wall of the ring is 1-4 mm in thickness and is usually 1-3 cm in size. One meta-analysis showed a 95% likelihood of an EP with this ultrasonographic finding.[34-36] Scan carefully to ascertain if it is structurally

**Figure 2. Ectopic Pregnancy**

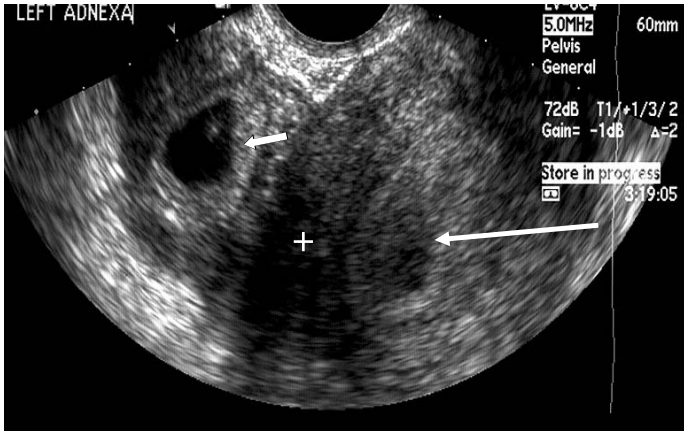


Transvaginal sonogram shows an echogenic thick-walled ring (short arrow). The ring is outside of the uterine fundus (cross). The lateral wall of the tubal ring is the same echogenicity as the endometrium (long arrow).

distinct from the ipsilateral ovary. A thick-walled cystic structure in or on the ovary is very likely to be a corpus luteal cyst: Ovarian EPs are exceedingly rare. A potential dilemma is created when there is no visible IUP, and a thick-walled adnexal structure is found but a separate ipsilateral ovary is not located. The emergency physician is left with an EP, a corpus luteum, or another pelvic structure still on the differential diagnosis list.

Attempts to distinguish between a tubal EP and a corpus luteum during pregnancy recently have been studied. Both the corpus luteum and the EP's trophoblastic ring are highly vascular structures. Applying color Doppler produces a "ring of fire" to both structures. Stein et al found no significant difference in the color Doppler flow distribution within the adnexal wall and the percentage of wall circumference with flow between tubal EPs and corpora lutea.[37] This study also suggested that comparison of the echogenicities of the adnexal thick-walled ring with the echogenicities of the ovaries and endometrial lining can be of assistance in distinguishing between a corpus luteum and an ectopic tubal ring. Ectopic tubal rings typically are equally or more echogenic than the ovarian parenchyma. The majority of walls in the corpus luteum group were of equal or less echogenicity to the endometrium. None of the 31 corpora luteal walls in this small study were more echogenic than the endometrium. Most of the corpora luteal walls had less echogenicity than the endometrium.[37,38] Use only the anterior and lateral walls of the ring when evaluating echogenicity. The posterior wall of any cystic structure is displayed with increased echogenicity due to increased transmission and lessened attenuation of sound passing through the cyst's fluid medium. This phenomenon is termed "posterior acoustic enhancement." Overall, the above-mentioned ancillary sonographic features are suggestive but, individually, are not reliably accurate distinguishing characteristics. *(See Figure 2.)*

Adnexal masses may be visualized. They may be solid, cystic or complex, with varying amounts of echolucent and echogenic areas. Masses that are tender when gently compressed between the TV probe tip and the examiner's hand pressing on the patient's abdomen should raise the suspicion for an EP. If the patient has a previous but recent imaging study, US or CT, that reports the presence of the mass, then it is unlikely to have developed during the current pregnancy. If no such report exists, then the possibility of an EP should not be dismissed. False positive results may come from ovarian masses and hemorrhagic corpus luteal cysts.

The presence of free pelvic or peritoneal fluid, in the absence of US evidence of an IUP, should raise the possibility of rupture of an EP. Ultrasound cannot determine the nature of the peritoneal fluid. In the setting of pelvic pain and/or vaginal bleeding, especially if the pregnant patient has unstable vital signs or is in extremis, consider the fluid to be blood. A small amount of fluid in the pelvis is a common normal finding. While small pelvic fluid collections can be found in EPs and normal IUPs, moderate to large fluid collections have a higher specificity for EP.[39] Fluid collection also may be found in normal and failing pregnancies. Echogenicity within the fluid suggests clotting and should increase suspicion for EP rupture or leak. TA scan may be used to determine if pelvic free fluid has accumulated in the paracolic gutter, hepatorenal or splenorenal potential spaces.

For a patient with an EP, any combination of the above-mentioned findings may be present. In a retrospective study of 109 EP cases, the US findings were: an adnexal mass in close to 80%; pelvic fluid in 82%; an extrauterine GS in 9%; and a pseudogestational sac in about 6% of cases.[40]

**Cervical Pregnancy.** A cervical pregnancy may appear as GS in the cervical area. It may be mistaken for a miscarriage in progress. The distinguishing feature of a cervical EP is that the GS is not irregular or collapsed. Cervical EPs have the significant risk of severe maternal hemorrhage with cervical injury and incompetence. Medical treatment with a cytotoxic agent, methotrexate (local or parenteral), or potassium chloride injected directly into the EP may be used.[41-46]

**Interstitial Pregnancy.** Interstitial pregnancies are unusual and account for 2-3% of all EPs. An interstitial EP can be mistaken for a normal IUP. If the site of implantation is at the junction of the uterine fundus and a fallopian tube, this still is considered an interstitial EP. The mortality rate for an interstitial pregnancy is 2.2% vs. 1% for other tubal pregnancies. An interstitial pregnancy has an easily distensible surrounding that may allow an EP to grow and dilate painlessly. Interstitial EPs tend to rupture at a later age (8-16 weeks gestation). The main danger is that the interstium is a highly vascular part of the uterus—when an EP expands within it and eventually ruptures, massive blood loss may ensue.

When evaluating any pelvic obstetrical scan, it is very important to assess the myometrium surrounding a GS. This is referred to as the myometrial mantle. Myometrium should completely surround the GS. Myometrium between the GS and the uterine cavity is suspicious for an interstitial EP. The finding of an asymmetric myometrial mantle produces a differential diagnosis of preg-

nancy in a myomatous uterus; an interstitial or corneal pregnancy; and a pregnancy in one of the horns of a bicornuate uterus (a true cornual pregnancy).

During the US, note the location of the GS. Normal embryonic implantation occurs in the middle one-third of the uterus. A GS high in the uterine fundus may be implanted in the interstitium. Other features suggestive of an early interstitial EP include the majority of the early GS being out of the uterine cavity. This is termed an eccentrically located GS.

Myometrial measurements are important. The myometrial mantle measurement begins from the outer edge of the decidual echogenicity. Pick a point along the edge of the decidual lining that appears to be the thinnest region of myometrial covering and create an imaginary tangent. The line of measurement must be kept perpendicular to the tangent and extend to the outer edge of the uterus. A myometrial mantle that is less than 8 mm at any point around the GS should have a confirmatory TV scan and/or obstetrical consultation to address concerns of an interstitial location.[29,47,48] Others have less stringent criteria: more than 5 mm of myometrium in all planes confirms a normal IUP.[29] *(See Figure 3.)*

When a GS is not evident, observe the entire uterus. In one study, 8 out of 12 interstitial EPs had a heterogeneous mass in the interstitial regions of the uterus as the only key sonographic feature.[49] Other features include a separate empty uterine cavity, with endometrial echoes, that is distinct from the eccentric GS or cornual heterogeneous mass.

The hormonally stimulated endometrial linings that are apposed create an echogenic linear endometrial stripe in a longitudinal view of the uterus. Within a few weeks of the development of an IUP, the linings are separated, removing this sonographic feature. An interstitial EP allows the stimulated endometrial surfaces to remain interfaced. The sonographic finding of endometrial canal or the interstitial portion of the tube—referred to as the interstitial line sign—is considered more sensitive (80%) than the eccentricity of GS (sensitivity 40%) and myometrial thinning (sensitivity 40%) in detecting an interstitial EP.[49-51] The specificity of the interstitial line sign was 92%.

The emergency physician should elicit as much sonographic information as is available to effectively increase the chance of an early detection of this EP or lower the risk of a false positive diagnosis of IUP.[29,52]

EP rupture in the highly vascular interstitium is associated usually with severe hemorrhage. Thorough scanning cannot be over-emphasized. Even after an IUP is confirmed, the clinician should make scanning the adnexae a habit. Heterotopic pregnancies, and even bilateral tubal EPs, are possible, though rare.[53]

**US Findings and Clinical Diagnosis.** Many scans in the pregnant patient with abdominal pain and or vaginal bleeding will not have evidence of definite EP or a normal IUP. *(See Table 2.)* TV scan has altered the ability of the physician to address concerns, viability and the prognosis for patients with first trimester pregnancies and abdominal discomfort and vaginal bleeding.[54]

**Figure 3. Interstitial Ectopic Pregnancy**

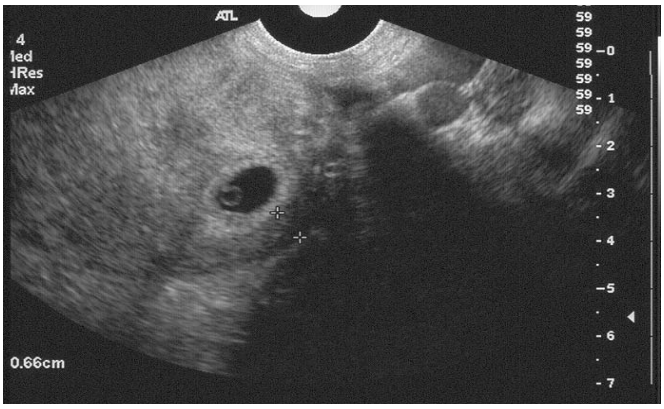


Image shows an interstitial ectopic pregnancy. Longitudinal transvaginal scan of the uterus shows the gestational sac with an inner yolk sac. The sac is high in the uterine fundus; the myometrium surrounding the sac is asymmetric and thin. The outer edge of decidual lining to outer myometrium measures less than 7 mm. This can easily be mistaken for an intrauterine pregnancy.

Threatened abortion is the diagnosis used to describe the condition of vaginal bleeding and/or abdominal discomfort without a history or description of the passage of fetal tissue or GS and a closed cervical os on the physical examination. An IUP is seen on US. If the intrauterine sac contains a YS or a fetal pole smaller than 5 mm with no cardiac activity, then the diagnosis of threatened abortion is accurate. Such patients are at risk for a miscarriage but may come to term as healthy pregnancies. Minimal bleeding and stable clinical appearance and vital signs permit discharge with close obstetrical follow-up.

If the fetal pole is larger than 5 mm with no fetal cardiac activity, then a different diagnosis—a nonviable pregnancy—is more accurate.[54]

It has been suggested that terms such as inevitable, incomplete, and complete abortions become subcategories of the nonviable pregnancy diagnosis.[54] Do not use the term "threatened abortion" in a patient if no definitive IUP (indeterminate findings) is featured on the US. Pregnancy at undetermined site is more accurate and maintains the suspicion of a possible EP. One study showed that 43% of confirmed EP had an initial erroneous diagnosis of threatened abortion.

Traditionally, incomplete abortion characterized the finding of an open cervical os in a patient with a history of passing clots or tissue and partial emptying of the uterus. The uterine cavity has variable irregular echogenic appearances but no true GS. The physical exam and/or the scan reveals closed cervical os. Endometrial thickness greater than 5 mm needs obstetric evaluation within a few days and, if greater than 10 mm, may be an indication for induced evacuation of the uterus for possible retained products of conception. Less than 5 mm endometrial thickening is considered an empty uterus, and expectant management—rather than dilatation and curettage (D&C), dilatation and

## Table 2. Pelvic Ultrasound Findings Consistent with an Indeterminate Study

| ULTRASOUND FINDING | DESCRIPTION OF FINDING |
|---|---|
| Empty uterus | The endometrial cavity is empty and the endometrial lining is uniform, with or without thickening. |
| Nonspecific fluid | An anechoic collection within the endometrial cavity; an echogenic border is not prominent or present. Its average diameter is fewer than 10 mm. |
| Echogenic material | A heterogeneous, possibly irregular contoured echogenic material identified in the endometrial cavity. There is no sac-like structure. |
| Abnormal sac | An anechoic region with no contents in the endometrial cavity; the anechoic mean diameter is > 10 mm or has irregular margins. |
| Heterogeneous material within the uterus | Reticulated or lacy echoes with or without distinct margins. May include trophoblastic disease, and degenerating uterine tumors. Heterogeneity of the uterine fundus may indicate a myoma or interstitial ectopic pregnancy. |
| Normal sac | An empty, smoothly shaped anechoic region with prominent echogenic rim margins; has no features of an abnormal sac. |

evacuation (D&E), or medical therapy—is safe from the risks of endometritis and coagulopathy due to retained products of conception (POC).[55]

In an inevitable abortion, there is no history of passage of clots or tissue. The cervical os is open, and an IUP is present on US.

**Completed Abortion.** There is a history of bleeding, which may be heavy, with the passage of tissue. The cervical os is now closed and the uterus is completely empty by US. This can occur with a nonviable IUP or an EP. Reliable confirmation is a confirmed IUP (previous ED or hospital visit and an US finding of an IUP, preferably documented). Passage of clots should not be used as evidence of passage of fetal tissue. Unless a fetus or obvious POC is visualized on inspection, only the finding of chorionic villi by tissue pathology can confirm the abortion of an IUP.

"Missed abortion" is the term used when there is no history of the passage of tissue and the nonviable pregnancy is not yet expelled from the uterus. It was used to signify patients with retained POCs for more than three weeks and who, thus, were at risk for endometritis and coagulopathy. Routine and earlier use of US have made the amount of retained products rather than length of time from fetal death, the determinant of the need for an induced evacuation of uterine contents. The term "missed abortion" is outdated and rarely should be used.[54]

Fetal demise should be cautiously diagnosed. Serial sonographic examinations within a week can determine if development has occurred or not. Confident first evaluation confirmation of fetal demise can occur if the GS is too large, larger than 25 mm without a fetal pole or larger than 20 mm without a YS (sometimes called a blighted ovum due to anembryonic development); the GS is distorted (e.g., irregular, collapsed, or angulated); the GS is located low in the uterus; there is a large subchorionic hemorrhage (semi-lunar echolucent area outside of the sac's outer decidual layer); and no fetal cardiac activity in a fetal pole larger than 7-10 mm. A more conservative approach is to refrain from the definitive diagnosis of fetal demise at an initial ED evaluation and facilitate scheduling of a follow-up evaluation in one to two days to accurately determine if fetal demise (evidenced by a lack of development of cardiac activity for example) has occurred.

**Indeterminate Ultrasound Findings.** Up to 75% of patients presenting to an ED with first-trimester pregnancy complications can be diagnosed accurately having an IUP or an EP with the use of TV scan. When US findings do not fulfill the criteria for a definite EP, a normal IUP, or abnormal IUP, then the emergency physician is left without clear clinical answers for the patient's pain and bleeding. The emergency physician is left to surmise whether the pregnancy is simply too early to be visualized, is abnormal IUP, or is an occult EP. There are several common findings that can be considered as indeterminate scans.

**Indeterminate Pelvic Findings.** *(See Table 2.)* Dart et al provided a subclassification of indeterminate pelvic scan findings and the risk of EP in each category.[56] It underscored the point that a completely empty uterus in a pregnant female is more likely (greater than 80% in this study) to be an abnormal pregnancy. Features of a normal sac were associated with an eventual normal pregnancy in 40% of the patients in the subcategory. Eventually, fewer than 5% were diagnosed as EPs.

The above-mentioned research prospectively evaluated the risk of EP after creating subclassifications of indeterminate pelvic ultrasonography findings within the uterus. The categories were empty uterus with or without endometrial stripe (ES) thickness,[57] an abnormal GS, nonspecific fluid collection, echogenic material, and a normal-appearing GS.[56]

In Dart's study, the normal appearing sac had the lowest risk for EP; in this group, there were no EPs and 30% were eventually confirmed as normal IUPs.

The highest risk groups were the empty uterus and nonspecific fluid collection groups. Twenty-five percent of cases with an empty uterus turned out to be EPs, and only 6% were normal IUPs. In the nonspecific fluid group, 20% had normal IUPs, but 13% were EPs. The subgroup with an endometrial stripe thicker than 13 mm had no EPs. Close to 70% of the empty uterus group with an endometrial stripe smaller than 8 mm were EPs.[56]

The abnormal GS group had no normal IUPs and only 3% EPs. The echogenic material group had no normal IUPs but just under 10% EPs.[56] Echogenic material may represent retained products of conception, degenerating pseudogestational sac contents or even a molar pregnancy.

Indeterminate US findings leave the distinct possibility that an EP may exist. The majority of initial USs on symptomatic women who turned out to have EPs are nondiagnostic, or indeterminate, of an EP.[21] In a study by Gracia et al, six published diagnostic algorithms of diagnosing EP, involving combinations of clinical examinations, TV scan, serum progesterone, serum human chorionic gonadotrophin (hCG), and D&C were compared. The study concluded that the best outcomes (most efficient and most accurate) came out of practice guidelines using TV scan as the first step, followed by serum hCG levels, in patients with indeterminate scan results.[58] The serum hCG level has its most significant value in clinical management of patients with indeterminate findings. hCG is a hormonal marker produced by trophoblastic cells that is gestational age specific. It normally doubles every 1.4-2.0 days until it reaches 100,000 mIU/mL.[17]

Discriminatory levels—1500 mIU/mL for TV scan and 6500 mIU/mL for TA scan—have been used as the lower hormonal level at which a GS should be visible.[35,59-66]

Clinicians, radiologists, and US technicians, not uncommonly, debate about the utility of an US when the serum hCG level is not available—either the blood sample is not drawn or sent, the result is not known—or the serum level is below the discriminatory level. Several studies have addressed the clinical question of the usefulness of TV scan in detecting an IUP when the serum hCG level is below 1000-1500 mIU/mL.[13,27,64]

Several studies have shown that IUP can be detected at levels less than 1000 mIU/mL by TV scan, including levels less than 300 mIU/mL.[27,64,67,68]

TV scanning also may detect an EP when the serum hCG level is less than 1000 mIU/mL.[69] In a prospective study of 439 patients presenting in the first trimester with pain and/or vaginal bleeding, 56 had the final diagnosis of EP.[24] Four of the 33 patients with evidence of EP on initial TV scan had serum hCG levels less than 1000 m IU/mL. Twenty-nine percent of the EPs, with serum hCG levels less than or equal to 1000 mIU/mL, already were ruptured.[24]

A retrospective study looked at 111 symptomatic first trimester ED patients, with an initial serum hCG of less than 1000 mIU/mL, Twenty-three were diagnosed with EPs. The initial TV scan confirmed an EP in nine of the 23 (39%).[70]

One series concluded that if there are no signs of IUP by TV scan and the discriminatory zone of greater than 1500 mIU/mL is reached, an EP still remains a distinct possibility (25% incidence).[71] At what value of serum hCG level, with no IUP by TV scan, can you be certain there is an abnormal pregnancy? One study concluded that with a serum level greater than 3000 mIU/mL, a normal IUP is unlikely and there was a high level of safety, without fear of aborting viable gestation, in performing D&C to verify pathology finding of chorionic villi and/or a diagnostic laparoscopy.[72]

In a prospective study of 354 patients suspected of having an EP (because of indeterminate TV scan, pain, bleeding, or risk factors), a cut-off serum hCG value of greater than 2000 mIU/mL correctly indicated an EP in all cases. When the indeterminate TV scan findings included an adnexal mass or free pelvic fluid, the cut-off was lower—1500 mIU/mL.[73]

After obtaining an indeterminate TV scan, can one rely on hormonal markers to determine if the pregnancy is normal, abnormal, or an EP? Unfortunately, a single, qualitative hCG level does not distinguish an IUP from an EP. Another hormonal marker is progesterone. Progesterone is produced mainly by the corpus luteum early in pregnancy. Unlike hCG levels, the progesterone level remains constant throughout the first trimester. Values less than 5 ng/mL are very highly predictive of an abnormal pregnancy—in one study, fewer than 0.2% of patients with progesterone levels below 5 ng/mL had viable IUPs.[74] A progesterone level greater than 25 ng/mL is very supportive of a normal IUP. Unfortunately, the majority of pregnancies have levels within the above-mentioned limits and cannot be distinguished as normal IUP, abnormal IUP, or EP. Use of progesterone was studied in the two highest risk subclasses of indeterminate TV scan findings. The sensitivity and specificity of a progesterone cut-off level of 5.0 ng/mL in diagnosing an abnormal pregnancy were 84% and 97%, respectively. In diagnosing EPs, however, the sensitivity and specificity of this hormonal cut-off level were 88% and 40%, respectively.[75]

The hormonal dynamics of an abnormal pregnancy are different. EPs can grow or regress. In one study, the doubling time for EPs is much slower at 7.7 days. Seven of 29 EPs had decreasing values (half-life 7.1 ± 3.8 days).[76] In most normal IUPs, the serum beta hCG level has a doubling time of 1.6-2.1 days.[77] Using greater than 66% rise in 48 hours as a cut-off, several studies have tried to determine if there are predictors of EP when serial hCG levels are used in patients with indeterminate TV scan findings.

A rise in hCG levels greater than 50-66% in two days suggests growth of a pregnancy. More that 80% of normal IUPs exhibit such dynamics. Unfortunately, so do 12-35% of EPs.[73,77-79]

An abnormal rise is considered to be less than 66% in two days. This is found in mostly abnormal pregnancies, includes the majority of EPs in one study, but may be found in up to 27% of normal IUPs.[77]

A decrease in hCG level is stronger evidence of an abnormal pregnancy. Twenty-four to 50% of EPs in two studies had hormonal decreases.[76,78] The majority of EPs will fail on their own.

There were no normal IUPs with more than 50% hCG decrease in 48 hours.[73,77] EPs tend to have longer half-lives than miscarriages or abnormal IUPs.[80] In one study, more than 85% of EPs showed a decrease of less than 50% in two days.[80] Fewer than 1% of pregnancies with indeterminate TV scan findings and a hCG decrease of less than 50% in 48 hours evolved into normal IUPs.[73,77] EP still remains possible, regardless of the serial

HCG pattern. A follow-up TV scan and repeat HCG should be done in 48 hours of the initial indeterminate TV scan findings. Decreasing hCG levels are so highly predictive of a non-viable pregnancy that D&C, D&E, or laparoscopic surgery can be employed at this point to make the diagnosis if the repeat TV scan still has indeterminate findings.

**Summary—Ectopic Pregnancy Protocol.** The ED patient population has a higher prevalence of EP than the general population. The diagnoses of a definite IUP (normal or abnormal) or a definite EP have relatively clear disposition and management plans. In cases where the TV scan is considered indeterminate, a real-time serum hCG level should be obtained. Serum hCG levels above the discriminatory level for TV scan should have obstetrical consultation especially if there is significant pain or findings such as free fluid, complex adnexal masses, an adnexal ring, or other incidental findings such as fibroids or an intrauterine device. Patients who have indeterminate TV scan findings, no incidental findings, hCG levels below the discriminatory level, and who show clinical stability require close follow-up, a repeat TV scan, and serum hCG in two days. Strict instructions need to be given to return immediately to the ED with any increase in abdominal pain and/or vaginal bleeding, dizziness, or syncope, as these symptoms may suggest rupture of an unseen EP. Such an EP protocol lessens the incidence of delayed diagnoses and ruptured EP. An earlier diagnosis of an unruptured EP allows tubal-conserving medical treatment to be employed.[15]

## Pelvic Inflammatory Disease

Abdominal pain in the adolescent female may be accompanied by vaginal discharge. Physical examination findings may include lower abdominal tenderness, cervical discharge, cervical motion tenderness and adnexal tenderness or fullness. When the diagnosis of pelvic inflammatory disease (PID) is made or suspected, TV scan has its use in staging of this disease. Endometrial thickening without a more plausible reason, such as the proliferative stage as secretory phase of the menstrual cycle, should prompt the clinician to search the adnexae for tubal wall prominence and/or filling. A tubal structure may appear cystic when initially viewed in transverse plane but lengthens with a 90° turn of the transducer. The normal fallopian tube usually is not visualized by sonography unless it is surrounded by, or filled with, fluid. The tubal walls may appear thickened. Hazy echogenicity within the tube may represent purulence. The ovarian margins, usually well demarcated, may now become unclear and blend in with the inflamed tubal structure forming a complex tubo-ovarian abscess. Sonographic structural tenderness may be elicited. The nonpregnant patient with these findings warrants more aggressive inpatient antimicrobial treatment.

## Ovarian Torsion

Ovarian torsion (OT) is clinically suspected when an adolescent female presents with a sudden onset of lower unilateral abdominal pain and associated nausea and vomiting. Torsion may occur during pregnancy as the tissue supporting the ovaries and oviducts develop more laxity. Classic histories and physical examination findings are not commonly available for the emergency physician. An abdominal or pelvic exam commonly misses causative pelvic masses seen on TV scan. The finding of a unilateral adnexal or ovarian mass/lesion on sonography will heighten concern that there may be rotational momentum to provoke varying degrees of ovarian blood flow obstruction. Each ovary has dual arterial supply. In one study, younger children with OT had either cystic teratomas or normal ovaries with no underlying etiology as the cause of their OTs. It is very rare to see torsion without an ovarian mass or cyst. An ovarian cyst simply may be the cause of the female patient's pain without actually causing OT. Internal echoes or heterogeneity within an ovarian cyst exclude the interpretation of a simple ovarian cyst and rules in a complex ovarian cyst. A complex ovarian cyst may suggest a neoplastic presence or hemorrhage within the cyst. A hemorrhagic cyst usually presents with acute onset of pain and a delayed or prolonged menses. The sonographic appearance is varied and depends on the amount of blood and clots within the ovarian cysts. A cyst may rupture, causing acute abdominal pain with spillage of fluid into the pelvic cavity. In older children, the cause was either a follicular or a corpus luteal cyst.[81] Absence of ovarian flow on the symptomatic side confirms ovarian ischemia. Both arterial and venous flow should be assessed. Early in torsion the venous flow is reduced and ovarian engorgement ensues. The dual ovarian arterial flow may not yet be compromised. Prolonged torsion eventually leads to both venous and arterial blood flow cessation to the ovary. Scanning an enlarged ovary during a pain-free interval may also show flow despite a high pretest probability of OT. This should not allow the clinician to dismiss OT from the differential diagnosis. OT has been found intraoperatively in patients with normal color flow Doppler studies. Reduced color flow Doppler is nonspecific to torsion and can be found in other ovarian problems such as cystic lesions.[82] Maintaining a high index of suspicion and seeking the skill of a more experienced sonographer or radiologist in unclear cases may be prudent.

## Pediatric Testicular Sonography

Although the most common etiology of acute scrotal pain in male pediatric and adolescent patients presenting to the ED is epididymitis, the most concerning and potentially organ compromising is testicular torsion.[83-85] The focused application of emergency US in the pediatric patient presenting with acute scrotal pain is the presence or absence of testicular torsion. Emergency physicians have demonstrated the ability to accurately diagnose testicular torsion with proper training.[86]

**ED Assessment.** In the child or adolescent presenting to the ED with acute scrotal pain, the differential diagnosis includes torsion (of the testicle or testicular appendage), trauma, and orcho-epididymitis. If the patient is presenting with subacute or chronic pain, a testicular condition such as inguinal hernia, hydrocele, variocele, or mass is more likely. Less common diagnoses to consider include Henoch-Schönlein purpura, idio-

## Table 3. Performing a Bedside Testicular Ultrasound

**PATIENT COMFORT**
- Pain control
- Frog-legged position
- Isolate testicles and prop on towels

**HIGH FREQUENCY PROBE**

**IDENTIFY 4 STRUCTURES**
- Testicle
- Epididymal head
- Epididymal body
- Vascular bundle

**COLOR FLOW DOPPLER BOTH TESTICLES**

**SPECTRAL DOPPLER BOTH TESTICLES**

## Table 4. Ultrasound Findings in a Variety of Testicular Conditions

| SONOGRAPHIC FINDING | TESTICULAR CONDITION |
|---|---|
| No flow | Testicular torsion, post-traumatic rupture |
| Decreased flow | Torsion of testicle or appendage, hydrocele, inguinal hernia |
| Increased flow | Epididymitis, orchitis, tumor, variocele |
| Enlarged epididymal head/body | Epididymitis |
| Normal flow | Hydrocele, post-traumatic rupture, inguinal hernia |

pathic scrotal edema, neonatal testicular torsion, or scrotal dermatopathology.

Adequate history and physical examination is of paramount importance in deciding whether or not torsion may be excluded from the differential diagnosis. Ask the patient or primary provider to describe the pain (i.e., location, duration, onset, previous history), history of cryptochordism, trauma, dysuria, urethral discharge, sexual activity, HIV, change in testicular or scrotal size, and testicular cancer in the family.

Physical examination of the patient with acute testicular pain includes a thorough evaluation of the abdomen, inguinal canal, scrotum, testis and epididymis. Perform a rectal examination if indicated. Laboratory analysis includes a urinalysis and urine culture and a urethral swab and culture. Perform a bedside testicular US and determine if a formal US or radionuclide study should be ordered. If torsion is suspected or cannot be ruled out, a surgical consultant should be contacted emergently.

**Testicular Sonography.** Bedside US is a particularly useful imaging modality for physicians working in a hospital with limited off-hour radiology resources. *(See Table 3.)* Bedside testicular sonography should be performed using a high frequency linear probe (7.5-10mHz). B-mode imaging of the testicles is inadequate for a proper evaluation. The US machine must have color or power Doppler options as well as spectral Doppler for a thorough evaluation of the testicle. Depending upon the specifications of the US machine available, power Doppler is preferable to color Doppler because of higher sensitivity.[87,88] In the Doppler mode, the US transducer perceives the frequency changes of fluid velocity over time. Spectral Doppler requires a basic understanding of US physics and waveforms. Graphically, spectral Doppler represents the flow velocity in time. The power of such flow is displayed as pixel brightness. The visualized brightness correlates with the number of red blood cells at a velocity at a point in time. Spectral Doppler allows waveform differentiation of venous vs. arterial blood flow.

Begin the examination by optimizing patient comfort and privacy. The patient should lay supine with the legs in a frog-leg position. Towels or sheets are used to prop up and isolate the testicles. Prior to initiation of the examination, pain medication may be administered. A copious amount of warmed coupling gel should be available. The four key anatomical features to be identified are the testicle, the body and tail of the epididymis, the spermatic cord, and the vascular bundle.

The testicle is composed of multiple septations arising from the tunica albuginea and encapsulated by the tunica vaginalis. The head body and tail of the epididymis lies adjacent to the testis and leaves the scrotal sac as the vas deferens. The vas runs in the spermatic cord along with the lymphatic drainage, testicular artery, cremasteric artery, deferential artery, and genitofemoral nerve. The testicle should be imaged in both the longitudinal and transverse planes. The epididymis should be identified in all cases.

First, examine the normal testicle. The testicle should appear homogeneously echogenic. The adjacent epididymis appears similarly homogeneous, but brighter or hyperechoic. By convention, the head of the epididymis should be on the left side of the screen. Set the spectral Doppler settings. Identify the vascular bundle with delineation of the venous and arterial waveforms respectively. Then, examine the affected testicle without adjusting settings. Once color flow Doppler identifies flow in multiple areas of the testicle, spectral Doppler should similarly document both venous and arterial waveforms.[87]

Decreased blood flow to the testicle is expected with testicular torsion, torsion of the appendix testis, hydrocele, abscess, hematoma or hernia. In torsion of the appendix testis, a third object next to the epididymis is seen. *(See Table 4.)* Increased flow is expected in inflammatory processes such as epididymitis, orchitis, and in a variocele, especially when the patient performs a Valsalva maneuver.

**Ultrasound vs. Radionuclide Imaging.** The advantages of US compared to nuclear imaging of the testicle include cost (less expensive), speed, and minimal invasiveness.[89,90] Nuclear imaging may be falsely positive in cases of hydrocele, abscess, hematoma, or scrotal hernia. It may be inaccurate in cases of sponta-

neous detorsion of the testis or in late-stage torsion with extensive scrotal edema. There may be an exception in young children, as blood flow is difficult to evaluate in the small testis.[90]

## Testicular Torsion

Testicular torsion is a surgical emergency. Two-thirds of cases occur in boys 12-18 years of age.[85,90] Time is critical and directly related to salvage rates of the gonadal organs. Physiologically, pain is caused by the testicle twisting on its own axis in the setting of laxity within the spermatic cord. Such twisting compromises particularly the arterial blood supply to the testicle, putting it at risk for infarction. The pain of testicular torsion typically is acute at onset; located in the lower abdomen, inguinal, or scrotal area; and may be associated with nausea, vomiting, or fever.[90] The patient or primary care provider should be queried about previous incidence of undescended testicle, similar acute pain episodes, preceding trauma, or physical exertion, which is associated with torsion in up to 20% of cases.[91,92] Testicular torsion also should be considered in patients complaining of flank pain but without renal calculi. On physical examination, the characteristics of the testicle should be noted. Particularly important is if the affected testicle is swollen, tender, lying higher, or horizontal, or the patient is lacking the cremasteric reflex.[90,93] B-mode imaging may be adequate only if one testicle is grossly necrotic or edematous secondary to complete lack of blood flow. Color Doppler imaging may be adequate if there is obviously no or diminished blood flow to one testicle when compared with the unaffected side. Venous blood flow is compromised before arterial flow in testicular torsion.[87] If the extent of blood flow to each testicle seems similar, spectral Doppler is necessary to confirm both venous and arterial waveforms.[87]

Torsion of the appendix testis or appendix epididymis is more common than torsion of the testicle itself and should be suspected in those age 7-12 years.[83] The presentation clinically is difficult to distinguish from testicular torsion, and only should be decided by a urologist. The acuity and severity of pain may be less than that of testicular torsion, the cremasteric reflex may be present, and a "blue dot" sign of an infarcted appendage may be visible. Sonographically, normal or increased blood flow to the testis may be seen.[90]

A testicle that is torsing and detorsing may demonstrate hyperemia. Perform serial examinations of the testicle and contact a surgical consultant if torsing/detorsing is suspected.

Whether diagnosed clinically or sonographically, emergent consultation with a urologist is indicated. Organ viability is directly related to time, with 100% viability if detorsion is accomplished within six hours.[85,94] Discussion of neonatal testicular torsion is beyond the scope of this paper. A manual detorsion of the testicle may be attempted in the ED when high clinical suspicion for testicular torsion exists. Success is suggested with relief of pain and reposition of the testicle to a normal anatomic position within the scrotum.

## Epididymitis

Epididymitis should be considered in any sexually active adolescent male complaining of unilateral testicular pain. Pathophysiologically, bacteria spreads retrograde from the prostate or bladder via the vas deferens. In younger boys, epididymitis can result from structural abnormalities in the urinary tract or torsion of the appendix testis. Complications of epididymitis include infarction, abscess, and infertility.

Physiologically, the epididymis becomes infected and inflamed, causing increased blood flow to the testicle. Usually, the testicle is swollen, tender, and the cremasteric reflex is intact. Urinalysis and culture, urethral swab and culture, and syphilis tests should be performed. Sonographically, in a patient with epididymitis, the epididymis is enlarged and the parenchyma appears more hyperechoic. Color flow and spectral Doppler US should be utilized to document increased flow. With acute inflammation, the epididymal head or body is enlarged when measured in comparison to the unaffected side. Orchitis occurs when the infectious or inflammatory process in the epididymis spreads to the testicle. The testicle becomes enlarged, painful, and edematous. Again, documentation of increased blood flow on the affected side is the sonographic key to differentiating this diagnosis from testicular torsion. Prescribe anti-inflammatory medication and scrotal elevation for pain control. Prescribe antibiotic treatment for the patient and partners.

## Testicular Trauma

A patient presenting with blunt trauma to the testicle may complain of a painful, swollen, and ecchymotic scrotum. Physical examination of a normal-appearing scrotum and a nontender testicle accompanied by sonographic visualization of a normal-appearing testicle is reassuring for exclusion of significant damage. If blunt trauma to the testicle disrupts the normal echogenic parenchymal texture (testicular fracture) or the testicular borders are irregular (disruption of the tunica vaginalis), contact a urologist emergently.

## Testicular Masses

Any testicular mass detected in the ED is a neoplasm until proven otherwise. Malignant masses typically present as a painless testicular enlargement, but become painful with hemorrhage or infarction within the tissue. Sonographic differentiation of a hematoma vs. mass usually is appreciable with color Doppler, since tumors tend to be vascular, while no flow is appreciated in a hematoma. The mass may present with a range of sonographic presentations with enlarged size and varying degrees of echogenicity. Order a formal and complete testicular US when a mass is found.

## Hernia

An inguinal hernia may present as acute scrotal pain when there is extension into the scrotum when abdominal contents herniate through the inguinal canal, causing swelling and pain to the affected scrotum. Consult the surgery service as clinically indicated.

## Hydrocele

A hydrocele is fluid that fills the potential space between the parietal and visceral tunica vaginalis within the scrotum. The patient with a hydrocele may note a scrotal swelling with or without pain. The fluid collection may be associated with testicular pathology such as torsion of the testis or appendage, epididymitis, tumor, or trauma. A congenital hydrocele, typically painless, results from a defect in the inguinal canal, causing direct communication with the abdominal cavity. The resultant soft, cystic scrotal mass typically disappears in the supine position, but recurs when standing. Hydroceles communicating with the peritoneal cavity resolve, but do not change if noncommunicating. Perform a sonogram to rule out more serious diagnoses. Sonographically, an anechoic fluid collection surrounds the testes anterolaterally. Refer patients for non-urgent follow-up to a urologist.

## Variocele

A variocele is a typically painless collection of abnormally dilated spermatic cord veins contained in the scrotum. The pampiniform plexus surrounding the spermatic cord appears and feels like a collection of dilated and tortuous veins. Typically found on routine examination in boys age 10-15 years, patients with a variocele may appreciate a dull pain and fullness in the scrotum that worsens with standing. Most varioceles are found on the left side secondary to the acute angle at which the testicular vein drains into the left renal vein, while the right testicular vein drains directly into the inferior vena cava.[90] On color flow Doppler there is normal vascular perfusion to the testicle, and when the patient performs the Valsalva maneuver, it is possible to see increased flow through the vascular structure outside the testicle. Refer the patient to a urologist as an outpatient.[95,96]

## Summary—Testicular Ultrasound Protocol

Studies support the notion that appropriately trained emergency physicians accurately can diagnose testicular torsion in the ED.[3,86,97] Accurate diagnosis requires facility in using color and spectral Doppler sonography. As with all emergency US applications, accurate evaluation is user-dependent and directly correlated with the practitioner's experience and comfort. Keep in mind the focused and limited question being addressed. Blood flow to the testicle in the infant and pre-pubescent boy is particularly difficult to evaluate and may require a formal radiographic evaluation.

## References


1. Heller MB, Mandavia D, Tayal VS, et al. Residency training in emergency ultrasound: Fulfilling the mandate. *Acad Emerg Med* 2002;9:835-839.
2. Blaivas M, Sierzenski P, Plecque D, et al. Do emergency physicians save time when locating a live intrauterine pregnancy with bedside ultrasonography? *Acad Emerg Med* 2000;79:988-993.
3. Blaivas M, Batts M, Lambert M. Ultrasonographic diagnosis of testicular torsion by emergency physicians. *Am J Emerg Med* 2000;182:198-200.
4. Blaivas M, Lambert MJ, Harwood RA, et al. Lower-extremity Doppler for deep venous thrombosis--can emergency physicians be accurate and fast? *Acad Emerg Med* 2000;72:120-126.
5. Mandavia DP, Aragona J, Chau L, et al. Ultrasound training for emergency physicians--a prospective study. *Acad Emerg Med* 2000; 7:1008-1014.
6. Lanoix R, Leak LV, Gaeta T, et al. A preliminary evaluation of emergency ultrasound in the setting of an emergency medicine training program. *Am J Emerg Med* 2000;18:41-45.
7. Lanoix R. Credentialing issues in emergency ultrasonography. *Emerg Med Clin North Am* 1997;15:913-920.
8. American Academy of Emergency Medicine. Position Statement: *Performance of Emergency Screening Ultrasound Examinations* Adopted by the AAEM Board of Directors. Feb. 1, 1999.
9. American College of Emergency Physicians, Policy #400327 *Emergency Ultrasound Guidelines* June 2001.
10. Society for Academic Emergency Medicine. Ultrasound Position Statement. *SAEM Newsletter*: September 1991.
11. Brennan DF. Ectopic pregnancy—Part II: Diagnostic procedures and imaging. *Acad Emerg Med* 1995;212:1090-1097.
12. Brennan DF. Diagnosis of ectopic pregnancy. *J Fla Med Assoc* 1997; 849: 549-556.
13. Della-Giustina D, Denny M. Ectopic pregnancy. *Emerg Med Clin North Am* 2003;21:565-584.
14. Mateer JR, Aiman EJ, Brown MH, et al. Ultrasonographic examination by emergency physicians of patients at risk for ectopic pregnancy. *Acad Emerg Med* 1995; 2:867-873.
15. Mateer JR, Valley VT, Aiman EJ, et al. Outcome analysis of a protocol including bedside endovaginal sonography in patients at risk for ectopic pregnancy. *Ann Emerg Med* 1996;27:283-289.
16. Timor-Tritsch I, Greenridge S, Admon D, et al. Emergency room use of transvaginal ultrasonography by obstetrics and gynecology residents. *Am J Obstet Gynecol* 1992;166:866-872.
17. Fylstra DL. Tubal pregnancy: A review of current diagnosis and treatment. *Obstet Gynecol Surv* 1998; 53:320-328.
18. Buckley RG, King KJ, Disney JD, et al. Derivation of a clinical prediction model for the emergency department diagnosis of ectopic pregnancy. *Acad Emerg Med* 1998;5:951-960.
19. Brennan DF. Ectopic pregnancy—Part I: Clinical and laboratory diagnosis. *Acad Emerg Med* 1995;2:1081-1089.
20. Emerson DS, McCord, ML. Clinician's approach to ectopic pregnancy. *Clin Obstet Gynecol* 1996;39:199-222.
21. Butts S, Sammel M, Hummel A, et al. Risk factors and clinical features of recurrent ectopic pregnancy: A case control study. *Fertil Steril* 2003;80: 1340-1344.
22. Dart RG, Kaplan B, Varaklis K. Predictive value of history and physical examination in patients with suspected ectopic pregnancy. *Ann Emerg Med* 1999; 33:283-290.
23. Kabus M, Rupprecht E, Kohler K, et al. Vein of Galen malformation in a newborn infant with clinical symptoms of a cardiologic emergency. *Kinderarztl Prax*,1990;58:247-253.
24. Kaplan BC, Dart RG, Moskos M, et al. Ectopic pregnancy: Prospective study with improved diagnostic accuracy. *Ann Emerg Med* 1996; 28:10-17.
25. Valenzano M, Anserini P, Remorgida V, et al. Transabdominal and transvaginal ultrasonographic diagnosis of ectopic pregnancy: clinical implications. *Gynecol Obstet Invest* 1991;31:8-11.
26. Tessler FN, Schiller VL, Perella RR, et al. Transabdominal versus endovaginal pelvic sonography: Prospective study. *Radiology* 1989;170:553-556.
27. Bernaschek G, Rudelstorfer R, Csaicsich, P. Vaginal sonography versus serum human chorionic gonadotropin in early detection of pregnancy. A*m J Obstet Gynecol* 1988;158:608-612.
28. Hill LM, Breckle, R. Value of a postvoid scan during adnexal sonography. *Am*

*J Obstet Gynecol* 1985;152:23-25.
29. DeWitt C, Abbott J. Interstitial pregnancy: A potential for misdiagnosis of ectopic pregnancy with emergency department ultrasonography. *Ann Emerg Med* 2002;40:106-109.
30. Hann LE, Bachman DM, McArdle CR. Coexistent intrauterine and ectopic pregnancy: A reevaluation. *Radiology* 1984;152:151-154.
31. Molloy D, Deambrosis W, Keeping D, et al. Multiple-sited (heterotopic) pregnancy after in vitro fertilization and gamete intrafallopian transfer. *Fertil Steril* 1990;53:1068-1071.
32. Reece EA, Petrie RH, Sirmans MF, et al. Combined intrauterine and extrauterine gestations: A review. *Am J Obstet Gynecol* 1983;146:323-330.
33. Vanderheyden JS, Van Dam PA. The rising incidence of heterotopic pregnancy: Two case reports. *Eur J Obstet Gynecol Reprod Biol* 1987;24:341-346.
34. Cacciatore B. Can the status of tubal pregnancy be predicted with transvaginal sonography? A prospective comparison of sonographic, surgical, and serum hCG findings. *Radiology* 1990;177:481-484.
35. Cacciatore B, Stenman UH, Ylostalo P. Diagnosis of ectopic pregnancy by vaginal ultrasonography in combination with a discriminatory serum hCG level of 1000 IU/l (IRP). *Br J Obstet Gynaecol* 1990;97:904-908.
36. Brown DL, Doubilet PM. Transvaginal sonography for diagnosing ectopic pregnancy: Positivity criteria and performance characteristics. *J Ultrasound Med* 1994;13:259-266.
37. Stein M, Ricci Z, Novak L, et al. Sonographic comparison of the tubal ring of ectopic pregnancy with the corpus luteum. *J Ultrasound Med* 2004;23:57-62.
38. Frates MC, Visweswaran A, Laing FC. Comparison of tubal ring and corpus luteum echogenicities: A useful differentiating characteristic. *J Ultrasound Med* 2001; 20:27-31.
39. Nyberg DA, Hughes MP, Mack LA, et al. Extrauterine findings of ectopic pregnancy of transvaginal US: importance of echogenic fluid. *Radiology* 1991;178:823-826.
40. Chechia A, Koubas A, Terras K, et al. Ultrasonographic diagnosis of ectopic pregnancies. A report of 109 cases. *Tunis Med* 2000;78:589-594.
41. Leeman LM, Wendland CL. Cervical ectopic pregnancy. Diagnosis with endovaginal ultrasound examination and successful treatment with methotrexate. *Arch Fam Med* 2000;9:72-77.
42. Eggebo TM, Elve KO. Cervical pregnancy treated with methotrexate. *Tidsskr Nor Laegeforen* 1998;118:1053.
43. Sepulveda WH, Vinals F, Donetch G, et al. Cervical pregnancy. A case report. *Arch Gynecol Obstet* 1993; 252:155-157.
44. Pastorelli G, Steiner R, Haller, U. Cervical pregnancy. A gynecologic-obstetric emergency situation. *Gynakol Geburtshilfliche Rundsch* 1997;37:209-215.
45. Giambanco L, Chianchiano N, Palmeri V, et al. Cervical pregnancy: An obstetric emergency. A clinical case. *Minerva Ginecol* 1998;50:321-324.
46. Pretzsch G, Einenkel J, Baier D, et al. Cervical pregnancy: Case report and review of the literature. *Zentralbl Gynakol* 1997;119:25-34.
47. De Bruyne F, Tutschek B, Hucke J, et al. Interstitial pregnancy treated with local and systemic methotrexate. *Gynecol Obstet Invest* 1998:46:133-138.
48. Batioglu S, Haberal A, Yesilyurt H, et al. Successful treatment of cornual pregnancy by local injection of methotrexate under laparoscopic and transvaginal ultrasonographic guidance. *Gynecol Obstet Invest* 1997;44:64-66.
49. Ackerman TE, Levi CS, Dashefsky SM, et al. Interstitial line: Sonographic finding in interstitial (cornual) ectopic pregnancy. *Radiology* 1993;189:83-87.
50. Jafri SZ, Loginsky SJ, Bouffard JA, et al. Sonographic detection of interstitial pregnancy. *J Clin Ultrasound* 1987;15:253-257.
51. Graham M, Cooperberg PL. Ultrasound diagnosis of interstitial pregnancy: Findings and pitfalls. *J Clin Ultrasound* 1979;7:433-437.
52. Maliha WE, Gonella P, Degnan EJ. Ruptured interstitial pregnancy presenting as an intrauterine pregnancy by ultrasound. *Ann Emerg Med* 1991;20:910-912.
53. Ryan MT, Saldana, B. Bilateral tubal ectopic pregnancy: A tale of caution. *Acad Emerg Med* 2000;7:1160-1163.
54. Nadukhovskaya L, Dart R. Emergency management of the nonviable intrauterine pregnancy. *Am J Emerg Med* 2001;19:495-500.
55. Rulin MC, Bornstein SG, Campbell JD. The reliability of ultrasonography in the management of spontaneous abortion, clinically thought to be complete: A prospective study. *Am J Obstet Gynecol* 1993;168:12-15.
56. Dart RG, Burke G, Dart L. Subclassification of indeterminate pelvic ultrasonography: prospective evaluation of the risk of ectopic pregnancy. *Ann Emerg Med* 2002;39:382-388.
57. Spandorfer SD, Barnhart KT. Endometrial stripe thickness as a predictor of ectopic pregnancy. *Fertil Steril*, 1996;66:474-477.
58. Gracia CR, Barnhart KT. Diagnosing ectopic pregnancy: Decision analysis comparing six strategies. *Obstet Gynecol* 2001;97:464-470.
59. Bree RL, Edwards M, Bohm-Velez M, et al. Transvaginal sonography in the evaluation of normal early pregnancy: Correlation with HCG level. *AJR Am J Roentgenol* 1989;153:75-79.
60. Kadar N, Romero R. HCG assays and ectopic pregnancy. *Lancet* 1981;1: 1205-1206.
61. Kadar N, Romero R. Discriminatory human chorionic gonadotropin zone "demilitarized." *Am J Obstet Gynecol* 1989;160:1255-1257.
62. Kadar N, Taylor KJ, Rosenfield AT, et al. Combined use of serum HCG and sonography in the diagnosis of ectopic pregnancy. *AJR Am J Roentgenol* 1983;141:609-615.
63. Kadar N, DeVore G, Romero R. Discriminatory hCG zone: Its use in the sonographic evaluation for ectopic pregnancy. *Obstet Gynecol* 1981;58:156-161.
64. Kadar N, Bohrer M, Kemmann E, et al. The discriminatory human chorionic gonadotropin zone for endovaginal sonography: A prospective, randomized study. *Fertil Steril* 1994;61:1016-1020.
65. Stiller RJ, Haynes de Regt R, Blair, E. Transvaginal ultrasonography in patients at risk for ectopic pregnancy. *Am J Obstet Gynecol* 1989;161:930-933.
66. Peisner DB, Timor-Tritsch IE. The discriminatory zone of beta-hCG for vaginal probes. *J Clin Ultrasound* 1990;18:280-285.
67. Shapiro BS, Escobar M, Makuch R, et al. A model-based prediction for transvaginal ultrasonographic identification of early intrauterine pregnancy. *Am J Obstet Gynecol* 1992;166:1495-1500.
68. Nyberg DA, Mack LA, Laing FC, et al. Early pregnancy complications: Endovaginal sonographic findings correlated with human chorionic gonadotropin levels. *Radiology* 1988;167:619-622.
69. ACEP Clinical Policies Committee and Clinical Policies Subcommittee on Early Pregnancy. American College of Emergency Physicians. Clinical policy: Critical issues in the initial evaluation and management of patients presenting to the emergency department in early pregnancy. *Ann Emerg Med* 2003;41: 123-133.
70. Dart RG, Kaplan B, Cox C. Transvaginal ultrasound in patients with low beta-human chorionic gonadotropin values: How often is the study diagnostic? *Ann Emerg Med* 1997; 30:135-140.
71. Barnhart KT, Simhan H, Kamelle SA. Diagnostic accuracy of ultrasound above and below the beta-hCG discriminatory zone. *Obstet Gynecol* 1999; 94:583-587.
72. Dart R, Kaplan B, Ortiz L, et al. Normal intrauterine pregnancy is unlikely in emergency department patients with either menstrual days > 38 days or beta-hCG > 3,000 mIU/mL, but without a gestational sac on ultrasonography. *Acad Emerg Med* 1997; 4:967-971.
73. Mol BW, Hajenius PG, Engelsbel S, et al. Serum human chorionic gonadotropin measurement in the diagnosis of ectopic pregnancy when transvaginal sonography is inconclusive. *Fertil Steril* 1998;70:972-981.
74. McCord ML, Muram D, Buster JE, et al. Single serum progesterone as a screen for ectopic pregnancy: Exchanging specificity and sensitivity to obtain optimal test performance. *Fertil Steril* 1996; 66:513-516.

75. Dart R, Ramanujam, P, Dart L. Progesterone as a predictor of ectopic pregnancy when the ultrasound is indeterminate. *Am J Emerg Med* 2002; 20:575-579.
76. Bateman BG, Nunley WC Jr, Kolp LA, et al. Vaginal sonography findings and hCG dynamics of early intrauterine and tubal pregnancies. *Obstet Gynecol* 1990;75:421-427.
77. Dart RG, Mitterando J, Dart L. Rate of change of serial beta-human chorionic gonadotropin values as a predictor of ectopic pregnancy in patients with indeterminate transvaginal ultrasound findings. *Ann Emerg Med* 1999;34:703-710.
78. Romero R, Kadar N, Copel JA, et al. The value of serial human chorionic gonadotropin testing as a diagnostic tool in ectopic pregnancy. *Am J Obstet Gynecol* 1986;155:392-394.
79. Emancipator K, Bock JL, Burke, MD. Diagnosis of ectopic pregnancy by the rate of increase of choriogonadotropin in serum: Diagnostic criteria compared. *Clin Chem* 1990;36:2097-2101.
80. Kadar N, Romero R. Further observations on serial human chorionic gonadotropin patterns in ectopic pregnancies and spontaneous abortions. *Fertil Steril* 1988;50:367-370.
81. Kokoska ER, Keller MS, Weber TR. Acute ovarian torsion in children. *Am J Surg* 2000;180:462-465.
82. Quillin SP, Siegel MJ. Transabdominal color Doppler ultrasonography of the painful adolescent ovary. *J Ultrasound Med* 1994;13:549-555.
83. Lewis AG, Bukowski TP, Jarvis PD, et al. Evaluation of acute scrotum in the emergency department. *J Pediatr Surg* 1995; 30:277-282.
84. Fernandez MS, Dominguez C, Sanguesa C, et al. The use of color doppler sonography of the acute scrotum in children. *Cir Pediatr* 1997;10:25-28.
85 Edelsberg, JS Surh YS. The acute scrotum. *Emerg Med Clin North Am* 1988;6:521-546.
86. Blaivas M, Sierzenski P, Lambert M. Emergency evaluation of patients presenting with acute scrotum using bedside ultrasonography. *Acad Emerg Med* 2001;8:90-93.
87. Blaivas M. *Testicular*. In: Ma OJ, Mateer JR, eds. *Emergency Ultrasound*. New York: McGraw-Hill Companies; 2003, 221-237.
88. Albrecht T, Lotzof K, Hussain HK, et al. Power Doppler US of the normal prepubertal testis: Does it live up to its promises? *Radiology* 1997;203:227-231.
89. Fenner MN, Roszhart DA , Texter JA. Testicular scanning: evaluating the acute scrotum in the clinical setting. *Urology* 1991;38:237-241.
90. Perron CE. "Pain-Scrotal." In: Fleischer GR, Fleischer L, eds. *Pediatric Emergency Medicine*. New York: Lippincott Williams & Wilkins; 2000:473-481.
91. Cos LR, Rabinowitz R. Trauma-induced testicular torsion in children. *J Trauma* 1982; 22:244-246.
92. Prater JM, Overdorf BS. Testicular torsion: A surgical emergency. *Am Fam Physician* 1991;44:834-840.
93. Kadish HA, Bolte, RG. A retrospective review of pediatric patients with epididymitis, testicular torsion, and torsion of testicular appendages. *Pediatrics* 1998;102:73-76.
94. Pillai SB, Besner GE. Pediatric testicular problems. *Pediatr Clin North Am* 1998; 45:813-830.
95. Kass EJ. Adolescent varicocele. *Pediatr Clin North Am* 2001; 48: 1559-1569.
96. Kass EJ. The adolescent varicocele: Treatment and outcome. *Curr Urol Rep* 2002;3:100-106.
97. Blaivas M, Sierzenski P. Emergency ultrasonography in the evaluation of the acute scrotum. *Acad Emerg Med* 2001; 8:85-89.

## CME Objectives

The CME objectives for *Pediatric Emergency Medicine Reports* are to help physicians:

a.) Quickly recognize or increase index of suspicion for specific conditions;

b.) Understand the epidemiology, etiology, pathophysiology, historical and physical examination findings associated with the entity discussed;

c.) Be educated about how to correctly formulate a differential diagnosis and perform necessary diagnostic tests;

d.) Apply state-of-the-art therapeutic techniques (including the implications of pharmacologic therapy discussed) to patients with the particular medical problems discussed;

e.) Provide patients with any necessary discharge instructions.

## Physician CME Questions

31. Which of the following is true regarding TV scanning compared with TA scanning?
    A. TV allows confirmation of an IUP one week earlier than TA scanning
    B. TV is best accomplished with a full bladder.
    C. TA scanning is more accurate in obese patients.
    D. TV offers better visualization of the structures outside the pelvis than TA scanning.

32. Which of the following ultrasonographic findings of the uterus suggests an abnormal pregnancy?
    A. An intrauterine yolk sac with a diameter of 4 mm
    B. A circular echolucent region ( mean diameter of 5 mm) with a thick echogenic rim
    C. An oval-shaped gestational sac
    D. A fetal pole, 4 mm in length, with no cardiac activity
    E. A gestational sac with a yolk sac, with a myometrial mantle of less than 4 mm

33. A 15-year-old female who has had two prior pregnancies and miscarried both (G2P0) presents to the ED with mild lower abdominal pain and heavy vaginal bleeding. Her last normal menstrual period was two months ago. The urine HCG is positive. Her vital signs are within normal limits and there is mild tenderness to the left lower abdomen and left adnexal region. There is some vaginal bleeding from a closed cervical os. The ED diagnostic workup of the above-mentioned vignette can have a vast permutation of outcomes. Which of the following conclusions is correct?
    A. A serum HCG of 900 mIU/mL argues strongly against the clinical utility of performing a TV scan.
    B. Free pelvic fluid is an uncommon sonographic feature associated with an EP.
    C. A normal-appearing gestational sac, with a yolk sac, and myometrial mantle greater than 1 cm confirms an IUP.
    D. Serum HCG 3000 mIU/mL *and* no sonographic features of a definite IUP confirms an EP.

34. Increased blood flow to the testicle is seen on sonography in which of the following causes of acute scrotal pain?
    A. Testicular torsion
    B. Torsion of the appendix testis
    C. Hydrocele

D. Epididymitis
E. Hernia

35. Two-D color Doppler sonography with spectral Doppler is the radiographic test of choice to evaluate vascular compromise in infant boys when the emergency physician suspects testicular torsion.
A. True
B. False

36. Which of the following is *true* regarding bedside testicular sonography?
A. Increased blood flow on 2-D color Doppler sonography to the affected testicle suggests testicular torsion.
B. Normal 2-D color Doppler sonography showing flow to both testicles is insufficient to rule out torsion.
C. A low frequency 3-5 mHz probe is best for imaging the testicle.
D. Inability to visualize the epididymal head or body rules out epididymitis.
E. Spectral Doppler waveforms of both arterial and venous flow to the affected testicle suggests torsion.

37. Which of the following factors has/have resulted in a decrease in the mortality associated with ectopic pregnancies?
A. Earlier detection of ectopic pregnancies
B. Reduced surgical risks with laproscopic surgery
C. Efficacy of earlier treatment with methotrexate
D. All of the above

38. Which of the following is a risk factor/are risk factors for an ectopic pregnancy?
A. Tubal surgery
B. Fertility stimulating medications
C. Pelvic inflammatory disease
D. All of the above

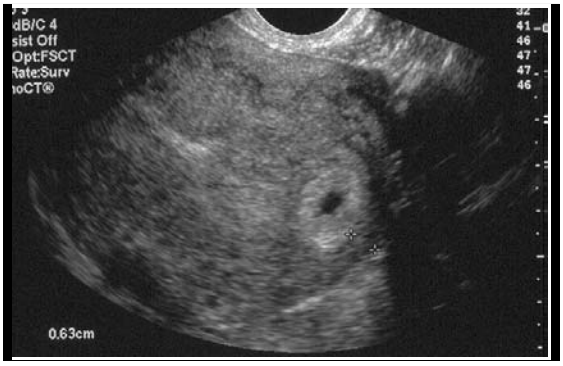


39. The pelvic ultrasound image above was obtained in an adolescent female with lower abdominal cramping and scant vaginal spotting. Vital signs are within normal limits and the pelvic and abdominal exams reveal no tenderness and a closed cervical os. The urine pregnancy test is positive and the serum HCG is not yet available. Which of the following interpretations of the image is correct?
A. A definite ectopic pregnancy
B. A definite early IUP with a double decidual sign.
C. Retained products of conception.
D. Indeterminate ultrasound with a thin myometrial mantle.

40. Which of the following is true regarding torsion of the appendix testes?
A. The cremasteric reflex always is absent.
B. The "blue dot" sign may be present.
C. It usually occurs in toddlers.
D. Decreased blood flow is seen sonographically.

## CME Instructions

Physicians participate in this continuing medical education program by reading the article, using the provided references for further research, and studying the questions at the end of the article. Participants should select what they believe to be the correct answers, then refer to the list of correct answers to test their knowledge.

To clarify confusion surrounding any questions answered incorrectly, please consult the source material. After completing this activity, you must complete the evaluation form that will be provided at the end of the semester and return it in the reply envelope provided to receive a certificate of completion. When your evaluation is received, a certificate will be mailed to you.

**Answer Key**:

| | |
|---|---|
| 31. A | 36. B |
| 32. A | 37. D |
| 33. C | 38. D |
| 34. D | 39. D |
| 35. B | 40. B |

**In Future Issues:**

**Pediatric Ultrasound: Cardiac and Abdominal Evaluation**

PEDIATRIC Emergency Medicine Reports

The Practical Journal of Pediatric Emergency Medicine

# Ultrasound — Abdominal and Testicular Pain

## Indicators of Fetal Demise

- Poorly formed decidua
- Large subchorionic hemorrhage
- Sac too small or too large ( > 25 mm without an embryo, or 20 mm without yolk sac)
- Distortion of gestational sac shape or contour (angulated or collapsed)
- Gestational sac located low in uterus
- Yolk sac is abnormal:
  - calcified
  - > 10mm
  - < 2 mm between 8-12 weeks
- Bradycardia (fewer than 90 beats per minute)
- No fetal heart activity when crown-rump length is greater than 7 mm
- Discrepancy in size and dates

## Ectopic Pregnancy

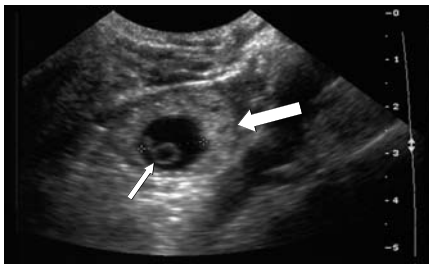

Image shows a pelvic adnexal transverse view of a thick walled tubal ring (thick arrow) and an inner yolk sac (thin arrow). The empty uterus (not shown) was separate from this structure.

## Ectopic Pregnancy

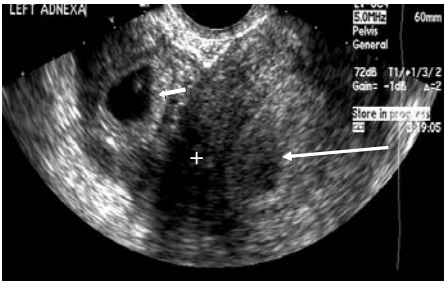


Transvaginal sonogram shows an echogenic thick-walled ring (short arrow). The ring is outside of the uterine fundus (cross). The lateral wall of the tubal ring is the same echogenicity as the endometrium (long arrow).

## Interstitial Ectopic Pregnancy


Image shows an interstitial ectopic pregnancy. Longitudinal transvaginal scan of the uterus shows the gestational sac with an inner yolk sac. The sac is high in the uterine fundus; the myometrium surrounding the sac is asymmetric and thin. The outer edge of decidual lining to outer myometrium measures less than 7 mm. This can easily be mistaken for an intrauterine pregnancy.

## Pelvic Ultrasound Findings Consistent with an Indeterminate Study

| ULTRASOUND FINDING | DESCRIPTION OF FINDING |
|---|---|
| Empty uterus | The endometrial cavity is empty and the endometrial lining is uniform, with or without thickening. |
| Nonspecific fluid | An anechoic collection within the endometrial cavity; an echogenic border is not prominent or present. Its average diameter is fewer than 10 mm. |
| Echogenic material | A heterogeneous, possibly irregular contoured echogenic material identified in the endometrial cavity. There is no sac-like structure. |
| Abnormal sac | An anechoic region with no contents in the endometrial cavity; the anechoic mean diameter is > 10 mm or has irregular margins. |
| Heterogeneous material within the uterus | Reticulated or lacy echoes with or without distinct margins. May include trophoblastic disease, and degenerating uterine tumors. Heterogeneity of the uterine fundus may indicate a myoma or interstitial ectopic pregnancy. |
| Normal sac | An empty, smoothly shaped anechoic region with prominent echogenic rim margins; has no features of an abnormal sac. |

## Performing a Bedside Testicular Ultrasound

**PATIENT COMFORT**

- Pain control
- Frog-legged position
- Isolate testicles and prop on towels

**HIGH FREQUENCY PROBE**

**IDENTIFY 4 STRUCTURES**

- Testicle
- Epididymal head
- Epididymal body
- Vascular bundle

**COLOR FLOW DOPPLER BOTH TESTICLES**

**SPECTRAL DOPPLER BOTH TESTICLES**

## Ultrasound Findings in a Variety of Testicular Conditions

| SONOGRAPHIC FINDING | TESTICULAR CONDITION |
|---|---|
| No flow | Testicular torsion, post-traumatic rupture |
| Decreased flow | Torsion of testicle or appendage, hydrocele, inguinal hernia |
| Increased flow | Epididymitis, orchitis, tumor, variocele |
| Enlarged epididymal head/body | Epididymitis |
| Normal flow | Hydrocele, post-traumatic rupture, inguinal hernia |

Supplement to *Pediatric Emergency Medicine Reports*, April 2004: "Advances in Pediatric " *Authors:* **Anthony J. Weekes, MD, RDMS,** Associate Medical Director, Emergency Ultrasound Director, Montefiore Medical Center, Bronx, NY; and **Resa E. Lewiss, MD,** Director, Division of Emergency Ultrasound, St. Luke's/Roosevelt Hospital Center, Columbia University College of Physicians and Surgeons, New York, NY. *Peer reviewer:* **Michael Blaivas, MD, RDMS,** Associate Professor of Emergency Medicine, Chief, Section of Emergency Ultrasound, Department of Emergency Medicine, Medical College of Georgia, Augusta.



**Vice President and Group Publisher:** Brenda Mooney. **Editor-in-Chief:** Ann Dietrich, MD, FAAP, FACEP. **Editorial Group Head:** Valerie Loner. **Managing Editor:** Allison Mechem. For customer service, call: **1-800-688-2421.** 