THOMSON
AMERICAN HEALTH CONSULTANTS

Rapid Reference Card Enclosed

Visit EMRonline.com for the latest emergency medicine information.

The Practical Journal for Emergency Physicians

Emergency Medicine Reports®

Volume 25, Number 17 August 9, 2004

Patients suffering from facial trauma present daily in virtually every emergency department (ED) across the country. The goal of emergency physicians (EPs) in treating ED patients is a smooth and confident transition of the patient through diagnosis and treatment of his or her condition while providing first-rate care. Care of a patient with facial injuries is multifaceted, including some issues unique to facial trauma. Foremost in the patient's mind are concerns about pain management and facial scarring. While the EP is cognizant of the patient's pain and potentially disfiguring scars, the EP's primary concern is for airway maintenance, which can challenge even the most skilled physician. There also is risk of deadly occult injury. Associated injuries can involve four of the five senses, as well as injuries to the brain, cervical spine (C-spine), chest, abdomen, and extremities. In addition, consultation to care for these patients also can be complex.

The Facial Trauma Patient in the Emergency Department: Review of Diagnosis and Management

Part I: Life-Threatening Injury and General Wound Repair

Authors: **Gary D. Hals, MD, PhD**, Attending Physician, Department of Emergency Medicine, Palmetto Richland Memorial Hospital, Columbia, SC; **Brandi McClain-Carter, MD**, Resident Physician, Department of Emergency Medicine, Palmetto Richland Memorial Hospital, Columbia, SC; and **Brent Mullis, MD**, Chief Resident, Department of Emergency Medicine, Palmetto Richland Memorial Hospital, Columbia, SC.

Peer Reviewers: **Andrew D. Perron, MD, FACEP, FACSM**, Residency Program Director, Department of Emergency Medicine, Maine Medical Center, Portland; and **Howard A. Werman, MD**, Associate Professor of Clinical Emergency Medicine, The Ohio State University College of Medicine and Public Health, Columbus; Medical Director, MedFlight, Columbus, OH.

Facial trauma is common, with head and neck wounds accounting for 50% of the 12 million traumatic wounds treated in EDs in the United States annually.[1] Estimating a charge per patient of $200, this translates to $1.2 billion annually just for laceration repair. Facial injuries also are quite variable and range from a small laceration on the chin or a chipped tooth to massive trauma that can require emergent management of a difficult airway to save the patient's life. Like fingertip injuries, many areas of the face are very sensitive and even small injuries, such as corneal abrasions, can cause tremendous pain relative to their size. Facial injuries usually are sudden, unexpected events that often produce intense emotional distress along with pain from the injury. Patients may be concerned that their injuries permanently will affect their vision, hearing, taste, or sense of smell. In addition,

patients can be very worried about how the injuries will affect their appearance, even with only minor injuries. These concerns are more than just physical, as one study of trauma patients in a large urban hospital found that 25% met criteria for post-traumatic stress disorder one month after injury.[2] As many patients will not have had a chance to see their injuries before arrival at the ED, their imaginations may run wild with worst-case scenarios. These feelings can be at their extreme in parents of young children who present with facial injuries for their first ED visit.

The causes of facial trauma also can be problematic for the ED physician. While motor vehicle accidents account for up to 50% of facial fractures, fully 33% are the result of assault.[3] The assault cases include domestic violence, sexual assault, and child abuse cases as well as barroom brawlers. The arrival of any of these patients can, in a matter of seconds, bring the smooth flow of any ED to a screeching halt. Further, while facial injuries are obvious and distracting, many of these patients will have more dangerous but subtle internal injuries that easily can be overlooked. Injuries associated with facial trauma are common and include: brain injury (25%),[4] C-spine injury (6%),[5] basal skull fractures, chest injuries (29%),[4] abdominal injuries (38%),[4] and extremity fractures (33%).[4]

Lastly, obtaining consults for these also can be difficult, and turf wars can be commonplace in some EDs. Plastic surgeons, otolaryngologists, oral surgeons, and ophthalmologists often all lay claim to overlapping areas of facial injury. Frequently, it is up to the EP to decide which consultant is the best choice for a given situation based on the EP's knowledge of the consultant's experience, abilities, and preferences. In other EDs, the opposite may occur. There may be a shortage of willing consultants to treat complex facial cases due to the combination of inconvenient time of presentation, perceived low likelihood of compliance and/or payment and seemingly high legal risk. In addition, most EPs have had experience with the patient or parent of a child who demands that plastic surgeons come in at all hours of the day and night to fix very minor facial lacerations under the misguided thought that plastic surgery will not leave a scar.

The purpose of this series is to provide an overview of the complex topic of facial trauma. For simplicity, the term facial trauma will be assumed to include the scalp. This article will cover management of severe injury with a focus on airway management, burns, hemorrhage, and associated injury. Next there will be a brief overview of wound management with special emphasis on facial wounds. Parts II and III will discuss facial injuries divided into anatomic sections (forehead/scalp, orbit, midface, mandible, ear, nose, mouth). The discussion will include care and repair of soft-tissue injury and deep-structure injury, including fracture and nerve injury.

—The Editor

Life-Threatening Injury

Airway Management and Facial Trauma. Facial trauma is caused more often by blunt trauma (i.e., motor vehicle accidents [MVAs], assault, etc.), and it is not unusual for these patients to require intubation early in their treatment. (*See Table 1.*) Associated brain injury and/or chest and abdominal injuries can result in a low Glasgow coma scale (GCS) or revised trauma score below levels that require intubation. Further, a patient with significant facial injury may not be able to protect his or her airway due to bleeding or from anatomic distortion. Other patients may not be cooperating sufficiently as a result of intoxication and/or brain injury and require intubation to allow computed tomography (CT) scan or other imaging to be performed safely. Regardless of the reason for intubation, the presence of facial trauma in these patients makes each case a potentially difficult intubation.

Airway management becomes difficult when one anticipates or encounters trouble intubating the patient. The airway attempt

Emergency Medicine Reports™ (ISSN 0746-2506) is published biweekly by Thomson American Health Consultants, 3525 Piedmont Road, N.E., Six Piedmont Center, Suite 400, Atlanta, GA 30305. Telephone: (800) 688-2421 or (404) 262-7436.

Vice President/Group Publisher: Brenda Mooney
Editorial Group Head: Valerie Loner
Specialty Editor: Shelly Morrow Mark
Marketing Manager: Schandale Kornegay
GST Registration No.: R128870672

Periodicals postage paid at Atlanta, GA. **POSTMASTER:** Send address changes to ***Emergency Medicine Reports***, P.O. Box 740059, Atlanta, GA 30374.

Back issues: $31. Missing issues will be fulfilled by customer service free of charge when contacted within one month of the missing issue's date.

Multiple copy prices: One to nine additional copies, $359 each; 10 to 20 additional copies, $319 each.

Subscriber Information

Customer Service: 1-800-688-2421

Customer Service E-Mail: customerservice@ahcpub.com
Editorial E-Mail: shelly.mark@thomson.com

World Wide Web page: http://www.ahcpub.com

Subscription Prices

1 year *with* 60 ACEP/60 AMA/60 AAFP Category 1/Prescribed credits (52 AOA Category 2B credits): $544
1 year *without* credit: $399
Resident's rate $199

All prices U.S. only.
U.S. possessions and Canada, add $30 plus applicable GST. Other international orders, add $30.

Accreditation

Emergency Medicine Reports'™ continuing education materials are sponsored and supervised by Thomson American Health Consultants. Thomson American Health Consultants designates this continuing education activity for up to 60 hours in Category 1 credit toward the AMA Physician's Recognition Award. Each physician should claim only those hours of credit that he/she actually spent in the educational activity.

This CME activity was planned and produced in accordance with the ACCME Essentials.

Emergency Medicine Reports™ also is approved by the American College of Emergency Physicians for 60 hours of ACEP Category 1 credit and has been approved for 52 Category 2B credit hours by the American Osteopathic Association. Emergency Medicine Reports has been reviewed by the American Academy of Family Physicians as having educational content acceptable for Prescribed credit hours. This volume has been approved for up to 60 Prescribed credit hours. Term of approval covers issues published within one year from the beginning distribution date of 1/04. Credit may be claimed for one year from the date of this issue. Thomson American Health Consultants (AHC) is accredited by the Accreditation Council for Continuing Medical Education (ACCME) to provide continuing medical education for physicians.

This is an educational publication designed to present scientific information and opinion to health professionals, to stimulate thought, and further investigation. It does not provide advice regarding medical diagnosis or treatment for any individual case. It is not intended for use by the layman. Opinions expressed are not necessarily those of this publication. Mention of products or services does not constitute endorsement. Clinical, legal, tax, and other comments are offered for general guidance only; professional counsel should be sought for specific situations.

This CME activity is intended for emergency physicians. It is in effect for 36 months from the date of the publication.

THOMSON
AMERICAN HEALTH CONSULTANTS

For Customer Service and CME questions,

Please call our customer service department at **(800) 688-2421.** For editorial questions or comments, please contact **Shelly Morrow Mark,** Specialty Editor, at shelly.mark@thomson.com or (954) 566-9203.

Statement of Financial Disclosure

To reveal any potential bias in this publication, and in accordance with Accreditation Council for Continuing Medical Education guidelines, we disclose that Drs. Hals, McClain-Carter, and Mullis (authors), and Perron and Werman (peer reviewers) report no relationships with companies related to the field of study covered by this CME program. Dr. Bosker (editor) is on the speaker's bureau for Pfizer, Sanofi-Synthelabo, Bristol-Myers Squibb, Roche Pharmaceuticals, and Schering Plough Corp. Dr. Bosker also acknowledges that he receives royalties, commissions, and other compensation relating to the sale of textbooks, reprints of articles, and other written materials to the following pharmaceutical companies: Pfizer, Genentech, Aventis, Pharmacia, and Bayer.

This publication does not receive commercial support.

Table 1. Pearls for Management of Life-Threatening Facial Trauma

- Try to stay 1-2 steps ahead in airway management. Know what your next move will be if what you are currently doing fails to work.
- Be cautious with timing and use of paralytics in patients with significant facial trauma. Awake intubation and fiberoptic intubation may be good alternatives when dealing with potentially distorted anatomy.
- Use nasal packing first, but refer patients with life-threatening facial bleeding early for embolization to definitively stop major hemorrhage.
- Isolated facial fractures are uncommon. Only 11% of patients with facial fractures from blunt trauma will *not* have associated brain, chest, or abdominal injuries.[4]
- Do not wait for signs of impending airway loss when considering intubation in facial burn patients.
- Significant facial burns alone are a reason for transfer to a burn center.

is considered failed when the physician cannot either bag the patient to keep oxygen saturations above 90% or intubate the patient after 2-3 attempts,[7] and adjunctive airway measures such as cricothyrotomy, laryngeal mask airway (LMA), or jet ventilation then may be indicated. Facial trauma can make airway management difficult for several reasons. First, a patient with facial trauma usually is difficult to ventilate with a bag-valve mask. Blood can make it difficult to seal the mask to the face; facial swelling and/or anatomic distortion can prevent the use of nasal or oral airways; and the presence of midface and mandible fractures can remove the normal handholds used to seal the mask to the face. In particular, nasal airways and nasotracheal intubation should be avoided in patients with obvious mid-facial fractures due to the concern about violating the cribiform plate and penetrating the cranial vault. Visualizing the cords and passing the tube also can be difficult and/or impossible with facial trauma. Uncontrolled bleeding easily can overwhelm suction devices and submerge the airway from view. Swelling from facial trauma can occur quickly, and distorted anatomy can shift the normal position of the cords or obscure them entirely. Damaged tissue can act as a foreign body in the airway. Deep hematomas (i.e., retropharyngeal space) may not be evident clinically until the patient deteriorates catastrophically. Early control of the airway is recommended as soon as any concern for airway compromise arises. Given these potential difficulties in oral intubation of patients with facial trauma, it is no surprise that maxillofacial trauma alone is listed in Roberts and Hedges' procedure book as an indication for cricothyrotomy.[8] The physician also should be aware that patients unlucky enough to have altered neck anatomy from combined neck trauma may make cricothyrotomy difficult as well. In these patients, the commercial cricothyrotomy kits, which make use of the Seldinger technique (guide wire to find airway and guide placement of a Shiley tracheostomy), are recommended. Even though cricothyrotomy is the procedure of choice for surgical airway management in facial trauma patients, remember that laryngeal fracture contraindicates cricothyrotomy and requires emergent tracheotomy instead.

The most important point is to recognize the facial trauma patient as a potentially difficult airway and to prepare alternative approaches whenever possible before proceeding. In other words, plan ahead. The first step is to be aware of the equipment and personnel available. Assemble cricothyrotomy kits and alternative airway equipment before patient arrival. A good solution is to keep a difficult airway kit[7] in a fixed location in the ED, or physicians should bring their own with them if they work in different hospitals. The EP should be aware of the capabilities and limits of the on-call anesthesia physician. Can the consultant rapidly respond with a fiberoptic scope when needed? Can jet-ventilation be set up? Are surgeons in-house if otolaryngologists are not available for an emergent tracheotomy, and vice versa?

When it comes time to intubate, the decision whether to use paralytics and their appropriate timing can be a key decision point. In some cases no other option may work, but be aware that the patient's own muscles may be the only thing holding the airway open and that paralysis immediately may result in a can't ventilate/can't intubate scenario. In patients with massive facial trauma, the use of paralytics generally should be avoided if the patient can be intubated safely without them. In some cases, the awake intubation may be the technique of choice. In this scenario, the patient is given minimal IV sedation to avoid further compromise of the airway. Topical anesthesia, such as a nebulized lidocaine, will temporarily suppress the gag reflex. This allows the EP to take a look with a laryngoscope without committing to oral intubation at that point. If the cords are visualized, then the physician can either intubate or follow standard rapid sequence protocol, knowing ahead of time that the cords will be accessible after the patient is chemically paralyzed. Obviously, complete IV sedation is given as soon as the airway is secured. If the cords cannot be seen, then the physician can proceed directly to alternative intubation approaches.

There are many rescue devices and non-surgical techniques that have been advanced for management of a difficult airway or failed intubation attempt. These include: the lighted stylet, digital intubation, fiberoptic assisted intubation, retrograde intubation, LMAs, combitubes, and so on. Each has its own advantages and disadvantages, and no one approach can be used in all situations. Fiberoptic intubation is the most commonly used approach for difficult airway management, but it requires significant training and airway visualization may be problematic with facial bleeding. Digital and lighted stylet intubation can be useful but are blind methods that require deeply unconscious or paralyzed patients. Retrograde intubation takes some time to perform, and is best reserved for patients who are not dangerously hypoxic. With the exception of the intubating LMA, LMAs and combitubes are only temporizing measures but can keep the patient alive until help arrives. While ideal, it may not be practical for every EP to be experienced with all the available alternative techniques. It is recommended that physicians become proficient in at least two alternative techniques and maintain skills by using them on straightforward intubations periodically. The reader is

referred to the excellent text by Murphy and Walls for more details on airway management and alternative techniques.[7]

Finally, on a positive note, not all facial trauma works against successful intubation. While mandible fractures may make bagging the patient more difficult, they can sometimes act to release normal anatomic constraints and allow easier than normal visualization of the cords.

Hemorrhage. When asked to list sources of life-threatening bleeding in trauma patients, most ED physicians or surgeons will not put the face near the top of the list. This would be accurate, as dangerous facial bleeding is not the norm for facial trauma. One article on patients with facial fractures over a five-year period found that only 5% of them were treated for life-threatening hemorrhage.[9] These articles cite that, even though facial fractures are an unusual source of dangerous bleeding, many texts in the recent past did not have treatment algorithms for control of severe facial bleeding when it does occur.[9] While dangerous facial bleeding may not be common, when it does occur in facial trauma it can be difficult or impossible for the ED physician to control. Unlike other areas of the body, midface fractures (especially Le Fort fractures) can puncture or sever arteries deep in the face and produce life-threatening bleeding at a location that can only be reached in the operating room (OR) or angiography suite. The internal maxillary artery and branches of the facial artery are common sources for this type of bleeding.

Before the 1980s, treatment of severe hemorrhage from facial trauma consisted of nasal packing followed by an otolaryngologist consult for OR reduction of fractures if bleeding did not stop spontaneously. If an otolaryngologist consult was not readily available, the trauma surgeon's option was to tie off the internal maxillary or external carotid artery to stop bleeding. As embolization of vessel injury in pelvic fractures became the treatment of choice to control hemorrhage, it was found to be very successful in stopping deep arterial facial bleeding as well with case reports appearing in the mid-1980s.[10] Currently, embolization is considered the treatment of choice in life-threatening facial bleeding.[11] It is relatively safe due to the good collateral blood supply in the face. A suggested algorithm for the ED physician treating a patient with life-threatening facial bleeding would be as follows. First, attempt control of the bleeding with nasal balloon packs, as with a posterior nosebleed. If this is unsuccessful, gross reduction of any obviously displaced fractures may help control bleeding.[12] At the same time, either consult the interventional radiologist or begin transfer arrangements to move the patient to a facility where embolization can be performed. Prepare to transfuse the patient early to stay ahead of potential blood loss and correct any coagulopathies. Early embolization or transfer to a center that can perform embolization is essential to prevent complications of massive blood loss.

Facial Burns. Up to 2 million people suffer burn injuries each year in the United States, and half of these are treated in EDs. Approximately 60,000 are admitted, and 5,000 die from their burns despite care.[13] Scalds are the most common mechanism followed by flame. Exact numbers are not available to define how many of these patients have burns to the face, but facial injury is common in burn patients. Remember that the amount of body surface area (BSA) the face represents changes dramatically with age. The face alone is 9.5% BSA in an infant, 6.5% in 5-year-old, but only 3.5% in adult. The entire head and neck is 9.5% BSA in an adult. An isolated facial burn is a serious injury, and The American Burn Association lists significant facial burns as an indication for transfer to a burn center due to potential difficulty dealing with eye, ear, nose, and lip burns. Immediate wound care, skin grafting, and cosmetic issues all can be problematic. Electrical cord injury to the mouth in a toddler also is an indication for admission to observe for treatment of delayed labial artery bleeding and for prevention of disfiguring contractures of the mouth. Ultimately for the ED physician, airway management will be the primary concern when treating facial burns.

It is well known that progressive swelling of the airway is the natural course in upper airway burns. Thus early intubation is recommended as opposed to observation in patients with symptoms or signs of airway burns. Any voice changes, stridor, complaints of difficulty breathing when laying flat, wheezing, painful swallowing, soot in mouth, burns of nasal/facial hair all should be considered clues of impending airway loss. The physician should err on the side of intubating the patient early when it still can be done easily; the tube always can be removed later, but the opportunity to place the tube may be lost if one waits for clinical symptoms to become pronounced. The relentless airway swelling produced by airway burns makes some alternative airway techniques less attractive. LMAs and combitubes are unlikely to be helpful as they require a relatively large airway for placement and do not provide definitive airway control. Likewise, blind techniques using digital intubation or a lighted stylet may not be as reliable. Retrograde intubation may be helpful, but may take some time to perform. Fiberoptic assisted intubation is the alternative technique most likely to be successful because the scope visually can be guided around swelling and partial obstructions. Unless a physician is comfortable (and skilled) with the fiberoptic scope, it may be necessary to proceed more rapidly to cricothyrotomy than in other cases of facial trauma. Remember to keep smaller tubes (6.0 mm) and cricothyrotomy equipment ready at the bedside when intubating any burn patient. If one suspects that a surgical airway may be needed, an assistant should prepare the neck and mark landmarks during the attempts at oral intubation or ahead of time, if time permits.

Several other points should be emphasized when intubating patients with facial burns. Be aware that even though 0_2 saturations are 100% on oxygen initially, the patient may drop saturation levels rapidly after paralysis for intubation. Inhalation injuries quickly affect the patient's ability to oxygenate effectively and make it impossible for the burn victim to maintain oxygen saturations greater than 90% with a bag-valve mask. Remember that just like flame exposure, scalding injuries to the face also can produce significant upper airway burns requiring intubation. Once the patient has been intubated, secure the tube in place and closely monitor as face/neck swelling increases to be sure the tube is not inadvertently displaced; it may not be able to be replaced. Escharotomy of the neck may be required after intuba-

tion if compression of airway occurs from loss of tissue elasticity in severe burns.

Facial Fractures and Associated Injury

Several aspects are important when treating patients with facial fractures in conjunction with other injuries. First, the highly visible nature of facial injuries may draw attention away from other injuries that, while occult, may be more dangerous and require more urgent attention. One must follow the same advanced trauma life support (ATLS) routine with all trauma patients.

Secondly, isolated facial fractures are relatively rare compared to those that occur in association with other injury. One reason isolated facial fractures are atypical is that the most common causes of facial fractures are blunt trauma, MVAs, assaults, and falls, all of which can produce other more serious injuries. Multiple authors have looked at the incidence of associated injury with facial fractures. While the numbers vary from study to study, the vast majority of these studies support that isolated facial fractures are rare in comparison to those with associated injury. One of the more extensive reviews studied 828 patients over a nine-year period and found only 11% of patients had isolated facial fractures.[4] In the 89% of patients with associated injuries, the most common injury was closed head trauma (40%), followed by extremity fracture (33%), thoracic trauma (29%), and traumatic brain injury (25%).[4] Another study emphasizes the serious nature of these associated injuries. Intubation was required in 42% of patients who had both facial fractures and/or concomitant brain and pulmonary injuries.[14] Intubation was prolonged in nearly 15%, leading to tracheostomy. Finally, just more than 50% of patients experienced hospital complications (sepsis, renal failure, anemia, etc), and 9% died from their injuries.[14]

One may think that C-spine injuries might be common in patients with facial fractures, but the opposite is actually true. The incidence of facial fracture and C-spine injury in the literature varies from 3% to 6%.[5,15] Although the numbers were relatively small, one study found that injury to the midface was more likely to be associated with C5-C7 damage, while injury to the lower face was more likely seen with upper C-spine injury.[15] Another study found that patients with facial fractures and C-spine injury tended to be older males (40s) and victims of MVAs.[5] This study also found that traumatic brain injuries were seen in 21% of patients with both facial fracture and C-spine injury,[5] underscoring the risk of occult C-spine injury in patients who are unable to communicate and thus help assess the extent of their injuries.

Once the physician has evaluated and treated other organ system injuries in patients suffering from facial trauma, there are several other subtle injuries that easily can be overlooked in these patients. Cranial nerve (CN) injuries can be difficult to detect in some patients if their brain function is impaired from injury and/or intoxication, and therefore prohibits the more detailed testing required to evaluate CN function. Common CN injuries seen in patients with facial trauma include: facial paralysis (CN 7—*See Section on Facial Nerve Injury in Part II*), complete or partial blindness (CN 2), diplopia (CN 3), and deafness (CN 8).[16] Be sure to document intact function of cranial nerves in patients who are able to permit accurate testing in the ED, especially if discharging the patient from the ED to home.

Minor damage to the dura easily can be present with facial fractures and is unlikely to be detected by CT scan alone. Left untreated, disruptions of the dura place the patient at relatively high risk for meningitis due to compromise of the blood-brain barrier. Fractures involving the frontal sinus, nasal bones, and Le Fort fractures are especially high risk for development of cerebrospinal fluid (CSF) leaks/fistulae. Basilar skull fractures also can accompany severe facial trauma and may not be seen easily on CT scan.[16] Initially, bleeding may cover up the presence of CSF. Any clear fluid or bleeding from the ears or nose should be assumed to be CSF until proven otherwise. Unfortunately, glucose levels in nasal fluid cannot reliably distinguish CSF from clear nasal secretions. A drop of fluid can be placed on a piece of filter paper to see if a clear area surrounds the central blood stain,[17] but a new test may be available that is much more accurate and sensitive. The PhastSystem is a high-speed gel electrophoresis device that can be used to detect a brain-specific protein (tau protein variant of transferrin) and which identifies CSF in fewer than 2 hours.[18] While not currently widely used, it is hoped that this or a similar test will be available in the near future.

In summary, physicians should be attentive and remember to treat patients with facial trauma as general trauma patients first. Physicians should evaluate patients for injury to other organ systems, and then remember when to examine the face more closely for commonly missed injuries (CNs and CSF leaks).

Overview of Facial Fractures

Although most facial fractures cannot be managed definitively in the ED, this is where loss of function and permanent disability can be prevented through early detection. Though a noble goal, this is not as easy as one would like. Patients with facial fractures can challenge the most skilled EP. Injuries can range from isolated nasal fractures to panfacial fractures. Some patients will have no soft-tissue injuries that require repair, while others will have extensive damage. The swelling that accompanies blunt facial trauma easily can hide clinical deformity associated with fractures, and thus the dilemma: Without imaging, the fracture won't be identified, but imaging all patients with facial trauma is not appropriate either. Some fractures only will be identified if the proper imaging study is ordered; i.e., a Panorex film will show condyle fractures of the mandible where plain mandible films are likely to miss it. The patient may have associated head injury that will prevent adequate clinical assessment, such as visual acuity and extra-ocular eye movements that may suggest orbital fracture with entrapment. The goal of this section is to provide an overview of ED management of facial fractures in the adult. Refer to the Section on Pediatric Facial Trauma for more information on pediatric patients in Part III.

The following discussion assumes that the patient has been stabilized and airway, breathing, and circulation (ABCs) have been addressed. (*See Section on Life-Threatening Facial Trauma*.) Evaluation of facial fractures begins with suspicion of their presence. As with all trauma patients, the physician is in a

Table 2. Force of Gravity Required for Facial Bone Fracture*

BONE	FORCE OF GRAVITY (GRAMS)
Nasal	30
Zygoma	50
Angle of the mandible	70
Frontal	80
Midline maxilla	100
Midline mandible	100
Supraorbital rim	200

Adapted from: Hollander JE, Singer A. Wound management. In: Harwood-Nuss A, et al, eds. *The Clinical Practice of Emergency Medicine*, 3rd ed. Philadelphia: Lippincott, Williams & Wilkins; 2001: 449-459.

better position to evaluate when he has accurate information on the mechanism of injury. It is important to seek details from other sources when the patient is not able to provide them, as is often the case. Emergency medical service workers, police, family, and bystanders should all be asked for relevant details of the event. Knowing that a patient was actually hit in the face with a baseball bat rather than a fist will drastically alter one's suspicion of the presence of fractures. The mechanism of injury also can help when combined with the location on the face. Each facial bone has different limits on how much force is required to produce a fracture. The nasal bones are the most easily broken, while the supraorbital rim requires nearly 10 times the force to break. (*See Table 2.*)

Several quick questions can be asked to rapidly assess a patient for the presence of facial fractures. The patient should be asked if he or she can see normally and if he or she has double vision. Double vision is an important clue for orbital/periorbital fractures with entrapment, although diplopia can have other causes. Binocular diplopia is more likely due to entrapment where monocular diplopia is more likely from globe injury (i.e., displaced lens, etc.). Sensation of the face quickly can be checked by lightly touching each side of the forehead, cheek, and jaw to evaluate all three trigeminal branches. Physicians should remember that penetrating injuries more often are associated with nerve damage. Simply asking where the face hurts can help localize the exam, and may reveal areas of injury that are not apparent visually. For example, the patient with a condyle fracture of the mandible may point to the preauricular area, which often will appear uninjured. The patient should be asked about malocclusion (i.e., "Do your teeth fit together normally?"), as this correlates with mandible fracture. Pain when the patient bites down also is suggestive of mandible fracture. Persistent clear nasal discharge can indicate fracture of the cribriform plate with subsequent CSF rhinorrhea. (*See section on CSF Rhinorrhea in Part II.*)

Once the suspicion of facial fracture is raised, the physician must verify or rule out its existence. While plain facial films used to be the imaging modality of choice, facial CT scan largely has taken the place of plain films. CT scan of the face is cost-effective, rapid, and offers a more accurate evaluation for facial fractures.[20] Another advantage of CT is that three-dimensional reconstructions easily can be performed to more clearly define a fracture and to help with pre-operative planning. If CT is unavailable, the standard set of facial films will include the Waters (occipitomental) view, the Caldwell (occipitofrontal), and lateral views. The Waters view is best for maxillary, maxilla, and orbital fractures. The Caldwell view shows the ethmoid and frontal sinuses.

The overall incidence of facial fractures in patients with general facial trauma is rather high, as evidenced by a 10-year study of more than 9500 patients with facial trauma.[21] The authors found an overall incidence of fractures in facial trauma patients of 37%. Certain subsets of patients are at particularly high risk for facial fractures and are more likely to need facial CT to rule out fractures than the average ED patient. Obviously, MVAs produce high-impact blunt trauma to the face, and they cause up to 50% of facial fractures.[22] Unrestrained or non-helmeted patients are at the highest risk. Assaults cause another 33% of fractures,[22] and it comes as no surprise that alcohol abuse frequently is part of both assaults and MVAs that cause fractures.[6] Thus a facial trauma patient in the ED involved in an MVA or assault and under the influence of alcohol may need a facial CT performed at the same time as cranial CT. As CT scan can be problematic (i.e., it is far from the ED, requires sedation for patient cooperation, patients can crash in CT, etc.) it usually is more efficient to try and obtain all the CT scans in only one trip. It may surprise some to know that as many as one-quarter of women who present to the ED with facial trauma are victims of domestic violence.[23] Physicians should remember to evaluate women for possible intervention with police, social workers, and support groups to avoid (when possible) returning the victim back to a dangerous situation. Likewise, children diagnosed with facial fractures also need evaluation for domestic abuse. Finally, fully 10% of facial fractures are the result of sports-related injury.[24] These patients should be considered to be at relatively high risk for fracture as well.

General Facial Wound Repair

According to 1996 figures, ED physicians care for an estimated 12 million patients yearly in the United States with traumatic wounds.[25] Data from one study of 5000 patients show the majority of lacerations occur in men with a median age 20 years, with fully 50% of lacerations occurring on the head.[26] Since ED physicians will be responsible for closure of the vast majority of these injuries, knowledge of wound care and suturing technique specific for facial lacerations is essential. Assuming a basic working knowledge of wound physiology and general suturing techniques, this section will give an overview of guidelines exclusively aimed at facial wound repair. Facial nerve blocks also will be discussed. Readers desiring a review of basic wound care and suturing technique are referred to several recent review articles[25,27] and to the excellent book by Trott on the subject.[28]

Depending on one's perspective, there are roughly seven specific areas on and around the face with unique wound care requirements: scalp/forehead, orbit, ear, nose, mouth/lips, chin,

and cheeks. Wound repair of each region will be discussed in detail under the appropriate section, and general advice on wound care will be presented in this section. Before discussing wound care, two basic questions must be answered about the wound first: Should the wound be closed in the ED, and who should perform the procedure?

Primary Closure and Bite Wounds. Although delayed or secondary closure (leaving a wound open for 3-5 days before repair) is a well established and useful technique, this approach is unlikely to be used for preventing infection of facial lacerations. Given the reputation of facial wounds for resisting infection, it may surprise some to realize that the scalp, forehead, and oral cavity have some of the highest concentrations of bacteria—in the millions per square centimeter, compared to 100-1000 for torso, arms, and legs.[19] Further, the critical number of bacteria to infect a wound is around 1 million bacteria.[29] The high vascularity of the scalp and face account for its renowned ability to resist infection. Thus, nearly all facial wounds closed by the ED physician will be primary closures. Possible exceptions include: bite wounds, wounds greater than 24 hours old, wounds with a foreign body that cannot be removed in the ED, or severely contaminated wounds.

Dog bites account for the majority—up to 80-90%—of bite wounds seen in the ED.[30] Cat bites come in second (up to 15%) and human bites third (3-10%).[30] The literature supports closure of dog bite wounds to the face,[31] provided that debridement of devitalized tissue and good irrigation be performed as part of the closure. Very small wounds of fewer than 5 mm may need to be treated as puncture wounds and left open. Most physicians will give a five-day prophylactic course of antibiotics (amoxicillin-clavulanate [Augmentin] 500 mg PO TID) as part of treatment when closing any facial bite wound, although some authors feel this is unnecessary for dog bites.[31] One study of 145 dog bite wounds with primary closure and no prophylaxis found only a 1.4% infection rate.[32] Most texts recommend *not* closing cat bites, as these usually are smaller puncture wounds with less disfiguring potential and higher risk of infection than dog bites.[30] The same text, however, does state that the face is the safest location for closure of cat bite wounds, and they should be sutured if the physician feels the wound cosmetically requires closure.

Closure of human bite wounds is subject to debate, although the consensus at this time is that primary repair of human bites to the face is safe. A recent study of facial bites found primary closure after debridement (if necessary) followed by a one-week course of antibiotics yielded complete healing at time of suture removal in 90% of cases.[33] These results are impressive considering the age of the wounds ranged from 1 to 4 days. There is no doubt that human bite wounds to the extremities (i.e., closed fist or fight bites) never should be closed. Likewise, any human bite to the face with signs of infection should not be closed primarily but should be treated with antibiotics and referred for secondary closure. Since current texts in emergency medicine recommend primary closure of deforming facial bite wounds,[29,30] the ED physician is well supported by the literature when primarily closing human bites to the face.

Finally, most physicians will close clean facial wounds fewer than 24 hours old. Simple wounds more than 24 hours old with no signs of infection can be closed primarily in most cases if the physician gently trims all the skin edges.[29] Wounds with severe contamination (i.e., with feces, large amounts of dirt, etc.) or with unrecoverable foreign bodies probably are better served if definitive closure is performed in the OR after thorough cleaning and debridement. This leads to the next question of when the ED physician should refer facial wounds to the consultant.

Table 3. Consult for Repair of Facial Wounds

Consult when:

- The patient or family demands it, even after education on wound closure and scarring.
- Closure is beyond expertise of ED physician (eyelid margin, complex ear laceration, etc).
- Closure likely to require secondary procedures (large flaps, large nasal lacs).
- Closure requires general anesthesia.
- ED physician does not have time required for good closure.
- Injury of deep structure (nerve, parotid or lacrimal duct, etc.)—by location of wound or exam.
- Wound will require frequent follow-ups—best done by only one physician.
- Delayed primary closure is indicated.

When to Refer Closure of Facial Lacerations. There are many indications for referral of facial wound repair. (*See Table 3.*) Perhaps one of the more difficult situations that can occur is when the patient presents with a minor, easily repaired wound but demands that a plastic surgeon perform the repair. The demand usually arises from the misguided opinion that wounds sutured by a plastic surgeon will not leave a scar. Although each situation is unique, a useful approach is to not spend time selling the idea of ED physician closure. Doing so puts the ED physician at risk as the patient/relative/friends are likely to be unhappy with the resulting scar at some point in the future if that is their concern in the ED. While not the case every time, the patient may be left with the thought: "If only the plastic surgeon had been there from the beginning…" EPs simply should educate the patient/family as follows: "All cuts that require sutures will leave a scar. The body heals wounds with scar tissue. Plastic surgeons trade one scar for another in the future after the wound heals. In general, small, straight wounds are closed by every physician in the same way. I will repair the wound or you can decide to have the plastic surgeon called in. The choice is up to you." It also may help for the EP to state that he or she will not be offended if the patient chooses to have a consult. It is important for the patient/family to know this is their decision. Then the physician should give the patient a realistic idea of how long it will take for the plastic surgeon to arrive and let the patient tell the physician what they want. If they decide not to have a consult, the EP should document the conversation and give them the referral for the plastic surgeon even if they think at the time they will not use it. Remember that while the EP may know that a plastic closure for a simple 1 cm lacera-

Table 4. Recommendations for Tetanus Prophylaxis[25]

HISTORY OF TETANUS IMMUNIZATION	CLEAN MINOR WOUNDS		ALL OTHER WOUNDS*	
	Td	TIG	Td	TIG
Uncertain or < 3 doses	YES	No	YES	YES
≥ 3 doses				
Last dose within 5 y	No	No	No	No
Last dose 5-10 y	No	No	YES	No
Last dose >10 y	YES	No	YES	No

Td: Tetanus-diphtheria toxoid; TIG: tetanus immune globulin.

* For example, contaminated wounds, puncture wounds, avulsions, burns, and crush injuries.

Table 5. Summary of Recommendations for Facial Wound Treatment

- Do not place staples on facial wounds—especially the forehead.
- Do not treat parotid gland/duct injury without evaluating for facial nerve injury (and visa versa).
- Do not assume patients with facial fractures from MVAs or assaults are isolated injuries without proving otherwise.
- Do not leave disfiguring facial bite wounds to heal by secondary intention.
- Do not forget to anesthetize wounds before cleaning them.
- Always align the vermillion lip border first.
- Try not to place absorbable sutures in ear cartilage.

tion really makes little difference, the physician also is treating the patient's perceptions and expectations.

There are other reasons to consider referring wound closure from the ED. (*See Table 3.*) The first and most obvious reason is that the repair is beyond the ability of the EP to perform. While there likely is broad variability in what an individual physician will feel comfortable closing, there are general recommendations for referral. These include lacerations that include the eyelid margins, nerve or other deep structure injury (or suspected injury), deep foreign bodies, ear wounds with significant cartilage damage, large flaps or nasal wounds, large lacerations with tissue loss, and delayed primary closures. Repair of eyelid margins requires detailed, layered closure for a good result and this is easiest with the initial repair. All nerve repairs require microsurgical technique and are reserved for the OR. Microsurgical repair also may be required for nerve injury or damage of other deep structures (i.e., lacrimal/parotid duct, etc.). EPs should remember that the facial nerve or its branches are most the common nerve injury, but other nerves also can be involved (i.e., supraorbital, infraorbital, mental, etc). Simple ear wounds may be closed easily, but more complex injuries require debridement of exposed cartilage, which often leads to further revision. Any wound that is likely to require secondary procedures, such as large flaps that often heal elevated, is best cared for from the beginning by a single physician. Unless special arrangements are made based on the ED physician's schedule, follow-ups in the ED commonly are seen by a different doctor every time. Finally, while some repairs may be satisfactorily done by the ED physician, they may be too time-consuming. The patient load in some single coverage or very busy EDs may become hopelessly backed up if the physician devotes the large amount of time required for the closure. Although the EP may feel capable of closing the wound, referral may be the best decision for the rest of the patients in the ED.

Tips on General Facial Wound Repair. This section will review care of facial wounds with emphasis on: anesthesia, wound cleaning, hemostasis, basic suture technique, suture alternatives, and discharge instructions. For review of wound repair in specific areas (i.e., ear, lips, etc.), see the section on wound repair under each anatomic location. EPs should remember to evaluate the patient for prior tetanus immunization; patients at higher risk are the elderly and recent immigrants/illegal aliens. See Table 4 for a summary of prophylaxis recommendations. Table 5 provides a quick summary of major recommendations for facial wound treatment.

Anesthesia/Sedation. Many people are apprehensive about needles, and patient fears can escalate when a physician approaches the face with one. In general to reduce pain and anxiety, the EP should try to keep the syringe and needle out of the patient's view. Most injections on the face do not allow a view of the needle to begin with, so having the patient watch the syringe slowly approach his or her face is unnecessary. The EP should bring the syringe in from the side of the face, but always tell the patient what is about to occur. The physician should never surprise patients, as they are much more likely to move and cause preventable injury. As the face is relatively sensitive, smaller-gauge needles (25-27 gauge) should be used unless a nerve block is being performed (see next section). Slightly larger needles should be used for blocks (23-25 gauge) to allow for aspiration. In addition, slower injection of warm, pH-balanced anesthetic injected subcutaneously (not intra-dermal) will significantly reduce pain with the procedure.[34] To buffer 1% lidocaine (Xylocaine), add 1 mL of bicarbonate (1 mEq/mL—same as found in most code cart vials) per 9 mL of lidocaine. Buffering of 2% lidocaine may cause precipitates. For a 1% 20 mL vial, remove 2 mL of lidocaine and replace with 2 mL of bicarbonate. The shelf life of the buffered solution is only 7 days when refrigerated, and epinephrine will degrade up to 20% in only 24 hours if exposed to light.[35] Using a 3- or 5-cc syringe instead of a standard 10-cc syringe gives more control and is an easy way to slow the injection. The maximum safe dose for plain lidocaine is 300 mg for a 700-kg adult. This translates to 30 mL of a 1% lidocaine solution. For lidocaine with epinephrine, the maximum dose is 500 mg or 50 mL of a 1% solution.

Lidocaine in a 1% preparation is the most frequently used local anesthetic. It has a rapid onset and anesthesia lasts anywhere from 30 minutes to 1 hour. This duration can be doubled with the addition of epinephrine, which causes vasoconstriction

and slows absorption of the agent. Bupivicaine (Marcaine), 0.25%, is an excellent alternative in regions where longer durations of anesthesia are needed, either for prolonged repairs or for extended analgesia after the procedure. Its onset of action is somewhat slower, but its duration is 4-8 hours. Either of these agents can be used for local infiltration or for regional blocks.

It is relatively common for patients to report allergies to local anesthetics, but true anaphylaxis is rare. In reality, actual testing for allergic reaction in patients who report allergy shows most patients are not allergic.[36] An easy solution to this problem is to use a local anesthetic from a different class than the reported allergy. Table 6 shows common local anesthetics and their chemical classes. There are two groups: amides and esters. Lidocaine, bupivacaine, and mepivacaine (Carbacaine) are amides, and procaine and tetracaine (Pontocaine) are esters. A potential complication to this scheme is that some patients actually may be allergic to the preservative methylparaben used in multidose vials. A breakdown of amide anesthetics is closely related to methylparaben and may produce a reaction as well. Diphenhydramine (Benadryl) and benzyl alcohol have been suggested as alternatives for local anesthetics, but diphenhydramine is more painful to inject, and benzyl alcohol has a fairly short half-life (minutes). Thus, in some patients with true concern for allergy, conscious sedation may be the anesthetic of choice.

Conscious or procedural sedation also can be extremely useful for very anxious and/or younger patients. Many times the physician needs the patient to be absolutely still during wound repair to achieve an acceptable closure. The American College of Emergency Physicians (ACEP) has a clinical policy on its website covering general recommendations on procedural sedation in the ED. In general, the EP should remember that, to treat both pain and anxiety, a combination such as fentanyl (Sublimaze) and midazolam (Versed) is needed. A good alternative is ketamine (Ketalar) as it provides sedation and analgesia as well as immobilization. Midazolam can be combined with ketamine and has been shown to reduce emergence hallucinations in adults.[37] The benefit in children is debatable, but midazolam at least will provide the comfort of amnesia if emergence reactions occur. Nitrous oxide is less helpful for facial lacerations as it must be administered by a mask that may restrict access to the wound.

Finally, topical anesthetic agents can be very useful providing adjuncts to or even complete anesthesia on their own. Several preparations are available, named by an acronym which represents the agents in the solution. XAP (Xylocaine/adrenaline/procaine), TAC (tetracaine/adrenaline/cocaine), or LET (lidocaine/epinephrine/tetracaine) are mixtures that usually are saturated into sterile cotton balls or gauze and applied firmly to the wound for 20 minutes. They absorb into the wound surface, and their efficacy usually can be established by the degree of blanching produced by the epinephrine. If complete anesthesia is not produced, the subsequent pain of injection is greatly reduced. To prevent potentially dangerous systemic absorption, these agents cannot be used on mucosal surfaces (i.e., lips, inside the nose, etc.) or on lacerations greater than 5 cm in length. Likewise, unless epinephrine is not used in the solution, the ear and nose should be avoided.

Table 6. Chemical Classification of Local Anesthetics[19]

AMIDES	ESTERS
Lidocaine	Procaine
Bupivacaine	Cocaine
Etidocaine	Tetracaine
Mepivacaine	Benzocaine

Nerve Blocks for the Face. *Scalp.* Sections of the scalp can be anesthetized if required. The posterior scalp is blocked by injection around the occipital nerve (both greater and lesser). The occipital artery lies just lateral to the nerve and often can be palpated midway between the external occipital protuberance and mastoid process. Using a 22-gauge needle, inject 5 mL in a fan over the area. Aspirate before pushing to avoid intra-arterial injection. As an alternative to direct wound injection, scalp blocks can be used to anesthetize a large area around the wound by subcutaneous (not deep) injection. Injection usually is done with a 22-gauge needle in a band 1 cm wide and 3 cm from the wound edge. Care should be taken to not exceed the recommended limits of anesthetic dosing for anesthesia of large wounds.

Forehead. Nerve blocks of the supraorbital nerve are relatively easy to perform and, when done bilaterally, give total anesthesia of the forehead and proximal scalp. They can facilitate eyebrow and eyelid repair by preventing significant distortion of important landmarks. The supratrochlear nerve lies just medial to the supraorbital foramen and provides sensation to the area near the bridge of the nose. As the supraorbital nerve gives many branches, the easiest method to block both nerves is to find the supraorbital foramen (near midline of superior orbit), and insert a 1.5-inch needle parallel to the eyebrow and just above the bone. Injection of 2-3 mL along the needle tract will give anesthesia in 4-6 minutes. A hematoma may form in the upper eyelid(s) as a result of the injection, and can be treated with local pressure. Even without hematoma evident in the ED, the block may result in echymosis appearing on the following day. Patients should be cautioned about this possibility.

Midface. Infraorbital nerve block anesthetizes the lower eyelid, medial cheek, upper lip, and lateral/inferior nose (but not the nasal mucosa). There are two approaches for block of this nerve: intraoral and extraoral. In both cases, the EP should keep a gloved finger resting on the inferior orbital rim to prevent accidental injection or injury of the globe. The intraoral route was reported as less painful in a small study of volunteers.[38] The physician can pre-treat the mucosa with topical viscous lidocaine and then insert a ¾-inch needle to the hub toward the infraorbital foramen. Insertion is through the gingival-buccal margin just above the maxillary canine tooth. Keep the needle along the surface of the maxialla to avoid exiting the skin on the face, and retract slightly before injection if paresthesias are produced to avoid injection into the foramen. Inject 2-3 mL at the entrance to the foramen, or inject 3-5 mL in a fan across the area if the foramen cannot be felt secondary to soft-tissue swelling. Massage of the area just after injection may hasten results. For extraoral

injection, penetrate the skin just below the infraorbital foramen and inject as before. Use anesthetic without epinephrine to avoid spasm of the facial artery which may lie nearby.

Lower Face. Mental nerve block provides good anesthesia of the lower lip and superior chin, but both nerves must be blocked for wounds near the midline. It can be helpful in lip laceration repair to prevent any distortion of the vermillion border. First locate the mental foramen by palpating the mandible midway between the upper and lower edges about 2.5 cm from the midline of the jaw. After pre-treatment of the mucosa with viscous lidocaine, insert a ¾-inch needle in the gingival-buccal margin just opposite the lower canine. The needle is held at a 45-degree angle to position the EP's hand away from the patient's nose. After aspiration, inject 1-2 mL of anesthetic and fan the injection as needed. Mental nerve block also can be done extraorally, but like infraorbital nerve blocks, is considered more painful.

Ear. Innervation of the external ear is provided anteriorly by the auriculotemporal nerve (from the mandibular branch of the trigeminal nerve) and posteriorly by the greater auricular nerve and the mastoid branch of the lesser occipital nerve (both branches of the cervical plexus). Auricular block is performed easily by subcutaneous injection circumferentially around the ear. This can be done with only two punctures of the skin. Using a full 10 cc syringe (no epinephrine), and 1.5- to 2-inch, 25-gauge needle, insert through the skin just below the earlobe. Pass behind the ear parallel and just above the bone (mastoid), and inject 2-3 mL as the needle is withdrawn. Without removing the needle from the skin, re-direct and pass the needle anterior to the tragus and inject. Refill the syringe if needed and repeat in a similar fashion from a starting point just above the ear. Anesthesia may take 10-15 minutes to be complete.

Cleaning the Wound—Irrigation and Debridement. Besides the obvious need to remove dirt from a wound, cleaning will help remove occult foreign bodies. The importance of this is underscored by the fact that failure to diagnose retained foreign body is the fifth leading cause of litigation against EPs. Foreign bodies are best located performing the exam under sterile conditions in a bloodless field with good lighting. One of the most important points about wound cleaning is to anesthetize the wound before cleaning. The physician can do a much better job cleaning the wound if the patient is comfortable during the procedure, especially on sensitive areas like the face. The area around the wound should be cleaned gently before injection, especially if there is matted hair/blood as this will likely hide sections of the wound and lead to a second round of injections. Diluted peroxide (10%) works best for removal of dried blood from around a wound, but care should be taken to keep it out of the wound as it is hemolytic.[39]

Mechanical scrubbing and irrigation are the two recommended approaches for wound cleaning. For facial injuries, scrubbing the internal surface of the wound usually will do more harm than good and is reserved for severely contaminated wounds (i.e., road rash) where irrigation alone is ineffective to remove imbedded debris that can tattoo the skin. Even irrigation of facial wounds is debatable. One recent study found no difference in infection rate and cosmetic outcome between simple, uncontaminated facial and scalp lacerations that were irrigated with normal saline and those that were not.[40] These authors recommended avoiding use of high-pressure irrigation (50-70 psi) on the face, especially in loose tissues such as the eyelids as the fluid actually can inject into tissues.[19] Likewise, low pressure techniques (less than 1 psi—bulb-syringe) also are not very effective. The best method is to use a 20-35 mL syringe and an 18-19 gauge catheter or splash guard.[41]

Wound soaking is a common ED practice, but should not be considered a substitute for scrubbing or irrigation. Soaking can loosen or help remove gross contamination, but does not significantly lower bacterial counts.[39] The Roberts and Hedges' text goes further to recommend that soaking a wound has "little value and is not recommended as a routine practice."[29] This is supported by one randomized study of ED patients with visibly contaminated wounds. The study randomized 33 wounds to no treatment, saline soak, or povidone-iodine soak for 10 minutes each. They found that the wounds left to sit for 10 minutes covered only by gauze had the lowest bacterial counts, and that counts were increased 100-fold in saline soak alone.[42]

The choice of solution used to irrigate wounds also has been debated. Peroxide has associated tissue toxicity and should be used only around (not in) the wound to remove excess blood.[29] Likewise, stock povidone-iodine (10% Betadyne) solution and detergents should not be used for wound irrigation. Plain normal saline is the solution of choice in most EDs.[19] At least one randomized study of 531 ED patients found no difference in rates of infection when irrigating with saline, diluted povidone-iodine, or wound detergent.[43] Some recent studies even support using tap water for irrigation in both adults[44] and children.[45] It also is recommended in Roberts and Hedges, as no studies have ever shown harmful effects of tap water irrigation.[29]

Even use of sterile gloves recently has been examined. A randomized, controlled study of 816 patients with facial and non-facial lacerations found no difference in infection rates when sterile gloves (6.1%) or clean non-sterile gloves (4.4%) were used.[46] The rationale here is that, unlike in the OR, traumatic wounds already are contaminated prior to ED treatment and the choice of gloves does not further alter risk of infection.

Hair that interferes with wound closure can be held out of the way using antibiotic ointment or trimmed—not shaved. This is especially true for eyebrow hair that does not predictably grow back and may cause permanent changes in appearance. Simply clip scalp, beard, or mustache hair close to the skin with scissors in a 1 cm perimeter around the wound. While no studies on ED closures of traumatic wounds exist, studies on surgical patients do show an increased risk of post-operative infection in shaved patients.[47] This is true perhaps because close shaving adds small dermal wounds that increase risk of bacterial invasion and infection.[39] While bacteria do inhabit hair shafts and follicles, at least one study of neurosurgical patients supports that hair will be cleaned sufficiently during the normal wound preparation.[48]

Finally, debridement is considered part of wound cleaning as it removes devitalized tissue and reduces the risk of infection. It also can clean up the wound and give a better cosmetic result by pro-

Figure 1. Normal Skin Tension Lines

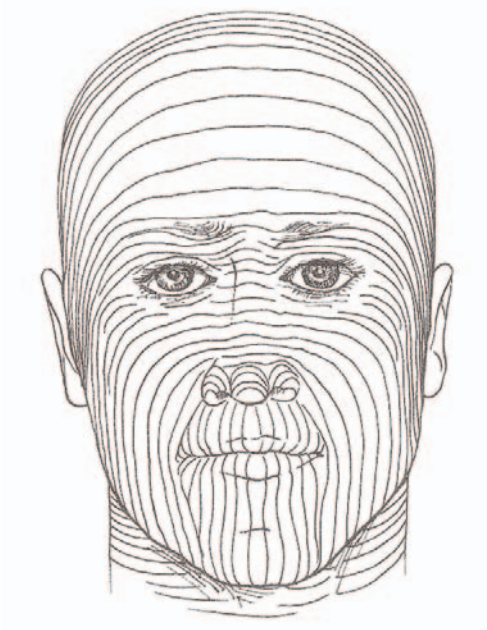

Any scar perpendicular to these lines will naturally widen over time, while scars parallel to them will naturally stay thin and hide well in facial wrinkles.

Reprinted with permission from: Harwood-Nuss A, et al, eds. *The Clinical Practice of Emergency Medicine*, 3rd ed. Lippincott, Williams & Wilkins; 2001: 449.

ducing straight, easy-to-close edges from a jagged wound. This can be done selectively where only small sections of the wound are removed, or completely where the full margins of the wound are excised. However, there are some points concerning debridement of facial wounds that should be emphasized. First, clean wounds with relatively sharp edges are unlikely to benefit from debridement. Removal of subcutaneous fat can result in sinking of the scar and distortion of the facial contour. Even some irregularly shaped wounds actually may heal with better cosmetic result using detailed approximation instead of a wide excision.[49] Second, tissue removal can prevent wound closure. In other words, after trimming wound edges one can be left with a gaping hole that can no longer be approximated. The nose is especially at risk as there is little natural skin laxity in this area. Third, excision of tissue must be parallel to the hair follicles or scar alopecia may be increased. Fourth, even if the wound still is easily closed, it will be under more tension, and that increased tension will contribute to widening of the scar. This will be more pronounced if the wound is across natural skin tension lines. (*See Figure 1.*) Lastly, debridement on the face should be performed using magnification (Loupes) to allow removal of as little skin as possible. Ultimately, any substantial debridement is best performed in the OR.

Hemostasis. Direct pressure and time often control bleeding of simple wounds prior to physician exam. While the face may not be thought of as a source of life-threatening hemorrhage, it does occur in up to 5% of facial trauma patients.[9] In these cases, the bleeding vessels are inaccessible to direct pressure, and embolization is the treatment of choice if nasal packing fails. (*See previous section on life-threatening injury.*) The act of wound cleaning nearly always removes small clots that have formed and reproduces brisk bleeding from facial wounds. The best first approach is to apply direct pressure and wait several minutes for hemostasis. Injection of lidocaine with epinephrine greatly can speed this process. In most cases where bleeding continues, re-approximation of the wound edges followed by a compression bandage will control persistent capillary oozing. This is especially true with the scalp where control of bleeding can be frustrating without wound approximation.[29] (*See section on Forehead/Scalp in Part II.*) Smaller, persistent arterioles that refuse to yield to the pressure of wound closure can be controlled with bipolar electrocautery (Bovie), small, heated wire filaments, or simply by clamping and twisting the end of the vessel. Notable exceptions are where vessel diameter exceeds 2 mm. Direct ligation of these vessels with absorbable suture (Vicryl) is recommended.[29] The physician always should try to isolate the vessel from the surrounding tissue before attempting coagulation or clamping to minimize damage to surrounding tissue. Care must be taken not to include nearby nerves in the process, and the nerves may not be seen easily. The concern for avoidable nerve damage should help balance the temptation to ligate bleeding vessels without trying more conservative approaches first. Consultation is needed if the EP's comfort level does not extend to ligating vessels near the facial nerve.

Wound Closure/Suture Technique. There is a wide variety of suture material to choose from, and the general rule for facial wounds is that smaller is better. Subcutaneous sutures should be 5-0 or 4-0 in size, and skin should be closed with 6-0 nonabsorbable suture. Coated polyglactin suture (Vicryl) and polyglycolic acid suture (Dexon) support wound integrity for approximately 30 days, but polyglactin suture takes 60-90 days to fully absorb, and polyglycolic acid suture lasts for 120-210 days.[50] As all sutures potentially can leave their own scars, inhibit host defenses, and increase inflammation and risk of infection,[51] physicians should use the least number of sutures required to adequately close the wound. On the face, this usually means placing surface sutures 1-3 mm apart and 1-2 mm from the wound edge.[29] Deep sutures can be spaced as widely as needed, and should be kept to the absolute minimum on the face. Besides the increased risk of infection, they provoke a greater healing response and can add to the bulk of the scar.[52]

Care should be taken to minimize handling tissue and reduce further trauma. Deep sutures can be placed to close muscle by suturing fascia rather than muscle itself. So-called fat stitches designed to close the adipose tissue do not work and should not be placed. Skin tension can be reduced by judicious use of subcutaneous sutures, but be aware that they are not routinely recommended in scalp wounds (*see section on Forehead/Scalp in Part II*), nasal wounds (*see section on Nasal Wounds in Part II*), or where there is little natural skin tension. When placing each suture, carefully try to ensure that the suture needle enters each

Figure 2A. How to Make Wound Edges Even

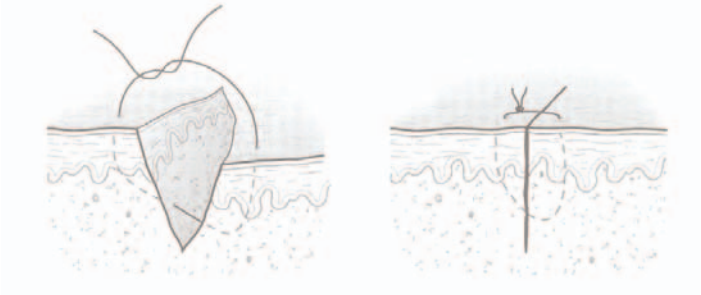

Proper placement of sutures in the wound will pull uneven edges back together. Make sure to enter and exit the sides of the wound at roughly the same depth to realign the surface.

Reprinted with permission from: Singer AJ, Hollander JE, eds. *Lacerations and Acute Wound Management*. Philadelphia: FA Davis Company;2003:130.

Figure 2B. Proper Technique for a Deep Stitch

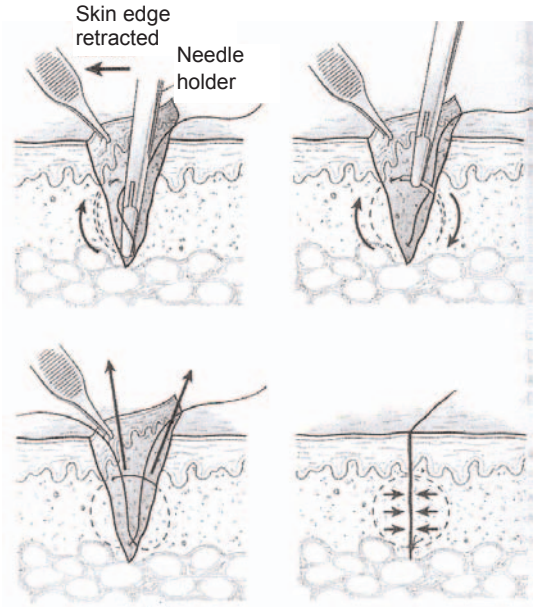

Notice that the entire suture is placed inside the dermis, not in the subcutaneous fat. Place the stitch as close as possible to the skin surface without causing dimples to produce near-perfect alignment of the surface. Under perfect conditions, one can do away with surface sutures altogether.

Reprinted with permission from: Roberts JR, Hedges JR. *Clinical Procedures in Emergency Medicine*, 3rd ed. Elsevier Inc.;1998:296.

side of the wound at the same depth. (*See Figure 2A.*) This is especially true when closing wounds that are beveled or occur at an angle to the skin surface. Great care must be taken to match the two edges. The thinner side often is retracted and it can help to gently stretch it back to the natural position to see where the sutures must be placed. Insertion of a midpoint retention stitch can help hold the position. To place a suture correctly, a smaller bite is taken from the thinner side and a larger bite from the thicker side. In other words, the suture must enter and exit underneath the skin at the same level for the surface skin to also match up. This will ensure an even skin surface and dramatically can reduce scar visibility.

Most EPs find that simple interrupted, continuous (subcutaneous or surface), and modified horizontal mattress sutures are sufficient for most facial wounds. Each suture technique has its own advantages and disadvantages. Interrupted sutures resist opening of the wound if a single stitch re-opens. Continuous sutures evenly distribute tension along the entire length of the wound and provide more effective hemostasis, but are at risk of unraveling if a knot fails. Continuous subcuticular sutures leave no suture marks on the skin and, therefore, can be left in place longer to support the wound, but facial wounds frequently require addition of percutaneous sutures for a good cosmetic closure. When not using surface sutures, subcutaneous stitches should pass through the dermal-epidermal junction up to 1-2 mm below the skin surface, or as close to the surface as possible without producing dimpling. (*See Figure 2B.*) Horizontal mattress sutures can pull together larger areas of the wound with a single stitch (*see Figure 2C*), and can be especially helpful on wound corners (*see Figure 2D*). Details on technique for these and other sutures can be found in Trott's *Wounds and Lacerations* book[28] and Roberts and Hedges' procedure book.[29]

No matter which type of suture is used, facial swelling after trauma can add to wound tension and exacerbate stitch marks. Swelling can be minimized by using mild pressure dressings and/or cool compresses after closure. Apply a thin layer of antibiotic ointment to the wound before applying any dressing. One randomized study of more than 400 ED patients with simple lacerations (not limited to the face) found that antibiotic ointment use cut infection rates in half.[53] Interestingly, though some consider not using silver sulfadiazine (Silvadene) on burns as unthinkable, in that study use of silver sulfadiazine resulted in nearly twice as many wound infections as bacitracin (Baciguent) or neomycin.[53]

Suture Alternatives: Adhesives, Staples, and Tape. Staples have been used in the United States since the 1960s, and studies support that they give comparable results to suturing in terms of infection rates, healing, and patient acceptance.[54] The main advantage of staples is that of speed. Comparison studies find stapling is 3-4 times faster than suturing and that closure of a 3-5 cm wound takes fewer than 30 seconds.[55] They also are relatively easy to see on the scalp compared to suture. Disadvantages include increased pain of removal compared to sutures, and increased cost when using larger staplers (25-35 staples). While staples are ideal for most scalp wounds, they should not be used for deep scalp lacerations (*see section on Forehead/Scalp in Part II*) and never should be used on the face. The biggest disadvantage of staples is that they do not permit the detailed approximation of wound edges required for facial wounds and leave unacceptably large scars themselves compared to 6-0 suture. In general, application of 1 or 2 staples to the scalp is less painful than

Figure 2C. Example of Corner Sutures

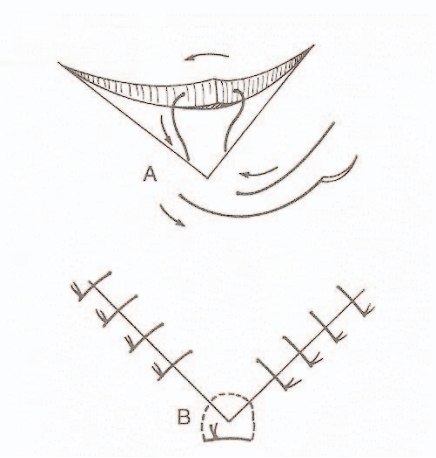

This is essentially a deep horizontal stitch (see Figure 2D) done across the corner of a wound. The same technique can be applied to stellate wounds. Place the suture through multiple wound corners at the same time to use a purse string technique to realign all corners simultaneously.

Reprinted with permission from: Roberts JR, Hedges JR. *Clinical Procedures in Emergency Medicine*, 3rd ed. Elsevier Inc.;1998:583.

Figure 2D. Horizontal Deep Stitch

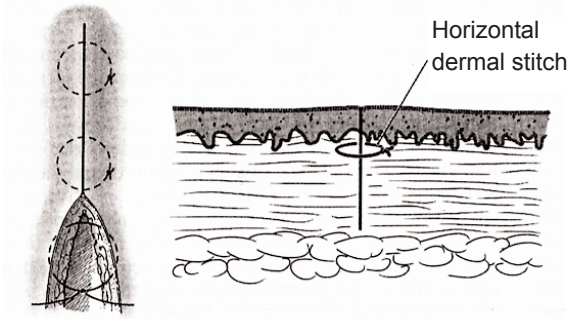

Correct placement of a horizontal deep stitch is at the upper dermis parallel to the skin surface. Placing the suture closer to the surface will maximally relieve wound tension compared to placing it deep in the wound. One needs to be careful tying this stitch, as putting too much tension on the knot will dimple and distort the skin surface. Only apply enough tension to bring the skin edges together and then stop.

Reprinted with permission from: Roberts JR, Hedges JR. *Clinical Procedures in Emergency Medicine*, 3rd ed. Elsevier Inc.;1998: 677.

injection anesthesia, but placement of more staples should be preceded by an anesthetic. Be aware that if staples are placed for hemostasis of scalp wounds, they may interfere with image quality of subsequent CT or MRI scans.

Wound tape was introduced in the 1950s and can be an excellent alternative to suture in certain cases. While many brands exist, most EPs use Steri Strips (3M Corporation, St. Paul, MN) as they have been show to outperform other products when combined with benzoin pre-treatment.[29] Wounds on the forehead and chin (if kept dry) are best suited to closure with tape, as there is little inherent wound tension. Wounds under tension, with jagged edges, or with moist surfaces from continued bleeding/oozing should be closed with sutures. Benzoin should be applied to dry wound edges, and one should avoid spilling benzoin into the eye or wound itself as it is painful and increases risk of infection.[57] Remember to allow benzoin to dry for 30 seconds before applying tape. Even with benzoin application, tape may be inadvertently pulled off (especially by children). Also, oily skin may cause tape to fall off prematurely. Ultimately, since sutures provide more control of the closure both in the ED and after discharge, a true cosmetic closure usually requires sutures instead of tape alone.

Tissue adhesives (or wound glue) represent the latest advance in wound closure techniques. It was approved for use in the United States in 1998 under the trade name Dermabond (Ethicon, Inc.), and the most recent meta-analysis supports previous conclusions that adhesives are as good as (or better) than sutures, staples, or tape for simple lacerations.[58] Wound glue is best used for smaller, straight facial wounds under no tension in hairless areas (i.e., on the forehead, cheek, etc.). Advantages are numerous: rapid wound closure, painless (unless spilled into the wound) since no needles are used, no return visits needed for removal, wound strength is equivalent to sutures at 7 days[29] (but not immediately after closure—see below), and cosmetic outcome is comparable to suture closure.[29] Further, animal studies comparing infection rates in wounds contaminated with *Staphylococcus aureus* found that sutured wounds actually had higher infection rates than those closed with adhesive.[59] Disadvantages for adhesive use include: up to 4 days after repair closures are not as strong as with sutures[60] and will have a small but higher risk of dehiscence,[61] glue cannot be used on moist surfaces (i.e., mucous membranes or persistently bleeding wounds), and that glue can be dissolved easily with antibiotic ointments, petrolatum jelly, or other solvents (i.e., acetone, nail polish remover, etc.). As the glue is not viscous, unintentional runoff of glue into the patient's eyes also can occur. This can be prevented best by placing the patient on his side or supine for the procedure and covering the eyes with gauze. Another option to prevent runoff is first to surround the wound with ointment. Runoff into the wound also should be avoided because glue that enters the wound may take more than 1 year before it is degraded.[62] Like tape, persistent patients (especially children) can remove glue by scratching at it.

When considering a wound for closure with glue, the physician must be able to approximate and hold the edges in the exact desired position during application of the glue. If a facial wound cannot be held with the fingers (or forceps) in an acceptable position prior to application, glue should not be used. A possible exception is to use a spot weld approach to glue application.[63] Adhesive is applied in spots along a wound as each part is held in good approximation, much in the same way simple interrupted sutures are placed. Even more care must be taken with this

method to keep glue from entering the wound. Aftercare instructions specific for wound adhesive should be given in every case.

In summary, all three techniques have some advantages over suturing: they are faster alternatives, often less painful, and avoid sharps that can cause needle sticks. They also avoid increased wound inflammation produced by suturing and, except for staples, do not leave hatch marks that can be dramatic when patients do not return on time for removal. It is estimated that adhesives alone are used for 25-33% of all ED laceration repairs.[64]

Wound Care after the ED. One of the most important instructions for patients after wound repair is when to return for suture/staple removal. Some physicians may not realize that sutures should be removed from facial wounds in only 4-5 days, except for sutures in the scalp, which should be removed in 7-10 days. Leaving sutures for any longer dramatically can increase the appearance of stitch marks. This occurs as epithelial cells migrate into the puncture wounds created by the suture to form plugs of tissue that will not disappear on their own. Variability exists though, as certain areas of the face are more prone to stitch marks (i.e., forehead and nose) and others seldom show them (i.e., eyelids and oral mucosa). A problem exists though, as at 4-5 days facial wound tensile strength barely has begun to increase. Thus after suture removal, facial lacerations should be supported with tape for the next 7-10 days to reduce the risk of wound dehiscence. Suture tape also helps decrease scar widening. Without support the width of the scar will gradually increase over the first 3-5 weeks. Scars across normal skin tension lines are more likely to widen. (*See Figure 1.*)

Although patients should be given written instructions on signs and symptoms of infection, they may not recognize its presence. Surprisingly, in a study of 433 ED patients, medical workers found 21 wound infections, of which only 52% were identified by the patient.[65] Further, some patients had the opposite problem and mistook the normal signs of healing for infection and instead overcalled its presence.[65] These results are not unique to trauma as another study found similar results for postoperative wound infections.[66] While some may confuse the normal signs of healing with infection and visa versa, patients usually have no trouble recognizing pain—and infections hurt. Patients should be instructed that the pain of most lacerations fades after 48 hours, and that increasing pain after this time often is due to infection. Ultimately, though, to ensure accuracy, patients should be instructed to return for a 48-hour recheck whenever there is a realistic concern for infection (i.e., bite wounds, damaged cartilage, or other deep structure injury).

Nearly all facial/scalp wounds can have a thin layer of antibiotic ointment applied, otherwise be left uncovered, and be washed gently with soap and water after 24 hours. Although many physicians are taught to keep wounds clean and dry while sutures are in place, there are no good data in the literature to support the dry part of this advice. One controlled study of head and neck wounds found washing with soap and water as early as 8 hours after repair had no effect on healing or infection.[67] A thin layer of antibiotic ointment should be applied after washing. Patients still should be cautioned against prolonged exposure to water (i.e., swimming, baths, etc.), especially with adhesives as they can be loosened by prolonged exposure to moisture.

Whether voiced or not, all patients are likely to have questions concerning the final appearance of their wound, especially on highly visible areas of the face (i.e., forehead, nose, etc.). It can be helpful to educate them that the appearance of the final scar is influenced most by the type of injury (i.e, abrasion, burn, clean laceration, etc.) and the location on the body. Patients who tend to keloid formation (most common in African-American and Asian patients) are still at risk for this with facial wounds. Therefore, the outcome is predetermined in a large part by factors out of the physician's control. While this may not reassure them, the patient can do something to improve scar appearance. Use of sunscreen containing PABA (para-aminobenzoic acid) for the following 6-12 months (the period of scar maturation) greatly can help reduce permanent hyperpigmentation of the scar.[68] The first four months are the most sensitive period for this effect,[29] and sunscreen even should be used in winter months. Giving a task for the patient to perform over the next year can help underscore the duration of scar maturation, and may reassure him or her that the pink, raised early scar will change and improve naturally with time. Likewise, it can be helpful to explain that plastic surgeons trade one scar for another and cannot completely remove scars. As they can greatly improve the final appearance though, patients with facial wounds should be given the number of the on-call plastic surgeon if they desire at the time of discharge and should be encouraged to call for consultation.

References

1. Singer AJ, Hollander JE, Quinn JV. Evaluation and management of traumatic lacerations. *N Engl J Med* 1997;337:1142-1148.
2. Glynn SM, Asarnow JR, Asarow R, et al. The development of acute PTSD after orofacial injury: A prospective study in a large urban hospital. *J Oral Maxillofac Surg* 2003;61:785-792.
3. Greene D, Maas CS, Carvalho G, et al. Epidemiology of facial injury in female blunt assault trauma cases. *Arch Facial Plast Surg* 1999;1:288-291.
4. Carlin CB, Ruff G, Mansfeld CP, et al. Facial fractures and related injuries: A ten-year retrospective analysis. *J Craniomaxillofac Trauma* 1988;4: 44-48.
5. Hackl W, Hausberger K, Sailer R, et al. Prevalence of cervical spine injuries in patients with facial trauma. *Oral Surg Oral Med Oral Pathol Oral Radiol Endod* 2001;92:370-376.
6. Hussain K, Wijetunge DB, Grubnic S, et al. A comprehensive analysis of craniofacial trauma. *J Trauma* 1994;36:34-47.
7. Murphy MF, Walls RM. The difficult and failed airway. In: *Manual of Emergency Airway Management*. Philadelphia: Lippincott Williams & Wilkins; 2000:31-39.
8. Mace SE. Cricothyrotomy and Transtracheal Jet Ventilation. In: Roberts JR, Hedges JR, eds. *Clinical Procedures in Emergency Medicine*, 3rd ed. Philadelphia: W.B. Saunders Co; 1998:57-74.
9. Ardekian L, Samet N, Shoshani Y, et al. Life-threatening bleeding following maxillofacial trauma. *J Craniomaxillofac Surg* 1993;21:336-338.
10. Mehrota ON, Brown GE, Widdowson WP, et al. Arteriography and selective embolisation in the control of life-threatening haemorrhage following facial fractures. *Br J Plast Surg* 1984;37:482-485.
11. Bynoe RP, Kerwin AJ, Parker HH, et al. Maxillofacial injuries and life-

threatening hemorrhage: Treatment with transcatheter arterial embolization. *J Trauma* 2003;55:74-79.
12. Shimoyama T. Initial management of massive oral bleeding after midfacial fracture. *J Trauma* 2003;54:332-336.
13. Edlich RF, Moghtader JC. Thermal Burns. In: Rosen P, et al, eds. *Emergency Medicine: Concepts and Clinical Practice*, 4th ed. St Louis: Mosby Inc; 1998:941-953.
14. Alvi A, Doherty T, Lewen G. Facial fractures and concomitant injuries in trauma patients. *Laryngoscope* 2003;113:102-106.
15. Lalani Z, Bonanthaya KM. Cervical spine injury in maxillofacial trauma. *Br J Oral Maxillofac Surg* 1997;35:243-245.
16. Katzen JT, Jarrahy R, Eby JB, et al. Craniofacial and skull base trauma. *J Trauma* 2003;54:1026-1034.
17. Waters TA, Peacock WF IV. Nasal emergencies and sinusitis. In: Tintinalli JE, et al, eds. *Emergency Medicine: A Comprehensive Study Guide*, 6th ed. New York: McGraw-Hill Inc; 2004:1476-1482.
18. Blennow K, Fredman P. Detection of cerebrospinal fluid leakage by isoelectric focusing on polyacrylamide gels with silver staining using the PhastSystem. *Acta Neurochir* 1995;136:135-139.
19. Hollander JE, Singer A. Wound management. In: Harwood-Nuss A, et al, eds. *The Clinical Practice of Emergency Medicine*, 3rd ed. Philadelphia: Lippincott Williams & Wilkins; 2001:449-459.
20. Rhea JT, Rao PM, Novelline RA. Helical CT and three-dimensional CT of facial and orbital injury. *Radiol Clin North Am* 1999;37:489-513.
21. Gassner R, Tuli T, Hachl O, et al. Cranio-maxillofacial trauma: A 10 year review of 9,543 cases with 21,067 injuries. *J Craniomaxillofac Surg* 2003; 31:51-61.
22. Ruff GL, Reifkohl R, Georgiade G, et al. Facial Fractures. In: *Neurosurgery*, 2nd ed. New York: McGraw-Hill Inc; 1996: 2763-2771.
23. Hasan N, Colucciello SA. Maxillofacial Trauma. In: Tintinalli JE, et al, eds. *Emergency Medicine: A Comprehensive Study Guide*, 6th ed. New York: McGraw-Hill Inc; 2004: 1583-1590.
24. Tanaka N, Hayashi S, Amegasa T, et al. Maxillofacial fractures sustained during sports. *J Oral Maxillofac Surg* 1996;54:715-719.
25. Hollander JE, Singer AJ. State of the Art: Laceration Management. *Ann Emerg Med* 1999;34:356-367.
26. Hollander JE, Singer AJ, Valentine S, et al. Wound registry: Development and validation. *Ann Emerg Med* 1995;25:675-685.
27. Capellan O, Hollander JE. Management of lacerations in the emergency department. *Emerg Med Clin North Am* 2003;21:205-231.
28. Trott AT. *Wounds and Lacerations: Emergency Care and Closure*, 2nd ed. New York: Mosby-Year Book Inc; 1997.
29. Lammers RL. Principles of wound management. In: Roberts JR, Hedges JR, eds. *Clinical Procedures in Emergency Medicine*, 3rd ed. Philadelphia: W.B. Saunders Co; 1998:533-559.
30. Trott AT. Bite Wounds. In: *Wounds and Lacerations: Emergency Care and Closure*, 2nd ed. New York: Mosby-Year Book Inc; 1997:265-284
31. Wolff KD. Management of animal bite injuries of the face: Experience with 94 patients. *J Oral Maxillofac Surg* 1998;56:838-843.
32. Guy RJ, Zook EG. Successful treatment of acute head and neck dog bite wounds without antibiotics. *Ann Plast Surg* 1986;17:45-48.
33. Donkor P, Bankas DO. A study of primary closure of human bite injuries to the face. *J Oral Maxillofac Surg* 1997;55:479-481.
34. Brogan GX Jr, Giarrusso E, Hollander JE, et al. Comparison of plain, warmed, and buffered lidocaine for anesthesia of traumatic wounds. *Ann Emerg Med* 1995;26:121-125.
35. Murakami CS, Odland PB, Ross BK. Buffered local anesthetics and epinephrine degradation. *J Dermatol Surg Oncol* 1994;20:192-195.
36. Chandler MJ, Grammer LC, Patterson R. Provocative challenge with local anesthetics in patients with a prior history of reaction. *J Allergy Clin Immunol* 1987;79:883-886.
37. Green SM, Krauss B. Procedural sedation and analgesia. In: Singer AJ, Hollander JE, eds. *Lacerations and Acute Wound Management*, Philadelphia: F.A. Davis Co; 2003: 42-55.
38. Lynch MT, Syverud SA, Schwab RA, et al. Comparison of intraoral and percutaneous approaches for infraorbital nerve block. *Acad Emerg Med* 1994;1:514-519.
39. Trott AT. Wound Cleansing and Irrigation. In: *Wounds and Lacerations: Emergency Care and Closure*, 2nd ed. New York: Mosby-Year Book Inc; 1997: 90-101.
40. Hollander JE, Richman PB, Werblud M, et al. Irrigation in facial and scalp lacerations: Does it alter outcome? *Ann Emerg Med* 1998;31:73-77.
41. Stevenson TR, Thacker JG, Rodeheaver GT, et al. Cleansing the traumatic wound by high pressure syringe irrigation. *JACEP* 1976;5:17-21.
42. Lammers RL, Fourre M, Callaham ML, et al. Effect of povidon-iodine and saline soaking on bacterial counts in acute, traumatic, contaminated wounds. *Ann Emerg Med* 1990;19:709-714.
43. Dire DJ, Welsh AP. A comparison of wound irrigation solutions used in the emergency department. *Ann Emerg Med* 1990;19:704-708.
44. Bansal BC, Wiebe RA, Perkins SD, et al. Tap water for irrigation of lacerations. *Am J Emerg Med* 2002;20:469-472.
45. Valente JH, Forti RJ, Freundlich LF, et al. Wound irrigation in children: saline solution or tap water? *Ann Emerg Med* 2003;41;609-616.
46. Perelman V, Francis GJ, Foote J, et al. Sterile vs nonsterile gloves for repair of uncomplicated lacerations in the ED: A randomized controlled trial. *Ann Emerg Med* 2004;43:362-369.
47. Seropian R, Reynolds B. Wound infections after preoperative depilatory vs razor preparation. *Am J Surg* 1971;121:251-254.
48. Sheinberg MA, Ross DA. Cranial procedures without hair removal. *Neurosurgery* 1999;44:1263-1265.
49. Singer AJ, Hollander JE. Wound preparation. In: *Lacerations and Acute Wounds: An Evidence-Based Guide*, Philadelphia: F.A. Davis Co; 2003: 13-22.
50. Katz AR, Turner RJ. Evaluation of tensile and absorption properties of polyglycolic acid sutures. *Surg Gynecol Obstet* 1970:131:701-716.
51. Edlich RF, Thacker JG, Buchanan L, et al. Modern concepts of treatment of traumatic wounds. *Adv Surg* 1979;13:169-197.
52. Trott AT. Basic laceration repair principles and techniques. In: *Wounds and Lacerations: Emergency Care and Closure*, 2nd ed. New York: Mosby-Year Book Inc; 1997:132-153.
53. Dire DJ, Coppola M, Dwyer DA, et al. Prospective evaluation of topical antibiotics for preventing infections in uncomplicated soft-tissue wounds repaired in the ED. *Acad Emerg Med* 1995;2:4-10.
54. Harvey CF, Hume Logan CJ. A prospective trial of skin staples and sutures in skin closure. *Ir J Med Sci* 1986;155:194-196.
55. Kanegaye JT, Vance CW, Chan L, et al. Comparison of skin stapling devices and standard sutures for pediatric scalp lacerations: A randomized study of cost and time benefits. *J Pediatr* 1997;130:808-813.
56. Ritchie AJ, Rocke LG. Staples versus sutures in the closure of scalp wounds: A prospective, double-blind, randomized trial. *Injury* 1989;20:217-218.

57. Panek PH, Prusak MP, Bolt D, et al. Potentiation of wound infection by adhesive adjuncts. *Am Surg* 1972;38:343-345.
58. Farion KJ. Tissue adhesives for traumatic lacerations: A systematic review of randomized controlled trials. *Acad Emerg Med* 2003;10:110-118.
59. Quinn J, Maw J, Ramotar K, et al. Octylcyanoacrylate tissue adhesive versus suture wound repair in a contaminated wound model. *Surgery* 1997;122: 69-72.
60. Noordzij JP, Foresam PA, Rodeheaver GT, et al. Tissue adhesive wound repair revisited. *J Emerg Med* 1994;12:645-640.
61. Farion K, Osmond MH, Hartling L, et al. Tissue adhesives for traumatic lacerations in children and adults. *Cochrane Database Syst Rev* 2002;3: CD003326.
62. Ellis DAF, Shaikh A. The ideal tissue adhesive in facial plastic and reconstructive surgery. *J Otoloaryngology* 1990;19:68-72.
63. Trott AT. Alternative closures: Tape, staples, and adhesives. In: *Wounds and Lacerations: Emergency Care and Closure*, 2nd ed. New York: Mosby-Year Book Inc; 1997: 248-264.
64. Singer AJ, Hollander JE. Tissue adhesives for laceration closure. *JAMA* 1997;278:703-704.
65. Seaman M, Lammers R. Inability of patients to self-diagnose wound infections. *J Emerg Med* 1991;9:215-219.
66. Whitby M, McLaws ML, Collopy B, et al. Post-discharge surveillance: Can patients reliably diagnose surgical wound infections? *J Hosp Infect* 2002;52:155-160.
67. Goldberg HM, Rosenthal SA, Nemetz JC. Effect of washing closed head and neck wounds on wound healing and infection. *Am J Surg* 1981;141: 358-359.
68. Ship AG, Weiss, PR. Pigmentation after dermabrasion: an avoidable complication. *Plast Reconstr Surg* 1985;75:528-532.

Physician CME Questions

31. Airway management in facial trauma patients can be complicated by:
    A. soft-tissue swelling.
    B. bleeding.
    C. damaged tissue.
    D. expanding hematomas.
    E. all of the above.

32. When managing the airway of a facial trauma patient:
    A. inability to intubate and keep oxygen saturations greater than 90% with bag-valve mask is an indication for adjunctive airway measure such as cricothyrotomy.
    B. one should avoid use of paralytics if possible.
    C. awake intubation may be the technique of choice.
    D. All of the above.

33. If nasal packing fails, embolization is the treatment of choice for life-threatening hemorrhage from facial trauma.
    A. True
    B. False

34. Facial fractures are:
    A. usually isolated.
    B. commonly are associated with C-spine fractures.
    C. usually cannot lead to meningitis as a complication.
    D. may have associated CN injuries that are not initially apparent.

35. Patients considered at high risk for facial fractures are:
    A. those with injuries from MVAs.
    B. those with injuries from assaults.
    C. those with sports-related injuries.
    D. All of the above.

36. All the following statements are true regarding staples *except*:
    A. Staples are faster than sutures to apply although more painful to remove.
    B. Staples are good for face repair as they allow more detailed wound approximation than sutures.
    C. Results regarding infection and wound healing are better for sutures than staples.
    D. Staples should not be used on deep scalp wounds.

37. Closure of facial wounds should be referred if:
    A. secondary procedure(s) are likely.
    B. there is possible deep structure injury by location (facial nerve or parotid duct).
    C. the patient or parent demands it.
    D. All of the above

38. Nerve blocks can easily be done on all of the following *except* the:
    A. forehead.
    B. scalp.
    C. ear.
    D. nose.
    E. lip.

39. Concerning wound preparation:
    A. Shaving hair around the wound is preferred.
    B. Mechanical scrubbing is required on facial wounds.
    C. High pressure irrigation on the face is recommended.
    D. None of the above.

40. Which areas are high risk for debridement (i.e., they have high skin tension, or are likely not to close afterward)?
    A. Nose
    B. Lip
    C. Cheek
    D. Chin

CME Answer Key

31. E; 32. D; 33. A; 34. D; 35. D; 36. B; 37. D; 38. D; 39. D; 40. A

In Future Issues: **Facial Trauma, Part II**

Emergency Medicine Reports®
The Practical Journal for Emergency Physicians

Facial Trauma, Part I

Pearls for Management of Life-Threatening Facial Trauma

- Try to stay 1-2 steps ahead in airway management. Know what your next move will be if what you are currently doing fails to work.
- Be cautious with timing and use of paralytics in patients with significant facial trauma. Awake intubation and fiberoptic intubation may be good alternatives when dealing with potentially distorted anatomy.
- Use nasal packing first, but refer patients with life-threatening facial bleeding early for embolization to definitively stop major hemorrhage.
- Isolated facial fractures are uncommon. Only 11% of patients with facial fractures from blunt trauma will *not* have associated brain, chest, or abdominal injuries.[4]
- Do not wait for signs of impending airway loss when considering intubation in facial burn patients.
- Significant facial burns alone are a reason for transfer to a burn center.

Force of Gravity Required for Facial Bone Fracture

BONE	FORCE OF GRAVITY (GRAMS)
Nasal	30
Zygoma	50
Angle of the mandible	70
Frontal	80
Midline maxilla	100
Midline mandible	100
Supraorbital rim	200

Adapted from: Hollander JE, Singer A. Wound management. In: Harwood-Nuss A, et al, eds. *The Clinical Practice of Emergency Medicine*, 3rd ed. Philadelphia: Lippincott, Williams & Wilkins; 2001: 449-459.

Consult for Repair of Facial Wounds

Consult when:

- The patient or family demands it, even after education on wound closure and scarring.
- Closure is beyond expertise of ED physician (eyelid margin, complex ear laceration, etc).
- Closure likely to require secondary procedures (large flaps, large nasal lacs).
- Closure requires general anesthesia.
- ED physician does not have time required for good closure.
- Injury of deep structure (nerve, parotid or lacrimal duct, etc.)—by location of wound or exam.
- Wound will require frequent follow-ups—best done by only one physician.
- Delayed primary closure is indicated.

Recommendations for Tetanus Prophylaxis

HISTORY OF TETANUS IMMUNIZATION	CLEAN MINOR WOUNDS		ALL OTHER WOUNDS*	
	Td	TIG	Td	TIG
Uncertain or < 3 doses	YES	No	YES	YES
≥ 3 doses				
Last dose within 5 y	No	No	No	No
Last dose 5-10 y	No	No	YES	No
Last dose >10 y	YES	No	YES	No

Td: Tetanus-diphtheria toxoid; TIG: tetanus immune globulin.

* For example, contaminated wounds, puncture wounds, avulsions, burns, and crush injuries.

Summary of Recommendations for Facial Wound Treatment

- Do not place staples on facial wounds—especially the forehead.
- Do not treat parotid gland/duct injury without evaluating for facial nerve injury (and visa versa).
- Do not assume patients with facial fractures from MVAs or assaults are isolated injuries without proving otherwise.
- Do not leave disfiguring facial bite wounds to heal by secondary intention.
- Do not forget to anesthetize wounds before cleaning them.
- Always align the vermillion lip border first.
- Try not to place absorbable sutures in ear cartilage.

Chemical Classification of Local Anesthetics

AMIDES	ESTERS
Lidocaine	Procaine
Bupivacaine	Cocaine
Etidocaine	Tetracaine
Mepivacaine	Benzocaine

Normal Skin Tension Lines

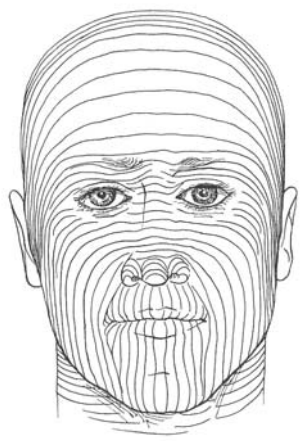

Any scar perpendicular to these lines will naturally widen over time, while scars parallel to them will naturally stay thin and hide well in facial wrinkles.

Reprinted with permission from: Harwood-Nuss A, et al, eds. *The Clinical Practice of Emergency Medicine*, 3rd ed. Lippincott, Williams & Wilkins; 2001: 449.

How to Make Wound Edges Even

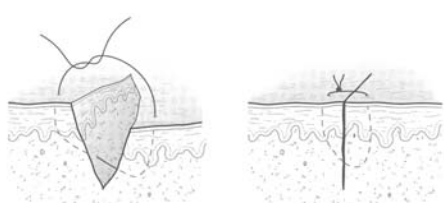

Proper placement of sutures in the wound will pull uneven edges back together. Make sure to enter and exit the sides of the wound at roughly the same depth to realign the surface.

Reprinted with permission from: Singer AJ, Hollander JE, eds. *Lacerations and Acute Wound Management*. Philadelphia: FA Davis Company;2003:130.

Proper Technique for a Deep Stitch

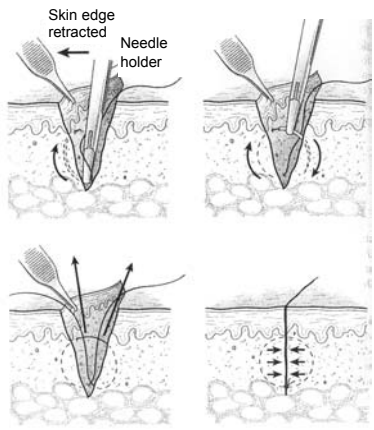

Notice that the entire suture is placed inside the dermis, not in the subcutaneous fat. Place the stitch as close as possible to the skin surface without causing dimples to produce near-perfect alignment of the surface. Under perfect conditions, one can do away with surface sutures altogether.

Reprinted with permission from: Roberts JR, Hedges JR. *Clinical Procedures in Emergency Medicine*, 3rd ed. Elsevier Inc.;1998:296.

Example of Corner Sutures

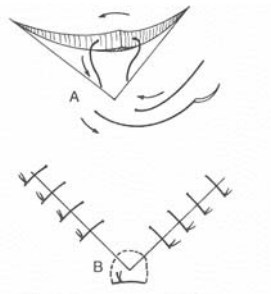

This is essentially a deep horizontal stitch (see Figure 2D) done across the corner of a wound. The same technique can be applied to stellate wounds. Place the suture through multiple wound corners at the same time to use a purse string technique to realign all corners simultaneously.

Reprinted with permission from: Roberts JR, Hedges JR. *Clinical Procedures in Emergency Medicine*, 3rd ed. Elsevier Inc.;1998:583.

Horizontal Deep Stitch

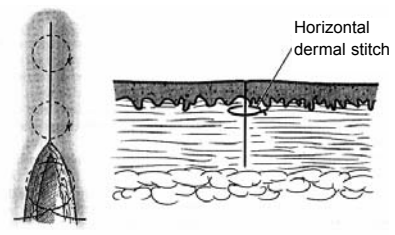

Correct placement of a horizontal deep stitch is at the upper dermis parallel to the skin surface. Placing the suture closer to the surface will maximally relieve wound tension compared to placing it deep in the wound. One needs to be careful tying this stitch, as putting too much tension on the knot will dimple and distort the skin surface. Only apply enough tension to bring the skin edges together and then stop.

Reprinted with permission from: Roberts JR, Hedges JR. *Clinical Procedures in Emergency Medicine*, 3rd ed. Elsevier Inc.;1998: 677.

Supplement to *Emergency Medicine Reports*, August 9, 2004: "The Facial Trauma Patient in the Emergency Department: Review of Diagnosis and Management. Part I: Life-Threatening Injury and General Wound Repair." *Authors:* **Gary D. Hals, MD, PhD,** Attending Physician, Department of Emergency Medicine, Palmetto Richland Memorial Hospital, Columbia, SC; **Brandi McClain-Carter, MD**, Resident Physician, Department of Emergency Medicine, Palmetto Richland Memorial Hospital, Columbia, SC; and **Brent Mullis, MD**, Chief Resident, Deparment of Emergency Medicine, Palmetto Richland Memorial Hospital, Columbia, SC.