THOMSON
AMERICAN HEALTH CONSULTANTS

Enclosed in this issue: CE/CME Evaluation

Evidence-Based M[illegible] ED

Trauma Reports

Vol. 5, No. 5

Supplement to *Emergency Medicine Reports*, *Pediatric Emergency Medicine Reports*, *ED Management*, and *Emergency Medicine Alert*

Sept./Oct. 2004

The Evaluation and Clearance of the Cervical Spine in Adult Trauma Patients: Clinical Concepts, Controversies, and Advances, Part 2

Authors: **S.V. Mahadevan, MD, FACEP,** Assistant Professor of Surgery/ Emergency Medicine, Stanford University School of Medicine; Associate Chief, Division of Emergency Medicine, and Medical Director, Stanford University Emergency Department, Stanford, CA; and **Misty Navarro, MD**, Senior Emergency Medicine Resident, Stanford-Kaiser Emergency Medicine Residency, Stanford, CA.

Reviewer: **Andrew D. Perron, MD, FACEP, FACSM,** Residency Program Director, Maine Medical Center, Portland, ME.

Cervical spine injuries, although uncommon (0.9-6% of blunt trauma patients),[1-5] have the potential to result in permanent neurologic devastation for the patient. Appropriate suspicion for cervical spine injury, immobilization, and the decision to obtain radiographic imaging are all important aspects of the acute care of an adult who has sustained a blunt traumatic injury (as discussed in Part 1 of this series); but the responsibilities of emergency department (ED)/trauma physicians do not end with the decision to obtain radiologic imaging.

The physician must then decide the most appropriate initial imaging modality (plain radiographs, computerized tomography [CT], or magnetic resonance imaging [MRI]) for the patient and when an adequate evaluation has been performed. Understanding the indications, advantages, and limitations of each radiographic modality is critical to obtaining a diagnostic evaluation that effectively identifies or excludes a cervical spine injury.

This issue presents the physician with a thorough discussion of the imaging alternatives available and facilitates clinical decision-making for diagnostic imaging. The author also provides a comprehensive discussion of the evaluation of a patient with a potential ligamentous injury to the cervical spine.

—The Editor

Introduction

Although cervical spine injury is uncommon, the implications of a missed injury are profound and may result in many serious complications for the patient and the physician. In one series, missed spinal injuries were responsible for 3% of malpractice claims and 9% of total dollars paid in claims.[6] A portion of these missed injuries resulted from inaccurate interpretation of radiographs or failure to obtain the appropriate imaging required to make the diagnosis. Trauma care providers must have a thorough understanding of imaging modalities, their indications, and more importantly, their limitations. Alternatives available include plain radiographs, CT, and MRI. Formulating an imaging approach to a patient with a potential cervical spine injury allows the trauma care provider to achieve an accurate diagnosis in a timely manner with minimal risk to the patient. Understanding the roles and risks with flexion-extension radiographs and fluo-

roscopy allows the trauma care provider to accurately identify ligamentous injury to the cervical spine, without placing the patient at risk for neurologic complications.

Radiographic Cervical Spine Clearance

Plain Films vs Computed Tomography. Although there is increasing consensus among clinicians as to which patients require cervical spine imaging, extensive variation still exists in the approach.[1] Once the decision to perform radiographic clearance has been made, the question remains: What study should I order: plain radiography, CT, or both? The ideal strategy is one that accurately and inexpensively identifies all cervical spine injuries. Unfortunately, no current approach singularly fits that bill.

Conventional radiography remains the most commonly employed approach to traumatic spine assessment in most hospitals in the world.[7] Most trauma physicians agree that at least a three-view series (i.e., lateral, open mouth, and anteroposterior) is the minimally acceptable standard for radiographic evaluation of most blunt trauma patients. A consensus agreement among emergency physicians, radiologists, and trauma surgeons states that, in an alert patient with cervical tenderness in the absence of neurologic injury, an adequate three-view series is sufficient for excluding cervical spine injury.[8] The addition of oblique views (five-view series) to improve sensitivity and improve detection of the lateral and posterior spinal elements adds little to the overall evaluation and simply prolongs the diagnostic work-up of these patients.[9] However, the swimmer's or oblique view may improve visualization of the cervico-thoracic junction when the lateral view fails to display these areas adequately.[10] The routine addition of flexion-extension views to the standard plain films is not necessary unless there is specific concern for ligamentous injury.

A single lateral view of the cervical spine is insensitive for excluding cervical spine injury. A survey of more than 100 hospitals in the mid-1990s revealed that 33% of their physicians were clearing the cervical spine using only lateral radiographs.[11] As many as 15-46% of cervical fractures were missed when cross-table lateral radiographs solely were used to exclude cervical spine injury.[6,11,12]

Although obtaining plain radiography is inexpensive, poses a low radiation risk, and is available widely, it has several distinct limitations and disadvantages. The diagnosis of significant cervical spine injury using plain films in the severely injured or unconscious patient is challenging. In many cases, the cervico-cranium (C_1-C_2) and cervicothoracic junction (C_7-T_1) are shown inadequately, or the quality of the portable films is poor. Plain films are repeated in almost 50-70% of those patients to obtain a complete study.[13,14] The result is more time lost, additional x-rays taken, and higher cost.[15,16] Moreover, the frequency of inadequate or false-positive plain radiographs increases with injury severity.[16]

In recent years, the diagnostic efficacy of cervical plain radiographs for demonstrating and excluding injury has come under increasing scrutiny. Results from a number of studies have exposed the limitations of conventional radiography. Fractures that are clearly evident on CT are not always evident on plain films. In a series comparing plain films with CT, Woodring and Lee showed that plain films revealed only 33% of all fractures and 55% of subluxations or dislocations.[11] They also found that 23% of patients (half of whom had unstable injuries) initially were diagnosed as normal.[11] Nunez et al found that 42% of injuries were not seen on plain films, including 10 patients with unstable fractures.[14] When pooling the data from several retrospective series (recognizing potential design limitations), the overall sensitivity of plain films in detecting cervical spine injury is only 53%, while that of CT is 98%.[6,14,17-19]

The availability of such an effective imaging strategy raises the question: Shouldn't everyone be screened using CT? The initial role of cervical CT was an adjunct to plain films, not a screening tool. CT was reserved for further delineation of areas suspicious for injury and areas poorly defined on plain films.[20-22] However, the widespread use of this imaging modality led to the identification of fractures and subluxations not readily apparent on plain film radiographs.

Helical CT represents an advance from the older approach of single acquisition CT. Advantages of helical CT include faster acquisition and image reconstruction times, reduction of arti-

Trauma Reports™ is published bimonthly by Thomson American Health Consultants, 3525 Piedmont Road, N.E., Six Piedmont Center, Suite 400, Atlanta, GA 30305. Telephone: (800) 688-2421 or (404) 262-7436.

Vice President/Group Publisher: Brenda Mooney
Editorial Group Head: Valerie Loner
Managing Editor: Martha Jo Dendinger
Marketing Manager: Schandale Kornegay

POSTMASTER: Send address changes to ***Trauma Reports***, P.O. Box 740059, Atlanta, GA 30374.

Subscriber Information

Customer Service: 1-800-688-2421

Customer Service E-Mail: customerservice@ahcpub.com
Editorial E-Mail: martha.dendinger@thomson.com

World Wide Web page: http://www.ahcpub.com

FREE to subscribers of *Emergency Medicine Reports, Pediatric Emergency Medicine Reports, Emergency Medicine Alert,* and *ED Management.*

Accreditation

Trauma Reports™ continuing education materials are sponsored and supervised by Thomson American Health Consultants. Thomson American Health Consultants designates this continuing education activity for up to 2.5 hours in Category 1 credit toward the AMA Physician's Recognition Award. Each physician should claim only those hours of credit that he/she actually spent in the educational activity. This CME activity was planned and produced in accordance with the ACCME Essentials. Approved by the American College of Emergency Physicians for 2.5 hours of CEP Category 1 credit.

Thomson American Health Consultants (AHC) is accredited by the Accreditation Council for Continuing Medical Education (ACCME) to provide continuing medical education for physicians.

Trauma Reports® is approved for approximately 2.5 nursing contact hours. This offering is sponsored by Thomson American Health Consultants, which is accredited as a provider of continuing education in nursing by the American Nurses' Credentialing Center's Commission on Accreditation.

Provider approved by the California Board of Registered Nursing, Provider Number CEP 10864, for approximately 2.5 contact hours. This program (#0105-1) has been approved by an AACN Certification Corp.-approved provider (#10852) under established AACN Certification Corp. guidelines for 2.5 contact hours, CERP Category A.

This is an educational publication designed to present scientific information and opinion to health professionals, to stimulate thought, and further investigation. It does not provide advice regarding medical diagnosis or treatment for any individual case. It is not intended for use by the layman. Opinions expressed are not necessarily those of this publication. Mention of products or services does not constitute endorsement. Clinical, legal, tax, and other comments are offered for general guidance only; professional counsel should be sought for specific situations.

This CME/CE activity is intended for emergency, family, osteopathic, trauma, surgical, and general practice physicians and nurses who have contact with trauma patients.

It is in effect for 36 months from the date of publication.

THOMSON™
AMERICAN HEALTH CONSULTANTS

For Customer Service,
Please call our customer service department at **(800) 688-2421.** For editorial questions or comments, please contact **Martha Jo Dendinger**, Managing Editor, at martha.dendinger@thomson.com.

Conflict of Interest Disclosure

In order to reveal any potential bias in this publication, and in accordance with Accreditation Council for Continuing Medical Education guidelines, Dr. Dietrich (editor in chief), and editorial board members Bowman, Diebel, Falcone, Finerty Hanlon, Jones, Mahadevan (author), Perkin, Santanello, Savitsky, an Stafford report no relationships with companies related to the field of study covered by this CME program. Drs. Navarro (co-author) and Perron (peer reviewer) also report no relationships with companies related to the field of study covered by this CME program.

Table. Harborview High-Risk Criteria

The presence of any of the following criteria indicates a subject at sufficiently high risk to warrant the initial use of CT to evaluate the cervical spine.

- High-energy injury mechanism, including high-speed (> 35 mph) motor vehicle or motorcycle crash, motor vehicle crash with a death at the scene, fall from height greater than 10 feet.
- High-risk clinical parameter, including significant head injury (i.e., intracranial hemorrhage or unconsciousness in emergency department), neurologic signs or symptoms referable to the cervical spine, pelvic or multiple extremity fractures.

Adapted from: Hanson JA, et al. *AJR Am J Roentgenol* 2000;174: 713-717.

facts, and a higher quality of reformatted and three dimensional images.[23] In the multiple-trauma patient, helical CT can assess several body regions in less time. Before helical CT, the time required for the scan itself and heating and cooling of the tube made screening of the entire cervical spine impractical.[24]

Rather than adopting CT as the primary screening modality, an early approach advocated limited use of CT to examine portions of the spine that were anatomically difficult to see on plain films, such as the cervicocranial and cervicothoracic junctions.[25] These guidelines recommended standard plain radiography supplemented by regional CT of the cervicocranium and areas of suspicion. However, results of a recent study revealed that the approach would have missed 71% (29/41) of injuries that occurred below the C_2 level and did not show up on plain films.[17]

Some centers routinely obtain cervical spine CT in all patients who are getting a CT scan of the head or body. That practice is supported by several small studies and is in keeping with the most recent American College of Radiology (ACR) Guidelines (2002), which recommend cervical spine CT in patients with paresthesias, altered level of consciousness, and in whom cranial CT will be obtained.[8] When CT of the head and cervical spine are obtained together, the overall time for cervical spine evaluation was reduced by an average of 17 minutes, and the estimated additional cost was only $184.42 per patient.[6,18,26-28] That approach also identified a significant number of fractures (occipital condyle fractures and C_1/C_2 fractures) not seen on plain films.[29]

An additional advantage of obtaining a cervical spine CT is its ability to provide information about surrounding anatomical structures. In one series, other injuries were detected in 9% of patients undergoing CT of the cervical spine, including fractures of the upper thoracic spine, proximal ribs, mandible, and skull base.[30] Small, apical pneumothoraces and airway injuries also may be detected.[26]

Considering the ease of obtaining a CT, the time saved, and the diagnostic sensitivity, there is a propensity to use it routinely for cervical spine clearance instead of conventional radiography. Advantages of helical CT compared with plain radiographs include improved accuracy and faster diagnosis; disadvantages include greater expense and higher radiation doses.[19,30] It is well known that the risk of thyroid cancer increases with radiation exposure, especially in children.[18,31,32] Estimates of radiation risk from a complete cervical CT scan vary depending upon the technique and type of scanner. Rybicki et al found that helical CT exposed the thyroid to 14 times the radiation of standard cervical spine plain radiographs, even when accounting for the need for repeat radiographs.[33]

With the radiation risk and cost of CT in mind, a number of authors have attempted to define high-risk patients who should be screened primarily with cervical CT.[6,18,26,30,34] High-risk patients as described by Hanson and Blackmore are patients with a probability of cervical spine injury exceeding 5-10%.[26,30] This definition included patients suffering a high-energy mechanism injury or presenting with a high-risk clinical parameter.[30,34] (*See Table.*) In their small prospective study, Berne et al defined high-risk patients as those who had an altered mental status, were unconscious, or required an admission to an intensive care unit.[18] Screening high-risk patients with CT has been shown to be cost-effective, time efficient, and clinically efficacious.[15,35]

Although Blackmore et al did not find CT to be cost-effective in low-risk patients (less than 4% chance of injury),[35] Griffin et al suggest there is a growing body of evidence that CT should replace plain films for the screening evaluation of the cervical spine in all blunt trauma patients.[17] In their recent, retrospective review of 1,199 trauma patients, they found that plain radiographs—interpreted as normal by the radiologists without recommendation for further radiography—failed to identify 41 of 116 cervical spine injuries detected by CT. A number of factors made it difficult to draw any firm conclusions from their study: 1) the retrospective nature of data collection; 2) types of injuries missed (including transverse process and spinous process fractures); 3) types of patients evaluated (including patients with neurologic deficits or deaths); and 4) absence of missed injuries (patients with normal plain films still were scanned). Before adopting a strategy of screening all patients with CT, further prospective research is needed.

Before abandoning plain films completely, it is important to understand that screening radiography is not intended to detect every cervical spine injury.[36] Rather, when plain films reveal an injury or area of suspicion, or prove to be inadequate, other modalities such as CT or MRI should be used to evaluate for cervical spine injuries. In a review of 34,069 patients screened with plain radiography, Mower et al found that screening radiography only missed three injuries associated with spinous instability, or one unstable injury for every 11,000 screening evaluations.[36]

No radiological modality—including CT— is 100% sensitive in the detection of cervical spine injuries. Brohi et al describe a patient with a C_6-C_7 bilateral facet dislocation missed on CT scan.[37] Schenarts et al revealed that CT had a sensitivity of 96% and missed three injuries seen on plain films (an atlanto-occipital dislocation and two subluxations).[19] They also describe the case of a patient with a C_4 fracture—missed on both CT and plain films—who suffered a severe neurologic injury after removal of

Figure 1. Cervical Spine Fracture Missed by Computed Tomography (CT)

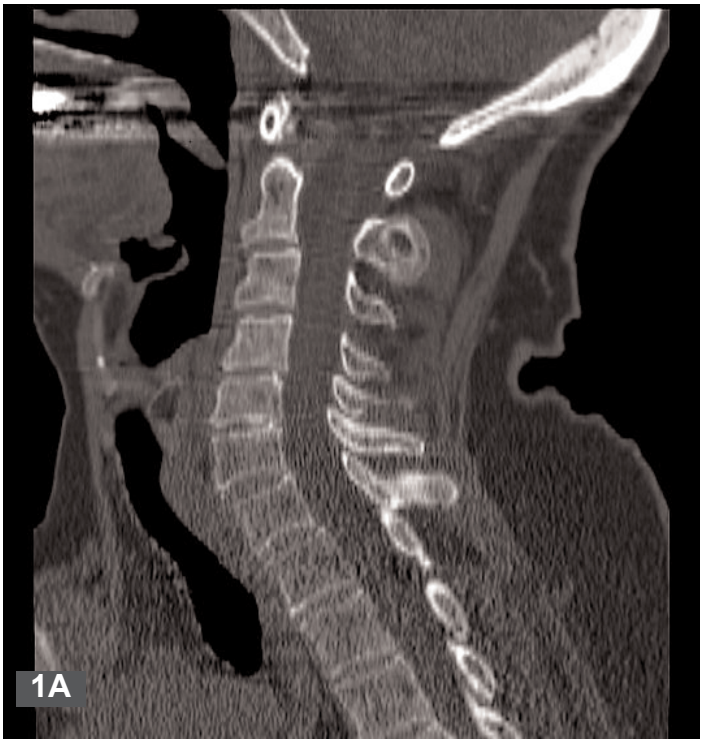

Figure 1A: Sagittally reformatted CT image of the cervical spine showing multilevel disc degeneration, but no apparent bony injury.

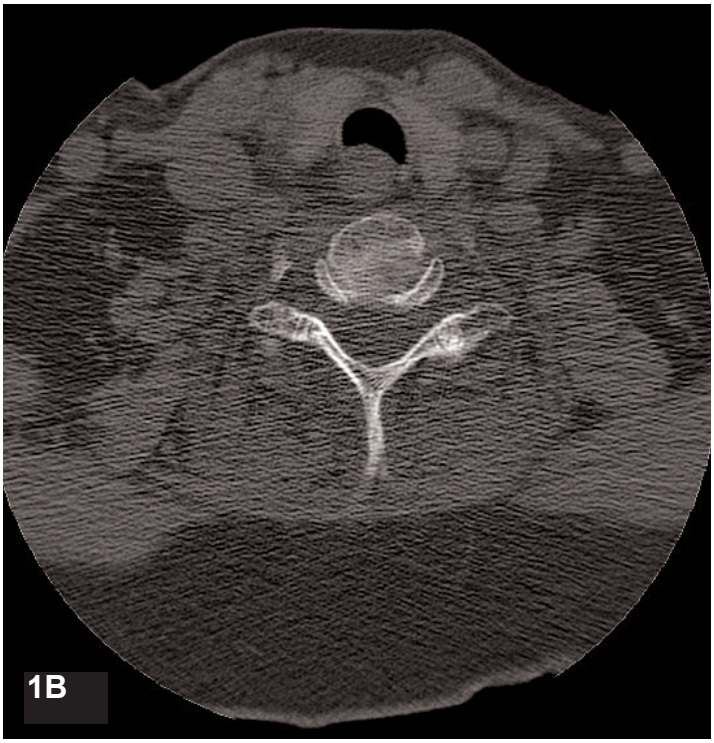

Figure 1B: Normal axial CT through the inferior aspect of the C_6 vertebral body.

Figure 1C: Lateral extension radiograph of the cervical spine in the same patient reveals a fracture of the anteroinferior aspect of the body of C_6.

Figure 1D: Magnified view of the fracture through the C_6 vertebral body.

Images courtesy of Kathryn Stevens, MD, FRCR, BSc(hons).

Figure 2. Swimmer's View and Dynamic Fluoroscopy in a Patient with a Potential Spine Injury

Figure 2A. Swimmer's view shows C_6-C_7 vertebral bodies.
Figure 2B. Fluoroscopic image of extension test shows abnormal angulation and anterior widening of C_6-C_7 interspace.

Reprinted with permission from Robert KQ et al. *South Med J.* 2000;93:974-976.

the cervical collar. Berne et al showed that helical CT of the entire cervical spine had a sensitivity of 90% and missed two stable injuries (a ligamentous injury and spinous process fracture).[18] The rationale for missed ligamentous injuries on CT is that moderate subluxation may be noted only when evaluating the spine in profile.[23] Though the addition of the lateral radiograph allows for detection of fractures or subluxation that might be subtle or overlooked on axial CT images **(**See Figure 1.**),** the improved technology of multi-detector scanners and reformatting may make this practice unnecessary.[38]

The identification of a cervical spine injury on plain films or CT mandates evaluation of the remainder of the cervical spine and the thoracic and lumbosacral spine to exclude concomitant spinal injuries.[37] The incidence of multiple level, non-contiguous fractures has been reported to be 15-24%.[39,40] Recent use of MRI reveals that percentage could be much higher (42%).[41]

Magnetic Resonance Imaging. MRI has several advantages as an imaging modality: high-resolution capabilities; the lack of ionizing radiation; multiplanar imaging capabilities; and the ability to visualize soft-tissue structures including intervertebral discs, ligaments, and the spinal cord. Disadvantages of MRI include prolonged acquisition time, impaired monitoring abilities, and several absolute contraindications (e.g., pacemakers, aneurysm clips, and metallic foreign bodies). In addition, MRI is not available universally, and patient transfer might be required to obtain this study.

In the acute trauma patient with potential cervical spine injury, the indications for MRI as part of the ED evaluation include: 1) complete or incomplete neurologic deficits with radiographic evidence of fracture or subluxation; 2) neurologic deficits not explained by plain films or CT findings (i.e., spinal cord injury without radiographic abnormality [SCIWORA]); 3) deterioration of neurologic function; and 4) suspicion of ligamentous injury following inadequate or negative flexion-extension film findings.[42]

Will MRI replace CT as the primary adjunct to plain film imaging? The ability of MRI to visualize cervical spine fractures (in addition to spinal cord and soft-tissue injuries) has been variable.[43-44] Holmes et al found that MRI missed 45% of osseous fractures identified on CT.[45] While MRI is clearly superior to CT in identifying spinal cord and ligamentous injuries, CT remains the preferred adjunct to plain radiography for the identification of bony injuries.

Diagnosis of Ligamentous Injury

Awake and Alert Patients. Patients without cervical spine fractures still may harbor unstable ligamentous injuries. Although the prevalence of isolated ligamentous injury in the absence of a cervical spine fracture is thought to be low—a reported frequency of 0.04-0.2% in all blunt trauma patients—the consequences of a missed ligamentous injury can be devastating for the patient.[46,47] The true incidence of such injury is actually unknown; a gold standard for such diagnosis currently does not exist. Although traditional cervical spine radiography is useful for detecting fractures and subluxation, the detection of liga-

mentous injury is less precise.[48] For that reason, a patient with normal cervical spine radiography still may remain in a cervical collar until his or her ligaments can be cleared clinically or definitive imaging is obtained.

If a patient has negative results on radiographic studies, is alert and awake, and denies neck pain, the cervical spine is considered clear. However, the persistence of cervical pain while initial radiographs are normal requires the exclusion of ligamentous injury. While ligamentous injury may be inferred on the basis of an injury seen on CT or plain radiographs, the possibility of ligamentous injury causing instability in the absence of fracture may be excluded through the use of flexion-extension films or MRI.

Flexion-extension radiographs generally are obtained by asking an upright patient to actively flex and extend the neck during cervical spine imaging. This action should be performed only by patients under their own power; the physician should never forcibly assist the patient with flexion or extension. Flexion-extension radiographs should be obtained only in awake, alert, cooperative patients without neurologic symptoms or deficits. Under those circumstances, the risk of neurologic compromise produced by flexion and extension of the cervical spine is very unlikely. When performed voluntarily by the patient, no serious adverse events have been reported.[37,43,48-51]

The goal in interpreting flexion-extension radiographs is to identify or exclude signs of soft-tissue ligamentous injury, such as abnormal subluxation, angulation, or uncovering of facet joints.[52,53] However, following an acute injury, pain associated with motion or muscle spasm may limit a patient's ability to flex and extend adequately. A patient must have a range greater than 30° in each direction from the neutral position for flexion-extension radiographs to be considered adequate.[54] The inability to flex and extend adequately may lead to masking of abnormalities (e.g., subluxation) and result in false-negative studies. Results from a number of series have revealed that 28-59% of flexion-extension radiographs obtained in acutely injured patients were deemed inadequate.[53,55-57]

For that reason, the practice of obtaining flexion-extension radiographs in the acutely traumatized patient has been questioned by numerous studies.[53,57-60] Most recently, the American College of Radiology stated in its guidelines that those views in general are not very helpful and should be reserved for follow up of symptomatic patients 7-10 days after initial injury.[8] In such cases, patients are discharged with a semi-rigid collar and pain medications, and asked to return when they can cooperate actively for flexion-extension radiographs. In a case series by Wilberger et al, 8 of 62 patients (13%), who returned 2-4 weeks after initial flexion-extension films for a repeat set, had significant ligamentous instability requiring cervical fusion.[55]

Do flexion-extension radiographs have any role in the acutely injured patient? Rather than completely abandoning them, a logical approach may be to screen the patient first for the ability to flex and extend the neck adequately. In patients with an adequate range of motion (i.e., greater than 30° in each direction from the neutral position), films may be warranted. In such patients with adequate mobility and negative radiographs, the cervical spine would be cleared effectively. This strategy is supported by the findings of Insko et al, who found that in patients with adequate imaging, flexion-extension radiographs had a false-negative rate of 0%.[57]

Figure 3. Adult SCIWORA

Figure 3. MRI image revealing spinal cord contusion in a patient with spinal canal narrowing at C_5-C_6 and an osteophyte causing mild impression on the thecal sac. There was no evidence of ligamentous injury or prevertebral hematoma. The patient's CT scan revealed no acute fractures or dislocation.

Image courtesy of S.V. Mahadevan, MD.

In cases of inadequate flexion-extension radiographs, patients also may be studied with an MRI to exclude ligamentous injuries. A negative MRI in the first 48 hours post injury combined with normal plain films and/or CT is sufficient to clear a patient.

Obtunded Patients. The evaluation of ligamentous injury in the obtunded or intoxicated individual is somewhat more difficult. In these patients, a detailed neurologic examination often is not feasible, and the physical exam may be unreliable. For that reason, obtunded, impaired, or distracted patients should not have flexion-extension studies performed in the ED, as such a practice is unsafe and potentially dangerous.

However, obtunded patients who are admitted to the hospital and subject to prolonged immobilization are at risk for detrimental consequences. Prolonged application of a cervical collar in obtunded patients has been associated with skin ulceration, interference with care of neck and shoulder wounds, difficulty with the placement of central lines, increased risk of aspiration, and

patient discomfort.[56,61,62] Additionally, the use of cervical collars alone is not sufficient for immobilizing the cervical spine.[63,64]

For those reasons, clearance of the cervical spine and removal of the collar should be performed in a timely manner. No clear consensus exists as to how to evaluate these patients, and practice varies greatly as to how to exclude ligamentous injury.[1] If a patient shows clinical improvement, has a clear sensorium, and can be examined reliably, then a ligamentous injury could be excluded either clinically or with flexion-extension radiographs. In a patient who remains obtunded, recommendations vary from removal of the collar after 24 hours in patients with normal radiographs, to indefinite immobilization in the cervical collar, to MRI and dynamic flexion-extension under fluoroscopy.[47]

MRI is highly sensitive for the recognition of ligamentous injuries, identifying soft-tissue injuries in 25% of obtunded patients with negative radiographs.[51,65] MRI has the added benefit of being able to exclude spinal cord injuries. A negative MRI study within 48 hours of injury implies the absence of ligamentous injury. However, MRI may be overly sensitive for the detection of ligamentous injuries and may reveal injuries of unclear clinical significance.[56] In addition, MRI may not be feasible in unstable patients due to prolonged scanning times and impaired monitoring abilities.[62]

Dynamic fluoroscopy may be used to evaluate for ligamentous injury in obtunded patients who are not candidates for MRI due to contraindications or instability. (*See Figures 2A and 2B*). Unlike MRI, this test may be performed in the critical care unit.[37] Unfortunately, dynamic fluoroscopy often is labor intensive and has the potential to induce secondary neurologic injury. Active flexion-extension under fluoroscopy places patients at risk for neurologic impairment due to subluxation at non-visualized segments or disc abnormalities not demonstrated by radiographs or CT.[66] There are reports of patients who developed quadriplegia following dynamic fluoroscopic evaluation.[47,67]

Due to the exceedingly low incidence of isolated ligamentous instability in obtunded patients with normal radiography, some authors have suggested that the cervical spine can be cleared with an adequate lateral view of the cervical spine and a helical CT from the occiput to T_4 with sagittal and coronal reconstructions.[56] That practice has yet to be validated in a large clinical trial and is in contrast to the most current *Eastern Association for the Surgery of Trauma (EAST) Guidelines*.[68]

Spinal Cord Injury without Radiographic Abnormality (SCIWORA)

Pang and Wilberger defined the term SCIWORA (spinal cord injury without radiographic abnormality) in 1982 to describe a syndrome of post-traumatic neurologic injury without evidence of fracture or ligamentous instability on plain radiographs or CT.[69] Although this syndrome classically is associated with children—playing a role in as many as 50% of pediatric spinal cord injuries—it also may occur in adults.[46,62-77] While the clinical presentations of this syndrome in children and adults may be similar, the hypothesized mechanisms by which they occur differ.

In the pediatric population, highly elastic ligaments in the juvenile spine are thought to allow transient intersegmental vertebral dislocation followed by spontaneous reduction, resulting in damage to the spinal cord, but a normal-appearing, bony vertebral column.[71] Adult patients with degenerative cervical spine conditions and stenosis of the spinal canal also are at risk for SCIWORA. In such patients with pre-existing cervical spondylitic changes, hyperextension can lead to pinching of the spinal cord between vertebral osteophytes and the inward bulging of the ligamentum flavum. (*See Figure 3*.) However, Bhatoe reported another mechanism for SCIWORA in young adult patients who lacked features of pre-existing cervical spine disease.[78] He concluded that acute stretching of the spinal cord from hyperflexion and torsional strain leads to SCIWORA in these patients.

Patients with SCIWORA often present with profound or progressive paralysis, either immediately or within 48 hours of a traumatic incident. While a significant number of patients have demonstrable neurologic deficits at time of presentation, others may present with transient or delayed symptoms. Pang et al found that almost 52% of the patients in their study with SCIWORA had a delayed onset of neurologic deficits ranging from 30 minutes to 4 days.[70] A number of these children had transient warning symptoms immediately following their trauma that had been ignored initially.[70] The observation of delayed deterioration by different investigators highlights the importance of screening patients for SCIWORA warning signs, such as transient weakness, paresthesias, numbness, shock-like sensations, or focal clumsiness following a traumatic event.[71,79] Although the initial neurologic exam may be unremarkable, frequent patient reassessment may detect an evolving neurologic condition. Results from one study showed that several adult patients had normal initial neurologic exams and later developed neurologic deficits.[46]

Hendey et al in their review of the NEXUS database found that the NEXUS criteria also were useful in identifying all 27 patients with SCIWORA.[77] The criteria may have a role in identifying patients at reduced risk for SCIWORA, although that has not been validated prospectively.

When Pang and Wilberger originally defined SCIWORA, MRI did not exist.[80] With its advent, some authors note that the term SCIWORA now may be a misnomer because most patients actually have a demonstrable radiographic spinal cord abnormality seen on MRI.[74] MRI has revealed such findings as spinal cord hemorrhage or edema, intervertebral disc herniation, and spinal cord transection. Occasionally, the MRI may be normal.

In their series, Pang and Wilberger reported that the primary predictor of neurologic outcome in SCIWORA was the presenting neurologic status.[69] More recent studies have revealed that the appearance of the spinal cord on MRI provides better prognostic information regarding the patient's ultimate neurological outcome.[79] A normal-appearing spinal cord (i.e., absence of signal change) portends an excellent outcome; the presence of edema or microhemorrhages without frank hematomyelia (hemorrhage into the spinal cord) is associated with significant improvement of neurologic function over time; and the presence of hematomyelia or cord transection is associated with severe, permanent neurologic injury.[80-82]

Conclusions

The evaluation and clearance of the cervical spine in adult trauma patients are challenging and evolving aspects of trauma care. Trauma care providers should have a thorough understanding of risk factors for cervical spine injury, techniques for protecting patients from exacerbation of their injuries, advances in the practice of clinical and radiographic clearance of the cervical spine, and the diagnosis of such conditions as isolated ligamentous injury and SCIWORA syndrome.

With adequate training, improved detection, and proper care, physicians can prevent the life-altering complications of cervical spine injury such as neurologic injury, severe disability, and death.

Special thanks to Kathryn Stevens, MD, FRCR, BSc (hons), Assistant Professor of Radiology, Department of Radiology, Stanford University School of Medicine, for her contributions to this article.

References

1. Grossman MD, Reilly PM, Gillett T, et al. National survey of the incidence of cervical spine injury and approach to cervical spine clearance in U.S. trauma centers. *J Trauma* 1999;47:684-690.
2. Hoffman JR, Wolfson AB, Todd K, et al. Selective cervical spine radiography in blunt trauma: Methodology of the National Emergency X-Radiography Utilization Study (NEXUS). *Ann Emerg Med* 1998;32:461-469.
3. Diliberti T, Lindsey RW. Evaluation of the cervical spine in the emergency setting: Who does not need an X-ray? *Orthopedics* 1992;15:179-183.
4. Stiell IG, Wells GA, Vandemheen K, et al. Variation in emergency department use of cervical spine radiography for alert, stable trauma patients. *CMAJ* 1997;156:1537-1544.
5. Roth BJ, Martin RR, Foley K, et al. Roentgenographic evaluation of the cervical spine: A selective approach. *Arch Surg* 1994;129: 643-645.
6. Barba CA, Taggert J, Morgan AS, et al. A new cervical spine clearance protocolusing computed tomography. *J Trauma* 2001;51: 652-657.
7. Cassar-Pullicino VN. Spinal injury: Optimising the imaging options. *Eur J Radiol* 2002;42:85-91.
8. Daffner RH, Dalinka MK, Alazraki N, et al. American College of Radiology ACR Appropriateness Criteria: Suspected Cervical Spine Trauma [Electronic]. Available at: www.acr.org. Accessed Sept. 20, 2003.
9. Freemyer B, Knopp R, Piche J, et al. Comparison of five-view and three-view cervical spine series in the evaluation of patients with cervical trauma. *Ann Emerg Med* 1989;18:818-821.
10. Turetsky DB, Vines FS, Clayman DA, et al. Technique and use of supine oblique views in acute cervical spine trauma. *Ann Emerg Med* 1993;22:685-689.
11. Woodring JH, Lee C. Limitations of cervical radiography in the evaluation of acute cervical trauma. *J Trauma* 1993;34:32-39.
12. Bachulis BL, Long WB, Hynes GD, et al. Clinical indications for cervical spine radiographs in the traumatized patient. *Am J Surg* 1987;153:473-478.
13. Velmahos GC, Theodorou D, Tatevossian R, et al. Radiographic cervical spine evaluation in the alert asymptomatic blunt trauma victim: Much ado about nothing. *J Trauma* 1996;40:768-774.
14. Nunez DB Jr, Zuluaga A, Fuentes-Bernardo DA, et al. Cervical spine trauma: How much more do we learn by routinely using helical CT? *Radiographics* 1996;16:1307-1321.
15. Blackmore CC, Zelman WN, Glick ND. Resource cost analysis of cervical spine trauma radiography. *Radiology* 2001;220:581-587.
16. Blackmore CC DR. Specificity of cervical spine radiography: Importance of clinical scenario. *Emerg Radiol* 1997;4:283-286.
17. Griffen MM, Frykberg ER, Kerwin AJ, et al. Radiographic clearance of blunt cervical spine injury: Plain radiograph or computed tomography scan? *J Trauma* 2003;55:222-227.
18. Berne JD, Velmahos GC, El-Tawil Q, et al. Value of complete cervical helical computed tomographic scanning in identifying cervical spine injury in the unevaluable blunt trauma patient with multiple injuries: A prospective study. *J Trauma* 1999;47:896-902.
19. Schenarts PJ, Diaz J, Kaiser C, et al. Prospective comparison of admission computed tomographic scan and plain films of the upper cervical spine in trauma patients with altered mental status. *J Trauma* 2001;51:663-669.
20. Woodring JH, Lee C. The role and limitations of computed tomographic scanning in the evaluation of cervical trauma. *J Trauma* 1992;33:698-708.
21. Borock EC, Gabram SG, Jacobs LM, et al. A prospective analysis of a two-year experience using computed tomography as an adjunct for cervical spine clearance. *J Trauma* 1991;31:1001-1006.
22. Choi D. Cervical x-rays and the atlanto-axial region: Supplementary computed tomography may be required in trauma. *Scott Med J* 2000;45:151.
23. LeBlang SD, Nunez DB, Jr. Helical CT of cervical spine and soft tissue injuries of the neck. *Radiol Clin North Am* 1999;37:515-532.
24. Cornelius RS. Imaging of acute cervical spine trauma. *Semin Ultrasound CT MR* 2001;22:108-124.
25. Ross SE, Schwab CW, David ET, et al. Clearing the cervical spine: Initial radiologic evaluation. *J Trauma* 1987;27:1055-1060.
26. Blackmore CC, Mann FA, Wilson AJ. Helical CT in the primary trauma evaluation of the cervical spine: An evidence-based approach. *Skeletal Radiol* 2000;29:632-639.
27. Keenan HT, Hollingshead MC, Chung CJ, et al. Using CT of the cervical spine for early evaluation of pediatric patients with head trauma. *AJR Am J Roentgenol* 2001;177:1405-1409.
28. Daffner RH. Helical CT of the cervical spine for trauma patients: A time study. *AJR Am J Roentgenol* 2001;177:677-679.
29. Link TM, Schuierer G, Hufendiak A, et al. Substantial head trauma: Value of routine CT examination of the cervicocranium. *Radiology* 1995;196:741-745.
30. Hanson JA, Blackmore CC, Mann FA, et al. Cervical spine injury: A clinical decision rule to identify high-risk patients for helical CT screening. *AJR Am J Roentgenol* 2000;174:713-717.
31. Schneider AB. Radiation-induced thyroid tumors. *Endocrinol Metab Clin North Am* 1990;19:495-508.
32. Atherton JV, Huda W. Energy imparted and effective doses in computed tomography. *Med Phys* 1996;23:735-741.
33. Rybicki F, Nawfel RD, Judy PF, et al. Skin and thyroid dosimetry in

cervical spine screening: Two methods for evaluation and a comparison between a helical CT and radiographic trauma series. *AJR Am J Roentgenol* 2002;179:933-937.
34. Blackmore CC. Evidence-based imaging evaluation of the cervical spine in trauma. *Neuroimaging Clin N Am* 2003;13:283-291.
35. Blackmore CC, Ramsey SD, Mann FA, et al. Cervical spine screening with CT in trauma patients: A cost-effectiveness analysis. *Radiology* 1999;212:117-125.
36. Mower WR, Hoffman JR, Pollack CV Jr, et al. Use of plain radiography to screen for cervical spine injuries. *Ann Emerg Med* 2001; 38:1-7.
37. Brohi K, Wilson-Macdonald J. Evaluation of unstable cervical spine injury: A 6-year experience. *J Trauma* 2000;49:76-80.
38. Lawrason J, Novelline RA, Rhea JT, et al. Can CT eliminate the initial portable lateral cervical spine radiograph in the multiple trauma patient? A review of 200 cases. *Emerg Radiol* 2001;8:272-275.
39. Hadden WA, Gillespie WJ. Multiple level injuries of the cervical spine. *Injury* 1985;16:628-633.
40. Henderson RL, Reid DC, Saboe LA. Multiple noncontiguous spine fractures. *Spine* 1991;16:128-131.
41. Qaiyum M, Tyrrell PN, McCall IW, et al. MRI detection of unsuspected vertebral injury in acute spinal trauma: Incidence and significance. *Skeletal Radiol* 2001;30:299-304.
42. Gibbs MA, Jones AE. Cervical Spine Injury: A-State-Of-The-Art Approach to Assessment and Management. *Emer Med Pract* 2001; 3:1-24.
43. Benzel EC, Hart BL, Ball PA, et al. Magnetic resonance imaging for the evaluation of patients with occult cervical spine injury. *J Neurosurg* 1996;85:824-829.
44. Katzberg RW, Benedetti PF, Drake CM, et al. Acute cervical spine injuries: Prospective MR imaging assessment at a level 1 trauma center. *Radiology*1999;213:203-212.
45. Holmes JF, Mirvis SE, Panacek EA, et al. Variability in computed tomography and magnetic resonance imaging in patients with cervical spine injuries. *J Trauma* 2002;53:524-530.
46. Demetriades D, Charalambides K, Chahwan S, et al. Nonskeletal cervical spine injuries: Epidemiology and diagnostic pitfalls. *J Trauma* 2000;48:724-727.
47. Davis JW, Kaups KL, Cunningham MA, et al. Routine evaluation of the cervical spine in head-injured patients with dynamic fluoroscopy: A reappraisal. *J Trauma* 2001;50:1044-1047.
48. Brady WJ, Moghtader J, Cutcher D, et al. ED use of flexion-extension cervical spine radiography in the evaluation of blunt trauma. *Am J Emerg Med* 1999;17:504-508.
49. Ajani AE, Cooper DJ, Scheinkestel CD, et al. Optimal assessment of cervical spine trauma in critically ill patients: A prospective evaluation. *Anaesth Intensive Care* 1998;26:487-491.
50. Banit DM, Grau G, Fisher JR. Evaluation of the acute cervical spine: A management algorithm. *J Trauma* 2000;49:450-456.
51. D'Alise MD, Benzel EC, Hart BL. Magnetic resonance imaging evaluation of the cervical spine in the comatose or obtunded trauma patient. *J Neurosurg*1999;91:54-59.
52. Robert KQ 3rd, Ricciardi EJ, Harris BM. Occult ligamentous injury of the cervical spine. *South Med J* 2000;93:974-976.
53. Wang JC, Hatch JD, Sandhu HS, et al. Cervical flexion and extension radiographs in acutely injured patients. *Clin Orthop* 1999;365:111-116.
54. Marion DW, Domier R, Dunham CM, et al. EAST Practice Management Guidelines for Identifying Cervical Spine Injuries Following Trauma. Available at: http://www.east.org/tpg/chap3.pdf.
55. Wilberger JE, Maroon JC. Occult posttraumatic cervical ligamentous instability. *J Spinal Disord* 1990;3:156-161.
56. Anglen J, Metzler M, Bunn P, et al. Flexion and extension views are not cost-effective in a cervical spine clearance protocol for obtunded trauma patients. *J Trauma* 2002;52:54-59.
57. Insko EK, Gracias VH, Gupta R, et al. Utility of flexion and extension radiographs of the cervical spine in the acute evaluation of blunt trauma. *J Trauma* 2002;53:426-429.
58. Harris MB, Waguespack AM, Kronlage S. 'Clearing' cervical spine injuries in polytrauma patients: Is it really safe to remove the collar? *Orthopedics* 1997;20:903-907.
59. Pollack CV Jr, Hendey GW, Martin DR, et al. Use of flexion-extension radiographs of the cervical spine in blunt trauma. *Ann Emerg Med* 2001;38:8-11.
60. Ralston ME, Chung K, Barnes PD, et al. Role of flexion-extension radiographs in blunt pediatric cervical spine injury. *Acad Emerg Med* 2001;8:237-245.
61. Davis JW, Parks SN, Detlefs CL, et al. Clearing the cervical spine in obtunded patients: The use of dynamic fluoroscopy. *J Trauma* 1995; 39:435-438.
62. Chiu WC, Haan JM, Cushing BM, et al. Ligamentous injuries of the cervical spine in unreliable blunt trauma patients: Incidence, evaluation, and outcome. *J Trauma* 2001;50:457-464.
63. Grady MS, Howard MA, Jane JA, et al. Use of the Philadelphia collar as an alternative to the halo vest in patients with $C-_2$, $C-_3$ fractures. *Neurosurgery* 1986;18:151-156.
64. Rosen PB, McSwain NE Jr, Arata M, et al. Comparison of two new immobilization collars. *Ann Emerg Med* 1992;21:1189-1195.
65. Albrecht RM, Kingsley D, Schermer CR, et al. Evaluation of cervical spine in intensive care patients following blunt trauma. *World J Surg* 2001;25:1089-1096.
66. Albrecht RM, Malik S, Kingsley DD, et al. Severity of cervical spine ligamentous injury correlates with mechanism of injury, not with severity of blunt head trauma. *Am Surg* 2003;69:261-265.
67. Davis JW, Phreaner DL, Hoyt DB, et al. The etiology of missed cervical spine injuries. *J Trauma* 1993;34:342-346.
68. Marion DW, Domier R, Dunham CM, et al. Determination of Cervical Spine Stability in Trauma Patients. Available at: http://www.east.org/tpg/chap3u.pdf.
69. Pang D, Wilberger JE Jr. Spinal cord injury without radiographic abnormalities in children. *J Neurosurg* 1982;57:114-129.
70. Pang D, Pollack IF. Spinal cord injury without radiographic abnormality in children—the SCIWORA syndrome. *J Trauma* 1989;29: 654-664.
71. Kriss VM, Kriss TC. SCIWORA (spinal cord injury without radiographic abnormality) in infants and children. *Clin Pediatr* (Phila) 1996;35:119-124.
72. Brown RL, Brunn MA, Garcia VF. Cervical spine injuries in children: A review of 103 patients treated consecutively at a level 1 pediatric trauma center. *J Pediatr Surg* 2001;36:1107-1114.

73. Kokoska ER, Keller MS, Rallo MC, et al. Characteristics of pediatric cervical spine injuries. *J Pediatr Surg* 2001;36:100-105.
74. Gupta SK, Rajeev K, Khosla VK, et al. Spinal cord injury without radiographic abnormality in adults. *Spinal Cord* 1999;37:726-729.
75. Kothari P, Freeman B, Grevitt M, et al. Injury to the spinal cord without radiological abnormality (SCIWORA) in adults. *J Bone Joint Surg* Br 2000;82:1034-1037.
76. Bhatoe HS. Spinal cord injury. *J Neurosurg* 2001;94:339-340.
77. Hendey GW, Wolfson AB, Mower WR, et al. Spinal cord injury without radiographic abnormality: Results of the National Emergency X-Radiography Utilization Study in blunt cervical trauma. *J Trauma* 2002;53:1-4.
78. Bhatoe HS. Cervical spinal cord injury without radiological abnormality in adults. *Neurol India* 2000;48:243-248.
79. Spinal cord injury without radiographic abnormality. *Neurosurgery* 2002;50:S100-104.
80. Cirak B, Ziegfeld S, Knight VM, et al. Spinal injuries in children. *J Pediatr Surg* 2004;39:607-612.
81. Davis PC, Reisner A, Hudgins PA, et al. Spinal injuries in children: Role of MR. *AJNR Am J Neuroradiol* 1993;14:607-617.
82. Grabb PA, Pang D. Magnetic resonance imaging in the evaluation of spinal cord injury without radiographic abnormality in children. *Neurosurgery* 1994;35:406-414.

CE/CME Questions

1. Which of the following statements is true regarding the role of computerized tomography (CT) in evaluating patients for cervical spine injury?
   A. CT of the cervical spine may be able to detect cervical spine injuries not readily apparent on plain radiographs.
   B. CT of the cervical spine should be obtained in all blunt trauma patients to exclude injury.
   C. CT is highly sensitive for the detection of ligamentous injury.
   D. CT imaging of the cervical spine poses a lower radiation risk to patients than plain radiographs.

2. Which of the following statements is true regarding plain radiographs of the cervical spine?
   A. A single lateral view is sufficient to exclude cervical spine injury.
   B. The routine addition of oblique views (five-view series) significantly improves the sensitivity.
   C. The routine addition of flexion-extension views is not indicated unless there is specific concern for ligamentous injury.
   D. The frequency of inadequate or false-positive films decreases with injury severity.

3. Which of the following is *not* an indication for cervical spine MRI as part of the ED evaluation?
   A. Cervical spine fracture or subluxation with neurologic deficit
   B. Suspected Spinal Cord Injury without Radiographic Abnormality (SCIWORA)
   C. Deterioration in neurologic function
   D. Suspicion of cervical spine ligamentous injury
   E. All of the above are indications for MRI.

4. Which of the following statements is true regarding flexion-extension films?
   A. Flexion-extension films are obtained while the clinician actively flexes and extends the neck of the acutely injured patient.
   B. Flexion-extension films may be obtained safely in obtunded or comatose patients.
   C. Flexion-extension films are extremely efficient in completely excluding ligamentous injury in the acutely injured patient.
   D. Flexion-extension films are unlikely to produce neurologic injury when obtained in the alert, cooperative patient.

5. Spinal Cord Injury without Radiographic Abnormality (SCIWORA):
   A. is an entity only found in the pediatric patient.
   B. occurs in adults by the same mechanism as in children.
   C. often presents with profound or progressive paralysis either immediately or within 48 hours.
   D. may be excluded with an initial normal neurologic examination.

6. Which of the following statements is *not* true regarding plain radiographs for a patient with a potential cervical spine injury?
   A. Plain radiographs are inexpensive.
   B. Plain radiographs in the severely injured or unconscious patient are all that is needed to exclude a spinal injury.
   C. Frequently, the cervicocranial area is viewed inadequately on a plain radiograph.
   D. Plain radiographs are repeated in almost 50-70% of severely injured or unconscious patients to obtain an adequate study.

7. Which of the following is an advantage of helical CT vs single acquisition CT?
   A. Faster image acquisition
   B. Faster image reconstruction times
   C. Reduction of image artifacts
   D. Higher quality reformatted and three-dimensional images
   E. All of the above

8. Which of the following statements is true regarding the initial use of CT to evaluate the cervical spine?
   A. High-risk clinical parameters, including a history of loss of consciousness, warrant the initial use of CT scan to evaluate the cervical spine.
   B. High-energy mechanisms, warranting the initial use of CT scan for the evaluation of the cervical spine, include high-speed (> 35 mph) motor vehicle or motorcycle crashes.
   C. High-energy mechanisms, warranting the initial use of CT scan for the evaluation of the cervical spine, include a fall from 8 feet.
   D. High-risk clinical parameters include a history of amnesia for the event following a fall from 6 feet.

9. A 35-year-old male presents to the ED following a motorcycle crash. He is unconscious and has a GCS score of 10. The patient was intubated in the field with appropriate spinal immobilization, which has been maintained. Following stabilization of the patient, which of the following would be the best initial test to evaluate the cervical spine?
   A. Flexion-extension radiographs

B. Oblique plain radiographs of the cervical spine
C. MRI
D. CT scan of the cervical spine

10. A 38-year-old female presents after a fall from a chair. She has a GCS score of 15 and no neurologic deficits. The initial radiographs (lateral, anterioposterior, and open-mouth view) are read by the radiologist as normal. She is complaining of neck pain. The patient has less than 30° of motion in both flexion and extension from the neutral position. The next step should be to:
    A. administer diazepam and actively flex and extend the neck.
    B. obtain a CT scan of the cervical spine.
    C. discharge the patient in a semi-rigid collar with careful instruction and follow-up.
    D. have the physician forcibly assist the patient during flexion-extension radiographs to obtain adequate radiographs.

Answer Key:

1. A	6. B
2. C	7. E
3. E	8. B
4. D	9. D
5. C	10. C

CE/CME Instructions

Physicians and nurses participate in this continuing medical education/continuing education program by reading the article, using the provided references for further research, and studying the questions at the end of the article. Participants should select what they believe to be the correct answers, then refer to the list of correct answers to test their knowledge. To clarify confusion surrounding any questions answered incorrectly, please consult the source material. **After completing this activity, you must complete the evaluation form provided and return it in the reply envelope provided in order to receive a certificate of completion.** When your evaluation is received, a certificate will be mailed to you.

CE/CME Objectives

Upon completing this program, the participants will be able to:

a.) Identify the indications, advantages, and limitations of plain radiography for the evaluation of patients with potential blunt cervical spine injury;
b.) Recognize the indications for the use of CT and MRI of the cervical spine;
c.) Define and translate into clinical practice the appropriate evaluation of a patient with a potential ligamentous injury of the cervical spine; and
d.) Discuss the presentation, diagnosis, and management of a patient with SCIWORA.

In Future Issues: **Knee Injuries**

Trauma Reports
Rapid Reference Guidelines

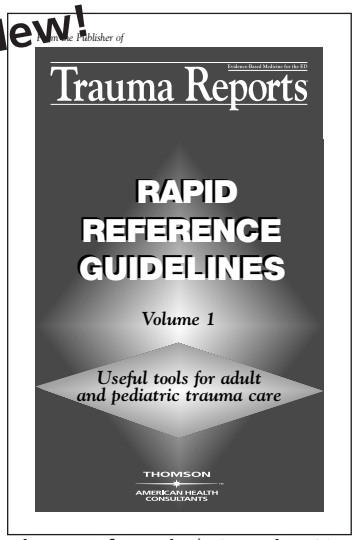

Order now for only $79 Book # S04115

A new resource perfect for heat-of-battle patient care

You face hundreds of trauma patients every week; finding quick and accurate answers to your critical questions shouldn't be another traumatic experience. That's why *Thomson American Health Consultants* offers you this new pocket-sized guide.

"**Trauma Reports: Rapid Reference Guidelines**" gets right to the point. Your job is too hectic for anything else.

You get at-a-glance treatment strategies in a summarized format. Our most popular, and heavily-used "guideline cards" are all pulled together into this single pocket guide. You get proven effective…

- diagnosis and treatment charts
- algorithms
- treatment guidelines

Because the topics covered in this pocket guide cover the situations you encounter every day, the facts are immediately applicable!

You get the added confidence of always having relevant, clinically accurate answers in the pocket of your lab coat.

The caliber of information you expect!

You already know the caliber of information you get from *Thomson American Health Consultants*. Now this newest release gives you the best of the best. With your heavy patient load, you should expect this level of convenience.

Call (800) 688-2421 (+1 404 262-5476 outside the US and Canada). Please refer to code 61192.