THOMSON
AMERICAN HEALTH CONSULTANTS

Enclosed in this issue: CE/CME Evaluation

Evidence-Based M[illegible] ED

Trauma Reports

Vol. 5, No. 6

Supplement to *Emergency Medicine Reports*, *Pediatric Emergency Medicine Reports*, *ED Management*, and *Emergency Medicine Alert*

Nov./Dec. 2004

As an isolated injury or a frequent component in a multiple trauma patient, the knee is one of the most commonly injured joints. Although not usually a life-threatening injury, correct management may significantly affect the quality of life and mobility for a patient following a traumatic event. In addition, failure to make a timely and accurate diagnosis of a vascular injury may have significant detrimental effects for the trauma patient and result in permanent disability.

It is critical that emergency department (ED) physicians use the history of the injury to direct the physical examination and diagnostic testing, as well as provide prompt referral to an orthopedic specialist if the condition requires surgical intervention. The ED physician also must understand the limitations faced in making a definitive diagnosis in the first 24 hours following an acute injury, a critical time period.

The authors present a thorough review of the anatomy, critical features of the physical examination, and indications for further diagnostic testing in a patient who has sustained a traumatic knee injury.

— The Editor

Knee Trauma: Assessment, Diagnostic Evaluation, and Management

Authors: **Howard A. Werman, MD**, Professor of Clinical Emergency Medicine, The Ohio State University College of Medicine and Public Health; Medical Director, MedFlight, Columbus, OH; **Robert E. Paasche, MD,** Emergency Medicine Physician, Emergency Physicians, PC, Benefis Hospital, Great Falls, MT; **M. Jake Ott, III, MD,** Attending Physician, St. Ann's Medical Center, Columbus, OH.

Peer Reviewer: **George L. Foltin, MD, FAAP, FACEP,** Director, Pediatric Emergency Medicine, Bellevue Hospital Center/New York University Medical Center, New York.

Introduction

Traumatic knee injuries are a common reason for presentation to EDs following injury; approximately 1 million knee injuries are treated in EDs in the United States each year.[1,2] In addition to isolated knee injuries, the knee joint is frequently injured in association with other injuries in multiple trauma victims.

Because the knee is a complex joint, it is critical to understand the different patterns of injury that can occur: injuries to bone, ligaments, cartilage, and surrounding soft tissue.

The emergency physician (EP) must develop a rational imaging strategy to identify potential injuries and have a good understanding of the types of injuries to properly care for the patient with knee trauma. Many traumatic knee injuries require orthopedic consultation for operative management, and those injuries must be identified quickly and efficiently to expedite care of the patient.

Finally, there are many pitfalls in the evaluation of the knee, especially the failure to diagnose arterial injury, which makes a thorough understanding of the knee and its surrounding structures essential to the active clinician.

Anatomy of the Knee

An understanding of the anatomy of the knee is imperative to assessing injuries involving this complex joint. The knee is the largest articular joint in the body and consists of a hinge joint formed by the articulation of the femur and the tibia. The femur broadens out at the knee joint into two rounded articular prominences: the medial and lateral condyles. Those prominences articulate with the tibial plateaus on the proximal tibia. Small eminences from the condyles form the medial and lateral epicondyles, which serve as attachment points for the collateral ligaments. The anterior portion between both condyles contains a shallow depression that accommodates the patella.

The patello-femoral articulation is not involved in weight bearing.[2] The proximal tibia also contains medial and lateral condyles, which are flattened surfaces that support weight bearing. These surfaces are referred to as the medial and lateral tibial plateaus. Each plateau has approximately 10° of downward slope away from the center of the tibia. Centrally, the tibial plateau contains two superior projections: the anterior and posterior tibial spine. These projections serve as attachment points for the cruciate ligaments.

Also of interest is the tibial tuberosity, which is located on the anterior surface of the tibia below the knee. This bony prominence serves as the attachment of the quadriceps tendon. The proximal fibula, although not technically part of the knee, is included in this discussion. These structures combine to form the major bony articulations of the knee. (*See Figure 1.*)

The popliteal fossa is a depression found behind the knee joint. Several important structures are located in this recess, including the popliteal artery and vein, as well as the peroneal and tibial nerves. The popliteal artery represents the continuation of the femoral artery into the knee joint. This artery supplies a rich anasthomosis of blood vessels supplying the knee joint and then divides into the anterior and posterior tibial arteries. The artery is relatively fixed within the popliteal fossa, thus, making it prone to injury with any stress on the knee joint.[3,4]

The common peroneal nerve wraps around the proximal fibula. Injury to this nerve may result in a foot drop.[5] Intact dorsiflexion at the ankle must be documented with any significant trauma to the proximal fibula.

The static stability of the knee joint depends on its surrounding ligaments (*See Figure 1*). The anterior cruciate ligament (ACL) prevents anterior displacement of the tibia in relation to the femur. The posterior cruciate ligament (PCL) prevents posterior and rotational displacement. Both the ACL and PCL also contribute to proprioception. The medial collateral ligament (MCL) resists valgus stress, while the lateral collateral ligament (LCL) resists varus stress.

With the knee in full extension, all of the ligaments are taut, ensuring complete stability of the knee joint. The knee must be flexed to 20-40° before the joint is relaxed, and some rotational movement of the joint is possible. The medial and lateral menisci are cartilaginous structures that support the femorotibial articulation and also aid in weight bearing. (*See Figure 2.*) The menisci contribute to joint stability and provide both lubrication and cushioning to the knee. The medial meniscus is attached firmly to the MCL and joint capsule making it more susceptible to injury. Because of the absence of pain fibers, menisci injuries may have a delayed detection or go undetected.

The muscular structures of the knee provide dynamic stability to the joint. The knee extensors (quadriceps group) include the vastus medialis, vastus intermedius, vastus lateralis, and rectus femoris. They combine to form the quadriceps tendon, which inserts into and encompasses the patella. The quadriceps tendon then becomes the patellar tendon and inserts into the tibial tuberosity. The vastus medialis exerts a medial force on the patella, thus, preventing lateral subluxation. The knee flexors (hamstrings group) include the semimembranosus, semitendinosus, and biceps femoris. The knee adductors include the gracilis, sartorius, and a portion of the semitendinosus, combining to form the pes anserinus medially. The iliotibial tract, popliteus muscle, and a portion of the biceps femoris attach laterally.

Trauma Reports™ (ISSN 1531-1082) is published bimonthly by Thomson American Health Consultants, 3525 Piedmont Road, N.E., Six Piedmont Center, Suite 400, Atlanta, GA 30305. Telephone: (800) 688-2421 or (404) 262-7436.

Vice President/Group Publisher: Brenda Mooney
Editorial Group Head: Valerie Loner
Managing Editor: Martha Jo Dendinger
Marketing Manager: Schandale Kornegay

POSTMASTER: Send address changes to ***Trauma Reports***, P.O. Box 740059, Atlanta, GA 30374.

Subscriber Information

Customer Service: 1-800-688-2421

Customer Service E-Mail: customerservice@ahcpub.com
Editorial E-Mail: martha.dendinger@thomson.com

World Wide Web page: http://www.ahcpub.com

FREE to subscribers of *Emergency Medicine Reports, Pediatric Emergency Medicine Reports, Emergency Medicine Alert*, and *ED Management.*

Accreditation

Trauma Reports™ continuing education materials are sponsored and supervised by Thomson American Health Consultants. Thomson American Health Consultants designates this continuing education activity for up to 2.5 hours in Category 1 credit toward the AMA Physician's Recognition Award. Each physician should claim only those hours of credit that he/she actually spent in the educational activity. This CME activity was planned and produced in accordance with the ACCME Essentials. Approved by the American College of Emergency Physicians for 2.5 hours of CEP Category 1 credit.

Thomson American Health Consultants (AHC) is accredited by the Accreditation Council for Continuing Medical Education (ACCME) to provide continuing medical education for physicians.

Trauma Reports® is approved for approximately 2.5 nursing contact hours. This offering is sponsored by Thomson American Health Consultants, which is accredited as a provider of continuing education in nursing by the American Nurses' Credentialing Center's Commission on Accreditation. Provider approved by the California Board of Registered Nursing, Provider Number CEP 10864, for approximately 2.5 contact hours. This program (#0105-1) has been approved by an AACN Certification Corp.-approved provider (#10852) under established AACN Certification Corp. guidelines for 2.5 contact hours, CERP Category A.

This is an educational publication designed to present scientific information and opinion to health professionals, to stimulate thought, and further investigation. It does not provide advice regarding medical diagnosis or treatment for any individual case. It is not intended for use by the layman. Opinions expressed are not necessarily those of this publication. Mention of products or services does not constitute endorsement. Clinical, legal, tax, and other comments are offered for general guidance only; professional counsel should be sought for specific situations.

This CME/CE activity is intended for emergency, family, osteopathic, trauma, surgical, and general practice physicians and nurses who have contact with trauma patients.

It is in effect for 36 months from the date of publication.

THOMSON AMERICAN HEALTH CONSULTANTS™

For Customer Service,

Please call our customer service department at **(800) 688-2421.** For editorial questions or comments, please contact **Martha Jo Dendinger**, Managing Editor, at martha.dendinger@thomson.com.

Conflict of Interest Disclosure

In order to reveal any potential bias in this publication, and in accordance with Accreditation Council for Continuing Medical Education guidelines, Dr. Dietrich (editor in chief), and editorial board members Bowman, Diebel, Falcone, Finerty Hanlon, Jones, Mahadevan, Perkin, Santanello, Savitsky, and Stafford report no relationships with companies related to the field of study covered by this CME program. Drs. Werman, Paasche, and Ott (authors) and Foltin (peer reviewer) report no relationships with companies related to the field of study covered by this CME program.

Figure 1. Knee Bony Anatomy

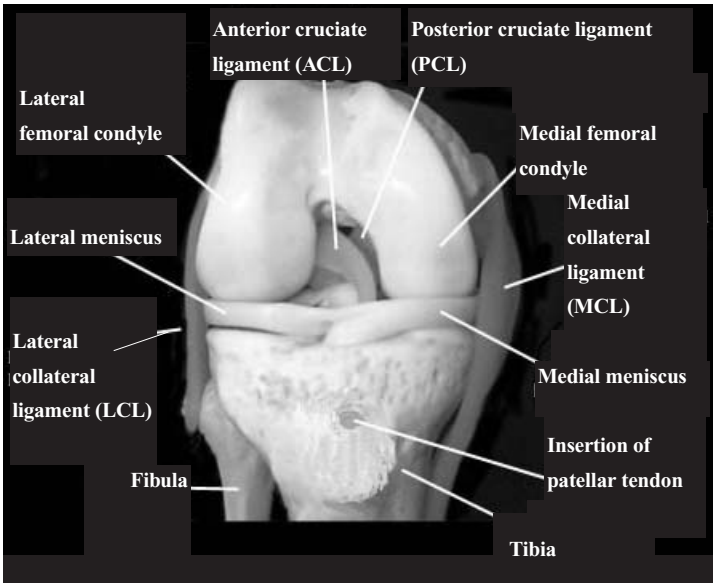

The bony anatomy of the knee consists of the articulation of the femur and the tibia, which meet to form a hinge joint. The joint is protected in front by the patella. The joint is cushioned by articular cartilage that is located at the ends of the tibia, femur, and under the patella. The lateral and medial meniscus are cartilaginous and further cushion the joint.

Reprinted with permission from: The Nicholas Institute of Sports Medicine and Athletic Trauma. Available at: www.nis-mat.org.

Figure 2. Knee Ligamentous Anatomy

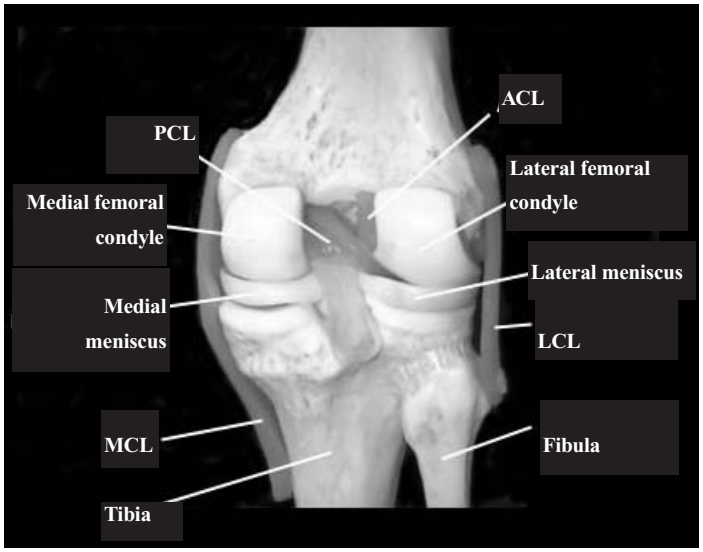

The ligaments of the knee are designed to stabilize the knee. The collateral ligaments are located along the sides of the knee and limit lateral motion. The ACL is located at the center of the knee and connects the tibia to the femur. The ACL functions to limit rotation and forward motion of the tibia. The PCL limits backward motion of the tibia. The MCL restricts valgus stress, and the LCL resists varus stress.

Reprinted with permission from: The Nicholas Institute of Sports Medicine and Athletic Trauma. Available at www.nis-mat.org.

History and Physical Examination

A thorough history regarding the mechanism of injury is crucial to identification of the particular pattern of knee injury. For example, an anterior force applied to the tibia with the foot planted typically results in an ACL injury; the PCL frequently is damaged by a posterior force under the same conditions.[6,7]

It should be noted, however, that an accurate history of the injury may be absent in patients with multiple trauma; therefore, a careful examination of the knee is imperative and correlation with historical information appropriate in all patients. Information obtained should include the direction of the force that caused the injury and the weight-bearing status of the patient at the time of impact. The knee is commonly subjected to compression, distraction, flexion, extension, rotation, valgus or varus stress, and sliding forces.

Additional information, including the position of the patient in an automobile (e.g., driver, front-seat or rear-seat passenger), anticipated impact, and damage to the dashboard, may be particularly important in association with motor vehicle trauma. The location of pain and the presence of a pop or snap (noted in up to 90% of cases associated with ACL rupture at the time of injury) are also very important.[8-10]

Patients with ACL or PCL injuries also may complain of the knee "giving out," especially with pivoting. Complaints of knee locking may indicate a torn meniscus, a loose body, rupture of the ACL or PCL, or an osteochondral fracture.[11-12]

An osteochondral fracture occurs when a portion of the articular surface, including both lining cartilage and underlying bone, becomes separated from either the femur or tibia. The time of injury and the amount of swelling or effusion that has developed can be helpful in distinguishing the injured structure. The cruciate ligaments are well vascularized, and a tear can produce a large effusion within a couple of hours.[8,9,13,14] Acute hemarthroses is a sign of intra-articular injury, with a high percentage of these injuries involving ACL tears. Osteochondral fractures also can produce large effusions quickly and account for as many as 67% of traumatic hemarthroses in children without apparent fracture on x-ray.[15] A smaller effusion that collects during a longer period of time is more indicative of a partial ligament tear or meniscal injury.

A detailed examination of the knee in flexion and extension can provide very specific information about the type of injury involved. The initial evaluation should include assessment of deformity, swelling, effusion, tenderness, and open wounds. It is also helpful to compare any findings to the uninjured knee. Location of tenderness on examination corresponds with the site of injury identified surgically in up to 76% of cases.[10] As noted above, the presence of a large effusion that is noted within 1-2

Figure. 3 The Lachman Test

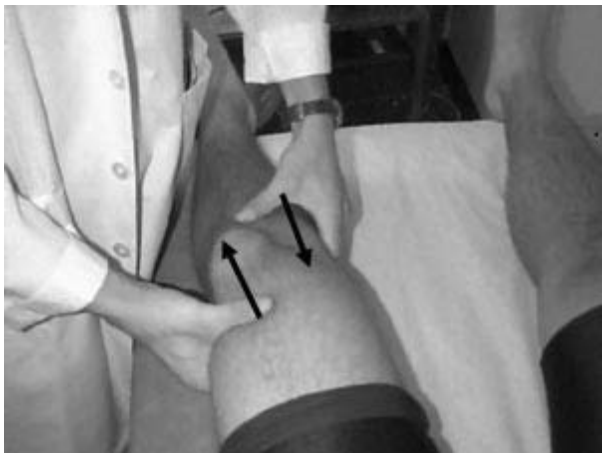

The Lachman's test is more sensitive than the anterior drawer test for ACL rupture. As illustrated above, the knee should be flexed 20-30°. One hand should hold the distal femur. With the other hand, apply anterior force to the proximal tibia. If an end-point is not appreciated or significant movement of the anterior tibia occurs, the test is considered positive.

Reprinted with permission from The Nicholas Institute of Sports Medicine and Athletic Trauma. Available at www.nismat.org.

Figure 4. The McMurray Test

The examiner flexes the knee beyond 90° with the foot externally rotated in the examiner's hand. The other hand palpates the medial joint line as the knee is extended gradually beyond 90°. A medial meniscus injury is indicated by pain, a popping sensation, or crepitus.

Reprinted with permission from The Nicholas Institute of Sports Medicine and Athletic Trauma. Available at www.nismat.org.

hours of injury is highly suggestive of cruciate ligament rupture or an osteochondral fracture. A full popliteal fossa may be seen with popliteal artery disruption, suggesting that the knee may have been dislocated, that a bicruciate ligament rupture may be present, or that both injuries have occurred simultaneously.

It is extremely important to remember that a reliable examination may not be possible within the first few hours of injury, and the patient may need to have a repeat exam in 24-48 hours when the pain and swelling have subsided. In the multiply injured patient, other priorities may limit the initial examination of the knee and associated structures. Following stabilization, a complete and directed physical examination will reveal likely injury patterns.[16]

Valgus and varus stress should be applied to the knee in 20-30°of flexion and in full extension. This action will help to identify MCL and LCL injuries. Examination of the knee in slight flexion allows for relaxation of the major muscle groups that provide support to the knee and isolates the supporting ligamentous structures of the knee joint.

Anterior and posterior drawer tests should be performed with the hip flexed at 45°, the knee flexed at 90°, and the foot secured in a neutral position on the exam table. Anterior force should be applied to the proximal tibia to assess for ACL integrity and posterior force applied to assess for PCL integrity. The same examinations also should be repeated with the foot secured in internal and external rotation.[2] The tibia should be limited by a discrete end-point in the anterior and posterior directions. Any sliding forward or backward suggests an ACL or PCL injury.

Lachman's test is more sensitive for ACL rupture (up to 99% sensitivity vs 77% for the anterior drawer test).[17] Hold the distal femur with one hand, and apply anterior force to the proximal tibia with the other hand while the knee is flexed 20-30° (*See Figure 3.*). Here again, a discrete end-point should be appreciated. A lack of a discrete end-point or significant anterior movement of the tibia is indicative of a positive test.

The Lateral Pivot Shift test is performed with the knee in full extension. The leg is lifted by the distal tibia, which will produce subluxation of the proximal tibia with ACL disruption. The knee is flexed carefully to 20-40°, while a mild valgus force is applied to the knee, and the foot is moved laterally. A thud can be appreciated as the tibia subluxes against the femur with this motion.

Meniscal injuries are detected using the McMurray's test, Apley compression test, or medial-lateral grind test.[18] The McMurray test involves flexion of the knee beyond 90° with the foot externally rotated in the examiner's hand. (*See Figure 4.*) The other hand palpates the medial joint line as the knee is extended gradually beyond 90°. Pain, a popping sensation, or crepitus indicates a medial meniscus injury. Repeat the test with the foot internally rotated while the lateral joint line is palpated. Pain and crepitus with flexion indicate lateral meniscus injury. The McMurray's test alone has been shown to have a low sensitivity and specificity for detecting medial meniscus injuries. [19,20]

Apley's compression test is performed with the patient in a prone position, and the knee flexed to 90°. Pain with rotation of

Figure 5. Intercondylar Femoral Fracture

This patient sustained an intercondylar femur fracture. Because a large amount of force is necessary to produce this injury, the patient should be assessed carefully for other injuries. In addition, the close proximity of the popiteal artery and vein to the distal femur should alert the clinicial to the possibility of vascular injury.

Image courtesy of Howard Werman, MD.

Figure 6. Tibial Plateau Fracture

This patient sustained a tibial plateau fracture. Meniscal and ligamentous injuries commonly accompany these fractures.

Image courtesy of Howard Werman, MD.

the foot while upward traction is applied suggests damage to the capsule and/or ligaments. Pain with rotation of the foot while downward traction is applied indicates meniscal injury.

The medial-lateral grind test is performed in the supine patient by cradling the calf in one hand and palpating the medial and lateral joint lines with the other. Valgus and varus stress is applied to the joint. Any crepitus felt along the joint line indicates possible meniscal injury.

Bragard's sign is tenderness along the anterior medial joint line upon internal rotation and extension of the tibia and indicates a likely medial meniscus injury.

Payr's sign is pain with pressure applied to the medial aspect of the knee with the patient sitting cross-legged. The knees should be flexed at 90°. This finding is also consistent with medial meniscus injury.

First Steinmann's sign is either pain in the anterolateral joint space with internal rotation and flexion of the knee, which is consistent with a lateral meniscus tear, or pain in the anteromedial joint space with external rotation and flexion of the knee, which suggests a medial meniscus tear.

Secondary Steinmann's sign helps to distinguish a meniscal injury from an LCL or MCL disruption. It involves a shifting location of tenderness from the region of the collateral ligament when the knee is flexed to the anterior aspect of the knee when fully extended.

In addition, a thorough evaluation of the neurovascular status of the knee should be done, focusing on the presence or absence of pulses in the posterior tibial, dorsalis pedis, and popliteal arteries, as well as the sensory function of the various nerves supplying the area below the knee.

Injury to the Bony Structures of the Knee

Bony injuries to the knee can involve the distal femur, proximal tibia and fibula, patella, or dislocation of the knee. The management of these various injuries differs based on the mechanism and location of injury.

Femoral Fractures. Fractures of the distal femur are rare injuries [1,21,22] and are grouped into four different categories: Class A, supracondylar fractures; Class B, intercondylar fractures; Class C, condylar fractures; and Class D, epiphyseal fractures *(See Figure 5.*)

All femoral fractures present with knee pain or hip pain, inability to bear weight, and tenderness over the distal femur. These fractures usually occur as the result of a direct blow to the distal femur, such as from a dashboard or steering wheel. A large amount of force is required to produce a femoral fracture and

consequently, these fractures often are associated with other injuries. Additionally, because of the muscular attachments of the quadriceps group, the hamstring muscles and both the gastrocnemius and soleus muscles, displacement of the fracture fragments is common. Remember that the popliteal artery and vein are in close proximity to the distal femur and are prone to injury with such fractures.

Supracondylar Fractures. By definition, these fractures occur above the femoral condyles and do not involve the knee joint. As a result, effusions are not associated with this type of injury. Five percent to 10% of these fractures are open fractures.[23] All of the other fractures mentioned above have an intra-articular component. Epiphyseal fractures usually occur in children older than 10 years. Because bone growth around the knee joint accounts for almost two-thirds of adult leg length, these injuries commonly are associated with leg shortening, and all Salter-Harris fractures of the knee joint should have urgent orthopedic evaluation.[10,21,22]

Distal femur fractures all require urgent orthopedic consultation and can be treated with immobilization, traction, or operative fixation at the discretion of the consulting orthopedic specialist. Skeletal traction often is the preferred method by orthopedic surgeons once the patient is admitted; however, a hare traction splint can be used to immobilize the fracture in the ED until the skeletal pins can be placed. Significant pain control often is required; traction on the femur is extremely painful.[2] Commonly associated injuries include ipsilateral hip fractures, popliteal vascular injuries, peroneal nerve injury, and damage to the quadriceps or hamstring groups.

Tibial Fractures. Tibial fractures are divided into four classes: Class A, condylar fractures; Class B, spine fractures; Class C, tuberosity fractures; and Class D, subcondylar fractures.

Tibial fractures typically occur in one of two ways: 1) a direct blow to the tibia (bumper injury); or 2) axial compression of the tibia, which occurs when the knee is forcibly extended in anticipation of a frontal impact.

Class A injuries (condylar and plateau fractures) usually are produced by axial loading (e.g., a fall from a height). (*See Figure 6.*) The rotational stress on the knee will determine whether the medial or lateral tibial plateau is affected.[24] The lateral plateau is the site of fracture in the majority of cases.[1] Meniscal and ligamentous injuries commonly accompany these fractures; the menisci and medial and lateral collateral ligaments are related closely to and attached to the tibial plateaus.[25] A plateau fracture without depression of the articular surface can be treated by a long leg cast. Any depression or irregularity of the articular surfaces requires immediate orthopedic consultation and surgical repair. ACL and MCL tears are associated with lateral plateau fractures; PCL and LCL tears are associated with medial plateau fractures. Lateral plateau injuries are more common and usually are due to involvement of the tibial spine.[25]

Class B injuries (spine fractures) are rare but present similar to ACL and PCL tears, depending upon which spine is fractured. The mechanism of injury typically involves an anterior or posterior force to the proximal tibia with the knee in flexion. Anterior spine fractures are 10 times more common than posterior spine fractures and are associated with ACL injuries.[25] Complete spine avulsion requires urgent orthopedic consultation and surgical repair, while incomplete fractures can be treated by a knee immobilizer and orthopedic follow-up.

Class C injuries (tuberosity fractures) involve the attachment of the quadriceps tendon, and present with pain over the anterior tibia with signs similar to either partial or complete quadriceps tendon rupture (difficulty or inability to perform a straight leg raise). These fractures can occur as the result of a shearing force or more commonly, due to forced flexion of the knee, creating stress on the quadriceps tendon. Partial avulsions can be treated by immobilization and orthopedic follow-up; complete avulsions require operative fixation. Clinically, this type of injury is indistinguishable from quadriceps tendon rupture, but plain x-rays

Figure 7. Patellar Fracture

This radiograph demonstrates a patellar fracture. Patellar fractures typically occur secondary to direct knee trauma. Non-displaced patellar fractures may be managed with a knee immobilizer and pain control.

Image courtesy of Howard Werman, MD.

Figure 8. Angiogram of Popliteal Artery Showing Intimal Tear

Injury to the popiliteal artery is common in patients with knee dislocations. These injuries require early recognition and, optimally, a repair within 6-8 hours of the injury. Intact pulses in the foot do not exclude vascular injury.

Image courtesy of Howard Werman, MD.

will show the avulsed segment of the tibial spine attached to the end of the quadriceps tendon.

Class D injuries (subcondylar fractures) can be treated with immobilization and do not require urgent orthopedic consultation unless there is comminution of the fragments or associated injuries. Like supracondylar patellar fractures, these injuries do not involve the joint space.

Proximal Fibular Fractures. These fractures are typically noted as the result of a direct blow to the area or a valgus stress on the knee joint. The latter mechanism typically produces lateral collateral ligament injury and peroneal nerve injury.[1] Isolated proximal fibular fractures can be treated symptomatically with a knee immobilizer and analgesics. A variant of the proximal fibular fracture, the Maisonneuve's fracture, involves a distal tibial fracture or ligamentous disruption, resulting in instability of the ankle. Thus, the ankle joint should be assessed carefully if a proximal fibular fracture is present, and x-rays should be obtained if the ankle is tender.

Patellar Fractures. Patellar fractures typically are caused by direct knee trauma (e.g., a knee striking a dashboard), and are divided into several classes: non-displaced, transverse, pole fractures, comminuted (non-displaced or displaced), vertical, or osteochondral. High impact injuries are associated with hip fractures and dislocations. A secondary mechanism may involve an avulsion caused by the pull of the quadriceps mechanism. Patellar fractures are more common in males.

A non-displaced fracture can be treated with a knee immobilizer and pain control. If the quadriceps mechanism is intact (See Figure 7), the patient can bear weight as well. Fractures associated with disruption of the extensor mechanism or displacement more than 3 mm requires operative repair in an urgent manner.

Remember that anatomical variants of the patella can include a bipartite and tripartite patella. With a bipartite patella, a secondary ossification center typically is noted in the upper outer portion of the patella, which may be confused with a fracture. Because these variants tend to be bilateral, a comparison view of the uninjured patella should be obtained.

Patellar Dislocation

Patellar dislocations typically occur when the patient twists on an extended knee. Rarely, dislocation can occur as the result of a lateral or medial blow to the patella. The condition is more common in women.[26] Many patients (10–50%) will have recurrent episodes during their lifetimes. The patella almost always dislocates laterally (80%).[26] Sometimes this injury is associated with medial joint capsule injury.

Patellar dislocation is very painful, and the patient often presents with a fixed, partially flexed knee with obvious displacement of the kneecap. The reduction can be performed in one of two manners.

Passive Hyperextension of the Knee. This is a painful procedure and often requires pain control and sedation. The lower leg is grasped in one hand, the upper leg in the other, and the knee is straightened passively. The patella then is moved back into place by hand, forcing the patella medially.

Active Hyperextension of the Knee. The patient can be asked to straighten the knee (e.g., to touch the bed with the back of his knee while standing or lying). A cooperative patient can perform this maneuver, and reduction causes immediate cessation of pain.

Whichever method is chosen, plain knee radiographs should be obtained following successful reduction to identify any associated patellar fractures or osteochondral injuries, which are seen in up to 5% of cases.[1,26] Additionally, a thorough knee examination should be performed once the patella is in anatomic alignment; up to 12% of patients with a patellar dislocation have an associated ligamentous or meniscal injury.[1,26] Knee immobiliza-

tion should be used to prevent recurrent dislocation, and follow-up within one to two weeks is indicated. If recurrent dislocation occurs, operative fixation may be needed.

Knee Dislocation

Knee dislocation is the result of a significant force delivered to the knee and occurs as the result of hyperextension, posterior forces to the tibia, or significant rotary forces.[27] One example is a bumper impact by a motor vehicle against a planted lower extremity. Any knee dislocation is associated with significant ligamentous disruption.[5] There are three types of dislocation of the knee: anterior, posterior, and lateral. In anterior dislocations (the most common type), the tibia is displaced anteriorly to the femur and typically is the result of hyperextension of the knee joint. In posterior dislocations, the tibia is forced posteriorly by a direct force applied to the proximal tibia. Lateral dislocations can be medial or lateral, and occur with equal frequency. Lateral dislocations can be complicated further with rotary deformity of the knee as well. Any type of knee dislocation carries a 20% incidence of open joint injury[5] and classically presents with a deformed knee and severe pain. Pulses in the foot must be assessed immediately and may be present or absent. Reduction of all three types of dislocations requires longitudinal traction. Sedation and pain relief commonly are required.[1,5] Post-reduction radiographs should be obtained to assess for concomitant fractures, which can include tibial and patellar fractures, as well as fibular head fractures. A thorough neurovascular examination must be conducted following successful reduction to determine if there is injury to the peroneal and tibial nerves. One additional injury pattern is worthy of mention—proximal tibiofibular dislocations or subluxations—rare injuries that are seen after a significant fall. Peroneal nerve injuries commonly are associated with this type of dislocation.

Injury to the popliteal artery is common in knee dislocations (up to 40% of all dislocations).[3,28] (*See Figure 8.)* It is critical that such injuries be identified early and repaired within 6-8 hours of injury.[28] Intact pulses in the foot do not exclude the possibility of arterial injury. An arteriogram should be performed on these patients according to most experts, although an alternative strategy of admission and repeated clinical examination after normal ankle brachial indices (ABI) in the ED has been suggested.[5] An ABI is performed by obtaining a blood pressure in the arm, by standard technique, then taking a blood pressure at the ankle. Dividing the ankle pressure by the arm pressure determines the ABI. Ankle pressure should be greater than brachial pressure. Thus, a ratio of one or greater is considered normal. An ABI of 0.9 or less is concern for possible arterial injury. Patients who have peripheral arterial disease also will have an ABI of less than 0.9, possibly leading to a false positive result. Whichever strategy is used, knee immobilization and urgent orthopedic consult is required.

Treatment of Bony Knee Injuries

Many bony knee injuries can be treated by casting; immobilization of the joint above and below the injury is critical for optimal healing. For tibial and fibular fractures, it can be accomplished either with a long leg cast or through the combined use of a short leg cast and a knee immobilizer. When properly applied, the knee immobilizer will combine effectively with the cast to immobilize both the knee and ankle. This technique can be used for a variety of knee fractures. Some fractures, however, require surgical repair and should have urgent orthopedic consultation.

Figure 9. Knee Ligamentous Injury

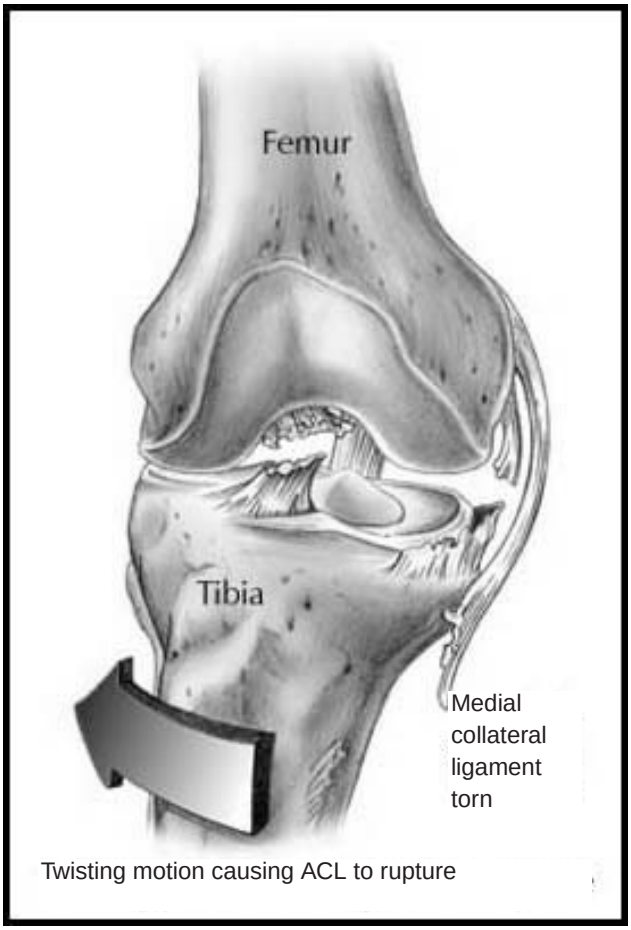

Sprains involve injury to the ligamentous structures of the knee. They vary in severity from a Grade 1 sprain (a small incomplete with no instabiity of the knee) to a Grade 3 sprain (a complete ligamentous disruption with complete joint instabilty).

Reprinted with permission from Hughston Sports Medicine Foundation.

Injury of the Supporting Structures of the Knee

Sprains involve injury to the ligaments of the knee. A Grade 1 sprain corresponds with a small incomplete tear and involves local tenderness with minimal swelling, no instability of the knee, and little increased pain with stress applied to the knee. A Grade 2 sprain corresponds with a moderate incomplete tear and involves local tenderness with moderate swelling, and some joint instability with a firm end-point on stress. A Grade 3 sprain cor-

Table 1. Ottawa Knee Rules

Plain radiographs are indicated if the patient has any one of the following conditions:

- Age 55 years or older
- Tenderness at head of fibula
- Isolated tenderness of the patella (no bone tenderness of knee other than patella)
- Inability to flex to 90°
- Inability to bear weight for four steps both in the ED and immediately after injury

Adapted from: Bachman LM, et al. The accuracy of the Ottawa knee rule to rule out knee fractures: A systematic review. *Ann Intern Med* 2004;140:121-124.

responds with a complete ligamentous disruption and involves local tenderness, swelling that can be minimal or marked, and significant joint instability with no clear end point.[29] (*See Figure 9.*)

Partial ligament tears typically are more painful and can produce significantly more swelling than complete disruptions. The MCL is the most commonly injured knee ligament. (*See Figure 9.)* The mechanism usually involves a strong lateral force applied to a slightly flexed knee. This type of injury also can produce ACL disruption and tearing of the medical meniscus. Isolated Grade 1 or Grade 2 sprains can be treated with immobilization, compression, rest, ice, elevation, and non-steroidal anti-inflammatory medications with orthopedic or primary care follow-up within a few days. Grade 3 injuries can be treated similarly with prompt orthopedic referral (within 24 hours).

The medial and lateral menisci also are commonly injured structures within the knee. They are not innervated, but injury may produce pain because of irritation from injury to adjacent ligaments. These structures are relatively avascular with their blood supply coming from peripheral capillaries. This poor blood supply results in slower accumulation of joint effusions associated with meniscal injury. The medial meniscus is fixed more securely and is more commonly injured. Acute meniscal tears are usually longitudinal and located peripherally.[14] If it extends along the entire length of the meniscus, it is considered a bucket-handle tear. Traumatic ruptures are rare before age 10 years. They typically produce a triad of symptoms including joint line pain, swelling, and locking of the knee. The patient also may complain of the knee "giving out." Treatment is the same as for a grade 1 or 2 sprain.

Knee trauma also can produce disruption or injury to the many tendinous insertions about the knee. Disruption of the quadriceps mechanism can occur in a number of possible locations. Such injuries commonly occur as the result of forced flexion of the knee with the quadriceps muscle contracted.[30] Rupture of the quadriceps tendon superior to the patella is more frequent in the elderly population, while patellar tendon ruptures inferior to the patella are more common in young athletes.[30] The extensor tendon mechanism also can be disrupted with a complete transverse fracture of the patella and with avulsion of the tibial tubercle. Split and referral for orthopedic repair of the injury is recommended. Repeated, low-grade stress to the patella tendon may produce tendonitis or jumper's knee.[31,32]

Radiography

Plain radiography can be very helpful in the diagnosis of fracture, dislocation, and effusion about the knee after trauma; however, it reveals little useful information about ligamentous, meniscal, or tendon injuries.[9,33-35] Standard views include a true anterior-posterior and lateral view of the knee along with one or two oblique views of the knee. Additional views may include a sunrise view of the knee, which is specifically used to identify patellar injuries.[1] In this projection, the knee is flexed, and the beam is directed tangentially to the longitudinal axis of the patella.

Historically, x-rays of the knee have been overused, and several clinical decision rules have been proposed to assist the examiner in determining which patients do not require imaging. The most widely accepted are the Ottawa Knee Rules,[36] which state that plain films of the knee are indicated if the patient is: 1) 55 years of age or older; 2) has tenderness at the head of the fibula; 3) has isolated tenderness of the patella; 4) is unable to flex the knee to 90°; or 5) is unable to bear weight for four steps both in the ED and immediately after the injury. (*See Table 1.*) These rules have helped decrease radiography rates, decrease cost to the patient, and decrease the length of stay in the ED without decreasing the rate of identifying clinically significant fractures of the knee.[15,36]

Computerized tomography (CT) scanning of the knee occasionally is used by the orthopedic consultants to delineate further the anatomy of a fracture, but it has a limited role in the ED evaluation of the acutely injured knee.[37] Magnetic resonance imaging (MRI) is useful in the outpatient setting for evaluating the soft-tissue structures about the knee when the specific injury is in question, but usually is not necessary as part of the emergency assessment.[9,33] When the type of injury is readily apparent from history and physical examination, the patient often will undergo arthroscopy without having an MRI.

Other Diagnostic Studies

Saline Arthrogram. When concerned about the possibility of a penetrating joint injury (e.g., a laceration that overlies the joint space), a saline arthrogram can be used safely to exclude communication with the joint. Proper performance of a saline arthrogram can help identify otherwise occult, open joint injuries.[38]

To perform a saline arthrogram, the knee is prepped and draped in a sterile fashion, with the knee in a 30° flexion. Lidocaine 1% with or without epinephrine can be used as local anesthesia. A superior medial or lateral approach should be used similar to an arthrocentesis. The choice of approach is based upon avoiding the suspected area of penetration. Using the margin of the patella as a landmark, the clinician inserts an 18-gauge needle attached to a syringe containing sterile saline into the knee joint under negative pressure. Once placement is confirmed by aspiration of synovial fluid, 20-30 mL of saline is instilled into

the joint space, while the laceration or other skin injury is observed. Leakage of saline from the laceration confirms that there is communication with the joint space. Open joint injuries require emergent orthopedic consultation, and usually operative debridement and irrigation.

After finishing the procedure, be sure to remove all injected saline from the joint; the extra fluid may be quite uncomfortable for the patient.

Angiography. Angiography is a critical imaging modality used with suspected anterior dislocations, posterior dislocations, or bicruciate ruptures. Popliteal artery injury occurs in association with these injuries in 30-40% of cases.[3,28] The prognosis is good when arterial injury is identified and repaired within 8 hours of injury. When the diagnosis is delayed, up to 86% of patients with popliteal artery injury require amputation, and 66% of those remaining have permanent ischemic changes of the leg and foot.[16,21] If distal pulses are absent with this type of injury post-reduction, immediate surgical exploration is necessary.

Pitfalls

Several potential pitfalls exist in the evaluation of patients with knee injuries, including: 1) not getting a complete history regarding the mechanism of injury; 2) failure to have the knee re-examined in 24-48 hours when pain and swelling have decreased; 3) failure to examine the knee in flexion and extension; and 4) failure to consider popliteal artery injury in the face of significant knee injury, especially in the case of dislocations, and address this condition with either angiography or immediate surgical exploration.

Summary

Patients frequently present in the ED with trauma to the knee. It is critical for the ED physician to be familiar with the anatomy of the knee, trauma associated with certain mechanisms of injury, and appropriate diagnostic testing that is indicated based on the history and a thorough physical examination. Limitations of the initial examination should be recognized, as well as the more subtle findings of potential vascular compromise. Appropriate diagnostic testing should be performed and orthopedic consultation and follow-up obtained when indicated.

References

1. Marx J, Hockberger R, Walls R, eds. *Rosen's Emergency Medicine: Concepts and Clinical Practice*. New York: Mosby; 2002:674-705.
2. Tintinalli JE, Kelen GD, Stapczynski JS, et al, eds. *Emergency Medicine: A Comprehensive Study Guide.* New York: McGraw Hill; 2000:1814-1822.
3. Seybold EA, Busconi BD. Traumatic popliteal artery thrombosis and compartment syndrome of the leg following blunt trauma to the knee: A discussion of treatment and complications. *J Orthop Trauma* 1996;10:138-141.
4. Fadale PD, Noerdlinger MA. Sports injuries of the knee. *Curr Opin Rheumatol* 1999;11:144-150.
5. Schenck RC Jr, Hunter RE, Ostrum RF, et al. Knee dislocations. *Instr Course Lect* 1999;48:515-522.
6. Harner CD, Hoher J. Evaluation and treatment of posterior cruciate ligament injuries. *Am J Sports Med* 1998;26:471-482.
7. Duri ZA, Aichroth P M, Zorrilla P. The posterior cruciate ligament: A review. *Am J Knee Surg* 1997;10:149-165.
8. Mallory N, Kelsberg G, Ketchell D. Does a knee brace decrease recurrent ACL injuries? *J Fam Pract* 2003;52: 803-804.
9. Ho CP, Marks PH, Steadman JR. MR imaging of knee anterior cruciate ligament and associated injuries in skiers. *Magn Reson Imaging Clin N Am* 1999;7:117-130.
10. Smith BW, Green GA. Acute knee injuries: Part II. Diagnosis and management. *Am Fam Physician* 1995;51:799-806.
11. Oeppen RS, Connolly SA, Bencardino JT, et al. Acute injury of the articular cartilage and subchondral bone: A common but unrecognized lesion in the immature knee. *AJR Am J Roentgenol* 2004; 182:111-117.
12. Fritz RC. MR imaging of meniscal and cruciate ligament injuries. *Magn Reson Imaging Clin N Am* 2003;11: 283-293.
13. Miller MD, Bergfeld JA, Fowler PJ, et al. The posterior cruciate ligament injured knee: Principles of evaluation and treatment. *Instr Course Lect* 1999;48:199-207.
14. Swenson TM, Harner CD. Knee ligament and meniscal injuries. Current concepts. *Orthop Clin North Am* 1995;26:529-546.
15. Shearman CM, el-Khoury GY. Pitfalls in the radiologic evaluation of extremity trauma: Part II. The lower extremity. *Am Fam Physician* 1998;57:1314-1322.
16. Solomon DR, Simel DL, Bates DW, et al. Does this patient have a torn meniscus or ligament of the knee. *JAMA* 2003;286:1610-1620.
17. Honari DB, Young CC, Boynton MD, et al. Diagnosis and treatment of common knee injuries in athletes. *Wis Med J* 1996;95:361-366.
18. Muellner T, Nikolic A, Vecsei V. Recommendations for the diagnosis of traumatic meniscal injuries in athletes. *Sports Med* 1999;27: 337-345.
19. Anderson AF, Lipscomb AB. Clinical diagnosis of meniscal tears. Description of a new manipulative test. *Am J Sports Med* 1986; 14:291-293.
20. Noble J, Erat K. In defense of the meniscus: A prospective study of 200 meniscectomy patients. *J Bone Joint Surg Br* 1980;62:7-11.
21. Zionts LE. Fractures around the knee in children. *J Am Acad Orthop Surg* 2002;10:345-355.
22. Stover M. Distal femoral fractures: Current treatment, results and problems. *Injury* 2001;32: SC3-13.
23. Iobst CA, Stanitski CL. Acute knee injuries. *Clin Sports Med* 2000;19:621-635.
24. Dirschl DR, Dahners LE. Current treatment of tibial plateau fractures. *J South Orthop Assoc* 1997;6:54-61.
25. Ruth JT. Fractures of the tibial plateau. *Am J Knee Surg* 2001;14: 125-128.
26. Garner JP, Pike JM, George CD. Intra-articular dislocation of the patella: Two cases and literature review. *J Trauma* 1999;47:780-783.
27. Ghalambor N, Vangsness CT Jr. Traumatic dislocation of the knee: A review of the literature. *Bull Hosp Jt Dis* 1995;54:19-24.
28. Tominaga GT, Connolly JE, Wilson SE. Bilateral popliteal artery injury from bumper crush injury. *J Trauma* 1996;40:311-313.
29. Perryman JR, Hershman EB. The acute management of soft tissue injuries of the knee. *Orthop Clin North Am* 2002;33:575-585.

30. Ilan DI, Tejwani N, Keschner M, et al. Quadriceps tendon rupture. *J Am Acad Orthop Surg* 2003;11:192-200.
31. Warden SJ, Brukner P. Patellar tendinopathy. *Clin Sports Med* 2003; 22:743-759.
32. Fredberg U, Bolvig L. Jumper's knee. Review of the literature. *Scand J Med Sci Sports*1999;9:66-73.
33. Laughlin WJ Jr. Clinically appropriate, cost-effective MR scan of the acute knee injury. *J La State Med Soc* 1998;150: 308-311.
34. Tandeter HB, Shvartzman P. Acute knee injuries: Use of decision rules for selective radiograph ordering. *Am Fam Physician* 1999; 60:2599-2608.
35. Gray SD, Kaplan PA, Dussault R G. Imaging of the knee. Current status. *Orthop Clin North Am* 1997;28:643-658.
36. Bachmann LM, Haberzeth S, Steurer J, et al. The accuracy of the Ottawa knee rule to rule out knee fractures: A systematic review. *Ann Intern Med* 2004;140:121-124.
37. Bharam S, Vrahas MS, Fu FH. Knee fractures in the athlete. *Orthop Clin North Am* 2002;33:565-574.
38. Coumas JM, Palmer WE. Knee arthrography. Evolution and current status. *Radiol Clin North Am* 1998;36:703-728.

CE/CME Questions

1. Which of the following statements regarding the popliteal fossa is *not* true?
   A. The popliteal fossa is a depression found behind the knee joint.
   B. The popliteal artery represents the continuation of the femoral artery into the knee joint and is located in this recess.
   C. The artery is not fixed within the fossa, which protects it from injury when the knee is stressed.
   D. The peroneal nerve is located within this recess.

2. Which of the following statements is true regarding meniscal injuries?
   A. Meniscal injuries are detected using the McMurray's test, Apley compression test or medial-lateral grind test.
   B. The McMurray test involves flexion of the knee beyond 90° with the foot externally rotated in the examiner's hand. The other hand palpates the medial joint line as the knee is extended gradually beyond 90°. Pain, a "popping" sensation, or crepitus indicates a medial meniscus injury.
   C. The McMurray test alone has been shown to have a low sensitivity and specificity for detecting medial meniscus injuries.
   D. Apley's compression test is performed with the patient in a prone position and the knee flexed to 90°. Pain with rotation of the foot while upward traction is applied suggests damage to the capsule and/or ligaments. Pain with rotation of the foot while downward traction is applied indicates meniscal injury.

3. Which of the following statements regarding tibial fractures is *not* true?
   A. Tibial fractures typically occur in one of two ways: 1) a direct blow to the tibia (bumper injury); or 2) axial compression of the tibia, which occurs when the knee is forcibly extended in anticipation of a frontal impact.
   B. Class A injuries (condylar and plateau fractures) usually are produced by axial loading (e.g., a fall from a height).
   C. The rotational stress on the knee will determine whether the medial or lateral tibial plateau is affected.
   D. The medial plateau is the site of fracture in the majority of cases.

4. Which of the following statements regarding disruption of the quadriceps mechanism is true?
   A. Such injuries commonly occur as the result of forced extension of the knee with the quadriceps muscle contracted.
   B. Rupture of the quadriceps tendon superior to the patella is more frequent in the elderly population, while patellar tendon ruptures inferior to the patella are more common in young athletes.
   C. The abduction tendon mechanism also can be disrupted with a complete transverse fracture of the patella and with avulsion of the tibial tubercle.
   D. Immediate arteriography is indicated.

5. Based upon the Ottawa rules, in which of the following patients should plain radiographs *not* be obtained?
   A. A 65-year-old male who has fallen down the steps and complains of knee pain.
   B. A 42-year-old female who presents after falling at a football game with tenderness at the head of the fibula.
   C. A 37-year-old skiier who presents after falling and has isolated tenderness of the patella.
   D. A 52-year-old male who presents with knee pain and can flex his knee to 90°.

CME Objectives

Upon completing this program, the participants will be able to:
a.) Quickly recognize or increase index of suspicion for occult knee injury;
b.) Be educated about how to correctly and quickly stabilize, and then to manage patients with knee trauma;
c.) Understand various diagnostic modalities for arterial injuries; and
d.) Understand both likely and rare complications that may occur.

CE/CME Instructions

Physicians and nurses participate in this continuing medical education/continuing education program by reading the article, using the provided references for further research, and studying the questions at the end of the article. Participants should select what they believe to be the correct answers, then refer to the list of correct answers to test their knowledge. To clarify confusion surrounding any questions answered incorrectly, please consult the source material. **After completing this activity, you must complete the evaluation form provided and return it in the reply envelope provided in order to receive a certificate of completion.** When your evaluation is received, a certificate will be mailed to you.

6. Which of the following statements regarding knee dislocations is *not* true?
   A. Knee dislocation is the result of a significant force delivered to the knee and occurs as the result of hyperextension, posterior forces to the tibia, or significant rotary forces.
   B. Any knee dislocation is associated with significant ligamentous disruption.
   C. There are three types of dislocation of the knee: anterior, posterior, and lateral.
   D. In anterior dislocations (the most common type), the tibia is displaced anteriorly to the femur and typically is the result of hyperextension of the knee joint.
   E. In a lateral dislocation, the tibia is forced posteriorly by a direct force applied to the proximal tibia.

7. Which of the following statements regarding lateral dislocations is *not* true?
   A Lateral dislocations can be medial or lateral and occur with equal frequency
   B. Lateral dislocations can be complicated further with rotary deformity of the knee.
   C. Any type of knee dislocation carries a 75% incidence of open joint injury.
   D. Reduction of the dislocation requires longitudinal traction.
   E. Sedation and pain relief commonly are required.

8. Which of the following statements regarding vascular injuries is true?
   A. Injury to the popliteal artery is common in knee dislocations (up to 40% of all dislocations).
   B. It is critical that such injuries be identified early and repaired within 6 to 8 hours of injury.
   C. Intact pulses in the foot do not exclude arterial injury.
   D. An arteriogram should be performed on these patients according to most experts, although an alternative strategy of admission and repeated clinical examination after normal ankle brachial indices (ABI) in the ED has been suggested.
   E. All of the above statements are true.

9. Which of the following statements regarding an ABI is *not* true?
   A. An ABI is performed by obtaining a blood pressure in the arm by standard technique, then taking a blood pressure at the ankle. Dividing the ankle pressure by the arm pressure determines the ABI.
   B. Ankle pressure should be greater than brachial pressure.
   C. A ratio of one or greater is considered normal.
   D. An ABI of 0.9 or less always means that the patient has sustained an arterial injury.
   E. Patients who have peripheral arterial disease also may have an ABI of less than 0.9.

10. A 35-year-old male presents with a patellar fracture. Which of the following statements is true?
   A. A patellar fractures typically is caused by direct knee trauma.
   B. A secondary mechanism may involve an avulsion caused by the pull of the quadriceps mechanism.
   C. Patellar fractures are more common in males.
   D. A non-displaced fracture can be treated with a knee immobilizer and pain control.
   E. All of the above statements are true.

Answer Key:
1. C; 2. B; 3. D; 4. B; 5. D; 6. E; 7. C; 8. E; 9. D; 10. E

In Future Issues:

Ocular Trauma