PRACTICAL SUMMARIES IN

ACUTE CARE

A Focused Topical Review of the Literature for the Acute Care Practitioner

Lacerations: To Glue or Not to Glue?

Author: **Donald W. Alves, MD, FACEP,** Assistant Professor, Division of Emergency Medicine, Department of Surgery and EMS Fellowship Director, University of Maryland School of Medicine, Baltimore

Peer Reviewer: **Andrew D. Perron, MD, FACEP, FACSM**, Associate Professor & Residency Program Director, Maine Medical Center, Portland

Introduction

As the pace of medical practice accelerates, health care providers seek tools that expedite patient care in a safe high-quality manner. The clinical utilization of cyanoacrylate tissue adhesives (or glues) is an example of a popular clinical topic that has the potential to enhance patient care. As many of the articles selected for this review will support, there is a clear time benefit to gluing. Questions do remain regarding cosmetic outcome, wound closure stability, infection risk, and the benefit of other potential, even less-sophisticated, wound closure techniques. Articles were selected based on their ability to maximize coverage of issues in the medical literature concerning tissue adhesive utilization, while selecting representative papers from within specific topic areas that are particularly relevant to clinical practice. The majority of literature reviewed is from the last two years, but articles were selected based on clinical relevance and applicability. The overall objective of this article is to arm the reader with a broad array of information regarding the clinical utilization of tissue adhesives, and allow him/her to answer the burning clinical question: to glue or not to glue?

Skill Level Needed?

Source: Lin M, et al. Tissue adhesive skills study: The physician learning curve. *Pediatr Emerg Care* 2004; 20:219-223.

This study sought to identify acceptable methods for introducing tissue adhesive use to medical students and house staff. Researchers prospectively identified two groups. The participants in one group were oriented by attending a 30-minute lecture that reviewed the medical literature, utilization of glue, exclusion criteria, and tissue application technique. Another group was trained on an individual basis. Practitioners were queried following each appropriate wound closure regarding:

- their perception of time required for closure versus suturing;
- difficulty of closure with tissue adhesive versus the expected complexity if it had been sutured;
- their personal satisfaction with immediate post-repair appearance of the wound; and
- the number of prior experiences utilizing tissue glue for wound closure.

During the nine-month study period, 81 such encounters were evaluated. Respondents in both groups uniformly reported significant time saved, expectation of substantially greater complexity of closure had the wound been sutured, and very good overall cosmesis-with measures >/= to 4.0 on a 1-5 scale; 37 of the 81 respondents were first-time tissue adhesive users. The authors concluded that wound clo-

VOLUME 1 • NUMBER 1 • JANUARY 2006 • PAGES 1-8

Thomson American Health Consultants Home Page—www.ahcpub.com • CME for Physicians—www.cmeweb.com

Statement of Financial Disclosure: Executive Editor, Ann R. Dietrich, MD, FAAP, FACEP, reported that she receives research support from the National Institutes of Health and is the medical director for the Ohio Chapter of ACEP. Dr. Alves (author) and Dr. Perron (peer reviewer) reported no financial relationships with companies having ties to this field of study.

THOMSON

AMERICAN HEALTH CONSULTANTS

sure utilizing tissue glue is an easily acquired skill and that the type of initial training did not significantly alter the parameters evaluated.

Subscriber Information

Customer Service: 1-800-688-2421.
Customer Service E-Mail: customerservice@thomson.com
World-Wide Web: www.ahcpub.com

Subscription Prices

United States
$299 per year (Student/Resident rate: $144.50).
Multiple Copies
Discounts are available for multiple subscriptions. For pricing information, call Steve Vance at (404) 262-5511.
Outside the United States
$329 per year plus GST (Student/Resident rate: $159.50 plus GST).

Practical Summaries in Acute Care, ISSN 1075-6914, is published monthly by Thomson American Health Consultants, 3525 Piedmont Rd., NE, Bldg. 6, Suite 400, Atlanta, GA 30305.

VICE PRESIDENT/PUBLISHER: Brenda L. Mooney
EDITORIAL GROUP HEAD: Glen Harris
MANAGING EDITOR: Martha Jo Dendinger
MARKETING MANAGER: Nan Webb
GST Registration Number: R128870672.

Periodical postage paid at Atlanta, GA.
POSTMASTER: Send address changes to ***Practical Summaries in Acute Care***, P.O. Box 740059, Atlanta, GA 30374.

Back Issues: $48 per issue. Missing issues will be fulfilled by Customer Service free of charge when contacted within one month of the missing issue's date.

Accreditation

Thomson American Health Consultants (AHC) is accredited by the Accreditation Council for Continuing Medical Education to provide continuing medical education for physicians.

Thomson American Health Consultants designates this educational activity for a maximum of 20 category 1 credits toward the AMA Physician's Recognition Award. Each physician should claim only those credits that he/she actually spent in the activity.

This CME activity is intended for emergency physicians. It is in effect for 24 months from the date of the publication.

Practical Summaries in Acute Care also is approved by the American College of Emergency Physicians for 20 hours of ACEP category 1 credit.

Practical Summaries in Acute Care has been reviewed and is acceptable for up to 20 Prescribed credits by the American Academy of Family Physicians. Term of approval is for one year from beginning distribution date of 06/01/05. Each issue is approved for 1.5 Prescribed credits. Credit may be claimed for 1 year from the date of this issue.

For CME credit, add $50.

Questions & Comments

Please call **Martha Jo Dendinger,** Managing Editor, at (404) 262-5514 between 8:30 a.m. and 4:30 p.m. ET, Monday-Friday.

Research assistance provided by Thomson Web of Science®.

THOMSON
AMERICAN HEALTH CONSULTANTS

Commentary

Initial training, need for in-service education, and the manner to be selected for such training are important considerations for program or department level decision makers regarding the implementation of tissue adhesive in the ED. Current "gluers" may have difficulty recalling exactly how or when they were introduced to the technique, but particularly in settings that receive frequent new, junior, or rotating providers, consideration must be given to the adequacy of initial instruction to minimize the risk of adverse outcomes for patients. While the number of participants was small, the data presented strongly support that wound closure utilizing tissue adhesives is an easily acquired skill. Advocates for tissue adhesive utilization may reasonably use this data to support the ease of acquirement of this skill. An additional layer of complexity that would have further supported the cosmetic outcome similarity would have been a query of the patient or a supervising clinician for their assessment of immediate post-procedure cosmesis.

Application Technique

Source: Santibanez-Gallerani A, et al. Improved esthetic results with fine-tip Dermabond application technique. *J Craniofac Surg* 2004;15:890-892.

Dr. Santibanez-Gallerani and colleagues sought a means to enhance the accuracy of application of tissue adhesive to better limit contact to the dermal layer of the wound, which they report is the source of the strength of the closure. To achieve this accuracy, at time of wound closure, deep dermal sutures were placed initially; after crushing the adhesive's inner container, a 25-gauge needle on a 1-mL syringe is introduced into the cotton-top applicator and the contents aspirated. The wound to be closed is dried and approximated. The needle is then allowed to "fall" into the break in dermal continuity without skin penetration by the needle. The tissue glue is then applied along the wound's defect without overflow onto surrounding intact skin. The wound is held approximated for 45 seconds to allow adequate time for polymerization and then released. The authors queried the patients immediately post-procedure; more than 90% reported a "good to excellent" esthetic result and patient satisfaction score. They concluded that this application technique could result in lower complication rates and superior esthetics than is currently reported in the literature.

Commentary

The authors pointed out that contact of the normal surrounding skin with tissue adhesive may result in a "chemical wrinkle-like effect" that can persist for several weeks, as well as a glue-based "scab" that persists around the wound for 9-25 days. These esthetic concerns combined with the potential for the standard packaging applicator swab to contact foreign objects (e.g., gloves or instruments) were motivators in the creation of this study. The potential to minimize or eliminate these occurrences made this an excellent area for study. The study included 20 patients, and the authors reported surveying participants immediately post-procedure and at 1-week and 4-week follow-ups. Patient complaints were documented and monitored. No information is provided on the 1- or 4-week survey results, and no information is provided as to the nature of complaints, if any. No mention of pres-

entation to an Institutional Review Board is included in the article. Despite these issues, the potential for further improvement of our clinical tissue adhesive application skills led me to include this paper. The authors concluded with the proviso that "basic [wound closure] principles must be followed." Further study would be required to determine suitability of using this technique in an outpatient (clinic or emergency department) setting where deep dermal sutures are not routinely placed for wound tension relief and closure support.

Steri-Strip Closure vs Tissue Adhesive

Source: Zempsky WT, et al. Randomized controlled comparison of cosmetic outcomes of simple facial lacerations closed with Steri-Strip Skin Closures or Dermabond tissue adhesive. *Pediatr Emerg Care* 2004;20:519-524.

The primary purpose of this study was to compare the cosmetic outcome of tissue adhesive (Dermabond®) versus tape closure strips (Steri-Strips™) on simple facial lacerations in children. Only patients with low-tension wounds less than 2.5 cm in length, less than 12 hours old, and who presented during the clinical shifts of one of the authors were eligible. Topical anesthesia with lidocaine-epinephrine-tetracaine (LET) was allowed to facilitate wound cleansing and care if required. Steri-Strips were applied following benzoin application and supplemented by a second layer of strips perpendicular to the first. The tissue adhesive closure group was approximated manually or using forceps and applied with usual technique. Both groups were instructed to keep the sites dry for five days. Follow-up phone calls to caregivers were made after one week to assess for wound dehiscence or infection.

At two months post closure, the wounds were photographed using a standardized technique and then evaluated by two cosmetic surgeons who were blinded to the closure technique used. The cosmetic outcome determination showed moderate agreement, and the 95% confidence intervals around each mean overlapped. Six (12%) of the glued wounds dehisced by report, although all were reported as "small" or after new trauma.

Commentary

The authors in Hartford, CT, elaborated upon a similar previous study by Mattick and colleagues from Edinburgh, UK (*Emerg Med J* 2002;19: 405-407), that had larger numbers: 100 total versus 60 and follow-up on 89 versus 44. The current study's conclusions are compatible with the prior study and lend support to the option to not formally close (with sutures, staples, or glue) appropriate simple facial lacerations in children, and still achieve "similar cosmetic outcomes," acceptable to plastic surgeons and parents alike.

The authors did comment on the need for hemostasis prior to tissue adhesive application and that a burning sensation may be reported. They noted that both of these may be mitigated by topical anesthetic application—LET or similar—however, they also identified an important limitation to this study: the utilization of such agents should be assessed for any independent effect on the study wound. An additional potential limitation was the provision of "research support" from 3M, Inc.

Potential 'Sticky' Situations

Source: Lo S, et al. A review of tissue glue use in facial lacerations: Potential problems with wound selection in accident and emergency. *Eur J Emerg Med* 2004;11:277-279.

Lo and associate conducted what they report as the first study to review the appropriateness of facial lacerations selected for tissue adhesive closure based upon current evidence. They retrospectively examined charts from a six-month period and identified 200 facial lacerations. Their search criteria excluded bite-related wounds and wounds to the neck or scalp; 45 of the 200 wounds were closed with tissue adhesive. Three of these 45 (7%) were nonlinear, and as such were assessed as not proper candidates for glue use.

Commentary

The authors did great work reviewing and identifying limitations of other tissue adhesive studies including restriction to lacerations less than 4 cm, and the absence of trials addressing traumatic flaps or stellate wounds. They commented on the risk of dehiscence and provided a 4% risk for a number needed to harm of 25, but they did not specify if this was borne out in their review or is only referencing published data. The authors subdivided the face into 15 areas to allow localization of the lacerations, and did identify 25/45 on the forehead, 12/45 in the periorbital area, and the final eight on the remainder of the face. The frequency of glue use in the periorbital area is an interesting finding as this typically is discouraged due to risk of eye injury.

An older study (Simon, et al. Lacerations against Langer's lines: To glue or suture? *J Emerg Med*

1998;16:185-189) assessed 48 children with facial wounds oriented either with or against Langer's lines and evaluated them for cosmetic appearance at a two-month follow-up visit. Two plastic surgeons evaluated the photographs and reported appearance as significantly worse for wounds counter to Langer's lines. In a larger study population, the addition of laceration detail—such as with this prior study—may provide further information to clinicians to help determine the appropriateness of a given facial laceration for tissue adhesive closure versus an alternate method.

Subcuticular Closure vs Tissue Adhesive

Source: Switzer EF, et al. Subcuticular closure versus Dermabond: A prospective randomized trial. *Am Surg* 2003;69:434-436.

This paper evaluated a new application of tissue adhesive to deeper wounds — specifically inguinal herniorrhaphy incisions — compared to subcuticular closure. Informed consent was obtained from 45 consecutive volunteers preoperatively. All patients had three interrupted 3.0 Vicryl® deep dermal sutures placed and, then, were randomized to either tissue adhesive or running subcuticular skin closure. Time for closure was significantly shorter in the adhesive group. Patients were followed up at two and four weeks by four staff surgeons who were blinded to the repair technique. The evaluators scored cosmetic and functional issues of step-off, contour irregularities, dehiscence, edge inversion, distortion, and overall appearance. The mean cosmetic scores reported were 3.88 for glue versus 4.20 for suture (on a 1-5 scale) and were not statistically significantly different.

Commentary

By randomization, the tissue adhesive group had a nonsignificant younger mean age (42.8 versus 50.2, p=0.23), which, if anything, might have led to an expectation of fewer wound healing complications, making the five found more attention grabbing. The authors explained the placement of the deep dermal sutures was a responsible precaution against frank adhesive closure failure and was standardized to both groups to minimize confounding. They attributed the failures to the increased fluid seepage from deeper wounds during the first 24 hours, which may have lifted the adhesive and led to the wound separations.

An editor's letter and author's reply (*Am Surg* 2004;70:369; author reply: 370-1) elaborated that while this was intended as a pilot study, with plans to repeat the methodology absent the deep dermal sutures, this intent and the pilot study itself were terminated early due to investigator concerns regarding the unacceptably high rate of "problems" encountered (5 of 24). The authors' response concluded with the recommendation that dermal sutures be placed to protect against wound separation should tissue adhesives be considered for use in deeper wounds. This study may further guide practitioners in their determination of the appropriateness of tissue adhesive use to minimize the overall complication rate.

Use in Traumatic Laceration Repair

Source: Farion K, et al. Tissue adhesives for traumatic lacerations in children and adults. *Cochrane Database Syst Rev* 2002;(3):CD003326.

Fairon and colleagues examined the literature for the use of tissue adhesives in adult and pediatric traumatic lacerations for the Cochrane Database. They cited the major factors—increasing popularity of glue use, ease of use, decreased pain, decreased time to apply, and no required follow-up visit—as advantages contributing to the popularity of this technique. None of the substantial number of studies published to date had adequate power or consistency in study parameters to allow assertion of definitive answers regarding the efficacy of tissue adhesives. The authors vigorously searched for randomized controlled trials and included them for comparison if they addressed acute, linear, low-tension traumatic (nonsurgical) lacerations. Eight studies were compared; no significant difference for cosmetic result was found. Favorable reductions in both procedural pain and time to complete were reported. A "small but statistically significant risk" of wound dehiscence was identified with tissue adhesives—number needed to harm (NNH) 25, with 95% CI 14-100, as well as local erythema—NNH 8, 95% CI 4-100. Their conclusions reflected these findings and reported tissue adhesives to be an "acceptable alternative to standard wound closure for simple traumatic lacerations."

Commentary

Since my initial introduction to it in residency training, the Cochrane Collaboration has been praised for its rigorous efforts and methodologies to present meta-analyses with the best information available for clinical application. I found no reason for change in my esteem of their reputation based upon my review of their methodology of literature search, scoring, inclusion, and

review techniques used for this topic. Their conclusions pre-dated many of the other papers summarized here, and are further supported by the findings of the subsequent authors. Of note to readers: A one-page summary of Fairon and colleagues' contribution is presented in *Evid Based Nurs* 2003; 6:46.

Antimicrobial Barrier Properties

Source: Bhende S, et al. In vitro assessment of microbial barrier properties of Dermabond® topical skin adhesive. *Surg Infect(Larchmt)* 2002;3:251-257.

This study was performed to gather additional information for the clinician (based upon an in vitro study) regarding the antimicrobial/ barrier effect of tissue adhesives in general, and octylcyanoacrylates (Dermabond®) in particular. Sterile agar containing bromocresol purple (as a color-change indicator of biological activity) was prepared and then layered with one or three "films" of adhesive with liquid from individual applicators, to create uniformly thick films, each approximately 20 mm in diameter. Positive control plates were created by punctures with a sterile needle. Negative controls included plain agar and uninoculated glue film agar plates. Twenty films per organism were subjected to a broad spectrum of organisms, including *S. epidermidis*, methicillin resistant *S. epidermidis* (MRSE), *S. aureus,* MRSA, *E. faecalis,* vancomycin-resistant *Enterococci* (VRE), *E. coli*, *Klebsiella pneumoniae*, *Proteus* species, *S. marcescens*, *Acinetobacter baumanii,* and *Candida albicans*. The plates were then incubated right side up for three days at 37°C. The 300 single-layer films had one plate lost due to compromise of the integrity of its glue layer, resulting in "95% confidence of 98.5% efficacy for 72 hours" as an in vitro barrier to microbial penetration. The 300 triple-layer films had one plate demonstrate growth around the layer as a contamination rather than an accepted true-positive result (=failure) by growth through the layer. This yielded similar efficacy estimates.

Commentary

The introduction does comment on potential mechanisms for reduction in the risk of infection with the use of tissue adhesives:

- elimination of punctures (for anesthesia and suture) that may introduce skin flora into the wound;
- the absence of suture material that may provide a migration path through the skin for bacteria; and
- the flexible seal over the wound to reduce secondary contamination.

The project was conducted with resources from Jansen® and Ethicon®, which could pose the only potential "cloud" over this otherwise elegant basic science investigation; however, as reported it is unlikely that there would be any interference with the project as reported.

The paper is well written and contains background information on tissue adhesives that likely only a manufacturer would be able to detail. The authors mentioned a guinea pig wound closure study that found lower infection rates than with traditional monofilament suture closures and built from this point to reflect that in this in vitro study model; absent the protection of an immune system's inherent protections, penetration of the film(s) by even one microorganism could have caused an agar color change and resulted in a positive (=failed) barrier determination.

Hair Apposition Technique

Source: Hock MO, et al. A randomized controlled trial comparing the hair apposition technique with tissue glue to standard suturing in scalp lacerations (HAT study). *Ann Emerg Med* 2002;40:19-26.

This article compared a hair twist secured by tissue adhesive against standard suturing. Researchers required the lacerations to be linear, not actively bleeding or severely contaminated, less than 10 cm total length, in an area with hair at least 3 cm long, and hemodynamic stability of the patient to be randomized.

Participating practitioners were in-serviced on the technique prior to the study. Ninety-six patients had hair apposition technique (HAT) used, and 93 were sutured. The patients were instructed to not wash the wound for two days. Wound inspection was performed after one week, and infection, bleeding, allergy, scarring, and wound breakdown were noted as either present or absent based upon definitions elaborated upon in the article. The examiner at follow-up was also to determine if "satisfactory wound healing had occurred." If this was not the case, the patient was brought back weekly until healing was deemed complete.

Demographic and wound characteristics were similar between groups. The investigators reported a significant reduction in procedural time with hair apposition and glue ($p < 0.001$) and an increased incidence of scarring and infection in the suture group ($p = 0.004$ and 0.005, respectively). They reported limitations of patients with very short or no hair, profusely bleeding wounds, or grossly contaminated wounds. They reported HAT to be

simple, effective, and able to be "learned quickly by anyone."

Commentary

The authors mentioned prior studies with use of hair, but clarified that those physically knotted the strands to oppose the wound edges and, thus, had to eventually be cut off. The related editorial (*Ann Emerg Med* 2002;40:27-29) elaborated on prior reports in the literature of hair-assisted wound closure techniques, plus pointed out that only the outermost layers of skin are opposed, which could potentially result in a deeper tissue dead space, and wound edge eversion with HAT would be very difficult to obtain. The editorialist pointed out that function and cosmesis are not critical in most scalp wounds, and that early wound appearance does not correlate to later outcome. The authors, editorialist, and I agree in the end that knowledge of this technique could only serve to benefit the occasional, appropriately wounded patient in the future. Lastly, brief synopses of Hock's work have been presented in two articles (Weick R, et al. Hair apposition technique is better than suturing scalp lacerations *J Fam Prac* 2002;51:818; and Brosnaham J. Treatment of scalp lacerations with a hair apposition technique reduced scarring, pain, and procedure duration compared with suturing. *Evid Based Nurs* 2003;6:17.)

Needle-stick Injuries and Glue Use

Source: Gordon CA. Reducing needle-stick injuries with the use of 2-octyl cyanoacrylates for laceration repair. *J Am Acad Nurse Pract* 2001;13:10-12.

This small descriptive study sought to confirm an expectation of reduced needle-stick exposure risk through the utilization of tissue adhesives for laceration repair. Thirty-eight patients had data collected when their treating practitioner (physician or nurse practitioner) selected glue as the closure method for a laceration; 58% of these cases were pediatric. "At the end of treatment," 92.1% of wounds were completely approximated, and there was no erythema, wound drainage, or warmth reported by any patient. They reported that 7.9% required reapplication of the adhesive due to wound dehiscence. Among the providers, no needle-stick injuries were reported as a result of these wound closures, and 82.3% preferred tissue adhesive as a closure technique.

Commentary

This study is reviewed here to remind us of the obvious: stuff happens. No matter the level of precaution, if someone/something moves wrong at the wrong time during a suture closure of a laceration, there is a potential for percutaneous blood exposure. Because it is widely acknowledged that more than 25% of persons with HIV do not know they have it, it is not just a "nondisclosure" circumstance. The opportunity to avoid contact with needles or other sharps in a procedure, when feasible, does make the risk of a sharps-related injury that much less likely.

Conclusion/ Recommendations

I will preface this summary with mention that given an appropriately cleansed, nonbleeding wound and a willing patient, I use tissue adhesives in a broad variety of laceration presentations, generally with excellent results. If an acceptable closure cannot be achieved in this manner, the glue is then removed and the wound prepped and closed in an alternate fashion. Lin demonstrated the relative simplicity of providing initial instruction on procedural aspects of this technique to a varied skill-level audience.

The syringe-and-needle technique as an alternate applicator may eventually migrate into the outpatient arena where "glue-clot" and self-adhesion issues can complicate wound closure, however this will require further investigation. Two separate, alternate techniques for laceration approximation were presented (hair apposition and adhesive strip application) with potentially even less discomfort than tissue adhesive application, and comparable cosmetic outcomes to broaden the practitioner's procedural armamentarium in appropriate lacerations. The Bhende paper elaborated on the potential added benefit to the use of tissue adhesives of an antimicrobial barrier, an excellent investigation utilizing an in vitro model.

Several of the abstracts either directly or indirectly drew attention to the importance of selecting appropriate wounds for tissue adhesive application to optimize the likelihood of satisfactory outcomes for our patients. Excessive depth, significant incongruity with Langer's lines, or lacerations located in more mobile or tensile areas of skin are factors that should be considered to yield an educated decision to utilize an alternate closure technique. The clinician should be able to articulate the rationale for selection of closure technique to the patient or other practitioners, if asked.

Alternately, if the clinical decision is made to utilize cyanoacrylate glue on a laceration that would

reasonably pose an increased risk of dehiscence, the old-fashioned practice of adding support and additional protection to a wound once closed via overriding adhesive strips, bulky dressings, or even splinting if necessary, will improve the odds in favor of the wound healing in an acceptable fashion.

Future Issues

• *What is the best diagnostic test for nephrolithiasis?*

• *Is an LP necessary in SAH with new generation scanners?*

• *Should steroids be used to treat croup?*

Wound Repair—Tissue Adhesives: Wound Types and Locations Contraindicated for Use of Tissue Adhesives

- Puncture wounds
- Animal or human bites
- Heavily contaminated wounds
- Wounds with active infection or gangrene
- Stellate or crush wounds
- Wounds of length greater than 4-6 cm
- Wounds gaping greater than 4-6 cm
- Wounds below skin surface
- Areas with dense natural hair
- Wounds near or on the eye
- Areas of tight skin tension, such as over a joint
- In patients with immune compromise, poor wound healing, collagen vascular disease, or coagulopathy
- Patients with known allergy to cyanoacrylate or formaldehyde
- Areas subjected to repetitive friction (hands, feet)
- Areas of prolonged moisture (mucosal surfaces, mucocutaneous junctions)

Wound Repair—Tissue Adhesives: Pearls and Pitfalls

PROBLEM	PREVENTION
Adhesive sticks to gloves	Use vinyl gloves instead of latex; adhesive easily is removed with gentle traction
Gauze sticks to skin	Dampen gauze with water or saline
Adhesive runs into eyes	Position sensitive areas uphill from area where adhesive is being applied and surround area with damp gauze
Adherence to plastic forceps	Use metal instruments; less adherent
Seepage into wound	Do not release wound edges until polymerization is complete; may remove with petroleum jelly-based ointment
Hematoma formation	Ensure complete hemostasis prior to wound closure
Adherence to skin sutures	Do not apply adhesive over or near skin sutures that already have been placed

Tables adapted from: Dietrich A. *Trauma Reports Rapid Reference Guidelines.* Atlanta: Thomson American Health Consultants;2004:72-73.

CME OBJECTIVES

Upon completing this program, participants will be able to:

- Summarize the most recent significant studies in emergency medicine/acute care related to a single topic;
- Discuss up-to-date information about new drugs, techniques, equipment, trials, studies, books, teaching aids, and other information pertinent to the stated topic;
- Evaluate the credibility of published data and recommendations about the stated topic.

CME INSTRUCTIONS

Physicians participate in this continuing medical education program by reading the articles, using the provided references for further research, and studying the CME questions. Participants should select what they believe to be the correct answers, then refer to the list of correct answers to test their knowledge. To clarify confusion surrounding any questions answered incorrectly, please consult the source material.

After completing this activity, participants must complete the evaluation form provided at the end of each semester (June and December) and return it in the reply envelope provided to receive a certificate of completion. When an evaluation form is received, a certificate will be mailed to the participant.

CME QUESTIONS

1. Tissue adhesive application instruction:

a. introduces a complex skill requiring dedicated instruction.
b. demonstrates basic information on an easily acquired skill.
c. is subject to skill-decay and must be in-serviced routinely.
d. should best be accomplished via video presentation.

2. As reported by the authors, the benefits for needle application of glue stem from:

a. chemical interaction from the plastic/air interface prior to application.
b. the ability to directly inject adhesive into the tissues to be approximated.
c. lack of tissue-applicator contact to minimize glue-clot and self-adhesion.
d. fine control of application to limit contact to dermal tissue only.

3. Octylcyanoacrylate tissue adhesives may result in a decreased risk of wound infection by:

a. creation of polymerization byproducts that are directly bactericidal.
b. engulfing microbes within the adhesive film to restrict nutrient access.
c. forming a solid barrier that microbes are not able to penetrate.
d. a complex chemical reaction that disrupts microbial mitochondria.

4. The hair apposition technique must be utilized with prudence due to the risk of:

a. severe follicular damage and creation of areas of nongrowth near the wound.
b. local autoimmune response to hair held in the wound by tissue adhesive.
c. creation of deeper tissue potential space for hematoma or abscess formation.
d. secondary trauma with wound re-opening during personal hygiene activities.

5. The association between needle-stick injuries and tissue adhesives utilization:

a. reminds clinicians that if sharps are not required, related injury risk is minimal.
b. serves to remind practitioners to use caution when crushing the ampoule.
c. identifies the frequent need to utilize local anesthesia to reduce pain from glue.
d. cautions providers regarding presentations of parenteral drug abuse as trauma.

Answers:

1. b
2. d
3. c
4. c
5. a

Thomson American Health Consultants
Building Six, Suite 400
3525 Piedmont Road NE
Atlanta, Georgia 30305-1515
Tel (404) 262-7436 Fax (404) 262-7837
www.ahcpub.com

THOMSON
AMERICAN HEALTH CONSULTANTS

January 2006

Dear *Emergency Medicine Alert* subscriber:

Emergency Medicine Alert ceased publication with the December issue. To fulfill your subscription we are pleased to offer you *Practical Summaries in Acute Care*, which is sponsored by Thomson American Health Consultants.

Practical Summaries in Acute Care is a monthly newsletter that brings you a comprehensive review and analysis of the most recent clinical developments in presentations frequently seen by emergency and acute care providers. Each issue reviews the most significant recent research on a particular topic, and an expert in that field analyses how each advances patient treatment. After reading each issue you will have a practical and concise - yet thorough - overview of the topic to help you make the best treatment decisions for your patients.

Practical Summaries in Acute Care offers 20 AMA PRA category 1 credits. It is also approved by the American College of Emergency Physicians for 20 hours of ACEP Category 1 credit and by the American Academy of Family Practitioners for 20 Prescribed credits. The educational objectives are to:

1. Summarize the most recent significant studies in emergency medicine/acute care related to a single topic;
2. Discuss up-to-date information about new drugs, techniques, equipment, trials, studies, books, and teaching aids;
3. Evaluate the credibility of published data.

Each issue of your newsletter contains questions relating to the information provided in that issue. After reading the issue, answer the questions at the end of the issue to the best of your ability. You can then compare your answers against the correct answers provided in an answer key in the newsletter. If any of your answers were incorrect, please refer back to the source material to clarify any misunderstanding.

At the end of each semester you will receive an evaluation form to complete and return in an envelope we will provide. Please make sure you sign the attestation verifying that you have completed the activity as designed. Once we have received your completed evaluation form, we will mail you a letter of credit. This activity is valid 24 months from the date of publication. The target audience for this activity is emergency department and acute care health care providers.

If you have any questions, please call one of our customer service representatives toll-free at (800) 688-2421.

Thank you for supporting *Emergency Medicine Alert*. We trust that you will find *Practical Summaries in Acute Care* equally valuable.

Sincerely,

Brenda L. Mooney

Brenda Mooney
Vice-President/Group Publisher
Thomson American Health Consultants

THOMSON
AMERICAN HEALTH CONSULTANTS

Evidence-Based M[illegible] ED

Trauma Reports

Enclosed in this issue: CE/CME Evaluation

Vol. 7, No. 1

Supplement to *Emergency Medicine Reports*, *Pediatric Emergency Medicine Reports*, *ED Management*, and *Practical Summaries in Acute Care*

Jan. / Feb. 2006

Emergency department (ED) physicians frequently are required to assess and stabilize multiple trauma patients. Following the initial stabilization of the patient's airway and circulatory status, secondary potential life-threatening injuries should be identified and addressed.

Pelvic injuries may occur secondary to blunt or penetrating trauma and may result in stable or life-threatening injury patterns. Patients with pelvic trauma require a thorough evaluation for associated injuries and careful monitoring for potential deteriorations.

Therapeutic options continue to advance and evolve as alternative modalities are explored. The authors review the early recognition, stabilization, and management of a patient with a pelvic fracture.

— The Editor

Pelvic Trauma

Authors: **LaMont C. Smith, MD**, Attending Physician and Clinical Instructor, Department of Surgery, Division of Surgical Critical Care, R. Adams Cowley Shock Trauma Center, Division of Emergency Medicine, University of Maryland Medical System, Baltimore; and **Thomas M. Scalea, MD**, Physician in Chief, R. Adams Cowley Shock Trauma Center; Division of Emergency Medicine, University of Maryland Medical System, Baltimore

Peer Reviewer: **O. John Ma, MD**, Professor and Vice Chair, Department of Emergency Medicine, University of Missouri-Kansas City School of Medicine, Kansas City, Missouri

Introduction

Although pelvic injury can be the result of either penetrating or blunt force injury, the majority of pelvic trauma cases involve blunt force. Pelvic fracture management is perhaps the best example of multidisciplinary care because patients often require therapy—in addition to bony stabilization—for associated system injury including neurologic, urologic, and vascular injuries. Although the initial patient focus should be rapid hemodynamic stabilization followed by complete radiologic survey to determine the severity of the injury and associated injuries, upper level interventions (e.g., angiographic embolization) may be necessary. Both general and orthopedic surgery expertise may be necessary to provide optimal care. It is also important to determine whether transfer to a higher level of care is necessary early in the patient's course.

Patients with penetrating pelvic trauma, although they have

Statement of Financial Disclosure

In order to reveal any potential bias in this publication, and in accordance with Accreditation Council for Continuing Medical Education guidelines, Dr. Dietrich (editor in chief) reports that she receives grant/research support from the National Institutes of Health and is the medical director for the Ohio Chapter of the American College of Emergency Physicians. Drs. Smith and Scalea (authors), and Ma (peer reviewer), Ms. Finnerty (nurse reviewer), and Ms. Neff (nurse reviewer) report no relationships with companies related to this field of study.

the potential for similar organ injury as those with blunt trauma, are more likely to sustain intra-abdominal injury. Penetrating pelvic injury should be suspected with any gunshot or stab wound that involves the flank, buttock, or lower back and paravertebral region. Patients who present in shock require immediate surgical exploration. Those patients who are stable can be evaluated with a series of radiographs and potentially treated nonoperatively.

Blunt Pelvic Injury

Epidemiology. More than 60% of pelvic fractures are the result of vehicular trauma, either vehicular crashes or struck pedestrians; falls from a height account for an additional 30%.[1] The remainder generally occur from industrial or recreational injury. Low impact injuries may produce stable isolated fractures (e.g., an isolated pubic rami fracture). High impact injuries often produce gross instability of the pelvic ring with concomitant soft-tissue injury and life-threatening hemorrhage.

The mortality from pelvic fractures ranges from 6% to 20%, but may reach 50% when associated with significant hemorrhage and hypotension.[2] Shock on arrival and age more than 60 years have been shown to be associated with increased mortality.[3,4] A base excess ($\geq$ -5) at the time of patient presentation also has been shown to be associated with increased mortality.[5] While death can occur directly from pelvic hemorrhage, more often it is the result of concomitant injuries.[6] The mortality rate from open pelvic fractures can be as high as 30-50%, also often from associated injuries.[7] Older patients tend to have a more protracted and complicated course, probably secondary to chronic medical problems and lack of physiologic reserves. Older patients also tend to have a worse outcome, are more likely to bleed, and may require angiography for relatively minor fractures.[8]

Anatomy of the Pelvis. The pelvis consists of two innominate bones and the sacrum. Each innominate bone consists of an the ilium, pubis, and ischium. The pubic bones are the thinnest of the pelvic bones and often are fractured in pelvic trauma. Their fragments may injure the bladder, urethra, or vagina.[9] Several strong posterior ligaments, as well as the sacroiliac joint, give the pelvis its stability. The two most important ligaments are the sacrotuberous ligaments, which extend from the sides of the sacrum to the iliac tuberosities; and the sacrospinous ligaments, which pass from the sides of the sacrum to the ischial spines.

There are four pelvic joints. The symphysis pubis is a slightly movable anterior joint that connects the two pubic bones. The sacroiliac (SI) joints, which are the strongest joints in the body, are formed where the ilium joins with the first two sacral vertebrae and connect the spine to the pelvis. These joints gain additional strength from the anterior and posterior ligaments; although rarely involved in pelvic fractures, when disrupted, the pelvis almost invariably is unstable. The sacrococcygeal joint is a hinge joint between the sacrum and the coccyx.

Muscles of note that attach to the pelvis include the sartorious, which inserts on the anterior superior iliac spine; the rectus femoris, which inserts on the anterior inferior iliac spine; and the hamstrings, which attach to the ischial tuberosities. Avulsion fractures sometimes occur at these sites.[10] Posterior fractures of the pelvis more commonly are associated with neurovascular structural damage and can affect weight-bearing activities. Anterior fractures are more likely to cause urogenital damage and usually do not affect weight-bearing activities.

The acetabulum articulates with the femoral head to make the hip joint. These two bones fit together like a ball and cup; there is free rotation of the femoral head. The anterior column of the acetabulum is formed by the pubic ramus and the anterior rim. The posterior column comprises the ischial tuberosity and the posterior rim of the acetabulum. The dome is especially important in weight-bearing activities.

Classification of Pelvic Fractures

Several different classifications of pelvic fractures exist, but all emphasize the underlying stability or instability of the pelvis. High-risk pelvic fractures are those with symphysis diastasis more than 2.5 cm, involvement of all four rami, widening of the SI joint more than 0.5 cm, or vertical shear. A stable fracture is one that will not undergo rotational or vertical deformation when subjected to normal physiologic loads. An unstable fracture is one in which movement —rotational, vertical, or both—can occur in the three-dimensional plane when normal forces are applied.

Morphologic Classification: The Kane Modification of the Key and Conwell Classification. This system is based upon radiographic assessment of the bony components involved and the number of breaks identified.

Type I. These are isolated disruptions of pelvic bone and do

Trauma Reports™ (ISSN 1531-1082) is published bimonthly by Thomson American Health Consultants, 3525 Piedmont Road, N.E., Six Piedmont Center, Suite 400, Atlanta, GA 30305. Telephone: (800) 688-2421 or (404) 262-7436.

Vice President/Group Publisher: Brenda Mooney
Editorial Group Head: Glen Harris
Managing Editor: Martha Jo Dendinger

POSTMASTER: Send address changes to ***Trauma Reports***, P.O. Box 740059, Atlanta, GA 30374.

Accreditation

Thomson American Health Consultants (AHC) is accredited by the Accreditation Council for Continuing Medical Education (ACCME) to provide continuing medical education for physicians.

Thomson American Health Consultants designates this educational activity for a maximum of 2.5 category 1 credits toward the AMA Physician's Recognition Award. Each physician should claim only those credits that he/she actually spent in the activity.

This activity is approved by the American College of Emergency Physicians for 2.5 hours of ACEP Category 1 credit.

Thomson American Health Consultants is accredited as a provider of continuing nursing education by the American Nurses Credentialing Center's Commission on Accreditation. Provider approved by the California Board of Registered Nursing, Provider Number CEP 10864. Trauma Reports ™ is approved for 2.2 contact hours. This program is approved by the American Association of Critical-Care Nurses (AACN) for 2.2 nursing contact hours. Provider # 10852.

This is an educational publication designed to present scientific information and opinion to health professionals, to stimulate thought, and further investigation. It does not provide advice regarding medical diagnosis or treatment for any individual case. It is not intended for use by the layman. Opinions expressed are not necessarily those of this publication. Mention of products or services does not constitute endorsement. Clinical, legal, tax, and other comments are offered for general guidance only; professional counsel should be sought for specific situations.

This CME/CE activity is intended for emergency, family, osteopathic, trauma, surgical, and general practice physicians and nurses who have contact with trauma patients.

It is in effect for 24 months from the date of publication.

THOMSON™
AMERICAN HEALTH CONSULTANTS

Subscriber Information

Customer Service: 1-800-688-2421

Customer Service E-Mail: customerservice@thomson.com
Editorial E-Mail: martha.dendinger@thomson.com

World Wide Web page: http://www.ahcpub.com

FREE to subscribers of *Emergency Medicine Reports, Pediatric Emergency Medicine Reports, Practical Summaries in Acute Care*, and *ED Management.*

For Customer Service,
Please call our customer service department at **(800) 688-2421.** For editorial questions or comments, please contact **Martha Jo Dendinger**, Managing Editor, at martha.dendinger@thomson.com.

Figure 1. Acetabular Fracture

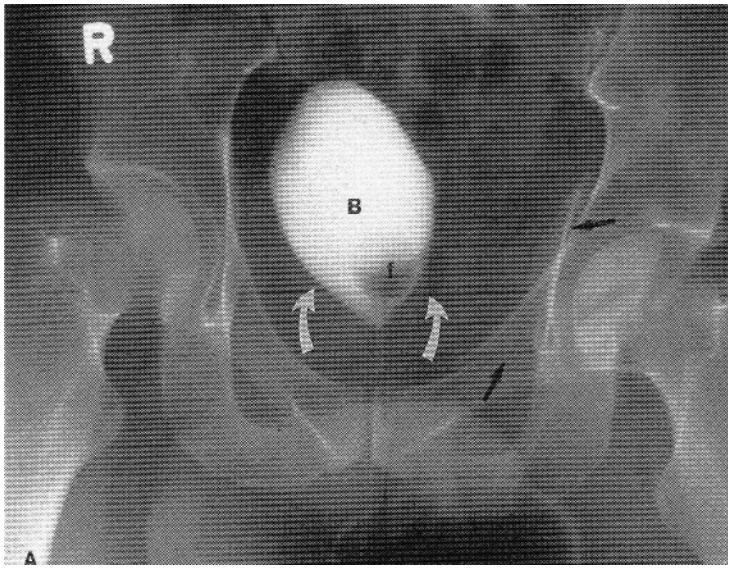

Figure 1. Acetabular Fracture. There is a left acetabular fracture. A cystogram was performed by instilling iodinated contrast into the patient's bladder (B) through the Foley catheter. The bladder is deformed and elevated by the pelvic hematoma (curved arrows).

Reprinted with permission: Wiest. *Fundamentals of Emergency Radiology.* Philadelphia: Elsevier;1996.

Table 1. Associated Injuries

• Closed head injury	• Liver
• Long-bone fracture	• Gastrointestinal tract
• Peripheral nerve injury	• Kidney
• Thoracic injury	• Urethra
• Bladder	• Mesentery
• Spleen	• Diaphragm

not involve the pelvic ring (e.g., fractures of single pubic ramus, iliac wing, sacrum, and avulsion fractures). The pelvic ring is intact, and these stable fractures generally heal rapidly. Avulsion fractures and those suggesting a single break in the ring are usually the result of less kinetic energy transfer, and hence have fewer sequelae.[11] These fractures may involve the anterior superior iliac spine, anterior inferior iliac spine, or the ischial tuberosities. Avulsion injuries of the anterior superior iliac spine or ischial tuberosities most commonly are seen in teenagers who have sustained an injury while participating in vigorous running or dancing. These fractures generally are treated conservatively with bed rest and gradual ambulation.

Type II. These are single fractures of the pelvic ring without displacement. These fractures commonly involve the pubis or sacroiliac (SI) joint, which are relatively mobile joints, allowing a single break to occur. These are stable fractures that are treated conservatively with bed rest. However, 25% of these patients will have a major soft-tissue injury and/or hemorrhage.[11] If displacement of the fracture fragment is found, a second break in the ring usually exists.

Type III. These involve double fractures of the pelvic ring. These are unstable fractures resulting from high-energy pelvic trauma and often are associated with life-threatening injuries. Examples include straddle fractures, open book fractures, bucket handle fractures, Malgaine fractures, and pelvic dislocations.

A Malgaine fracture is a fracture of the pubis and ischium associated with a vertical shear fracture of the ipsilateral ilium, fracture/dislocation of the sacroiliac joint, or a vertical fracture of the sacrum. This is an extremely unstable pelvis, often associated with leg shortening. There is rupture of the entire pelvic floor, and this fracture is rotationally and vertically unstable. It usually results from a fall from a height onto lower limbs. Approximately 20% of all patients who sustain a fatal injury in a motor vehicle crash also have a Malgaine fracture.[12]

Type IV. These involve a fracture of the acetabulum (*Figure 1*). Although these fractures only account for 5% of all pelvic fractures, they may affect weight-bearing activities.[11] Fractures can alter the integrity of the anterior or posterior column or the dome of the acetabular cavity.

Classification by Mechanism of Injury. The Young and Burgess Classification. This classification system has good predictive value of mortality and morbidity by incorporating an appreciation of the causative forces and resulting injury patterns.[13]

Lateral Compression (LC) Fractures I, II, III. Lateral compression is the most common type of pelvic fracture (about 60% of injuries) and has an associated 6.6% mortality.[13] Force is applied to one side of the pelvis (e.g., when a patient is "t-boned" in a motor vehicle crash). With these injuries the pelvic ring implodes or collapses; one side rotates medially toward and sometimes beyond the midline, usually on a posteriorly based perpendicular axis. Usually, the sacrotuberous and sacrospinous ligaments are intact. While bleeding is less common, LC fractures more often are associated with life-threatening torso injury. Thirty percent of these patients present in shock, usually from extra pelvic bleeding, and 20% develop adult respiratory distress syndrome (ARDS) with its associated high mortality rate.[13-15]

Anterior-Posterior Compression (APC) Fractures. In these fractures, force is applied directly to the pubis (e.g., when a pedestrian is struck frontally by a car). These fractures compose 15% of pelvic fractures and have an associated mortality of approximately 20%. They are associated with the largest amount of blood loss. Sixty percent of these patients present in shock, and 20% develop ARDS.[13-15]

Unclassified Injuries. Open fractures: These often occur with motorcycle accidents and struck pedestrians. An open fracture occurs when there is communication between the pelvic fracture and a laceration or puncture of the skin, vagina, bowel, or rectum. These are associated with a mortality rate as high as 50% from massive hemorrhage, major vessel injury, and sepsis. Controlling hemorrhage with wound packing, MAST trousers, or angiography can reduce the mortality rate to below 10%.[16] Many

of these patients will require a colostomy. Principles of care include rapid control of bleeding, fecal diversion, and wide local debridement of nonviable tissue. *Straddle injury:* This injury usually causes fractures of bilateral pubic rami and often is the result of a high-speed motorcycle accident or a fall from great height. Genitourinary and renal damage are common.

Associated Injuries. In pelvic fractures and high-energy injuries, many patients have associated injuries. (*See Table 1.*)

The high association of multisystem injury in patients with pelvic fractures should lead to a thorough evaluation of all organ systems based on injury mechanism, patient history, and current examination of the patient. A computed tomography (CT) head scan should have a high priority in patients with altered level of consciousness; patients with the possibility for an associated long-bone fracture should undergo focused appropriate imaging, remembering that patients with associated brain injury may be unable to identify sites of pain. Serial examinations are also an important tool to identify potential areas of injury.

Significant thoracic trauma also is associated with pelvic fractures, and the patient should be evaluated for pneumothoraces, or hemothoraces and blunt aortic injury. Aortic injury is most common in patients with lateral compression mechanisms. Initially, a chest radiograph is used to identify obvious abnormalities or findings that are significant for more serious underlying injury. Spiral CT can be used to obtain more detailed imaging. In patients who require immediate operative intervention for life-threatening hemorrhage, transesophageal echocardiography can be quite helpful for aortic injury.

Intra-abdominal injuries often accompany pelvic fractures and may involve the liver, spleen, or mesentery. The reported incidence of diaphragmatic injuries is relatively low, but the statistics may be badly under reported because the diagnosis can be missed. The perineum should be examined carefully on the secondary survey for vaginal and/or perirectal laceration, signifying an open pelvic fracture. These injuries must be dealt with expeditiously to avoid the complications of retroperitoneal sepsis.

Urinary tract injuries are common, especially with displaced pelvic fractures. With major pelvic injuries, it is safe to assume a urinary tract injury exists until proven otherwise. Urethral injuries are twice as common as bladder injuries and are the most common lower urinary tract injuries associated with pelvic fractures. Signs include gross hematuria, blood at the meatus, a high-riding prostate, and scrotal ecchymosis. The high-riding prostate is the result of shearing of the prostate from the pelvis with subsequent migration superiorly and a hematoma filling the normal position of the prostate. If there is no meatal blood and the rectal examination is normal, then a gentle attempt at Foley catheter placement may be tried. If any resistance is encountered, assume a urethral injury exists and consult urology for suprapubic cystostomy.[17] Male patients should have a retrograde urethrogram before a Foley catheter is placed if there is blood at the meatus.

The most common associated lower urinary tract injury in the male is a posterior urethral tear and should be suspected in any patient who presents with gross hematuria and a pelvic injury.[17]

Anterior urethral tears commonly are associated with straddle injuries, but actually occur infrequently.

Bladder contusions are the least serious bladder injury. They are common and usually resolve without complications. They result from an incomplete tear of the bladder mucosa and usually are treated with short-term bed rest until hematuria resolves. Bladder rupture occurs in about 5-8% of pelvic fractures.[19] A full bladder usually will rupture at the dome, which is the weakest part of the bladder wall and the only part of the adult bladder covered by peritoneum. Intraperitoneal bladder ruptures are more commonly the result of seat belt compression of a full bladder, representing 20-40% of traumatic bladder ruptures.[19] An intraperitoneal bladder rupture requires surgical repair because of the risk of associated chemical peritonitis. It is diagnosed via retrograde cystogram (voiding cystourethrography).

An empty bladder usually will not rupture but may be lacerated by a bony fragment producing an extra-peritoneal rupture; 50-80% of bladder ruptures associated with pelvic fracture are extraperitoneal and usually occur near the base of the bladder.[19] The mechanism is believed to be a burst injury or the shearing force of the deformed pelvic ring. The pelvic fracture itself usually does not cause the bladder perforation. The bladder must be distended fully during the evaluation, and a post-void film is done. The post-void film is important because posterior tears may not be evident in a simple anterior-posterior film; 10% of bladder ruptures are detected only on post-drainage films.[19] Some practitioners advocate the use of a CT cystogram as a more sensitive detector of small bladder rupture as well as soft-tissue injury. A cystogram of an extraperitoneal bladder rupture may show extravasation around the base of the bladder and may extend into the thigh and penis; these injuries usually are treated with only Foley catheter drainage.

Combined intraperitoneal and extraperitoneal bladder injuries occur in approximately 10% of bladder ruptures. The mortality rate for combined injuries approaches 60%, owing to the severity of concomitant injuries.[19] Penetrating pelvic trauma also can result in bladder injuries. There is a high association with intra-abdominal injury with penetrating trauma, and surgical exploration often is mandated. The cystogram may be negative in patients with small caliber bullet wounds; these injuries sometimes are diagnosed only at exploratory laparotomy.

Initial Management

The priority for a patient with a significant pelvic injury is the same as any trauma patient with multisystem injury. Immediate airway control is critical and endotracheal intubation should be performed in any patient in extremis or in whom there is a suspicion of significant pelvic trauma. Endotracheal intubation will help facilitate the evaluation process and allow for adequate analgesia. The adequacy of oxygenation and ventilation should be monitored continuously, and an arterial blood gas (ABG) measurement can be extremely helpful.

Assessment of hemodynamic stability follows; some patients with significant blood loss will present with classic findings (e.g.,

hypotension and tachycardia); other younger patients may compensate for blood loss relatively well, so a high degree of suspicion is critical. A significant base deficit on arterial blood gas measurement is also a marker of volume depletion. Ongoing resuscitation to maintain stability also should be monitored and fluid totals carefully recorded; these patients almost always are bleeding, and a rapid search for the source is imperative.

Geriatric patients also represent a rapidly growing population with unique considerations and requirements. In addition to the presence of co-morbidities (e.g., diabetes, chronic obstructive pulmonary disease, and renal insufficiency), they are much more likely to develop multisystem organ disease during their hospitalization.

Because of the high incidence of multisystem trauma, patients with pelvic fractures may be unstable from other entities, in addition to pelvic fracture bleeding, and should be evaluated for tension pneumothorax, hemothorax, intra-abdominal injury, and bleeding from lower extremity fractures.

Caring for a patient with a pelvic fracture can be extraordinarily challenging. It is important to anticipate problems; these patients often have multiple injuries and can decompensate quite quickly.

Large bore intravenous access is mandatory in all patients with pelvic fractures. Every patient should have blood type and cross-matched and immediately available. In patients who are unstable, it is important to anticipate the need for coagulation factors (e.g., fresh frozen plasma and platelet packs). Hypothermia can be extremely problematic. It is wise to warm all fluids and blood early in the resuscitation. Finally, all patients with pelvic fractures must be assumed to have multiple injuries. The evaluation process must be rapid. It is important to anticipate the need for consultation and have all resources available when needed. The algorithms in Figures 2 and 3 may be useful in managing the pelvic trauma patient based upon the patient's level of hemodynamic stability.

Physical Examination

A careful physical examination is part of every trauma patient's evaluation and should be performed following the primary survey. In general, patients who have pelvic fractures will complain of pain. They may not complain of direct pelvic pain but often complain of lower abdominal pain, hip pain, or low back pain. Careful abdominal examination should be performed. Retroperitoneal injury, particularly if accompanied with significant blood loss, often will produce abdominal distension with tympany. The abdomen should be evaluated for bruising and tenderness.

The genitourinary tract should be examined with careful attention to identify blood at the urethral meatus in men, a sign of urethral disruption. In addition, suprapubic pain, tenderness, or the inability to void strongly suggests either a bladder or urethral injury; however, the ability to void does not rule out one. A careful rectal examination should be performed to evaluate rectal tone and the position of the prostate. A high-riding prostate also strongly suggests a urethral injury.

Lower extremities should be evaluated for concomitant fractures as well as their position. Some patients with significant posterior pelvic fractures often have unopposed motion of the ipsilateral psoas muscle, thus, that hemipelvis migrates cephalad and shortens the extremity. Careful neurologic examination should be performed with attention to the lower extremities. Patients with pelvic fractures may have lower extremity sensory or motor changes, some of which may be identifiable at the initial presentation.

The pelvis should be examined carefully. Rocking the pelvis is not considered to be an appropriate way to examine the pelvis. In addition to producing significant pain in patients with pelvic fractures, vigorous motion may cause recurrent bleeding in patients with unstable pelvic fractures. Thus, this maneuver should be avoided. Instead, the correct way to examine for pelvic stability is to gently attempt to compress the pelvis medially by squeezing the pelvis at the level of the iliac crest. If the pelvis is stable, there will be no motion. In patients with an unstable pelvis, there will be give with gentle manual compression.

The following physical findings may be helpful in patients with suspected pelvic fractures. Earle's sign is present when, on rectal examination, there is a large hematoma present or there is tenderness along the fracture line. A bony prominence also may be palpable. Destot's sign is a superficial hematoma seen above the inguinal ligament or on the scrotum. Roux's sign is present when the distance measured from the greater trochanter to the pubic spine is diminished on one side compared with the other. This finding suggests an overlying fracture of the anterior pelvic ring.

Laboratory Work

All patients with a suspected pelvic fracture should have routine chemistries and a complete blood count performed. The urine should be examined for gross or microscopic hematuria. The majority of patients with a bladder injury will have gross or microscopic hematuria; however, 5% will have a normal urinalysis.[19] ABG measurements are useful, especially early, to determine if there is a base deficit and the degree of acidosis. The serum lactate level also is useful as a measure of the adequacy of resuscitation. Coagulation profiles should be followed because patients with severe injury commonly develop coagulopathies.

Radiologic Evaluation

Plain Films. Every patient at risk for a pelvic fracture should be screened with an AP pelvic film. Patients who are hemodynamically stable, awake, and alert, who have no complaints of pelvic pain, and who are nontender on examination, do not require radiographic evaluation. However, any patient with a significant mechanism of injury and the potential for multitrauma, patients unable to provide a history, and those who are hemodynamically unstable, must be imaged.

The pelvic radiograph must be examined carefully for evidence of fracture. A systematic approach will minimize missed

Figure 2. Stable Algorithm

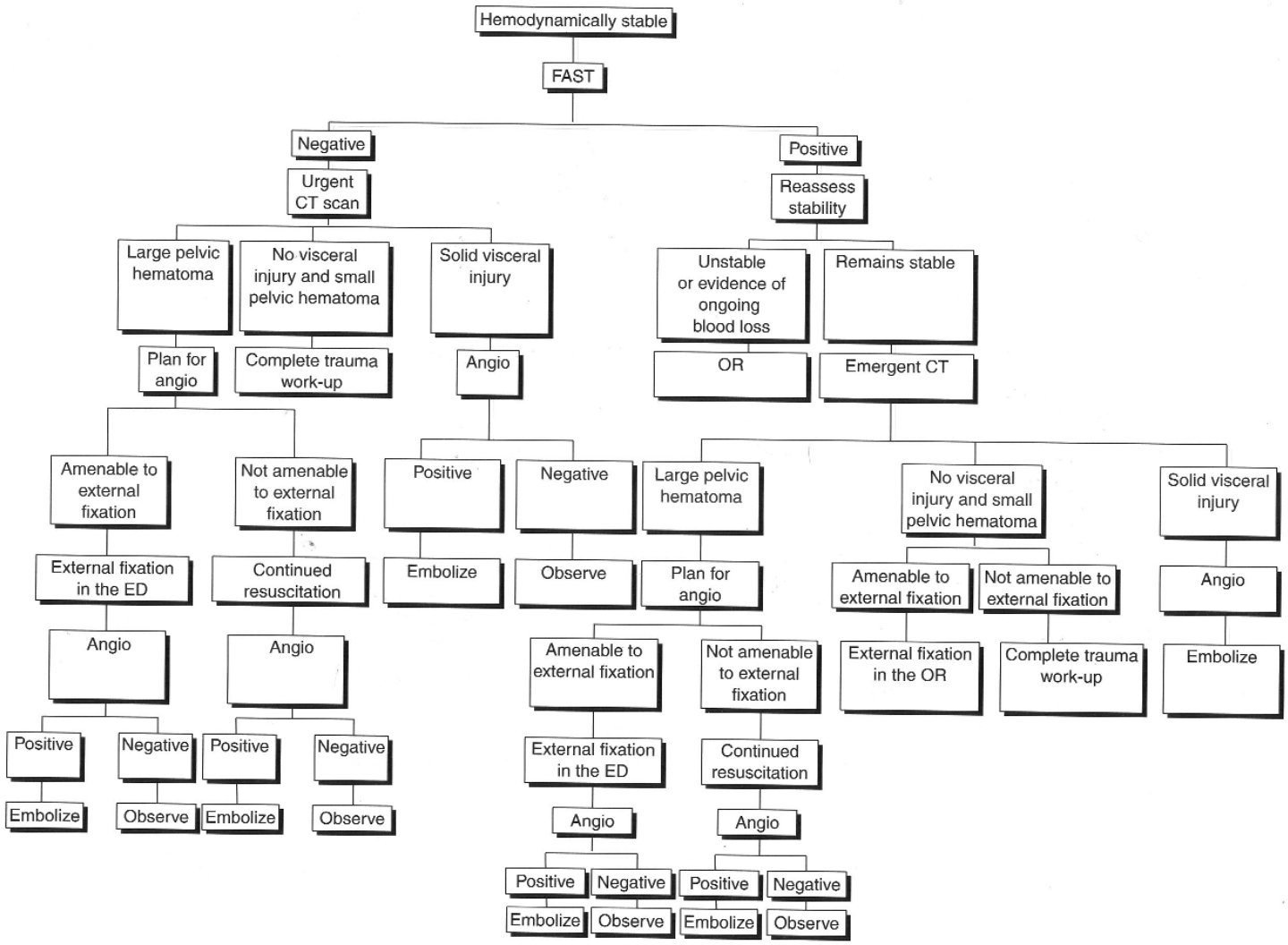

Reprinted with permission: Mattox K, et al. *Trauma*. New York:McGraw Hill;2000:824.

fractures. Initially, we should ignore the pelvic bones and evaluate the soft tissue for signs of inflammation or foreign bodies. The next step is to examine the lumbar spine for evidence of fracture and the femoral head and neck for signs of injury. Finally, the pelvis itself should be examined. It is useful to start with the three big circles that form the majority of the pelvis. The two circles that represent the superior and inferior rami should be examined for fracture or loss of continuity of the cortices, which will signify more subtle fractures. Finally, the circle that represents the pelvic inlet should be examined. Then, the SI joints should be examined for width and the sacral bone then examined. The arcuate lines of the sacrum should each be traced; this will identify subtle fractures. The iliac bones should be examined next, followed by each acetabular surface. It is important to trace both the anterior and posterior lip of the acetabulum to identify more subtle fractures.

It is also important to remember that the pelvis is a circle. It is difficult to break the pelvis in a single place. Virtually all pelvic fractures have at least two breaks. If one identifies a single pelvic fracture, a careful search for a second fracture is essential. In addition, plain films can underestimate both the number and severity of pelvic fractures. This fact is particularly evident in the posterior elements. The gastrointestinal tract may obscure subtle fractures. Even badly displaced posterior fractures may be difficult to see on plain x-ray because they are viewed only in a single projection.

Alternative views may be helpful. Inlet views place the radiographic beam at 45 degrees and shoot through the pelvis. These are most helpful in identifying sacral fractures or subtle anterior element fractures. Outlet views place the beam at 45 degrees with the beam sent through the anterior pelvis. These provide additional information about the sacrum at the SI joints. Judet views involve bumping the patient up and directing the beam at the acetabular surfaces and are very useful in identifying acetabular fractures.

CT Imaging. Abdominal and pelvic CT scans offer advan-

Figure 3. Unstable Algorithm

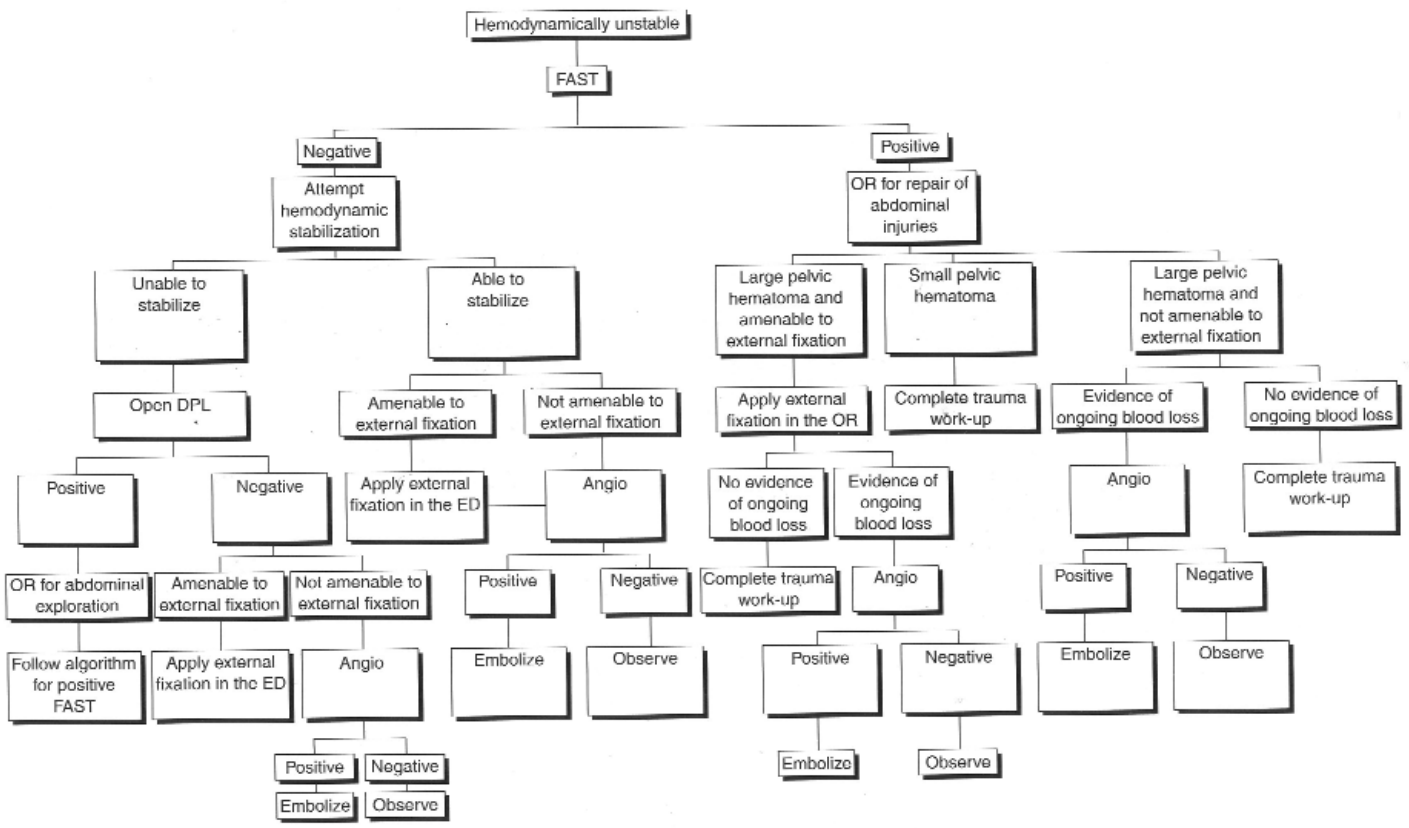

Reprinted with permission: Mattox K, et al. *Trauma*. New York:McGraw Hill;2000:824.

tages in many patients who have sustained pelvic fractures. The ability to image the abdomen and pelvis simultaneously can be of great value. Clearly, CT imaging has become the gold standard imaging for blunt, solid, and hollow visceral injuries following blunt trauma. In addition, many patients who have pelvic fractures may have intra-abdominal injury without hemoperitoneum that will be missed with either ultrasound examination or diagnostic peritoneal lavage.

CT imaging also allows for better definition of pelvic fracture anatomy. Because CT images in three dimensions, it easily can define anterior-posterior displacement, which can be difficult to see on plain x-rays. Three-dimensional reconstructions can provide sophisticated images that will help define anatomy and operative fixation.

The final advantage of CT imaging is its ability to quantify intra-abdominal and retroperitoneal hemorrhage. Occasionally, patients with pelvic vascular injuries will have contrast blush or active extravasation at the time of the CT scan.

The disadvantage of CT imaging involves the time required and the small—but real—chance of IV contrast reaction. While CT imaging can be extremely helpful, it is contraindicated in patients who are hemodynamically unstable because the patient usually must be transferred out of the resuscitation area for the study. In this case, other methods of evaluation must be employed, or the patient must be stabilized before CT imaging is appropriate.

Treating Pelvic Fracture Bleeding

Treating pelvic fracture bleeding is a significant challenge. First, it is necessary to localize the pelvis as the source of blood loss. Other areas should be examined (e.g., the thorax and the abdomen). The general rule of thumb is that each major closed long-bone fracture results in a loss of several units of blood. When patients show signs of hemorrhage that cannot be ascribed to the chest, abdomen, or muscle compartments, pelvic fracture bleeding must be considered.

It can be very difficult to discern retroperitoneal hemorrhage from intra-abdominal hemorrhage on physical examination. Several modalities can be extremely helpful in rapidly assessing the abdomen for blood loss. Diagnostic peritoneal lavage (DPL) is a simple test that can be performed at the bedside. In patients with pelvic fractures, it is imperative to do this test using a supraumbilical open technique, which radically decreases the chances of inadvertently tapping any retroperitoneal hemorrhage.[20, 21] Aspiration of 5 to 10 mL of gross blood generally is considered an indication for emergent laparotomy. Results from a recent study demonstrated that 84% of patients with grossly positive tap had life-threatening hemorrhage at the time of laparotomy.[21] Decision

making can be more difficult in cases where patients have a negative tap but bloody lavage fluid. False-positive lavage can result from diapedesis of red cells from retroperitoneal hemorrhage. DPL can be too sensitive, and small quantities of blood in the peritoneum may turn the lavage positive. This major risk is performing surgery on an insignificant intra-abdominal injury at the time the patient is exsanguinating from pelvic fracture bleeding.

Focused assessment with sonography for trauma (FAST) examination largely has replaced DPL in many trauma centers. FAST examination is portable and rapid and often can identify even small quantities of intraperitoneal fluid. It can be repeated if equivocal and should be able to identify large-volume hemorrhage in virtually every patient if the operator is skilled. In the hemodynamically unstable patient, it can be extraordinarily helpful in rapidly identifying free intraperitoneal fluid. If no free fluid is identified, then the focus for finding the source of hemorrhage may be directed toward the pelvic injury. While the amount of fluid necessary to turn a FAST examination positive may vary based upon body habitus, a FAST examination is usually positive with 200-300 mL of intra-abdominal blood.[22,,23] Thus, hemodynamically unstable patients with a positive FAST examination almost certainly should undergo prompt laparotomy.

Methods of Hemodynamic Stabilization

External Compression. External compressive devices are considered the first-line therapy for treatment of pelvic fracture bleeding. External compression reduces the pelvic bony elements, restoring more normal pelvic anatomy. While this almost certainly will not stop major arterial bleeding, it can be helpful in tamponading venous bleeding or reducing blood loss from fracture fragments.[24] A number of methods exist to achieve this result. Among the simplest is placement of a bed sheet under the patient with subsequent crisscrossing across the patient and then tying it down.[25] While not elegant, it can be extremely effective and is perhaps most useful when transferring patients from rural EDs to a higher level of care.

The medical anti-shock trousers (MAST) garment was developed for use in the field. Although its role in patients with hypotension is debated, it can be quite helpful in patients with a pelvic fracture. The MAST garment acts as a pelvic splint and can reduce fracture fragments similar to the bed sheet with the advantage of pressure regulation, making this a more attractive alternative. It may be particularly effective when transporting patients within the hospital; keeping the fracture fragments stable reduces the blood loss that so often is associated with patient movement (e.g., from the stretcher to the bed).[26] Disadvantages of using the MAST garment include a potential for increased intra-abdominal as well as intrathoracic pressure, difficulty with oxygenation and ventilation, renal dysfunction, and limb ischemia.

A number of pelvic clamps have been devised that can compress the posterior fragments of a pelvic fracture. The disadvantage of the pelvic clamps is that they require significant expertise, and general anesthesia frequently is required to place them. The advantages include good reduction of the posterior pelvic elements and the ability to be adjusted to give better access to the groin or abdomen for angiography or laparotomy.

One of the greatest advances recently has been the development of the pelvic binder. The pelvic binder acts similarly to the bed sheet, putting even pressure on the pelvis. The binder can be placed and, then, adjusted using the Velcro straps. This simple device can dramatically reduce displaced fracture fragments. Its advantages are its ease and rapidity of use. However, it must be adjusted to obtain access to the groin or anterior abdominal wall.

External fixation offers a number of advantages in patients with skeletally unstable fractures. The skeletal rigidity provided by an external fixator is probably superior to all other methods, except the posterior pelvic clamp. The external fixator can provide definitive stabilization in some patients with pelvic fractures. In some level I or II trauma centers where orthopedic expertise is immediately available, the external fixator can be applied immediately. Similar to the MAST or pelvic clamps, external fixation almost certainly helps tamponade bleeding from bony fragments and by reducing pelvic volume, it almost certainly stops venous bleeding as well. The external fixator can be adjusted to give access to the abdomen for laparotomy or to the groin for angiography.

Angiography and Selective Embolization. Angiography has the ability to precisely define a pelvic vascular injury. In addition, transcatheter embolization can provide definitive hemostasis in patients with pelvic fractures.[27] Embolization has been demonstrated to be both safe and effective in obtaining pelvic hemostasis.[28,29]

Identifying patients in need of embolization can be difficult. It is wise to have a pre-established limit on the amount of blood transfused for pelvic bleeding to rapidly identify patients who may benefit from embolization.

The Eastern Association for the Surgery of Trauma suggests the following guidelines for angiography: 1) patients with major pelvic fracture who have signs of ongoing bleeding after non-pelvic sources have been ruled out; 2) patients with major pelvic fracture who are found to have bleeding in the pelvis who cannot be controlled adequately at the time of laparotomy; and 3) patients with evidence of arterial extravasation of intravenous contrast in the pelvis by CT imaging.[25]

Our institutional indications for angiography are: 1) patients with pelvic fracture with ongoing hypotension and a negative FAST examination; 2) larger expanding hematoma seen at the time of laparotomy; 3) more than four units of blood for pelvic fracture bleeding in 24 hours; 4) more than six units of blood for pelvic fracture bleeding in 48 hours, and 5) evidence of vascular injury seen on CT imaging.

Diagnostic angiography should involve a flush aortogram first, which may identify very large pelvic vascular injuries, allowing the angiographer to deal with them expeditiously. In addition, aortography may identify other injuries (e.g., concomitant lumbar artery injuries). Once the arterial injury is identified, it can be embolized with a number of substances (e.g., polystyrene spheres, wire coils, or hemostatic gelatin sponges).[29] Ideally, one would like to occlude the blood vessel at its point of bleeding but not flush hemostatic material distally. Dual

embolization potentially increases complications such as impotency or perineal ischemia. Contrast studies of the genitourinary tract should be delayed until after angiography is completed. If positive, contrast extravasation of the pelvis may limit the ability of the angiographer to identify pelvic vascular injuries. Independent predictors of finding bleeding on angiography include: 1) age more than 55 years; 2) absence of long bone fractures; and 3) emergent angiography.[29]

Direct Operative Control of Pelvic and/or Abdominal Hemorrhage. Many patients with pelvic fractures have concomitant intra-abdominal injuries that are best treated with operative control. It is tempting, then, to attempt direct operative control of the pelvic fracture bleeding; in the majority of situations this is unwise. The main hypogastric vessel artery is extremely short and sequences into a large number of vessels deep in the pelvis. It can be extraordinarily difficult to identify the precise source of bleeding deep in the pelvis. In addition, unroofing the hematoma loses all tamponade effect that the hematoma has provided. Venous injuries that have stopped bleeding may bleed again with real force once the pelvic fracture hematoma is entered.

Main hypogastric ligation typically is not selected as an operative procedure in most patients. While ligation may drop the perfusion pressure to the injured blood vessel, it may be insufficient to stop the bleeding, and, more importantly may negate the potential for the use of angiography, or the interventional radiologist may have to attempt access to the injured blood vessel through a ligated hypogastric artery.

Direct operative control may be indicated for selected patients; some authors suggest that patients with ongoing shock and stable pelvic fractures are more likely to be bleeding intraperitoneally and should undergo laparotomy; similar patients with unstable pelvic fractures are more likely to have a pelvic bleeding source, and therefore, should undergo angiography, and then laparotomy if necessary.[31-33] Patients who present with hemorrhagic shock and a unilaterally absent femoral pulse generally have injury to the common iliac or external iliac artery. Prompt therapy obviously is necessary to salvage these patients; they are best served by direct operative control and bypass grafting of the injured blood vessel. These patients typically present with badly displaced posterior pelvic fractures and have essentially sustained a traumatic hemipelvectomy. The leg is attached only by skin and soft tissue.

Patients who present in refractory hemorrhagic shock from pelvic fracture bleeding sometimes may not survive until the angiography team can be mobilized; in selected centers, there may be a rule for direct operative control of this type of pelvic fracture bleeding in these patients.

Finally, bony fixation can stop bleeding. In patients with badly displaced SI joints, early percutaneous fixation is extremely attractive. The percutaneous nature of the procedure means that the pelvic hematoma is undisturbed. The SI joint is closed down and bony stability provided. While this action will not stop major arterial bleeding in most cases, it reduces the volume in the pelvis, provides definitive fixation, and allows for early mobility.

An Approach to Pelvic Fracture Bleeding. Several algorithms to treat pelvic fracture bleeding have been developed. A number of decision nodes exist; the first is to determine the hemodynamic stability of the patient. Hemodynamically unstable patients are managed in a very different manner than hemodynamically stable patients (*See Figures 2 and 3.*)

Complications of Pelvic Fractures

Thromboembolism is probably the most common complication following a pelvic fracture. The force needed to fracture a pelvis almost always disrupts some of the pelvic veins. The incidence of proximal deep vein thrombosis (DVT) with pelvic fractures has been reported to be 25-35%. The incidence of symptomatic pulmonary embolism is 2-10%.[34] Certainly, every patient with a pelvic fracture should receive prophylaxis for DVT. Unfortunately, the potential hemorrhagic complications of pelvic fractures may make prophylaxis also somewhat dangerous. Recognizing a DVT on physical examination may be challenging on a patient with a pelvic fracture secondary to lower extremity swelling from fractures or fluid resuscitation. Duplex ultrasound examinations can be helpful in assessing for proximal venous thrombosis but almost never will be able to image the pelvic venous structures.

If possible, all patients should receive either unfractionated heparin or low molecular weight heparin and have sequential compression devices placed. If both therapies are not possible, at least one is better than no prophylaxis at all. Certainly, early fixation and aggressive mobilization are key to preventing DVT. Despite all efforts, however, these may not be possible.

Patients with significantly displaced pelvic fractures or those who have other concomitant critical illness injuries, should be evaluated for placement of a prophylactic inferior vena cava filter. While some may consider this procedure overly aggressive, prophylactic filter placement is relatively safe and should decrease the rate of pulmonary embolism.[35,36] With the advent of retrievable filters, filters can be placed and then removed some weeks later when the risk of thromboembolic complications may be less significant.

The mortality for pelvic fractures is approximately 5-10%.[2] In the past, this was due to hemorrhage, but it is no longer the case. Better organization of trauma systems and trauma centers has allowed for more expeditious management of pelvic fracture bleeding. While almost half of patients with pelvic fracture who die do so from hemorrhage, the hemorrhage may be from sources other than the pelvis. Other common sources of major morbidity involve traumatic brain injury, sepsis, and multiple organ failure.

Unfortunately, patients who survive may have significant ongoing morbidity. Pelvic fractures have significant associated pain, especially if fractures involve the sacrum or SI joints. Malunion or delayed union can cause leg length discrepancy or malrotation of the hemipelvis; both can alter gait mechanics.[38] Other long-term complications involve sexual dysfunction and impotence. There is a surprising rate of genitourinary and lower gastrointestinal symptoms in patients with pelvic fractures, even

in those patients who did not have an associated urologic or intestinal injury. Neurologic problems or impingement on visceral organs can occur secondary to the disturbed integrity of the pelvic ring.[39,40] It is not clear whether treatment decisions affect long-term outcome. While some practitioners would argue that meticulous fracture fixation that restores the pelvic anatomy as close to normal as possible improves long-term outcome, the data are unconvincing. More work will need to be done to define long-term outcome and the role that therapy may have in it.

Penetrating Pelvic Injuries

Penetrating pelvic injury is treated largely the same as penetrating intra-abdominal injury. All structures in the pelvis are at risk from penetrating injury and must be evaluated. As with abdominal injury, any patient with transpelvic penetration and hypotension or peritonitis is best served by prompt laparotomy. In addition, patients with rectal bleeding can be explored for diagnosis, or they will require a colostomy. The abdomen can be explored first, followed by direct operative exploration of the pelvis. Injuries are identified and treated.

More controversial is the patient who presents hemodynamically stable following penetrating injury to the buttock or pelvis. Mandatory laparotomy in those patients will be negative approximately 95% of the time.[41,42] Some authors advocate expectant observation in patients who are hemodynamically stable, and who do not have peritoneal signs, gross hematuria, or rectal bleeding.[41,42] There are several approaches: The first involves serial physical examinations.[43] A group at Los Angeles County Hospital has demonstrated clearly that careful physical examination during a 24-hour period will identify virtually all patients with significant injury. It is important to remember that this is a group of highly sophisticated clinicians who practice in a high volume trauma center, and the patients are managed on strict protocol. In doing so, missed injuries are identified early and treated before the patient suffers irreversible consequence.

The second option is to evaluate the patient with CT imaging. Historically, the triple contrast CT imaging was first described for the evaluation of patients with pelvic and retroperitoneal trajectories. In the original study, the abdomen was evaluated by DPL, and then the patient underwent CT imaging with oral, rectal, and intravenous contrast, which allowed the clinician to evaluate the patient for injuries that may not have been obvious on first presentation.

More recently, triple contrast CT imaging has been advanced as a way to image both the abdomen and retroperitoneum. Early results have been quite good. These include retroperitoneal colon injuries and injury to the ureter or bladder. CT imaging should identify trajectory adjacent to other important structures (e.g., vascular structures or the rectum), then, these can be investigated further with adjunctive studies such as proctoscopy and/or angiography.

Conclusion

The management of pelvic trauma can be challenging, but the same principles guiding all trauma care should be applied. Bleeding from blunt pelvic injury can be among the most difficult challenges facing any clinician caring for injury. It is important to keep institutional resources in mind and mobilize patients early to maximize outcome.

References

1. Kinzl L, Burri C, Coldewey J. Fractures of the pelvis and associated intrapelvic injuries. *Injury* 1982;14:63.
2. Gilliland MD, Ward RE, Barton, RM. Factors affecting mortality in pelvic fractures. *J Trauma* 1982;22:691.
3. Starr AJ, Griffin DR, Reinert CM, et al. Pelvic ring disruptions: Prediction of associated injuries, transfusion requirement, pelvic arteriography, complications, and mortality. *J Orthop Trauma* 2002; 16:553-561.
4. O'Neill PA, Riina J, Sclafani S, et al. Angiographic findings in pelvic fractures. *Clin Orthop Relat Res* 1996;329:60-67.
5. Allen CF, Goslar PW, Barry M, et al. Management guidelines for hypotensive pelvic fracture patients. *Am Surg* 2000;66:735-738.
6. Wubben RC. Mortality rate of pelvic fracture patients. *Wis Med J* 1996;95:702-704.
7. Wolinsky PR. Assessment and management of pelvic fracture in the hemodynamically unstable patient. *Orthp Clin North Am* 1997; 28:321-329.
8. Henry SM, Pollack AN, Jones AL, et al. Pelvic fracture in geriatric patients: A distinct clinical entity. *J Trauma* 2002;53:15-20.
9. Izawa JI, Dinney CP. Surgical anatomy of the pelvis. In: Levy D. *Urology Pearls of Wisdom*. Boston;Boston Medical Publishing: 2001.
10. Coppola PT, Coppola M. Emergency department evaluation and treatment of pelvic fractures. *Emerg Med Clin North Am* 2000;18: 1-27.
11. Jerrard DA. Pelvic fractures. *Emerg Med Clin North Am* 1993; 11:147-163.
12. Bucholz R. The pathological anatomy of Malgaigne fracture-dislocations of the pelvis. *J Bone Joint Surg Am* 1987;63A:400.
13. Burgess AR, Eastridge BJ, Young JW, et al. Pelvic ring disruptions: Effective classification system and treatment protocols. *J Trauma* 1990;30:848-856.
14. Cryer HM, Miller FB, Evers BM, et al. Pelvic fracture classification: Correlation with hemorrhage. *J Trauma* 1988;28:973-980.
15. Dalal SA, Burgess AR, Siegel JH, et al. Pelvic fracture in multiple trauma: Classification by mechanism is key to pattern of organ injury, resuscitative requirements, and outcome. *J Trauma* 1989; 29:981-1000; discussion 1000-1002.
16. Richardson JD, Harty J, Amin M, et al. Open pelvic fractures. *J Trauma* 1982;22:533-538.
17. Henry SM, Tornetta P, Scalea TM. Damage control for devastating pelvic and extremity injuries. *Surg Clin North Am* 1997; 77: 879-895.
18. Demetriades D, Karaiskakis M, Toutouzas K, et al. Pelvic fractures: Epidemiology and predictors of associated abdominal injuries and outcomes. *J Am Coll Surg* 2002;195:1-10.
19. Gomez RG, Ceballos L, Coburn M, et al. Consensus statement on bladder injuries. *BJU Int* 2004;94:27-32.
20. Flint LM Jr, Brown A, Richardson JP, et al. Definitive control of

bleeding from severe pelvic fractures. *Ann Surg* 1979;189:709.
21. Moreno C, Moore E, Rosenberger A, et al. Hemorrhage associated with major pelvic fracture: A multispecialty challenge. *J Trauma* 1986;26:987-994.
22. Tiling T, Bouilon B, Schmid A, et al. Ultrasound in blunt abdominothoracic trauma. In: Borden J, Algoewer M, Reudi T, eds. *Blunt Multiple Trauma*. Marcel Dekker:NewYork;1990.
23. Kawaguchi S, Toyonaga J, Ikeda K, et al. Five point method: An ultrasonographic quantification formula of intra-abdominal fluid collection. *Japan J Acute Med* 1987;7:993-997.
24. Grimm MR, Vrahas MS, Thomas KA. Pressure-volume characteristics of the intact and disrupted pelvic retroperitoneum. *J Trauma* 1998;44:454-459.
25. DiGiacomo J, Scalea T, et al. Practice management guidelines for hemorrhage in pelvic fracture. The Eastern Association for the Surgery of Trauma Management Guidelines Workgroup 2001.
26. Flint L, Babikian G, Anders M, et al. Definitive control of mortality from severe pelvic fracture. *Ann Surg* 1990;211:703-707.
27. Maull KI, Sachatello CR. Current management of pelvic fractures: A combined surgical-angiographic approach to hemorrhage. *South Med J* 1976;69:1285-1289.
28. Velmahos GC, Chahwan S, Falabella A, et al. Angiographic embolization for intraperitoneal and retroperitoneal injuries. *World J Surg* 2000;24:539-545.
29. Velmahos GC, Toutouzas KG, Vassiliu P, et al. A prospective study on the safety and efficacy of angiographic embolization for pelvic and visceral injuries. *J Trauma* 2002;53:303-308.
30. Cwinn A. Pelvis and hip. In: Rosen P, Barkin R (eds). *Emergency Medicine-Concepts and Clinical Practice.* St. Louis: CV Mosby; 1992;617.
31. Eastridge BJ, Starr A, Minei JP, et al. The importance of fracture pattern in guiding therapeutic decision making with hemorrhagic shock and pelvic ring disruptions. *J Trauma* 2002;53:446-450.
32. Cooke RE, Keating JF, Gillespie I. The role of angiography in the management of haemorrhage from major fractures of the pelvis. *J Bone Joint Surg Br* 2002;84:178-182.
33. Bassam D, Cephas GA, Ferguson KA, et al. A protocol for the initial management of unstable pelvic fractures. *Am Surg* 1998;64: 862-867.
34. Montgomery KD, Geerts WH, Potter HG, et al. Thromboembolic complications in patients with pelvic trauma. *Clin Orthop Relat Res* 1996;329:68-87.
35. Langan EM 3rd, Miller RS, Caey WJ 3rd, et al. Prophylactic inferior vena cava filters in trauma patients at high risk: Follow-up examination and risk/benefit assessment. *J Vasc Surg* 1999;30:484-488.
36. Sekharan J, Dennis JW, Miranda FE, et al. Long-term follow-up of prophylactic greenfield filters in multisystem trauma patients. *J Trauma* 2001;51:1087-1090.
37. Poole GV, Ward EF, Griswold JS, Muakkassa FF, Hsu HS. Complications of pelvic fractures from blunt trauma. *Am Surg* 1992 Apr;58(4):225-231.]
38. Trafton PG. Lower – Extremity Fractures and dislocations. In: *Trauma*. Mattox-Feliciano-Moore 4th ed. New York:McGraw-Hill;2000.
39. Gautier E, Rommens PM, Matta JM. Late reconstruction after pelvic ring injuries. *Injury* 1996;27 Suppl 2:B39-46.
40. Brenneman FD, Katyal D, Boulanger BR, et al. Long-term outcomes in open pelvic fractures. *J Trauma* 1997;42:773-777.
41. Velmahos GC, Demetriades D, Cornwell EE 3rd. Transpelvic gunshot wounds: Routine laparotomy or selective management? *World J Surg* 1998;22:1034-1038.
42. Duncan AO, Phillips TF, Scalea TM, et al. Management of transpelvic gunshot wounds. *J Trauma* 1989;29:1335-1340.
43. DiGiacomo JC, Schwab CW, Rotondo MF, et al. Gluteal gunshot wounds: Who warrants exploration? *J Trauma* 1994;37:622-628.

CE/CME Questions

1. Which one of the following statements is true?
   A. More than 60% of pelvic fractures are the result of car accidents.
   B. Penetrating trauma to the pelvis always requires surgical exploration.
   C. Rupture of the diaphragm rarely is associated with pelvic trauma.
   D. Arterial blood gases measurement has little utility in the management of pelvic fractures.

2. Injury to the urethra:
   A. occurs less often than injury to the bladder.
   B. is the most common lower urinary tract injury associated with a pelvic fracture.
   C. is ruled out if there is no blood at the meatus of a male.
   D. can be diagnosed via the presence of Destot's sign.

CE/CME Objectives

Upon completing this program, the participants will be able to:

a.) discuss conditions that should increase suspicion for traumatic injuries;
b.) describe the various modalities used to identify different traumatic conditions;
c.) cite methods of quickly stabilizing and managing patients; and
d.) identify possible complications that may occur with traumatic injuries.

CE/CME Instructions

Physicians and nurses participate in this continuing medical education/continuing education program by reading the article, using the provided references for further research, and studying the questions at the end of the article. Participants should select what they believe to be the correct answers, then refer to the list of correct answers to test their knowledge. To clarify confusion surrounding any questions answered incorrectly, please consult the source material. **After completing this activity, you must complete the evaluation form provided and return it in the reply envelope provided in order to receive a certificate of completion.** When your evaluation is received, a certificate will be mailed to you.

3. The sacroiliac joints:
   A. are the weakest joints in the body.
   B. join the thinnest bones of the pelvis.
   C. are strengthened by the anterior longitudinal ligament.
   D. rarely are involved in pelvic fractures.

4. Which one of the following statements is correct?
   A. High-risk pelvic fractures typically involve diastasis of the pubis less than 2.5 cm.
   B. The majority of patients who die in a car crash have sustained a Malgaine fracture.
   C. Acetabular fractures account for less than 5% of all pelvic fractures.
   D. Anterior-posterior compression is the most common classification of pelvic fracture.

5. Which one of the following statements regarding anterior-posterior compression (APC) fractures is true?
   A. APC fractures bleed more than lateral compression fractures.
   B. The majority of victims with anterior-posterior compression fractures die despite intervention.
   C. The pubic symphysis is widened more than 2 cm in an APC I fracture.
   D. An APC III fracture has the lowest incidence of hemorrhage of all classifications.

6. Which one of the following statements regarding bladder rupture is true?
   A. Bladder contusions usually are treated with Foley catheter drainage until hematuria stops.
   B. The majority of bladder ruptures are detected only on post-voiding films.
   C. The majority of bladder ruptures are extraperitoneal.
   D. Intraperitoneal bladder ruptures usually are the result of puncture by bone fragments.

7. The Young and Burgess Classification of pelvic fracture:
   A. is based upon the number of associated injuries involved in a pelvic fracture.
   B. is useful for predicting mortality and morbidity.
   C. can be used to predict the likelihood of a posterior urethral tear.
   D. is based upon radiographic assessment of the number of breaks involved.

8. Which one of the following statements regarding penetrating pelvic injury is true?
   A. Transpelvic penetrating pelvic trauma and hypotension is best treated by laparotomy.
   B. Laparotomy in patients with penetrating pelvic injury reveals colon injury most often.
   C. Associated liver injury is more common with blunt pelvic trauma than is penetrating injury.
   D. Most patients with penetrating pelvic injury and shock can be managed nonoperatively.

9. Which of the following conditions is associated with an increased mortality from pelvic trauma?
   A. Shock on arrival
   B. Posterior urethral tears
   C. A base excess greater than or equal to –5
   D. Sacroiliac joint disruption
   E. A and C are correct.

10. The most common complication of a pelvic fracture is:
   A. Foot ischemia
   B. Thromboembolism
   C. Femoral vascular bleeding
   D. Peroneal nerve damage
   E. Inability to walk

Answers:

1. A
2. B
3. D
4. C
5. A
6. C
7. B
8. A
9. E
10. B

In Future Issues:

Ultrasound applications in the hypotensive patient

Thomson American Health Consultants
Building Six, Suite 400
3525 Piedmont Road NE
Atlanta, Georgia 30305-1515
Tel (404) 262-7436 Fax (404) 262-7837
www.ahcpub.com

THOMSON
AMERICAN HEALTH CONSULTANTS

Dear *Trauma Reports* Subscriber:

This issue of your newsletter marks the start of a new continuing medical education (CME) or continuing education (CE) semester and provides us with an opportunity to review the procedures.

***Trauma Reports*, sponsored by Thomson American Health Consultants,** provides you with evidence-based information and best practices that help you make informed decisions concerning treatment options and medical practices. Our intent is the same as yours — the best possible patient care.

The objectives of *Trauma Reports* are to:

1. Discuss conditions that should increase suspicion for traumatic injuries;
2. Describe the various modalities used to identify different traumatic conditions;
3. Cite methods of quickly stabilizing and managing patients; and
4. Identify possible complications that may occur with traumatic injuries.

Each issue of your newsletter contains questions relating to the information provided in that issue. After reading the issue, answer the questions at the end of the issue to the best of your ability. You can then compare your answers against the correct answers provided in an answer key in the newsletter. If any of your answers were incorrect, please refer back to the source material to clarify any misunderstanding.

Enclosed in this issue is an evaluation form to complete and return in an envelope we will provide. Please make sure you sign the attestation verifying that you have completed the activity as designed. Once we have received your completed evaluation form we will mail you a letter of credit. This activity is valid 24 months from the date of publication. The target audience for this activity is emergency, trauma, and surgical physicians and nurses.

If you have any questions about the process, please call us at (800) 688-2421, or outside the U.S. at (404) 262-5476. You can also fax us at (800) 284-3291, or outside the U.S. at (404) 262-5525. You can also email us at: ahc.customerservice@thomson.com.

On behalf of Thomson American Health Consultants, we thank you for your trust and look forward to a continuing education partnership.

Sincerely,

Brenda L. Mooney

Brenda Mooney
Vice-President/Group Publisher
Thomson American Health Consultants