THOMSON
AMERICAN HEALTH CONSULTANTS

The Practical, Peer-Reviewed Journal for Primary Care and Family Physicians

Primary Care Reports™

Volume 12, Number 5 May 2006

Sports Medicine in Primary Care

Authors: **Brian L. Springer, MD**, Assistant Professor, Department of Emergency Medicine, Wright State University Boonshoft School of Medicine; Associate Director, Wright State University/Kettering Medical Center Integrated Fellowship in Sports Medicine, Dayton, OH; **Benjamin Moorehead, MD**, Fellow, Wright State University/Kettering Medical Center Integrated Fellowship in Sports Medicine, Dayton, OH; and **James Tytko, MD**, Clinical Assistant Professor, Department of Family Medicine, Wright State University Boonshoft School of Medicine; Program Director, Wright State University/Kettering Medical Center Integrated Fellowship in Sports Medicine, Dayton, OH.

Peer Reviewer: **Jordan Metzl, MD**, Medical Director, The Sports Medicine Institute for Young Athletes, Hospital for Special Surgery; Assistant Professor, Department of Pediatrics, Cornell Medical College, New York, NY

Introduction

Sports and recreation-related injuries commonly are seen in the offices of internists, family practitioners, and pediatricians. They may be the first physician to whom the injured athlete turns, or they may be referred from an urgent care or emergency department. For this reason, sports medicine is an integral component of the practice of primary care. Recent data bear this out: The Centers for Disease Control published data from the National Electronic Injury Surveillance System All Injury Program in 2002. The report found that between July 2000 and June 2001 an estimated 4.3 million nonfatal sports- and recreation-related injuries were seen and treated in U.S. emergency departments.[1] These data are similar to National Center for Health Statistics Data from 1997-1998, which found that, in persons age 5-25, 22% of injury visits were due to sport-related activities. A random-sample survey of pediatric emergency departments found that, of an estimated more than 10 million injury-related visits annually (age 19 or younger), 20% were sports-related. The sports most likely to result in a visit were bicycling, basketball, football, baseball/softball, and gymnastics. A random sample of primary care offices measured injury-related visits for patients younger than 19 years old. Injuries accounted for more than 10 million visits per year; the leading cause of pediatric injury was sports activities. The sports most likely to generate an injury-related visit in children younger than 19 years old were basketball, football, baseball/softball, bicycle riding, volleyball, and soccer.

Several factors are important to note. These studies looked at sport-related injury, and thus exclude other sport-related illness

Statement of Financial Disclosure

To reveal any potential bias in this publication, we disclose that Dr. Wise (Editor-in-Chief), Dr. Springer (author), Dr. Moorehead (coauthor), Dr. Tytko (coauthor), and Dr. Metzl (peer reviewer) report no consultant, stockholder, speaker's bureau, research, or other financial relationships with companies having ties to this field of study.
This publication receives no commercial support.

such as heat-injury, soft-tissue infection, exercise-induced bronchoconstriction, and sudden death. Additionally, the CDC data exclude patients who died on the field or in the emergency department.

Primary care physicians often are the first-line when screening patients for safe participation in athletics. The pre-participation physical exam may help detect historical or physical exam findings suspicious for risk of sudden cardiac death. This is true of both adult and pediatric patients. Patients of all ages also may present to their physicians' offices with complaints of chest pain, syncope, or performance decrements that actually may signal risk of sudden death. These patients must be recognized and referred appropriately.

The Surgeon General's recommendations for sedentary U.S. adults and children to start exercising can only be expected to increase the prevalence of sports- and recreation-related injuries.[2] Primary care physicians who prescribe exercise will benefit their patients, and they also may expect to see patients back in their offices if they are injured during exercise.

Historically, sports medicine education for primary care physicians has been lacking. Resident requirements for musculoskeletal training and athletic injury/illness come from, in most cases, an orthopedic rotation in which exposure to athletics is highly variable. Some residencies mandate a primary care sports medicine rotation or offer it as an option. Sports medicine continuing medical education directed toward primary care physicians is of variable quality. Most offerings by societies such as the American College of Sports Medicine or the American Medical Society for Sports Medicine are aimed at physicians engaged in full- or part-time sports medicine practice. This article provides an overview of common sports medicine issues likely to present in the primary care office. A careful history, physical exam, and working knowledge of basic sports medicine will help the physician get patients back to their activities sooner and safer. Additionally, familiarity with sports medicine will enable the physician to recognize complex pathology and refer patients when appropriate.

Pre-participation Evaluation

Each year, a tremendous number of children and adults participate in organized sports and recreational activities; estimates of organized childhood and adolescent athletic participation alone is 30 million annually.[1] Many athletes are instructed to obtain medical evaluation before they can participate, and this should be encouraged even if not specifically required. The most widely used guidelines for pre-participation screening are those published by the American Academy of Family Physicians, the American Academy of Pediatrics, the American Medical Society for Sports Medicine, the American Orthopaedic Society for Sports Medicine, and the American Osteopathic Academy of Sports Medicine.[3] The main objective is to detect medical conditions that could be life-threatening and to find any musculoskeletal conditions that may require limitation of activity. Secondary goals are to determine general health and discuss general health issues, and to address any administrative requirements.

Setup. Time constraints, finances, available personnel, and the number of athletes to be screened all determine the manner in which the pre-participation evaluation (PPE) is conducted. Many times, PPEs are scheduled by the school or team and performed in a coordinated station system (i.e., station 1 for history, station 2 for cardiac exam, station 3 for musculoskeletal exam, etc.); others are done in the physician's office. There should be no difference in the contents of the exam itself. The PPE should be done at least 6 weeks prior to the start of practice to deal with possible issues raised during the process. There should be a comprehensive evaluation every 2-4 years with update annual evaluations in between.

History. Up to 75% of the problems affecting athletes can be identified by the medical history. It is important that the history be inclusive and specific. The history should include any allergies to medications or to any stinging insects that may necessitate the availability of epinephrine. Any ongoing medical conditions such as asthma, diabetes, or hypertension should be noted and addressed. Ask about any recent injuries (including head injuries), determine the extent of injury, ask about current or prior treatment, and whether any symptoms persist.

The PPE remains the first line in detecting athletes at risk for sudden cardiac death.[4] As a general rule, young athletes (younger than 30 years) are at risk from structural (and most often congenital) heart disease. Hypertrophic cardiomyopathy (HCM), the most common cause of sudden death in young athletes, is autosomal dominant but carries variable expressivity. Unfortunately, even thorough screening identifies only 3-15% of athletes who are at risk. Athletes older than 30 years are at risk from complications of coronary artery disease and most often will have identifiable risk factors on history or exam.

***Primary Care Reports*™**, ISSN 1040-2497, is published monthly by Thomson American Health Consultants, 3525 Piedmont Rd., NE, Bldg. 6, Suite 400, Atlanta, GA 30305.

VICE PRESIDENT/GROUP PUBLISHER: Brenda Mooney.
EDITORIAL GROUP HEAD: Glen Harris.
SPECIALTY EDITOR: Shelly Morrow Mark.
MARKETING PRODUCT MANAGER: Nan Webb.
GST Registration Number: R128870672.
POSTMASTER: Send address changes to ***Primary Care Reports*™**, P.O. Box 740059, Atlanta, GA 30374.

Periodicals postage paid at Atlanta, GA.
Back issues: $26. Missing issues will be fulfilled by Customer Service free of charge when contacted within one month of the missing issue's date.

Subscriber Information

Customer Service: 1-800-688-2421.

E-Mail Address: customerservice@ahcpub.com
Editorial E-Mail Address: shelly.mark@thomson.com
World-Wide Web: http://www.ahcpub.com

Subscription Prices

United States
1 year *with* free AMA Category 1 credits: $349
(Student/Resident rate: $170).
Multiple Copies
1-9 additional copies: $314 each; 10 or more copies: $279 each.
Canada
Add GST and $30 shipping
Elsewhere
Add $30 shipping

Accreditation

Thomson American Health Consultants (AHC) designates this educational activity for a maximum of 36 AMA PRA Category 1 Credit(s)™. Physicians should only claim credit commensurate with the extent of their participation in the activity."

AHC is accredited by the Accreditation Council for Continuing Medical Education (ACCME) to provide continuing medical education for physicians.

This CME activity was planned and produced in accordance with the ACCME Essentials.

This program has been approved by the American Academy of Family Physicians as having educational content acceptable for Prescribed credit hours. This volume has been approved for up to 40 Prescribed credit hours. Credit may be claimed for one year from the date of this issue.

This program is intended for primary care and family practice physicians. It is in effect for 24 months from the date of publication.

THOMSON
AMERICAN HEALTH CONSULTANTS

Questions & Comments

Please call **Shelly Morrow Mark,** Specialty Editor, at (352) 351-2587 or e-mail: shelly.mark@thomson.com between 8:30 a.m. and 4:30 p.m. ET, Monday-Friday.

Table 1. Pre-participation Exam Red Flags

HISTORY
• Exertional syncope or presyncope
• Uncontrolled asthma
• Sudden cardiac death in the family (especially in someone younger than 40 years)
EXAM
• Skeletal proportions suggestive of Marfan's
• Diastolic murmurs
• Systolic murmur grade III or greater
• Systolic murmur increasing intensity with valsalva
• Delayed or decreased femoral artery pulse
• Splenomegaly

Any history of exertional syncope, near-syncope, or chest pain should be noted as a possible sign of structural or ischemic cardiac disease. (*See Table 1.*) Elicit any history of cardiac disease or sudden death in relatives younger than 50 years. Episodes of dyspnea on exertion or coughing or wheezing during or after exercise should be noted as an indicator for exercise-induced bronchoconstriction or other pulmonary disease, or as a symptom of cardiac pathology. A family history of Marfan's syndrome should lead the clinician to consider the diagnosis; Marfan's syndrome is a connective tissue disorder that places the athlete at risk for the development of aortic aneurysm and dissection.

Examination. Beginning with appearance, make note of morphologic features that may suggest Marfan's syndrome (i.e., arm span greater than height, pectus excavatum, or arachnodactyly). Also scan the skin for possible infectious disease that would require treatment before participation in contact sports. Blood pressure should be compared with age-adjusted normals. Visual acuity should be checked to ensure that the athlete is not functionally blind or functionally one-eyed. A minimum visual acuity should be 20/40. A basic neurological exam should include assessment of pupils for anisicoria. This is important to note in the case of future head injury to avoid mistaking it for an acute change.

The cardiovascular exam is focused on seeking evidence of structural heart disease. Careful auscultation is important to identify any critical murmur. The classic systolic ejection murmur of HCM increases with standing or valsalva (via decreased venous return) and decreases with squatting as venous return increases. On the contrary, the murmurs aortic stenosis and mitral regurgitation will diminish with decreased venous return. Any murmur that increases in intensity with valsalva or standing, any systolic murmur grade 3 or higher, and any diastolic murmur should be evaluated further. Simultaneous palpation of radial and femoral pulses is a fast and easy screen for coarctation of the aorta.

The pulmonary examination should assess for asymmetry, wheezing, or prolonged expiratory phase. Most asthmatics report exercise as an asthma trigger; however, a small percentage of athletes only develop bronchoconstriction secondary to exercise. These athletes will have a normal exam at rest. If the history is suspicious, referral to a specialist for exercise challenge (spirometric measures compared pre- and post-exercise, as well as post-albuterol treatment) is indicated. Most cases of exercise-induced bronchoconstriction can be managed with albuterol inhaler treatment 20-30 minutes prior to exercise.

The abdominal exam should look for the presence of organomegaly or tenderness and any identifiable hernias. Infectious mononucleosis increases the risk for splenic rupture, and athletes with a tender or enlarged spleen should be followed by ultrasound until splenomegaly resolves.

The musculoskeletal examination should focus on any problems noted in the history. In addition, a two-minute orthopedic screen can be done. This should include inspection for symmetry; cervical motion; back extension and flexion; shoulder shrug; shoulder abduction, internal, and external rotation; extension, flexion, supination, and pronation of elbow; clenched fist and spread fingers; toe walk; heel walk; and duck walk. Any abnormality in the screening should prompt a thorough examination.

Determination of Clearance. After reviewing the history and examining the athlete, one must determine if the athlete may participate, or whether additional information is needed.

Any orthopedic condition that limits the athlete's range of motion, strength, or elicits pain that inhibits activity requires further evaluation. If the physician is not comfortable doing this him- or herself, referral to a specialist is appropriate.

Abnormalities in the medical screening often lead to further studies such as electrocardiography, chest radiography, graded exercise stress testing, and echocardiography. The threshold for referral to a cardiologist or other specialist should be low. There are many medical conditions that require special consideration before clearance for all sports. These include structural heart disease, coronary artery disease, various dysrhythmias, solitary organs, uncontrolled asthma, uncontrolled seizure disorders, and sickle cell disease. Recommendations found in the 36th Bethesda Conference can help guide the practitioner, in consultation with the athlete, the athlete's family, specialists, coaches, and trainers.[5]

Concussion: Diagnosis and Management

Head injury is the most common cause of death related to sports. Concussion or mild traumatic brain injury (MTBI) is the most common athletic head injury. Frequently it is the responsibility of the primary physician to clear an athlete for participation following a head injury. In recent years there has been much debate in both the classification and management of concussion. This can be burdensome for those who are inexperienced in dealing with concussed athletes.

Presently, the most agreed upon definition of concussion comes from the Summary and Agreement Statement of the 2nd International Conference on Concussion in Sport, Prague 2004.[6] The consensus defines concussion as a complex pathophysiological process affecting the brain, induced by traumatic biomechanical forces. Common features used in defining concussive injury include the following:

• Concussion may be caused either by a direct blow to the head, face, neck, or elsewhere on the body with an "impulsive"

Table 2. Return to Play Following Concussion

* Allow 24 hours between stages. If symptoms recur with activity, drop back to previous asymptomatic stage and attempt to progress after 24 hours.

1. Complete rest. Once asymptomatic at rest, proceed to step 2.
2. Light aerobic exercise (i.e., walking, stationary cycle)
3. Sport-specific exercise (i.e., running, skating)
4. Non-contact drills
5. Full-contact drills
6. Game play

Adapted with permission from McCrory P, et al. Summary and Agreement Statement of the Second International Conference on Concussion in Sport, Prague 2004. *Clin J Sport Med* 2005;15:48-55.

force transmitted to the head. The key point here is that the athlete need not have struck his/her head to sustain a concussion.

• Concussion typically results in the rapid onset of short-lived impairment of neurological function that resolves spontaneously. This impairment may resolve anywhere from seconds to weeks later; it is impossible to predict healing time prospectively.

• Concussion may result in neuropathological changes but the acute clinical symptoms largely reflect a functional disturbance rather than structural injury. Unlike traumatic cerebral contusions or bleeds, a concussed athlete is unlikely to present with incapacitating headache, cranial nerve palsies, or unilateral neurological deficits. The signs and symptoms often are much more subtle.

• Concussion results in a graded set of clinical syndromes that may or may not involve loss of consciousness. Resolution of the clinical and cognitive symptoms typically follows a sequential course. Herein lies a critical take-home point: Concussion does *not* necessarily involve a loss of consciousness (LOC). In fact, it is estimated that up to 90% of concussions do not involve LOC.

• Concussion typically is associated with grossly normal structural neuroimaging studies. Concussion is not a diagnosis you make with a CT scan or MRI. Obtain these studies only if a structural injury is suspected.

The most important considerations when evaluating an athlete with MTBI is not only management of the current injury, but risk assessment for subsequent injury. Recent studies have demonstrated that athletes who have sustained a concussion are at risk for a repeat concussion during the season.[7] Much debate persists regarding the effects of repeat concussion. The effects of repetitive head injury in combative sports (such as martial arts or boxing) are well documented. Whether repeat concussion in sports such as soccer or football results in long-term cumulative injury remains a matter of contention.

Second impact syndrome is a rare but devastating injury scenario in which an individual has a second concussive incident while still recovering from a head injury. In this scenario, the second impact results in loss of vasomotor regulation. A subsequent increase in intracranial pressure can lead to herniation and death. As there is nearly 100% morbidity and 50% mortality with second impact syndrome, prevention is key. No one should be allowed to return to play while still symptomatic from a head injury.[8]

A history should be obtained from both the individual and a witness, if possible. Elicit symptoms such as headache, dizziness, nausea, or impaired concentration. The initial examination should focus on mental status and identifying any focal neurologic deficits. Look for cognitive deficits by assessing orientation and memory. When assessing an athlete down on the field, always be cognizant of possible cervical spine injury. No symptomatic athlete should be allowed to return to play.

There are multiple concussion grading systems dating back to the 1980s. The three most commonly used are the Cantu (1986), Colorado (1991), and the American Academy of Neurology (1997). Each of these systems grades concussions on a scale of increasing severity; none of these scales have been validated scientifically.

The Prague Conference recommends against the use of injury grading scales and instead advocates a combined measure of recovery to determine injury severity and prognosis. Simple concussions are those that improve and resolve over the course of 7-10 days. Self-reported symptoms resolve prior to normalization of cognitive function, so the athlete should not be rushed back into play following symptomatic improvement.[9,10] A graded return to play can be used once the athlete is asymptomatic with rest; the average duration from time of injury to return to play should be 7 days. (*See Table 2.*) Referral for formal neuropsychological testing does not provide additional benefit in this situation. Complex concussions typically manifest with persistent or recurrent symptoms, prolonged loss of consciousness at the time of injury, seizure activity in a non-epileptic patient or individuals with multiple concussions. Referral for formalized testing may be useful in these cases to ensure return of cognitive function.

More recently there has been a trend toward computer-based neuropsychologic concussion testing. There are two neuropsychological testing programs now in wide use: ImPACT and Cogsport. Both of these require preseason baseline testing with repeat evaluation following concussion. The test can be administered in the physician's office or even in the training room. The tests make objective assessments of attention span, reaction time, memory, and problem-solving skills. This can be useful to provide hard data to back up a return-to-play decision. However, all decisions must rest on clinical grounds. Athletes must be sidelined until they are completely asymptomatic.

Acute Sports and Recreation Injuries

Acute Shoulder Injuries. The shoulder is the most mobile joint in the human body. The same mechanisms that allow for mobility also put the shoulder at risk for traumatic and overuse injuries. Given the wide range of motion allowed, stability of the shoulder requires both static and dynamic (active) components. Static stability of the shoulder is provided by the joint capsule, the cartilaginous labrum, and the glenohumeral ligaments.

Dynamic stability is provided by the muscles and tendons of the rotator cuff. The four components of the cuff are remembered easiest by the mnemonic SITS: *Supraspinatus* (abduction); *Infraspinatus* and *Teres Minor* (external rotation); and *Subscapularis* (internal rotation). When fully firing, the muscles of the cuff help pull the humeral head inferior and medial, securing it in the glenoid, and keeping the supraspinatus muscle away from the underside of the AC joint.

Acute shoulder injuries most often occur with an external force applied to the shoulder. This can be either an impact or pulling force applied to the arm as can occur in wrestling. A history of the arm going "dead" or feeling the shoulder slip could indicate a subluxation of the shoulder. A dead feeling also is common with a stinger, which is an injury of the brachial plexus.

Proper examination of the shoulder can be challenging. Begin by checking the shoulder closely for any asymmetry of musculature at the AC and SC joints, and for any scapular winging. Next, palpate with close attention to the clavicle, AC joint, infraspinatus, supraspinatus, rotator cuff insertion on the anterior humeral head, and the proximal biceps tendon. Check abduction, forward flexion, cross body adduction, and internal and external rotation. Abduction and flexion should be observed from behind so that any asymmetry in scapular movement can be noted. Assess rotator cuff strength with resisted abduction (arm angled 30 degrees anterior to minimize deltoid activity), external rotation (with elbow flexed at 90 degrees, patient rotates away from midline against resistance), and internal rotation (have the patient place his hand against the small of his back and push off against resistance). Test for subacromial impingement by passively forward flexing the shoulder with the thumb pointing down, internally rotating the humerus (Neer's test), or by abducting the shoulder to 90 degrees and internally rotating (Hawkin's test). Pain on either maneuver is considered a positive exam. Weakness in multiple muscles of the cuff may be due to less common pathology such as nerve injury or adhesive capsulitis.

Instability is a common cause of acute and chronic shoulder pain in the younger athlete, and may be unidirectional (most often inferior or anterior) or multidirectional. A characteristic history may be present with a sensation of looseness in the joint but often presents only as pain. Application of stress to the shoulder may reveal a visible shift of the joint or may only elicit discomfort. An acute injury is likely when the arm is abducted and externally rotated with a force applied to the anterior surface of the distal arm. With this force, the arm acts as a lever and partially or completely dislocates the humeral head anteriorly. Anterior apprehension is tested with the arm in 90-degree abduction, and elbow at 90-degree flexion, then maximally externally rotated. A sense of apprehension and impending dislocation is positive for anterior instability, whereas pain itself is not specific.

Testing for labral tears is operator dependent, and findings are neither sensitive nor specific.[11] The clunk test can help suggest a tear is present. Place one hand behind the humeral head and with the other hand keep the elbow at 90 degrees and rotate the shoulder with both internal and external rotation while applying gentle axial compression to the glenohumeral joint. A clunking or grinding sound is positive clunk test result.[12]

Findings will vary depending on the history and timing of injury. Following acute anterior dislocation, motion is limited and painful. Palpate for any bony step-offs or crepitus that may indicate a fracture. Check distal pulses and assess the axillary nerve by checking sensation over the region of the deltoid. There is probably no need for a pre-reduction radiograph of a younger athlete if there is an obvious, uncomplicated dislocation; based on the clinician's experience and comfort, the joint can be reduced in the office or on the field. Follow-up radiographs within 24 hours are appropriate. Early treatment involves sling immobilization with early progression of range of motion. The athlete with full range of motion then can progress to strengthening.[13]

In the case of subluxation without dislocation, the immobilization and range-of-motion phase may be eliminated, proceeding directly to strengthening of the rotator cuff. In cases of subluxation and dislocation, return to play is allowed only after the patient has full range of motion and strength. Risk of recurrence for shoulder dislocation is high. In some sports, it is possible to play in a shoulder harness that prevents performing from full abduction of the arm for additional stability. In cases of recurrent dislocation or subluxation despite conservative therapy, a surgical evaluation should be obtained.

A fall or hit directly on the shoulder may result in a separation of the acromioclavicular joint. On presentation, the patient's shoulder will be tender to palpation along the acromioclavicular (AC) joint. Motion typically is painful with abduction and flexion, but worst with cross body adduction. Rotator cuff strength may be compromised due to pain. Radiographs should be obtained to evaluate the joint.

An AC injury may be graded depending on the location and extent of ligament damage. Type I involves only a strain of the acromioclavicular ligaments with widening of AC joint but no change in coracoclavicular (CC) space. A type II injury involves disruption of the AC ligaments and CC ligaments, with depression of the scapula under weighted stress. A type III injury involves complete rupture of both ligaments and is further broken down depending on displacement of the clavicle and coracoid. Types I and II generally are treated conservatively with rest, ice, and gradual progression of activities over 7-14 days. Heavy lifting should be avoided for 2-3 months. If the athlete is involved in a contact sport, additional padding is used to protect the joint. With a high-grade injury, treatment (operative vs conservative) remains controversial, and these athletes should be referred to an orthopedic surgeon.

Acute Hand Injuries. Hand injuries occur with many mechanisms, including falls, collisions with other players or obstacles, and impact from projectiles. Due to the high morbidity associated with loss of function of the wrist, hand, or fingers, use extreme caution in evaluation and treatment of these injuries. The threshold for specialist referral should be low.

The scaphoid or carpal navicular is the most frequently fractured carpal bone. The most common mechanism is a fall on an outstretched hand.[14] Due to a distal to proximal blood supply,

scaphoid fractures are at high risk for non-union. Suspect this injury if there is point tenderness in the anatomic snuffbox. Obtain wrist films, but be aware that non-displaced fractures may not be apparent on film for up to two weeks. Nondisplaced distal fractures should be treated with thumb spica casting for a minimum of six weeks. If a fracture is suspected, but not visualized on radiographs, the individual should be placed in a thumb spica cast and rechecked in 1-2 weeks.[15] If the repeat radiographs indicate a fracture, the individual should be placed in a cast, again for a minimum of six weeks. When fracture is suspected despite negative films, or if time is of the essence in making a return-to-play decision, MRI has become the gold standard in detecting injury, although a bone scan remains a useful alternative.[16]

If a fracture is present proximally or through the waist of the scaphoid, then surgical referral is indicated. Any nonunion of the scaphoid, or displacement greater than 2 mm, should be referred for surgical evaluation. A nonunion of the scaphoid can lead to arthrosis (joint degeneration) even if initially non-tender.

A tear of the ulnar collateral ligament of the thumb commonly is referred to as Gamekeeper's thumb or Skier's thumb. This injury often occurs with a fall onto an outstretched hand with the thumb abducted, or when a skier's thumb is forcibly abducted by a planted ski pole.

On exam, point tenderness will be on the ulnar aspect of the MCP joint. If there is increased laxity of more than 20 degrees compared to the unaffected side, then there likely is a complete rupture of the ligament. In cases of a complete tear, the distal edge of the ligament may become entrapped by the adductor aponeurosis, preventing healing; this is referred to as a Stener lesion. It is important to diagnose a complete tear early as surgical repair done in the first 2-3 weeks is thought to improve outcome. Appropriate treatment of partial tears involves bracing or casting with the MCP in slight flexion for 4-6 weeks. Refer any suspected Stener lesion to a hand specialist.[17]

Common sports-related injuries of the distal interphalangeal joint (DIP) include mallet finger and jersey finger. A mallet finger is an injury to the extensor tendon that results in the inability to actively extend the DIP. This commonly occurs when a ball hits the tip of an extended finger and there is a sudden forceful flexion of the joint. A radiograph should be taken. An avulsion fracture may or may not be present. If a fracture involves more than 25% of the articular surface, refer the patient for surgical evaluation. In smaller or absent avulsion fracture, treat by splinting the DIP joint in extension for six weeks while still allowing the proximal interphalangeal (PIP) joint to remain mobile.

A lack of active flexion of the DIP joint is a sign of injury to the flexor digitorum profundus, referred to as jersey finger. This occurs with hyperextension of the DIP while actively flexing, and commonly occurs when making a tackle from behind and getting a finger caught in the opponent's jersey. On examination it is important to localize tenderness along the volar surface as the tendon may retract all the way to the palm. Surgical intervention is necessary, with the amount of retraction dictating immediate vs. delayed repair. Radiographs should be taken for possible avulsion or for other concomitant injury.

Figure 1. Dislocation of Transverse Tarsal Joint

A 15-year-old male was referred 1 month following an ankle and mid-foot inversion injury. An identical film at that time had been read as "normal." This patient has a dislocation of the transverse tarsal joint (Chopart's joint, connecting the talus with the navicular and cuboid). Open reduction and internal fixation ultimately were required.

Acute Ankle Injuries. Ankle injuries are common, especially in running and jumping sports such as soccer and basketball. Ankle sprains alone account for an estimated 25% of all sports-related injuries.[18] Although the term sprain refers specifically to ligamentous injury, there are frequently associated injuries that occur simultaneously.

The ankle joint is formed by articulation of the talus, tibia, and fibula, and allows plantarflexion and dorsiflexion of the foot. The subtalar joint is formed by the articulation of the talus and calcaneous, and allows for inversion and eversion.

The lateral ankle ligaments are the most frequently injured and include the anterior talofibular ligament (ATFL), calcaneofibular ligament (CFL), and the posterior talofibular ligament (PTFL). Injury of the lateral ligaments occurs with inversion of the foot. The medial ligament (deltoid ligament) sprain occurs less frequently and typically happens with an eversion force. The deltoid ligament is fan-shaped and connects the medial malleolus to the navicular anterior, to the calcaneous inferior, and to the talus posterior. The syndesmotic ligaments stabilize the distal tibia and fibula and may be injured with forced internal or, more commonly, external rotation of the foot.

The ankle exam is done best with the patient sitting and the lower leg hanging off the exam table. Goals are to assess the ligamentous stability of the ankle, reveal the likelihood of bony injury, and to determine if radiographic evaluation is necessary.

Observe the ankle and foot for any swelling or ecchymosis. The ankle and foot should be palpated in a well organized approach so as not to miss any injury. As a general rule, always examine a joint above and a joint below the injured body part; palpate the knee so as not to miss fracture patterns associated with ankle injury (Maissoneuve fracture). (*See Figure 1.*) Palpate the ankle joint itself, being particularly alert for tenderness in

either malleolus. Palpate the base of the fifth metatarsal to assess for avulsion (dancer's fracture). Active motion with plantarflexion, dorsiflexion, eversion, and inversion should be assessed.

The anterior drawer test assesses anterior–posterior translation. Stabilize the distal tibia with one hand while the other hand grasps the heel and exerts an anterior force. A significant increased translation compared to the unaffected side indicates injury to the ATFL. Talar tilt assesses stability of the calcaneofibular ligament. One hand again stabilizes the lower leg with the other hand on the heel. An inversion force is applied to the heel, while the physician feels for abnormal medial translation.[19]

Assess stability of the tibial-fibular articulation with palpation along the syndesmosis and performance of a squeeze test (squeezing the proximal fibula and tibia together with one hand; eliciting pain is considered a sign of syndesmotic injury). Look for laxity or ankle pain with external rotation of the foot. A syndesmotic sprain may display a large amount of swelling that is contained to a level above the ankle, but it often is subtle and easy to miss without a careful exam.

The majority of ankle radiographs taken following acute injury do not affect clinical management. The Ottawa Ankle Rules were designed to cut down on unnecessary radiographs and have been validated in a number of settings. Be aware, though, that these rules do not apply for pediatric patients (younger than 18 years), those with multiple painful injuries, pregnant patients, or those with diminished sensation due to neurologic deficit.[20]

The Ottawa Ankle Rules state that radiographs are indicated in adults if any of the following are present:

- Inability to walk for four steps;
- Tenderness over posterior lateral or medial malleolus;
- Tenderness over base of fifth metatarsal; or
- Tenderness over navicular.

The goal of initial treatment is to reduce pain and swelling. Treatment of an ankle sprain can be summarized best with the mnemonic PRICE (protection, rest, ice, compression, elevation.) Protect the ankle from further injury with a lace up brace or removable air-splint. Crutches may be required initially, but weight-bearing should be encouraged as soon as tolerated. An elastic wrap bandage may help reduce swelling, and the leg should be kept elevated during periods of inactivity and sleep.[21] The subacute phase focuses reestablishing range of motion as well as regaining strength with isometric activity. During the subacute phase, the ankle should remain braced. The rehabilitative phase is used to regain full motion and strength as well as to regain lost proprioception. Once the athlete has regained full motion and strength, sport-specific (functional) training can commence. Ligamentous healing may take months, so bracing during activity should continue for the remainder of the season and be reevaluated for stability at that time.[22]

Nondisplaced fractures of either malleolus can be treated with immobilization until healed as long as the mortise is intact. In case of a displaced fracture or disruption of the ankle mortise, surgical fixation may be indicated. Avulsion fractures of the fifth metatarsal can be treated by use of an orthopedic shoe or boot until the patient is pain free. A gradual return to play then can begin. Fractures at the junction of the metaphysis and diaphysis are known as Jones' fractures, and are associated with high rates of non-union. Treatment consists of casting and non-weightbearing for at least six weeks; delayed healing or those wishing a more rapid return to sport should be referred for surgical evaluation.

Table 3. Causes of Acute Knee Effusion

- Cruciate ligament tear
- Fracture
- Patellar dislocation
- Meniscal tear

Acute Knee Injuries. The knee is comprised of four bones (femur, tibia, fibula, and patella) and supported by four main ligaments. The collateral ligaments, medial (MCL) and lateral (LCL) stabilize the knee from varus and valgus forces. The anterior cruciate ligament (ACL) prevents movement of the tibia in an anterior direction from the femur, and the posterior cruciate ligament (PCL) prevents movement of the tibia posteriorly.

The history gives important clues to the diagnosis.[23] Knee injuries most often occur with twisting movements and sudden changes of direction, with or without contact.

The mechanism of injury, whether it is a result of twisting, collision, or fall, will direct the physician to possible ligament or bony injury. It also is important to know what happened after the injury and whether the athlete was able to continue playing, required assistance to come off the playing area, or initially tried to return but could not because of either instability or pain. Next, inquire about any swelling and the timing of the injury. A large amount of swelling immediately post injury is suspicious for hemarthrosis and limits the diagnosis to a select few injuries. Swelling during the 24 hours following injury has a different subset of causes. If the individual has been walking since the injury, an inquiry should indicate whether there is any catching or locking in the knee, or any signs of instability or "giving way." Inquire about any previous injuries or surgeries to the joint.

A well-structured exam should follow. This will begin with inspection of the knee. Any bruising or effusion should be noted. (*See Table 3.*) It may be necessary to milk the concavity medial to the patella, and then observe for any subtle returning fluid wave to detect small effusions. Next the range of motion should be assessed. The inability to fully extend the knee may indicate there is a mechanical obstruction that could represent either ACL or meniscus injury.

If there is a strong suspicion for fracture, consider obtaining radiographs before proceeding with stability testing. The Ottawa Knee Rules are a validated clinical decision rule.[24] Obtain a radiograph in traumatic knee injuries when any of the following are present:

- Age older than 55 years;
- Inability to bear weight for four steps;
- Tenderness at the head of the fibula or over the patella; or
- Inability to flex the knee to 90 degrees.

Table 4. Recommended Basic History and Physical Examination for Patients with Suspected Ligamentous Knee Injuries

- Nature of the injury and direction of the forces
- Was there a "pop" at the time of injury?
- Was the athlete able to continue play after the injury?
- Did the knee swell at the time of the injury or anytime since?
- Is the knee buckling or giving way?

Observation: Is an effusion present? Do the femur, tibia, and patella align normally?

Range of motion: Check active and passive flexion and extension.

Palpation: Can an effusion be palpated (i.e., is there a fluid wave or ballottable patella)? Is there any focal bony or joint-line tenderness?

Stress Testing:

Lachman test: Is an end point felt with anterior subluxation of the tibia on the femur?

Varus and valgus stress testing: Is there pain or joint widening when stressed?

Posterior drawer: Is there posterior sag or translation of the tibia when posterior force is applied?

Adapted from Solomon DH, et al. Does this patient have a torn meniscus or ligament of the knee? Value of the physical exam. *JAMA* 2001; 286:1610-1620.

If radiographs are obtained, scrutinize them carefully. Look for subtle abnormalities that may signify tibial plateau fracture, avulsion fracture, or injury to the articular cartilage.[25]

Check the collateral ligaments with the knee slightly flexed and apply direct valgus and varus stress. (*See Table 4.*) Pain or increased laxity compared to the unaffected side indicates a sprain of the collateral ligament. Continued laxity with the knee fully extended represents significant sprain or ligament rupture. The Lachman's test for ACL integrity is done with the knee slightly flexed, the thigh stabilized, and anterior force applied to the lower leg. A firm endpoint should be felt. Any laxity or lack of firm endpoint should raise suspicion of an ACL injury. This can be a difficult maneuver if the patient does not relax the hamstring muscles, as this resists the movement. Make sure the patient is completely relaxed. Allowing the thigh to rest on the exam table and the lower leg to fall just over the edge can help reduce the resistance. The PCL should be tested with the knee bent and the foot flat on the table. A posterior force then is applied to the lower leg, and any movement noted is abnormal. This usually is accompanied by a posterior sag, observed with the hip flexed and the lower leg at horizontal.

Tests for the menisci are less specific than for the ligaments.[23] Signs of a tear include tenderness over the joint line, discomfort on forced flexion and/or extension, and inability to squat. The McMurray test is performed with palpation of the joint line while internally or externally rotating the knee and extending the knee to 90 degrees. A positive test is one with a palpable click over the joint line and reproduced pain.

It is important not to reflexively immobilize all knee injuries as this can decrease the present motion in the knee and lead to an increased recovery time. There are times, however, when immobilization is the treatment of choice. If there is a near dislocation of the knee with multiple ligament tears, or a patellar dislocation requiring reduction, temporary immobilization should be considered, but the patient should see a specialist within a few days. If radiographs are not immediately available and there is concern for significant injury, immobilize the knee and refer the patient for radiographic and orthopedic follow-up within 24 hours.

Treatment of collateral ligament sprains is conservative, even for complete tears. Grading is based on laxity with valgus stress for the MCL and varus stress for the LCL. If there is no laxity but evidence of injury and pain with stress, then a Grade I injury is present. If there is laxity with the knee in 30-degree flexion and none with the knee in extension, there is a Grade II sprain. Finally, with significant laxity in flexion, no endpoint felt, and some laxity with the knee fully extended, there may be a complete tear or Grade III sprain. Treatment begins with ice, rest, stretching, range of motion, and low impact quadriceps strengthening.[25] Hinged braces provide additional support over the collateral ligaments. This can be used at all times initially and then only with sporting activities after the athlete is able to walk pain free without the brace. After 1-2 weeks of the initial rehab, the individual can progress to light jogging in the brace and then progress functionally in a step-wise fashion to running, jumping, and sport-specific maneuvers.

The typical history of an ACL injury consists of a rapid pivoting or stopping while the foot remains planted. Often no contact is made, and the injury may be accompanied by the sensation of a pop or even an audible popping. The athlete may describe instability or "giving way" if an attempt is made to continue play. The exam reveals an effusion and an abnormal Lachman's test. MRI can help confirm the diagnosis, as well as assess for other injury to the meniscus or articular cartilage.

Although quality randomized controlled studies are lacking, the general consensus is that in active individuals, the ACL should be repaired with via autograph or cadaver graft.[26] This enables the individual to return to full activities and reduces subsequent risk of osteoarthritis. There are times, however, when conservative treatment without surgery may be utilized. In older, less active individuals who do not wish to return to sports or activity requiring significant turning or twisting of the knee, bracing may be an option. Injury may occur early or mid-season; the athlete may postpone surgery and attempt to return to play while braced. If there are any subsequent episodes of instability, however, the activity must be terminated, and the athlete must avoid participation until repair is complete. Also, in the case of the skeletally immature, surgical reconstruction should be delayed. In each of these cases an experienced surgeon should be consulted before the decision to avoid or delay surgery is made.

PCL injury is far less frequent than ACL injury among athletes. The mechanism of injury most often is a hard fall onto a flexed knee with a plantar flexed foot. Posterior drawer testing will reveal increased laxity. Controversy exists regarding the nat-

Figure 2. Bone Scan of Stress Fracture

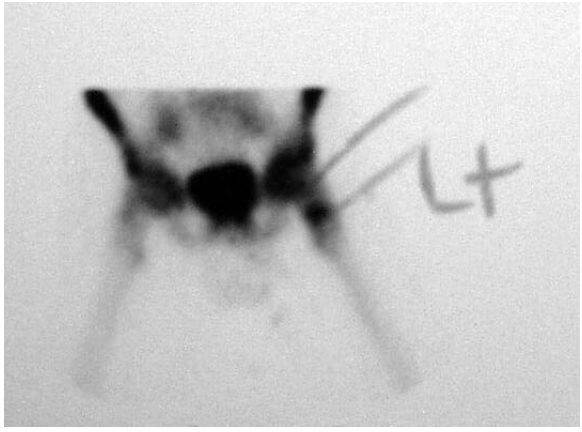

A 16-year-old active male recreational athlete was referred for hip pain worsening over 4 weeks. His initial radiographs at 2 weeks were unremarkable. Radionuclide technetium-99 diphosphonate scan reveals a stress fracture of the femoral neck. Follow up radiographs reveal sclerotic bone changes. (*See Figure 3.*) The patient was immediately pulled from activity and restricted to non-weight-bearing activity.

Figure 3. Sclerotic Bone Changes

ural history and optimal treatment of an isolated PCL injury.[27] It often is treated conservatively with bracing, rest, and isometric knee exercises and gradual return to activity after a few weeks. Surgery may be necessary for an acute avulsion or for persistent PCL laxity. In any patient in whom PCL injury is suspected, further evaluation by an orthopedist is recommended.

Overuse Injury

Overuse injuries are common complaints among athletes. Most often, these injuries arise from opposite sides of the spectrum. At one end is the competitive athlete whose activity of choice results in long-term wear and tear on parts of the body. When the body's ability to heal is exceeded by repetitive stress, overuse injury occurs. At the other extreme is the weekend warrior who pushes him- or herself during an infrequent activity, with resultant over-stressing of muscle or tendon. Most subacute injuries respond to the principles of PRICE and resolve within several days.

Of greater concern is the active athlete who develops an overuse injury over the course of weeks to months. This may herald the development of a stress fracture or of significant connective tissue pathology. The term tendinitis which implies inflammatory change to the muscle/tendon unit largely has been disregarded and replaced by the more physiologically appropriate tendinosis or tendinopathy. While early injury may indeed involve inflammation, histopathologic changes of long-term overuse injuries reveal tissue necrosis and degeneration. A better knowledge of this process and its implications for treatment still are being assessed.[28]

Stress Fractures. Bone is living tissue and thus displays a physiologic response to overload. Repetitive stress on a bone results in micro-injury that triggers healing. Over time, areas affected by stress will strengthen in response to gradual overload. However, when the rate of damage exceeds the rate of repair, a stress fracture can occur. This is an overuse injury most often seen in the lower extremities in running sports such as distance running, soccer, and basketball. Stress fractures occur over the course of weeks in parts of the body where bones either absorb direct shock or are repeatedly stressed by attached contracting muscle. Thorough questioning usually elicits a typical scenario for stress fracture: a recent increase in activity precipitates gradually worsening pain that, after a number of weeks, now impedes athletic activities and may affect daily activities. Early on, the patient may complain of pain at night following their training. Eventually the pain appears during activity. Common locations include the metatarsals, tibia, and femur.[29]

A physical examination typically reveals localized tenderness at the fracture site. Soft-tissue swelling may be present. Percussion testing may localize pain to the fracture site (such as in the "hop test").

Radiographs often are normal until late in the disease process. Elevation of the periosteum is one of the earliest radiographic findings. Eventually, sclerotic changes and/or the appearance of a fracture line will appear. (*See Figures 2 and 3.*) The diagnosis can be confirmed early with MRI or a bone scan.[30] In most cases, the athlete should be restricted from high-impact activities until pain free; a gradual return to sport then can be initiated over a several-week period to allow for appropriate skeletal adaptation. Exceptions include stress fractures of the tarsal navicular and fifth metatarsal metaphyseal/diaphyseal junction (associated with a high rates of non-union) and of the femoral neck (where progression to complete fracture may lead to avascular necrosis of

the hip). When these injuries are suspected, have the athlete avoid weight-bearing, obtain appropriate imaging studies, and provide prompt orthopedic referral.

Shoulder. Young and active overhand athletes tend to have a greater degree of joint laxity than older adults, and this inherent laxity can lead to functional subacromial impingement. The basic mechanism is as follows: due to joint laxity, the dynamic stabilizers (rotator cuff) provide much of the stability of the active joint. They can become fatigued, and the humerus will ride "up and out," narrowing the subacromial space and irritating the supraspinatus tendon. During the next bout of physical activity, the irritated tendon fatigues sooner, and stability again is compromised. Eventually a cycle develops where tendon irritation rapidly leads to fatigue and impairment of shoulder performance and stability.[31]

The most common presentation is a young athlete who complains of unilateral (and sometimes bilateral) shoulder pain with overhead activity. The athlete also may complain of anterior shoulder subluxation ("it feels like my shoulder slips out"), weakness, and loss of accuracy and velocity with throwing.

When examining young athletes, look for pain and/or weakness of the supraspinatus with resisted abduction. Assess inferior instability (pulling downward on the humerus opens up a sulcus below the acromion), posterior instability (grasping the humeral head and gliding it posterior results in subluxation), and anterior instability (anterior apprehension—abduction and external rotation of the shoulder creates pain or an impending feeling of subluxation). The threshold for obtaining radiographs should be low in the young athlete, as bony tumors must be considered in the differential diagnosis.

Treatment consists of reassurance, relative rest, and initiation of a rotator cuff strengthening program. Increased dynamic stability usually improves symptoms in 3-4 weeks. If symptoms do not improve, referral to a sports medicine specialist should be considered.

In athletes older than 40-50 years, pain and impingement often are due to degenerative changes of the tendon and osteoarthritis (OA) of the acromioclavicular joint. Pain and decreased range of motion in multiple directions with active and passive movements should prompt suspicion of glenohumeral arthritis. Obtain shoulder films and look for the radiographic hallmarks of OA at the AC and glenohumeral joints: joint space narrowing, increased bone sclerosis, bony cystic changes, and the presence of osteophytes. Thus, the mechanisms primarily responsible for impingement become rotator cuff weakness and/or injury and loss of subacromial space. Second, abnormalities of the AC joint can physically impinge on the supraspinatus tendon, accelerating injury. Third, age takes it toll, and degenerative changes of the cuff occur with repeated overload. Relative hypovascularity of the supraspinatus tendon approximately 2 cm from the humeral insertion is a common site of injury.

Historically, the patient will present with unilateral, painful overhand activity, sports-related and otherwise (reaching up into a cabinet, changing a light bulb, etc.). Sleep may be difficult due to pain when lying on the affected shoulder. Acute onset of subacromial pain associated with recent overuse may indicate irritation of the subacromial bursa. Examination of the adult is unlikely to reveal laxity, but signs of impingement often are present. Radiographs often are unremarkable, but may reveal abnormality of the acromium or a physically narrowed subacromial space.

Initial treatment consists of relative rest, analgesics (nonsteroidal anti-inflammatory drugs or acetaminophen), and instructions to maintain good range of motion ("walking" the hand up a wall is a good way to maintain abduction). Moderate to severe pain can be treated with a brief course of narcotics, especially for evening. Those comfortable with joint injections can place 5-10 mL of a 1:1:1 mixture of lidocaine, marcaine, and corticosteroid into the subacromial space. The patient often will have rapid relief, but must be warned of possible steroid flair and increased pain for 1-2 days following injection.

Once the patient has full range of motion, strengthening exercises may be added. Most overuse injuries will respond to conservative treatment,[32] but others will require surgery for repair of chronically damaged tendons and bone trimming/resection to widen the subacromial space. Failure to improve after 4-6 weeks of conservative treatment should prompt referral.

Knee. Anterior knee pain is one of the most common complaints in physically active children and adults. Often, the only major findings are subjective, and finding a specific anatomic abnormality can be challenging. Thus, anatomically specific terms such as patellofemoral syndrome and chondromalacia often are replaced with the more generic term anterior knee pain syndrome.[33] Anterior knee pain frequently is multifactorial. Intrinsic factors include injury to the articular cartilage or subchondral bone or repetitive trauma. The extrinsic factors include quadriceps weakness, femoral anteversion, or patellar instability. History should seek recent changes in activity, to include increased training intensity, duration, new shoes or playing surface, or relatively recent acute injury. On exam, assess for leg alignment and any leg length discrepancy. Excess anteversion at the hip will cause the patella to squint inward. Measure the Q angle (line drawn from anterior superior iliac spine to mid patella, and line drawn from mid patella to tibial tubercle; intersection of the lines should measure less than 15 degrees for males and less than 18 degrees for females). An excessive Q angle may indicate excessive lateral patellar stress, although recent studies have shown a poor correlation between Q angle and knee pain.[34,35] Look at quadriceps development and assess the degree of patellar motion. Palpate the patella throughout range of motion, noting if the patella tracks laterally during terminal extension. Look carefully for an effusion, which may be indicative of a more significant injury to the articular cartilage. On pediatric patients, always consider that hip pathology may result in referred pain to the knee.

Pain at the inferior pole of the patella and/or along the patellar tendon is consistent with patellar tendinosis or jumper's knee. Acute overuse may result in inflammation and swelling of the tendon, while pain lasting several weeks or longer typically is associated with tendon degeneration. Elicit a history of repeated

Figure 4. Acute Forefoot Fracture

A 21-year-old college basketball player reported a painful forefoot pop during a rapid change of direction on the court. Further prompting revealed a history of gradually worsening forefoot pain over several weeks. Radiographs revealed cortical thickening and periostial elevation at the site of the injury. The patient has sustained an acute fracture through an already developing stress fracture.

Table 5. Foot Pain in the Running Athlete: Red Flags

Historical and physical findings that should prompt close scrutiny:

NIGHT PAIN

Pain that develops in the evening after physical activity often is seen early in stress fracture. Remove patient from all painful activity until asymptomatic. Consider bone scan or MRI to confirm diagnosis. Following resolution of symptoms, a graded return to activity is appropriate.

PERIOSTIAL ELEVATION

This is the earliest radiographic change from stress fracture. Immobilize these patients (a post-operative shoe often is adequate) and restrict activity until asymptomatic.

DORSAL PAIN

Complaints of dorsomedial pain, especially when combined with navicular tenderness on exam, may indicate navicular stress fracture. Early radiographs are often normal. Place the patient in a non-weight bearing splint and arrange for bone scan or MRI.

JONES' FRACTURE

Whether acute or chronic, fracture at the junction of the metaphysis and diaphysis of the fifth metatarsal has a high rate of malunion, and orthopedic evaluation is recommended.

sprinting, jumping, or squatting, and look for excessive tightness in the quadriceps and hamstrings.

Most overuse injuries to the knee respond with conservative treatment. Relative rest and cross-training with low-impact activities should be encouraged. Cycling, swimming, and elliptical machines provide excellent alternatives for the running athlete. Malalignment issues may need to be addressed with orthotic inserts. Therapeutic exercise consists of low-impact exercise (such as straight leg raises) to increase quadriceps strength, and stretching to increase quadriceps and hamstring flexibility. Patellar taping and bracing may be useful in reducing discomfort and increasing proprioceptive stimuli. Generally, imaging studies are not indicated in knee overuse unless the history or physical exam points toward another diagnosis or the patient fails to respond to conservative treatment. Plain films can be used to determine the presence of bony tumors or OA; MRI is the preferred imaging modality when cartilaginous injury is suspected.

Foot and Ankle. Achilles tendinosis is seen predominantly in running athletes. Onset usually is insidious and related to degenerative changes within the tendon, most often in the relatively avascular region 3-4 cm above the calcaneal insertion.[28] The physical exam reveals tenderness along the tendon body, and tenderness may be present at the tendon insertion. Passive dorsiflexion may reveal tightness of the affected tendon. Conservative treatment consists of relative rest, cross-training, and gentle stretching. Heel lifts may provide temporary relief, but significant malalignment issues should be addressed with orthotic inserts. Injections are not recommended routinely due to the risk of tendon rupture. Patients with long-standing pain and tendon degeneration may require surgical referral.

Retrocalcaneal bursitis occurs when the bursa between the skin and the Achilles tendon or between the tendon and the calcaneus becomes irritated. This occurs due to friction from tight-fitting shoes, most often in runners or in organized aerobics. The patient will complain of pain on the posterior heel. A positive two-finger squeeze test (pain with pressure on the bursa just anterior and superior to the tendon insertion) helps confirm the diagnosis. This entity should be differentiated from Haglund's deformity or "pump bump," in which friction from use of tight-fitting women's shoes cause pathologic bone growth over the posterior calcaneus.[36] Initial intervention consists of friction reduction, using either open-back shoes or padding such as moleskin, lamb's wool, or pre-shaped adhesive pads. Ensure that the patient is wearing a quality shoe that is neither too tight over the heel, nor allows excessive foot sliding. Haglund's deformity will respond to the same treatments, although referral to a podiatrist or orthopedic surgeon for excision of the abnormal bone growth may be required.

Plantar fasciitis also is referred to as subcalcaneal pain or, more generally, heel pain syndrome. It is a common problem among athletes and non-athletes alike. Patients complain of gradual onset heel pain that is worse upon arising in the morning or after a period of inactivity. This is secondary to the disruption of connective tissue cross-links formed while the foot rests in plan-

tarflexion. Examination reveals maximal tenderness at the plantar-medial aspect of the calcaneus. Radiographs of the foot may reveal a "heel spur." While often present in chronic or recurrent cases, spurring of the calcaneus is not the cause of pain but rather a result of ongoing periosteal irritation.

Examination may reveal hyperpronation and a tight Achilles tendon, both of which increase tensile forces on the plantar fascia. Other risk factors include a change in sporting activity or intensity, poorly fitting footwear, and obesity.

Treatment can be challenging, and symptoms may persist for months.[37] Limit barefoot walking, and be sure the patient is wearing a well-padded athletic shoe that protects the heel and supports the arch. Over-the-counter or custom-made arch supports may be helpful. Instruct the patient on proper Achilles tendon stretching and toe curls to strengthen muscles of the foot. Oral analgesics and ice massage (i.e., rolling a can of frozen juice under the foot) can help ease pain. Night splints are available from a number of manufacturers. The theory is that by sleeping with the foot in dorsiflexion (cocked up toward the body), injured fascia heals under tension. Therefore, the first few steps in the morning will not stretch and reinjure tissue cross-linking formed overnight. Night splints have not been proven effective, however, and compliance is low due to bulk and discomfort.

Running athletes who present with gradually worsening foot pain should be scrutinized carefully. (*See Table 5 and Figure 4.*) Early stress injury may be difficult to diagnose. Stress fractures of the tarsal navicular and Jones' fractures have high rates of nonunion. Early use of a bone scan or MRI is indicated if these injuries are suspected.[36,38]

The Pediatric Athlete

The number of children and adolescents participating in organized athletics has seen a steady growth over the past 10 years. As a result, the number of injuries has increased as well. Recent calls by public health officials to get sedentary kids and teens off the couch and out participating in athletics likely will help maintain this upward trend.[1,39] The family practitioner who sees a sizeable number of pediatric patients can expect to see a growing number of injuries. Often, the pediatrician or family practice physician will be asked to perform the pre-participation physical exam and, following injury, will be asked to determine if the child can safely return to play. Therefore, a working knowledge of pediatric sports medicine is mandatory.

The adage about children not being small adults is particularly true in regard to the musculoskeletal system. As a general rule, sports-related musculoskeletal injury can be divided into two broad categories: acute traumatic injury and repetitive trauma (overuse) injury. While both of these entities also present in adults, unique features of growing muscle and bone alter the injury patterns. These features include the increased elasticity of pediatric bone, the presence of growth plates (epiphyses and apophyses), and growth spurts wherein fast-growing bone outpaces muscle and tendon growth, with resultant muscular tightness and heightened risk of tendinous avulsion.

As in the adult, the most common acute injuries in pediatric athletes are contusions, muscle and tendon strains, and ligament sprains. Unlike adults, the weak link in the pediatric kinetic chain is not connective tissue but rather the soft bone to which the tissues connect, and adjacent growth plates. Any child who sustains a significant sprain or strain in the vicinity of bone should receive a radiograph to rule out bony avulsion or a fracture of the epiphysis. If the patient is tender to palpation over an apophysis (a secondary ossification site at a tendon attachment) such as the ASIS, AIIS, medial epicondyle, or base of the fifth metatarsal, examine the film to ensure the growth plate has not been avulsed. If it is uncertain, obtain a comparison view of the opposite growth plate. Most contusions, sprains, strains, and even minor (several millimeters or less) avulsion injuries can be treated conservatively with PRICE and a gradual return to play once symptoms have resolved. Significantly displaced or debilitating injury should be referred to a pediatric orthopedist.[40]

Thick periosteum and elastic bone results in unique pediatric fracture patterns.[41] Compressive force to the bone can cause it to fail, resulting in a buckle or torus fracture at the junction of the metaphysis and diaphysis. These fractures appear as a small buckle in the cortex, and can be easy to overlook if small. Torus fractures can be treated conservatively with rest and immobilization for comfort, and heal without complication. Greenstick fractures are an incomplete fracture wherein the bone bends under stress. This results in bowing and compression on the concave side, with cortical disruption on the convex side. Minimally angulated bone may be treated with immobilization, but any significant angulation will require orthopedic referral for reduction and casting.

Physeal (growth plate) fractures classically have been described using the Salter-Harris Classification. The most common injuries are Salter Harris 1 through 5, wherein the larger number carries an increased risk for growth plate arrest. Salter 1 is a fracture through the physis; the physis is tender and may be widened on radiographs. Non-displaced Salter 1 fractures have an excellent prognosis and can be treated with rest and immobilization. Significantly widened Salter 1 injuries will need referral for reduction and prolonged immobilization. Salter 2 fractures are transverse through the physis and metaphysis. Theprognosis for these fractures is similar to Salter 1 injuries; a non-displaced Salter 2 should heal following several weeks of immobilization. Salter 3 injuries extend through the physis into the epiphysis. Growth plate arrest is rare; however, these are intra-articular fractures, so anatomic reduction by an orthopedist is paramount prior to immobilization. Salter 4 fractures project through the metaphysis, across the physis, and through the epiphysis. These fractures may result in growth plate arrest and/or damage to the articular cartilage, so immobilization with early orthopedic referral is mandatory. Salter 5 fractures result from compression of the physis, and may present initially similar to Salter 1 fracture. These often are recognized retrospectively, when premature closure or asymmetric growth of the physis is noted radiographically. If this injury is suspected, immobilize the extremity and refer the patient to an orthopedist; unfortunately, little can be done to alter prognosis.

The epidemiology of overuse injuries in the pediatric population has changed in recent years.[42,43] Children involved in free play or multiple, seasonal sports rarely develop overuse syndromes. With growing participation in competitive youth sports, often with involvement in the same sport year-round, the number of overuse injuries has grown.

As in adults, pediatric athletes can develop inflammatory and/or degenerative changes to muscle and tendon; however, growth plates remain the area most vulnerable to overuse injury. Traction apophysitis occurs with repetitive stress at an apophysis. Among the most common are the insertion of the patellar tendon on the tibial tuberosity (Osgood Schlatter's disease), the abdominals and hip abductors on the iliac crest, and the Achilles tendon on the calcaneal apophysis (Sever's disease). In most cases, these diagnoses can be made by history and physical exam, wherein the active athlete (often during a growth spurt) is tender to palpation over the physis. Soft-tissue swelling may be evident. Radiographs may be used to look for other conditions, such as infection or neoplasm. Treatment consists of relative rest and cross-training, ice, and stretching. A gradual return to play is warranted once symptoms subside.

The pediatric athlete who presents with a limp should be evaluated for slipped capital femoral epiphysis (SCIFE). This disorder, seen mostly in adolescent males, occurs when the proximal femoral epiphysis slips posterior at the growth plate.[44] The child may complain of hip pain or develop referred pain to the knee or thigh. A physical exam reveals tenderness over the anterior hip and pain with internal rotation. The diagnosis is confirmed by the presence of capital epiphyseal displacement downward and posterior on AP and frog-leg lateral radiographs. Compare bilateral Kline's lines (drawn parallel to the superior femoral neck); a line transecting less or none of the physis on one side suggests SCIFE. Treatment is immediate cessation of weight-bearing and referral to a pediatric orthopedist for surgical fixation.

The pathophysiology of stress fractures in the pediatric athlete is similar to that in adults.[45] Of particular concern in the growing athlete is the complaint of low back pain, which may be indicative of stress fracture of the pars interarticularis, known as spondylolysis. Athletes at risk include those in sports that require repetitive hyperextension of the back, such as football players, gymnasts, and weight lifters. Stress injury to the pars classically presents with the gradual development of low back pain, most often during rapid growth, which is exacerbated by lumbar extension. Early plain radiographs most often are negative, but a bone scan or MRI should show changes of the affected joint. Once a pars stress fracture has gone on to completion, it should be visible on AP and lateral radiographs; oblique films may increase sensitivity somewhat, where a pars fracture will appear as a line through the neck of the "Scotty dog." Unstable unilateral and bilateral pars fractures may result in spondylolisthesis, anterior displacement of a vertebral body on the adjacent vertebra. Once this has occurred it is irreversible. Early diagnosis is important; a period of rest and stretching/strengthening exercises can allow the stress fracture to heal. In athletes in whom the diagnosis is suspected, obtain a bone scan if an initial period of rest and stretching does not result in marked improvement. Athletes with a positive scan should discontinue their sport and engage in low-impact cross training. Some authors advocate bracing, but this has not been proven to improve outcomes. Treatment regimens are variable and should be tailored to the athlete. Restrict athletes until they are asymptomatic (this may take several weeks to several months) combined with functional rehabilitation, and then begin a graded return to sport. Athletes with spondylololisthesis can safely participate; treatment for discomfort consists of flexibility and core stability exercises. Surgery is controversial and generally reserved for those with high-grade slippage (> 50%), progressive slippage, or neurological compromise.

References

1. Centers for Disease Control and Prevention. Nonfatal sports- and recreation-related injuries treated in emergency departments—United States, July 2000-June 2001. *MMWR Morb Mortal Wkly Rep* 2002;51:736-740.
2. US Department of Health and Human Services, The Surgeon General's call to action to prevent and decrease overweight and obesity. Rockville, Maryland: US Department of Health and Human Services, Public Health Office, Office of the Surgeon General, 2001.
3. Matheson G, Pallay R, Cardone D, et al. *Preparticipation Physical Evaluation,* 3rd ed. New York City: McGraw-Hill; 2004.
4. Maron BJ. Sudden death in young athletes. *N Engl J Med* 2003;349:1064-1075.
5. Maron BJ, Zipes DP. Introduction: Eligibility recommendations for competitive athletes with cardiovascular abnormalities. *J Am Coll Cardiol* 2005;45:1318-1321.
6. McCrory P, Johnston K, Meeuwisse W, et al. Summary and Agreement Statement of the 2nd International Conference on Concussion in Sport, Prague 2004. *Clin J Sport Med* 2005; 15:48-55.
7. Guskiewicz KM, McCrea M, Marshall SW, et al. Cumulative effects associated with recurrent concussion in collegiate football players: The NCAA Concussion Study. *JAMA* 2003; 290:2549-2555.
8. Kushner DS. Concussion in sports: Minimizing the risk for complications. *Am Fam Phys* 2001;64:1007-1014.
9. Lovell MR, Collins MW, Iverson GL, et al Recovery from mild concussion in high school athletes. *J Neurosurg* 2003; 98:295-301.
10. McCrea M, Guskiewicz KM, Marshall SW, et al. Acute effects and recovery time following concussion in collegiate football players: The NCAA Concussion Study. *JAMA* 2003; 290:2556-2563.
11. Luime JJ, Verhagen AP, Miedema HS, et al. Does this patient have an instability of the shoulder or a labrum lesion? *JAMA* 2004;292:1989-1999.
12. Hutton K, Julin M. Shoulder Injuries. *The Team Physician Handbook*, 2nd ed. Philadelphia, PA: Hanley & Belfus; 1997.
13. Gronski D. Injuries to the upper extremity. *Sports Medicine*

in Primary Care. Philadelphia, PA: WB Saunders; 2000.
14. Zemel NP, Stark HH. Fractures and dislocations of the carpal bones. *Clin Sports Med* 1986;5:709-724.
15. Geissler WB. Carpal fractures in athletes. *Clin Sports Med* 2001;20:167-188.
16. Brooks S, Wluka AE, Stuckey S, et al. The management of scaphold fractures. *J Sci Med Sport* 2005;8:181-189.
17. Tiedeman J, Thomas F. Hand and wrist injuries. *The Team Physician Handbook*, 2nd ed. Philadelphia, PA: Hanley & Belfus; 1997.
18. Mack RP. Ankle injuries in athletes. *Clin Sports Med* 1982;1:71.
19. Brown D. Ankle and leg injuries. *The Team Physician Handbook*, 2nd ed. Philadelphia, PA: Hanley & Belfus; 1997.
20. Stiell IG, Greenberg GH, McKnight RD, et al. Decision rules for the use of radiography in acute ankle injuries: Refinement and prospective validation. *JAMA* 1993;269:1127.
21. Safran MR, Benedetti RS, Bartolozzi AR 3rd, et al. Lateral ankle sprains: A comprehensive review. Part 1: Etiology, pathoanatomy, histiopathogenesis, and diagnosis. *Med Sci Sports Exerc* 1999;31:S429.
22. Safran MR, Zachazewski JE, Benedetti RS, et al. Lateral ankle sprains: A comprehensive review. Part 2: Treatment and rehabilitation with an emphasis on the athlete. *Med Sci Sports Exerc* 1999; 31:S438.
23. Solomon DH, Simel DL, Bates DW, et al. The rational clinical examination. Does this patient have a torn meniscus or ligament of the knee? Value of the physical exam. *JAMA* 2001;286:1610-1620.
24. Emparanza JI, Aginaga JR, Estudio Multicentro en Urgencias de Osakidetza: Reglas de Ottawa (EMUORO) Group. Validation of the Ottawa Knee Rules. *Ann Emerg Med* 2001;38:364-368.
25. Cooper R, et al. Acute knee injuries. *Clinical Sports Medicine*. New York: McGraw-Hill; 2002.
26. Linko E, Harilainen A, Malmivaara A, et al. Surgical versus conservative interventions for anterior cruciate ligament ruptures in adults. *Cochrane Database Syst Rev* 2005; (2):CD001356.
27. Margheritini F, Rihn J, Musahl V, et al. Posterior cruciate ligament injuries in the athlete: An anatomical, biomechanical and clinical review. *Sports Med* 2002;32:393-408.
28. Maffulli N, Testa V, Capasso G, et al. Similar histopathological picture in males with Achilles and patellar tendinopathy. *Med Sci Sports Exerc* 2004;36:1470-1475.
29. Stanitski CL, McMaster JH, Scranton PE. On the nature of stress fractures. *Am J Sports Med* 1978;6:391-396.
30. Gaeta M, Minutoli F, Scribano E, et al. CT and MR imaging findings in athletes with early tibial stress injuries: Comparison with bone scintigraphy findings and emphasis on cortical abnormalities. *Radiology* 2005;235:553-561.
31. Jobe FW, Bradley JP. The Diagnosis and Nonoperative Treatment of Shoulder Injuries in Athletes. *Clin Sports Med* 1989; 8:419-437.
32. Nadler SF, Sherman AL, Malanga GA. Sport-specific shoulder injuries. *Phys Med Rehabil Clin N Am* 2004;15:607-626.
33. LaBotz M. Patellofemoral syndrome: Diagnostic pointers and individual treatment. *The Physician and Sportsmedicin*e 2004;32:22-29.
34. Hand CJ, Spalding TJ. Association between anatomical features and anterior knee pain in a "fit" service population. *J R Nav Med Serv* 2004;90:125-134.
35. Biedert RM, Warnke K. Correlation between the Q angle and the patella position: a clinical and axial computed tomography evaluation. *Arch Orthop Trauma Surg* 2001;121: 346-349.
36. Wargon C. Common foot injuries. *ACSM's Essentials of Musculoskeletal Care*. St. Louis, MO: Mosby; 1997.
37. Crawford F, Thomson C. Interventions for treating plantar heel pain. *Cochrane Database Syst Re*v 2003;(3):CD000416.
38. Coris EE, Lombardo JA. Tarsal navicular stress fractures. *Am Fam Physician* 2003;67:85-90.
39. US Department of Health and Human Services. *Healthy People 2010*, 2nd ed. With understanding and improving health and objectives for improving health. Washington, DC: US Department of Health and Human Services, 2000.
40. Moeller Jl. Pelvic and hip apophyseal avulsion injuries in young athletes. *Curr Sports Med Rep* 2003;2:110-115.
41. Smith A. Musculoskeletal injuries unique to growing children and adolescents. *ACSM's Essentials of Musculoskeletal Care*. St. Louis, MO: Mosby; 1997.
42. Lord J, Winell JJ. Overuse injuries in pediatric athletes. *Curr Opin Pediatr* 2004;16:47-50.
43. Hogan KA, Gross RH. Overuse injuries in pediatric athletes. *Orthop Clin North Am* 2003;34:405-415.
44. Greene WB, ed. *Essentials of Musculoskeletal Care*, 2nd ed. Rosemont, Ill: American Academy of Orthopaedic Surgeons; 2001.
45. Richardson C, Singer JI, Springer B. Subacute leg pain. *Pediatric Emergency Care* 2005;21:387-390.

Physician CME Questions

25. When performing a pre-participation evaluation, it is the physician's responsibility to do all of the following *except*:
    A. assess the patient from both a medical and musculoskeletal perspective.
    B. obtain an echocardiogram.
    C. inquire about history of previous concussions.
    D. make a notation of any chronic medical conditions and allergies.

26. Risk factors for exercise-associated sudden death include which of the following?
    A. Marfan's syndrome
    B. Family history of structural heart disease
    C. Hyperlipidemia
    D. All of the above

27. The murmur associated with hypertrophic cardiomyopathy decreases with standing or valsalva.

A. True
B. False

28. A 17-year-old high school quarterback is slow to get up after being sacked in the second quarter. On the next play, he throws an interception to the right side, despite all receivers being on the left. On the sidelines, he denies any headaches, nausea, or dizziness. He has a normal neurological evaluation, but on questioning he does not recall the sack or the interception. By halftime, he is eager to return to the game. He is asymptomatic, has 3 out of 3 short- and long-term memory, and a normal serial sevens exam. The physician should:
    A. allow him to return to play. If he has further symptoms, then remove him from this game and from play for one week.
    B. physically exert him on the sidelines and re-evaluate symptoms. If he still is asymptomatic, then he has a grade 1 concussion and must sit out for one week.
    C. rest him the remainder of the game and re-evaluate him later in the week.
    D. obtain imaging studies before further decisions are made.

29. An 18-year-old soccer player was cutting off of her left leg yesterday when she felt a pop and her knee gave way. She was unable to continue play and required assistance off the field. On exam you note a large effusion. The most useful next step is to :
    A. immobilize the knee and obtain radiographs.
    B. place her in a hinged knee brace and allow her to resume activity as tolerated.
    C. perform Lachman's test and anterior drawer test.
    D. perform McMurray's test.

30. A basketball player jammed his long finger diving for a ball. He has a swollen DIP joint. He has full motion of the PIP, but lacks active extension of the DIP. Radiographs of the long finger do not demonstrate a fracture. Proper treatment consists of:
    A. splinting the entire finger in extension for 6 weeks.
    B. splinting the DIP only in full extension for 6 weeks.
    C. splinting the DIP for activity, but allowing him to take the splint off at least twice daily to maintain motion.
    D. immobilizing the wrist and hand in a short arm cast for 6 weeks.

31. Weakness of the infraspinatus tendon of the shoulder is most likely to affect which of the following motions?
    A. Internal rotation
    B. Horizontal flexion
    C. Abduction
    D. External rotation

32. Which of the following statements is true regarding patellofemoral pain in athletes?
    A. It is strongly linked to the Q-angle.
    B. It is associated with development of an effusion.
    C. It often is lacking in objective physical findings.
    D. It is seen more often in older athletes.

33. A 10-year-old multi-sport athlete complains of gradually increasing pain in his heels while running, with pain in the left heel greater than that in the right. The exam is essentially unremarkable. Options to treat include:
    A. corticosteroid injection of the plantar fascia.
    B. gentle stretching of the Achilles tendon.
    C. low impact cross-training.
    D. both B and C.

In Future Issues:

Secondary Osteoporosis

Primary Care Reports

CME Objectives

To help physicians:

• summarize the most recent significant primary care medicine-related studies;

• discuss up-to-date information on all aspects of primary care, including new drugs, techniques, equipment, trials, studies, books, teaching aids, and other information pertinent to primary care;

• evaluate the credibility of published data and recommendations; and

• describe the pros and cons of new testing procedures.

CME Instructions

Physicians participate in this continuing medical education program by reading the article, using the provided references for further research, and studying the questions at the end of the article. Participants should select what they believe to be the correct answers, then refer to the list of correct answers to evaluate their knowledge. To clarify confusion surrounding any questions answered incorrectly, please consult the source material. *After completing this activity, you must complete the evaluation form that will be provided at the end of the semester and return it in the reply envelope provided to receive a certificate of completion.* When your evaluation is received, a certificate will be mailed to you.

CME Answer Key

25. B
26. D
27. B
28. C
29. C
30. B
31. D
32. C
33. D

MANAGING PAIN AND END-OF-LIFE ISSUES

Thomson American Health Consultants

Online CME activity:

Online: visit www.cmeweb.com. Log in with your username and password. If this is your first visit, click "Register now" and sign up. Then, enter "managing pain" in the search box and click "go." Follow the prompts to take the course online. Upon completion, you will receive your CME credit letter via email. The cost is $69. Payment is made online with your credit card.

Objectives: The objectives of *Managing Pain and End-of-Life Issues* are to: discuss the ethics involved in end-of-life care and pain management; describe steps the clinician can take to facilitate negotiations and resolve conflicts related to end-of-life issues; discuss what steps to take with patients to plan for end of life; identify key steps in the definition, assessment, and treatment options related to pain.

Target Audience: This program is intended for primary care physicians and hospital physicians.

Sponsor: The sponsor of this CME activity is Thomson American Health Consultants.

Accreditation: Thomson American Health Consultants is accredited by the Accreditation Council for Continuing Medical Education (ACCME) to provide continuing medical education for physicians.

Managing Pain and End-of-Life Issues: A Guide for California Physicians, Volume 1

Thomson American Health Consultants designates this educational activity for a maximum of 7 *AMA PRA Category 1 Credits*™. Physicians should only claim credit commensurate with the extent of their participation in the activity.

PHARMACOLOGY WATCH

Supplement to Clinical Cardiology Alert, Clinical Oncology Alert, Critical Care Alert, Infectious Disease Alert, Internal Medicine Alert, Neurology Alert, OB/GYN Clinical Alert, Primary Care Reports, Travel Medicine Advisor.

Reversal of Atherosclerosis Via Intensive Statin Therapy

Aggressive LDL lowering with statins, so-called "very intensive statin therapy," leads to reversal of coronary atherosclerosis, according to a new study. The ASTEROID (A Study to Evaluate the Effect of Rosuvastatin on Intravascular Ultrasound-Derived Coronary Atheroma Burden) trial, a perspective, open label, blinded end-points trial, utilized the potent statin rosuvastatin in evaluating whether very intensive statin therapy resulting in LDL cholesterols in the low 60s associated with increases in HDL cholesterol could reverse atherosclerosis. Five hundred and seven patients were initially evaluated with intravascular ultrasound (IVUS) to determine baseline atheroma burden. Patients were then treated with intensive statin therapy with rosuvastatin 40 mg daily for 24 months, which resulted in an average LDL cholesterol of 60.8 mg/dL (mean reduction, 53.2%) and increased HDL cholesterol by 14.7%. IVUS was performed again at 24 months. The mean change in atheroma volume in the most diseased 10 mm sub segment was -6.1 (10.1) mm^3, with a median of -5.6 mm^3 ($P < .001$ vs baseline). Change in total atheroma volume showed a 6.8% median reduction. Adverse events were infrequent. Specifically there were no cases of rhabdomyolysis.

The authors conclude that lowering LDL-C to levels below currently accepted guidelines, when accompanied by significant increases HDL-C, can regress atherosclerosis in coronary disease patients, and is indicated for high-risk patients with established coronary disease (*JAMA*. 2006;295:1556-1565). An accompanying editorial notes that the study had several limitations, including lack of a control group or a comparator drug. They also note that the modest plaque reduction noted in this study "may not be the best measure of the treatment's effect on hard cardiovascular end points", however, they do applaud the pioneering work using intravascular ultrasound to help understand the anatomy and pathophysiology of coronary atherosclerosis and the effect of medical therapy on atheroma (*JAMA*. 2006;295:1583-1584).

Alternative Therapy for Depression?

Patients who fail SSRI treatment for depression may respond to an alternative medication, or the addition of a second medication, according to 2 studies in the March 23 *New England Journal of Medicine*. In the first study, 727 adults with a nonpsychotic major depressive disorder who had no remission of symptoms or could not tolerate the SSRI citalopram (Celexa) were randomized to receive sustained release bupropion

This supplement was written by William T. Elliott, MD, FACP, Chair, Formulary Committee, Kaiser Permanente, California Division; Assistant Clinical Professor of Medicine, University of California-San Francisco. In order to reveal any potential bias in this publication, we disclose that Dr. Elliott reports no consultant, stockholder, speaker's bureau, research, or other financial relationships with companies having ties to this field of study. Questions and comments, call: (404) 262-5416. E-mail: leslie.hamlin@thomson.com.

(Wellbutrin) in a maximal daily dose of 400 mg, sertraline (Zoloft) at a maximum daily dose of 200 mg, or extended release venlafaxine (Effexor-XR) at a maximal daily dose of 375 mg for up to 14 weeks. The primary outcome was remission of symptoms based on the Hamilton Rating Scale of Depression (HRSD-17). Secondary outcomes included scores on the Quick Inventory of Depressive Symptomatology (Self-Report) (QIDS-SR-16). Remission rates, as assessed by the 2 scales, respectively, were bupropion - 21.3% and 25.5%, sertraline - 17.6% and 26.6%, venlafaxine - 24.8% and 25.0%. Response rates based on the QIDS-SR-16 were bupropion 26.1%, sertraline 26.7%, and venlafaxine 28.2%. There was no significant difference with respect to outcomes, tolerability, or adverse effects among the 3 drugs.

The authors conclude that after unsuccessful treatment with an SSRI, 1 in 4 patients have a remission after switching to another antidepressant, and all 3 drugs in the trial were reasonable choices (*N Engl J Med*. 2006;354:1231-1242). Another option for treating patients who failed treatment with citalopram was explored in the second study in the same issue. In the study, 565 adults who had a nonpsychotic major depressive disorder without remission after 12 weeks of citalopram therapy were randomized to receive add-on therapy with sustained release bupropion up to 400 mg per day, and 286 were randomized to receive buspirone (Buspar) at a dose of up to 60 mg per day. The same depression rating scales were used in this study as in the previous study. For bupropion and buspiron, respectively, HRSD-17 remission rate was 29.7% vs 30.1%, QIDS-SR-16 remission rate was 30.9% vs 32.9%, and QIDS-SR-16 response rate was 31.8% vs 26.9%. Bupropion was associated with a greater change in QIDS-SR-16 score, as well as the overall lower QIDS-SR-16 score at the end of the study and a lower dropout rate to due to intolerance (12.5% vs 20.6%, $P < 0.009$).

The authors conclude that the addition of bupropion or buspirone to citalopram is useful; however, the addition of bupropion may have some advantages, including a greater reduction in the severity of symptoms in fewer side effects (*N Engl J Med*. 2006;354:1243-1252).

FDA Actions

The FDA has approved the first generic HIV/AIDS drug for use in the United States. Zidovudine, manufactured under the trade name Retrovir by GlaxoSmithKline, was initially approved in 1987, and the company has had exclusive manufacturing rights until the drug's patent expired in September 2005. The generic is made by Aurobindo Pharma LTD of India. This is the same company that recently received approval from the FDA to co-package 3 antiretroviral drugs for the treatment of HIV/AIDS outside the United States. The regimen consists of lamivudine/zidovudine combination tablet along with efavirenz tablets. The co-packaging of these products has met the clinical safety, efficacy, and manufacturing quality standards required by the FDA. The approval is part of the Presidents Emergency Plan for offering full HIV treatment regimens for targeted areas of the world that are at risk to prevent HIV transmission and to treat AIDS and associated conditions. Patents and exclusivity prevent marketing of this combination in United States.

The FDA has approved a transdermal patch for the treatment of children with attention-deficit hyperactivity disorder. The patch delivers methylphenidate, the same ingredient found in Ritalin, in a daily patch that is applied early in the morning and removed 9 hours later. Methylphenidate patch is manufactured by Shire Pharmaceuticals and Noven Pharmaceuticals under the trade name Daytrana.

Salix pharmaceuticals has received approval to market a new tablet bowel prep for colon cleansing prior to colonoscopy. The virtually tasteless sodium phosphate tablets are an alternative to traditional liquid PEG bowel preps. The recommended dose is 32 tablets taken orally with a total of 2 quarts of clear liquids, administered as 4 tablets with 8 ounces of liquid every 15 minutes. Twenty tablets are given on the night prior to the procedure, with the remaining 12 tablets administered 3 to 5 hours prior to colonoscopy. Sodium phosphate tablets will be manufactured under the trade name OsmoPrep. ■