THOMSON
AMERICAN HEALTH CONSULTANTS

Evidence-Based M ED

Trauma Reports

Enclosed in this issue: CE/CME Evaluation

Vol. 7, No. 5

Supplement to *Emergency Medicine Reports* and *Pediatric Emergency Medicine Reports*

September/October 2006

The authors of this article discuss the diagnosis and treatment of the traumatized hand. Trauma practices often focus on mortality, and while death by hand injury is rare, the morbidity is vast. The complexity of the hand is striking, and the examination alone of the hand is daunting to many practitioners. In this article the authors present a review of the basics, beginning with a section describing a standard-of-care hand examination including a structured "two-minute hand exam," followed by a discussion of many classic hand injuries. Common fractures, dislocations, and ligamentous injuries also are covered in detail, as are the appropriate acute care treatments including appropriate splinting techniques and follow-up. This article simplifies a complicated topic and will be beneficial to diverse practitioners responsible for assessing, triaging, and managing a patient with a hand injury.

— The Editor

Adult Hand Trauma

Authors: **John C. Southall, MD, FAAEM, FACEP,** Resident Research Director, Department of Emergency Medicine, Maine Medical Center, Portland, Maine; **Stephen Patrick Sanders, MD,** Emergency Medicine Resident, Maine Medical Center, Portland ME

Peer Reviewer: **Mary Jo Bowman, MD, FAAP, FCP,** Associate Professor of Clinical Pediatrics, Ohio State University College of Medicine, Attending Physician, Emergency Department, Columbus Children's Hospital, Columbus, Ohio

Epidemiology and Introduction

Annually, more than 16 million people suffer some form of hand injury with more than 4.8 million seen in emergency departments (EDs).[1] Traumatic injuries may include lacerations, fractures, and tendon or ligamentous injuries. Fortunately, most injuries can be easily identified in the ED by history, physical examination, and plain film radiography alone.[2] Because the morbidity from misdiagnosed or mistreated hand injuries can be high, the clinician needs to remain vigilant for these injuries.

History

As with all areas of medicine, a careful history in a patient with a hand injury is critical. Specific questions should include mechanism of injury, hand position at the time of injury, the direction of the force, time elapsed since the injury, and environ-

Statement of Financial Disclosure

Dr. Dietrich (editor in chief) reports that she receives grant/research support from the National Institutes of Health and is the medical director for the Ohio Chapter of the American College of Emergency Physicians. Drs. Southall and Sanders (authors), and Bowman (peer reviewer), Ms. Finerty (nurse reviewer), and Ms. Neff (nurse reviewer) report no relationships with companies related to this field of study.

mental (contamination) considerations.[3] Some mechanisms yield classic injury patterns, such as the 'jersey' or 'mallet' fingers, and should increase the practitioner's index of suspicion. Other injury patterns are known for their poor outcomes (e.g., 'fight bite' or high-pressure injection injuries) and require specific management strategies.[4] Other wounds are more prone to infection (e.g., crush injuries and grossly contaminated wounds).

The patient's hand dominance and career also should be ascertained and documented, as well as factors that may compromise healing (e.g., smoking, drug use, or any immunocompromised state).[3] While not relevant to the diagnosis of acute injury, the answers to these questions will affect follow-up by affecting the risk/benefit ratios that the hand surgeons will use in their discussions with the patient. Lastly, tetanus immunization status should be ascertained.[4]

Physical Examination

The following description is that of a thorough hand-specific examination. The authors assume that there are no 'ABC' issues or multitrauma concerns or that they have already been addressed.

Despite its complicated nature, the hand may be examined adequately in a short period of time. Memorizing a rapid routine hand exam and performing it systematically and regularly will decrease the chances of missing more subtle injuries.[5] *Table 1* highlights one technique for performing a rapid but thorough exam.

Knowledge of the basic bony structures of the hand is assumed. The back of the hand is referred to as the dorsal surface, while the palm may be called either the palmar or volar surface. The lateral borders of the hand are referred to as radial or ulnar. Movement may be in any of these planes. Additionally, fingers may abduct away from, or adduct toward, an imaginary plane bisecting the third finger. The thumb has further planes of movement. These and specific ligaments and tendons of importance will be discussed individually.

Assuming that there is no active bleeding requiring immediate attention, the examination of the hand begins with simple observation. All rings, watches, or other potentially constricting devices should be removed immediately regardless of their proximity to the injury because soft-tissue swelling and edema may spread to non-injured digits.[6] Violations of the skin should be easily recognized, but also note any erythema, soft-tissue swelling, or ecchymoses. It is important to compare the general position of the hand with the unaffected side because many fractures or tendon disruptions will alter the outward appearance of the hand. For example, a hand held in flexion may indicate disruption of an extensor tendon, while bruising or discoloration at a joint may indicate closed tendon or joint capsule injury.

Vascular integrity can be determined quickly by feeling for ulnar and radial pulses, and by documenting intact and symmetric distal capillary refill. Normal capillary refill is less than two seconds in a normotensive adult.

Neurologic testing should be performed prior to anesthesia. Radial, median, and ulnar nerves should be individually challenged as below, and digital nerves interrogated via both light touch and two-point testing. Two-point discrimination of 3-5 mm is considered normal.[6] Comparison with the unaffected side can be useful, especially in calloused patients. Denervated skin will not wrinkle when immersed in water for 10 minutes, a fact that can be useful when examining an infant for potential injury.[6] To evaluate for radial neuropathy, first test for decreased sensation at the dorsal aspect of the second and third web space. Proximal limb radial nerve lesions will cause wrist drop. However, the superficial radial nerve, as it courses through the hand, is sensory only. To test for median neuropathy, assess for decreased sensation at the distal, palmar surface of the second digit. Lying the hand dorsal side down and abducting the fifth digit toward the ceiling best tests motor function. Apply resistance and palpate the thenar eminence for contraction of the abductor pollicis brevis. To test for ulnar neuropathy, assess for decreased sensation at the distal, palmar surface of the fifth digit. Challenging the interosseous muscles best tests ulnar motor function. One method is to ask the patient to place his/her hand on a surface with the fifth digit down and the thumb pointing at the ceiling. Then, the patient abducts the second finger (spreading the fingers) against resistance. Document weakness and palpate the first interosseous muscle to verify contraction.

Bone structures should be thoroughly palpated, as should all joints looking for pain, laxity, and limitation to range of motion. Even when a specific injury may be obvious, it is important to examine the entire hand to avoid misdiagnosis of less obvious injuries. Thorough palpation of all bones and passive range of motion at all joints takes the focus off obvious injuries and ensures the entire hand has been examined.

Trauma Reports™ (ISSN 1531-1082) is published bimonthly by Thomson American Health Consultants, 3525 Piedmont Road, N.E., Six Piedmont Center, Suite 400, Atlanta, GA 30305. Telephone: (800) 688-2421 or (404) 262-7436.

Vice President/Group Publisher: Brenda Mooney
Editorial Group Head: Glen Harris
Managing Editor: Martha Jo Dendinger

POSTMASTER: Send address changes to ***Trauma Reports***, P.O. Box 740059, Atlanta, GA 30374.

Accreditation

Thomson American Health Consultants is accredited by the Accreditation Council for Continuing Medical Education to provide continuing medical education for physicians.

Thomson American Health Consultants designates this educational activity for a maximum of 2.5 *AMA PRA Category 1 Credits* . Physicians should only claim credit commensurate with the extent of their participation in the activity.

This activity is approved by the American College of Emergency Physicians for 2.5 hours of ACEP Category 1 credit.

Thomson American Health Consultants is accredited as a provider of continuing nursing education by the American Nurses Credentialing Center's Commission on Accreditation.

Thomson American Health Consultants also is approved by the California Board of Registered Nursing, provider number CEP10864. This activity is approved by the American Association of Critical-Care Nurses (AACN), provider number 10852. This activity is approved for 2.2 nursing contact hours.

This is an educational publication designed to present scientific information and opinion to health professionals, to stimulate thought, and further investigation. It does not provide advice regarding medical diagnosis or treatment for any individual case. It is not intended for use by the layman. Opinions expressed are not necessarily those of this publication. Mention of products or services does not constitute endorsement. Clinical, legal, tax, and other comments are offered for general guidance only; professional counsel should be sought for specific situations.

This CME/CE activity is intended for emergency, family, osteopathic, trauma, surgical, and general practice physicians and nurses who have contact with trauma patients.

It is in effect for 24 months from the date of publication.

THOMSON™
AMERICAN HEALTH CONSULTANTS

Subscriber Information

Customer Service: 1-800-688-2421

Customer Service E-Mail: customerservice@thomson.com
Editorial E-Mail: martha.dendinger@thomson.com

World Wide Web page: http://www.ahcpub.com

FREE to subscribers of *Emergency Medicine Reports* and *Pediatric Emergency Medicine Reports*

For Customer Service,

Please call our customer service department at **(800) 688-2421.** For editorial questions or comments, please contact **Martha Jo Dendinger**, Managing Editor, at martha.dendinger@thomson.com.

Table 1. Two-minute Hand Exam

GENERAL

- General appearence
- Obvious deformity

VASCULAR

- Ulnar, radial pulses
- Capillary refill < 2 seconds
- Hemorrhage control

NEUROLOGICAL

- Ulnar
  - *Sensation:* light touch distal, volar 5th digit
  - *Motor:* Interosseous – abduction 2nd digit
- Median
  - *Sensation:* light touch distal, volar 2nd digit
  - *Motor:* Thenar eminence – adduction 1st digit
- Radial
  - *Sensation:* light touch to dorsal webspace between 2nd-3rd digit
  - *Motor:* Wrist extension, otherwise sensation only in hand
- Two-point discrimination-2-5mm at finger tip, 7-12mm palm; measurable difference between digits

MUSCULOSKELETAL

- Bony palpation of all digits and joints
- Active range of motion: make fist, fully extend all digits
- Passive range of motion: passively take all digits/joints through all ranges
- Resistance: all joints, all ranges with resistance to diagnose partial ligament injuries

LIGAMENTOUS

- FDP: hold PIP in extension, flex DIP against resistance
- FDS: hold MCP in extension, flex PIP against resistance
- Extensor tendons: hand palm down, extend digit with resistance at nail bed
- Ulnar collateral: adduct thumb against resistance

Anesthesia

Multiple techniques exist for anesthetizing the hand and digits, all useful with specific situations. Proper technique is important to limit pain, infection, and to ensure proper anesthesia.[7]

Local infiltration is best used for small superficial, nondigitial lacerations on the hand to allow for complete wound exposure, exploration, and painless closure.[8] Infiltration of anesthetic can be uncomfortable for the patient; but if done properly, the clinician can limit the discomfort. Injection through the open edge of the laceration will limit skin penetration of the anesthetic needle, thus decreasing infection potential. Pre-mixing one part sodium bicarbonate and nine parts lidocaine decreases the acidity of the solution, decreasing initial pain without effecting anesthetic effects.[9]

Digital blocks are preferential for digital lacerations and will provide faster anesthetia without disrupting local anatomy.[10] While digital blocks are safe and effective, contraindications include severe peripheral vascular disease and vasospastic disease (i.e., Raynaud's).[11] Common practice is to use a nonepinephrine-containing local anesthetic. However, a dilute (1:100,000) epinephrine-containing anesthetic may aid the repair by decreasing bleeding and prolonging the efficacy of the anesthetic. Historical concerns that utilizing lidocaine with epinephrine for digital blocks will cause necrosis of the digits have been shown to be false.[11-17] Proper technique is as follows:

- Administer buffered lidocaine with epinephrine (1:100,000) in small amounts. No more that 2-3 mL should be deposited in each digit.
- Do not inject in a circumferential fashion. This will lead to increased dosage and a possible tourniquet effect.
- Use 27-gauge or small needle for injection.
- Avoid tourniquets when not needed, post-anesthetic hot soaks, and excessively tight bandages.[11]

Inject at the middle of the volar aspect of the digit, raise a small subcutaneous wheel of anesthetic agent, and slowly move toward either the ulnar or radial aspect of the digit. Insert the needle until the palmer aspect of the skin begins to tent; aspirate and inject 1 mL of anesthetic agent. Pull the needle back without removing it from the digit, shift the needle to the other side, and repeat. Effect may be seen within 1-2 minutes, but maximal effect won't be seen until after 10 minutes has elapsed.

The Open Wound

Open hand and digit wounds are very common in the ED and have the potential to cause great morbidity if not treated properly. As discussed earlier, after a complete neurological and motor exam, effective anesthetic and irrigation take priority. The type of irrigation fluid used has not been shown to be significant; it is the pressure and amount of irrigating fluid that minimizes infectious complications. Tap water irrigation has proven to be as safe as sterile solutions.[18] One effective and timesaving technique involves holding the wound under tap water for 5-10 minutes rather than having the physician irrigate the wound. When directly irrigating, a 60-mL syringe and an 18-gauge angiocath or splashguard mechanism will create proper irrigation pressure. The generally agreed upon pressure goal is 8-10 psi and a minimum of 500 mL for clean wounds, with additional irrigation as needed. There are no studies to date showing benefit of wound soaking or use of antiseptic solution during irrigation.

Exposure is often a problem with open wounds.[12] Finger tourniquets can be helpful in digital injuries. For more proximal injuries, a blood pressure cuff applied to the forearm can help to create a bloodless field. All wounds need to be explored for foreign bodies. Plain film radiography is indicated if there is a concern for retained radio-opaque foreign body.[19] If tendon injury is a concern, it is imperative to manipulate the tendon through its entire range of motion while examining the wound.[20] When possible, an attempt should be made to recreate the specific position of injury. Nonvisualization of the tendon does not rule out tendon injury because a completely disrupted tendon may retract.[20] Ten-

don injuries may be difficult to identify which stresses the need to assess every joint. Every digit and joint is put through complete active and passive range of motion assessing for pain, weakness, and laxity.[20] Specific tendon function is evaluated by ranging every joint individually. Check extensor tendon function by extending all interphalangeal (IP) and metaphalangeal (MP) joints against resistance. Flexor digitorum superficialis (FDS) injury limits flexion at the proximal interphalangeal (PIP) joint. Test by holding the metacarpophalangeal (MCP) joint in extension and flexing the PIP joint against resistance. False-negative examinations will occur if all other digits are not held in complete extension. Flexor digitorum profundus (FDP) injury limits flexion at the distal interphalangeal (DIP) joint. Test by holding the PIP and MP in extension, and flex the DIP against resistance. Pain out of proportion to examination indicates a partial tendon injury.[6] The uninjured thumb will have complete active range of motion without pain and should be able to oppose to the fifth digit. Full flexion to a fist and full extension should be normal. Comparison with the unaffected side may be helpful in patients with chronic conditions such as degenerative joint disease or rheumatoid arthritis.

Wound Repair

Lacerations larger than 2 cm should be repaired primarily if conditions allow. Closing lacerations with 4.0-6.0 sutures and removing them in 8-10 days is suggested. There are no trials comparing absorbable and non-absorbable suture material in hand injuries.

Simple lacerations smaller than 2 cm may be managed conservatively without suture repair. A randomized controlled study demonstrated that conservative management decreased pain and anxiety by eliminating suturing and had similar cosmetic and functional outcomes compared with those of the sutured group.[21]

Radiography

Suspicion of fracture, dislocation, retained foreign body, or high-pressure injection all can trigger radiographic evaluation. The anterior-posterior, lateral, and oblique views are adequate to see the vast majority of metacarpal and phalange injuries.[4] Dedicated soft-tissue views will increase sensitivity when evaluating for foreign bodies, although not all foreign bodies will be identified by this method.[22] Further evaluation will be dictated by clinical evidence and hand surgeon request.

Classic Injuries

Because of the complexity of the hand and its propensity to injury, it enjoys a long list of named or titled injuries.[23] The names are historical and not always intuitive, and therefore, warrant special attention. Below is a list of the more prominent named hand injuries.

Bennett's/Reverse Bennett's and Rolando Fractures. A Bennett's fracture is a fracture of the proximal thumb metacarpal (*Figure 1*). The classic mechanism is an axial load to a flexed and adducted thumb. For example, a football quarterback strikes the helmet of an opposing player after releasing a throw. This avulsion injury is caused as the strong abductor pollicis longus fractures the bone at the point of its insertion at the ulnar aspect of the first metacarpal bone. This causes displacement of a bony fragment, which can be seen on plain film. This is usually an unstable fracture, and ED management should consist of referral to a hand surgeon and immobilization in a thumb spica splint. Potential long-term morbidity includes malunion, decreased function, and significant arthritis.

The same injury pattern and mechanism of injury also can occur in the fifth metacarpal and is called a reverse Bennett's fracture. This fracture pattern is equally as unstable as the Bennett's fracture because of the traction by the extensor carpi ulnaris on the distal aspect of the fifth metacarpal. Traction tends to pull the distal segment ulnarly. Closed reduction with ulnar gutter splinting may be attempted, but any articular incongruity must be recognized and referred emergently to the hand surgeon for potential immediate operative repair.

A Rolando fracture is similar to a Bennett's fracture; however, it is comminuted and by definition extends into the joint space. ED management is identical to that of a Bennett's fracture.

Boutonnière's Deformity. Boutonnière's deformity is not an

Figure 1. Bennett's Fracture

Reprinted with permission: Mettler F. *Essentials of Radiology*. 2 ed. Saunders;2004.

Figure 2. Boutonnière's Deformity

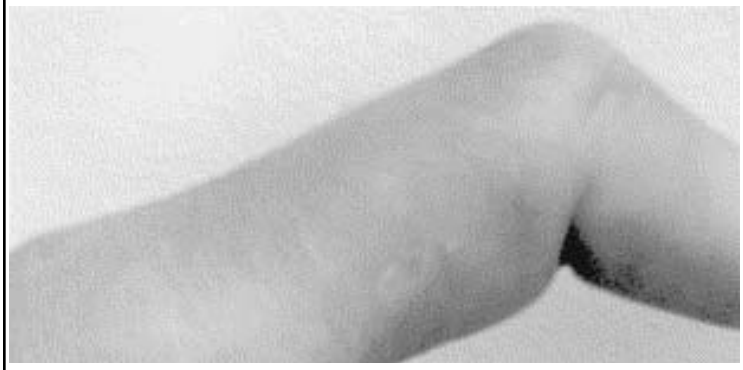

Reprinted with permission: Perron A, et al. Evaluation and management of the high risk orthopedic injury. *Emerg Med Clin North Am* 2003;21:159-204.

Figure 3. Boxer's Fracture

Reprinted with permission: Mettler F. *Essentials of Radiology.* 2 ed. Saunders;2004.

acute injury (*Figure 2*).[25] This deformity results from misdiagnosed or inadequately treated central slip rupture. The central slip joins the lateral bands and is responsible for extension at the PIP joint. Injury to the PIP joint is common and often sports related. Dislocations may have been relocated in the field, and the practitioner will need to have a high index of suspicion for soft-tissue injury. Acute central slip ruptures occur by one of two mechanisms: The most common is forced flexion of the extended PIP joint. This mechanism is seen in basketball players and martial artists who use hand-blocking techniques. Volar dislocations of the PIP joint are less common but also may cause central slip rupture. An unreduced volar dislocation will present with the obvious deformity of the PIP joint.[24] The middle phalanx will be palmar to the proximal phalanx. Patients may present with an acute boutonnière deformity, with flexion of the PIP joint and hyperextension of the DIP and MCP joints.[25] In these patients, the PIP joint can be passively brought to full extension, but active extension is not possible.

However, the patient who presents with the painful, swollen PIP joint without gross deformity is the one who requires careful examination. Central slip disruption is a diagnosis that must be made clinically, although Westerheide and colleagues recently suggested that there is potentially some value in interrogating the central slip with high frequency ultrasound.[26] This ultrasound technique remains an experimental protocol at this time. On physical examination, location of maximal tenderness leads the physician to the proper diagnosis. The patient usually will have tenderness about one or both of the collateral ligaments and only mild to minimal tenderness over the volar plate. The area of maximal tenderness will be over the central slip on the dorsal aspect of the PIP joint. Generally, this area also will be ecchymotic. Acutely, the patient may or may not be able to fully extend the PIP joint. However, full range of motion does not rule out acute central slip disruption because the patient may be able to fully extend through the action of the lateral bands.[25]

An anterior-posterior and lateral radiograph of the digit should be obtained before any attempted reduction when this injury is suspected.[2] In a volar dislocation, the base of the proximal phalanx is volar relative to the head of the middle phalanx. If the dislocation has been reduced, or if the rupture is isolated without dislocation, the radiographs will be normal.

Physical examination will make the diagnosis of central slip injury but may not clarify whether the structure is partially or completely torn because active extension still may be present.[25] The prudent course, therefore, is to initially treat all central slip injuries as though they are complete ruptures. The PIP joint should be splinted in extension leaving the DIP and MCP joints free to move. The patient should be instructed to aggressively move the DIP joint so as not to develop an extension contracture.[25] Prompt referral should be made to a hand surgeon.

Cyclist's Palsy. Cyclist's palsy is an entrapment neuropathy of the ulnar nerve. It is often experienced by cyclists who lean on handlebars for prolonged periods of time, and also has been called 'handle bar palsy.' This action compresses the ulnar nerve as it passes through Guyon's canal in the wrist, a potential space formed by the volar carpal ligament, the hamate, and the pisiform and pisohamatum ligament. Symptoms are parethesias of the fifth digit and ulnar half of the fourth digit. Treatment is supportive with administration of nonsteroidal anti-inflammatory drugs (NSAIDs) and a removable wrist splint, with the hand held in a position of function. A small percentage of patients will fail medical management and may require steroid injections or surgical release of the canal. Therefore, it is recommended that

Figure 4. Gamekeeper's Thumb

Reprinted with permission: Mettler F. *Essentials of Radiology.* 2 ed. Saunders;2004.

Figure 5. Testing for Ulnar Collateral Ligament Integrity

Reprinted with permission: Patel D, et al. The hand in sports: An update on the clinical anatomy and physical examination. *Prim Care* 2005;32:71-89.

patients be referred to a hand surgeon for follow-up.

Boxer's Fracture. Although many people refer to any fracture of the fifth metacarpal as a boxer's fracture, the specific injury is a fracture through the neck of the fifth metacarpal. This injury is most frequently seen when a solid object is forcefully struck with a closed fist (*Figure 3*).[28] Many patients presenting with this injury are intoxicated, a fact which must be taken into account when performing the physical examination.[3] True boxer's fractures may carry significant morbidity.[28] In addition to being an unstable fracture, there is often a rotational component to the fracture. If allowed to heal in this position, the hand will be deformed and weakened. ED management usually will consist of an attempt at closed reduction and placement of a dorsal-volar splint. Some authors suggest an ulnar–gutter or "cobra" splint. Regardless of the splint used, at a minimum the fourth and fifth MCP joints should be splinted at 90 degrees of flexion. Because of the instability of this fracture, all patients should be referred to a hand surgeon and also advised that there is a significant likelihood that they will require operative management.

DeQuervain's Tenosynovitis. DeQuervain's tenosynovitis is an overuse injury of the thumb. The classic mechanism is that of a fly-fisherman repetitively collecting his line after each cast using the thumb and index finger to grasp the line, resulting in inflammation of the abductor pollicis longus and the extensor pollicis brevis. The diagnosis is made clinically, and a positive Finkelstein's test is said to be pathognomic. The Finkelstein test is considered positive when pain is elicited with passive ulnar deviation of a closed fist. It is important to note that patients with this condition may complain of pain upon palpation of the anatomic snuffbox because the aforementioned tendons form the radial border of that structure. If the history of present illness is suggestive of a possible scaphoid injury, an x-ray should be performed and a thumb spica splint applied until appropriate follow-up with a hand surgeon can be obtained.[6] If the diagnosis is simple Dequervain's tenosynovitis, then rest, ice, and and administration of NSAIDs are the treatments of choice. More severe cases may be splinted to rest the injured joint.

Gamekeeper's/Skier's Thumb. Gamekeeper's thumb also is called skier's thumb. The mechanism is hyperextension of the abducted thumb causing injury to the ulnar collateral ligament (UCL) and is often associated with an avulsion fracture (*Figure 4*). Historically old-world gamekeepers would sustain this injury while dispatching wounded birds during hunts.[28] Today this injury is most frequently seen when a skier falls while grasping the pole or upon an extended thumb.[3]

The physical exam will be remarkable for tenderness at the UCL, laxity at the MCP joint, and an inability to actively oppose the thumb. Most UCL ruptures occur at the distal attachment. If the injured joint demonstrates 40 degrees of radial angulation during stressing, a complete ligament rupture should be assumed (*Figure 5*). There may be an associated avulsion fracture. Treatment is immobilization in a thumb-spica splint, administration of

Figure 6. Jersey Finger

Reprinted with permission: Perron A, et al. Evaluation and management of the high risk orthopedic injury. *Emerg Med Clin North Am* 2003;21:159-204.

Figure 7. Mallet Finger

Reprinted with permission: Perron A, et al. Evaluation and management of the high risk orthopedic injury. *Emerg Med Clin North Am* 2003;21:159-204.

NSAIDs , and referral to a hand surgeon. The window of opportunity for open reduction with internal fixation (ORIF) is long (6-8 weeks), and most surgeons will observe the patient for clinical improvement during that time period.

The initial exam may be compromised secondary to pain and spasm. In these cases, the most prudent course of action is immobilization in a thumb-spica splint and referral for re-evaluation.

Jersey Finger. 'Jersey finger' is an injury often associated with tackling sports (e.g. rugby, American football) (*Figure 6*).[27] The injury is a disruption of FDP, which is responsible for flexion of the digit at the DIP joint. This occurs when a digit (often the 2nd digit) is forced into extension while actively being flexed, as might occur when grabbing a jersey during a tackle.

On physical examination the injured patient will not be able to flex the digit at the DIP joint when the PIP joint is held (by the examiner) in extension. Examining the DIP joint without holding the PIP joint may result in a false-negative result due to contribution from the lateral bands.[6] The patient may complain of pain more proximally along the flexor tendon sheath, or even in the palm, as the ruptured FDP will retract.[25] Therefore, it is imperative to challenge the distal joint as above, despite only proximal pain. For full disruption the best outcomes are dependent upon early surgical repair, and all patients should receive referral to a hand surgeon.

Mallet Finger. 'Mallet finger' is in many ways the functional opposite of jersey finger. In mallet finger, there is a rupture of the distal extensor tendon. This often occurs when the distal phalanx of a finger (or thumb) is forced into flexion while being actively extended. In sports the middle finger is most often affected secondary to length, and occurs when the finger is 'jammed' as when mis-catching a ball.[3]

This injury is often painless, therefore, it does not always present immediately.[28] Physical examination is remarkable for the inability to extend at the affected DIP joint (*Figure 7*). Radiographs may demonstrate an avulsion fracture. Treatment is immobilization by splinting the DIP joint in full extension. This allows for full range of motion at the PIP joint. The patient should be referred to a hand surgeon for follow-up. Most mallet fingers are treated non-operatively; however, those with large avulsion fracture fragments may require operative management.

Other Common Fractures

The common theme with all phalangeal and metacarpal fractures is intolerance for rotational deformity.[6] Differing degrees of angulations are tolerated in different areas of the hand. Referral will depend largely upon the necessity for further reduction and the stability of the fracture.

Distal Phalynx Fractures. The most common distal phalynx (DP) fracture is the tuft fracture, and nail bed injuries are the most common complication of this fracture.[3] There is some controversy regarding the need to repair nail bed injuries.[29] Most authors do suggest, however, performing trephination for nail bed hemotomas involving 30%-50% or more of the nail bed surface.[30] When there is nail bed involvement, these tuft fractures are considered open, and while some physicians do prescribe empiric antibiotics, there is evidence suggesting that prophylactic antibiotics are not indicated.[31] More proximal DP fractures are often unstable and will require hand surgeon referral for percutaneous wire placement. An attempt to reduce any rotational deformity or angulation should be made prior to splinting. Splinting should isolate the DIP joint alone.

Middle and Proximal Phalynx Fractures. Middle phalynx (MP) and proximal phalynx (PP) fractures are managed similarly. The degree of instability is dependent on the nature of the fracture.[23] Transverse or spiral fractures will inherently have greater instability than simple fractures, and therefore, are more likely to require percutaneous fixation.[6] Again, rotational deformity cannot be tolerated. When the hand is held in a relaxed fist, the fingers should all point to the scaphoid region. Visual deviation from this plane suggests a rotational deformity of greater than 10%. Buddy taping best manages simple fractures. Rotated, transverse, displaced, or intra-articular fractures should be reduced, splinted in either a dorsal volar or ulnar gutter splint as indicated, and referred to hand surgery.

Metacarpal Fractures. Metacarpal fractures cannot be dis-

cussed as a group because of the vast difference in both mobility and function between them.

The first metacarpal is very mobile and fractures are relatively uncommon.[23] Proper reduction, thumb spica splint, and follow-up with a hand surgeon are appropriate. Bennett's and Rolando's fractures are discussed under "named" injuries.

The second and third metacarpals are the 'fixed center' of the hand and proper reduction of fractures is crucial for return of function. The fourth and fifth metacarpals, however, are more mobile and have greater ability to compensate for angular deformities.[23] Description of injury and determination of proper reduction is based upon angulation and rotational malalignment. Please refer to *Table 2*, which describes the allowed degree of angulation after fracture reduction of metacarpal neck and shaft fractures, and proper splinting technique for each fracture. Stable fractures may be splinted and referred to hand surgeons for outpatient follow-up.

Table 2. Acceptable Angulations and Splinting of Metacarpal Fractures

DIGIT	NECK (DEGREES)	SHAFT (DEGREES)	APPROPRIATE SPLINT
2nd	10	None	Volar splint w/wrist @ 30° extension; Dorsal splint with MCP joint @ 90°
3rd	10	None	Volar splint w/ wrist @ 30° extension; Dorsal splint with MCP joint @ 90°
4th	30	10	Ulnar gutter with MCP joint @90°; IP joints extended or mobile
5th	40	20	Ulnar gutter with MCP joint @90°; IP joints extended or mobile

Key: MCP = metacarpophalangeal. IP = interphalangeal.

All unstable reductions, irreducible, open, or intra-articular fractures, and any fracture with rotational malalignment should merit hand surgery consultation while the patient is in the ED.

Metacarpal base fractures are uncommon and usually of little significance.[3] The exception is at the base of the fifth metacarpal where there can be an associated subluxation of metacarpal-hamate joint. These patients should be immobilized in an ulnar gutter splint and referred to hand surgery.

Digit Dislocation. Dislocation of the DIP joint is a rare injury, but when it occurs it most commonly dislocates in the dorsal direction after direct force on the finger pad. Relocation is best accomplished after digital block with traction longitudinally and pressure directing the proximal aspect of the distal phalanx back to correct alignment.[24] After relocation the entire digit is splinted in extension. Some injuries will be nonreducible and will require operative repair as the volar plate and/or the profundus tendon may occupy the joint space.[5] Any indication of joint involvement should prompt referral to a hand surgeon.

PIP joint dislocations result in more complications than DIP joint dislocations.[27] The complex biomechanics of the joint add a degree of intricacy that often results in the need for operative repair. The volar plate may be injured in dorsal dislocations, and the lateral collateral ligaments with either ulnar or radial dislocations. It is important to assess any relocated joint for stability to better rule out potential of ligament or volar plate injury.[25] Refer any irreducible or unstable joint to a hand surgeon for operative repair. If stable, the joint should be splinted in 30 degrees of flexion for 2-4 weeks.

MCP joint dislocations are seen less commonly than PIP joint dislocations, but share a similar rate of complications.[3] Dislocations may be partial or complete, and may involve the volar plate. Care should be taken during the exam not to convert a partial dislocation to a complete dislocation.[6] Injury most commonly occurs as a hyperextension mechanism. With complete dislocations and volar plate involvement, relocation is often impossible as again, the volar plate may become entrapped in the joint space. For best chance of relocation, place the wrist in full flexion to relieve all flexor tendon tension and use longitudinal and volar force. The MCP joint should be splinted in full flexion.

Extensor Tendon Injury. Open wounds on the dorsum of the hand and digits must trigger suspicion of extensor tendon injury and initiate referral to a hand surgeon. The Verdan extensor tendon injury classification system uses eight anatomic zones to direct treatment. Treatment of extensor tendon injuries usually should be coordinated with a hand surgeon. Data concerning suture repair of partial tendon lacerations are lacking, and current treatment is based upon flexor tendon treatment. Conservative treatment of injuries of less than 50% cross-sectional area has been proposed.

Injuries to Zones I and II occur with axial loading to a fully extended DIP joint, forcing the DIP joint into flexion and disrupting the distal aspect of the extensor tendon. This creates a 'mallet' injury, as described previously.

Zone III injuries occur either by axial loading and forced flexion of the PIP joint or by direct trauma to the PIP joint. These injuries should be splinted with the PIP joint in extension and the patient referred to a hand surgeon. With complete disruption of the central slip, the lateral bands will slide toward the volar surface of the digit causing the extensor tendons to act as flexors. Untreated injuries lead to a boutonnière deformity, as described previously.

Most Zone IV injuries are caused by direct trauma. Open injuries may be treated primarily as injuries in zone IV because there is, by definition, no joint involvement. Closed injuries should be splinted with extension of the PIP joint. The extensor tendons of the proximal phalange are broad and flat allowing for easier primary repair.

Fight bite injury must be considered with all open zone V ligamentous injuries. Open injuries should be referred to a hand surgeon for primary repair. Closed injuries can be treated by

Table 3. Extensor Tendon Zones Injuries with Appropriate Disposition

ZONE	ANATOMIC LOCATION	DISPOSITION
I	Distal phalange to DIP	Splint/hand surgeon referral
II	Middle phalange	Splint/hand surgeon referral
III	PIP	Splint/hand surgeon referral
IV	Proximal phalange	Primary ED repair/splint
V	MCP	Splint/hand surgeon referral
VI	Dorsum of hand/metacarpals	Primary ED repair/splint
VII	Dorsum of wrist/carpals	Hand surgeon primary repair
VIII	Distal forearm/proximal wrist	Hand surgeon primary repair

Key: DIP = distal interphalangeal. PIP = proximal interphalangeal. MCP = metacarpophalangeal.

splinting the MCP joint in extension while allowing free range of motion of the PIP joint.

Zone VI injuries are usually superficial and easily repaired primarily by the emergency physician. After closure, the wrist should be splinted in 30 degrees of extension, the MCP joint in 15 degrees of flexion, and the PIP joint free. Refer the patient for dynamic splinting.

Zones VII and VIII injuries often involve the extensor retinaculum and should be referred to the hand surgeon for primary closure. The affected tendon often retracts into the forearm complicating the repair. Due to the density of associated anatomic structures, operative survey of the injury to identify additional injuries is indicated. *Table 3* reviews extensor tendon zone injuries and appropriate disposition.

Flexor Tendon Injuries

All open flexor tendon injuries should be referred to a hand surgeon for emergent evaluation. However, some knowledge of the nomenclature and prognoses associated with the various flexor tendon injuries will aid in conversations with both the consultant and patient.[20] Repair of complete lacerations is most commonly recommended within 24 hours. Operative repair is usually limited to injury involving greater than 50% cross-section area.[1] Injuries of less than 50% are frequently treated conservatively with splinting. Newer data are suggesting that conservative management be utilized for injuries of less than 75% cross-sectional area, however this decision should be deferred to the consulting hand surgeon.[1] When splinting flexor tendon injuries, the wrist should be placed in 30 degrees of flexion, MCP joint at 70 degrees of flexion, and the DIP/PIP joint in 10 degrees of flexion. Flexor tendon injuries are classified based on anatomic location, treatments, and prognosis.

Zone I injuries limit flexion of the DIP joint due to FDP injury. The tendon often retracts and is very difficult to retrieve. Laceration or avulsion of the FDP is referred to as a jersey finger, injury occurs with forced extension of the DIP joint while in a flexed position. Pain is elicited at the insertion of the FDP at the volar aspect of the DIP joint. Assess function by holding the PIP joint in extension while flexing the DIP joint. This will isolate the FDP tendon.

Table 4. Flexor Tendon Zones Injuries with Appropriate Disposition

ZONE	ANATOMIC LOCATION	DISPOSITION
I	Distal to insertion of FDS	Hand surgeon
II	Area of flexor sheath with both FDS/FDP	Hand surgeon
III	Carpal tunnel to the proximal aspect of flexor sheath	Hand surgeon
IV	Carpal tunnel	Hand surgeon
V	Forearm proximal to carpal tunnel	Hand surgeon

Key: FDS = flexor digitorum sublimis. FDP = flexor digitorum profundus.

'No man's land' or Zone II historically has been associated with poor prognosis. Both the FDP and FDS tendons are in close proximity to each other, and exact operative repair is essential to limit contractures, triggering, scarring, and loss of function. Improved operative techniques have improved prognosis.

Zone III generally is associated with the best prognosis. The lumbricals originate from the FDP in Zone III and must be evaluated. Injuries in Zones IV and V involve the carpal tunnel and forearm and often involve other vital anatomical structures; isolated flexor tendon injuries are rare. All flexor tendon injuries should be referred to a hand surgeon for operative exploration and repair. (*See Table 4.*)

Bite Injuries

Because of the potential for injury and morbidity, an open injury to the MCP joint should be treated as a fight bite until proven otherwise. These often minor-appearing injuries are by definition caused by clenched fist versus human teeth and are well known for poor outcomes. Potential complications include violation of the joint capsule, extensor tendon injury, and deep fascial space contamination.[32] The potential for infection is great because of the poor vascular supply to the extensor tendon and joint capsule. Additionally, high concentration of pathogens may be inoculated. The treatment of these injuries is three fold: surgical decontamination, antibiotic administration, and dynamic splinting.[33] These injuries are not limited to fist fights, and also are commonly found during sporting events.[32] Delayed presentation most commonly occurs two to three days after inciting event with signs and symptoms of local or significantly advanced infection. Any indication of infection or joint space or tendon sheath involvement should prompt referral to a hand surgeon for irrigation and debridement.[34] The timing of initiation of intravenous antibiotics should be made in consultation with the hand surgeon, who may wish to delay antibiotic treatment until after intra-operative cultures have been obtained. Antimicrobials should cover common pathogens found in the human oral and skin flora,[35] including aerobic and anaerobic pathogens. *Staphy-*

lococcus aureus is the most common pathogen, followed by *Streptococcus* species, *Corynebacterium* species, and *Eikenella corrodens*.[32]

If the patient presentation is acute and if there is no indication of fracture, joint space involvement, or extensor tendon injury, then antibiotic treatment and local wound care alone is indicated. This non-operative patient group should be treated by high volume irrigation and the wounds should be left open to heal by secondary intention. These patients should be splinted in the position of function, instructed to elevate the affected limb, and to return for any concerns of infection.[34] There should be a mandatory re-evaluation.

Prophylactic antibiotics for clenched fist bite wounds should be initiated in all but the most superficial injuries.[36] Recommended regimens are numerous and include amoxicillin/clavulanic acid, a combination of penicillin and dicloxacillin, or a combination of penicillin and a first-generation cephalosporin.[35]

High Pressure Injuries

Modern technological advances have greatly increased the incidence of high-pressure injuries. Many substances are now sprayed under high-pressure, including paint, water, oil and other petroleum-based substances, solvents, and grease.[38] As the incidence continues to grow, the emergency physician should recognize the potential for injury and infection from these injuries.[39]

These injuries can lead to high rates of infection, inflammatory reactions, fibrosis, disability and amputation rates of nearly 50%.[40] Early and aggressive open surgical approach has improved prognosis and ability to return to previous employment.[41] One report demonstrated 100% amputation rates for patients presenting 6 or more hours after initial injury, thus signifying the importance of early management.[41]

Historical information including the time since injury, material injected, amount injected, temperature of material, and velocity/pressure of injection may be very helpful in determining prognosis. As an example, amputation rate is considerably lower with grease injection versus paint or solvent-based material.[41,42] Thinner and less viscous material is more apt to lead to amputation because of easier spread and subsequent larger extent of injury.

Presentation of a small puncture wound with a history of high-pressure injury is an indication for radiographic imaging.[42] Subcutaneous air and radio-opaque substances may be visualized, and can indicate the extent of injury. Initial radiographs also may help define the extent and approach of surgical debridement.[2]

The initial pain complaints in high pressure injection injuries may be significant and may require large doses of intravenous narcotic analgesia. Due to the local injury and inflammation, regional anesthesia (i.e., digital blocks or infiltrative) are contraindicated, and have been shown to worsen outcomes.[44] Many of the complications from high-pressure injection injuries are related to inflammation, however, there is little data to either support or refute the use of systemic steroids. Similarly, the role of empiric antibiotics is unknown. Tetanus prophylaxis continues to be indicated as with all penetration injuries of the skin.

Summary

The hand is complicated and injury prone. The goal of the acute care practitioner managing hand injuries first should be to correctly identify the injury via a careful history, a systematic and practiced physical exam, and with the aid of appropriate radiography. Management should then focus on a return to function, with a bias toward empiric management. While a significant subset of patients will require an emergent hand surgeon evaluation, the majority can be treated or stabilized in the acute care setting and be referred to the hand surgeon for outpatient management and follow-up.

References

1. Amadio PC. What's new in hand surgery. *J Bone Joint Surg* 2005; 87(2):468-74.
2. American College of Radiology, Expert Panel on Musculoskeletal Imaging. Acute hand and wrist trauma. *ACR*. 2001:7p.
3. Chung KC, Spilson SV. The frequency and epidemiology of hand and forearm fractures in the United States. *J Hand Surg* 2001; 26:908-15.
4. Kall S, Vogt PM. [Surgical therapy for hand infections. Part I.] *Chirurg* 2005 Jun;76(6): 615-25.
5. Griffiths MA, Moloney DM, Pickford MA. Multiple carpometacarpal dislocation after a low-impact injury: A missed diagnosis. *J Trauma* 2005;58:391-2.
6. Harrison B, Holland P. Diagnosis and management of hand injuries in the ED. *Emerg Med Pract* 2005;7(2):1-28.
7. Barfield JM, Gennis P, Barbera J, Breuer B, Gallagher EJ. Buffered versus plain lidocaine as a local anesthetic for simple laceration repair. *Ann Emerg Med* 1990;19(12):1387-9.
8. Thompson WL, Malchow RJ. Peripheral nerve blocks and anesthesia of the hand. *Mil Med* 2002;167(6):478-82.
9. Johnson HA. Infiltration with epinephrine and local anesthesia mixture in the hand. *JAMA* 1967;61(9):341-3.
10. Denkler K. A comprehensive review of epinephrine in the finger: To do or not to do. *J Plast Reconstruct Surg* 2001;108(1):114-24.
11. Krunic AL, Wang LC, Soltani K, Weitzul S, Taylor RS. Digital anesthesia with epinephrine: An old myth revisited. *J Am Acad Dermatol* 2004;51(5):755-9.
12. Robson AK, Bloom PA. Suturing of digital lacerations: Digital block or local infiltration. *Ann R Coll Surg Engl* 1990;72(6):360-1.
13. Wilhelmi BJ, Blackwell SJ, Miller JH, et al. Do not use epinephrine in digital blocks: myth or truth? *J Plast Reconstruct Surg* 2001; 107(2):393-7.
14. Sylaidis P, Logan A. Digital blocks with adrenaline. An old dogma refuted. *J Hand Surg* 1998;23(1):17-9.
15. Furia JP, Alioto RJ, Marquardt JD. The efficacy and safety of the hematoma block for fracture reduction in closed, isolated fractures. *J Orthop* 1997; 20(5):423-6.
16. Wilhelmi BJ, Blackwell SJ, Miller JH, Mancoll JS, Phillips LG. Epinephrine in digital blocks: revisited. *Ann Plast Surg* 1998;41(4): 410-4.
17. Burnham PJ. Regional block anesthesia for surgery of the fingers and thumb. *Ind Med Surg* 1958;27(2):67-9.
18. Valente JH, Forti RJ, Freundlich LF, Zandieh SO, Crain EF. Wound

irrigation in children: Saline solution or tap water? *Ann Emerg Med* 2003;41(5):609-16.
19. Courter BJ. Radiographic screening for foreign bodies-what does a "negative" foreign body series really mean? *Ann Emerg Med* 1990; 19(9):997-1000.
20. Kotwal PP, Gupta V. Neglected tendon and nerve injuries of the hand. *Clin Orthop* 2005;431:66-71.
21. Quinn J, Cummings S, Callaham M, Sellers K. Suturing versus conservative management of lacerations of the hand. *BMJ* 2002; 325:299-300.
22. James SLJ, Davies AM. Surface lesions of the bones of the hand. *Eur Radiol* Epub 2005 Apr 16.
23. Hardy M. Principles of Metacarpal and phalangeal fracture management. *J Orthop Sports Phys Ther* 2004;34:781-99.
24. Daniels JM, Zook EG, Lynch JM. Hand and wrist injuries: Part I. Non-emergent evaluation. *Am Fam Physician* 2004;69:1941-8.
25. Morrison CM, Thompson NW, Herbert KJ, Brennen MD. Missed injuries in the acutely traumatized hand. *Ulster Med J* 2003; 72(1):22-5.
26. Westerheide E, Failla JM, van Holsbeeck M, Ceulemans R. Ultrasound visualization of central slip injuries of the finger extensor mechanism. *J Hand Surg* [Am] 2003; 28(6):1009-13.
27. Daniels JM, Zook EG, Lynch JM. Hand and wrist injuries: Part II. Emergent evaluation. *Am Fam Physician* 2004;69:1949-56.
28. Van Onselen EBH, Karim RB, JorisHage J, Ritt MJPF. Prevalence and distribution of hand fractures. *J Hand Surg* (Brit/European). 2003;285(5):491-5.
29. Hart RG, Kleinert HE. Fingertip and nail bed injuries. *Emerg Med Clin North Am* 1993 Aug;11(3):755-65.
30. Roser SE, Gellman H. Comparison of nail bed repair versus nail trephination for subungual hematomas in children. *J Hand Surg* [Am] 1999 Nov;24(6):1166-70.
31. Sukop A, Kufa R. Primary surgical treatment of amputated fingers and indications for digital replantation. *Acta Chir Orthop Traumatol Cech* 2005;72(2):129-33.
32. Perron AD, Miller MD, Brady WJ. Orthopedic pitfalls in the ED: Fight bite. *Am J Emerg Med* 2002;20:114-7.
33. Talan DA, Abrahamian FM, Moran GJ, et al. Clinical presentation and bacteriologic analysis of infected human bites in patients presenting to emergency departments. *J Clin Infect Dis* 2003; 37(11):1481-9.
34. Bunzli WF, Wright DH, Hoang AT, et al. Current management of human bites. *Pharmacotherapy* 1998 Mar-Apr;18(2):227-34.
35. Talan DA, Citron DM, Abrahamian FM, et al. Bacteriologic analysis of infected dog and cat bites. Emergency Medicine Animal Bite Infection Study Group. *NEJM* 1999;340(2):85-92.
36. Medeiros L, Saconato H. Antibiotic prophylaxis for mammalian bites. *Cochrane Database Syst Rev* 2003(2):CD001738.
37. Mitnovetski S, Kimble F. Cat bites of the hand. *ANZ J Surg* 2004; 74:859-62.
38. Mizani MR, Weber BE. High-pressure injection injury of the hand. *Postgrad Med* 2000;108(1):183-5.
39. Vasilevski D, Noorbergen M, Depierreux M, Lafontaine M. High-pressure injection injuries to the hand. *Am J Emerg Med* 2000; 18:820-4.
40. Harter BT Jr, Harter KC. High-pressure injection injuries. *Hand Clin* 1986 Aug;2(3):547-52.
41. Pinto MR, Turkula-Pinto LD, Cooney WP, Wood MB, Dobyns JH. High-pressure injection injuries of the hand: Review of 25 patients managed by open wound technique. *J Hand Surg* [Am] 1993 Jan; 18(1):125-30.
42. Luber KT, Rehm JP, Freeland AE. High-pressure injection injuries of the hand. *Orthopedics* 2005 Feb;28(2):129-32.
43. Neal NC, Burke FD. High-pressure injection injuries. *Injury* 1991 Nov;22(6):467-70.
44. Hayes CW, Pan HC. High-pressure injection injuries to the hand. *South Med J* 1982 Dec;75(12): 491-8, 1516.

CE/CME Questions

1. When attaining a history, which of the following must be attained?
   A. Hand dominance and profession
   B. PMH for immunocompromising conditions, smoking status
   C. Hand position at time of injury
   D. Mechanism of injury
   E. All of the above

2. Which one of the following pathogens is most likely associated with a 'fight bite,' and what is the preferred antibiotic of choice?
   A. *Staphylococcus aureus*; amoxicillin + clavulanate
   B. *Pasturella*; ceftriaxone
   C. *Streptococcus epidermitis*; cephalexin
   D. *Streptococcus viridans*; gentamycin
   E. *Eikenella corrodens*; ciprofloxicin

CE/CME Objectives

Upon completing this program, the participants will be able to:

a.) discuss conditions that should increase suspicion for traumatic injuries;
b.) describe the various modalities used to identify different traumatic conditions;
c.) cite methods of quickly stabilizing and managing patients; and
d.) identify possible complications that may occur with traumatic injuries.

CE/CME Instructions

Physicians and nurses participate in this continuing medical education/continuing education program by reading the article, using the provided references for further research, and studying the questions at the end of the article. Participants should select what they believe to be the correct answers, then refer to the list of correct answers to test their knowledge. To clarify confusion surrounding any questions answered incorrectly, please consult the source material. **After completing this activity, you must complete the evaluation form provided and return it in the reply envelope provided in order to receive a letter of credit.** When your evaluation is received, a letter of credit will be mailed to you.

3. Which one of the following symptoms is least concerning when evaluating for tendon injury?
   A. Pain and ecchymosis at location of injury
   B. Pain on palpation proximally on the injured digit
   C. Inability to actively range the joint
   D. Decreased passive range of motion of injured joint
   E. Changes in resting position of injured joint

4. Which one of the following statements regarding flexor tendon injuries is true?
   A. Open flexor tendon injues can be cared for in the ED.
   B. The flexor tendon should be placed in 60 degrees of flexion.
   C. Repair of complete lacerations is recommended within 24 hours
   D. Flexor tendon injuries do not require referral to a hand surgeon.

5. Which one of the following neurological findings may be considered normal?
   A. Two-point discrimination of 4 mm
   B. Lack of palpable contraction of the thenar eminence on abduction of the 1st digit
   C. No skin changes after 10 minutes of soaking
   D. Subjective difference in light touch sensation between hands

6. Extensor tendon injuries of which zone may be repaired by the EP?
   A. Zone I, distal phalange
   B. Zone II, middle phalange
   C. Zone III, PIP
   D. Zone IV, proximal phalange
   E. Zone V, MCP

7. Which one of the following is contraindicated in a patient with a high-pressure injury?
   A. Radiographic evaluation
   B. Determination of substance injected
   C. Immediate referral to hand surgeon
   D. Digital/regional anesthesia for pain control
   E. Tetanus prophylaxis

8. Which one of the following activities is necessary when treating open wounds?
   A. Immediate administration of prophylactic antibiotics
   B. Recreating the position of injury during wound exploration
   C. Primarily repairing all hand wounds regardless of the size
   D. Soaking the wound before closure

9. Which of the following techniques will appropriately assess the flexor digitorum superficialis?
   A. Comparative grip strength
   B. Hand held palm up, hold the PIP in extension, and flex the DIP against resistance
   C. Hand held palm up, hold the MCP in extension, and flex the PIP against resistance
   D. Hand held palm down, actively extend the digit against resistance
   E. Hand held ulnar side down, actively abduct the 2nd digit against resistance

10. Which one of the following fractures is considered 'stable' ?
   A. Rotational deformity of the 5th metacarpal
   B. 20 degrees of volar angulation of the 2nd metacarpal
   C. Bennett's fracture: proximal metacarpal of the 1st digit
   D. Boxer's fracture: fracture of the neck of the 5th metacarpal
   E. Skier's/Gamekeeper's thumb: tear of the ulnar collateral ligament and associated avulsion fracture of the base of the proximal phalange

Answers:

1. E
2. A
3. D
4. C
5. A
6. D
7. D
8. B
9. C
10. E

In Future Issues:

Penetrating neck injuries

Thomson American Health Consultants
Building Six, Suite 400
3525 Piedmont Road NE
Atlanta, Georgia 30305-1515
Tel (404) 262-7436 Fax (404) 262-7837
www.ahcpub.com

THOMSON
AMERICAN HEALTH CONSULTANTS

Dear *Trauma Reports* Subscriber:

This issue of your newsletter marks the start of a new continuing medical education (CME) or continuing education (CE) semester and provides us with an opportunity to review the procedures.

Trauma Reports, sponsored by Thomson American Health Consultants, provides you with evidence-based information and best practices that help you make informed decisions concerning treatment options and medical practices. Our intent is the same as yours — the best possible patient care.

The objectives of *Trauma Reports* are to:

1. Discuss conditions that should increase suspicion for traumatic injuries;
2. Describe the various modalities used to identify different traumatic conditions;
3. Cite methods of quickly stabilizing and managing patients; and
4. Identify possible complications that may occur with traumatic injuries.

Each issue of your newsletter contains questions relating to the information provided in that issue. After reading the issue, answer the questions at the end of the issue to the best of your ability. You can then compare your answers against the correct answers provided in an answer key in the newsletter. If any of your answers were incorrect, please refer back to the source material to clarify any misunderstanding.

Enclosed in this issue is an evaluation form to complete and return in an envelope we will provide. Please make sure you sign the attestation verifying that you have completed the activity as designed. Once we have received your completed evaluation form we will mail you a letter of credit. This activity is valid 24 months from the date of publication. The target audience for this activity is emergency, trauma, and surgical physicians and nurses.

If you have any questions about the process, please call us at (800) 688-2421, or outside the U.S. at (404) 262-5476. You can also fax us at (800) 284-3291, or outside the U.S. at (404) 262-5525. You can also email us at: ahc.customerservice@thomson.com.

On behalf of Thomson American Health Consultants, we thank you for your trust and look forward to a continuing education partnership.

Sincerely,

Brenda L. Mooney

Brenda Mooney
Vice-President/Group Publisher
Thomson American Health Consultants

Trauma Reports
Evidence-Based Medicine for the ED

TR090106TM

CE/CME Evaluation — Adult Hand Trauma

Please take a moment to answer the following questions to let us know your thoughts on the CE/CME program. Fill in the appropriate space and return this page in the envelope provided. **You must return this evaluation to receive your certificate. ACEP members — Please see reverse side for option to mail in answers.** Thank you.

CORRECT ● **INCORRECT** ◐ ✓ ✗ ⚠

1. In which program do you participate? ○ CE ○ CME
2. If you are claiming physician credits, please indicate the appropriate credential: ○ MD ○ DO ○ Other _____
3. If you are claiming nursing contact hours, please indicate your highest credential: ○ RN ○ NP ○ Other _____

After participating in this program, I am able to:	**Strongly Disagree**	**Disagree**	**Slightly Disagree**	**Slightly Agree**	**Agree**	**Strongly Agree**
4. Discuss conditions that should increase suspicion for traumatic injuries.	○	○	○	○	○	○
5. Describe the various modalities used to identify different traumatic conditions.	○	○	○	○	○	○
6. Cite methods of quickly stabilizing and managing patients.	○	○	○	○	○	○
7. Identify possible complications that may occur with traumatic injuries.	○	○	○	○	○	○
8. The test questions were clear and appropriate.	○	○	○	○	○	○
9. I am satisfied with customer service for the CE/CME program.	○	○	○	○	○	○
10. I detected no commercial bias in this activity.	○	○	○	○	○	○
11. This activity reaffirmed my clinical practice.	○	○	○	○	○	○
12. This activity has changed my clinical practice.	○	○	○	○	○	○

If so, how? _____

13. How many minutes do you estimate it took you to complete this activity? Please include time for reading, reviewing, answering the questions, and comparing your answers with the correct ones listed. _____ minutes.
14. Do you have any general comments about the effectiveness of this CE/CME program?

_____

I have completed the requirements for this activity.

Name (printed) _____ **Signature** _____

Nursing license number ***(required for nurses licensed by the state of California)*** _____

Please make label address corrections here or PRINT address information to receive a certificate.

Account # _____

Name: _____

Company: _____

Address: _____

City: _____ State: _____ Zip _____

Fax: _____ Phone: _____

E-mail: _____

PLEASE NOTE: If your correct name and address do not appear below, please complete the section at left.

Optional for ACEP members: In accordance with ACEP requirements, below we provide the option for ACEP members to submit their answers for this CME activity. If you wish to submit answers for this activity, please refer to this issue (Vol. 7, No. 5) and circle the correct responses.

1. A
   B
   C
   D
   E

2. A
   B
   C
   D
   E

3. A
   B
   C
   D
   E

4. A
   B
   C
   D

5. A
   B
   C
   D

6. A
   B
   C
   D
   E

7. A
   B
   C
   D
   E

8. A
   B
   C
   D

9. A
   B
   C
   D
   E

10. A
    B
    C
    D
    E