PRACTICAL SUMMARIES IN

ACUTE CARE

A Focused Topical Review of the Literature for the Acute Care Practitioner

Nephrolithiasis: Imaging Options and Controversies

Author: **Brock Boscovich, MD**, Attending Physician, Carson Tahoe Regional Hospital, Carson City, NV; and **Catherine A. Marco, MD, FACEP**, Clinical Professor, Department of Surgery, Division of Emergency Medicine; Attending Physician, St. Vincent Mercy Medical Center, Toledo, OH.

Peer Reviewer: **David E. Manthey, MD, FACEP, FAAEM**, Associate Professor, Director, Undergraduate Medical Education, Department of Emergency Medicine, Wake Forest University School of Medicine, Winston-Salem, NC.

Introduction

Flank pain is a common complaint of patients presenting to the emergency department (ED). Despite the tendency to immediately hone in on ureterolithiasis as the etiology of this pain, emergency physicians (EPs) must rule out other serious causes of flank pain (e.g., abdominal aortic aneurysm, appendicitis, pyelonephritis, ovarian torsion, ectopic pregnancy, and tubo-ovarian abscess).

There are a number of imaging modalities to assist the EP in prompt diagnosis and treatment for patients with flank pain. The ideal test in the ED should quickly and accurately diagnose ureterolithiasis as well as other causes of flank pain, while imposing minimal risk on the patient. It also should be sensitive for signs of obstruction, which may require emergent urologic intervention in the setting of sepsis or a single functioning kidney.

We review recent literature on the best imaging techniques to evaluate patients with flank pain for ureterolithiasis, and to rule out the potentially disastrous imitators of this disease. We also make recommendations for evaluation of flank pain in pregnancy.

IVU vs CT

Source: Pfister SA, et al. Unenhanced helical computed tomography vs intravenous urography in patients with acute flank pain: accuracy and economic impact in a randomized prospective trial. *Eur Radiol* 2003;13:2513-20.

This study reviewed multiple variables in the evaluation of patients with flank pain using either unenhanced helical computed tomography (UHCT) or intravenous urography (IVU). Since the use of UHCT for the diagnosis of ureterolithiasis was first described in 1995, it has become the imaging modality of choice for many.[1] The authors analyzed the diagnostic accuracy, economic impact, radiation dose, and length of stay using either UHCT or IVU. The study prospectively compared 122 consecutive patients who presented with acute flank pain. All patients received a urinalysis, blood work, a kidney-ureter-bladder (KUB) x-ray, and an abdominal ultrasound (US) study. The patients were randomly selected to receive UHCT or IVU.

Sensitivity and specificity of UHCT was 85.1% and 98.1%, while that of IVU was 75% and 91.7%, respectively. The average charge for IVU at the study institution (based in Switzerland) was 309 euro, while the average charge for UHCT was 310 euro. Average patient time spent in the examination room for IVU and UHCT was 1 hour 21 minutes and 23 minutes, respectively. The average radiation dose for UHCT was 6.5 mSv, while that for IVU was 3.3 mSv. Of 58 patients, there were three cutaneous allergic reactions to intravenous contrast material, which were described as mild to moderate.

Commentary

The sensitivity of UHCT derived from this study was somewhat less impressive than that of many other studies comparing UHCT to IVU. A recent

VOLUME 1 • NUMBER 10 • OCTOBER 2006 • PAGES 77-84

Thomson American Health Consultants Home Page—www.ahcpub.com • CME for Physicians—www.cmeweb.com

Statement of Financial Disclosure: Executive Editor, Ann M. Dietrich, MD, FAAP, FACEP, reported that she receives research support from the National Institutes of Health and is the medical director for the Ohio Chapter of ACEP. Drs. Boscovich and Marco (authors) and Dr. Manthey (peer reviewer) reported no financial relationships with companies having ties to this field of study.

THOMSON AMERICAN HEALTH CONSULTANTS

meta-analysis revealed UHCT (sensitivity 94-100%, specificity 92-100%) to be more accurate 'across the board' than IVU (sensitivity 52-87%, specificity 92-94%).[2] A short summary of this article is provided (*See Worster A, et al*). Despite these discrepancies, the information regarding cost, radiation dose, and duration of tests is extremely useful.

Subscriber Information

Customer Service: 1-800-688-2421.
Customer Service E-Mail: customerservice@thomson.com
World-Wide Web: www.ahcpub.com

Subscription Prices

United States
$299 per year (Student/Resident rate: $144.50).
Multiple Copies
Discounts are available for multiple subscriptions. For pricing information, call Steve Vance at (404) 262-5511.
Outside the United States
$329 per year plus GST (Student/Resident rate: $159.50 plus GST).

Practical Summaries in Acute Care, ISSN 1930-1103, is published monthly by Thomson American Health Consultants, 3525 Piedmont Rd., NE, Bldg. 6, Suite 400, Atlanta, GA 30305.

VICE PRESIDENT/PUBLISHER: Brenda L. Mooney
EDITORIAL GROUP HEAD: Glen Harris
MANAGING EDITOR: Martha Jo Dendinger
MARKETING MANAGER: Shawn DeMario
GST Registration Number: R128870672.

Periodical postage paid at Atlanta, GA.
POSTMASTER: Send address changes to ***Practical Summaries in Acute Care***, P.O. Box 740059, Atlanta, GA 30374.

Back Issues: $48 per issue. Missing issues will be fulfilled by Customer Service free of charge when contacted within one month of the missing issue's date.

Accreditation

Thomson American Health Consultants is accredited by the Accreditation Council for Continuing Medical Education to provide continuing medical education for physicians.

Thomson American Health Consultants designates this educational activity for a maximum of 20 *AMA PRA Category 1 Credits* . Physicians should only claim credit commensurate with the extent of their participation in the activity.

Practical Summaries in Acute Care also is approved by the American College of Emergency Physicians for 20 hours of ACEP category 1 credit.

Practical Summaries in Acute Care has been reviewed and is acceptable for up to 12 Prescribed credits by the American Academy of Family Physicians. Term of approval is for one year from beginning distribution date of 06/01/06. Each issue is approved for 1.0 Prescribed credits. Credit may be claimed for 1 year from the date of this issue. The AAFP invites comments on any activity that has been approved for AAFP CME credit. Please forward your comments on the quality of this activity to cmecomment@aafp.org.

This CME activity is intended for emergency physicians. It is in effect for 24 months from the date of the publication.

Questions & Comments

Please call **Martha Jo Dendinger,** Managing Editor, at (404) 262-5514 between 8:30 a.m. and 4:30 p.m. ET, Monday-Friday.

THOMSON
AMERICAN HEALTH CONSULTANTS

The cost of UHCT and IVU will vary among institutions. In this study, the cost was almost equivalent, but it was done in Europe. According to one study of the cost difference between IVU and UHCT at one ED in the United States, the average charges were $445 and $1,409, respectively.[3] However, if we consider the speed of diagnosis, shorter patient stay, and ability to identify other potentially life-threatening etiologies for flank pain, the price difference is less apparent.

It was noted that 4 of the 55 patients (7%) who underwent UHCT were diagnosed with other disease outside of the urinary tract. Other studies have found an even higher percentage of incidental findings when UHCT was used in the evaluation of flank pain. Boulay and colleagues found 17%, Ahmad and colleagues found 12%, and Kataz and colleagues found 10%, many of which were deemed as significant.[4-6] This additional diagnostic ability of UHCT comes at the cost of exposing the patient to twice the radiation dosage compared with that of IVU. Interestingly, one study described no significant change in accuracy of UHCT using reduced radiation-dose techniques (approximately 25% reduction).[7] Another study suggested using low-dose CT (equivalent radiation dose of an abdominal plain film) as a screening tool in patients with flank pain to avoid further imaging, and were able to decrease the mean radiation dose for their patients by 50%.[8] Such methods to reduce the amount of ionizing radiation should be explored further.

Patients with newly diagnosed stones

Source: Ha M, et al. Impact of CT scan in patients with first episode of suspected nephrolithiasis. *J Emerg Med* 2004; 27:225-31.

In this prospective observational outcome study, the investigators assessed the impact of helical computed tomography (CT) scanning in patients with a first episode of suspected nephrolithiasis. Before CT scanning, EPs assessed the diagnostic certainty of nephrolithiasis and anticipated patient disposition. CT scanning identified urinary calculi in 28.6% of patients with low pre-CT diagnostic certainty, and in 80.5% of patients with high pre-CT diagnostic certainty. CT scanning revealed alternate diagnoses in 40 cases (33.1%).

The authors concluded that patients presenting with a first episode of clinically suspected nephrolithiasis should undergo CT scanning because it enhances diagnostic certainty by identifying alternate diagnoses not suspected on clinical grounds alone.

Commentary

Other studies (see previous commentary) have also identified the importance of incidental findings when UHCT was used in the evaluation of flank pain.

CT vs IVU: Can we put the question to rest?

Source: Worster A, et al. The accuracy of noncontrast helical computed tomography versus intravenous pyelography in the diagnosis of suspected acute urolithiasis: a meta-analysis. *Ann Emerg Med* 2002;40:280-6.

In this meta-analysis, the authors reviewed four studies that met inclusion criteria, and identified pooled positive likelihood ratios (LR+) of 23.15 (95% CI 11.53-47.23) for UHCT, and 9.32 (5.23-16.61) for IVU. The pooled negative likelihood ratios (LR-) were 0.05 (0.02-0.15) for UHCT and 0.33 (0.23-0.48) for IVU. Differences were statistically significant for both LR+ and LR-. The authors concluded that UHCT is superior to IVU in the diagnosis of ureterolithiasis, and the differences for LR+ and LR- were statistically significant, compared with IVU.

Commentary

As previous individual studies have concluded, this meta-analysis demonstrated by pooled data and evidence-based medicine that UHCT is superior to IVU. The study did not address renal function, however. If there is high clinical suspicion for renal artery stenosis or obstruction, or concern for renal infarction, an IVU should be performed.

Size Matters!

Source: Boulay I, et al. Ureteral calculi: diagnostic efficacy of helical CT and implications for treatment of patients. *AJR Am J Roentgenol* 1999; 172:1485-90.

Does the CT scan identify information that has implications for the treatment of patients with ureteral calculi? The authors retrospectively analyzed CT scans from 99 patients who presented with flank pain for the presence, size, and location of ureteral stones as well as secondary signs of obstruction. Secondary signs of ureteral obstruction included hydronephrosis, perinephric stranding, and renal enlargement. The scans were read by a radiologist blinded to the clinical outcomes of each patient.

Ureterolithiasis was recognized in 51 scans and confirmed by either reported spontaneous passage, or retrieval of the calculus during urologic intervention. There were 48 scans that were interpreted as negative, and the absence of calculus was confirmed in all of these patients either by follow-up, further imaging, and in one case, surgery. Alternative diagnoses were made in 17% of these patients and included pyelonephritis, duodenitis, diverticulitis, and one T12 metastasis from multiple myeloma. Additional delayed images with modifications in CT technique were performed in 22 patients, which either required contrast or high-resolution imagery to differentiate phleboliths from ureterolithiasis.

The authors found sensitivity, specificity, and accuracy of 100%, 96%, and 98%, respectively, for UHCT or UHCT combined with enhanced images in this study. Twenty patients were treated conservatively with a mean stone size of 3.3 ± 1.3 mm (range 2-6 mm). Twenty-nine patients underwent intervention with mean stone sizes of 7 ± 6.2 mm (range 2-35 mm). Most calculi (72%) were found in the distal ureter, but location was not correlated with the type of therapy instituted.

Commentary

Of all the parameters measured, stone size was the most important variable that correlated with conservative versus interventional therapy. Findings of secondary signs of obstruction were useful for diagnosing obstruction, which is vital information in the setting of concurrent infection, but did not predict treatment for simple ureterolithiasis. In contrast, two studies suggested that stone composition and location are useful for determining treatment, both of which can be accurately characterized by UHCT.[9,10]

All calculi larger than 6 mm required urologic intervention. Stone size was determined solely by measurements taken on UHCT. This article did not address the accuracy of UHCT with actual stone size. Many patients requiring intervention underwent internal or external lithotripsy, making final stone measurement impossible. To summarize, three potentially important pieces of data for determining treatment are identified by helical CT: size, location, and presence of obstruction.

What about MRI?

Source: Sudah M, et al. Patients with acute flank pain: comparison of MR urography with unenhanced helical CT. *Radiology* 2002;223:98-105.

This study compared the accuracy of magnetic resonance (MR) urography with UHCT for detection of ureterolithiasis. The authors enrolled all patients presenting in a 10-month period with acute flank pain who would had otherwise been evaluated with IVU. Each patient underwent UHCT followed by MR urography and finally IVU. Those patients presenting during the night were scheduled for MR urography the next morning. Imaging was completed in a total of 49 patients. IVU images were interpreted by a radiologist and an urologist. UHCT results were interpreted by two blinded radiologists, and MR urography results were interpreted by two other blinded radiologists. Final diagnoses were made by pooling information from the IVU, clinical findings, interventional findings, and clinical outcome.

Ureterolithiasis was confirmed in 32 patients. Alternative diagnoses were found in 5 patients and included appendicitis, acute ulcerative colitis, urinary tract infection, sactosalpinx (a multiloculated tubal cyst), tubal torsion, and biliary colic. The tubal torsion was missed by all four radiologists on MR urography and UHCT. Upon follow-up, 12 patients had no conclusive diagnosis, all of whom had spontaneous resolution of their symptoms. Actual imaging time was less than one minute for UHCT, while the mean imaging time for MR urography was 56 minutes. Sensitivities of UHCT and MR urography for stones were 90.6% and 93.8-100%, respectively. Specificity for MR urography was 100%, while that of UHCT was 94.1-100%. Overall accuracy of UHCT for stone was 91.8-93.9% and accuracy of MR urography was 95.9-100%. For obstruction, UHCT had an accuracy of 95.9%, but MR urography correctly identified all cases of obstruction with an overall accuracy of 100%. UHCT was found to be more accurate in estimating stone size when compared with MR urography.

Commentary

This study confirmed the high accuracy of MR urography and UHCT in the evaluation of ureterolithiasis. There were two stones that were missed by UHCT, both of which proved to be uric acid stones. MR urography also may be of benefit for evaluating calculi caused by indinavir therapy, which are commonly missed by UHCT. Secondary signs of obstruction were evident in both cases allowing for a presumed diagnosis of ureterolithiasis.

MR urography does not facilitate direct visualization of the stones. Instead, a signal void is often observed with indications of proximal obstruction and a filling defect inside the ureteral lumen. This filling defect also can be caused by a neoplasm or blood clots, making this sign nonspecific. If there is question, the authors recommend a plain radiograph to identify a calcification at the site of obstruction. Conversely, UHCT clearly depicts stones and allows for more accurate size estimations when compared with MR urography. This also allows better identification of fur-

ther stone burden in the renal calices.

Both of the imaging modalities discussed here have unique advantages and are accurate in the diagnosis of ureterolithiasis and other causes of acute flank pain. UHCT offers timely diagnosis and useful information important for determining interventional versus conservative therapy. Radiation is not a factor with MR urography, and it provides functional information about the kidneys. Because of the general unavailability of MR urography in most EDs and its increased cost, its use should be reserved for pregnant patients who present with acute flank pain in the ED.

Does ultrasound have a role?

Source: Sheafor DH, et al. Nonenhanced helical CT and US in the emergency evaluation of patients with renal colic: prospective comparison. *Radiolo*gy 2000;217:792-7.

The purpose of this blinded prospective study was to compare the sensitivity and specificity of ultrasonography (US) with that of UHCT in the evaluation of ureterolithiasis. It consisted of 45 consecutive patients who presented to the ED with acute flank pain. Each patient was first evaluated with UHCT; the test was immediately read by one of six attending radiologists. US was then performed on each of the patients, and the results were determined by one of eight attending radiologists. The radiologists were blinded to the UHCT results. The average room time for UHCT was 10-15 minutes, while that for US was 30 minutes or less (including the radiologist reading time).

There were 23 documented cases of ureterolithiasis confirmed by follow-up or calculus recovery; 22 were detected by UHCT, giving a sensitivity of 96%. Only 14 were detected by US with a sensitivity of 61%. Specificity was 100% for both methods. The sensitivity for individual observers in the detection of ureterolithiasis was 83-91% for UHCT and 39-61% for US. Sensitivity for US and UHCT improved (from 61% to 85% and from 96% to 100%, respectively) for detection of any clinically relevant abnormality such as hydronephrosis, renal masses, or appendicitis. US and UHCT provided 92% and 100% sensitivity, respectively, for any clinically relevant abnormality (defined as unilateral hydronephrosis and/or ureterolithiasis). Of note, the single case of appendicitis diagnosed by UHCT was missed by US.

Commentary

US may never replace UHCT as the study of choice for ureterolithiasis, however it may be a useful adjunct to quickly assess patients in the ED and guide further management, especially for pregnant patients. Of course, US is operator dependent, and results are variable depending upon factors such as bowel gas and body habitus. This article did not specifically address the accuracy of US when performed as a bedside examination by an EP.

Is bedside US useful in the evaluation of flank pain?

Source: Rosen CL, et al. Ultrasonography by emergency physicians in patients with suspected ureteral colic. *J Emerg Med* 1998;16:865-70.

Bedside US is quickly becoming one of the most useful diagnostic and procedural tools available to the EP. This prospective study was designed to determine the ability of 13 EPs with varying US experience to identify hydronephrosis with bedside US. Each participating physician was required to complete an orientation course in US consisting of two hours of didactic training followed by three hours of supervised hands on training. Patients were selected if they presented with symptoms consistent with ureteral colic and were to undergo UHCT or IVU. A pretest probability was determined based on the results of the urinalysis and the patient's clinical presentation. The EP performed a bedside US on 126 selected patients to determine the presence or absence of hydronephrosis. Then, they categorized the patients into three groups based on *low* (0-24%), *intermediate* (25-74%) and, *high* (75-100%) post-test probability. Then, IVU or UHCT was performed on each patient. Both UHCT and IVU were considered gold standard tests for determining the presence of stones, but IVU was considered the only gold standard test for the presence of hydronephrosis.

IVU was performed in 84 patients as the formal imaging study, and 42 patients received an UHCT. Of these, 63 (75%) of the patients who had an IVU and 33 (79%) of the patients receiving UHCT had confirmed ureterolithiasis. The overall sensitivity and specificity of bedside US for hydronephrosis (confirmed with IVU) was 72% and 73%, respectively. The overall positive predictive value (PPV) was 85%. EPs with previous experience in US (i.e., having performed more than 50 ultrasound studies prior to the study) reached a sensitivity and specificity of 75% and 89%, respectively with a PPV of 93%. Of the 126 patients enrolled, 102 were classified as having a high (>75%) post-test probability for ureterolithiasis, 88 of whom had confirmed calculi by IVU or CT (PPV 86%).

Commentary

Bedside US is a simple, rapid, and noninvasive imaging tool becoming widely available to the practice of emergency medicine. Unfortunately, this article does not support the use of bedside US in the work-up of acute flank pain.

The authors noted more accurate results of the US studies performed by EPs with prior experience in US, although this difference was not significant. In addition, IVU was used for approximately 66% of the patients as the gold standard imaging study for the detection of ureterolithiasis. As IVU has a lower sensitivity for detection of ureterolithiasis compared with UHCT, there may have been a significant number of false-negative IVU results, which would decrease the number of false-positive results in those patients with a high post-test probability. It also was postulated that IVU was more sensitive for the detection of hydronephrosis than UHCT. However, the study by Sheafor

and colleagues discussed previously revealed a sensitivity of 100% when using UHCT for detection of any clinically relevant abnormality such as unilateral hydronephrosis and/or ureterolithiasis.[11] Despite these discrepancies, we still cannot postulate that the results would have been better under ideal circumstances.

This study relayed generally poor accuracy of bedside US for hydronephrosis when performed by EPs. The use of a subjective pretest probability and a generally poor mode of imaging to determine post-test probability for presence of ureterolithiasis is not recommended for everyday practice and does not preclude the need for UHCT.

More on bedside US

Source: Surange RS, et al. Bedside ultrasound: a useful tool for the on-call urologist? *Int Urol Nephrol* 2001;32: 591-6.

The objective of this study was to determine the accuracy and efficacy of bedside US in the workup of patients with acute flank pain. Bedside US was performed in 111 patients presenting with flank pain by an urologist in training who had received an unspecified amount of US training by a consulting radiologist. Of the 111 US studies performed, 109 received definitive imaging to confirm any detected abnormalities. Two positive US results were confirmed procedurally, one with laparotomy for a leaking abdominal aortic aneurysm (AAA), the other with ureteroscopy for a suspected ureteral stone in a patient who also had an intravenous contrast allergy. Definitive imaging included IVU, formal US, or UHCT alone or in combination with each other. All patients with hematuria received cystoscopy after IVU with or without formal US.

Bedside US showed a sensitivity and specificity of 80.7% and 92.3%, respectively. Any US abnormality was considered a positive test for US, but actual abnormalities detected were not specified. Positive and negative predictive values were 85.6% and 89.7%, respectively. Bedside US proved life-saving in 5 patients: 2 with a leaking AAA, 2 with bilateral ureteral obstruction, and one with pyonephrosis. The study implied that all 5 of these patients underwent urgent or emergent intervention based on the US results. The authors also mentioned US allowing "urgent diagnosis" of obstructive versus non-obstructive processes as the etiology of renal failure in 10 patients, influencing initial management by more appropriate consultation.

Commentary

Results of this study remain unclear in many ways. The authors did not specify what abnormalities were detected for the patients with positive results. We assume most patients with an abnormal bedside US study had detectable hydronephrosis. All findings were confirmed using a combination of imaging techniques, which have variable, and in some cases, less than ideal accuracy for the detection of ureterolithiasis or obstruction. Definitive imaging was performed more than 48 hours after the bedside US study in some cases. The authors also measured the numbers of patients in which bedside US was helpful in early diagnosis, which appears largely as a subjective measurement. The sensitivity and specificity cited in this study have been duplicated in a recent study that identified a sensitivity of 83.3% and a specificity of 92.0%.[12]

Bedside US proved life-saving in 5 patients. This fact alone may support its use in the initial evaluation of acute flank pain, although it is not sufficient to be the only imaging study. Flank pain is commonly the presentation for a ruptured AAA, which has deadly consequences with delayed diagnosis. Patients who appear septic with urinary tract infection should have an immediate US study to detect obstruction to facilitate emergent urologic consultation and intervention. Further studies are needed to determine the accuracy and efficacy of US for detection of simple ureteral stones. Until then, UHCT should be used to confirm bedside US findings.

Source: Calabro JL et al. Does kidney stone size correlate with degree of hydronephrosis on focused emergency department ultrasonography? *Ann Emerg Med* 2004;44 (4 S):S114.

This interesting study examined the significance of the size of kidney stones and relation to hydronephrosis. The investigators performed a retrospective study of 44 patients who had a focused ED bedside renal US study and also underwent noncontrast CT in 2004. ED sonographers were blinded to the CT results.

CT was considered the gold standard. The authors identified a 90% sensitivity and 97% specificity for ED ultrasonography. No correlation between stone size on CT and degree of hydronephrosis was identified.

The authors concluded that ED US is quite sensitive and specific for hydronephrosis, but the severity of hydronephrosis does not correlate with stone size.

Commentary

Two of the reasons for ED imaging of suspected ureterolithiasis include estimating stone size, which correlates with need for urologic intervention, and identification of hydronephrosis, which may be associated with need for urgent intervention. Although ED US was useful for identifying hydronephrosis, inability to measure stone size is a significant limitation of the study.

Evaluation of flank pain in pregnancy

Source: Shokeir AA, et al. Renal colic in pregnant women: role of renal resistive index. *Urology* 2000; 55:344-7.

This article studied 22 pregnant women during a period of 2 ½ years who presented with acute unilateral renal colic (Group A). All 22 patients had confirmed ureterolithiasis via IVU, ureteroscopy, or direct visualization on US. US was the initial test of choice and ureterolithiasis with proximal obstruction was confirmed by limited IVU. Standard gray-scale images of all kidneys were recorded, and pelvicaliceal dilation was subjectively graded as *absent*, *mild*, *moderate*, or *marked*.

Doppler US also was performed on the arcuate or interlobar arteries of the kidneys and the resistive index (RI), and change (D) in RI were calculated. A RI of 0.70 and a DRI of 0.04 or greater were considered positive. The RI was expected to be elevated in the setting of acute ureteral obstruction. Two other groups of patients consisting of 71 normotensive asymptomatic pregnant patients with similar gestational ages (Group B), and 20 nonpregnant women (Group C) were used as controls. There was no significant difference in RI between the control groups and no significant difference in the mean RI between the kidneys showing pelvicaliceal dilation and the normal appearing kidneys in Group B. This suggests RI is only elevated in the setting of acute ureteral obstruction despite findings of pelvicaliceal dilation on standard gray-scale US.

The RI had a sensitivity, specificity, and accuracy of 45%, 91%, and 87%, respectively for acute ureteral obstruction. The DRI between the affected and unaffected kidneys boasted a sensitivity, specificity, and accuracy of 95%, 100%, and 99%, respectively.

Commentary

As mentioned in the review above, DRI proves promising in the diagnosis of acute ureteral obstruction while avoiding harmful radiation exposure to the fetus.

Caveats to using DRI include having a single kidney and use of NSAIDs prior to the study, which will inhibit prostaglandin synthesis and their vasoconstrictive effects on the vessels of the affected kidney. If there is no change in the RI, acute ureteral obstruction is less likely, however further studies (i.e., limited IVU or MRU) are indicated in those patients with persistent pain.

Flank pain and pregnancy: diagnostic considerations

Source: McAleer SJ, et al. Nephrolithiasis and pregnancy. *Curr Opin Urol* 2004; 14:123-7.

This article reviews the diagnosis and management of ureterolithiasis in the pregnant patient. Physiologic hydronephrosis is common in pregnancy and is present in 90% of gravid patients presenting to the ED. When these patients present with flank pain, the EP's task is to rule out acute ureteral obstruction, whether it be caused by ureterolithiasis or other obstructive pathology.

First trimester fetuses exposed to radiation have a greater incidence of fetal malformations, while those exposed in the second or third trimester have increased risk of childhood malignancies. To put it into perspective, a pelvic CT scan will expose a fetus to 2.2-2.5 cGy, while a three-film IVU inflicts a dose of only 0.2 cGy. The risk of fetal malformations increases by 5% at a dose of 10 cGy. One retrospective study revealed a relative risk of 2.4 for childhood malignancy when exposed to an average of only 1 cGy.[13]

The authors discussed the poor sensitivity and specificity of standard US for ureterolithiasis. As previously presented, Shokeir and colleagues found the sensitivity, specificity, and accuracy for identifying acute obstruction increased to 95%, 100%, and 99%, when using the change in RI.[14] The change in RI becomes larger as blood flow is shunted to the unobstructed kidney and is thought to be due largely to prostaglandin synthesis in the setting of acute ureteral obstruction. Other techniques that facilitated the diagnosis of ureteral stones included transvaginal US (for direct visualization of the stones) and the use of color Doppler to determine the presence of ureteral jets (which are absent in obstructed ureters).

When US fails to diagnose obstruction, the authors recommend the use of a limited IVU. This involves shielding the unaffected side and shooting a scout film, then films at 30 seconds and 20 minutes. Stothers and Lee were able to diagnose 16/17 cases of ureterolithiasis using this technique.[15] The authors discouraged the use of MRU based on the lack of direct visualization of ureteral calculi, cost, unavailability, and time requirement. These conclusions were based on older studies and appeared biased as they failed to mention the excellent accuracy and ability to assess kidney function with the use of MRU.

Management of ureterolithiasis in pregnant patients is usually conservative, based on the fact that 70-80% of the stones will pass spontaneously.[16,17] Those with persistent symptoms have undergone a variety of treatments in the past including percutaneous nephrostomy, internal stents, ureteroscopy with basket extraction, various methods of lithotripsy, and nephrolithotomy. The least invasive technique is obviously preferred and often consists of ureteroscopy with basket extraction or lithotripsy using Holmium laser.

Commentary

The authors of this review outlined a manageable plan for the diagnosis of ureterolithiasis in pregnant patients. Our role as EPs should be to rule out acute ureteral obstruction in the pregnant patient who presents with flank pain. It is clear that all pregnant patients presenting with acute flank pain should receive an initial US study, preferably with the techniques mentioned above. EPs also should be keen to the other causes of flank pain in these patients (e.g., pyelonephritis and appendicitis). Appropriate obstetrical, urologic, and surgical consultations should be made in a prompt manner to guide further diagnostic work-up in patients with concerning symptomatology.

Conclusion/ Recommendations

There is ample evidence that UHCT should be used as the first-line imaging modality in most patients presenting with suspected ureterolithiasis. UHCT is very accurate for identifying ureterolithiasis and often can identify other extra-renal causes of flank pain, which may require emergent intervention. UHCT also provides accurate information regarding stone size, which is the most significant factor in determining definitive therapy. As well, it identifies two other issues pertinent to treatment, the location of the stone and the presence of hydronephrosis. Helical

CT however, does not evaluate the functional status of the kidney and therefore further evaluation may be required if vascular insults are suspected (IVP, contrast CT, Doppler US, and MRU).

Bedside US continues to gain utility and acceptance in emergency medicine. Its ability to detect hydronephrosis is variable (sensitivity 72-90% and specificity 73-97%). Even if we were able to accurately detect hydronephrosis at the bedside, hydronephrosis is not specific to ureterolithiasis and that may be caused by other pathology such as urethral stricture or mass. However, bedside US can facilitate the rapid diagnosis of life-threatening mimics of renal colic such as ruptured AAA or pyonephrosis. Based on this finding, routine use of bedside US is recommended for patients with flank pain as an initial screening tool for emergent diagnoses. In all cases, the imaging should be followed by more definitive evaluation.

Pregnant patients are a special population who should undergo formal renal US as the initial study of choice. The combination of standard grey-scale US evaluation with calculation of DRI, color Doppler of ureteral jets, and transvaginal US make this study much more accurate in the pregnant patient.

Limited IVU is a reasonable option for pregnant patients with an US finding that suggests acute ureteral obstruction. MRU may be a better study in facilities where it is readily available because of its ability to diagnose other causes of flank pain. Radiation exposure is a significant consideration in pregnant patients. When compared with UHCT, MRU boasts the same diagnostic ability, provides information about renal function, and avoids such radiation exposure. However, MRU does not relay accurate information on stone size, which is the major determinant of interventional versus conservative therapy for ureterolithiasis.

Figure. Recommended Algorithm for the Worksup of Flank Pain in the ED

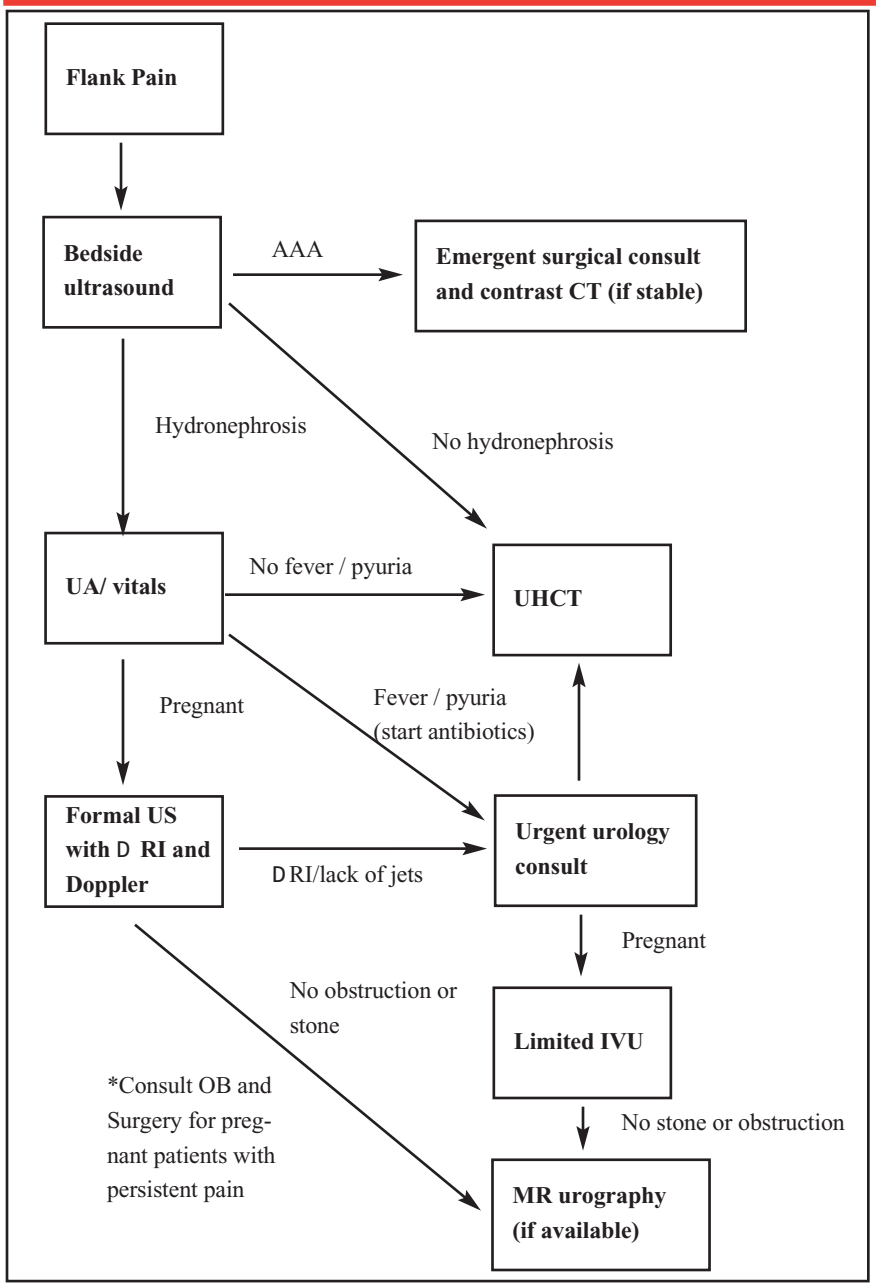

References

1. Smith RC, et al. *Radiology* 1995; 194:789-94.
2. Worster A, et al. *Ann Emerg Med* 2002;40(3):280-6.
3. Li J, et al. *J Urol* 2001;165:782-4.
4. Boulay I, et al. *AJR Am J Roentgerol* 1999:174(2):S68-9.
5. Ahmad NA, et al. *Int J Urol* 2003; 10:287-92.
6. Katz DS, et al. *Urology* 2000:56:53-7.
7. Heneghan JP, et al. *Radiology* 2003 ;229(2):575-80.
8. Poletti PA, et al. Urology 2006 67(1): 64-8.
9. Singal RK, et al. *Urol Clin North Am* 1997;24:59-70.
10. Marberger M, et al. Euro Urol 1994; 25(4):265-72.
11. Sheafor DH, et al. *Radiology* 2000; 271:792-7.
12. Gaspari RJ, et al. *Acad Emerg Med* 2005;12(12):1180-4
13. Harvey EB, et al. *N Eng J Med* 1985; 312(9):541-5.
14. Shokeir AA, et al. *Urology* 2000; 55:344-7.
15. Stothers L, Lee LM. *J Urol* 1992; 148(5):1383-7.
16. Loughlin KR. *Urology* 1994;44:159-69
17. Lewis DF, et al. *J Reprod Med*;2003; 48:28-32.
18. Walther PC, et al. *Pediatrics* 1980; 65(6):1068-72.

CME OBJECTIVES

Upon completing this program, participants will be able to:

- Summarize the most recent significant studies in emergency medicine/acute care related to a single topic;
- Discuss up-to-date information about new drugs, techniques, equipment, trials, studies, books, teaching aids, and other information pertinent to the stated topic;
- Evaluate the credibility of published data and recommendations about the stated topic.

CME INSTRUCTIONS

Physicians participate in this continuing medical education program by reading the articles, using the provided references for further research, and studying the CME questions. Participants should select what they believe to be the correct answers, then refer to the list of correct answers to test their knowledge. To clarify confusion surrounding any questions answered incorrectly, please consult the source material.

After completing this activity, participants must complete the evaluation form provided at the end of each semester (May and November) and return it in the reply envelope provided to receive a credit letter. When an evaluation form is received, a credit letter will be mailed to the participant.

CME QUESTIONS

46. Which of the following statements regarding imaging for ureterolithiasis is correct?

a. IVU boasts a similar sensitivity and specificity to that of UHCT, but is more costly.
b. UHCT provides the best information to determine conservative versus interventional treatment for ureterolithiasis.
c. The sensitivity of UHCT is far superior to that of MR urography.
d. Ultrasonography should be reserved only for pregnant patients presenting with flank pain.

47. Which of the following is *not* major benefit to the use of bedside ultrasound for acute flank pain?

a. It can facilitate immediate intervention for life-threatening causes of flank pain.
b. There is no radiation exposure to the patient.
c. It has a low cost and is portable.
d. Most ureteral stones can be seen on bedside ultrasound, obviating the need for UHCT.

48. Which of the following statements is *not* correct?

a. Patients with fever, pyuria, and hydronephrosis require prompt urologic involvement.
b. The best predictor for interventional therapy for a ureteral stone is the size of the stone.
c. MR urography is easily obtained in most EDs today.
d. Transvaginal US may facilitate the diagnosis of ureteral stones.

49. Which of the following cannot be accurately visualized on MR urography?

a. Hydroneprosis
b. Extra-renal causes of flank pain
c. Stone size
d. Renal function

50. Which of the following statements regarding imaging in acute flank pain is true?

a. Helical CT is helpful in determining size, location, and presence of obstruction.
b. MR urography should be used in all patient with flank pain.
c. UHCT is recommended for pregnant patients with a negative ultrasound result.
d. Ultrasonography may be used to exclude ureteral stones in a patient with flank pain.

Answers: 46. b ; 47. d ; 48. c ; 49. c ; 50. a