THOMSON
AMERICAN HEALTH CONSULTANTS

Rapid Reference Card Enclosed

The Practical Journal for Emergency Physicians

Emergency Medicine Reports®

Volume 27, Number 20 September 18, 2006

The first documented treatment of nasal hemorrhage by medical professionals stems from ancient Egypt nearly 4,000 years ago. Epistaxis remains a common problem, continuing to plague patients and physicians today. One in every 200 emergency department (ED) visits is for nosebleed. The etiologies of epistaxis vary, ranging from the mundane such as drying of the mucosa, to the life-threatening (i.e., post traumatic pseudoaneurysm or profound coagulopathy.)

The emergency physician must be adequately prepared and equipped to treat all forms. A thorough familiarity with nasal anatomy and vascular supply is essential, as is a command of management strategies. Laboratory and diagnostic imaging studies are indicated only in certain limited situations. The need for blood pressure control with antihypertensive agents remains controversial. The treatment should be organized into a stepwise approach of increasingly invasive techniques for hemorrhage control. Ear, nose, and throat

Management of Epistaxis in the Emergency Department

Authors: **Liudvikas Jagminas, MD, FACEP**, Associate Professor of Emergency Medicine, Brown Medical School, Providence, RI; Physician in Chief of Emergency Medicine, Memorial Hospital of Rhode Island, Pawtucket, RI; and **Michelle Daniel, MD**, Attending Physician, Department of Emergency Medicine, Memorial Hospital of Rhode Island, Pawtucket, RI; Clinical Instructor, Brown Medical School, Providence, RI.

Peer Reviewers: **Andrew D. Perron, MD, FACEP, FACSM**, Residency Program Director, Associate Professor, Department of Emergency Medicine, Maine Medical Center, Portland; and **Jonathan Glauser, MD, FACEP**, Vice Chair, Department of Emergency Medicine, Cleveland Clinic Foundation, Faculty, Emergency Medicine Residency, MetroHealth Medical Center, Cleveland, OH.

Statement of Financial Disclosure

To reveal any potential bias in this publication, and in accordance with Accreditation Council for Continuing Medical Education guidelines, we disclose that Dr. Farel (CME question reviewer) owns stock in Johnson & Johnson. Dr. Jagminas (author) serves on the speaker's bureau for Sepracor and holds stock in Pfizer. Drs. Daniel (author), Perron (peer reviewer), Glauser (peer reviewer), and Dr. Schneider (editor) report no relationships with companies related to the field of study covered by this CME activity. Dr. Stapczynski (editor) reports that he served as a consultant to Pfizer on the drugs linezolid and dalbavancin. Dr. Bosker (editor in chief) has been compensated for speaking engagements and/or editorial services related to production of peer-reviewed Clinical Consensus Reports under the auspices of unrestricted educational grants for Pfizer, Sanofi-Aventis, Bristol-Myers Squibb, Roche Pharmaceuticals, Bayer, Novartis, Forest Pharmaceuticals, and Schering Plough Corporation. Dr. Bosker also acknowledges that he has received royalties, commissions, and other compensation relating to the sale of textbooks, reprints of articles, and/or other electronic or print materials to the following pharmaceutical companies: Pfizer, Sanofi-Aventis, Bayer, Roche, Forest Laboratories, and Novartis. He is a minor stockholder in Pfizer. Any other stock ownership which he may have in other pharmaceutical companies is managed in blinded fashion by an independent consultant without Dr. Bosker's input or consultation.

(ENT) specialists should be contacted urgently for severe or refractory cases.

—J. Stephan Stapczynski, MD, Editor

Background

Epistaxis, the Greek term for nosebleed, has been a part of the human experience since ancient times. Physicians have been involved in the treatment of refractory cases since the pharaohs walked the earth. The Edwin Smith Papyrus, a 17th century B.C. composite text discovered in 1862, describes the surgical treatment of epistaxis in ancient Egypt, starting with a description of how to clear away clots—"thou shouldst clean out every worm of blood which has coagulated on the inside." The hieroglyphics go on to describe the first nasal packing with "two swabs of linen."

Hippocrates, generally recognized as the father of modern medicine, was the first to comment in 400 B.C. that firm pressure on the alae was an excellent initial method for controlling nosebleeds. He also described packing of the nares using sheep's wool soaked in the oil of figs.

Two millennia ago, Pliny the Elder used snail derivatives to control bleeding—a technique that is being reevaluated by holistic pharmaceutical companies as of 2005.[1] In the 1600s, the physician Lubon scrawled a magical saying on his patients' foreheads to halt nasal hemorrhage. A century later, the physician Moncrief fried his patient's own blood and proffered the mixture to inhale as snuff. Their contemporaries prescribed amulets to wear to ward off evil nasal vapors. Others suggested drinking whey with raisins while wearing a skein of scarlet silk with nine knots to prevent the occurrence of epistaxis. While clearance of clots, the application of pressure, and nasal packing remain mainstays of therapy today, for obvious reasons, the other remedies will remain historical footnotes.

Ali Ibn Rabban Al-Tabiri in A.D. 850 suggested that epistaxis was caused by the swelling of a vein and its rupture. This still is a fundamental pathophysiologic concept today. Carl Michel (1871), James Little (1879), and Wilhelm Kiesselbach were the first modern physicians to identify the nasal septum's anterior plexus as a major source of bleeding. They also were among the first to recognize that although the anterior plexus was the most common source of bleeding, the posterior areas were more refractory to treatment. Pilz performed the first common carotid artery ligature in 1869 to treat refractory posterior epistaxis. Seiffert successfully ligated the internal maxillary artery to treat the same condition via the maxillary sinus in the 1920s. Henry Goodyear was the first to tie the anterior ethmoidal artery in 1937.

The medical community's understanding of nosebleeds has expanded dramatically since the writing of Egyptian papyri and the era of Hippocrates. Technological advances in the 20th and 21st centuries have greatly improved the ability of both emergency and specialty physicians to treat nasal hemorrhage. The current management of epistaxis tends to involve a strategy of increasing intervention, with antiquarian ideas of pressure application and packing continuing to form the foundation of modern therapies.

Epidemiology

Epistaxis is the most common rhinocologic emergency seen in ENT units. Most nosebleeds are merely nuisances, some are intense, but only a few are life-threatening. When specialty medical care is needed, the problem is likely to be recurrent, severe, or simply frightening and poorly understood.

For years the epidemiology of epistaxis was not well defined. Most publications cite data from population surveys performed in the 1970s, which are unlikely to accurately reflect our current aging and increasingly anticoagulated demographics. These surveys, which appeared in the otolaryngology literature, suggested a lifetime prevalence of nasal hemorrhage in the United States of 60%, with 10% of those seeking medical care, and 10% of those requiring ENT referral.[2] The yearly incidence was broadly estimated to be between 5 and 14%. Of course, the true incidence of epistaxis will probably never be known, as most episodes are self-treated.

Until recently, no study had addressed the key epidemiologic questions for emergency physicians, namely what is the prevalence of nosebleeds presenting to the ED, what are the key

Emergency Medicine Reports™ (ISSN 0746-2506) is published biweekly by Thomson American Health Consultants, 3525 Piedmont Road, N.E., Six Piedmont Center, Suite 400, Atlanta, GA 30305. Telephone: (800) 688-2421 or (404) 262-7436.

Vice President/Group Publisher: Brenda Mooney
Editorial Group Head: Glen Harris
Specialty Editor: Shelly Morrow Mark
Marketing Manager: Nan Webb
GST Registration No.: R128870672

Periodicals postage paid at Atlanta, GA. **POSTMASTER:** Send address changes to ***Emergency Medicine Reports***, P.O. Box 740059, Atlanta, GA 30374.

Back issues: $31. Missing issues will be fulfilled by customer service free of charge when contacted within one month of the missing issue's date.

Multiple copy prices: One to nine additional copies, $359 each; 10 to 20 additional copies, $319 each.

Accreditation

Thomson American Health Consultants is accredited by the Accreditation Council for Continuing Medical Education to provide continuing medical education for physicians.

Thomson American Health Consultants designates this educational activity for a maximum of 60 *AMA PRA Category 1 Credits™*. Physicians should only claim credit commensurate with the extent of their participation in the activity.

Emergency Medicine Reports™ also is approved by the American College of Emergency Physicians for 60 hours of ACEP Category 1 credit. *Emergency Medicine Reports* has been reviewed and is acceptable for up to 39 Prescribed credits by the American Academy of Family Physicians. AAFP accreditation begins 01/01/06. Term of approval is for one year from this date. Each issue is approved for 1.5 Prescribed credits. Credit may be claimed for 1 year from the date of this issue.

This is an educational publication designed to present scientific information and opinion to health professionals, to stimulate thought, and further investigation. It does not provide advice regarding medical diagnosis or treatment for any individual case. It is not intended for use by the layman. Opinions expressed are not necessarily those of this publication. Mention of products or services does not constitute endorsement. Clinical, legal, tax, and other comments are offered for general guidance only; professional counsel should be sought for specific situations.

This CME activity is intended for emergency physicians. It is in effect for 24 months from the date of the publication.

THOMSON™
AMERICAN HEALTH CONSULTANTS

Subscriber Information

Customer Service: 1-800-688-2421

Customer Service E-Mail: customerservice@ahcpub.com
Editorial E-Mail: shelly.mark@thomson.com

World Wide Web page: http://www.ahcpub.com

Subscription Prices

1 year *with* 60 ACEP/60 AMA/60 AAFP Category 1/Prescribed credits: $544
1 year *without* credit: $399
Resident's rate $199

All prices U.S. only.
U.S. possessions and Canada, add $30 plus applicable GST. Other international orders, add $30.

For Customer Service and CME questions,

Please call our customer service department at **(800) 688-2421.** For editorial questions or comments, please contact **Shelly Morrow Mark,** Specialty Editor, at shelly.mark@thomson.com or (352) 351-2587.

Figure 1. Visits to U.S. EDs for Epistaxis by Age, 1992-2001

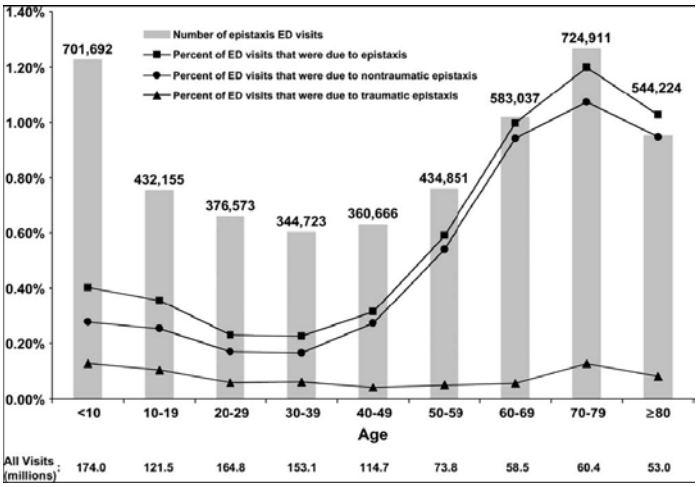

Reprinted with permission from: Pallin DJ, Chng YM, McKay MP, et al. Epidemiology of epistaxis in U.S. emergency departments, 1992 to 2001. *Ann Emerg Med* 2005;46:79.

Figure 2. Blood Supply of the Nasal Septum

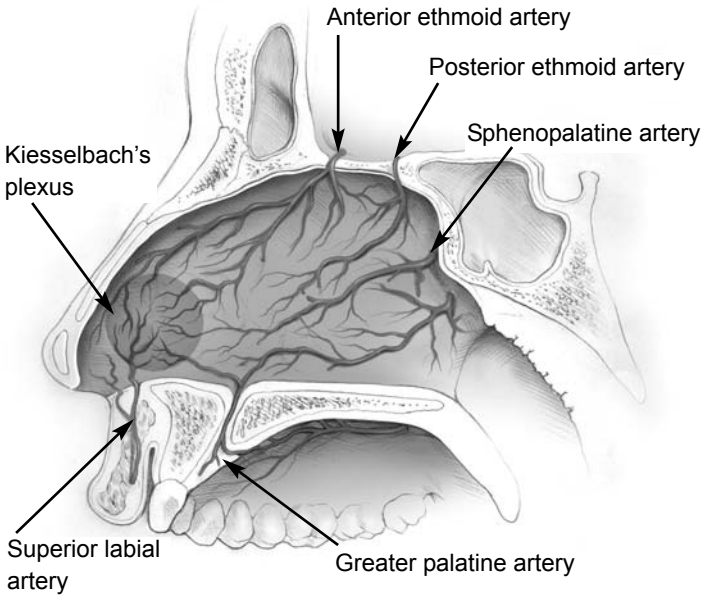

Illustration reprinted with permission from: Christy Krames, certified medical illustrator.

patient demographics in the ED population, and what percentage of these patients require admission. An article in *Annals of Emergency Medicine* in July 2005 highlights these issues. The retrospective review found that epistaxis resulted in 4,503,000 ED visits over a 10-year period from 1992-2001. This accounted for 0.46% of all ED visits, or approximately 1 in every 200 ED patients. The overall prevalence of epistaxis presenting to the ED was 1.7 visits per 1,000 population.[3]

This article supported earlier studies from the Western hemisphere that suggested the age distribution of epistaxis was bimodal, with peaks among those younger than 10 years (4 per 1,000 visits) and those 70-79 years (12 per 1,000 visits). Despite this early age peak, the majority of cases of epistaxis occur in the elderly adult population. (*See Figure 1.*) Of note, this bimodal pattern does not appear to be universal. In the tropics, particularly in the developing world, epistaxis is more a disease of the young, with the highest incidence occurring in patients younger than 20 years old.[4] This is thought to be due in part to the different social age structures, with lower life expectancies and subsequent lack of cardiovascular disease in the third world. In both the developing and the developed world, trauma accounted for only a small percentage (7% and 17% of cases, respectively), and was more common in younger age groups.[3,4]

No racial or ethnic differences in rates of epistaxis have been described. A sex predilection has been reported by multiple authors, with approximately 60% of patients being male and 40% female.[3-5] This may be due in part to the protective effects of estrogen, which locally fosters a healthy nasal mucosa and systemically reduces the risk of cardiovascular disease. This theory is supported by the observation that the sex differences in nasal hemorrhage incidence equalize after menopause.

Marked seasonal variation in rates of epistaxis occurs in both temperate and tropical climes. In the United States, nosebleeds are more common in the winter months. An increase in ED visits is seen from December to February, and a 100% increase in admission rates was observed in at least one study.[3,6] This spike in prevalence is attributed to a decrease in ambient humidity, as well as an increase in the frequency of comorbid upper respiratory infections. In tropical climates, epistaxis occurs with greater frequency during the dry seasons.[4]

Overall, 6% of patients presenting to the ED with nasal hemorrhage will require admission.[3] The need for hospital admission increases with age and concomitant use of warfarin.[7,8] Mortality is rare (estimated case fatality rate 0.1%) and usually is due to complications of hypovolemia from severe hemorrhage or complications of underlying disease states.[9]

Anatomy

The nasal cavity is bounded medially by the nasal septum and laterally by the lateral nasal wall, consisting of three turbinates, a system of ostia, sinuses, and fossae. Anteriorly the cavity opens out the nare, and posteriorly feeds out the nasopharyngeal opening. The roof is composed of the cribriform plate and the fovea ethmoidalis. The floor consists of the maxillary bone. The respiratory mucosa is lined by pseudostratified ciliated epithelium, serous, and mucin-secreting glands. This mucosa, along with its rich underlying vascular supply, serves to regulate heat exchange and humidification during respiration.

The blood supply of the nose is rich and complex with branches arising from both the internal and external carotid arteries with multiple anastomoses. The external carotid artery supplies the nose via the facial and internal maxillary branches. The superior labial branch of the facial artery supplies the anterior nasal floor and

Table 1. Etiology of Epistaxis

LOCAL

Trauma
- Nasal fracture (lacerated vasculature, damaged mucosa)
- Rhinotillexomania (compulsive nose picking)
- Nasal foreign body (often associated with unilateral purulent discharge)
- Iatrogenic (nasogastric or nasotracheal intubations, head and neck surgeries)
- Carotid aneurysm (rare, deadly; delayed presentation of posterior bleed, associated cranial nerve deficits)

Infectious/Inflammatory
- Allergic rhinitis
- Upper respiratory infections (bacterial, viral, fungal)
- Chronic sinusitis
- Intranasal parasites
- Nasal cellulitis
- Entomophthoromycosis

Neoplasm
- Juvenile nasopharyngeal angiofibroma (pubertal males with triad of posterior bleed, obstruction, and mass)
- Nasal hemangioma
- Papilloma
- Adenoid cystic carcinoma
- Squamous cell carcinoma
- Adenocarcinoma
- Hemangiopericytoma
- Rhabdomyosarcoma
- Esthesioneuroblastoma

Chemical/Irritants
- Cocaine
- Cigarette smoke
- Cannabis
- Ammonia
- Others (gasoline, phosphorus, acids, etc.)

Medications
- Rhinitis medicomentosa (improper/long-term use of nasal decongestants → ischemic mucosa)
- Topical corticosteroids

Environmental
- Rhinitis sicca (dry nose—due to lack of humidity, air conditioning, heated environments)
- Barometric changes (altitude, dysbarism)

Anatomic
- Septal deviation (disrupts local airflow, desiccating adjacent tissues)
- Septal perforation (bleeds from surrounding friable granulation tissue)
- Meningocele, encephalocele, glioma
- Unilateral choanal atresia

SYSTEMIC

Coagulopathies
- Von Willibrand's disease (most common)
- Hemophilia A (Factor VIII deficiency)
- Hemophilia B (Factor IX deficiency)
- Platelet dysfunction (liver disease, ETOH abuse, renal disease)
- Thrombocytopenia (chemotherapy, malignancy, DIC, hypersplenism, ITP, drugs)
- Vitamin K deficiency
- Leukemia

Medications
- Anticoagulants (heparin, warfarin)
- Aspirin, NSAIDs,
- Herbals (Ginko Biloba, vitamin E)
- Clopidogrel, ticlodipine
- Dipyridimole
- SSRIs
- Sildenafil

Granulomatous Disorders
- Syphillis
- Sarcoidosis
- Tuberculosis
- Wegener's granulomatosis

Vascular
- Hypertension
  - Circadian onset (primary peak in the morning 8 a.m., secondary peak in evening at 8 p.m.)
- Atherosclerosis
- Scurvy
- Osler-Weber-Rendu disease (hereditary telangiectasias, affects the GI, GU, respiratory tracts, onset in puberty)

Other
- Pregnancy
- Hemorrhagic fevers (Ebola, Marburg, Dengue)
- Whooping cough
- Measles

nasal septum. The internal maxillary artery divides into multiple branches in the pterygomaxillary fossa. The most important nasal branch, the sphenopalatine artery, supplies the turbinates and meati laterally, and the posterior and inferior septum medially. The internal carotid artery provides blood supply to the nose via the ophthalmic artery, which passes through the superior orbital fissure and divides into several branches, with the most prominent being the anterior and posterior ethmoidal arteries. Both give off branches to the lateral and septal walls. (*See Figure 2.*)

Two venous areas have been described that often are implicated in nasal hemorrhage—Kiesselbach's plexus (anterior nosebleeds) and Woodruff's plexus (posterior nosebleeds). Kiesselbach's plexus, also known as Little's area, is located on the anterior nasal septum. Branches of the sphenopalatine, anterior ethmoidal, and superior labial arteries anastomose at this site. The mucosa over the area is very thin and friable, making it the most common source of nasal bleeding. In the 1940s, Woodruff described another venous plexus located over the posterior mid-

dle turbinate. The area is made up of anastomoses between multiple branches of the internal maxillary artery, the sphenopalatine being most prominent, and the anterior and posterior ethmoidal arteries. Eighty to ninety percent of nosebleeds arise from anterior sites, while a much smaller number arise posteriorly. Both venous and arterial posterior bleeds have been described, whereas anterior bleeds tend to be only venous. Due to their relatively inaccessible anatomic location, posterior bleeds are more difficult to visualize and treat, making them more life-threatening. Anterior bleeding is more accessible, easier to treat, and therefore less dangerous.

Etiology/Differential Diagnosis

The etiology of epistaxis is multiple, with most causes falling into one of three broad categories—local, systemic, or idiopathic. (*See Table 1.*) The three most common precipitants are trauma, infection, and inflammation. While most causes of nosebleed are self-explanatory, some merit special discussion, either due to their complexity or to a lack of consensus in the literature.

Idiopathic. *Trauma.* Causes of traumatic nosebleed range from simple anterior mucosal bleeds from over-digitalization to life-threatening posterior bleeds from pseudoaneurysm formation. Nose-picking is exceedingly common, particularly among children.[10] The septum may become ulcerated from repetitive digging. Alternatively, venules and capillaries may be lacerated by a fingernail. Facial trauma can result in epistaxis. Usually the bleeding is from minor mucosal tears and is self-limited. Occasionally, larger veins and arteries tear and packing is required. A rare but deadly cause of delayed posterior bleeding after trauma is the rupture of an internal carotid pseudoaneurysm. One clue to its presence is coexisting cranial nerve deficits. Though a "classic triad" of unilateral blindness, orbital fractures, and massive epistaxis has been described, it occurs in fewer than half of these patients.[11] Onset of epistaxis can range from days to years after trauma, although the majority occur within the first 2 months. The treatment is emergent embolization.

Infection/Inflammation. A variety of infectious and inflammatory disorders result in mucosal hyperemia and may contribute to nasal bleeding. Viral, bacterial, fungal, and allergic rhinosinusitis all irritate the mucosa. Epistaxis in these cases usually is limited to blood-streaked nasal discharge, but may be more severe. An increase in the prevalence of upper respiratory tract infections in part accounts for the increased incidence of epistaxis in winter months in temperate climates.

Blood Dyscrasias. While most cases of epistaxis are not indicative of serious underlying disease states, one must always consider the possibility of a coagulopathy. Nosebleed, particularly when recurrent or severe, may be the heralding sign of a congenital or acquired clotting disorder. Coagulopathies should be suspected when there is a history of easy bruising, prolonged bleeding from minor trauma, gingival bleeding, hemarthrosis, or a positive family history. One-third of pediatric patients with recurrent epistaxis have a diagnosable coagulopathy.[12] The increase in incidence of nosebleed in the elderly population is partly attributable to their frequent use of anticoagulants (warfarin and heparin) and antiplatelets (aspirin and NSAIDs). Almost 20% of patients admitted for epistaxis are on warfarin,[8] and one-third of those have a supratherapeutic INR.[13] Aspirin has been shown in multiple studies to predispose to epistaxis; however, the relationship between NSAID use and nosebleed is more controversial.[14,15] Aspirin is more potent than most other NSAIDs, with a half life of 5-7 days, compared to only one day for the majority of NSAIDs. Reducing the dosage of aspirin from 325 mg to 81 mg per day may help prevent epistaxis. Low-dose aspirin has been shown to be equally effective in the prevention of cardiovascular and intracerebral events.

Hereditary Hemorrhagic Telangiectasia (HHT). Also known as Osler-Weber-Rendu disease, HHT deserves special mention because it is particularly difficult to control. The disease is an autosomal dominant condition associated with multiple AV malformations and telangiectasias in the respiratory, gastrointestinal (GI), central nervous system (CNS), and genitourinary (GU) tracts. Most often these patients succumb to massive GI hemorrhage. Nonetheless, epistaxis remains a common complaint and a nuisance to these patients. Nasal hemorrhage occurs after minor trauma and does not stop spontaneously due to a lack of elastic tissue in the vessel wall. Bleeds are almost universally recurrent.

Hypertension. The association between epistaxis and hypertension has long been disputed. Several population-based studies have failed to show an association between hypertension and nasal bleeding.[16-18] These studies, however, address the question "Is epistaxis more common in patients with hypertension?" Karras, et al. looked at an ED population with elevated blood pressures on presentation and questioned the patients regarding recent blood pressure associated symptoms, including epistaxis.[19] They found no correlation between elevated ED blood pressures and recent epistaxis. Both the population-based studies and the ED-based study by Karras are subjected to significant recall bias. They also fail to answer the pertinent questions for the ED physician—namely, do patients presenting with epistaxis have higher blood pressures than patients without epistaxis and, more importantly, does lowering blood pressure acutely improve success at controlling nasal hemorrhage? A study in 2001 showed that patients presenting with active epistaxis had higher blood pressures compared to controls. Patients with active nasal hemorrhage also were more likely to have a history of hypertension.[20] A study by Jackson and Jackson suggested that hypertension does contribute to refractory bleeding by showing it to be the most common comorbidity in difficult to control scenarios.[21] Pathophysiologically, lowering blood pressure, taking away the vascular pressure head, and allowing more time for clot to form would seem to make good sense. This may be particularly true in subgroups of patients such as the elderly and those with posterior bleeds. Further research is needed before this debate will be put to rest.

Figure 3. ENT Tray

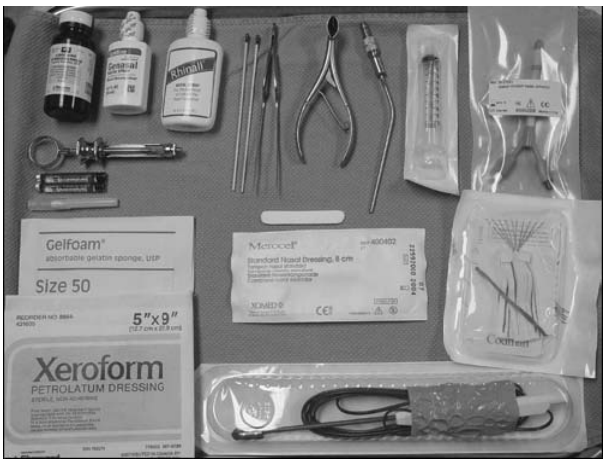

Reprinted with permission from: Kucik CJ, Clenney T. Management of epistaxis. *Am Fam Physician* 2005;71:307.

Table 2. Suggested ENT Tray Contents

- Head light/light source and mirror
- Bayonet forceps
- Nasal speculum
- Frazier suction tip
- Silver nitrate sticks
- Cotton balls
- 4" x 4" gauze sponges
- Hydrophilic nasal tampons
- Petroleum-coated packing
- Intranasal balloon (e.g., Epistat, Nasostat)
- 10-mL syringe
- Foley catheter, #16 with 30 cc balloon
- Umbilical or Hoffman clamp
- 0 silk suture
- Absorbable gelatin sponge or other hemostatic agent
- Triple-antibiotic ointment
- Vasoconstrictor and anesthetic solutions

Table 3. Topical Anesthetic Agents

- Cocaine 4% topical solution
- Phenylephrine (Neo-synephrine) 0.5-1% concentration
- Oxymetazoline (Afrin) 0.5% concentration
- Epinephrine 0.25 mL of 1:1,000 concentration mixed with 20 mL of 4% lidocaine

History and Physical Examination

The history should focus on the initial presentation of bleeding. What activity was the patient engaged in at onset? Which side did the bleed start on—does it remain unilateral or bilateral? How long has the bleeding been going on? What measures have been taken to attempt to stop the bleeding? Is there bleeding into the oropharynx? Did it begin anteriorly, and then begin to drip into the oropharynx or did it initiate with bleeding down the throat? (This may help to differentiate an anterior from a posterior bleed, respectively.) What precipitating events surrounded the bleed (humidity, heat, air conditioning, URIs, allergies, etc.)? On review of systems, does the patient describe any petechiae, purpura, easy bruising, or prolonged bleeding from minor trauma? In terms of past medical history, does the patient have a history of epistaxis? What therapy was required to treat prior episodes? How many have there been? Is there co-morbid cardiovascular, cerebral, or pulmonary disease? Is there a history of precedent trauma or head and neck surgery? Are there any known bleeding disorders? Is there a family history of bleeding disorders? Does the patient smoke (cigarettes or marijuana,) drink heavily, or snort cocaine? Does the patient take any medications known to contribute to epistaxis? (*See Table 1.*)

The initial physical assessment must begin with the ABCs (airway, breathing, and circulation). Encourage the patient to spit out blood to reduce the chance of emesis and aspiration. Check the vital signs, including a pulse oximetry reading, and observe the patient's overall color and peripheral perfusion for signs of severe hemorrhage. Look into the oropharynx to assess how much blood is being lost posteriorly. When preparing for the nasal examination, it is best to have the patient upright in a sitting position with the neck slightly flexed. Have all the equipment prepared in advance. Observe universal precautions (gown, gloves, protective eyewear.) Cover the patient with a protective sheet and provide an emesis basin. Optimal visualization of the nares requires use of a nasal speculum, a narrow beam head lamp, and a suction device. An ENT tray containing any necessary therapeutic devices should be at the bedside. (*See Figure 3 and Table 2 for suggested contents.*) Have the patient blow out all remaining clots. Spray each nostril with 4-6 sprays of 0.05% oxymetazoline or an alternative vasoconstrictor. Numb the nasal mucosa with pledgets soaked in additional oxymetazoline and 4% viscous lidocaine. Once the nose has been vasoconstricted and anesthetized, insert the nasal speculum and orient the blades of the speculum in a 1 o'clock to 7 o'clock direction. This allows optimal visualization of most anterior bleeding sites. Depending on operator skill and facility resources, the physician also may perform nasal endoscopy.

Diagnostic Studies

Laboratory and imaging studies are not indicated for the majority of cases of epistaxis. Indications for obtaining laboratory studies include recurrent, prolonged, severe, or refractory bleeding; diffuse oozing or multiple bleeding sites; a personal or family history of symptoms suggesting a coagulopathy; or the use of anticoagulants.[13,22] In these cases, a complete blood count (CBC) and prothrombin time (PT)/activated partial thromboplastin time (PTT) should be ordered at a minimum. Depending on the scenario and in consultation with specialty services, a bleeding time and more specific coagulation studies may be in order. These studies are generally not ordered from the ED as they will not acutely alter patient management. Elec-

Figure 4. Stepwise Approach to Management of Epistaxis in the ED

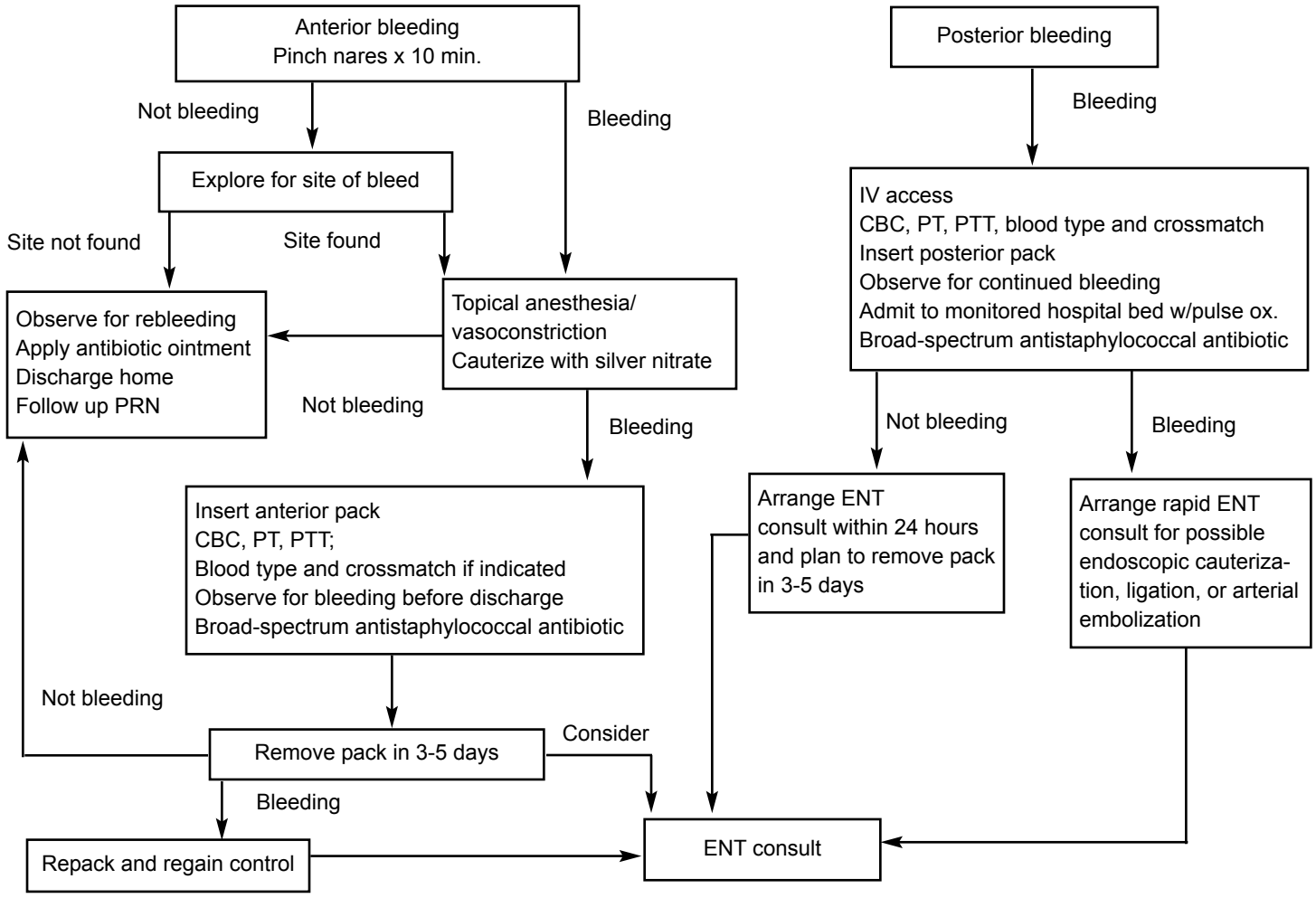

trolytes and liver function tests may also be indicated if the history or physical examination indicates possible dysfunction. A type and screen or crossmatch may be indicated if the blood loss is severe.[23,24]

On rare occasions, imaging studies will be useful. For the ED physician, facial CT may be needed to define the extent of facial fractures and basilar skull trauma. Elective CT or MRI may be performed in patients suspected of having a neoplasm, to define the extent of rhinosinusitis, or to define pre-operative surgical anatomy. Angiography may be indicated in rare cases to localize the site of bleeding or to define anatomy prior to embolization. Angiography is the diagnostic modality of choice for suspected post-traumatic pseudoaneurysm.

Management Overview

The majority of patients presenting with nasal hemorrhage can be treated in the ED by emergency physicians, with only the occasional need to call in specialty consultants. The management of acute epistaxis follows a stepwise approach, beginning with firm pressure on the alae, application of topical vasoconstrictors, and anterior packing with some form of gauze or nasal tampon. Basic interventions control the bleeding 80-90% of the time. Failing these maneuvers, management then progresses to more advanced techniques using compressive balloons and posterior packing. In rare cases, arterial ligation or embolization by ENT specialists is required. (*See Figure 4 for an overview of the stepwise management of epistaxis.*)

Keep in mind that rebleeding is common and that a short period of ED observation (1-2 hours) once bleeding has been controlled is prudent. Most patients with epistaxis can be discharged and managed on an outpatient basis. Hospital admission and close observation are recommended for all patients with posterior bleeding, and should be considered for elderly patients and those with coagulopathies or anemia. Admission also is indicated for patients with complicating comorbid conditions, particularly coronary artery disease, severe hypertension, and chronic obstructive pulmonary disease (COPD).[25]

Immediate Stabilization

Upon arrival in the ED, instruct the alert/cooperative patient to firmly grasp their nostrils, maintaining continuous pressure for at least 10 minutes without release. Tilt the head forward to prevent blood from pooling in the posterior pharynx. This

Figure 5. Traditional Anterior Packing

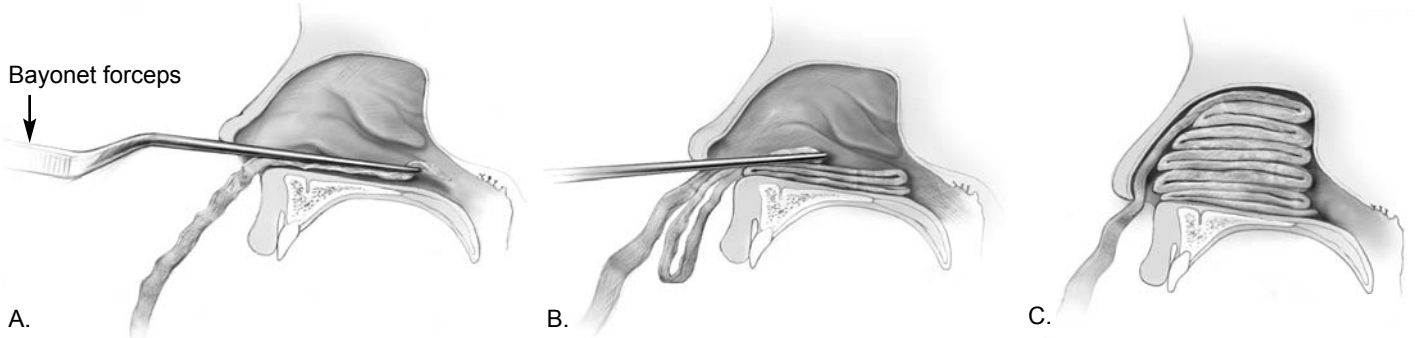

Packing of the anterior nasal cavity using gauze strip impregnated with petroleum jelly. A. Gauze is gripped with bayonet forceps and inserted into the anterior nasal cavity. B. With a nasal speculum (not shown) used for exposure, the first packing layer is inserted along the floor of the anterior nasal cavity. Forceps and speculum then are withdrawn. C. Additional layers of packing are added in an accordion-fold fashion, with the nasal speculum used to hold the positioned layers down while a new layer is inserted. Packing is continued until the anterior nasal cavity is filled.
Reprinted with permission from: Kucik CJ, Clenney T. Management of epistaxis. *Am Fam Physician* 2005;71:310. Copyright AAFP.
Illustrations used with permission from: Cindy Krames, certified medical illustrator.

decreases nausea due to swallowed blood and helps avert potential airway obstruction from clots. Next, rapidly review the ABCs. Assess airway patency, oxygenation status, and hemodynamic stability. Place the patient on a monitor. Severe cases of epistaxis may require endotracheal intubation for airway protection. If volume depletion is suspected based on history, physical examination, or vital signs, begin fluid resuscitation with crystalloids, and send laboratory studies per discussion above. Transfuse packed red blood cells for anemia, platelets for thrombocytopenia, and fresh frozen plasma (FFP) or specific coagulation factors as indicated by laboratory studies. Patients on warfarin with a supratherapeutic INR should receive FFP to return the INR to a therapeutic range. Complete reversal is rarely indicated.[8]

Many patients present with marked elevations in systolic and diastolic blood pressures. The need for and timing of interventions for hypertension still are debated.[16-21] Administration of oral or intravenous analgesics and antianxiety agents is appropriate at this stage and often adequately controls pressures. Only rarely are specific antihypertensives required, and only anecdotal evidence supports the practice and the choice of agent. Patients who receive antihypertensive medications generally should be monitored for a longer period in the ED and referred for close follow-up if discharged.

Based on the initial history and physical exam, the clinician must determine if the bleeding is anterior or posterior. From there the treatment proceeds in a stepwise fashion from simple to more advanced techniques.

Treatment of Anterior Nasal Hemorrhage

Some patients respond to the application of direct pressure alone. Once the bleeding has stopped, explore the nares for the bleeding site. If a specific origin of hemorrhage is not found, apply antibiotic ointment diffusely to the nasal septum and discharge home with follow up as needed. If the site of bleeding can be identified, apply a topical anesthetic, vasoconstrictor, and cauterize the site with silver nitrate as described below.

If the bleeding does not stop with direct pressure alone, have the patient blow out any clots, and insert cotton pledgets soaked with an anesthetic and vasoconstrictor solution into the nasal cavity to numb and shrink the nasal mucosa. Four percent topical lidocaine may be mixed with any of a number of vasoconstrictors. (*See Table 3 for a list of agents.*) Caution should be utilized not to exceed the maximum dose of lidocaine (4 mg/kg). Allow the pledgets to remain in place for 10-15 minutes. Generally, systemic analgesia is not necessary when inspecting or packing the nose. Once adequate local anesthesia is achieved, the nasal cavity can be examined and treatment initiated to stem the hemorrhage.

Upon removal of the pledgets, the nose should be blown again to remove any residual clots. Carefully inspect Kiesselbach's plexus for bleeding. (*See Figure 2.*) A vessel that has stopped bleeding appears as a small red dot (less than 1 mm). The clot sits on the most external part of the blood vessel, which protrudes through the thin mucosa. With the bleeding point identified, chemical cautery may be attempted using a silver nitrate stick applied directly to the bleeding site.[26] The tip of the silver nitrate stick is rolled over the nasal mucosa until a grey eschar forms, usually within 3-5 seconds. To avoid septal necrosis or perforation, only one side of the septum should be cauterized at a time.

Larger vessels generally respond more readily to electrocautery. Electrocautery must be performed cautiously, however, to avoid excessive destruction of healthy tissues and to avoid the risk of septal perforation. Cauterizing an actively bleeding site is difficult with either chemical or electrocautery, and cauterization is best reserved for bleeding that stops after pressure, anesthetic, and vasoconstrictor application. If cautery is attempted to stem

Figure 6. Examples of Anterior-Posterior Combination Balloon Devices

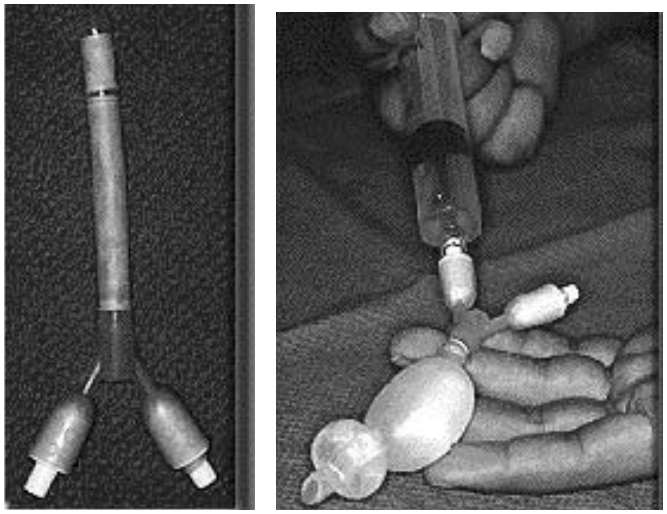

flow in an actively bleeding vessel, the recommended approach is to start proximally and move distally. One recent study showed no difference in efficacy or outcomes comparing electrocautery to chemical cautery.[27]

Other treatment options for anterior bleeds include hemostatic packing with absorbable gelatin foam (Gelfoam) or oxidized cellulose (Surgicel). Use of desmopressin spray (DDAVP) may be considered in a patient with a known bleeding disorder.[26,28]

If these treatments fail to stop anterior bleeding, an anterior pack should be placed. Traditional packing agents include layered ribbon gauze impregnated with petroleum jelly or polymyxin B-bacitracin zinc-neomycin (Neosporin) ointment or nonadherent gauze containing petroleum jelly and 3% bismuth tribromophenate (Xeroform).[23,26] After adequate topical anesthesia and vasoconstriction has been achieved, grasp the ribbon gauze about 6 inches from its end with bayonet forceps. Place it in the nasal cavity as far back as possible, ensuring that the free end protrudes from the nose. On the first pass, the gauze is pressed onto the floor of nasopharynx with closed bayonets. The ribbon is then grasped about 4-5 inches from the nasal alae and repositioned in the nasal speculum so that the lower blade holds the ribbon against the lower border of the nasal alae. Bring a second strip into the posterior nasal cavity and press downward. Continue this process, layering the gauze until the nose is completely packed. (*See Figure 5.*) Secure the end of ribbon that protrudes from the nose with tape. If this does not stop the bleeding, consider bilateral nasal packing.

Nasal tampons and epistaxis balloons largely have replaced traditional gauze packing due to their superior ease and speed of placement. Examples of nasal tampons include Merocel or Doyle sponges. Merocel is made of polyvinyl alcohol, a compressed foam polymer. Apply lubricant jelly or antibiotic ointment (Neosporin, Bacitracin) to the tampon prior to insertion. After insertion, wet it with a small amount of a topical vasoconstrictor followed by saline to achieve full expansion of the tampon. This causes pressure over the bleeding point, allowing clotting factors to coalesce and reach a critical level, facilitating coagulation. Nasal tampons are effective in 85% of cases, with no difference between the success rates or patient comfort compared to traditional ribbon gauze.[27,29] Once inserted, the nasal tampon or packing must be left in place for 3-5 days to ensure formation of an adequate stable clot.[24]

Anterior epistaxis balloons come in different lengths but have only one chamber. Rapid Rhino is an example of a coated balloon. Its exterior is wrapped with carboxymethylcellulose (a hydrocolloid material), which acts as a platelet aggregator and also forms a lubricant on contact with water.[30] Unlike Merocel, it has a cuff that is inflated with air and the hydrocolloid or Gel-Knit is supposed to preserve newly formed clot during removal. If only a standard balloon is available, cover it with antibiotic ointment prior to insertion. Pass the balloon along the floor of the nasal cavity, and inflate it slowly with sterile water or air (per the manufacturer's recommendations) until the bleeding stops. Be careful not to over inflate because pressure necrosis or damage to the septum may result. Record the amount of fluid placed in the balloon. Systemic analgesics may be required for the time the balloon remains inserted.

Due to the very real possibility of toxic shock syndrome with prolonged nasal packing, use of a topical antistaphylococcal antibiotic ointment on the packing materials has been recommended. Coating the packing with triple antibiotic ointment has been shown to decrease the nasal bacteria count, as well as the number of episodes of bacteremia.[24,26,31] In addition, patients with nasal packing must be given systemic antistaphylococcal antibiotics for the duration of the packing period, usually 3-5 days.[26,31] Patients should be instructed to keep the packs moist with sterile saline or oxymetazoline spray twice daily. A subsequent referral to an otolaryngologist for pack removal and a complete endoscopic examination is prudent.

Another recent treatment development for anterior bleeds has been the use of fibrin glue (Floseal, Quixil) developed from human plasma cryoprecipitate, which binds itself to damaged vessels. A thin layer of glue is sprayed over the bleeding site and can be repeated as needed. A recent randomized trial reported that complications of local swelling, nasal mucosal atrophy, and excessive nasal discharge were lower than with electrocautery, silver nitrate, or nasal packing. The rebleed rate was 15%, which is comparable to electrocautery.[32] Several studies using various types of fibrin glue or hemostatic sealants have shown great promise.[31-33] Compared to foam, nasal packing, and/or cautery, these agents were better tolerated, more effective, easier to use, and controlled bleeding more readily, even in patients with a coagulopathy.

Patients with anterior bleeding that continues despite the best efforts of the emergency physician will require treatment by an otolaryngologist. The specialist may employ nasal endoscopy or angiography (see discussion in next section) to locate the exact site of bleeding.

Treatment of Posterior Nasal Hemorrhage

Posterior bleeding is much less common than anterior bleed-

Figure 7. Treatment of Posterior Epistaxis

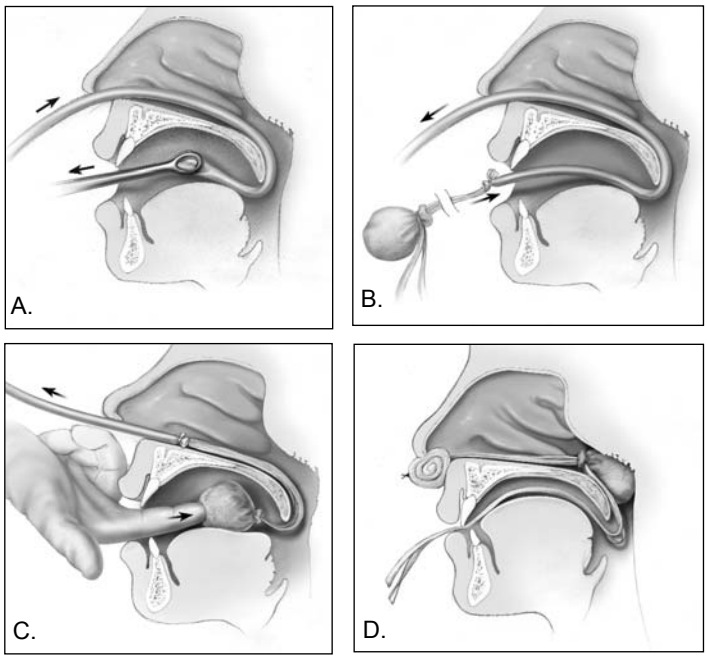

A. After adequate anesthesia has been obtained, a catheter is passed through the affected nostril and through the nasopharynx, and drawn ouf of the mouth with the aid of ring forceps. B. A gauze pack is secured to the end of the catheter using umbilical tap or suture material, with long tails left to protrude from the mouth. C. The gauze pack is guided through the mouth and around the soft palate using a combination of careful traction on the catheter and pushing with a gloved finger. This is the most uncomfortable (and most dangerous) part of the procedure; it should be completed smoothly and with the aid of a bite block (not shown) to protect the physician's finger. D. The gauze pack shoudl come to rest in the posterior nasal cavity. It is secured in position by maintaing tension on the catheter with a padded clamp or firm gauze roll placed anterior to the nostril. The ties protruding from the mouth, which will be used to remove the pack, are taped to the patient's cheek.
Reprinted with permission from: Kucik CJ, Clenney T. Management of epistaxis. *Am Fam Physician* 2005;71:310. Copyright AAFP.
Illustrations used with permission from: Cindy Krames, certified medical illustrator.

ing,[35] occurring in only 10% of cases, and usually requires treatment by an otolaryngologist. Blood loss is more severe, and the bleeding site is not visualized with a traditional nasal speculum examination.

All patients with posterior epistaxis require IV access and laboratory evaluations. A posterior pack may be inserted by either the emergency physician or ENT specialist. Posterior packing involves the use of balloon devices, Foley catheters, or other tamponading material. Various balloon systems are effective for managing posterior bleeding and are less complicated than the packing procedure. Commercially available devices such as Epi-statsTM, Storz Epistaxis Catheter, or Xomed Treace Nasal Post Pac provide a double-balloon system that serves as both an anterior and a posterior pack. (*See Figure 6.*) Advantages of inflatable balloon packs are that they are more easily inserted, less traumatic to the patient, and most allow a partial nasal airway through a central canal. Disadvantages include the fact that they are less effective than standard packs (due to uneven pressure distribution), some balloons are inflated with water while others inflate with air (inflation with the wrong agent can lead to balloon failure), and they may cause an upper airway obstruction.[36]

If a specialized balloon device is not available, a Foley catheter (10 to 16 French) with a 30-mL balloon may be used. The catheter is inserted through the bleeding nostril until the balloon can be visualized in the oropharynx before inflating.[37] Fill with 10-15 mL of saline, and withdraw the catheter gently through the nostril, pulling the balloon up and forward until it rests firmly against the posterior choanae.[26] (*See Figure 7.*) While maintaining traction on the catheter, pack the anterior nasal cavity as previously described. Place an umbilical or Hoffman clamp on the catheter beyond the nostrils to secure the Foley and pad around the clamp to prevent alar necrosis. Balloon packs generally are left in place for 2-5 days. As with anterior packing, tissue necrosis can occur if a posterior pack is inserted improperly or balloons are overinflated. Topical antistaphylococcal antibiotic ointment and systemic antibiotics are used to prevent sinus infections and toxic shock syndrome.[26,38] Additionally, periodic deflation of balloon devices may be needed to prevent tissue necrosis.

All patients requiring a posterior pack must be admitted to the hospital. Older patients, children, and those with comorbidities should be admitted to telemetry or an ICU for cardiopulmonary monitoring. Several newer balloon tamponade devices have internal airways that allow airflow through the nasal cavity despite packing. Additional studies are needed to determine if these newer devices have a lower complication rate compared to standard posterior packs.

Complications of nasal packing procedures include:

- Failure to stem bleeding;
- Toxic shock syndrome;
- Blockage of :
  - –nasolacrimal duct leading to epiphora;
  - –sinus drainage leading to acute sinusitis;
  - –nasal airway leading to hypoxia;
- Nasovagal reflex, which occurs during insertion of a pack or instrumentation of the nasal cavity. It leads to vagal stimulation, with consequent hypotension and bradycardia;
- Sleep apnea, attributable to decreased nasal air entry leading to hypoxia during somnolence;
- Displacement of pack into the oropharynx with risk of acute airway obstruction;
- Pain or discomfort; and
- Pressure necrosis secondary to excessively tight packing.

When posterior bleeding is present, the general location of the source needs to be determined. This step is important because different arteries supply the floor and roof of the posterior nasal

cavity. If packing fails to control hemorrhage, the condition should be considered life-threatening and urgent ENT consultation is vital. Selective arterial ligation of the carotid system or surgery may be necessary.[26,39]

Management of Persistent Bleeding

Recent articles debate the cost implications, success rate, and complication rate of surgical intervention as the first-line treatment for posterior epistaxis compared to traditional anterior-posterior packing and admission to an ENT ward.[40,41] Embolization and arterial ligation were found to be associated with higher hospital charges; however, complications, transfusion rates, and lengths of stay were similar.[42]

Arterial Ligations. *Sphenopalatine artery ligation* is performed in cases of ongoing hemorrhage despite the above methods. The procedure is performed under direct rigid endoscopy and the vessel is either clipped or coagulated using bipolar diathermy. Success rates are reported to be better than other forms of arterial ligation, probably because it is an end artery with little collateral flow.[43]

Anterior/posterior ethmoidal artery ligation is occasionally required for severe bleeding from the ethmoidal region and is traditionally performed via an external ethmoidectomy incision, through a subperiosteal plane on the medial orbital wall. An endoscopic technique has been described[44] and also, more recently, an endoscopically assisted external approach.[45]

Maxillary artery ligation is rarely performed now since the introduction of endoscopic nasal surgery, but it has been shown to be effective in 87% of cases.[46] The approach is a modified Caldwell-Luc operation through the posterior wall of the maxillary sinus into the pterygopalatine fossa. The maxillary vessel can be either clipped or diathermied. Complications of this include devitalised gums and teeth, sinusitis, and problematic intraoperative bleeding.

External carotid artery ligation is reserved for intractable epistaxis. This extreme measure is a non-specific method of decreasing blood flow to the nose. Studies have shown a long-term failure rate of 45% because the nasal blood supply has marked watershed areas supplied by the contralateral external carotid.[47] In general, external carotid artery ligation is considered a last resort useful only in profound uncontrolled hemorrhage when the previously discussed methods fail.

Septal surgery is an alternative to arterial ligation. The procedure allows access to the nasal cavity. As most hemorrhages occur from the septum, raising a mucoperichondral flap during septal surgery will decrease blood flow to the mucosa, which often stems bleeding. Surgery also is used to correct a deviated septum or remove a septal spur, which may be the cause of recurrent epistaxis.

Angiographic embolization for acute epistaxis was first performed by Sokoloff in 1972.[48] This technique entails cannulation of the external carotid artery and location of the bleeding point using contrast dye. Coils, gel foam, or polyvinyl alcohol are then employed to embolize the offending artery. The success rate has been reported to be as high as 87%, which is similar to arterial ligation.[49] This technique's limiting factors include a lack of specialist radiologists and equipment at most hospitals, the inability to embolize ethmoidal arteries due to the risk of blindness, false aneurysm development at the insertion site, cerebrovascular accidents, and imaging difficulties after nasal packing. Studies have reported a complication rate of 17%-27%.[50]

Endoscopic Electrocautery. The invention of the Hopkins rod in the 1960s revolutionized nasal surgery. Only recently has this new technology been adapted for the treatment of epistaxis.[51-53] The nose is prepared as described previously. Examination of the nasal cavity is performed using a rigid Hopkin's rod endoscope. Clots are removed using suction, which also will elicit the bleeding point. On location of the bleeding point, electrocautery is used to seal the vessel. The authors recommend a bipolar cautery device with an integrated suction tip to improve the field of view and increase efficiency of the cautery. Nasal packing is used if the bleeding fails to cease after the procedure or if the bleeding point cannot be identified. If no re-bleeding occurs after two hours of observation, the patient can be discharged home. A recent study showed that this procedure was successful in treating 89% of patients with epistaxis, and 74% were able to be safely discharged home.[53] This reduction in the need for admission, added to the benefits of not inserting a pack, makes it a useful and cost-effective procedure.

Hot Water Irrigation. Hot water irrigation, a technique described more than 100 years ago, has been reexamined recently. This technique has shown promise in reducing discomfort and length of hospitalization in patients with posterior epistaxis.[54,55] Techniques vary, but essentially a balloon catheter is used to close off the posterior choana, and water at 45–50°C is inserted into the nasal cavity. As well as helping to clear blood clots from the nose, it reduces local blood flow by causing mucosal edema.[56]

Laser therapy has proven to be particularly useful in cases of recurrent epistaxis, such as those occurring in hereditary hemorrhagic telangiectasia (Osler-Weber-Rendu disease). A neodymium yttrium-aluminum-garnet (Nd:YAG) laser commonly is used (via endoscopy), although the application of other lasers such as argon or carbon dioxide also has been described.[57]

Medical/Legal Considerations

• Attempts at nasal packing may result in slowing but not cessation of hemorrhage. Failure to adequately control hemorrhage is an indication for consultation with an ENT specialist in the ED.

• Both anterior and posterior nasal packing can lead to serious infection. Patients should be started on appropriate antistaphylococcal antibiotics.

• Avoid cauterizing both sides of the septum at the same time because of the risk for septal perforation.

• Epistaxis management in general is simple and straightforward. On occasion, however, a nosebleed may be the heralding

sign of a serious underlying pathology (i.e., coagulopathies, neoplasms), especially in children and elderly patients. Therefore, consider sending all patients who present with anything more than minor epistaxis for follow-up care with an ENT specialist for a complete nasopharyngeal examination.

• Posterior nasal packing is quite uncomfortable for the patient and promotes hypoxia and hypoventilation. Failure to admit and appropriately monitor all patients who require a posterior pack may result in significant morbidity and mortality.

Conclusion

Nosebleeds are very common, with the majority occurring in the elderly adult population. Epistaxis increases in prevalence in the dry months and commonly is associated with mucosal inflammation or infection. The majority of anterior bleeds are venous, with most originating from Kiesselbach's plexus. Posterior bleeds may be venous or arterial. They generally are more severe and refractory to treatment.

The history and physical examination should be used to determine the source of bleeding and the presence of any indications for laboratory studies, particularly those suggestive of a coagulopathy. The patient should blow out all clots and be prepared for rhinoscopy using topical vasoconstrictors and anesthetic. A stepwise approach to the management of epistaxis is prudent. The majority of nosebleeds can be controlled with direct pressure alone. Cautery, packing with gauze, balloons, or nasal tampons, and the use of topical coagulants or fibrin glue are all excellent methods for controlling anterior nasal hemorrhage. Refractory bleeding and most posterior bleeds require the involvement of an ENT specialist. Vessel ligation or embolization may be required.

All patients with nasal packing, either anterior or posterior, should be placed on systemic antibiotics. The pack should be removed in 3-5 days. Patients taking anticoagulants should be carefully monitored to maintain a therapeutic range. Hypertension may co-exist at the time of epistaxis presentation. Significant blood pressure reduction usually can be obtained with analgesia and mild sedation without resorting to antihypertensive medications. All posterior bleeds should be admitted to a monitored setting, as should those with significant blood loss, or comorbid conditions and an anterior pack. Patients with controlled anterior bleeds should be referred to ENT on an outpatient basis.

References

1. Bonnemain B. Helix and drugs: Snails for Western health care from antiquity to the present. *Evid Based Complement Alternat Med* 2005;2:25-28.
2. Juselius H. Epistaxis. A clinical study of 1,724 patients. *J Laryngol Otol* 1974;88:317.
3. Pallin DJ, Chng YM, McKay MP, et al. Epidemiology of epistaxis in US emergency departments, 1992 to 2001. *Ann Emerg Med* 2005;46:77-81.
4. Ofakor BC. Epistaxis: A clinical study of 540 cases. *Ear Nose Throat J* 1984;63:153.
5. Pollice PA, Yoder MG. Epistaxis: A retrospective review of hospitalized patients. *Otolaryngol Head Neck Surg* 1997; 117:49-53.
6. Danielides V, Kontogiannis N, Bartzokas A, et al. The influence of meteorological factors on the frequency of epistaxis. *Clin Otolaryngol Allied Sci* 2002;27:84-88.
7. Tomkinson A, Roblin DG, Flanagan P, et al. Patterns of hospital attendance with epistaxis. *Rhinology* 1997;35:129.
8. Srinivasan V, Patel H, John DG, et al. Warfarin and epistaxis: Should warfarin always be discontinued? *Clinical Otolaryngology* 1997;22:542-544.
9. Somnath S, Sudipta C, Mondal PK, et al. Emergency otorhinolarygolocal cases in medical college, Kolkata-A statistical analysis. *IJOHNS* 2005;57:219-225.
10. Guarisco JL, Graham HD 3rd. Epistaxis in children: Causes, daignosis, and treatment. *Ea, Nose Throat J* 1989;68: 528-530.
11. Chen D, Concus AP, Halbach VV, et al. Epistaxis originating from traumatic pseudoaneurysm of the internal carotid artery: Diagnosis and endovascular therapy. *Laryngoscope* 1998;108:326-331.
12. Sandoval C, Dong S, Visintainer P, et al. Clinical and laboratory features of 178 children with recurrent epistaxis. *J Pediatr Hematol Oncol* 2002;24:47-49.
13. Thaha MA, Nilssen ELK, Holland S, et al. Routine coagulation screening in the management of emergency epistaxis—is it necessary? *J Laryngol Otol* 2000;114:38-40.
14. Tay HL, McMahon AD, Evans JMM, et al. Aspirin, nonsteroidal anti-inflammatory drugs, and epistaxis—A regional record linked case control study. *Ann Otol Rhinol Laryngol* 1998;107:671-674.
15. Watson MG, Shenoi PM. Drug induced epistaxis? *J R Soc Med* 1990;83:162-164.
16. Weiss NS. Relation of high blood pressure to headache, epitaxis, and selected other symptoms. The United States Health Examination Survey of Adults. *N Engl J Med* 1972;287: 631-633.
17. Beran M, Petrusno B. Occurrence of epistaxis in habitual nose-bleeders and analysis of some etiological factors. *ORL J Otorhinolaryngol Relat Spec* 1986;48:297-303.
18. Fuchs FD, Moreira LB, Pires CP, et al. Absence of association between hypertension and epistaxis: A population-based study. *Blood Press* 2003;12:145-148.
19. Karras DJ, Ufberg JW, Harrigan RA, et al. Lack of relationship between hypertension-associated symptoms and blood pressure in hypertensive ED patients. *Am J Emerg Med* 2005;23:106-110.
20. Herkner H, Havel C, Mullner M, et al. Active epistaxis at ED presentation is associated with arterial hypertension. *Am J Emerg Med* 2002;20:92-95.
21. Jackson KR, Jackson RT. Factors associated with active, refractory epistaxis. *Arch Otolarygol Head Neck Surg* 1988; 114;862-865.
22. Jones GL, Browning S, Phillipps J. The value of coagulation

profiles in epistaxis management. *Int J Clin Pract* 2003;57:577.
23. Pond F, Sizeland A. Epistaxis. Strategies for management. *Aust Fam Physician* 2000;29:933-938.
24. Frazee TA, Hauser MS. Nonsurgical management of epistaxis. *J Oral Maxillofac Surg* 2000;58:419-424.
25. Pope LE, Hobbs CG. Epistaxis: An update on current management. *Postgrad Med J* 2005;81:309-314.
26. Tan LK, Calhoun KH. Epistaxis. *Med Clin North Am* 1999; 83:43-56.
27. Pringle MB, Beasley P, Brightwell AP. The use of Merocel nasal packs in the treatment of epistaxis. *J Laryngol Otol* 1996;110:543-546.
28. Lethagen S, Ragnarson Tennvall G. Self-treatment with desmopressin intranasal spray in patients with bleeding disorders: Effect on bleeding symptoms and socioeconomic factors. *Ann Hematol* 1993;66:257-260.
29. Corbridge RJ, Djazaeri B, Hellier WP, et al. A prospective randomized controlled trial comparing the use of Merocel nasal tampons and BIPP in the control of acute epistaxis. *Clin Otolaryngol* 1995;20:305-307.
30. Singer AJ, Blanda M, Cronin K,et al. Comparison of nasal tampons for the treatment of epistaxis in the emergency department: A randomized controlled trial. *Ann Emerg Med* 2005;45:134.
31. Rubin J, Rood S, Myers E, et al. The management of epistaxis. Self instructional package. Alexandria, VA: American Academy of Otolaryngology-Head and Neck Surgery, 1990.
32. Vaiman M, Segal S, Eviatar E. Fibrin glue treatment for epistaxis. *Rhinology* 2002;40:88-91.
33. MethasianRA, Cruz RM. Perspective, randomized, clinical trial of a novel matrix hemostatic sealant in patients with acute anterior epistaxis. *Laryngoscope* (Abstract) 2005; 115:889-902.
34. Walshe P, Harkin C, Murphy S, et al. The use of fibrin glue in refractory coagulopathic epistaxis. *Clin Otolaryngol Allied Sci* 2001;26:284-285.
35. Viducich RA, Blanda MP, Gerson LW. Posterior epistaxis: Clinical features and acute complications. *Ann Emerg Med* 1995;25:592-596.
36. Jiang Y, Acquadro MA. Upper airway obstruction caused by a double-cuffed nasal balloon after extubation. *J Clin Anesth* 2004;16:301-304.
37. Williams M, Onslow J. Airway difficulties associated with severe epistaxis. *Anaesthesia* 1999;54:812-813.
38. Derkay CS, Hirsch BE, Johnson JT, et al. Posterior nasal packing. Are intravenous antibiotics really necessary? *Arch Otolaryngol Head Neck Surg* 1989;115:439-441.
39. Adornato SG. Epistaxis: New approach [Letter]. *Otolaryngol Head Neck Surg* 2000;123:524.
40. Klotz DA, Winkle MR, Richmon J, et al. Surgical management of posterior epistaxis: A changing paradigm. *Laryngoscope* 2002;112:1577-1582.
41. Monte ED, Belmont MJ, Wax MK. Management paradigms for posterior epistaxis: A comparison of costs and complications. *Otolaryngol Head Neck Surg* 1999;121:103-106.
42. Goddard JC, Reiter ER. Inpatient management of epistaxis: Outcomes and cost. *Otolaryngol Head Neck Surg* 2005;132: 707-712.
43. O'Flynn PE, Shadaba A. Management of posterior epistaxis by endoscopic clipping of the sphenopalatine artery. *Clin Otolaryngol* 2000;25:374-377.
44. Woolford TJ, Jones NS. Endoscopic ligation of anterior ethmoidal artery in treatment of epistaxis. *J Laryngol Otol* 2000; 114:858-860.
45. Douglas SA, Gupta D. Endoscopic assisted external approach anterior ethmoidal artery ligation for the management of epistaxis. *J Laryngol Otol* 2003;117:132-133.
46. Strong EB, Bell DA, Johnson LP, et al. Intractable epistaxis: Transantral ligation vs. embolization: Efficacy review and cost analysis. *Otolaryngol Head Neck Surg* 1995;113: 674-678.
47. Spafford P, Durham JS. Epistaxis: Efficacy of arterial ligation and long-term outcome. *J Otolaryngol* 1992;21:252-256.
48. Sokoloff J, Wickbom I, McDonald D, et al. Therapeutic percutaneous embolization in intractable epistaxis. *Radiology* 1974;111:285-287.
49. Vitek J. Idiopathic intractable epistaxis: endovascular therapy. *Radiology* 1991;181:113-116.
50. Tseng EY, Narducci CA, Willing SJ, et al. Angiographic embolization for epistaxis: A review of 114 cases. *Laryngoscope* 1998;108:615-619.
51. Frikart L, Agrifoglio A. Endoscopic treatment of posterior epistaxis. *Rhinology* 1998;36:59-61.
52. McGarry GW. Nasal endoscope in posterior epistaxis: A preliminary evaluation. *J Laryngol Otol* 1991;105:428-431.
53. Ahmed A, Woolford TJ. Endoscopic bipolar diathermy in the management of epistaxis: An effective and cost-efficient treatment. *Clin Otolaryngol* 2003;28:273-275.
54. Stangerup SE, Dommerby H, Lau T. Hot-water irrigation as a treatment of posterior epistaxis. *Rhinology* 1996;34:18-20.
55. Stangerup SE, Dommerby J, Siim C, et al. New modification of hot-water irrigation in the treatment of posterior epistaxis. *Arch Otolaryngol Head Neck Surg* 1999;125: 686-690.
56. Shin EJ, Murr AH. Managing epistaxis. *Curr Opin Otolaryngol Head Neck Surg* 2000;8:37-42.

57. Stankiewicz JA. Nasal endoscopy and control of epistaxis. *Curr Opin Otolaryngol Head Neck Surg* 2004;12:43-45.

Physician CME Questions

61. The age distribution for epistaxis presenting to the ED in the western hemisphere is:
    A. Seen almost exclusively in the young (younger than 10 years of age)
    B. Bimodal with peaks younger than 10 years and those older than 70 years of age
    C. Evenly distributed across all age groups
    D. Unreliable and shows no trending

62. Of patients presenting to the ED with acute epistaxis:
    A. Most are due to trauma.
    B. The vast majority require admission.
    C. The majority can be managed simply with nasal compression or packing.
    D. Many require laboratory testing and prolonged observation.

63. Possible causes of epistaxis include:
    A. nasotracheal intubation.
    B. disseminated intravascular coagulation (DIC).
    C. neoplasms.
    D. anticoagulant use.
    E. all of the above.

64. The most common source of anterior nasal bleeding is:
    A. Woodruff's plexus.
    B. anterior ethmoidal artery.
    C. Kiesselbach's plexus.
    D. sphenopalatine artery.

65. Which of the following is/are recognized complications of nasal packing?
    A. Sinus infection
    B. Aspiration
    C. Pressure necrosis
    D. Nasovagal reflex
    E. All of the above

66. Patients presenting with posterior epistaxis:
    A. are seen more commonly than anterior.
    B. can be safely managed with a nasal balloon as an outpatient.
    C. are usually younger and the site can be easily visualized.
    D. require antibiotics and admission to a monitored setting.
    E. are due to arterial bleeding secondary to a coagulopathy.

67. An alternative management option for epistaxis may include:
    A. angiographic embolization.
    B. hot water irrigation.
    C. endoscopic electrocautery.
    D. fibrin glue.
    E. all of the above.

68. Topical anesthetic agents for use in epistaxis control include:
    A. cocaine 4% topical solution.
    B. phenylephrine 0.5-1% solution.
    C. oxymetazoline 0.5% solution.
    D. epinephrine 1:1,000 concentration.
    E. all of the above.

69. Patients discharged from the ED after nasal packing should:
    A. Remove the packing themselves after 2-3 days.
    B. Have a follow-up ENT appointment for removal in 3-5 days.
    C. Keep the packing dry.
    D. Take nonsteroidals for analgesia.

70. Indications for laboratory testing in patients presenting with epistaxis include:
    A. diffuse oozing.
    B. multiple bleeding sites.
    C. recurrent bleeding.
    D. oral anticoagulants.
    E. all of the above.

CME Answer Key

61. B
62. C
63. E
64. C
65. E
66. D
67. E
68. E
69. B
70. E

In Future Issues:

Pediatric Infections

Emergency Medicine Reports CME Objectives

To help physicians:

- quickly recognize or increase index of suspicion for specific conditions;
- understand the epidemiology, etiology, pathophysiology, and clinical features of the entity discussed;
- apply state-of-the-art diagnostic and therapeutic techniques (including the implications of pharmaceutical therapy discussed) to patients with the particular medical problems discussed;
- understand the differential diagnosis of the entity discussed;
- understand both likely and rare complications that may occur.

CME Instructions

Physicians participate in this continuing medical education program by reading the article, using the provided references for further research, and studying the questions at the end of the article. Participants should select what they believe to be the correct answers, then refer to the list of correct answers to evaluate their knowledge. To clarify confusion surrounding any questions answered incorrectly, please consult the source material. *After completing this activity, you must complete the evaluation form that will be provided at the end of the semester and return it in the reply envelope provided to receive a certificate of completion.* When your evaluation is received, a certificate will be mailed to you.

Emergency Medicine Reports®
The Practical Journal for Emergency Physicians

Management of Epistaxis in the ED

Etiology of Epistaxis

LOCAL

Trauma
- Nasal fracture (lacerated vasculature, damaged mucosa)
- Rhinotillexomania (compulsive nose picking)
- Nasal foreign body (often associated with unilateral purulent discharge)
- Iatrogenic (nasogastric or nasotracheal intubations, head and neck surgeries)
- Carotid aneurysm (rare, deadly; delayed presentation of posterior bleed, associated cranial nerve deficits)

Infectious/Inflammatory
- Allergic rhinitis
- Upper respiratory infections (bacterial, viral, fungal)
- Chronic sinusitis
- Intranasal parasites
- Nasal cellulitis
- Entomophthoromycosis

Neoplasm
- Juvenile nasopharyngeal angiofibroma (pubertal males with triad of posterior bleed, obstruction, and mass)
- Nasal hemangioma
- Papilloma
- Adenoid cystic carcinoma
- Squamous cell carcinoma
- Adenocarcinoma
- Hemangiopericytoma
- Rhabdomyosarcoma
- Esthesioneuroblastoma

Chemical/Irritants
- Cocaine
- Cigarette smoke
- Cannabis
- Ammonia
- Others (gasoline, phosphorus, acids, etc.)

Medications
- Rhinitis medicomentosa (improper/long-term use of nasal decongestants → ischemic mucosa)
- Topical corticosteroids

Environmental
- Rhinitis sicca (dry nose—due to lack of humidity, air conditioning, heated environments)
- Barometric changes (altitude, dysbarism)

Anatomic
- Septal deviation (disrupts local airflow, desiccating adjacent tissues)
- Septal perforation (bleeds from surrounding friable granulation tissue)
- Meningocele, encephalocele, glioma
- Unilateral choanal atresia

SYSTEMIC

Coagulopathies
- Von Willibrand's disease (most common)
- Hemophilia A (Factor VIII deficiency)
- Hemophilia B (Factor IX deficiency)
- Platelet dysfunction (liver disease, ETOH abuse, renal disease)
- Thrombocytopenia (chemotherapy, malignancy, DIC, hypersplenism, ITP, drugs)
- Vitamin K deficiency
- Leukemia

Medications
- Anticoagulants (heparin, warfarin)
- Aspirin, NSAIDs,
- Herbals (Ginko Biloba, vitamin E)
- Clopidogrel, ticlodipine
- Dipyridimole
- SSRIs
- Sildenafil

Granulomatous Disorders
- Syphillis
- Sarcoidosis
- Tuberculosis
- Wegener's granulomatosis

Vascular
- Hypertension
  - Circadian onset (primary peak in the morning 8 a.m., secondary peak in evening at 8 p.m.)
- Atherosclerosis
- Scurvy
- Osler-Weber-Rendu disease (hereditary telangiectasias, affects the GI, GU, respiratory tracts, onset in puberty)

Other
- Pregnancy
- Hemorrhagic fevers (Ebola, Marburg, Dengue)
- Whooping cough
- Measles

Visits to U.S. EDs for Epistaxis by Age, 1992-2001

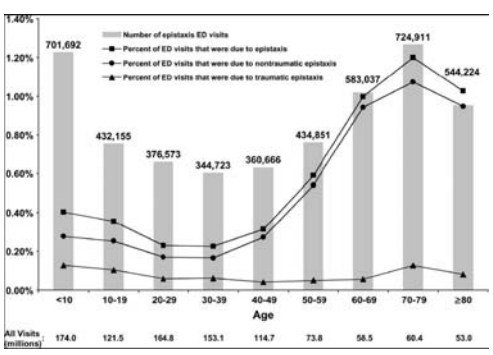

Reprinted with permission from: Pallin DJ, Chng YM, McKay MP, et al. Epidemiology of epistaxis in U.S. emergency departments, 1992 to 2001. *Ann Emerg Med* 2005;46:79.

Blood Supply of the Nasal Septum

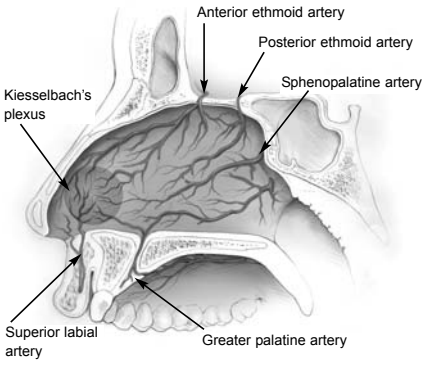

Illustration reprinted with permission from: Christy Krames, certified medical illustrator.

ENT Tray

Reprinted with permission from: Kucik CJ, Clenney T. Management of epistaxis. *Am Fam Physician* 2005;71:307.

Suggested ENT Tray Contents

- Head light/light source and mirror
- Bayonet forceps
- Nasal speculum
- Frazier suction tip
- Silver nitrate sticks
- Cotton balls
- 4" x 4" gauze sponges
- Hydrophilic nasal tampons
- Petroleum-coated packing
- Intranasal balloon (e.g., Epistat, Nasostat)
- 10-mL syringe
- Foley catheter, #16 with 30 cc balloon
- Umbilical or Hoffman clamp
- 0 silk suture
- Absorbable gelatin sponge or other hemostatic agent
- Triple-antibiotic ointment
- Vasoconstrictor and anesthetic solutions

Topical Anesthetic Agents

- Cocaine 4% topical solution
- Phenylephrine (Neo-synephrine) 0.5-1% concentration
- Oxymetazoline (Afrin) 0.5% concentration
- Epinephrine 0.25 mL of 1:1,000 concentration mixed with 20 mL of 4% lidocaine

Stepwise Approach to Management of Epistaxis in the ED

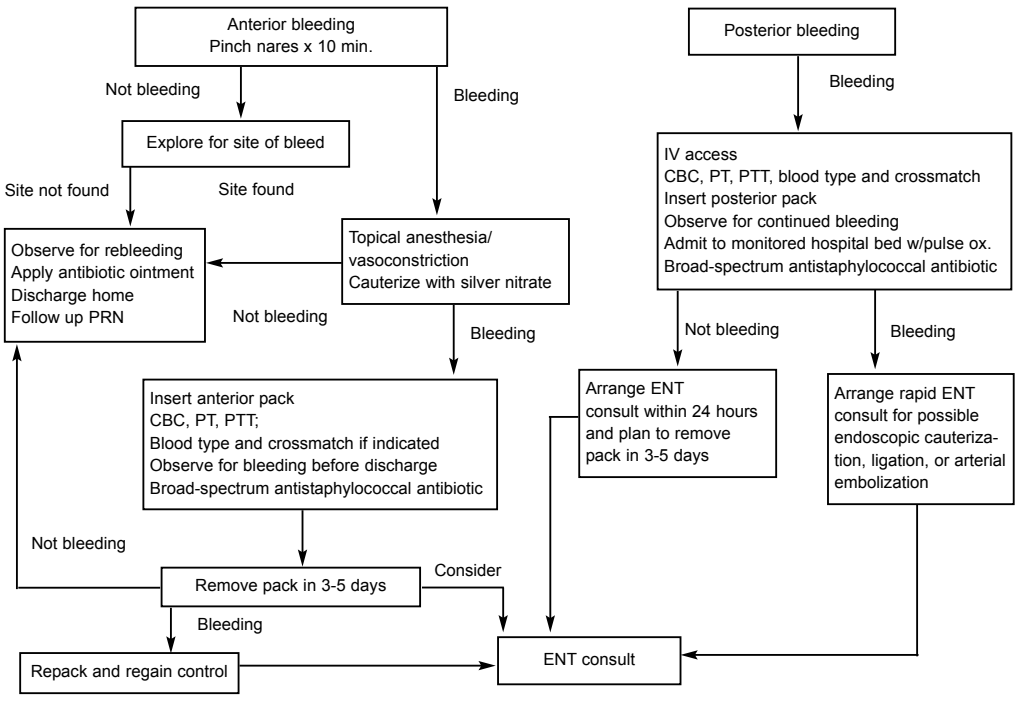

Traditional Anterior Packing

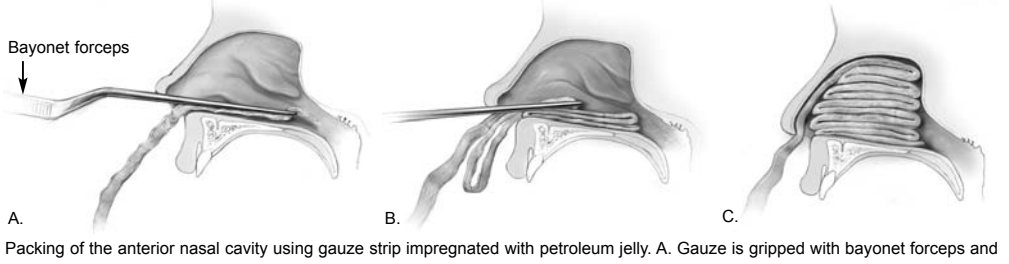

Packing of the anterior nasal cavity using gauze strip impregnated with petroleum jelly. A. Gauze is gripped with bayonet forceps and inserted into the anterior nasal cavity. B. With a nasal speculum (not shown) used for exposure, the first packing layer is inserted along the floor of the anterior nasal cavity. Forceps and speculum then are withdrawn. C. Additional layers of packing are added in an accordion-fold fashion, with the nasal speculum used to hold the positioned layers down while a new layer is inserted. Packing is continued until the anterior nasal cavity is filled.
Reprinted with permission from: Kucik CJ, Clenney T. Management of epistaxis. *Am Fam Physician* 2005;71:310. Copyright AAFP.
Illustrations used with permission from: Cindy Krames, certified medical illustrator.

Examples of Anterior-Posterior Combination Balloon Devices

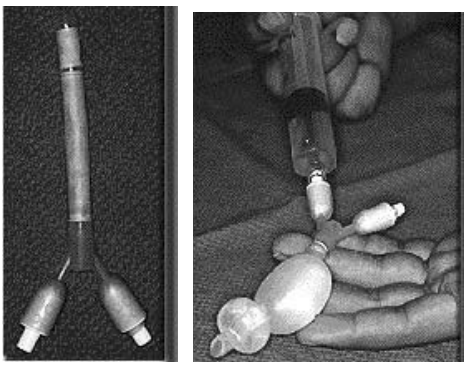

Treatment of Posterior Epistaxis

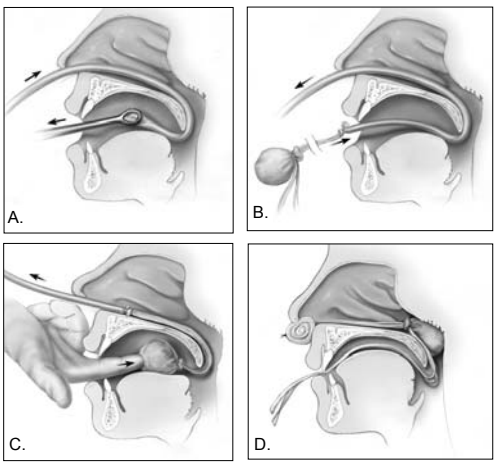

A. After adequate anesthesia has been obtained, a catheter is passed through the affected nostril and through the nasopharynx, and drawn ouf of the mouth with the aid of ring forceps. B. A gauze pack is secured to the end of the catheter using umbilical tap or suture material, with long tails left to protrude from the mouth. C. The gauze pack is guided through the mouth and around the soft palate using a combination of careful traction on the catheter and pushing with a gloved finger. This is the most uncomfortable (and most dangerous) part of the procedure; it should be completed smoothly and with the aid of a bite block (not shown) to protect the physician's finger. D. The gauze pack shoudl come to rest in the posterior nasal cavity. It is secured in position by maintaing tension on the catheter with a padded clamp or firm gauze roll placed anterior to the nostril. The ties protruding from the mouth, which will be used to remove the pack, are taped to the patient's cheek.
Reprinted with permission from: Kucik CJ, Clenney T. Management of epistaxis. *Am Fam Physician* 2005;71:310. Copyright AAFP.
Illustrations used with permission from: Cindy Krames, certified medical illustrator.

Supplement to *Emergency Medicine Reports*, September 18, 2006: "Management of Epistaxis in the Emergency Department." *Authors:* **Liudvikas Jagminas, MD, FACEP,** Associate Professor of Emergency Medicine, Brown Medical School, Providence, RI; Physician in Chief of Emergency Medicine, Memorial Hospital of Rhode Island, Pawtucket; and **Michelle Daniel, MD**, Attending Physician, Department of Emergency Medicine, Memorial Hospital of Rhode Island, Pawtucket; Clinical Instructor, Brown Medical School, Providence, RI.