AHC Media LLC

Enclosed in this issue: CME/CME Evaluation

Evidence-Based M ED

Trauma Reports

Vol. 7, No. 6

Supplement to *Emergency Medicine Reports* and *Pediatric Emergency Medicine Reports*

Nov./Dec. 2006

Penetrating neck trauma continues to be a challenging subset of trauma care. This area is loaded with potential high-risk injuries and controversies about the optimal management. The literature favors a more selective approach to these patients, however, the fundamental principles of resuscitation still apply because airway compromise and exsanguination are the greatest immediate life threats. This article reviews the medical literature on the diagnosis and management of these complex injuries.

– The Editor

Penetrating Neck Trauma

Authors: **Dennis Hanlon, MD, FAAEM,** Vice Chairman, Academics, Department of Emergency Medicine, Allegheny General Hospital, Pittsburgh, PA; **Rick J. Sumrok, MD**, Senior Resident, Emergency Medicine, Allegheny General Hospital, Pittsburgh, PA.

Peer Reviewer: **Perry W. Stafford, MD, FACS, FAAP, FCCM**, Head, Pediatric Surgery, Jersey City Medical Center, Jersey City, NJ.

Introduction

The management of penetrating neck trauma presents a significant challenge to emergency personnel. Penetrating injuries to the neck present a challenging diagnostic and therapeutic dilemma because the spectrum of injuries ranges from minor to acutely life threatening. Successful management requires a practical understanding of the anatomy of the neck and the tremendous number of vital structures in close proximity. A thorough diagnostic and management strategy must be implemented in the emergency department (ED) to avoid missing potentially devastating injuries. Optimal strategy remains controversial, and there remains substantial institutional variation.

Epidemiology

Although there has been a decrease of penetrating neck injury in the United States in the past years, it remains a significant public health concern.[1] This is due to the epidemic numbers of firearm-related injuries from interpersonal violence that still occur, particularly in highly populated urban areas. Most injuries are secondary to stabbings or gunshot wounds. Penetrating neck trauma accounts for 5%-10 % of all traumatic injuries in some urban trauma centers.[2-4] Most penetrating injuries to the neck involve zone II, which extends

Statement of Financial Disclosure

Dr. Dietrich (editor in chief) reports that she receives grant/research support from the National Institutes of Health and is the medical director for the Ohio Chapter of the American College of Emergency Physicians. Drs. Hanlon and Sumrok (authors), and Stafford (peer reviewer), Ms. Finerty (nurse reviewer) report no relationships with companies related to this field of study.

from the cricoid cartilage to the angle of the mandible. As with most penetrating trauma mechanisms, males are affected more commonly than females by approximately fourfold.[2] Mortality from penetrating neck trauma ranges from 2% to 10%.[2,3]

In the neck, vascular structures are the important anatomical structure most often injured.[2] Venous injuries occur more often than arterial injuries. The common carotid artery is the most common arterial injury, with the subclavian artery being the next most commonly injured.[2] Laryngotracheal and esophageal injuries occur almost equally with esophageal injuries being less common.[2,5]

Historical Perspective

Historical accounts of penetrating neck injury date to antiquity. One of the first works involves an esophageal injury from a stab wound 5000 years ago.[6] Ambrose Pare described the first repair of a cervical vascular injury.[7] Both the common carotid artery and internal jugular vein were lacerated and subsequently ligated. The battlefield gave rise to many accounts and advances in diagnosis and management of penetrating neck trauma. During the Civil War, penetrating neck trauma management focused primarily on observation. Mortality rates were approximately 15%.[8] World War I management also focused primarily on observation, although exploration and ligation became more prevalent. Mortality rates remained essentially unchanged. By World War II through the Vietnam conflict, mandatory exploration with vascular repair was the accepted practice.[9] Although this strategy missed very few injuries, it resulted in numerous negative surgical explorations. Today's modern diagnostic capabilities have given rise to new management strategies, some of which focus on nonoperative management following diagnostic testing or observation alone.

Etiology

The etiology of penetrating neck injuries can be divided into three categories: gunshots, stabbings, and miscellaneous. Each category has different predisposing factors and injury patterns. Gunshot wounds and other high-velocity injuries generally produce greater damage and thus are more likely to require surgical exploration. Injuries from gunshots and stabbings most often have a clear etiology, and their epidemiological patterns vary according to causal factors (e.g., crime rates, hunting accidents, military activity). Concomitant injury patterns obviously must be diagnosed and managed. The miscellaneous category represents a broad spectrum of injury by various other penetrating objects — from automobile glass secondary to car collisions to impalement from airborne objects. Associated injury patterns can be as broad and unpredictable as the mechanism of injury itself.

The pediatric patient with penetrating neck trauma represents a unique management challenge. This type of injury is uncommon in the pediatric population, but the potential injuries and complications can be devastating.[10] Literature on diagnosis and management regarding the pediatric patient is also scant. One study demonstrated motor vehicle collisions to be the most common mechanism of injury at 32.2%. Gunshot wounds and animal bites followed at 22.8% and 12.9%, respectively.[10] A specific mechanism of concern is penetrating neck injuries from air-guns because physicians and other personnel may mistakenly consider BB gun injuries as somewhat trivial. Significant injuries have been reported, including an expanding spinal hematoma.[11] Mortality rates were similar to the adult population. Zone II injuries were most common, a fact also seen in the adult studies.[10] Associated injury patterns remain very broad, depending upon the mechanism of trauma and whether the injury is isolated or associated with multiple injuries.

Pathophysiology

The pathophysiology of penetrating injury is relatively straightforward. Traditionally, gunshot wounds are divided into low-velocity weapons (< 1000 ft/sec) and high-velocity weapons (>2500 ft/sec).[12,13] Low-velocity weapons, which includes most handguns, tend to cause direct vascular injury. High-velocity weapons (e.g., hunting rifles and assault rifles) cause cavitation or disruption of tissue well removed from the tract. Types of *direct* vascular injury include intimal flap (most common), (*Figure 1*) transec-

Trauma Reports™ (ISSN 1531-1082) is published bimonthly by AHC Media LLC, 3525 Piedmont Road, N.E., Six Piedmont Center, Suite 400, Atlanta, GA 30305. Telephone: (800) 688-2421 or (404) 262-7436.

Vice President/Group Publisher: Brenda Mooney
Editorial Group Head: Glen Harris
Managing Editor: Martha Jo Dendinger

POSTMASTER: Send address changes to ***Trauma Reports***, P.O. Box 740059, Atlanta, GA 30374.

Accreditation

AHC Media LLC is accredited by the Accreditation Council for Continuing Medical Education to provide continuing medical education for physicians.

AHC Media LLC designates this educational activity for a maximum of 2.5 *AMA PRA Category 1 Credits™*. Physicians should only claim credit commensurate with the extent of their participation in the activity.

Approved by the American College of Emergency Physicians for 2.5 hours of ACEP Category 1 credit.

AHC Media LLC is accredited as a provider of continuing nursing education by the American Nurses Credentialing Center's Commission on Accreditation.

This activity has been approved for 2.2 nursing contact hours using a 50-minute contact hour.

Provider approved by the California Board of Registered Nursing, Provider # 14749, for 22 contact hours.

AHC Media LLC

Subscriber Information

Customer Service: 1-800-688-2421

Customer Service E-Mail: customerservice@ahcmedia.com
Editorial E-Mail: martha.dendinger@ahcmedia.com

World Wide Web page: http://www.ahcmedia.com

FREE to subscribers of *Emergency Medicine Reports* and *Pediatric Emergency Medicine Reports*

This is an educational publication designed to present scientific information and opinion to health professionals, to stimulate thought, and further investigation. It does not provide advice regarding medical diagnosis or treatment for any individual case. It is not intended for use by the layman. Opinions expressed are not necessarily those of this publication. Mention of products or services does not constitute endorsement. Clinical, legal, tax, and other comments are offered for general guidance only; professional counsel should be sought for specific situations.

This CME/CNE activity is intended for emergency, family, osteopathic, trauma, surgical, and general practice physicians and nurses who have contact with trauma patients.

It is in effect for 24 months from the date of publication.

For Customer Service,

Please call our customer service department at **(800) 688-2421.** For editorial questions or comments, please contact **Martha Jo Dendinger**, Managing Editor, at martha.dendinger@ahcmedia.com.

Figure 1. Gunshot Wound to Zone II of the Neck

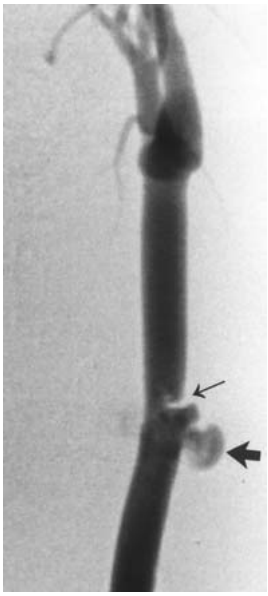

Figure 1. A 59-year-old man who attempted suicide by gunshot to zone II left neck. Lateral view from common carotid arteriogram confirms the pseudoaneurysm (thick arrow) and intimal flap (thin arrow).

Reprinted with permission from the American Journal of Roentgenology. *LeBlang SD, Nunez, DB Jr.* AJR *2000;174:1269-1278.*

Figure 2. Arteriogram of Patient with a Stab Wound to the Neck

Figure 2. A 21-year-old man who presented with stab wound to right neck traversing zones I and II. Anteroposterior view from arteriogram shows pseudoaneurysm (arrow) of proximal right common carotid artery.

Reprinted with permission from the American Journal of Roentgenology. *LeBlang SD, Nunez, DB Jr.* AJR *2000;174: 1269-1278.*

tion, laceration, puncture, arteriovenous fistula, and pseudoaneurysm (*Figure 2*).[12] Types of *indirect* vascular trauma include spasm, external compression, mural contusion, and thrombosis.[12] Although the ballistics may be relatively straight forward, the path of the bullet may be difficult to predict.

The injuries from stab wounds are directly related to the characteristics of the weapon used, although the path and depth of penetration are often difficult to predict. Apparently minor wounds may be associated with significant underlying injuries.

Anatomy

The anatomy of the neck is complex. There are many important structures in proximity to each other. Traditionally, the neck is divided into three zones for the management of penetrating trauma. (*See Table 1 and Figure 3.*) *Zone I* extends from the sternal notch to the cricoid cartilage. Injuries to zone I have the highest mortality due to associated injuries to intrathoracic structures (*Figure 4*).[2] *Zone II* lies between the cricoid cartilage and the angle of the mandible. Zone II injuries are the most common. *Zone III* consists of the upper neck above the angle of the mandible to the base of the skull. Surgical exposure is difficult in zones I and III.

Another classification separates the neck into triangles. The sternocleidomastoid muscle is the anatomical landmark that divides the neck into anterior and posterior triangles.[13] The *anterior triangle* lies between the anterior midline of the neck, the inferior aspect of the angle, and the anterior border of the sternocleidomastoid. The *posterior triangle* is bordered by the posterior aspect of the sternocleidomastoid, the middle third of the clavicle, and the anterior aspect of the trapezius. Injuries to the posterior triangle have a lower incidence of significant injuries than those to the anterior triangle.[14]

The fascial and muscle planes of the neck are extremely important in the evaluation of penetrating injuries. The platysma is a thin, broad muscle that originates from the deep fascia that covers the upper chest and inserts on the inferior aspect of the mandible.[13] It is covered anteriorly by the superficial fascia and by the deep fascia posteriorly. Any violation of this muscle defines penetrating neck trauma and mandates surgical consultation. The deep fascial layers may help contain a hematoma. These fascial layers also may provide a route for spread of infection in case of injury, especially the pretracheal fascia, which connects to the anterior pericardium.[2,4]

Clinical Features of Penetrating Neck Trauma

Isolated penetrating neck injuries are uncommon. Penetrating neck injuries occur most often in the setting of multiple trauma.[4] The presentation may range from relatively asymptomatic to dramatic and acutely life-threatening depending upon the structures involved. To avoid missing subtle findings, the search for injuries must be systematic. The history and physical examination should be directed to the areas of potential injury including vascular, laryngotracheal, esophageal, and neurological injuries.[15]

Vascular injuries occur in approximately 25% of patients with penetrating neck injuries.[15-17] Exsanguination is the most common cause of immediate death after a vascular injury.[17] Morbidity and mortality also result from

Table 1. Anatomic Contents of the Zones of the Neck

ZONE	LOCATION	ANATOMICAL CONTENTS
I	Sternal notch to cricoid cartilage	Proximal subclavian vessels, proximal carotid artery, vertebral artery, internal jugular vein, trachea, esophagus, thyroid, thoracic duct, cervical nerve roots, spinal cord, and apex of lung
II	Cricoid cartilage to the angle of the mandible	Common carotid artery, external & internal carotid artery, vertebral artery, jugular veins, larynx, trachea, esophagus, phrenic nerve, vagus nerve, spinal cord, and recurrent laryngeal nerve
III	The angle of the mandible to the base of the skull	Distal internal carotid artery, vertebral artery, jugular veins, oropharynx, salivary glands, and cranial nerves (IX,X,XI, & XII)

Figure 3. Zones of the Neck

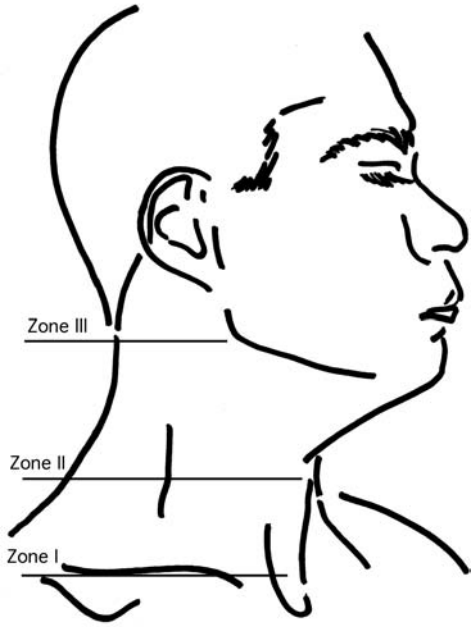

Illustration courtesy of Marcus Eubanks, MD.

hematomas compromising the airway, direct vascular injury with subsequent occlusion, and bullet embolization.[17] Mortality from these injuries ranges from 5% to 50%.[2,4,13,15] The clinical features of a vascular injury may be quite obvious, such as pulsatile bleeding or an expanding hematoma. These signs, believed to demonstrate a definite vascular injury, are referred to as "hard signs".[2,13] (*See Table 2.*) Vascular injuries also may present with subtle neurologic or pulse deficits, therefore, a rapid yet vigilant exam is necessary. Late complications include traumatic aneurysm and arteriovenous fistula.[5]

Laryngotracheal injuries complicate 10% of penetrating neck injuries.[15,17] With penetrating trauma, these injuries are rarely occult.[3] The most common signs and symptoms include dyspnea, stridor, dysphonia, hemoptysis, laryngeal tenderness, subcutaneous emphysema, and air bubbling from the wound.[2,3,13,15] (*See Table 3.*) Any of the above findings mandate laryngoscopy.

Esophageal injury occurs less frequently than vascular or laryngotracheal injuries due to the relatively protected location of the esophagus.[17] Some authors have noted dyspnea, hemoptysis, and air-bubbling through wounds as "hard signs" of aerodigestive tract injuries.[18] Most esophageal injuries are associated with laryngotracheal injuries due to its location.[5] Signs and symptoms of esophageal injury include dysphagia, oropharyngeal hemorrhage, nasogastric tube bleeding, subcutaneous emphysema, and resistance to movement of the neck. As with laryngotracheal injuries, crepitance is a strong indicator of esophageal injury.[2,3,4,17-19] (*See Table 4.*) Despite these signs, esophageal injuries are the most commonly missed injuries in the neck.[17,20] A delay in the diagnosis of these injuries increases mortality.[13] An early diagnosis is required to prevent the development of mediastinitis due to para-esophageal contamination.

Figure 4. Penetrating Trauma to Zone I of the Neck

Figure 4. A patient who presented following penetrating trauma to zone I of the neck.

Figure courtesy of Howie Werman, MD, FACEP, Professor of Clinical Emergency Medicine, The Ohio State University College of Medicine and Public Health; Medical Director, MedFlight, Columbus, OH.

Injuries to the nervous system include direct spinal cord injury, cranial nerve injury, peripheral nerve injury, and

Table 2. Clinical Features of a Vascular Injury

HARD SIGNS OF ARTERIAL INJURY
• Pulsatile bleeding
• Expanding hematoma
• Palpable thrill
• Bruit
• Findings of cerebral ischemia
• Findings of peripheral ischemia in upper limb
- Pulselessness
- Pallor
- Paralysis
- Poikliothermia
- Pain

Table 3. Clinical Features of Laryngotracheal Injury

- Hoarseness/ altered voice
- Anterior neck pain / tenderness
- Hemoptysis
- Stridor
- Subcutaneous emphysema / crepitance
- Deformity of neck landmarks
- Air bubbling from wound

Table 4. Clinical Features of Esophageal Injury

- Dysphagia
- Oral bleeding / nasogastric tube bleeding
- Anterior neck pain / tenderness
- Subcutaneous emphysema / **crepitance**
- Resistance to range of motion of the neck

deficits in the central nervous system. Approximately 10% of patients with penetrating neck trauma will have an associated spinal cord or brachial plexus injury.[13] The clinical presentation will depend upon the involved structure and the extent of the injury. In a recent study, almost 10% of asymptomatic patients with gunshot wounds to the trunk, head, or neck had spinal injuries.[21] This percentage is much higher than had been reported in previous studies, and its results have been challenged.[22,23] In Connell's study, no spinal injuries were found among nonintoxicated patients with a normal neurological examination who had penetrating trauma.[22] Also, the presence of a peripheral nerve injury should alert the evaluating personnel to the possibility of an associated arterial injury because most nerves are located close to large arteries.[5]

Diagnostic Studies

A successful diagnostic approach to penetrating neck injury must include evaluation of the three individual organ systems: vascular, laryngotracheal, and para-esophageal. Also, the nervous system, such as the spinal cord/column and nerves and nerve root, must be evaluated. The venous structures that may be potentially injured include the internal and external jugular veins along with the subclavian veins. Arteries at risk of injury include the carotid, subclavian, and vertebral arteries. The vertebral artery is the least injured due to its well-protected position.[13,17] Visceral structures with injury potential are the pharynx, larynx, trachea, esophagus, and pleural cavity.

If the integrity of the platysma muscle is not compromised throughout the entire wound and the physical examination is otherwise normal, one can assume no serious penetration occurred. No further tests need be performed to detect internal injury due to penetrating trauma. Any violation of the platysma indicates penetrating neck trauma has occurred and mandates both surgical consultation and further diagnostic evaluation. The hemodynamically unstable patient may require immediate operative exploration. As discussed in the historical perspective, the management has evolved from mandatory exploration to a more selective management if the patient is stable.[2,13] This evolution has not been without controversy. Some authors have advocated a mandatory exploration of all significant penetrating neck trauma to avoid missing any important injuries. This approach yields a range of 30% to 89% negative explorations.[24-28] This high negative exploration rate has produced the selective management of penetrating neck trauma. Currently, the controversy focuses on the selection of diagnostic testing needed to exclude the potential injuries.[13] The choice of diagnostic tests will depend upon the resources available at an individual institution.

Advanced imaging technologies have enabled the detection of vascular and other injuries in penetrating neck trauma. Diagnosing vascular injuries remains paramount in penetrating neck trauma. Angiography has traditionally been considered the gold standard in evaluating such injuries (*Figure 5*). However, it is an invasive study and is not without risk. At the other end of the diagnostic spectrum, some have advocated the use of physical examination alone. Generally, it is believed to be insufficient.[29] Bishara documented that almost 25% of vascular injuries were missed when relying on physical examination alone.[29] Mohammed and colleagues reported a negative predictive value of 67% for the absence of signs of vascular injury on physical exam in patients with gunshot wounds to the neck.[30] Diagnostic studies are clearly required to exclude potentially life-threatening injuries. Recently, noninvasive techniques have emerged, such as computed tomographic angiography (CTA), magnetic resonance angiography (MRA), and color flow ultrasound (US).

In patients who are not deemed to require emergent surgical intervention, four main imaging modalities are considered: angiography, MRA, US, and CTA. MRA has been

Figure 5. Common Carotid Arteriogram in a Patient with a Zone III Penetrating Injury of the Neck

Figure 5. A 22-year-old man with gunshot wound to zone III right neck in whom neurologic examination findings were normal. Lateral view from common carotid arteriogram confirms total occlusion (arrow) of internal carotid artery.

Reprinted with permission from the American Journal of Roentgenology. *LeBlang SD, Nunez, DB Jr.* AJR *2000;174:1269-1278.*

Figure 6. MR Imaging of Zone II Penetrating Trauma

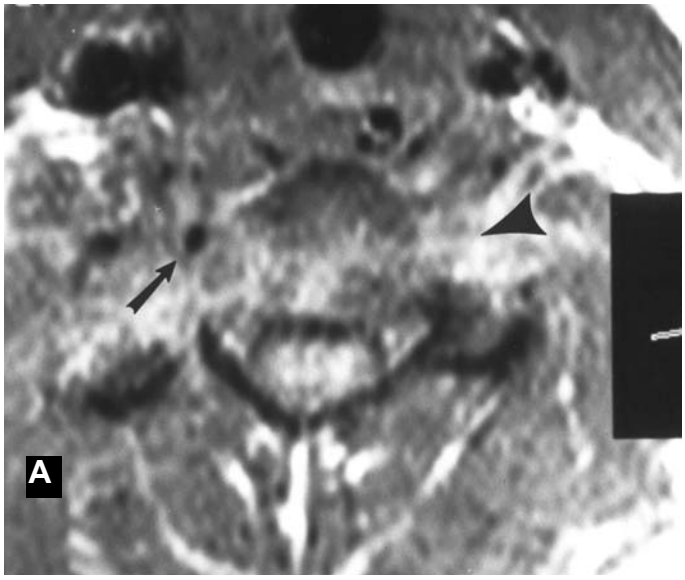

Figure 6A. A 14-year-old boy with gunshot wound across zone II who presented as C4-level quadreplegic. Axial T1-weighted MR image shows horizontal fracture extending through vertebral body and both transverse foramina. Note normal signal void in right vertebral artery (arrow) but lack of flow void in region of left vertebral artery (arrowhead).

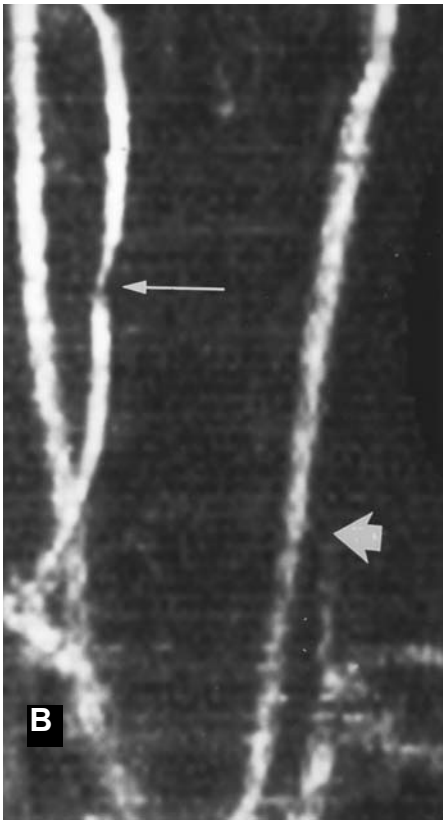

Figure 6B. A 14-year-old boy with gunshot wound across zone II who presented as C4-level quadreplegic.Coronal maximum-intensity-projection image from two-dimenstional time-of-flight MR angiogram, acquired with axial slices, reveals absent flow-related enhancement of left vertebral artery beyond origin consistent with occlusion (short arrow). Also note external compression of right vertebral artery at level of fracture (long arrow).

Reprinted with permission from the American Journal of Roentgenology. *LeBlang SD, Nunez, DB Jr.* AJR *2000;174:1269-1278.*

used for imaging vascular injuries. However, it is limited in the assessment of bony structures. In addition, it is not practical in the acute assessment of the trauma patient because of the need for proper monitoring and MR-incompatible equipment. The availability of emergent MR also is limited in many hospitals and trauma centers. Thus, MRA will not be further discussed. However, MR/MRA (*Figure 6*) remains a potential diagnostic modality if it becomes more efficient and more readily available.

Color flow US offers a viable noninvasive alternative to angiography. US allows a noninvasive evaluation of the vascular bundles and adjacent tissue and a real-time analysis of blood flow velocity (*Figure 7*). US, like MRA, does have several significant limitations: It requires a trained technician and is highly operator dependent. In many hospitals, US is not available at night or on weekends. Imaging artifact may be generated by bone, and examination of smaller arterial branches may cause errors. Studies have been promising in the use of US, however, and its sensitivity was approximately 90%-91% compared with angiography, and its specificity was 100%.[31] Positive predictive value was found at 100%, and negative predictive value was 99%.[31] In spite of these encouraging numbers, the limited availability of US and the inter-operator variability make US less feasible in the reliable evaluation of vascular injury in penetrating neck trauma. Also, US may be misleading in zone III due to artifact.[32]

Helical CT angiography has been studied at several centers and has shown very promising results (*Figure 8*). Its sensitivity and specificity compared with angiography was 90%-100%. Munera and colleagues demonstrated a sensitivity of 90%, specificity of 100%, positive predictive value

Figure 7. Sonogram of Penetrating Trauma to Zone II of the Neck

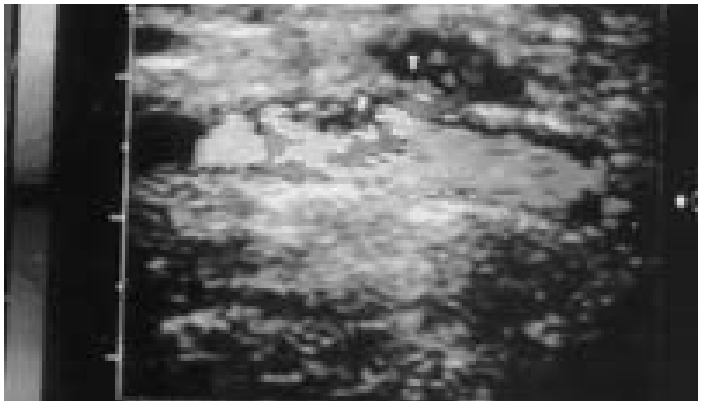

Figure 7 A 59-year-old man who attempted suicide by gunshot to zone II left neck. Longitudinal color sonogram of left common carotid artery shows pseudoaneurysm (PSA) with partial thrombus (T) and intimal flap (F).

Reprinted with permission from the American Journal of Roentgenology. *LeBlang SD, Nunez, DB Jr.* AJR *2000;174:1269-1278.*

Figure 8. Penetrating Trauma to Zone III of the Neck

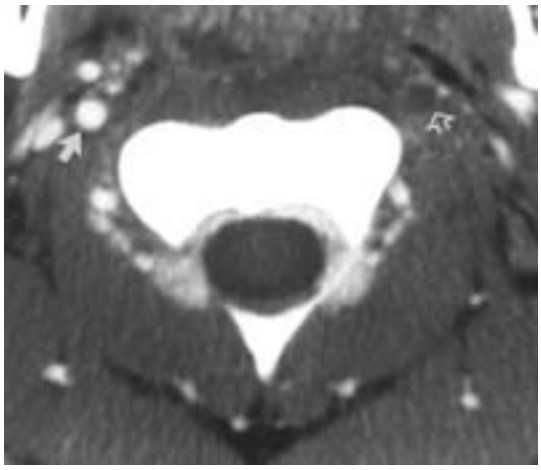

Figure 8. A 22-year-old man with gunshot wound to zone III right neck in whom neurologic examination findings were normal. Axial helical CT angiogram reveals normal enchangement in right internal carotid artery (solid arrow) and no enhancement in region of left internal carotid artery (clear arrow), indicating occlusion.

Reprinted with permission from the American Journal of Roentgenology. *LeBlang SD, Nunez, DB Jr.* AJR *2000;174:1269-1278.*

Figure 9. Axial Helical CT Angiogram

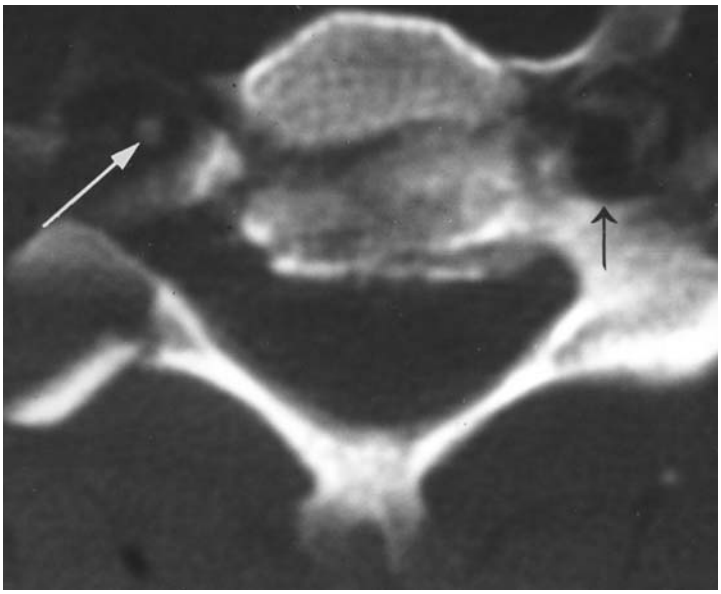

Figure 9. A 14-year-old boy with gunshot wound across zone II who presented as C4-level quadreplegic. Axial helical CT angiogram filmed in bone windows shows path of bullet and fractures across C4 vertebral body involving both transverse foramina. Note contrast-enhanced right vertebral artery (white arrow) and nonvisualization of left vertebral artery (black arrow) in left transverse foramen.

Reprinted with permission from the American Journal of Roentgenology. *LeBlang SD, Nunez, DB Jr.* AJR *2000;174:1269-1278.*

of 100%, and a negative predictive value of 98%.[33] Several other studies have shown similar results making helical CT angiography an attractive alternative to standard angiography.[34-36] In addition, CT may reveal aerodigestive injuries, bony injuries, and the tract of the bullet. When combined with physical examination, CT can reveal damage to the spinal column and spinal cord (*Figure 9*). There is no evidence that a negative CT study will exclude aerodigestive injuries, although it may sometimes diagnose these injuries. Some of the limitations of CTA include motion and foreign body artifact. Vascular abnormalities or congenital anomalies may be confused with pathologic lesions. Subclavian arteries may not be adequately visualized due to the imaging plane in some CT scanners, but greater spatial resolution in machinery is overcoming this deficit. Small lesions of questionable significance may be missed. Lastly, CT imaging is only diagnostic, and not therapeutic such as angiography. Nevertheless, CT imaging to detect vascular injuries remains an excellent choice in the initial assessment of vascular injury in penetrating trauma (*Figures 10 and 11*). Depending on the CT result, angiography may be indicated for confirmatory testing or intervention.

Evaluation of the aerodigestive structures of the neck, specifically the laryngotracheal and para-esophageal systems, requires the same rigorous approach as mandated for vascular injury. Injuries may be silent initially, and serious complications can result. Careful clinical examination remains the focal point in the diagnosis of aerodigestive tract injuries. Demetriades and colleagues propose that in awake, alert patients who are able to be evaluated clinical-

Figure 10. Penetrating Trauma of Zone I and II of the Neck

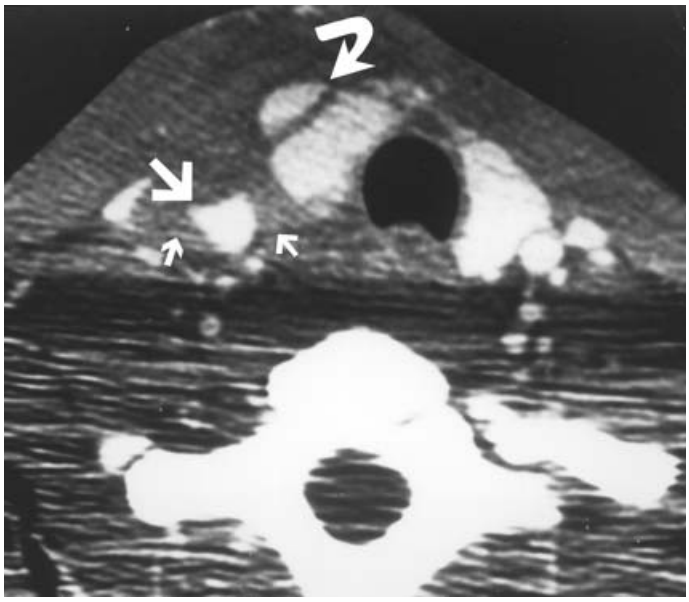

Figure 10. A 21-year-old man who presented with stab wound to right neck traversing zones I and II. Axial slice from helical CT angiogram reveals irregular contour of proximal right common carotid artery with contrast material extending outside confines of vessel lumen (large straight arrow) corresponding to site of pseudoaneurysm formation. Note hematoma surrounding artery (small arrows) and fracture through right lobe of thyroid gland (curved arrow).

Reprinted with permission from the American Journal of Roentgenology. *LeBlang SD, Nunez, DB Jr.* AJR *2000; 174:1269-1278.*

Figure 11. Axial Helical CT Angiogram of Patient with a Dog Bite to the Neck

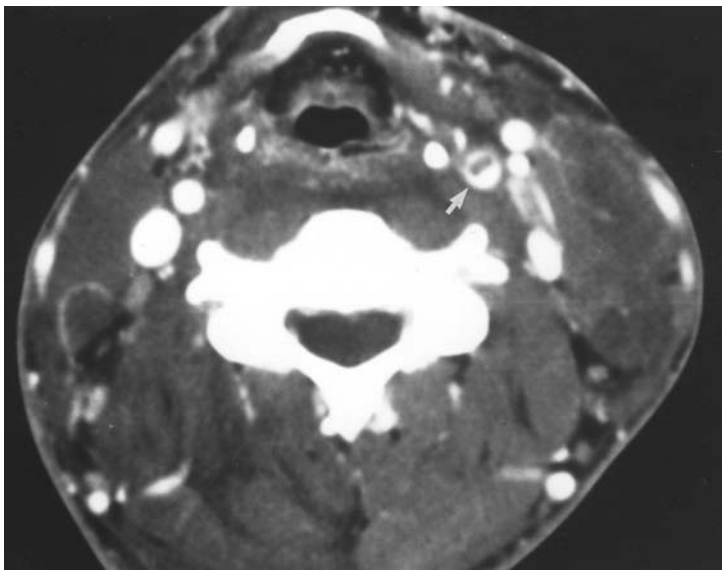

Figure 11. A 34-year-old man who presented with a dog bite to zone II of left neck. Axial helical CT angiogram shows focal filling defect in left common carotidy artery (arrow).

Reprinted with permission from the American Journal of Roentgenology. *LeBlang SD, Nunez, DB Jr.* AJR *2000;174:1269-1278.*

ly, physical examination alone can exclude or raise suspicion for significant injuries.[37] In another study, all patients eventually proven to have an injury to aerodigestive structures were initially symptomatic.[17] In a study with contrarian results, Gonzales and colleagues reported 4 esophageal injuries that were missed by a combination of physical examination and helical CT study.[38]

As in vascular injury, a chest and lateral neck radiograph should be a standard initial tool in the aerodigestive system evaluation. Flexible fiberoptic endoscopy is the desired modality for identifying laryngotracheal trauma. CT scanning of the neck can reveal laryngeal structural damage and fractures and dislocations of bone and cartilage. However, a negative CT study does not exclude aerodigestive injury. The evaluation of the esophagus and pharynx is not as straightforward as the laryngotracheal system. While the evaluation of the pharynx can be done via direct endoscopy with satisfactory results, the cervical esophageal evaluation remains much more complex, especially compared with the thoracic and abdominal esophagus. Flexible endoscopy has a lower sensitivity in the cervical region than compared with other esophageal areas, thus injuries may be missed in this area. Radiological imaging may be performed in the form of a swallow study or, in the case of intubated patients, with contrast injected via a tube. Sensitivities vary widely in radiological imaging from 60% to 100%, while sensitivity with endoscopy ranges in the 80th percentile in the cervical esophagus.[39-42] Rigid endoscopy provides a higher sensitivity, but it must be done by experienced operators under general anesthesia. The combination of endoscopy and esophagoscopy has a synergistic ability to diagnose para-esophageal injuries. Demetriades and colleagues recommend this approach in the evaluation of the pharynx and esophagus in penetrating neck trauma.[37]

As previously mentioned, literature in the management of pediatric penetrating neck injury is sparse. One retrospective study done by Abujamra and Joseph examined 31 children with penetrating neck trauma.[10] Most had only minor physical examination findings and did not merit exploration or diagnostic imaging. Observation alone was sufficient for the stable patient. Larger multicenter studies are needed before specific conclusions can be made; however, currently, the overall management of penetrating cervical injuries in children should follow the adult guidelines above.

Management

The initial management of a patient with penetrating neck trauma is similar to any potential major trauma patient. Of primary concern in a patient with this type of injury is airway compromise and extensive bleeding. The

Table 5. Absolute Indications for Mandatory Exploration

- Airway compromise
- Extensive subcutaneous emphysema
- Pulsatile hematomas
- Shock or active, uncontrollable bleeding

status of the airway can deteriorate precipitously due to edema and bleeding. The primary survey is rapidly performed with concurrent evaluation and management using a team approach if such resources are available. Supplemental oxygen should be provided, monitoring performed, and vascular access should be established. This access should be established on the opposite side of the injury.

Airway and Breathing

Airway management in penetrating neck injury patients is potentially very problematic. Approximately 10% of these patients will present with airway compromise, either partial or complete.[5] There is not a universal consensus for either the indications for active airway management or the appropriate technique. The emergency medical literature in this area is somewhat scarce.

Orotracheal Intubation. Early intubation has been the rule if there is any question of airway compromise or anticipated problems. Orotracheal intubation using a rapid sequence intubation (RSI) technique is the method of choice in most patients with penetrating neck trauma. Concerns with using RSI in the patient with a neck injury include the difficulties or failure to intubate due to anatomic distortion and the potential conversion of a partial laryngotracheal injury into a complete transaction.[43] Mandavia and colleagues reported a 100% success rate with this technique.[43] Awake intubation is often recommended due to these potential complications. Despite these concerns, in one retrospective study, three cases had failure of fiberoptic intubation, yet these patients were successfully intubated using an RSI technique.[43]

Nasotracheal Intubation. Nasotracheal intubation has been relatively contraindicated in penetrating neck trauma due to concerns of dislodging a hematoma and lack of visualization of the airway. A prehospital study demonstrated a 90% success rate in a well-trained emergency medical services system.[44] Also, these patients did not experience any complications related to this technique of airway management.[44] Despite previous concerns, blind nasotracheal intubation may be a reasonable alternative for airway management by appropriately trained personnel in patients with penetrating neck trauma. Further study in this area is required.

Fiberoptic Intubation. Fiberoptic intubation may be considered in the management of these patients. This technique is time consuming and difficult if the airway is bloody. Awake fiberoptic intubation is considered the safest technique in cooperative patients with suspected airway injury at some trauma centers.[45] Desjardins reports that his trauma center uses a rapid sequence technique with fiberoptic intubation in uncooperative patients who did not appear difficult to intubate.[45]

Direct Intubation. Direct intubation into the distal segment of an injured larynx may be possible in penetrating trauma. The trachea is held with hemostats, tracheal hook, or towel clip, and the endotracheal tube is placed directly into the trachea. Placement of an endotracheal tube through the wound is not universally successful depending upon the characteristics of the wound. A gum elastic bougie has been used to establish the airway through the wound in such a case.[46] This device is usually used as an airway adjunct when the laryngoscopic view is suboptimal. The bougie is passed to the cords without direct visualization. If it finds the trachea, a clicking can be felt from the tracheal rings. This device also may become caught at the carina, and the resistance ensures tracheal insertion.[46]

Cricothyrotomy. Cricothyrotomy may be used as a rescue method if the injury is above the level of the cricothyroid membrane. Also proceed with this technique if the patient's condition does not allow time for a tracheostomy.

Tracheostomy. Tracheostomy may be used as a rescue method and usually will be performed by surgical colleagues. It should be performed at least one tracheal ring below the level of the injury.[45]

The method of stabilizing the airway will depend upon the skills of the practitioners available, the condition of the patient, and the resources of the institution.

Circulation: Hemorrhage Control. Direct pressure is used to control bleeding. Clamping of vessels should be discouraged. Wounds should be covered with an airtight dressing because lacerations involving the venous system may lead to air embolus.[2] Fluid resuscitation and blood product replacement should follow standard guidelines.

Diagnostic Strategies

After stabilization, the initial key question is: Does the wound penetrate the platysma? If the answer is yes, a surgical consultation is mandatory. (The penetration of the platysma defines penetrating neck trauma.) The next question is: Should these wounds be managed with mandatory operative exploration or selective operations? The approach will vary by hemodynamic stability, the zone involved, mechanism of injury, and institution. Definite signs and symptoms of vascular or aerodigestive injuries requires urgent operative intervention.[4,13] (*See Table 5.*)

Unless the patient is very unstable, zone I and zone III injures are managed selectively due to the difficulties in examining these areas as well as obtaining good intra-operative exposure.[13] The controversy primarily concerns the management of a stable patient with a zone II injury and no significant symptoms. Most experts favor selective management over mandatory exploration.[4,13] All such patients

should have a chest x-ray and soft-tissue neck radiography both anterior-posterior and lateral views in addition to the routine trauma laboratory studies. Patients with zone I injuries often have an associated pneumothorax or hemothorax. After these initial tests are performed and stabilization is obtained, the management of the stable patient with penetrating neck trauma proceeds based upon the involved zone, the mechanism, and the resources available.

Stable patients with a zone I injury require studies of the great vessels, airway, and esophagus. An arteriogram is performed to exclude great vessel injury. Bronchoscopy will identify laryngotracheal injuries. The combination of esophagram and esophagoscopy may evaluate potential esophageal injuries.

A stable patient with a zone II injury may require studies of the great vessels, airway, and esophagus. These patients are managed based on the mechanism and the presence of signs or symptoms of injury. A patient with transcervical wounds (wounds that cross the midline) is explored if symptomatic and undergoes selective management if asymptomatic. Some trauma centers practice expectant management of asymptomatic zone II injuries caused by stab wounds or low-velocity gunshot wounds.[13] Patients with zone II injuries have a lower mortality rate because the access for surgical exploration is good and direct pressure can control hemorrhage. [46]

A stable patient with a zone III injury requires studies of the cerebral circulation, upper airway, and esophagus. Ferguson and colleagues have questioned the need for an angiogram in patients with zone III injuries lacking hard signs of vascular trauma.[47] All symptomatic patients with zone III injuries require diagnostic evaluation of the esophagus and arteries.[2]

Disposition

All patients with penetrating neck wounds—which by definition violate the platysma—require admission to a qualified surgeon with appropriate resources, preferably at a trauma center. A facility that does not have adequate resources should have transfer guidelines in place with a trauma center to facilitate transfer. ED physicians should be familiar with their facility's resources and should transfer patients, following stabilization, as appropriate.

Summary

Injuries to the neck present a difficult challenge in both diagnosis and management (*See Table 6.*). Successful management requires a thorough understanding of the complex anatomy of the neck. Clinical presentations and physical examination findings also must be reviewed. Some injuries may present dramatically and catastrophically, while others may be more insidious. A thorough and structured approach must be implemented for every patient.

The controversy over mandatory exploration versus selective, nonoperative management is being replaced by discussion about the optimal nonoperative strategy for each zone realizing which structures are at risk for injury. Selective evaluation is based on the symptoms and physical findings, unlike routine imaging in which all patients undergo a complete battery of studies. The diagnosis of injuries in penetrating neck trauma should focus on evaluating vascular, laryngotracheal, and esophageal trauma. Spinal cord and other nervous system trauma must not be overlooked, although there is some controversy about its prevalence.[21-23] Similar to adults, the selective management of penetrating neck injuries is a safe, effective strategy in the pediatric population in an experienced pediatric trauma center.[48]

Angiography remains the gold standard for vascular injury diagnosis, but newer imaging modalities—primarily helical CT angiography— provide an excellent alternative for initial screening and soon may become the primary imaging modality. MRA and US offer comparable results, but these diagnostic tools are not as practical in the acute injury setting due to operator dependency and limited after-hours availability. Aerodigestive injury can be suggested from physical examination findings, but the combination of endoscopy and esophagography along with bronchoscopy provides a reliable diagnostic modality to identify or rule out esophageal and laryngotracheal injury.

Table 6. Pearls and Pitfalls

- Never clamp vessels in the neck.
- Don't probe neck wounds.
- Don't remove impaled objects.
- Earlier intubation is often the safest choice.

References

1. Thompson EC, Porter JM, Fernandez LG. Pentrating neck trauma: An overview in management. *J Oral Maxillofac Surg* 2002;60: 918-923.
2. Duchynski RM. Neck injury. In: Ferrera PC, Colucciello SA, Marx JA, et al , eds. *The Management of Trauma: An Emergency Medicine Approach.* Philadelphia:Mosby 2001:218-231.
3. Baron BJ. Penetrating and blunt neck trauma. In: Tintinalli JE, Kelen GD, Stapczynski JS, eds. *Emergency Medicine: A Comprehensive Study Guide*. 6th Ed. New York:McGraw-Hill 2004: 1590 -1595.
4. Schaider J, Bailitz J. Neck trauma: Don't put your neck on the line. *Emerg Med Pract* 1993;5(7).
5. Craducci B, Lowe RA, Dalsey W. Penetrating neck trauma: consensus and controversies. *Ann Emerg Med* 1986;15:208-215.
6. Breasted JH. *The Edwin Smith Surgical Papyrus*. Chicago, IL: University of Chicago Press; 1930.
7. Key G. *The Apologie and Treatise of Ambroise Pare Containing the Voyages Made into Divers Places with Many Writings Upon Surgery*. London, UK: Falcon Education Book;1957.
8. Otis GA. *Medical and Surgical History of the War of Rebellion, Part 3, Vol 2: Surgical History*. Washington, DC: U.S. Government Print-

ing Office;1983.
9. Fogelman MJ, Stewart RD. Penetrating wounds of the neck. *Am J Surg* 1956; 91:581-93
10. Abujamra L, Joseph MM. Penetrating neck injuries in children: A retrospective review. *Pediatr Emerg Care* 2003;19:308-313.
11. Keller JE, Hindman JW, Kidd JN, et al. Air-gun injuries: Initial evaluation and resultant morbidity. *Amer Surg 2004*;70(6):484-490.
12. Frykberg ER, Schinco MA. Peripheral vascular injury. In: Moore EE, Feliciano DV, Mattox KL, eds. *Trauma*. 5th Ed. New York: McGraw-Hill 2004:969-1003.
13. Britt LD, Peyser MB. Penetrating and blunt neck trauma. In:Moore EE, Feliciano DV, Mattox KL, eds. *Trauma*. 5th Ed. New York: McGraw-Hill 2004:445-458.
14. Siegrist B, Steeb G. Penetrating neck injuries. *South Med J* 2000; 93:567-570.
15. Kendall JL, Anglin D, Demetriades D. Penetrating neck trauma. *Emerg Med Clin North Amer* 1998;16:85-105.
16. Asensio JA, Valenzianio CP, Falcone RE, Grosh JD. Management of penetrating neck iInjuries: The controversy surrounding zone II injuries. *Surg Clin North Am* 1991;71:267-296.
17. Newton K. Neck trauma. In: Marx JA, Hockberger RS, Walls RM, eds. *Rosen's Emergency Medicine: Concepts and Clinical Practice*. 5th Ed. Philadelphia: Mosby 2002:370-380.
18. Vassiliu P, Baker J, Henderson S, Alo K, Velmahos G, Demetriades D. Aerodigestive injuries of the neck. *Amer Surg* 2001;67:75-79.
19. Weigelt JA, Thal ER, Snyder WH, et al. Diagnosis of penetrating cervical esophageal injuries. *Am J Surg* 1987;154:619-622.
20. Demetriades D, Asensio JA, Valmahos G, Thai E. Complex problems in penetrating neck trauma. *Surg Clin North Am* 1996;76: 661-683.
21. Klein Y, Cohn SM, Soffer D, et al. Spine injuries are common among asymptomatic patients after gunshot wounds. *J Trauma* 2005;58:833-836.
22. Connell RA, Graham CA, Munro PT. Is spinal immobilisation necessary for all patients sustaining isolated penetrating trauma? *Injury* 2003;34:912-914.
23. Rhee P, Martin M, Pleurad D, et al. Letter to editor. *J Trauma* 2005; 59:1033-1034.
24. Apffelstaedt JP, Muller R. Results of mandatory exploration for penetrating neck trauma. *World J Surg* 1994;18:917-919.
25. Walsh MS. The management of penetrating injuries of the anterior triangle of the neck. *Injury* 1994;25:393-395.
26. Jurkovich GJ, Zingarelli W, Wallace J, Curreri PW. Penetrating neck trauma: diagnostic studies in the asymptomatic patient. *J Trauma* 1985;25:819-822.
27. Meyer JP, Barret JA, Schuler JJ, Flanigan DP. Mandatory vs. selective exploration for penetrating neck trauma; A prospective assessment. *Arch Surg* 1987;122:592.
28. Golueke PJ, Goldstein AS, Sclafani SJA, et al. Routine versus selective exploration of penetrating neck injuries: a radiological prospective study. *J Trauma* 1984;24:1010-1014
29. Bishara RA, Pasch AR, Douglas DD, et al. The necessity of mandatory exploration of penetrating zone II injuries. *Surg* 1986;100(4): 655-660.
30. Mohammed GS, Pillay WR, Barker P, Robbs JV. The role of clinical examination in excluding vascular injury in haemodynamically stable patients with gunshot wounds to the neck. A prospective study of 59 Patients. *Eur J Vasc Endovasc Surg* 2004;28(4):425-430.
31. Kuzniec S, Kauffman P, Molnar LJ, et al. Diagnosis of limbs and neck arterial trauma using duplex ultrasonography. *Cardiovas Surg* 1998;6:358-366.
32. Unal M, Akbas Y, Pata YS, et al. A gunshot wound in zone III of the neck with an atypical bullet trajectory and its management. *J Emerg Med* 2005;28(3):349-351.
33. Munera F, Cohn S, Rivas LA. Penetrating injuries of the neck: Use of helical computed tomographic angiography. *J Trauma* 2005; 58:413-418.
34. Leblang SD, Nunez DB, Rivas LA, et al. Helical computed tomographic angiography in penetrating neck trauma. *Emerg Radiol* 1997;4:200-206.
35. Munera F, Soto JA, Palacio D, et al. Diagnosis of arterial injuries caused by penetrating trauma to the neck: Comparison of helical CT angiography and conventional angiography. *Radiology* 2000;216: 356-362.
36. Munera F, Soto JA, Palacio D, et al. Penetrating neck injuries: Helical CT angiography for initial evaluation. *Radiology* 2002;224: 366-372.
37. Demetriades D, Velmahos GG, Asensio JA. Cervical pharyngoesophageal and laryngotracheal injuries. *World J Surg* 2001;25: 1044-1048.
38. Gonzales RP, Falimirski M, Holevar MR, Turk B. Penetrating zone II neck injury: Does dynamic computed tomography scan contribute to the diagnostic sensitivity of physical examination for surgically

CNE/CME Objectives

Upon completing this program, the participants will be able to:

a.) discuss conditions that should increase suspicion for traumatic injuries;
b.) describe the various modalities used to identify different traumatic conditions;
c.) cite methods of quickly stabilizing and managing patients; and
d.) identify possible complications that may occur with traumatic injuries.

CNE/CME Instructions

Physicians and nurses participate in this continuing medical education/continuing education program by reading the article, using the provided references for further research, and studying the questions at the end of the article. Participants should select what they believe to be the correct answers, then refer to the list of correct answers to test their knowledge. To clarify confusion surrounding any questions answered incorrectly, please consult the source material. **After completing this activity, you must complete the evaluation form provided and return it in the reply envelope provided in order to receive a letter of credit.** When your evaluation is received, a letter of credit will be mailed to you.

significant injury? A prospective blinded study. *J Trauma* 2003; 54:61-65.
39. Grewal H, Rao PM, Mukerji S, Ivatury RR. Management of penetrating laryngotracheal injuries. *Head Neck* 1995;17:494-502.
40. Symbas PN, Hatcher CR Jr, Vlasis SE. Esophageal gunshot injuries. *Ann Surg* 1980;191:703-707.
41. Glatterer MS, Toon RS, Ellestad C, et al. Management of blunt and penetrating external esophageal trauma. *J Trauma* 1985;25:784-92
42. Armstrong WB, Detar TR, Stanley RB. Diagnosis and management of external penetrating cervical esophageal injuries. *Ann Otol Rhino Laryngol* 1994;103:863-871.
43. Mandavia DP, Qualls S, Rokos I. Emergency airway management in penetrating neck injury. *Ann Emerg Med* 2000;35(3):221-225.
44. Weitzel N, Kendall J, Pons P. Blind nasotracheal intubation for patients with penetrating neck trauma. *J Trauma* 2004;56:1097-1101.
45. Desjardins G, Varon AJ. Airway management for penetrating neck injuries: The Miami experience. *Resuscitation* 2001;48:71-75.
46. Steinfeldt J, Bey TA, Rich JM. Use of a gum elastic bougie (GEB) in a zone II penetrating neck trauma: a case report. *J Emerg Med* 2003;24(3):267-270.
47. Ferguson E, Dennis JW, Vu JH, Frykberg ER. Redefing the role of arterial imaging in the management of penetrating zone 3 neck injuries. *Vascular* 2005;13:158-163.
48. Kim MK, Buckman R, Szeremeta W. Penetrating neck trauma in Children: An urban hospital's experience. *Otolaryngol Head Neck Surg* 2000;123(4):439-443.

CNE/CME Questions

1. Which of the following anatomical areas of the neck is the most common site of injury in penetrating neck injuries?
   A. Zone III
   B. Zone II
   C. Zone I
   D. Posterior triangle

2. Which of the following is the most commonly missed significant injury in penetrating neck trauma?
   A. Spinal fracture
   B. Carotid dissection
   C. Jugular vein laceration
   D. Esophageal injury

3. Which of the following anatomical areas of the neck has the highest mortality in penetrating neck injuries?
   A. Zone III
   B. Zone II
   C. Zone I
   D. Posterior triangle

4. Which of the following is a "hard sign" of vascular trauma?
   A. History of extensive bleeding at the scene
   B. Nonexpanding hematoma
   C. Palpable thrill
   D. Extensive associated injuries

5. Which of the following arteries is most commonly injured in penetrating neck trauma?
   A. Common carotid artery
   B. Vertebral artery
   C. Subclavian artery
   D. Internal Carotid artery

6. Which of the following injuries is most likely to be associated with a zone I injury to the neck?
   A. Vertebral artery transaction
   B. Esophageal tear
   C. Hemothorax
   D. Salivary gland injury

7. Which of the following statements regarding airway management in a patient with penetrating neck trauma is most true?
   A. Cricothyrotomy is recommended.
   B. Nasotracheal intubation is absolutely contraindicated.
   C. There is no clear consensus on airway management.
   D. Noninvasive airway management is preferred over endotracheal intubation.

8. What of the following procedures is the most appropriate step in a neck wound that does not penetrate the platysma and is located in zone II in a patient without other symptoms?
   A. Local wound care
   B. Helical CT study
   C. Angiography
   D. Esophagram

9. What are the anatomical boundaries of zone I regarding penetrating neck trauma?
   A. Between the cricoid cartilage and the angle of the mandible
   B. Extends from the sternal notch to the cricoid cartilage
   C. Above the angle of the mandible to the base of the skull
   D. Below the sternal notch

10. Which of the following characteristics is an advantage of color flow ultrasound compared with angiography?
   A Readily available
   B. More accurate in zone III
   C. Noninvasive
   D. Better evaluation of smaller arterial branches

Answers: 1. B; 2. D; 3. C; 4. C; 5. A; 6. C; 7. C; 8. A; 9. B; 10. C

In Future Issues: **Airway management in the pediatric trauma patient**

AHC Media LLC

Dear *Trauma Reports* Subscriber:

This issue of your newsletter marks the start of a new continuing medical education (CME) or continuing nursing education (CNE) semester and provides us with an opportunity to review the procedures.

Trauma Reports, sponsored by AHC Media, provides you with evidence-based information and best practices that help you make informed decisions concerning treatment options and medical practices. Our intent is the same as yours — the best possible patient care.

The objectives of *Trauma Reports* are to:

1. Discuss conditions that should increase suspicion for traumatic injuries;
2. Describe the various modalities used to identify different traumatic conditions;
3. Cite methods of quickly stabilizing and managing patients; and
4. Identify possible complications that may occur with traumatic injuries.

Each issue of your newsletter contains questions relating to the information provided in that issue. After reading the issue, answer the questions at the end of the issue to the best of your ability. You can then compare your answers with the correct answers provided in an answer key in the newsletter. If any of your answers were incorrect, please refer back to the source material to clarify any misunderstanding.

Enclosed in this issue is an evaluation form to complete and return in an envelope we will provide. Please make sure you sign the attestation verifying that you have completed the activity as designed. Once we have received your completed evaluation form we will mail you a letter of credit. This activity is valid 24 months from the date of publication. The target audience for this activity is emergency, trauma, and surgical physicians and nurses.

If you have any questions about the process, please call us at (800) 688-2421, or outside the U.S. at (404) 262-5476. You can also fax us at (800) 284-3291, or outside the U.S. at (404) 262-5525. You can also email us at: customerservice@ahcmedia.com.

On behalf of AHC Media, we thank you for your trust and look forward to a continuing education partnership.

Brenda L. Mooney

Brenda Mooney
Vice-President/Group Publisher
AHC Media, LLC