AHC Media LLC

Rapid Reference Card Enclosed

The Practical Journal for Emergency Physicians

Emergency Medicine Reports®

Volume 28, Number 11 May 14, 2007

The last issue of Emergency Medicine Reports *reviewed the anatomy, biomechanics, examination, and bony injuries of the knee. While fractures can be serious and limb-threatening, they are not the most common knee condition seen in the emergency department. Soft-tissue injuries or conditions constitute the majority of disorders that present with knee pain. In my experience, greater patient satisfaction and more appropriate referral occurs if the emergency physician can ascertain these conditions and explain them to the patient. In addition, because these soft-tissue conditions are more difficult to detect, greater medical-legal liability can often occur if these conditions are missed.*

—J. Stephan Stapczynski, MD, Editor

Evaluation of the Acutely Injured Knee in the ED: Diagnosis and Treatment. Part II.

Authors: **Gary D. Hals MD, PhD**, Attending Physician, Department of Emergency Medicine, Palmetto Richland Memorial Hospital, Columbia, SC; **Steven Cruea, MD**, Resident Physician, Department of Emergency Medicine, Palmetto Richland Memorial Hospital, Columbia, SC; and **Dusty Moses, MD**, Resident Physician, Department of Emergency Medicine, Palmetto Richland Memorial Hospital, Columbia, SC.

Peer Reviewers: **Andrew D. Perron, MD**, Residency Program Director, Maine Medical Center, Portland; and **Timothy C. Stallard, MD**, Program Director, Emergency Medicine Residency, Texas A&M Health Sciences Center, Scott & White Hospital, Temple, TX.

Dislocations

Knee Dislocations. The term knee dislocation refers to dislocation of the tibia in relation to the femur, or tibial-femoral dislocation. Knee dislocations classically have been a rare injury, compared to other joint dislocations such as the shoulder, hip, or ankle.[1] However, some authors report increasing incidence of knee dislocation.[2] One explanation offered was that nearly 50% of knee dislocations either reduce spontaneously in the field or are reduced by paramedics/EMTs before arrival at the ED.[3] Knee dislocations are an orthopedic emergency because injury to the popliteal artery is common and can lead to disastrous consequences if not diagnosed and treated in a timely fashion. Failing to recognize popliteal injury with knee dislocation puts the

Statement of Financial Disclosure

To reveal any potential bias in this publication, and in accordance with Accreditation Council for Continuing Medical Education guidelines, we disclose that Dr. Farel (CME question reviewer) owns stock in Johnson & Johnson. Drs. Hals (author), Cruea (author), Moses (author), Perron (peer reviewer), Stallard (peer reviewer), Schneider (editor), and Stapczynski (editor) report no relationships with companies related to the field of study covered by this CME activity.

patient at significant risk of amputation and increases overall morbidity.[4]

Knee dislocations most often result from high-energy forces, with motor vehicle accidents causing 66% of cases.[5] As expected, the majority of these patients are males in their teens and 20s.[3] Motorcycles and pedestrians struck by a vehicle account for a higher proportion of knee dislocations as they lack the protection of the vehicle compartment. Falls from a height, industrial accidents, and sporting injuries cause the majority of the other cases. Recently, knee dislocations also have been reported in obese patients without history of trauma, i.e., resulting from performing activities of daily living.[4,6] Be aware that while knee dislocation may be clinically obvious in normal-size patients, knee dislocation may not be as clinically obvious in the morbidly obese. Only patients with dislocations resulting from lower-velocity injuries (sports, simple falls) typically have isolated knee trauma, with all other patients being at high risk of multiple trauma.

Knee dislocations are classed by the position of the tibia in relation to the femur, and can be anterior, posterior, medial, lateral, or rotary. Anterior dislocations are by far the most common and account for 50-60% of cases.[5] Anterior dislocations result from significant hyperextension of the knee and cause complete tears of both the ACL and PCL. Without ligament support, the tibia is pushed forward on the femur. Cadaver studies estimate that only 30° of hyperextension is required to produce this injury.[7] Posterior dislocations are the second most common type, and typically result from a direct blow to the tibia when the knee is flexed (i.e., dashboard striking knee). Medial and lateral dislocations occur less frequently and cause tears of MCL and LCL, respectively, in addition to cruciate ligament disruption. Tibial plateau fractures are also seen in 20% of medial/lateral dislocations, and generally do poorly.[8] Only rotary dislocations may leave the cruciate ligaments intact, but typically they are also damaged.

Common complications from knee dislocation include vascular and nerve injury. Both occur from traction injuries where the artery or nerve is stretched beyond its limits by the dislocation. Vascular (popliteal artery) injuries can be severe and lead to loss of limb if not recognized and treated rapidly (*see next section*). Nerve injuries also occur, but are not as frequent as vascular trauma because the peroneal and tibial nerves are not fixed as securely in place as the popliteal artery. The peroneal nerve is affected more often than the tibial nerve, with incidence of injury ranging from 14-35%.[9] Prognosis of the resulting foot drop is poor, with permanent disability seen in 50-80% of cases.[5,9]

In addition to vessels and nerves, the skin can also be stretched to the point of injury during dislocation. One series found that 20%-30% of dislocations are open joint injuries, and these most commonly result from high-energy injuries.[10] Open dislocations most often result from anterior or posterior dislocations. As expected, prognosis is poor in these cases. Due to the large amount of soft-tissue damage or subsequent infection, amputation rates are near 40%.[11] The outlook for patients who do not lose their limbs is not much better, with functional outcomes classed as only fair to poor.[11]

Diagnosis of knee dislocation with plain films is usually straightforward, except in cases of posteriolateral or rotary dislocation where radiograph interpretation may be more challenging. Be careful to note any associated fractures. Treatment of acute knee dislocations centers on urgent reduction, evaluation for vascular injury (*see next section and Figure 1*), and orthopedic consultation for admission. Reduction usually does not require general anesthesia and is performed using simple traction/countertraction. Remember, once dislocation is recognized, reduction should be performed as quickly as possible. While one may need to wait for IV access and appropriate analgesia, do not delay reduction for imaging, phone consultation, etc. This is especially true for patients with any sign of vascular compromise, as blood flow may be improved by reduction which may reduce risk of further complication. After reduction, immobilize the limb with a long leg splint at 15°-20° of flexion. Disposition is usually not an issue as many patients will have other associated injuries that require admission for further treatment. However, be aware that in patients with isolated knee dislocations current literature suggests that all patients be admitted to observe for delayed indications of vascular injury or compartment syndrome.[4]

Popliteal Artery Injury in Knee Dislocation. Popliteal artery injury is the most feared complication resulting from knee dislocation. In World War II popliteal injuries lead to a 72%

Emergency Medicine Reports™ (ISSN 0746-2506) is published biweekly by AHC Media LLC, 3525 Piedmont Road, N.E., Six Piedmont Center, Suite 400, Atlanta, GA 30305. Telephone: (800) 688-2421 or (404) 262-7436.

Senior Vice President/Group Publisher: Brenda Mooney
Associate Publisher: Lee Landenberger
Specialty Editor: Shelly Morrow Mark
Marketing Manager: Shawn DeMario
GST Registration No.: R128870672

Periodicals postage paid at Atlanta, GA. **POSTMASTER:** Send address changes to ***Emergency Medicine Reports***, P.O. Box 740059, Atlanta, GA 30374.

Back issues: $31. Missing issues will be fulfilled by customer service free of charge when contacted within one month of the missing issue's date.

Multiple copy prices: One to nine additional copies, $359 each; 10 to 20 additional copies, $319 each.

Subscriber Information

Customer Service: 1-800-688-2421

Customer Service E-Mail: customerservice@ahcmedia.com
Editorial E-Mail: shelly.mark@ahcmedia.com

World Wide Web page: http://www.ahcmedia.com

Subscription Prices

1 year *with* 60 ACEP/60 AMA/60 AAFP Category 1/Prescribed credits: $544
1 year *without* credit: $399
Add $9.95 for shipping & handling
Resident's rate $199
Discounts available for group subscriptions.
For pricing information, call Tria Kreutzer at (404) 262-5482.

All prices U.S. only.
U.S. possessions and Canada, add $30 plus applicable GST. Other international orders, add $30.

Accreditation

AHC Media LLC is accredited by the Accreditation Council for Continuing Medical Education to provide continuing medical education for physicians.

AHC Media LLC designates this educational activity for a maximum of 60 *AMA PRA Category 1 Credits™*. Physicians should only claim credit commensurate with the extent of their participation in the activity.

Approved by the American College of Emergency Physicians for 60 hours of ACEP Category 1 credit.

Emergency Medicine Reports has been reviewed and is acceptable for up to 39 Prescribed credits by the American Academy of Family Physicians. AAFP accreditation begins 01/01/07. Term of approval is for one year from this date. Each issue is approved for 1.50 Prescribed credits. Credit may be claimed for 1 year from the date of each issue. The AAFP invites comments on any activity that has been approved for AAFP CME credit. Please forward your comments on the quality of this activity to cmecomment@aafp.org.

This is an educational publication designed to present scientific information and opinion to health professionals, to stimulate thought, and further investigation. It does not provide advice regarding medical diagnosis or treatment for any individual case. It is not intended for use by the layman. Opinions expressed are not necessarily those of this publication. Mention of products or services does not constitute endorsement. Clinical, legal, tax, and other comments are offered for general guidance only; professional counsel should be sought for specific situations.

This CME activity is intended for emergency physicians. It is in effect for 24 months from the date of the publication.

AHC Media LLC

For Customer Service and CME questions,

Please call our customer service department at **(800) 688-2421.** For editorial questions or comments, please contact **Shelly Morrow Mark,** Specialty Editor, at shelly.mark@ahcmedia.com or (352) 351-2587.

Figure 1. Algorithm for Evaluation and Treatment of Knee Dislocations

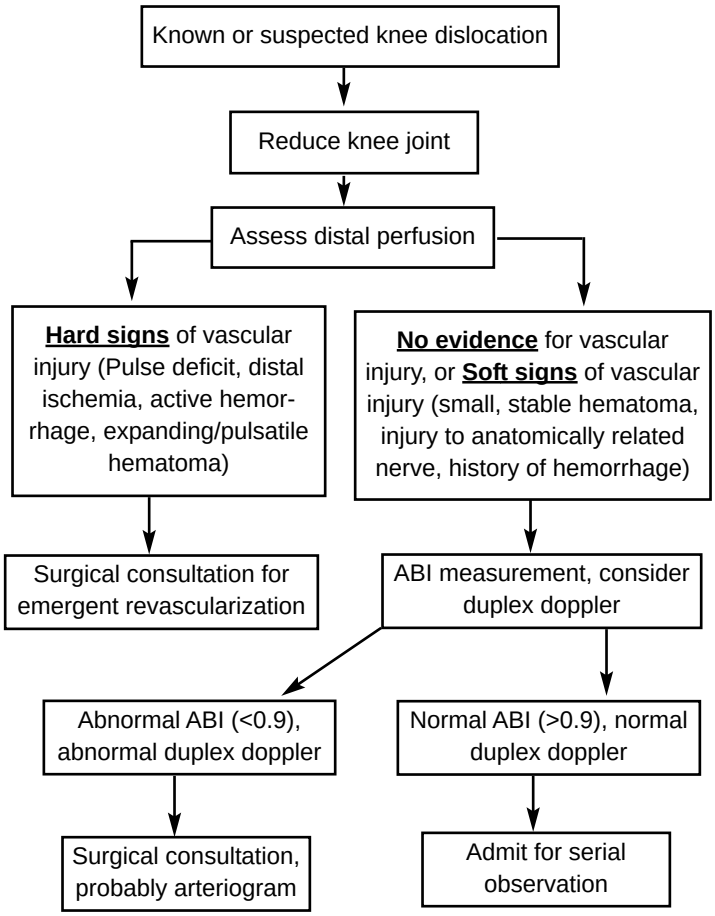

Note hard signs of arterial injury prompt immediate orthopedic consultation/transfer for definitive care. Also even if studies evaluating popliteal artery are normal, the patient should be admitted for observation.

Reprinted from: *American Journal of Emergency Medicine*, volume 19, Perron AD, Brady WJ, Sing RF. Orthopedic pitfalls in the ED: Vascular injury associated with knee dislocation. Pages 583-588, Copyright © 2001, with permission from Elsevier.

amputation rate,[12] but current advances in care have only reduced this rate to around 30%.[13] These injuries occur in dislocation because the artery is anatomically tethered against the distal femur. The large displacement that occurs in knee dislocation can easily injure the artery. Popliteal artery injuries are so important because too little collateral flow usually exists to keep the limb perfused. Anterior dislocations tend to severely stretch the artery producing damage over a longer section, where posterior ones tend to cause isolated transaction of the artery. Studies vary in estimating the incidence of artery injury from 14-65%.[14] Dislocations resulting from high-energy mechanisms (motor vehicle accident, motorcycle accident, pedestrian accidents) tend to produce more of the vascular injuries than do lower-energy mechanisms. However, the degree of hyperextension that occurs is a deciding factor regardless of the mechanism of injury. Cadaver studies estimate that the popliteal artery ruptures at about 50° of hyperextension.[7] Although anterior and posterior dislocations are higher risk for arterial injury than lateral/medial/rotary types,[4] any type of dislocation may result in significant arterial injury.

Further, patients who present with dislocations spontaneously reduced prior to ED presentation carry the same risk of vascular injury.[3] Thus in patients with clinical signs of vascular compromise where no other obvious cause of injury can be detected, the diagnosis of spontaneously reduced knee dislocation should be considered. Be aware that the expected hemarthrosis may be absent due to vascular injury.[9] Spontaneous reduction of knee dislocation should also be considered in patients with significant knee pain with no apparent cause after trauma. Given the substantial ligament damage occurring with knee dislocation, clinical evidence of gross knee instability should help identify these patients.

While one must evaluate for popliteal artery injury in all patients presenting with knee dislocation or spontaneously reduced dislocation,[15] the exact approach to take can be controversial. Nearly half of the patients with dislocation will not suffer vascular injury and one would like to avoid unnecessary invasive testing. On the other hand, not all popliteal artery injuries will be clinically obvious in the ED and delay of definitive repair can be disastrous. Several studies have shown that when surgical repair is preformed more than 8 hours after injury the amputation rate remains about 85%, but when repair is done less than 8 hours after injury the amputation rate drops to about 15%.[4,5] Delay to diagnosis is cited in most series as the single factor responsible for limb loss.[16] In one recent review, patients at higher risk for delay of diagnosis were multiple trauma patients.[17] As expected, in these critical patients care of obvious life-threatening injuries may preclude extremity films, especially in those with no external signs of injury at presentation.

In the past, all patients with knee dislocation were referred for arteriography.[18,19] More recent studies have suggested that not all patients need to undergo invasive imaging.[20-22] Specifically, authors suggest following serial physical examination for signs of vascular compromise[20,21] or using duplex Doppler tests (ABI < 0.9 defined as abnormal) to differentiate which patients require arteriography.[4,23] Doppler studies have been shown to be95% sensitive and 99% specific for arterial injury, but are known to miss intimal tears.[23] One attempt at a meta-analysis of past studies found that abnormal pedal pulses were only 79% sensitive and 91% specific for popliteal artery injury requiring surgical repair.[24] These authors concluded that arteriography should still be performed on knee dislocations to evaluate for vascular damage.

Regardless of the debate on which approach to take for patients where arterial injury is not clinically evident, all authors agree that "hard" signs of vascular injury require urgent repair rather than additional testing. (*See Table 1.*)[1,25] Hard signs of vascular injury include: evidence of ischemia (cool, cyanotic foot), obvious pedal pulse deficits (especially when compared to the unaffected side), expanding pulsatile mass in popliteal fossa, and active arterial bleeding.[1,25] Any patient with knee dislocation and one or more of these signs needs to have emergent surgical consultation. Remember that roughly 10% of patients with popliteal artery injury will retain normal pedal pulses.[13]

Thus current recommendations for evaluating patients in the ED with acute knee dislocation are as follows. (*See Figure 1.*) Key points to remember in caring for knee dislocations are summarized in Table 1. Any patient with clinical evidence of vascular injury should be referred urgently for surgical repair instead of testing. Patients without clinical evidence of vascular injury after reduction should be consulted for serial physical exams and/or Doppler studies at the discretion of the consultant. Even patients who have normal arteriography should be admitted for 24-48 hours of observation to screen for compartment syndrome (from prolonged limb ischemia) or other delayed complications.[4]

Patellar Dislocations. Patellar dislocations are relatively common with children and younger adults being at highest risk. The majority of dislocations occur in patients with baseline anatomic abnormalities (patellofemoral dysplasia).[26] Support for this idea comes from the 49% re-occurrence rate observed,[27] and the fact that patients often dislocate both patella at some point in life. Some authors have suggested women are more commonly affected than men,[28] while others suggest the reverse.[29] Regardless of the sex of the patient, most patellar dislocations actually occur as the result of sports. One study found that up to 72% of dislocations were the result of sporting activity.[30] The most common mechanisms of injury described were direct blows to the medial patella, or planting the foot while pivoting the body.

Nearly all patellar dislocations are lateral ones. As a result, the patella stretches or tears the medial retinaculum during dislocation. Patients present with a partially flexed knee, and inability to move the knee or bear weight. In non-obese patients one can usually appreciate the laterally displaced patella. Realize that some patients may spontaneously reduce in the field, and therefore they may only present with a knee effusion. Reduction is normally easily accomplished by applying medial pressure to the patella and simultaneously straightening the leg. Cases of difficult reduction have been described.[31,32] This can be due to intra-articular dislocations, which occur rarely.[32] Plain films should easily identify this condition. These patients present with knee locked in near full extension and may require open reduction. Another more common cause of difficult reduction can be when the medial facet of an internally rotated patella locks on the lateral femoral condyle.[31,32] In these cases, applying downward pressure on the lateral edge of the patella may help release it and aid reduction.[31]

Although pre-reduction films are not routinely indicated, post-reduction films are recommended to screen for small fractures. A surprisingly high number of patients (30-40%) in one study had associated osteochondral fractures.[33] Some patients may only have cartilage damage resulting from the dislocation. One study of military recruits where every patient with dislocation had arthroscopy found that an unexpected 76% had damaged cartilage.[34] Once reduced, patients can be discharged with the knee immobilized in full extension, made non-weight bearing, and pain treated with ice, elevation, and analgesics. Orthopedic follow-up is required as most recommend immobilization for 3-6 weeks so the medial retinaculum can heal. Current orthopedic texts estimate about 50% of patients will do well with this treatment.[35] Likewise, some patients will do better with surgery, but in others it does not seem beneficial. Not enough prospective studies have been done to show which subgroups of patients do well with conservative vs. surgical treatment, but in general most orthopedists treat patients with non-operative therapy first. Patients with congenital predisposition for dislocation, or those with loose osteochondral fragments are the ones most often treated surgically.[36,37]

Table 1. Key Points in ED Care of Acute Knee Dislocation (Tibial-Femoral Dislocation)

1. All knee dislocations need evaluation for integrity of popliteal artery
   - Use of arteriography, serial exams, Doppler studies at discretion of consultant.
2. Any patient with "hard signs" of arterial injury requires emergent consultation for arterial repair.[1,25] Hard signs include:
   - Cool, cyanotic foot
   - Obvious pedal pulse deficits
   - Expanding pulsatile mass in popliteal fossa
   - Active arterial bleeding
3. Presence of pedal pulse dose not rule out arterial injury
   - 10% of popliteal artery injuries will have normal pedal pulse.[13]
4. Time to arterial repair is critical to prevent amputation
   - Goal is < 6 – 8 hours of ischemia
   - > 8 hours delay of repair raises amputation rate from 15% to 85%[4,5]
5. Acute knee dislocations should be reduced as soon as possible after diagnosis
   - It is not necessary to wait for films, phone consultations before reduction
   - It is advisable to wait for IV sedation to aid in reduction procedure
6. All patients with acute knee dislocation should be admitted for observation.[4]

Soft-Tissue Injuries

Quadriceps Tendon Rupture. The quadriceps muscle group (rectus femoris, vastus lateralis/medialis/intermedius) are the primary knee extensors. They form a common tendon that attaches to and contains the proximal patella. The quadriceps tendon is the portion proximal to the patella and the patellar tendon is the distal section (*see next section*). Rupture of the quadriceps tendon occurs about three times as often as rupture of the patellar tendon,[38] and also is misdiagnosed more often.[39] Injuries can be complete or partial. Partial tears are seen in younger patients resulting from athletic injuries, and complete tears are usually seen in patients 40 years old or older.[1] One study found 88% of injuries were in patients older than 40 years.[40] Besides age, other risk factors cited for tendon rupture include steroid use, especially when used for immunosuppression in transplant recipients,[39]

and systemic illness (diabetes, rheumatoid arthritis, gout, and lupus). One large series on 891 patients with spontaneous tendon ruptures found that ruptures of any tendon (quadriceps, Achilles, patella, etc.) were only seen in those with pathologic degeneration, such as chronic tendinitis and calcification.[41]

Most injuries are unilateral, but bilateral injuries have been reported and are more likely to be misdiagnosed.[42] The most common mechanism of injury cited is forceful, rapid contraction of the quadriceps muscle group with the foot planted and knee partially flexed; direct blows and lacerations also can cause rupture. Ruptures can also occur with relatively minor trauma; in 1997 President Clinton ruptured his quadriceps tendon when he caught his heel on a step and briefly stumbled. Ruptures typically occur at 1-2 cm proximal to the superior pole of the patella. As with Achilles tendon ruptures, some patients report hearing a loud "pop" at the time of injury. Patients present with pain, swelling, and ecchymosis in the proximal knee. Complete tears will lead to loss of active knee extension, but partial tears may be more difficult to diagnose in the ED as knee extension will be preserved.

Plain films of the knee may reveal an abnormally low-riding patella or "patella baja." Other findings include quadriceps tendon calcifications, and small avulsion fracture(s) of the superior aspect of the patella. As one might suspect, these findings are not often seen on plain radiographs. Other imaging studies are usually needed to make the diagnosis, and in the past MRI has been the modality of choice. However, recently ultrasound has also been used to diagnose quadriceps tendon injury.[43] Ultrasound has been shown to be useful in distinguishing partial and complete tears as well.[44] MRI does retain the advantage of visualization of all other knee structures with the same study.

Treatment varies with the degree of injury. Partial tears can be treated with 4-6 weeks of immobilization in full extension, with only partial weight-bearing during the first 4 weeks. Surgical repair provides the best outcome in cases of complete ruptures. Further, surgical intervention during the first 2-4 weeks after injury yields a much better outcome than delayed treatment.[1] Thus, accurate diagnosis of these injuries on the first visit to the ED is central to their treatment. Later surgery is complicated by the retraction of the quadriceps tendon.

Patellar Tendon Rupture. The patellar tendon completes the attachment of the quadriceps muscle group to the tibial tuberosity, and is the portion between the inferior patellar pole and the tibial attachment. Risk factors and mechanism of injury for the patellar tendon are similar to quadriceps tendon injury (*see previous section*). The peak incidence of injury is in the fourth and fifth decades, and it has been shown that nearly 100% of ruptured tendons show signs of preexisting degeneration.[41] Except for penetrating injury, most ruptures occur from forceful contraction of the quadriceps with partial knee flexion. However, a significant difference from quadriceps tendon injuries is that patellar injuries are usually complete ruptures.[38]

Most patients report hearing or feeling a "pop" and since there is less soft-tissue coverage, the tendon defect can be felt more easily than in quadriceps tendon ruptures. However if enough time has passed to allow swelling, one may not be able to palpate the defect. Complete ruptures lead to loss of active knee extension, and patients will complain of difficulty walking up inclines or up stairs. Plain films will be done to rule out patellar fractures, and may show some diagnostic findings. Patella ala, or a high-riding patella, may be seen on the lateral knee view. Small avulsions from the inferior patellar pole or calcification of the patellar tendon may also be seen. MRI has been the gold standard to image patellar tendon injuries, but ultrasound has also been used in this regard.[45] As with quadriceps tendon injuries partial tears can be treated with immobilization for 4-6 weeks, but complete tears require surgical repair.

Ligament Injury. *Anterior Cruciate Ligament (ACL).* The ACL is intra-articular, and attaches to the posteromedial portion of the lateral femoral condyle superiorly, and to the anterior intercondylar area on the tibia inferiorly. While both the ACL and PCL together act as the primary ligaments stabilizing anterior/posterior movements of the tibia on the femur, ACL injuries are much more common than PCL injuries (approximately 9:1).[46] A main reason for this difference is that besides preventing anterior displacement of the tibia, the ACL also acts to prevent hyperextension and rotation of the knee when cutting, twisting, or turning. These abrupt pivoting motions are pervasive in a variety of popular sports (especially football, basketball, soccer, and skiing), placing literally millions of people at risk every year for ACL injuries. Indeed, the ACL is the most commonly injured ligament with more than 200,000 ruptures (or 1 of every 3000 people) documented yearly in the United States alone.[47] ACL injuries are even more common in patients aged 15-40 years, with an annual incidence of 1 in 1750 people.[48] The majority (70-80%) of ACL injuries occur through non-contact (pivoting) mechanisms.[49] Contact injuries consist of a direct blow to the flexed knee, such as in MVAs, or in "clipping" injuries where the patient's knee is struck laterally as is common in football tackling, causing the "unhappy triad" of ACL, MCL, and medial meniscus injury. Damage to other knee structures is common with all ACL injuries; up to 50% of patients will have associated meniscal tears.[46]

As more women have entered athletics over the last few decades, it has become apparent that when playing the same sports (basketball, soccer, volleyball, rugby, and track and field), women athletes are at higher risk than men for ACL injury.[50] Specifically, women are 4-8 times more likely to suffer ACL injuries in basketball and 2.5 times more likely in soccer.[50] Much research has been done to determine the basis for this difference in injury risk. While factors such as anatomical differences between the knee joint (for example increased laxity), effects of estrogen on ACL tissue, influence of menstrual cycle on injury rates, use of oral contraception pills, fatigue and conditioning have all been studied, conclusive answers have yet to be defined. It is likely that a multitude of factors combine to increase women's risk for ACL injury in sports, but it is important that the emergency physician be aware of their increased risk.

Patients will present with history of knee injury and about 70% will state they heard or felt a "pop" at the time of injury.[1] Many will note knee instability after injury, and complain of knee "giving out," buckling, locking, or inability to bear weight. Some patients state

that a partial tear is more painful than a complete one. The ACL is well vascularized, and rupture will produce a large hemarthrosis in 70% of cases by 4-6 hours.[51] The rapidly developing hemarthrosis is not specific for ACL injury, as damage to any intra-articular structure will produce it as well. Other common injuries that produce acute hemarthrosis include: patellar dislocations, PCL injuries, meniscal tears, and osteochondral fractures.[1] In some cases the hemarthrosis will be tense and painful, however one should discuss with the consultant who will see the patient in follow-up before routinely aspirating the effusion just for pain relief.

Plain radiographs are taken to rule out other conditions (fractures, dislocations) and typically will not identify ACL injury. However in some cases, one can see small avulsion fractures associated with ACL rupture. The Segond fracture, or avulsion of the lateral aspect of the tibial plateau, is highly suggestive of ACL rupture. An avulsion of the tibial spine also correlates with ACL rupture, and is seen in 40% of adults and 60% of children with ACL injuries.[52] Ultrasound has also been used to identify ACL injury, but uses indirect signs to diagnose damage. Thus, while sensitivities are reported as high (98%),[53] when prospectively compared to arthroscopy the specificity is lower (50%).[54]

Definitive diagnosis of ACL tears can be performed using three main approaches: stability testing, MRI, or arthroscopy. Obviously arthroscopy is the gold standard for diagnosis, but it is not part of the emergency physician's armamentarium. MRI is very good at defining ACL pathology as well as detecting other co-existing injuries whose presence will impact treatment decisions by the consultant. Identification of co-existing PCL, LCL, or meniscal tears can alter surgical planning, timing, and outcomes and is important to recognize early in treatment. However, MRI may not be available on demand in the acute setting at all centers. Three stability tests are used for diagnosing ACL injury: the Lachman's, anterior drawer, and pivot shift tests. (*See section on stability testing in Part I.*) Of these, only the Lachman's test is recommended for use in the acute setting. The pivot shift test can actually worsen ACL damage when performed during the acute phase.[1] As mentioned previously, some patients may not tolerate stability tests even with appropriate analgesia. Ultimately as long as one has ruled out diagnoses that require urgent orthopedic consultation (fracture, spontaneously reduced dislocation, for example), in many cases it is appropriate to discuss the case with an orthopedist to confirm follow-up in a 1-3 day period and schedule the patient for an outpatient MRI. Both surgical and non-surgical approaches are used to treat ACL injuries, and the choice should be individualized for each patient. Most younger, active patients with complete ACL rupture, associated PCL rupture, or meniscal injury will be treated with surgical reconstruction using autografts (typically from the patellar tendon). Regardless of which treatment option is taken, patients can be discharged to follow-up with an orthopedist in a knee immobilizer, made non-weight bearing until follow-up, and given adequate analgesics. Ice packs and elevation can also help reduce pain.

Posterior Cruciate Ligament (PCL). The PCL attaches to the lateral border of the medial femoral condyle and to the posterior tibial plateau. Essentially it sits just behind the ACL, and together the two ligaments form a "cross" at the center of the knee. Like the ACL it is enclosed in a synovial envelope, and is thus intra-articular but extrasynovial. The PCL's primary function is to restrain posterior movement of the tibia on the femur. It also resists external tibial rotation, but is secondary in this regard to the ACL. While the ACL is commonly injured, PCL injuries are more unusual and account for only 3% of all knee ligament injuries in the general population.[55] The incidence of injury in athletes is only slightly higher (4%).[46] A prime reason for this difference is the inherent strength of the PCL. It is twice as strong as the ACL, with a cross-sectional area 1.5 times that of the ACL as well as higher tensile strength.[46]

PCL injuries can be isolated or, more commonly, occur in combination with other ligamentous damage. The most common mechanism of isolated PCL injury is through hyperflexion. A direct blow to the anterior tibia in a flexed knee (forcing the tibia posteriorly) is the second most common manner in which PCL injuries occur, such as in MVAs or falling forward on a flexed knee. Hyperextension combined with varus or valgus force can also produce PCL injuries. However, direct blows and hyperextension mechanisms do not produce isolated injuries to the PCL. Up to 95% of these patients will have co-existing ligament damage in the same knee.[56] The most common co-existing ligament injuries include: ACL (65%), MCL (50%), and medial meniscus (30%) with many patients having more than one additional injury.[57]

While many patients with ACL injury will present complaining of hearing/feeling a "pop" at the time of injury, this is not the case with PCL tears. Patients also do not complain of knee instability early after injury as they do with ACL tears. They simply present with knee pain, swelling, and history of injury. Some patients state that a partial tear is more painful than a complete one. One should try to elicit the details on the mechanism of injury in cases where the patient can provide them. Given the vague nature of PCL injury presentation, it is not surprising that the diagnosis is often missed on their first visit to a physician.[58] The posterior drawer test and posterior sag test (*see section on stability testing in part I*) may be helpful if positive, but the pain and swelling of acute injury may prevent accurate testing.

Plain radiographs will be taken to rule out other injury, but rarely show findings useful in diagnosis of PCL injury. As only 7% of PCL tears are avulsion injuries, the avulsion fracture of the medial tibial plateau that correlates with PCL tears ("reverse Segond") is rare.[59] Likewise, as few PCL tears are isolated injuries, outpatient MRI scanning is recommended to fully define all ligament injuries present.

As with the ACL injury, after ED evaluation for other diagnoses that require urgent orthopedic consultation (fracture, spontaneously reduced dislocation for example), the patient can be discharged for close follow-up in the next 1-3 days. As with ACL injuries, the patient should be immobilized in full extension, made non-weight bearing until follow-up, and given appropriate analgesia. Clear indications for surgical treatment do not presently exist, but most surgeons will opt to repair complete PCL tears, especially those associated with avulsion fractures and those in young athletes.[46]

Medial Collateral Ligament. MCL injuries are very common

with some sources citing it as the most common knee ligament injury[1] and others citing the ACL.[46] These injuries often occur together as well, and the MCL is the most common associated injury with ACL tears. MCL damage often results from athletic activity. In fact, each year MCL injuries compete with ACL injuries as the most common sports injury overall in all age groups.[60] MCL injuries are common in football, soccer, snow skiing, and even in non-contact sports such as gymnastics and track and field events. In a one-year reporting period, the Nation Collegiate Athletic Association (NCAA) injury surveillance system found an incidence of 2 MCL injuries per 1000 players in all NCAA games.[60]

The MCL, ACL, and LCL comprise the primary knee stabilizers. The MCL runs along the medial knee from the medial femoral epicondyle and the medial tibia, and has both a superficial and deep component. The MCL is the primary ligament resisting valgus movement in all stages of flexion, but most of the stability comes when the knee is flexed. Thus most isolated MCL injuries occur from a direct blow to the lateral, flexed knee. When the patient can provide it, history on the exact mechanism of injury should be sought. As with most ligament injuries, partial tears cause more pain than complete ruptures. Isolated MCL injuries present with pain and swelling localized to the medial knee. The presence of a large effusion suggests a co-existing ACL and/or meniscal injury. Patients may note locking or catching sensations when moving the knee, which indicate meniscal damage. (*See section on meniscal injury.*) Complaints of knee instability are more common with ACL injury than with isolated MCL tears.

Stress testing (*see section on stability testing*) can be performed in the acute setting (when not precluded by pain), and in experienced hands can help grade the extent of injury as well as identify it. MCL injuries are graded as follows. Grade 1 injuries are mild sprains, and the patient will localize pain to the MCL, but will not have any joint laxity. Grade 2 injuries are partial tears, and patients will have joint laxity, but a firm end point will still be present when placing valgus stress. Grade 3 injuries are complete ruptures, and either a soft end point or no end point will be felt with valgus stress. One should also use the Lachman's test to examine the ACL when performing MCL stability testing, as the ACL is injured in approximately 20% of grade 1 injuries and as many as 78% of grade 3 injuries.[61]

Although clinical examination can be useful in diagnosis of MCL injury, plain radiographs should be taken to rule out osteochondral injury, loose bodies, and avulsion fractures of ligament attachments. Most patients with isolated MCL injury will have no findings on plain films, but those with associated ACL damage may have findings suggestive of its injury. MRI will likely be performed as an outpatient to fully evaluate the knee ligaments and to define the extent of injury. MRI has been shown to be effective in grading MCL injury and guiding treatment decisions, and is especially useful when physical examination is non-conclusive.[60]

Treatment of grade 1 and 2 injuries has been controversial in past, but the consensus now is that the best outcomes are achieved with non-surgical measures. All patients should be referred for orthopedic follow-up. Ice and an elastic bandage wrap with early mobilization is usually sufficient for grade 1 injuries. These patients should be able to bear weight without significant difficulty in the ED. Those with grade 2 injuries or those who cannot bear weight should be treated with crutches, knee immobilization, and ultimately early strengthening exercises. Isolated grade 3 tears can be treated without surgery, but those associated with ACL or meniscal tears are surgical candidates.

Lateral Collateral Ligament. The LCL attaches to the lateral femoral condyle and to the fibula. The ligament acts to resist tibial rotation and varus stress, and provides maximum support when the knee is in full extension. The most common mechanism of injury is a blow to the medial knee while in full extension. The LCL can also be injured by hyperextension injuries. LCL injuries tend to be more disabling than MCL ones, as the lateral ligaments stabilize normal gait more so than their medial counterparts.

Injuries to the LCL are much less common than ones to the MCL, with studies documenting LCL injury in only 7% to 16% of cases.[62,63] One reason is that the opposite knee usually guards the medial knee from trauma. Another may be that the LCL is stronger than the MCL, as greater force is required to produce LCL injury than for MCL injury. Thus, in contrast to MCL injuries where many cases are related to athletic activity, one recent study found 52% of LCL injuries were due to MVAs and only 25% were sports related.[64] Since greater forces are required, LCL injuries are more disabling than MCL ones and are less often isolated injuries. The ACL and PCL are the most common associated injuries.[60] Other associated injuries include the lateral meniscus and avulsion fractures of the fibular head. Since the MCL is directly attached to the underlying medial meniscus and the LCL is separated from the lateral meniscus by a small fat pad, menisci injuries are more commonly seen with MCL rather than LCL trauma.

Like with MCL injuries, patients will present with pain and swelling over the ligament when isolated injury occurs, but with knee effusion when other structures (cruciate ligaments) are damaged as well. Likewise, hearing a "pop" more likely indicates additional injury than just the LCL. When the patient can tolerate stability testing, one can try to assess the level of LCL injury. (*See section on stability testing*). Like with the MCL, a grading system exists based on physical findings. Grade 1 injury occurs with stress testing only producing lateral pain, but no joint opening. Grade 2 injury produces 5-10 mm of joint opening with a firm end point. Grade 3 represents complete rupture with joint laxity and no end point. Grade 3 injuries have a high association with cruciate ligament tears and fibular fractures. As with all fibular head injuries, remember to assess for common peroneal nerve function (ankle dorsiflexion and lateral leg sensation). Nerve injuries are relatively common in lateral knee trauma, with 15% of patients suffering nerve deficits.[65]

Plain radiographs can be taken to rule out bony injury, and most commonly will diagnose fibular head fractures, ACL avulsion fractures (Segond fractures), or PCL avulsion fractures (reverse Segond fractures). As with other knee ligament trauma, MRI remains the definitive imaging modality. Patients should be immobilized in full extension, made non-weight bearing, given analgesics, and have orthopedic follow-up within 1-3 days when possible. While grade 1 injuries are treated as sprains with elastic

bandage wraps and weight bearing as tolerated, grade 2 injuries are treated much more aggressively with bracing for 3-4 weeks and post-injury muscle strengthening. Unless one can accurately distinguish between the two, it is recommended that all patients be treated with immobilization and crutches until orthopedic follow-up can more accurately sort out the grade 1 and grade 2 patients. In the past, conservative treatment of grade 3 injuries was attempted, but found to be inadequate.[65] Thus, grade 3 injuries are treated with surgical repair to improve outcome, and to treat the associated ligament tears/ruptures.

Meniscal Injury

The menisci are C-shaped fibrocartilaginous structures that sit on top of the tibial plateau articular cartilage. The menisci are thickest in the middle and taper on the ends. They sit with the open part of the "C" facing the interior of the knee joint and their thickest part lies on the lateral aspect of the joint. Thus the thickest part of the medial meniscus is just under the MCL. In fact, the MCL is attached to the medial meniscus here, but the LCL is separated from the lateral meniscus by a small fat pad. The medial meniscus is more fixed in place than the lateral one, which glides twice as much as the medial meniscus during normal knee motion. This movement apparently protects the lateral meniscus from injury, as the medial meniscus is damaged more commonly.

The menisci function as shock absorbers and also as secondary knee stabilizers because they increase the depth of the "pocket" on the tibial plateau that holds the femoral condyles. Otherwise, the relatively flat tibial plateau would not accommodate the rounded femoral condyles as efficiently. Just how effective they are at this is shown by the accelerated development in osteoarthritis seen with meniscal injury. One study estimated that normal knees have 20% better shock absorbing capacity than those without a meniscus, and that resection of only 15-34% of the meniscus increases contact pressure on the articular cartilage by about 350%.[66]

Meniscal injuries are very common knee injuries, and it is estimated that more than 1.7 million patients undergo meniscal surgery every year in the United States.[67] These injuries usually result from twisting motions or rapid knee flexion/extension. During these movements, the meniscus is caught between the tibia and femur causing the tear. Injuries can be from high-impact sporting events or from simple activities of daily living, such as getting up from a seated position and turning to the side. Patients present with knee pain and swelling, and often note "clicking" or "catching" during knee range of motion. Some patients complain of knee "locking," which can be of two types. True locking occurs immediately after injury and represents a portion of the meniscus caught between the tibia and femur. The patient will usually present with the knee at about 30° of flexion. Patients presenting 1-2 days later complaining of "locking" are usually describing "catching" instead, where knee motion is limited by pain or muscle spasm rather than by an actual loose piece of meniscal cartilage.[1]

Knee effusions occur with meniscal tears but may take 12-24 hours to accumulate, compared to the rapid (< 4 hour) accumulation time seen with ACL/PCL tears. Classic physical findings are pain and tenderness localized over the joint line, often more apparent at the extremes of flexion/extension. Special attention should be paid the posterior joint line area, as up to 80% of meniscal damage occurs on the posterior aspect.[68] The McMurray and Apley stress tests (*see section on stability tests in part I*) may be performed if the patient can tolerate these maneuvers. Even with clinical suspicion, MRI will undoubtedly be performed on a follow-up visit with the consultant as associated ligament injuries are common. One study found that isolated meniscal injuries only occur about 25% of the time (both for medial and lateral menisci), and medial meniscus injury is seen in 52% of ACL ruptures.[69] Using MRI, one can classify meniscal injuries as: longitudinal tears (include bucket-handle tears when displaced), radial tears, oblique tears, horizontal tears, and complex or combination tears. Be aware that longitudinal (bucket-handle) tears are usually seen in younger patients with ACL injury.

Patients with meniscal injuries are immobilized in full extension, made non-weight bearing, and given adequate analgesia and orthopedic follow-up. The exception is the case of the truly locked knee. Intra-articular injection of lidocaine may be needed for the patient to tolerate the reduction procedure. One can attempt to displace the locked meniscal fragment by placing the leg over the side of the bed and flexing to 90°. This allows gravity to help separate the tibia and femur. Applying mild rotation to the tibia should help release the locked meniscal fragment.

Non-traumatic Knee Pain

Septic Arthritis. The majority of septic arthritis occurs in children younger than 4 years of age or adults older than 65 years, but the incidence in adults is increasing. The increasing frequency in adults is primarily a result of increasing age in the population and an increase in risk factors. The knee is the most common joint in adults to suffer from septic arthritis, and represents 45% of cases.[70] Other joints are affected much less frequently: hip (15%), ankle (9%), elbow (8%), wrist (6%), and shoulder (5%).[71] Polyarticular presentations do occur in about 10-20 % of cases, and are more common with gonococcal, group B streptococcal, and gram-negative pathogens.[70] While gonococcal arthritis was more common in the past, joint infections from group B streptococcal and MRSA (methicillin-resistant *Staphylococcus aureus*) have recently increased in incidence. However, gonococcal disease is still the most common cause of septic arthritis in young healthy adults in the United States, and is seen in about 1-2% of cases of *N. gonorrhoeae* infection.[72]

The majority of cases in adults occur in those with risk factors of underlying joint disease or medical risk factors. Only 22% of cases in one series occurred in patients with neither of the above.[73] Of the two, the principal risk factor is pre-existing joint disease. Synovial membranes of diseased joints have increased vascularity as well as tissue adhesion factors that increase the chance for binding of bacteria, which is important since most septic arthritis is thought to arise via hematogenous spread. Examples of pre-existing joint disease include rheumatoid arthritis, osteoarthritis, gout, and systemic lupus erythematous. Of these, rheumatoid arthritis carries the highest risk and these patients tend to have worse outcomes as well. The presence of

Table 2. Synovial Fluid Results and Suggested Diagnosis

FLUID RESULTS	NORMAL	NON-INFLAMMATORY	INFLAMMATORY	SEPTIC
Color	Clear, yellow	Yellow	Yellow to green	Yellow to gray
Clarity	Transparent	Transparent	Turbid	Turbid
Viscosity	High	High	Low	Variable
WBC / mm^3	< 200	200–2,000	1,000–100,000	15,000–200,000
PMNs	< 10 %	< 25 %	> 50 %	> 75 %
Glucose	~ 90 % of serum	~ 90 % of serum	~ 70 % of serum	< 50 % serum (< 25 mg/dL)
Mucin clot	Good	Good	Good to poor	Poor

rheumatoid arthritis can confuse the diagnosis, as septic arthritis may present as just a flare of their typical arthritis. Medical risk factors include diseases that affect skin integrity (psoriasis, ulcers, eczema, injection drug abuse) or those that lower immune function (diabetes, chronic renal failure, corticosteroid use, cirrhosis, alcoholism, HIV, and use of immunosuppressive drugs).

Prosthetic joint replacement is also a risk factor for septic arthritis, and while this occurs in only a small proportion of patients undergoing joint replacement, more joint replacements are being performed each year. Risk of infection is highest in knee joints when compared to hip or shoulder joints.[74] Current risks are estimated at 2% for patients with knee replacement, but the risk rises to 6% when they undergo revision surgeries.[74] Finally, while less common than other causes, penetrating injury can also cause infection. While one may first think of true open joint injuries, minor injuries can also cause joint infection. Injury with plant thorns, wood splinters, and nails can penetrate the joint but at first appear as only superficial injuries. One should ask the patient with suspected joint infection about any recent trauma, even perceived minor trauma, and carefully examine the skin over the knee for recent injury.

Classically, patients present with an acutely painful, hot, swollen joint. Fever is common, and the patient complains of severe pain with joint movement. Unfortunately presentations can be variable, especially in immunosuppressed patients. High fevers were only seen in 58% of patients in one series, but 90% did have low grade fever.[73] White blood cell count (WBC) is non-specific with elevation seen in only 60%.[73] Likewise C-reactive protein and erythrocyte sedimentation rate are non-specific markers of acute inflammation.[74] Further, patients at higher risk (rheumatoid arthritis, corticosteroids) typically have less pain.[75] Patients with prosthetic joint replacements can present early as a direct complication of surgery (days to 2 weeks) or may present much later (months to 2 years) from an indolent post-surgical infection or with a new infection resulting from hematogenous spread. The delayed presentation of chronic low-grade infection months after surgery is the most common one, with coagulase-negative staphylococci a common cause. Plain films will likely only show joint effusion in most cases, but they may be useful in joint replacement patients. Findings include prosthetic loosening, bony erosion, or subperiostial bone growth. Labeled leukocyte studies have been used to help identify indolent infections in post-surgical patients, but ultimately, only synovial fluid analysis may confirm the diagnosis of septic arthritis.

Synovial fluid from the affected knee should be aspirated (*see section on arthrocentesis in part I*) and sent for WBC, gram stain, and culture. (*See Table 2.*) Classically WBC counts greater than 50,000 cells/mm^3 have been used as a cut-off to recommend empiric treatment for septic arthritis. Differentials usually show greater than 50-75% polymorphonuclear cells. Unfortunately, using synovial fluid WBC alone is imprecise. Gout and pseudogout can easily produce synovial WBCs greater than 50,000 cells/mm^3.[70] Further, one recent study found that 33% of patients with documented septic arthritis had synovial fluid WBCs less than 50,000 cells/mm^3,[76] and another study found that 50 % of patients had counts less than 28,000 cells/mm^3.[77] Immunosuppressed patients also may not produce normal WBC levels. Gram stains should be done, but they may not be as helpful as one might think. Gram stains are positive in only 71% of gram-positive cases of septic arthritis,[78] 40-50% of cases of gram-negative septic arthritis,[77] and in fewer than 25% of patients with gonococcal arthritis.[79] Blood cultures also should be obtained, as up to 33% of patients will have bacteremia, and in 14% of patients the pathogen is isolated only through the blood culture.[80] Even cultures of synovial fluid are not always positive in cases of suspected septic arthritis.[81] Synovial fluid glucose levels are typically less than 25 mg/dL, or less than 50% of plasma levels.

Broad-spectrum cephalosporins can be used as initial treatment in most cases, but one should consider adding vancomycin (30 mg/kg divided in 2 doses daily) to cover MRSA in patients with nursing home or hospital-acquired infections. Orthopedic consultation is necessary for joint irrigation or more aggressive surgical therapy. Patients with prosthetic joints will require removal of the infected prosthesis and 6 weeks of antibiotic treatment before a new prosthesis can be inserted.

Thus, as accurate diagnosis of septic arthritis is problematic, one should maintain a low threshold for consultation, admission, and treatment of patients with suspected septic arthritis. This is especially true for high-risk patients: those with rheumatoid arthritis, diabetes, chronic renal failure, immunosuppression, and injection drug use. The fact that mortality rates are still in the 10-15% range[71] should underscore the need for aggressive treatment. Even though most patients survive the infection, the consequences of septic arthritis can be severe. The primary effect is damage of the articular cartilage. Some organisms cause more

damage to the cartilage than others; *S. aureus* is particularly damaging, while *N. gonorrhoeae* is less so. As infection continues, bacteria can spread into the underlying bone causing necrosis leading to osteomyelitis, and permanent disability is seen in up to 50% of patients.[81] It is important for the emergency physician to try to recognize septic arthritis on the first presentation, as spread to the underlying bone can occur in as little as three days.

Baker's Cyst (Popliteal Cyst). Symptomatic Baker's cyst should also be considered in a patient with acute atraumatic knee pain. Baker's cysts are synovial cysts formed posterior to the medial femoral condyle between the tendonous heads of the gastrocnemius and semimembranosus muscles. They arise when knee joint effusions occur and act as a "safety valve" for the knee. The pressure inside the knee joint is lessened as synovial fluid can displace into the cyst. Thus Baker's cysts are most often seen in patients with pre-existing knee pathology (osteoarthritis, rheumatoid arthritis). Presenting symptoms of a Baker's cyst rupture can often be confused with an acute deep vein thrombosis. Intact Baker's cysts can be the source of acute knee pain, usually when the patient's joint disease (osteoarthritis) is active as this increases the size of the cyst. The patient's entire knee is usually painful and mildly swollen. In some cases, one can palpate a swelling in the popliteal fossa but usually the diagnosis of a Baker's cyst is done with ultrasound.

Medical Disorders Causing Knee Pain

There are multiple systemic diseases that have acute arthritis as a component. Acute viral infections with rubella, hepatitis B or C, mumps, adenovirus, enteroviruses, parvovirus B19, and HIV can all cause acute inflammation of knee joints. In most cases the other symptoms caused by viral infection will help guide one toward a diagnosis (i.e., mumps, hepatitis, rubella). HIV arthritis is usually a later complication and is seen in patients with lower CD4 counts. Multiple systemic diseases are also associated with arthritis, including knee joints.

Gout/Pseudogout. Gout and pseudogout are the two most common crystal-induced arthropathies. Gout results from a precipitation of monosodium urate monohydrate (uric acid) crystals in the joint, and pseudogout from a precipitation of calcium pyrophosphate crystals. In both cases, an elevated serum level triggers the accumulation in the joint. This can be due to overproduction or reduced excretion, and impaired renal excretion of uric acid is a common cause of gout. Impaired renal metabolism of uric acid is a relatively common genetic abnormality and on average 20% of people in a family with this defect will suffer from gout.[82] Overall, gout affects nearly 3 in every 1000 adults in the United States.[82] Typical triggers include hypertension, diabetes, alcohol use, "dietary excess" (i.e., diet high in protein), obesity, or stress from other illness or surgery.[82] Both gout and pseudogout are most commonly seen in middle age people.

Although one classically thinks of the first metatarsal phalangeal joint (MTP) as the site of gout, the ankle, knee, and wrist are also commonly affected. Most patients will only have one joint involved at a time, but up to 40% will have polyarticular symptoms.[83] Pseudogout commonly affects the knee, wrist, and shoulder. Patients present with a very painful, warm, swollen joint. Gout and pseudogout cannot usually be distinguished clinically, but gout tends to come on in a period of hours, whereas pseudogout symptoms build up over several days. Unfortunately, the presentation also overlaps with that of a septic joint and patients with gout/pseudogout can present with systemic symptoms (fever, chills) as well. All three disorders can also produce a systemic leukocytosis and elevated erythrocyte sedimentation rate. Thus it is important to perform arthrocentesis when the diagnosis is in question. Synovial fluid in gout will show needle-shaped negative birefringent crystals when using a polarizing microscope (a yellow crystal against a red background). In pseudogout the crystals are rhomboid-shaped and positively birefringent (do not change color with polarized light).

Although attacks of crystal-induced arthritis are self-limiting, they tend to recur over time and can lead to build-up of deposits or tophi (hands, knees, feet, toes, fingers, olecranon bursa, Achilles tendon) that can be deforming. Early on, attacks may occur every few years. However, unless the patient is taking medication to reduce frequency of attacks, the time between them usually becomes shorter. Acute treatment consists of NSAIDs (indomethacin 25 mg or ibuprofen 800 mg orally every 8 hours,) and opiates to alleviate pain. Colchicine can also be given, but is most effective if taken during the first 24 hours of an attack. Give 0.6 mg orally every hour up to a total of 1.8 mg (maximum 3 tablets), or until nausea/vomiting/diarrhea begin.[84] Relief with colchicine may provide evidence to support a diagnosis of gout over septic arthritis, as colchicine should not be effective in treating pain from infection. If effective, the patient may continue colchicine 0.6 mg daily for up to one week to prevent reoccurrence. Patients with underlying renal, hepatic, gastrointestinal, or hematologic disease should not be given colchicine. Allopurinol (decreased uric acid production) and probenecid (increased excretion) are two agents used to reduce reoccurrence of gouty attacks, but these are typically only used in patients with joint deposits (tophi) or recurrent renal stones and are not of use for acute gout pain. There are no preventative agents to use for pseudogout.

Rheumatoid Arthritis. Rheumatoid arthritis is a chronic, destructive joint disease that develops most commonly in patients aged 25-50 years of age. It is seen in women 3 times as often as men. The disease causes inflammation of the synovial membrane and articular surfaces. Multiple joints are affected from the foot to the hands, and joint involvement is symmetric. The hands are especially vulnerable, but while the MP and PIP joints are affected, the DIP joints of the fingers are spared. Although a chronic condition, up to 20% of patients present with acute flares of joint pain. Patients complain of warm, tender, and swollen joints, usually in multiple symmetric locations at the same time. Baker's cysts are more commonly seen in patients with rheumatoid arthritis as well. Rheumatoid flares usually are treated with NSAIDs and corticosteroids, but some patients are treated with methotrexate or cyclosporine as well. The primary concern for patients with acute rheumatoid flares in the ED is to try to rule out a septic joint presenting simply as a rheumatoid flare. (*See previous section on septic arthritis.*) Realize that these patients are at higher risk for septic arthritis, and maintain a low threshold for knee arthrocente-

sis and orthopedic consultation. In most cases, the synovial WBC should be between 4,000 and 50,000 cells/mm^3, but synovial WBC alone should not be relied on to rule out a septic knee joint.

Lyme Disease. Lyme disease, caused by the spirochete *Borrelia burgdorferi*, is named for the location where it was originally described (Lyme, Connecticut). Lyme disease is common primarily in the East coast, Midwest (Wisconsin, Minnesota), and West (California, Oregon, Utah, Nevada). Patients are infected when they are bitten by deer ticks (*Ixodes dammini*) that carry the spirochete. The initial signs of infection are flu-like, with fever, fatigue, myalgias, headaches, and of course the classic rash erythema chronicum migrans at the bite location. Various neurologic symptoms (Bell's palsy, meningitis) and cardiac dysrhythmias can also occur. Arthritis from Lyme disease is usually a late manifestation of the disease, but can also be seen in the early phase. If not treated in the early phase, up to 60% of patients develop arthritis, especially in the knee joints.[85] While large effusions may develop, pain is less than one would expect by the swelling. Arthritis can be recurrent in about 15% of cases. The diagnosis can be difficult as false positives are common in ELISA testing, and the organism does not culture easily. Most patients will have positive immunoglobulin G titers by the time arthritis is a major feature of the disease, but this result may not be available in the ED. Oral medications (doxycycline, erythromycin, amoxicillin) can be used in early cases, but prolonged treatment with ceftriaxone or IV penicillin is recommended for persistent arthritis.

Pediatric Patients with Knee Pain

Knee pain in the pediatric patient can result from a wide variety of sources, and can be difficult to accurately diagnosis in every case. Large numbers of younger children are participating in sports every year, and soft-tissue injuries not often seen in younger children in the past are becoming more common. Some ED physicians may not be used to thinking of these issues, i.e., ACL tears, in school age children. Obesity problems in children are on the rise, and obese children also appear to be at increased risk for knee injuries according to recent studies.[86] In this study the knee was the most common joint reported by the children as a source of pain or injury, with 21% of obese children reporting knee problems compared to 16% of non-overweight children.[86] The presence of growth plates can make treatment of pediatric knee fractures more complicated than for adults. Making matters more complicated, some patients may present with knee pain that is actually referred pain from hip pathology such as fracture, malignancy, avascular necrosis, slipped capital femoral epiphysis (SCFE), or a bacterial infection. Septic arthritis is most often seen in children younger than 3 years of age, where the patient's limited language skills may make arriving at the correct diagnosis more challenging. The following sections will give a brief overview of common diagnoses seen in children with acute knee pain.

Pediatric Knee Trauma. *Fractures.* Developing bones in the pediatric population also respond to trauma differently than those of adult bones. Fractures can occur even after mild trauma. Pediatric bone is also more porous and can tolerate a greater degree of bending without fracturing. However, the primary difference in pediatric knee fractures and adult knee fractures is the presence of the growth plates or physes. The physis is a cartilaginous structure and is the site of active bone growth. Physeal fractures have unique diagnosis, treatment, and complication concerns compared to metaphyseal (shaft) injuries or to adult fractures. Before discussion of these injuries, one should briefly review the Salter-Harris (SH) classification system. (*See Figure 2.*) The severity of injury and prognosis in general gets increasingly worse as the numbers increase. Briefly, SH type I fractures are simple separations of the growth plate. Be aware that some of these may be non-displaced and very difficult to detect on initial plain radiographs. SH type II fractures include a triangular-shaped proximal (shaft) component in addition to the physeal fracture. These are the most common SH fractures, making up 75% of cases. SH type III fractures extend in the opposite direction with the small additional break now extending into the joint instead of back to the shaft. SH type IV fractures include both fracture components (shaft and joint) of type II and III fractures. SH type V are crush injuries where the physis is compacted. These have the worst prognosis for growth arrest, and are also the most difficult to diagnose with plain radiographs. Fortunately, they are also the least common SH fracture type.

Distal femur physeal fractures are not the most common type of SH fracture (distal radius is most common), and they comprise only about 5% of physeal fractures.[87] However, both the distal femur and proximal tibia are two of the sites where growth plate fracture complications are the most common. Complications of growth arrest (leg shortening or angulation) are seen in up to 80% of patients with distal femur physeal fractures.[88] Even the relatively benign SH types I and II injuries carry a 50% risk for growth disturbance.[88] These complications occur as the distal femur physis is responsible for approximately 40% of total leg length or an estimated 1 cm per year. The proximal tibia physis contributes 25% of total length at a rate of 5-6 mm per year. Thus premature complete or partial physeal closure can cause significant limb length discrepancies and angular deformities.

Proximal tibia fractures are relatively rare in children, but carry the highest risk of all for growth complications. Most often, these injuries occur as a result of MVAs or sporting activities. Patella fractures in children are similar to adult patella fractures in terms of mechanisms of injury, presentation, diagnosis, and treatment.

Dislocations. Tibial-femoral (knee) dislocations in children are relatively rare, and as in adults, are devastating injuries. They generally can be treated as in adults, and injuries to the popliteal artery are the primary complication to look for. Be wary of the patient who presents after spontaneous reduction of the knee in the field. Knee dislocation disrupts all or most of the primary stabilizing knee ligaments, and this instability should be detectable on examination. The patient with multiple injuries may not be conscious to complain of knee pain, so any grossly swollen knee with no obvious fractures should be closely examined with this in mind.

Patellar instability and dislocation are relatively common in the school-age child, especially those who participate in sports. In the past the prototypical patient with patellar dislocation was the overweight, valgus-kneed, unathletic girl with ligamentous laxity.[30] However, more recent studies have confirmed, like in

Figure 2. Salter-Harris Classification of Growth Plate Fractures



Used with permission from: Tintinalli et al. *Emergency Medicine: A comprehensive study guide*, 6th edition. Figure 267.7, page 1658; 2004.

adults, patellar dislocations are actually seen in equal numbers between the sexes and more often occur in athletes. Lateral dislocations are most common and result from a direct blow or from pivoting maneuvers. Many times the patient will present with the patella spontaneously relocated, and the history of "something moving" on the anterior knee. Although plain films in most cases will only show a knee effusion, osteochondral fractures of the patella can occur. Even when no fracture is present, damage to the patellar and lateral femoral condyle cartilage does take place. Recent studies in patients undergoing arthroscopy show that up to 70% of patients have articular cartilage damage that was only detected by plain films in 23% of the patients pre-operatively.[89] Reduction, immobilization for 3-5 days, weight-bearing as tolerated, and follow-up with an orthopedist are done as with adults.

Soft-Tissue Injuries. ACL injuries are common in adults, but complete ACL ruptures are less common in children because the ACL is stronger than the surrounding bones or growth plates. One recent study of these injuries found that 82% of complete tears occur in sporting activity.[90] Partial tears are more common than complete ruptures. ACL injuries can be difficult to diagnose in kids. Even with complete tears, a few days after injury children may be able to walk and even run without significant difficulty. Plain radiographs should be done specifically looking for physeal injuries or a tibial spine fracture, which is common in children with ACL ruptures. The Lachman test (*see section on stability testing in part I*) can be performed in children as in adults. Outpatient referral for specialty consultation and probable MRI to define injury is recommended for suspected isolated ACL injuries. Surgical treatment is often delayed until physes close, as reconstruction can damage growing bone. Likewise, PCL ruptures are even more uncommon in children. When injuries do occur, they tend to be avulsion fractures rather than isolated midsubstance ligament injuries.

MCL and meniscal injuries are fairly common in adults, but are much less common in children. Children tend to suffer from physeal fractures due to the relative greater strength of the ligaments compared to growing bone. Pure ligament injuries were once thought to be so rare in children that they were believed to occur only after growth plate closure.[91] It now is known they do occur, but still most are not isolated injuries and usually are associated with avulsion fractures. Interestingly, whereas in adults medial meniscal injuries are much more common than lateral ones, in children they occur with nearly equal frequency. As in adults, they present with medial (MCL, medial meniscus) or lateral (LCL or lateral meniscus) knee pain and knee effusion. These ligament injuries are not likely to be specifically diagnosed in the ED, but one should use plain films to rule out bony injury, immobilize, and refer for orthopedic evaluation in the next 3-5 days. Be aware that if MRI is performed in the ED, that false-positive results are increased in the patient with an immature skeleton. One study found that patients younger than 13 years had 60% false-positive readings compared to 25% of adults.[90]

Septic Arthritis. Septic arthritis is most commonly seen in children younger than 3 years of age, with most infections occurring in the hip joint. In adult cases the knee is the most common joint involved, but in children it is the second most commonly infected joint. The difference in rates of infection between the two joints is not that great, and one recent review cited the hip and the knee each as being responsible for one-third of cases.[70] Young children with hip infections may present complaining only of knee pain, and the ED physician must remember to evaluate the hip joint if no explanation of the symptoms is found on knee examination. Like in adults, hematogenous spread of bacteria is the most common cause of infection. In children younger than 3 years, Staph and Strep are the most common organisms responsible for infection. *Neisseria gonorrhoeae* should be considered when treating adolescents. *H. influenzae* type B was a more common pathogen in the past, but immunizations have reduced its incidence by up to 80%.[81] Unfortunately community-acquired MRSA infections are increasing in frequency and one recent survey in Houston found that 50% of recent cases of septic arthritis were caused by MRSA.[92]

Children who present with a bulging, warm, tender joint are much easier to diagnose than those who present early on in the course of illness. Patients may only be fussy, febrile, and have minor swelling of the knee. In this context when the child's knee is consistently painful on range of motion, or the child repeatedly refuses to bear weight, keep the diagnosis in mind and maintain a low threshold for arthrocentesis. Synovial fluid WBC greater than 50,000 cells/mm^3 with greater than 75% neutrophils and very low glucose levels (less than 30% of serum levels) (*see Table 2*) are the two most reliable findings to support septic arthritis, but these are not present in every case. Likewise, synovial fluid culture results are not always positive. *Neisseria gonorrhoeae* are notorious for negative culture results, with positive culture seen in only approximately 25% of cases.[81] Gram stains are also not as accurate as one would like, with positive results seen in only 71% of gram-positive cases of septic arthritis,[78] 40-50% of cases of gram-negative septic arthritis,[77] and in less than 25% of patients with gonococcal arthritis.[79] Blood cultures should be taken as well, as up to 33% of patients will have bacteremia and in 14% of patients the pathogen is isolated only through the blood culture.[80]

In patients of any age, septic arthritis is an orthopedic emergency as cartilage destruction rapidly progresses to bone infection and permanent disability. Third-generation cephalosporins, with vancomycin added for MRSA coverage when appropriate,

are good antibiotic choices to begin with. Remember in the very young (< 3 months) that systemic infection (meningitis) may also be present, and that spinal fluid cultures should be obtained when initiating antibiotic therapy in the ED. Be aware that septic arthritis in any age patient is a time-sensitive diagnosis. Joint irrigation and antibiotic therapy are both needed urgently to reduce the risk of degenerative arthritis and other complications.

Juvenile Rheumatoid Arthritis (JRA). JRA is actually a group of diseases that manifest as chronic joint inflammation. Causes are unknown, but like adult rheumatoid arthritis, JRA is defined by chronic inflammation of the synovial membrane. JRA onset is usually slow, but can be abrupt with morning stiffness of joints. JRA can present with systemic symptoms of fever, rash, and myositis. In contrast to adults where smaller joints of the hands and fingers are most commonly affected, JRA strikes larger joints most often (knees, ankles, wrists). Diagnosis of JRA is involved and typically not accomplished by an ED visit. If concerned for JRA, one should discuss follow-up and laboratory tests with the patient's pediatrician. NSAIDs and corticosteroids are the most commonly used medications. Be aware that systemic complications can be significant (pericarditis, anemia, among others) and that some patients may require admission when systemic complications occur.

Referred Pain. Especially in younger patients, distinguishing knee pain from hip pain may be challenging. It is well known that a limping child may present with complaints of knee pain that actually represents referred pain from hip pathology. Remember in referred knee pain, the knee examination will be normal. Pain is only elicited when movements of the knee also involve the hip joint. A normal physical examination of the knee should prompt one to evaluate the hip as well, and likewise the presence of a knee effusion localizes the pathology to the knee. Arthrocentesis of the knee may be useful in some cases to distinguish between juvenile rheumatoid arthritis, bacterial infections, and hemorrhage secondary to trauma or hemophilia.

Common examples of hip pathology causing referred knee pain include septic arthritis of the hip (*see previous section*), toxic synovitis, slipped capital femoral epiphysis (SCFE), and Legg-Calve-Perthes disease (LCPD). Viral or toxic synovitis is a benign, self-limited inflammation of the synovial membrane in the hip that is relatively common in children aged 2-12 years. One should be aware that this condition may cause referred knee pain, but does not primarily affect the knee. Abnormalities seen on physical examination of the knee joint (effusion, painful isolated knee motion) should not be ascribed to toxic synovitis.

SCFE is a slippage of the femoral head on the femoral neck through the growth plate. While it can occur as a complication of acute trauma, it is most frequently seen in obese adolescent males who present complaining of non-traumatic anterior thigh and knee pain. Up to 20% of patients with SCFE will complain only of knee pain.[93] Plain radiographs (with the frog-leg view) often are diagnostic alone.

LCPD is an idiopathic avascular necrosis of the femoral head. It usually strikes between the ages of 4-8 years and is bilateral in up to 20% of cases. Males are affected 4 times more often than females. It is a slowly progressive disease, and patients can present in early stages with referred knee pain. As with SCFE, the knee itself will appear normal and should prompt one to evaluate the hip with plain films when pain causes limping gait. Plain radiographs will be normal early in the disease, but CT scan or MRI will show bony collapse and sclerosis diagnostic of LCPD. Treatment depends on the severity of the necrosis and is directed at halting progression. Treatment options range from rest and NSAIDs, to casting or surgery.

Osteochondritis Dissecans. Osteochondritis dissecans is relatively common in the knee, and occurs when a portion of subchondral bone necroses and separates from the cartilage. It is most often seen on the femoral condyles, with the lateral portion of the medial condyle as the most common site, as the medial side bears more weight. Exact causes are unclear, but some propose that repetitive microtrauma from athletics is a frequent source. Osteochondritis dissecans can lead to loose joint bodies when the affected area of cartilage completely separates from the underlying bone. This is less common in younger children and more so in adults. Patients usually present with several weeks to months of knee pain that begins as mild and gradually worsens. Mild effusions can be seen. Plain films can show bony changes suggestive of osteochondritis dissecans, but radionuclide bone scans or MRI may be needed for definitive diagnosis. Children 11 years or younger are typically treated conservatively with cessation of athletics and limited weight-bearing. Lesions that do not respond to conservative treatment or those that fully separate to become loose joint bodies will need surgical intervention. In some cases the loose body is simply removed and is screwed back in place, and in others bone grafts may be needed.

Osgood-Schlatter Disease. Osgood-Schlatter disease is one of the most common causes of knee pain in adolescents. It is presumed to be caused by periods of rapid bone growth where the bone actually grows faster than the soft tissue, resulting in increased tightness of the quadriceps and patellar tendon. Combined with repetitive microtrauma, usually via athletic activity, it leads to a partial avulsion fracture through the ossification center of the tibial tuberosity. Up to 30% of cases are bilateral.[1] Once thought to be more common in boys, more recent studies reveal no gender differences, and suggest that the level of activity and skeletal maturity determine the prevalence.[94] Most boys present between 13-14 years of age and girls between 10-11 years of age.

Patients usually present with complaints of anterior knee pain associated with walking, running, kneeling, or climbing stairs. Symptoms have often been present intermittently for several weeks to months before presentation. In some cases, swelling over the tibial tuberosity will be noted and a firm mass may be palpable. Most patients have tenderness to palpation even if no swelling is observed. The knee joint examination will be normal, but patients will complain of pain with active knee extension against resistance. Plain films may rule out other disorders (cancer), but usually show no findings. If plain films are taken, comparison films of the other leg may be needed as ossification patterns of the tubercle are variable.

Treatment is with rest, ice, elevation, and NSAIDs. As long as the patient will cooperate with reduced activity and no athletics,

knee immobilization is not necessary and may further weaken the quadriceps. When immobilization is used, do so only for 2-3 weeks. Most patients' symptoms will ease with this, but in some cases closure of the physeal plate may need to take place before symptoms resolve.

Malignancy. Primary bone tumors occur in a higher frequency in children than in adults. Patients may present with persistent knee pain, particularly with activity. Plain radiographs typically reveal lytic lesions or abnormal new bone growth. The two most common malignant bony tumors are osteosarcoma and Ewing's sarcoma.

Osteosarcoma is the most common malignant bone tumor. It is rare in children younger than 5 years of age, and incidence rises until it peaks in association with the growth spurt of adolescence. Although it is unclear why, there is a slightly higher risk in the African-American population. The most common sites are in the femur, tibia, humerus, skull, and pelvis. However, the knee is the most common area affected, as nearly 47% of cases occur either in the distal femur or proximal tibia.[95] Pathologic fractures are rare. Osteosarcoma metastasizes primarily to the lung, so chest films should be taken anytime a new diagnosis is made. Up to 15% of cases will be metastatic at time of diagnosis.[95]

Ewing's sarcoma is the second most common primary bone malignancy in childhood. Like osteosarcoma, the peak incidence occurs between 10 and 20 years of age, but unlike osteosarcoma Ewing's also occurs in children younger than 5 years of age and in 9% of cases is seen between the ages of 20 and 30 years.[95] Also unlike osteosarcoma, the incidence in Caucasians is 9 times higher than in African-Americans. Patients present with persistent knee pain, and pathologic fractures do occur. Ewing's is most commonly seen in areas of bone marrow production, such as the axial skeleton (vertebrae, ribs, sternum, pelvis, and cranium) and proximal long bones (femur, humerus). Most cases are seen in the pelvis, with the femur affected less often. Plain films reveal destructive bone changes with reactive bone formation. The periosteal reaction seen has classically been described as "onion skin" or "hair on end" in appearance.

References

1. Lyn E, Pallin D, Antosia RE. Knee and lower leg. In: Marx, JA ed. *Rosen's Emergency Medicine: Concepts and Clinical Practice*, 6th ed. St. Louis: Mosby; 2006: 770-796.
2. Frassica FJ, Sim FJ, Staeheli JW, et al. Dislocation of the knee. *Clin Orthop* 1991;263:200-205
3. Wascher D. The dislocated knee. *Clin Sports Med* 2000;19:457-462.
4. Perron AD, Brady WJ, Sing RF. Orthopedic pitfalls in the ED: Vascular injury associated with knee dislocation. *Am J Emerg Med* 2001;19:583-588.
5. Roberts DM, Stallard TC. Emergency department evaluation and treatment of knee and leg injuries. *Emerg Med Clin North Am* 2000;18:67-84.
6. Marin EL, Bifulco SS, Fast A. Obesity. A risk factor for knee dislocation. *Am J Phys Med Rehabil* 1990;69:132-134.
7. Girgis M. The cruciate ligaments of the knee joint. *Clin Orthop* 1975;106: 216-231.
8. Cole BJ, Harner CD. The multiple ligament injured knee. *Clin Sports Med* 1999;18:241-262.
9. Hegyes MS, Richardson MW, Miller MD. Knee dislocation. Complications of nonoperative and operative management. *Clin Sports Med* 2000;19:519-543.
10. Meyers M, Harvey JP. Traumatic dislocation of the knee joint. *J Bone Joint Surg Am* 1971;53A:16-29.
11. Wright DG, Covey DC, Born CI, et al. Open dislocation of the knee. *J Orthop Trauma* 1995;9:135-140.
12. DeBakey ME, Simeone FA. Battle injuries in WW II. *Ann Surg* 1946;123: 534-571.
13. Peck JJ, Eastmen AB, Bergan JJ, et al. Popliteal vascular trauma. *Arch Surg* 1990;125:1399-1344.
14. Wascher DC. High-velocity knee dislocation with vascular injury. Treatment principles. *Clin Sports Med* 2000;19:457-477.
15. Rihn JA, Groff YJ, Harner CD, et al. The acutely dislocated knee: Evaluation and management. *J Am Acad Orthop Surg* 2004;12:334-346.
16. Frykberg ER. Popliteal vascular injuries. *Surg Clin North Am* 2002;82:67-89.
17. Lassonen EM, Kivioja A. Delayed diagnosis of extremity injuries in patients with multiple injuries. *J Trauma* 1991;31:257-260.
18. McCabe CJ, Ferguson CM, Ottinger LW. Improve limb salvage in popliteal artery injuries. *J Trauma* 1983;23:982-985.
19. Abou-Sayed H, Berger D. Blunt lower extremity trauma and popliteal artery injuries. *Arch Surg* 2002;137:585-589.
20. Hollis JD, Daley BJ. 10-year review of knee dislocations: Is arteriography always necessary? *J Trauma* 2005;59:672-675.
21. Stannard JP, Sheils TM, Lopez-Ben RR, et al. Vascular injuries in knee dislocations: The role of physical examination in determining the need for arteriography. *J Bone Joint Surg Am* 2004;86:910-915.
22. Klineberg EO, Crites BM, Flinn WR, et al. The role of arteriography in assessing popliteal artery injury in knee dislocations. *J Trauma* 2004;56:786-790.
23. Fry WR, Smith RS, Sayers DV. The success of duplex ultrasound arterial scanning in diagnosis of extremity vascular trauma. *Arch Surg* 1993;128:1368-1372.
24. Barnes CJ, Pietrobon R, Higgins LD. Does the pulse examination in patients with traumatic knee dislocation predict a surgical arterial injury? A meta-analysis. *J Trauma* 2002;53:1109-1114.
25. Whittle P, Wood GW. Fractures of the lower extremity. In: Canale ST ed. *Canale: Campbell's Operative Orthopaedics*, 10th ed. St. Louis: Mosby; 2003:2805-2873.
26. Merchant AC. Classification of patellofemoral disorders. *Arthroscopy* 1988;4:235-240.
27. Maenpaa H, Lehto MUK. Patellar dislocation: The long-term results of nonoperative management in 100 patients. *Am J Sports Med* 1997;25:213-217.
28. Maenpaa H, Lehto MUK. Surgery in acute patellar dislocation—evaluation of the effect of injury mechanism and family occurrence on the outcome of the treatment. *Br J Sports Med* 1995;29:239-241.
29. Sallay PI, Poggi J, Speer KP et al. Acute dislocation of the patella. A correlative pathoanatomic study. *Am J Sports Med* 199;24:52-60.
30. Atkin DM, Fithian DC, Marangi KS, et al. Characteristics of patients with primary acute lateral patellar dislocation and their recovery within the first 6 months of injury. *Am J Sports Med* 2000;28:472-479.
31. Roger DJ, Williamson SC, Uhl RL. Difficult reductions in traumatic patellar dislocation. *Orthop Rev* 1992;21:1333-1337.
32. Singletary EM, Dobson J. Intercondylar dislocation of the patella with vertical axis rotation. *Am J Emerg Med* 1999;17:76-77.
33. Nietosvaara Y, Aalto K, Kallio PE. Acute patellar dislocation in children: Incidence and associated osteochondral fractures. *J Pediatr Orthop* 1994; 14:513-515.
34. Virolainen H, Visuri T, Kuusela T. Acute dislocation of the patella: MR find-

ings. *Radiology* 1993;189:243-246.
35. Diehl LH, Garrett WE. Acute dislocation of the patella in the adult. In: DeLee JC, Drez D. Jr. eds. *DeLee and Drez's Orthopaedic Sports Medicine*, 2nd ed. St. Louis: W.B. Saunders; 2003: 1697-1708.
36. Morelli V, Rowe RH. Patellar tendonitis and patellar dislocations. *Prim Care Clin Office Pract* 2004;31:909-924.
37. Buchner M, Baudendistel B, Sabo D, et al. Acute traumatic primary patellar dislocation: Long-term results comparing conservative and surgical treatment. *Clin J Sport Med* 2005;15:62-66.
38. Hyman J, Rodeo SA, Wickiesicz T. Patellofemoral tendinopathy. In: DeLee JC, Drez D. Jr. eds. *DeLee and Drez's Orthopaedic Sports Medicine*, 2nd ed. St. Louis: W.B. Saunders; 2003: 1841-1854.
39. Ramseier LE, Werner CM, Heinzelmann M. Quadriceps and patellar tendon rupture. *Injury* 2006;37:516-519.
40. Siwek CW, Rao JP. Ruptures of the extensor mechanism of the knee joint. *J Bone Joint Surg Am* 1981;63:932-937.
41. Kannus P, Jozsa L. Histiopathological changes preceding spontaneous rupture of a tendon. A controlled study of 891 patients. *J Bone Joint Surg Am* 1991;73:1507-1525.
42. Neubauer T, Wagner M, Potschka T, et al. Bilateral, simultaneous rupture of the quadriceps tendon: A diagnostic pitfall?: Report of three cases and meta-analysis of the literature. *Knee Surg Sports Traumatol Arthosc* 2007;15:43-53.
43. Bianchi S, Zwass A, Adbelwahab IF, et al. Diagnosis of tears of the quadriceps tendon of the knee: Value of sonography. *AJR Am J Roentgenol* 1994; 162:1137-1140.
44. La S, Fessell DP, Femino JE, et al. Sonography of partial-thickness quadriceps tendon tears with surgical correlation. *J Ultrasound Med* 2003;22:1323-1329.
45. Maffulli N, Wong J. Rupture of the Achilles and patellar tendons. *Clin Sports Med* 2003;22:761-776.
46. Brown JR, Trojian TH. Anterior and posterior cruciate ligament injuries. *Prim Care Clin Office Prac* 2004;31:925-956.
47. Weitzel PP, Richmond JC, Altman GH, et al. Future direction of the treatment of ACL ruptures. *Orthop Clin North Am* 2002;33:653-661.
48. Griffin LY, Agel J, Albohm MJ, et al. Noncontact ALC injuries: Risk factors and prevention strategies. *Am J Acad Orthop Surg* 2000;8:141-150.
49. DeMorat G, Weinhold P, Blackburn T, et al. Aggressive quadriceps loading can induce non-contact anterior cruciate ligament injury. *Am J Sports Med* 2004;32:477-483.
50. Yu B, Kirkendall DT, Taft TN, et al. Lower extremity motor control-related and other risk factors for noncontact ACL injuries. *Instr Course Lect* 2002;51:315-324.
51. Johnson MW. Acute knee effusions: A systematic approach to diagnosis. *Am Fam Physician* 2000;61:2391-2400.
52. Kendall NS, Hsu SY, Chan KM. Fracture of the tibial spine in adults and children. A review of 31 cases. *J Bone Joint Surg Br* 1992;74:848-852.
53. Skovgaard LP, Rasmussen OS. Diagnosis of acute rupture of the anterior cruciate ligament of the knee by sonography. *Eur J Ultrasound* 2000;12:163-167.
54. Fuchs S, Chylarecki C. Sonographic evaluation of ACL rupture signs compared to arthroscopic findings in acutely injured knees. *Ultrasound Med Biol* 2002;28:149-154.
55. Harner DC, Hoher J. Evaluation and treatment of PCL injuries. *Am J Sports Med* 1998;26:471-482.
56. Allen CR, Kaplan LD, Fluhme DJ, et al. PCL injuries. *Curr Opin Rheumatol* 2002;14:142-149.
57. Mink JH, Deutsch AL. Magnetic resonance imaging of the knee. *Clin Orthop Relat Res* 1989;244:29-47.
58. Margheritini F, Rihn J, Musahl V, et al. PCL injuries in the athlete: An anatomical, biomechanical, and clinical review. *Sports Med* 2002;32:393-408.
59. Escobedo RM. The "reverse Segond" fracture: association with a tear of the PCL and medial meniscus. *AJR Am J Roentgenol* 2002;178:979-983.
60. Quarles JD, Hosey RG. Medial and lateral collateral injuries: Prognosis and treatment. *Prim Care Clin Office Pract* 2004;31:957-975.
61. Sims W, Jacobson K. The posteromedial corner of the knee. Medial-sided injury patterns revisited. *Am J Sports Med* 2004;32:337-345.
62. Grana WA, Janssen T. Lateral ligament injury of the knee. *Orthopedics* 1987;10:1039-1044.
63. DeLee JC, Riley MB, Rockwood CA Jr. Acute straight lateral instability of the knee. *Am J Sports Med* 1983;11:404-411.
64. Krukhaug Y, Molster A, Rodt A, et al. Lateral ligament injuries of the knee. *Knee Surg Sports Traumatol Arthrosc* 1998;64:536-541.
65. LaPrade RF, Wentorf F. Diagnosis and treatment of posteriolateral knee injuries. *Clin Orthop* 2002;402:110-121.
66. Adachi N, Ochi M, Uchio Y, et al. Torn discoid lateral meniscus treated using partial central meniscectomy and suture of the peripheral tear. *Arthroscopy* 2004;20:536-542.
67. Rodkey WG. Basic biology of the meniscus and response to injury. *Instr Course Lect* 2000;49:189-193.
68. Hardin GT, Farr J, Bach Jr BR. Meniscal tears: Diagnosis, evaluation, and treatment. *Orthop Rev* 1992;21:1311-1317.
69. Thompson WO, Fu FH. The meniscus in the cruciate deficient knee. *Clin Sports Med* 1993;12:771-796.
70. Ross JJ. Septic arthritis. *Infect Dis Clin N Am* 2005;19:799-817.
71. Kaandorp CJ, Dinant HJ, van der Laar MA, et al. Incidence and sources of native and prosthetic joint infection: A community based prospective survey. *Ann Rheum Dis* 1997;56:470-475.
72. Rompalo AM, Hook EW III, Roberts PL. The acute arthritis-dermatitis syndrome: The changing importance of *N gonorrhoeae*. *Arch Intern Med* 1987;147:281-283.
73. Weston VC, Jones AC, Bradbury N, et al. Clinical features and outcomes of septic arthritis in a single UK health district 1982-1991. *Ann Rheum Dis* 1999;58:214-277.
74. Sia IG, Berbari EF, Karchmer AW. Prosthetic joint infections. *Infect Dis Clin N Am* 2005;19:885-914.
75. Edwards SA, Cranfield T, Clarke HJ. Atypical presentation of septic arthritis in the immunosuppressed patient. *Orthopedics* 2002;25:1089-1090.
76. McCutchan HJ, Fisher RC. Synovial leukocytosis in infectious arthritis. *Clin Orthop* 1990;257:226-230.
77. Shmerling RH, Delbanco TL, Tosteson AN, et al. Synovial fluid tests. What should be ordered? *JAMA* 1990;264:1009-1014.
78. Goldenberg DL, Reed JI. Bacterial arthritis. *N Engl J Med* 1985;312:764-771.
79. Goldenberg DL, Reed JI. Bacterial arthritis. *N Engl J Med* 1985;312:764-771.
80. Cooper C, Cawley MI. Bacterial arthritis in an English health district: A 10-year review. *Ann Rheum Dis* 1986;45:458-463.
81. La Torre IGD. Advances in the managements of septic arthritis. *Infect Dis Clin N Am* 2006;20:773-788.
82. Lally EV, Ho G, Kaplan SR. The clinical spectrum of gouty arthritis in women. *Arch Intern Med* 1986;146:2221-2225.
83. Agarwal AK. Gout and pseudogout. *Prim Care* 1993;20:839-855.
84. Terkeltaub RA. Gout. *N Engl J Med* 2003;349:1647-1655.

85. Steere AC. Musculoskeletal manifestations of Lyme disease. *Am J Med* 1995;98:44S-48S.
86. Taylor ED, Theim KR, Mirch MC, et al. Orthopedic complications of overweight in children and adolescents. *Pediatrics* 2006;117:2167-2174.
87. Peterson CA, Peterson HA. Analysis of the incidence of injuries to the epiphyseal growth plate. *J Trauma* 1972;12:275-281.
88. Riseborough EJ, Barrett IR, Shaprio F. Growth disturbances following distal femoral physeal fracture separations. *J Bone Joint Surg Am* 1983;65:885-893.
89. Stanitski CL, Paletta Jr GA. Articular cartilage injury with acute patellar dislocation in adolescents. Arthroscopic and radiographic correlation. *Am J Sports Med* 1998;26:52-55.
90. Erickson MA, Schmale GA. Medial ligament injuries in children. In: DeLee JC, Drez D. Jr. eds. *DeLee and Drez's Orthopaedic Sports Medicine*, 2nd ed. St. Louis: W.B. Saunders; 2003:1949-1967.
91. Pressman AE, Letts RM, Jarvis JG. ACL tears in children: An analysis of operative versus nonoperative treatment. *J Pediatr Orthop* 1997;17:505-511.
92. Martinez-Aguilar G, Avalos-Mishaan A, Hulten K, et al. Community-acquired MRSA and methicillin-susceptible *S. aureus* musculoskeletal infections in children. *Pediatr Infect Dis J* 2004;23:701-706.
93. Thompson GH. The Knee. In: Behrman RE, et al, eds. *Nelson's Textbook of Pediatrics*, 17th ed. St. Louis: W.B. Saunders; 2004: 2271-2274.
94. Kujala UM, Kvist M, Heinonen O. Osgood-Schlatter's disease in adolescent athletes: Retrospective study of incidence and duration. *Am J Sports Med* 1985;13:236-241.
95. Himelstein B, Dormans J. Malignant bone tumors of childhood. *Pediatr Clin North Am* 1996;43:967-984.

Physician CME Questions

101. "Hard" signs of popliteal artery injury after reduction of a dislocated knee include all of the following *except*:
    A. obvious pedal pulse deficit.
    B. cool cyanotic foot.
    C. injury to anatomically related nerve.
    D. active arterial bleeding.

102. Which of the following is true concerning popliteal injury with knee dislocation?
    A. The goal is to repair artery in < 10 hours after injury.
    B. It is not necessary to wait for analgesia to reduce the knee.
    C. Presence of pedal pulse does not rule out arterial injury.
    D. One should wait for plain films before attempting reduction.

103. Which of the following is true concerning quadriceps tendon rupture?
    A. Partial tears are seen more often in older patients (> 40 years).
    B. Complete tears are seen more often in younger patients (< 40 years).
    C. Ruptures occur primarily in the presence of degeneration.
    D. There are no plain film findings associated with tendon rupture.

104. Which of the following is true in ACL injury?
    A. Pivoting or cutting maneuvers cause a large number of ACL injuries.
    B. The majority of ACL injuries are non-contact.
    C. Damage to other knee structures is common with ACL injuries.
    D. Most cases produce hemarthrosis in 4-6 hours.
    E. All of the above are true.

105. Which of the following statements is true of PCL injuries?
    A. They are more common than ACL injuries.
    B. They are usually isolated ligament injuries.
    C. Many patients present complaining of a "pop."
    D. Most commonly occur through hyperflexion.

106. Which of the following is true of meniscal injuries?
    A. They are associated with effusions that take 12-24 hours to develop.
    B. They commonly result in "locking" or "catching" complaints.
    C. They are diagnosed with the McMurray or Apley stress test.
    D. Medial meniscus injuries associated with ACL rupture are seen more often than lateral ones.
    E. All of the above are true.

107. Which is true about septic arthritis?
    A. The knee is the most common joint affected in children.
    B. Rheumatoid arthritis does not increase the risk of joint infections.
    C. Replacement of a knee prosthetic device carries a 6% risk of septic arthritis.
    D. *N. gonorrhoeae* infections show up on culture and/or gram stain in a majority of cases.

108. Which of the following is true of septic arthritis?
    A. It cannot occur if the synovial WBC is < 50,000 cells/mm^3.
    B. It cannot occur if the Gram stain of synovial fluid is negative for organisms.
    C. It cannot occur if the culture of synovial fluid is negative.
    D. Pathogen is only identified in 14% of cases through the blood culture.

109. Which of the following statements is true?
    A. The average risk of gout is 20% if present in family members.
    B. Baker's cysts are actually composed of synovial membrane.
    C. Arthritis can occur in the acute phase of Lyme disease infection.
    D. All of the above.

110. Which of the following statements is true?
    A. Distal femur fractures involving the physis carry a high risk of growth arrest.
    B. Patellar dislocations are most common in non-athletic, obese, adolescent females.
    C. Partial ACL tears are less common than complete ruptures in children.
    D. Children with referred knee pain may present with a knee effusion.

CME Answer Key

101. C; 102. C; 103. C; 104. E; 105. D; 106. E; 107. C; 108. D; 109. D; 110. A

Emergency Medicine Reports®
The Practical Journal for Emergency Physicians

The Acutely Injured Knee Part II

Synovial Fluid Results and Suggested Diagnosis

FLUID RESULTS	NORMAL	NON-INFLAMMATORY	INFLAMMATORY	SEPTIC
Color	Clear, yellow	Yellow	Yellow to green	Yellow to gray
Clarity	Transparent	Transparent	Turbid	Turbid
Viscosity	High	High	Low	Variable
WBC / mm^3	< 200	200–2,000	1,000–100,000	15,000–200,000
PMNs	< 10 %	< 25 %	> 50 %	> 75 %
Glucose	~ 90 % of serum	~ 90 % of serum	~ 70 % of serum	< 50 % serum (< 25 mg/dL)
Mucin clot	Good	Good	Good to poor	Poor

Algorithm for Evaluation and Treatment of Knee Dislocations

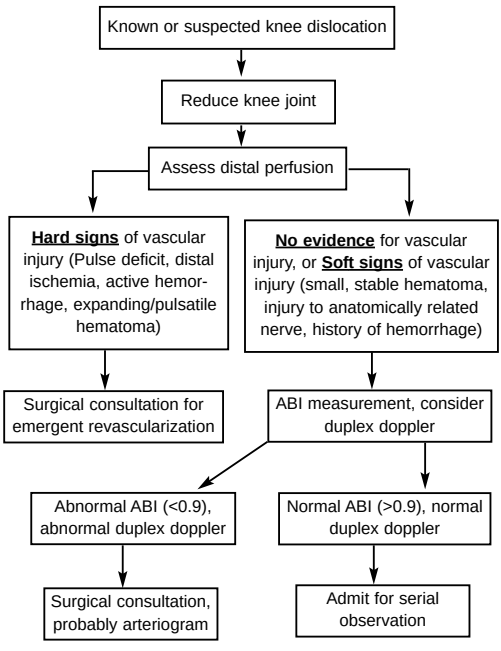

Note hard signs of arterial injury prompt immediate orthopedic consultation/transfer for definitive care. Also even if studies evaluating popliteal artery are normal, the patient should be admitted for observation.

Reprinted from: *American Journal of Emergency Medicine*, volume 19, Perron AD, Brady WJ, Sing RF. Orthopedic pitfalls in the ED: Vascular injury associated with knee dislocation. Pages 583-588, Copyright © 2001, with permission from Elsevier.

Salter-Harris Classification of Growth Plate Fractures

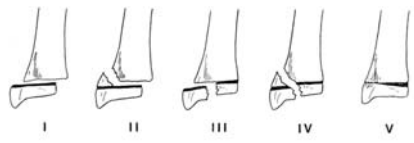

Used with permission from: Tintinalli et al. *Emergency Medicine: A comprehensive study guide*, 6th edition. Figure 267.7, page 1658; 2004.

Key Points in ED Care of Acute Knee Dislocation (Tibial-Femoral Dislocation)

1. All knee dislocations need evaluation for integrity of popliteal artery
   - Use of arteriography, serial exams, Doppler studies at discretion of consultant.
2. Any patient with "hard signs" of arterial injury requires emergent consultation for arterial repair. Hard signs include:
   - Cool, cyanotic foot
   - Obvious pedal pulse deficits
   - Expanding pulsatile mass in popliteal fossa
   - Active arterial bleeding
3. Presence of pedal pulse dose not rule out arterial injury
   - 10% of popliteal artery injuries will have normal pedal pulse.
4. Time to arterial repair is critical to prevent amputation
   - Goal is < 6 – 8 hours of ischemia
   - > 8 hours delay of repair raises amputation rate from 15% to 85%
5. Acute knee dislocations should be reduced as soon as possible after diagnosis
   - It is not necessary to wait for films, phone consultations before reduction
   - It is advisable to wait for IV sedation to aid in reduction procedure
6. All patients with acute knee dislocation should be admitted for observation.

Supplement to *Emergency Medicine Reports*, May 14, 2007: "Evaluation of the Acutely Injured Knee in the ED: Diagnosis and Treatment. Part II." *Authors:* **Gary D. Hals, MD, PhD**, Attending Physician, Department of Emergency Medicine, Palmetto Richland Memorial Hospital, Columbia, SC; **Steven Cruea, MD**, Resident Physician, Department of Emergency Medicine, Palmetto Richland Memorial Hospital, Columbia, SC; and **Dusty Moses, MD**, Resident Physician, Department of Emergency Medicine, Palmetto Richland Memorial Hospital, Columbia, SC