AHC Media LLC

Rapid Reference Card Enclosed

The Practical Journal for Emergency Physicians

# Emergency Medicine Reports®

Volume 28, Number 18 August 20, 2007

*This issue is the second part of a discussion of hand and wrist injuries. The complexity of the anatomy and the variation of injuries provides an explanation of why so many injuries are initially missed. One lesson I have learned is that focal tenderness implies focal injury despite "normal appearing" plain radiographs. I agree with the author's caution for comparison views and advanced imaging modalities (CT or MRI) to detect these often subtle injuries that may have long-term complications.*

*—J. Stephan Stapczynski, MD, FACEP, FAAEM, Editor*

## Falls on the Out-Stretched Hand and Other Traumatic Injuries of the Hand and Wrist: Part II.

*Author:* **Thomas Germano, MD, FACEP**, Assistant Clinical Professor, Brown University Medical School, Attending Physician, Rhode Island Hospital, Providence, RI.

*Peer Reviewers:* **Carl Menckhoff, MD, FACEP, FAAEM**, Associate Professor, Department of Emergency Medicine, Medical College of Georgia, Augusta; and **Andrew D. Perron, MD,** Residency Program Director, Maine Medical Center, Portland.

### Scaphoid Fractures

The scaphoid bone is the most commonly fractured carpal bone, and patient outcomes are frequently less than ideal. Most, but not all, are the result of a fall on the outstretched hand (FOOSH) with resultant hyperextension. Upon hyperextension, the scaphoid impacts the articular radial surface, shearing the bone most commonly at the scaphoid waist. Scaphoid fractures are often seen in adolescents and younger adults. In contrast, older individuals more commonly fracture the distal radial metaphysis, and children are more prone to a growth plate injury.[1-4]

The scaphoid has a relatively large articular surface, limiting direct vascular access to the bone. Its chief blood supply enters the dorsum near the bone's waist. The proximal aspect of the bone, however, receives no direct vasculature and is thus jeopardized following a fracture, which isolates it from the more distally situated nutrient artery. The more proximal a scaphoid fracture, the greater the chance that the proximal bony fragment will undergo avascular necrosis (AVN), and the greater the likelihood of nonunion. While perhaps 30% of fractures of the scaphoid waist result in AVN, it is almost a certainty when a fracture line tran-



**Statement of Financial Disclosure**

To reveal any potential bias in this publication, and in accordance with Accreditation Council for Continuing Medical Education guidelines, we disclose that Dr. Farel (CME question reviewer) owns stock in Johnson & Johnson. Dr. Germano (author), Dr. Menckhoff (peer reviewer), Dr. Perron (peer reviewer), Dr. Schneider (editor), and Dr. Stapczynski (editor) report no relationships with companies related to the field of study covered by this CME activity.

sects the proximal fifth of the bone. Other indicators of a poor prognosis include displacement greater than 1 mm or angulation between the fracture fragments.[1,2,5]

On clinical evaluation, most patients will complain of radial sided wrist pain and tenderness, especially over the anatomic snuffbox. The patient may also note pain over the volar situated scaphoid tubercle, palpable below the snuffbox at the wrist crease, as well as tenderness with thumb axial loading. Increased discomfort with forceful supination of the wrist, pain when circumscribing arcs with the thumb, or pain with ulnar wrist deviation may all indicate a scaphoid fracture.

Snuffbox tenderness, while relatively sensitive, is not specific for a scaphoid fracture. In fact, more often than not, patients exhibiting snuffbox tenderness will eventually be found not to have a scaphoid fracture. A carefully performed goal-directed examination has a high sensitivity for fracture, perhaps as high as 90% and probably exceeding that of plain radiography.[2,3,6]

The initial radiographic evaluation should include standard PA, lateral and oblique projections. A dedicated "scaphoid view" should be ordered in cases where the examination is suspicious. This view elongates the appearance of the bone on the film improving sensitivity. While considerable disagreement exists in the literature regarding the sensitivity of plain radiography (perhaps 60-90%) it is clear that the emergency physician cannot use plain radiography alone to exclude the diagnosis of a scaphoid fracture.

In addition to a diligent search for a lucency, the physician should carefully inspect all spaces between the carpal bones (described previously) as well as evaluate the normal attitudes of the scaphoid and lunate on the lateral view. In the presence of a scaphoid fracture, an abnormal lie of the lunate implies fracture instability and a high potential for nonunion. Loss of the normal scaphoid fat stripe, a small collection of fat parallel to the scaphoid and distal to the radial styloid, may imply a ligament disruption or occult fracture.[1-5,7,8] (*See Figure 1.*)

The clear-cut limitation of plain radiography for this diagnosis, coupled with an understanding that inadequate or delayed treatment may contribute to a poor outcome, has led to various strategies to ensure that patients who have scaphoid fractures are accurately diagnosed. These include the use of computed tomography (CT), magnetic resonance imaging (MRI), or radionuclide bone scanning, as well as empiric splinting in the emergency department (ED) with follow-up plain radiography and examination to be done in several weeks. The latter strategy relies on the principle that the initial bone resorption at the fracture site will allow for fracture visualization on a repeated plain film.[6]

The goals of imaging studies beyond plain radiography are the confirmation of scaphoid fracture, determination of fracture displacement, assessment of fragment viability, and identification of other associated bony or soft-tissue injuries. Equally important is excluding the injury in those patients who don't have it, since the widely used practice of empiric splinting results in loss of mobility, discomfort, and potential stiffness from merely being immobilized while awaiting a definitive diagnosis. The inconvenience includes potential loss of work time and income, diminished ability to safely operate a car, and an overall impediment to activities of daily living. Since the majority of patients with snuffbox tenderness following a FOOSH mechanism with negative initial plain films will ultimately not have a fracture, some of these patients could be returned to normal activity sooner with a more definitive up front imaging study.[6] This, of course, needs to be weighed against the cost of obtaining the more definitive imaging study.

CT scanning has relatively good sensitivity for the diagnosis. In one study of 30 patients, 13 of whom had a scaphoid fracture, CT scanning was 89% sensitive and 91% specific.[9] Radionuclide bone scanning has near-perfect sensitivity for fractures of the scaphoid and, if negative, essentially rules out the diagnosis.[2,6,10] MRI scanning, too, has sensitivity in the 95-100% range, is highly specific, and has the added advantages of providing information regarding fracture displacement, angulation, and associated ligamentous injuries.[6,11-13] CT scanning, MRI, and bone scanning, while often not performed in the ED, may be arranged along with follow-up care.

A delay in diagnosis and proper treatment of a mere week or two may increase the chance of a poor outcome such as a nonunion.[12] It is therefore important upon ED discharge to splint any patients with suspected fracture (focal tenderness but nor-

***Emergency Medicine Reports™*** (ISSN 0746-2506) is published biweekly by AHC Media LLC, 3525 Piedmont Road, N.E., Six Piedmont Center, Suite 400, Atlanta, GA 30305. Telephone: (800) 688-2421 or (404) 262-7436.

**Senior Vice President/Group Publisher:** Brenda Mooney
**Associate Publisher:** Lee Landenberger
**Specialty Editor:** Shelly Morrow Mark
**Marketing Manager:** Shawn DeMario
**GST Registration No.:** R128870672

Periodicals postage paid at Atlanta, GA. **POSTMASTER:** Send address changes to ***Emergency Medicine Reports***, P.O. Box 740059, Atlanta, GA 30374.



**Back issues: $31.** Missing issues will be fulfilled by customer service free of charge when contacted within one month of the missing issue's date.

**Multiple copy prices:** One to nine additional copies, $359 each; 10 to 20 additional copies, $319 each.

**Subscriber Information**

**Customer Service: 1-800-688-2421**

**Customer Service E-Mail:** customerservice@ahcmedia.com
**Editorial E-Mail:** shelly.mark@ahcmedia.com

**World Wide Web page:** http://www.ahcmedia.com

**Subscription Prices**

1 year *with* 60 ACEP/60 AMA/60 AAFP Category 1/Prescribed credits: $544
1 year *without* credit: $399
Add $9.95 for shipping & handling
Resident's rate $199
Discounts available for group subscriptions.
For pricing information, call Tria Kreutzer at (404) 262-5482.

All prices U.S. only.
U.S. possessions and Canada, add $30 plus applicable GST. Other international orders, add $30.

**Accreditation**

AHC Media LLC is accredited by the Accreditation Council for Continuing Medical Education to provide continuing medical education for physicians.

AHC Media LLC designates this educational activity for a maximum of 60 *AMA PRA Category 1 Credits™*. Physicians should only claim credit commensurate with the extent of their participation in the activity.

Approved by the American College of Emergency Physicians for 60 hours of ACEP Category 1 credit.

*Emergency Medicine Reports* has been reviewed and is acceptable for up to 39 Prescribed credits by the American Academy of Family Physicians. AAFP accreditation begins 01/01/07. Term of approval is for one year from this date. Each issue is approved for 1.50 Prescribed credits. Credit may be claimed for 1 year from the date of each issue. The AAFP invites comments on any activity that has been approved for AAFP CME credit. Please forward your comments on the quality of this activity to cmecomment@aafp.org.

This is an educational publication designed to present scientific information and opinion to health professionals, to stimulate thought, and further investigation. It does not provide advice regarding medical diagnosis or treatment for any individual case. It is not intended for use by the layman. Opinions expressed are not necessarily those of this publication. Mention of products or services does not constitute endorsement. Clinical, legal, tax, and other comments are offered for general guidance only; professional counsel should be sought for specific situations.

This CME activity is intended for emergency and family physicians. It is in effect for 24 months from the date of the publication.

AHC Media LLC

**For Customer Service and CME questions,**

Please call our customer service department at **(800) 688-2421.** For editorial questions or comments, please contact **Shelly Morrow Mark,** Specialty Editor, at shelly.mark@ahcmedia.com or (352) 351-2587.

**Figure 1. Scaphoid Fracture**

The scaphoid fat pad has been obliterated.

**Figure 2. The Terry Thomas Sign**

The scapholunate space is markedly abnormal in this patient. Additionally, a signet ring sign is present owing to rotary subluxation.

mal plain radiographs) and arrange for close follow-up and/or further imaging. This practice is justified since false-negative plain films are not infrequent, and associated ligamentous injuries or other fractures often will be missed on initial evaluation. In one group of 59 patients with symptoms suggestive of a scaphoid fracture—all with negative plain radiographs—MRI discovered 4 scaphoid fractures, 10 other fractures, and 3 important ligamentous injuries.[14]

Non-displaced fractures may be managed by closed means, whereas unstable fractures may require surgical management. Instability is defined as a fracture gap greater than 1 mm on any projection, a scapholunate angle greater than 60 degrees, a radiolunate angle greater than 15 degrees, or an intrascaphoid angle greater than 35 degrees. More aggressive approaches may also be warranted with proximal pole fractures or injuries with significant ligamentous disruption.[2-4,6,13,15]

The exact technique of splinting has generated much debate. Some recommend a thumb spica splint be applied from the thumb IP joint to the distal humerus, with the elbow at 90 degrees and the wrist in slight flexion.[8] Others, however, suggest that a short arm splint is adequate.[7] Since the optimal technique of immobilization for these fractures is an area that has generated much controversy, consultation with the surgeon assuming the patient's care seems reasonable. An initial period of immobilization of eight weeks is not unusual given the tenuous nature of the bone's blood supply.

Potential complications of scaphoid fractures are numerous. The most common complication is nonunion. With nonunion or malunion, there is significant risk of carpal instability and ultimately carpal collapse. Additionally, since the scaphoid has a large articular surface with the radius as well as four other carpal bones, there is a high propensity for post-traumatic arthritis.[16,17]

**Scapholunate Ligament Injury.** The most common ligamentous injury of the wrist is disruption of the scapholunate ligament, caused most often by the FOOSH mechanism with the wrist in ulnar deviation. Since these injuries have the same potential long-term complications as scaphoid fractures, namely instability and potential carpal collapse, they are equally important to diagnose correctly. Additionally, since radiographic examination is often normal or yields only subtle clues on plain film, it is important for the emergency physician to maintain a high index of suspicion for this diagnosis. Scapholunate ligament injury may complicate scaphoid fractures as well as distal radial fractures especially if the latter extend into the radiocarpal joint.[18,19]

On examination, the patient often will have tenderness just distal to Lister's tubercle, the approximate location of the scapholunate interval. A positive scaphoid shift test may also assist in making the diagnosis. To perform the test, the physician places his fingers on the dorsal radius and his thumb on the volar wrist at the scaphoid tubercle. The patient's wrist is then brought into ulnar deviation with the examiner's free hand. The examiner then pushes the wrist into radial deviation while pressure is placed dorsally on the scaphoid tubercle. Normally, with radial deviation the tubercle of the scaphoid rotates, assuming a more volar position. Pain and a potential click may be noted in the patient with scapholunate instability. The acutely injured patient may have difficulty complying with this maneuver.[7,19,20]

## Figure 3. DISI and VISI Illustrated

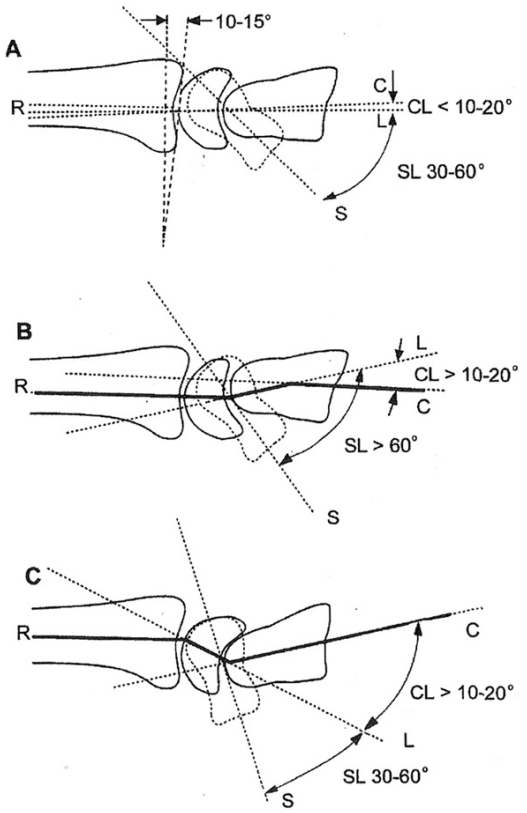


**A.** Normal wrist. (1) Axis of the radius, lunate, and capitate are collinear (three C's sign). (2) The capitolunate (CL) angle is less than 10 to 20 degrees. (3) The scapholunate (SL) angle is between 30 and 60 degrees. (4) The radial volar tilt is 10 to 15 degrees. **B.** Dorsal intercalated segment instability (DISI). The lunate tilts dorsal and slides palmar, increasing the capitolunate angle. The scaphoid tilts more palmar and increases the scapholunate angle. The axes of the radius, lunate, and capitate take on a zigzag pattern (dark line). **C.** Volar intercalated segment instability (VISI). The lunate tilts palmar and the capitolunate angle increases, but the scapholunate angle is maintained. The zigzag pattern is in the opposite direction.

Used with permission from Uehara D, Wolanyk D, Escarza R. Wrist Injuries. In: Tintinalli J, ed. *Emergency Medicine: A Comprehensive Study Guide*. 6th ed. 2004. McGraw Hill & Co.:1676.

## Figure 4. Perilunate Dislocation

The articulation of the radius and lunate is preserved. The capitate is dorsally dislocated.

There are several radiographic signs associated with scapholunate dissociation. A widened scapholunate interval (> 3 mm) on the PA film may be the most obvious. (*See Figure 2.*) This is known as the "Terry Thomas" or "Dave Letterman" sign (for the space between the front teeth of these famous persons). Additionally, the scaphoid may undergo rotary subluxation, flexing abnormally into the palm along its long axis, creating a foreshortened appearance with a "ring" sign on the PA film. (*See Figure 2.*) This ring is not normally seen and is the result of the beam of the x–ray aligning parallel to the cortices of the palmar flexed distal scaphoid. Comparison films may be helpful.

Emergency physicians should become facile at the evaluation of the scapholunate and capitolunate angles on the lateral film. With scapholunate dissociation, the abnormal palmar flexion of the scaphoid and dorsal rotation of the lunate will create abnormally wide scapholunate and capitolunate angles. These are generally not greater than 60 degrees and 20 degrees, respectively. (*See Figure 3.*) This deformity is known as "DISI"—dorsal intercalated segment instability.[7,19]

Some patients will only manifest an abnormality with a stress film known as a clenched fist view. This projection causes the capitate to be driven into the proximal carpal row resulting in a widened scapholunate distance visualized on the PA film. MRI scanning has the advantages discussed above under scaphoid fractures but is generally not performed from the ED.[7,21]

Since there is a wide range of injury from a mild sprain to frank ligament disruption with carpal instability, and since the extent of injury is frequently difficult to elucidate in the emergency department, splinting the patient with a concerning examination in a radial gutter or short arm volar splint is wise. Close orthopedic follow-up should be arranged. If a surgical procedure is required, the likelihood of a good outcome is reduced when the diagnosis is delayed.[22] Patients should be educated that follow-up is important even in the face of normal plain wrist x-rays.

Pitfalls for the emergency physician should be avoidable if a few simple principles are kept in mind. First, patients may not always present acutely to the ED following trauma. Instead, they may treat a "sprain" at home and present days or weeks later.[20,22] Additionally, carpal injuries often complicate distal radius fractures and subtle findings on x–ray may be overlooked when a more obvious diagnosis presents itself. Finally, the limitation of plain radiography, even in the best of hands, suggests a conservative stance with all patients with post-traumatic wrist pain: Splint and arrange follow-up with a hand consultant.

**Perilunate and Lunate Dislocations.** With hyperextension following a scaphoid fracture or scapholunate ligament rupture, the likely next stage of evolving injury is to other ligaments around the lunate. This results in perilunate dislocation and then, ultimately, in frank lunate dislocation. With a perilunate dislocation, there is usually a dorsal dislocation of the capitate from the

**Figure 5. Lunate Dislocation**

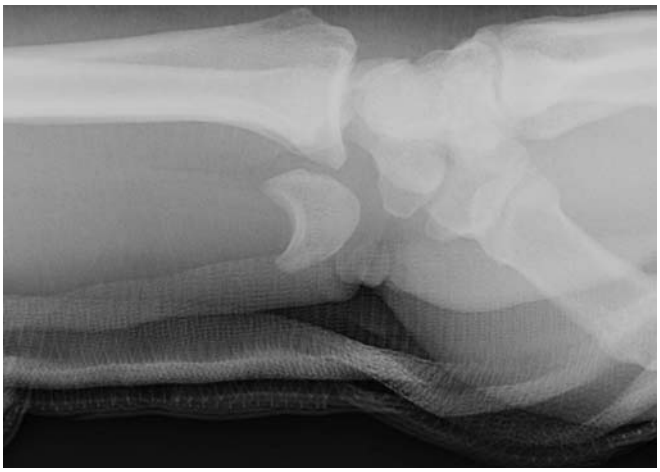

The lunate has dislocated from its radial articulation and the capitate now abuts the distal radius.

lunate while the lunate's position relative to the distal radius remains intact. Far less commonly, a blow to the dorsum of the wrist, or a fall on the palmar flexed hand, may result in a volar dislocation of the capitate from the lunate—a volar perilunate dislocation. Nearly 2 out of 3 patients sustaining a perilunate dislocation have associated fractures—most commonly involving the scaphoid. Other associated fractures include the radial styloid, capitate, triquetrum, hamate, or ulnar styloid.[1,4,23]

On the PA wrist film there will be a loss of the usual carpal arcs. The bones may have a crowded or overlapping appearance. On the lateral film with a true perilunate dislocation, the lunate is still ensconced within its radial articulation. (*See Figure 4.*) It may assume somewhat of a dorsal rotation resulting from pressure on its dorsal surface by an overriding capitate. On occasion, a perilunate dislocation will reduce itself spontaneously, only leaving behind fingerprints of a fracture of a nearby carpal bone, the distal radius, or ulnar styloid.[1]

Lunate dislocations represent the most severe end of the spectrum of hyperextension injuries to the proximal row following a FOOSH. These are associated with even more ligamentous trauma, which allows the lunate to dislocate itself from its radial articulation (usually volarly) as pressure from the overriding capitate causes the bone's displacement. In the classic example, the proximal capitate comes to rest against the distal radial articular surface.

On the lateral plain radiograph, the lunate will have become dissociated from its normal articulation with the distal radius. Most of these are volar dislocations, and the lunate will appear as the classic "spilled tea-cup" palmar to its usual location. (*See Figure 5.*) In some cases, the overriding capitate may appear to articulate directly with radius. On the PA projection, the lunate's rotation toward the palm will create a triangular contour instead of its usual trapezoidal shape—the "piece of pie" sign.[1,7,20]

Associated injuries include carpal bone fractures, distal radius or ulnar styloid fractures, as well as acute median nerve palsy resulting from encroachment on the carpal tunnel by the dislocated lunate. Treatment of perilunate and lunate dislocations will be by either open or closed methods. As a general rule, closed reduction is usually unsuccessful with lunate dislocations. Both perilunate and lunate dislocations will frequently require operative reduction, thus, involvement of a hand surgeon in the patient's initial care should be considered.[8]

**Lunate Fractures.** Lunate fractures are unusual injuries and account for only a small percentage of carpal fractures. Isolated avulsions may occur from either the dorsal or volar surface and may be associated with significant ligamentous injuries, or the body of the lunate may fail under direct axial compression. The overlap of other osseous structures can obscure the radiographic findings of a lunate fracture.[1,8]

Almost a century ago, Keinboch described avascular necrosis of the lunate, which he believed was related to previous trauma. Curiously, this process may take years to develop, and in some cases the inciting injury is not recalled by the patient. It is possible that repetitive trauma for which the patient does not seek medical attention is the cause. The end result of the process may be disabling and require surgical intervention. It is important to consider this possibility when evaluating a patient with subacute wrist pain, even if there is no specific history of antecedent trauma. Early on, MRI may be required to make the diagnosis.[1,7,20]

**Lunotriquetral Ligament Injuries.** A FOOSH injury resulting in sudden radial deviation may result in a tear of the lunotriquetral ligament. Recalling that the triquetrum imparts an extension torquing force on the lunate bone, a complete rupture of the lunotriquetral ligament will result in abnormal volar flexion of the lunate. Clinically, patients complain of ulnar sided wrist pain. On the lateral film, with volar flexion of the lunate, the capitolunate angle is increased but the scapholunate angle is generally preserved. This type of carpal instability is known as volar intercalated instability or VISI. (*See Figure 3.*) That said, it is important to note that the majority of patients with VISI have associated ligamentous injuries, and those with isolated lunotriquetral ligament injury have normal plain films.

Isolated lunotriquetral ligament injury is less common than its scapholunate counterpart. As an isolated injury, it usually carries a more benign prognosis, the exception being the patient with VISI. It is usually treated by closed means, although in some individuals operative intervention may be required.[7,20,24]

**Triquetral Fractures.** The triquetrum is the second most commonly fractured carpal bone, usually resulting from a blow to the dorsal aspect of the hand or a FOOSH with the wrist extended. Small dorsal chip fractures have been theorized to occur as a result of tendinous avulsion or a chiseling action from contact with the triquetrum by either the ulnar styloid or the hamate. Most small dorsal chip fractures occur as isolated fractures, are best viewed on the lateral x-ray, and generally are of little long-term concern. However, significant body fractures may occur and should raise the clinician's suspicion for a spontaneously reduced perilunate dislocation. Avascular necrosis following this injury is not usually a concern. Clinical findings include pain, swelling, and tenderness on the ulnar–dorsal wrist,

especially with wrist flexion and compromise of the ulnar nerve, which lies in close proximity to the triquetrum. These fractures may be treated in a short arm splint in the ED and referred for follow-up.[4,5,7,25,26]

**Pisiform Fractures.** Pisiform fractures account for a small minority of all carpal bone fractures. The injury usually occurs as the result of direct trauma to the bone, such as a FOOSH with a blow to the base of the hypothenar eminence or an avulsion secondary to forceful contraction of the flexor carpi ulnaris (FCU). The latter may occur while doing heavy lifting. Pisiform fractures may also present in a subacute fashion as the result of repetitive trauma to the bone.[27,28]

This fracture is diagnostically challenging since there is often no gross deformity, and plain radiography often appears normal. Two views, the carpal tunnel view and the reverse oblique view, may aid in the diagnosis, although CT or MRI may be required.

The ulnar nerve and artery are closely situated along the radial aspect of the pisiform and may be concomitantly injured. Treatment in the ED consists of applying an ulnar gutter type splint to any patient with a known or suspected fracture and arranging follow-up with the appropriate specialist. Malunion or nonunion with chronic pain is a potential complication, and surgical excision of the bone may be required.[7,8,27]

## Fractures and Dislocations of the Distal Carpal Row

**Capitate Fractures.** Capitate fractures are rare within the spectrum of carpal fractures. Since the proximal capitate bone is intra-articular and relies upon the bone's waist for nutrition, fractures of the waist of the bone may progress to avascular necrosis. The mechanism of injury is usually a FOOSH, direct blow, or an axial load transmitted via the third metacarpal. Examination may reveal tenderness to axial compression of the third digit. These injures may be difficult to diagnose by plain film. In some instances rotation of the proximal fragment may cause an acute fracture to appear old or obscure the fracture line altogether. CT or MRI may be required for diagnosis. Fifty percent are associated with other bony or ligamentous injuries, most frequently a scaphoid fracture. Other associated injures include distal radius fractures and dislocations of either the proximal row or carpometacarpal joint. Non-displaced fractures may be splinted and treated by closed means. Injuries with displacement or other associated trauma will require hand consultation for surgical management.[7,8,29-32]

**Fractures of the Hamate.** Hamate fractures most commonly involve the "hook" and usually occur as a result of a blow to the hypothenar eminence. While these injuries may occur as a result of a fall, they are commonly the result of a blow incurred when a gripped object such as a golf club, baseball bat, or racquet handle strikes a hard object such as the ground. The ricochet of the handle into the palm causes the fracture. Fractures of the body of the hamate are less common and tend to occur as the result of a direct blow such as a crush or after an axial loading force is transmitted through the fourth and fifth metacarpals, such as when an individual punches a wall.

Hamate fractures may be diagnostically challenging since the wrist will often not look deformed on inspection. Additionally, the diagnosis is frequently missed on standard wrist views if it involves only the hook portion of the bone. An associated ulnar nerve or ulnar artery injury may occur since these structures pass through Guyon's canal. Other associated injuries include flexor tendon rupture, carpometacarpal dislocation, or fracture of the fourth or fifth metacarpals.

Clinically, patients will have pain and tenderness over the proximal hypothenar eminence. In the face of normal plain radiographs, pain in the palm with tenderness over the hamate hook, especially if worsened with grip, should raise the possibility of false-negative films.[20,27,33,34] Radiographically, fractures of the hook are best demonstrated on the carpal tunnel view or a reverse (supinated) oblique. Still, some fractures will remain elusive requiring CT scanning or MRI for diagnosis.

Emergent treatment consists of splinting using a short-arm ulnar gutter splint for suspected fractures and isolated non-displaced fractures. Displaced fractures warrant consultation as do any fractures associated with dislocation or neurovascular compromise. Further imaging and hand surgery referral are also warranted for suspected fractures. Third, nonunion may occur, and failure to diagnose the injury will add to that potential. Unfortunately, there is often significant delay in diagnosis contributing to nonunion which then may require excision of the bony hook.[1,7,8,22,27]

**Fractures of the Trapezium and Trapezoid.** Fractures of the trapezium account for approximately 3% of all wrist fractures. These are usually the result of a direct blow or the FOOSH mechanism. While volar trapezial ridge fractures are often isolated avulsion injuries, trapezial body fractures are often associated with other fractures, especially of the first metacarpal, or dislocations of the first carpometacarpal joint. Trapezial body fractures may result from an axial load or hyperextension of the thumb. Tenderness on examination between the first and second metacarpal bases is suggestive of the diagnosis. Plain films usually suffice, but more advanced imaging may be required where fracture anatomy requires better definition or in the patient whose physical examination is suggestive in the face of negative plain films. A carpal tunnel view may be helpful in the diagnosis of a volar ridge fracture. Fractures of the dorsal-ulnar aspect of the bone are easily missed by plain radiographs. While isolated non–displaced fractures may be treated in the ED with a thumb spica splint, displaced fractures and those associated with more significant bony injury or joint trauma will require operative reduction and fixation.

Trapezoid fractures are also rare and infrequently occur alone. A direct blow or a jamming injury with force transmitted along the long axis of the second metacarpal is the usual mechanism. Tenderness with axial compression of the index finger is suggestive. Plain radiographs often will not demonstrate the true nature of the injury because of bony overlap on standard views. As noted elsewhere, if the examination is suspicious, empirical splinting and referral to a hand specialist seems prudent.[5,7,29,35,36]

**Figure 6. A Bennett Fracture**

There is an intra-articular fracture of the first metacarpal base with joint subluxation.

**Figure 7. A Boxer's Fracture**

## Orthopedic Injuries of the Hand

**Thumb Metacarpal Fractures.** The mobility of the thumb metacarpal affords some protection against fracture. When a fracture does occur, it is generally the result of an axial load or a direct blow to the bone. When sending a patient for films, the radiology technician should be alerted to the thumb as the area of interest rather than the hand. An adequate radiographic examination of the thumb must include a dedicated true PA film also known as the Robert's view as well as a true lateral. Fortunately, while most thumb metacarpal fractures involve the base, they remain extra-articular. If non-displaced, these may be treated by immobilization in a thumb spica splint and outpatient follow-up with a generally good prognosis. While 30 degrees of angulation may be tolerable given the mobility of the digit, any rotational deformity is unacceptable.

The situation is different for intra-articular fractures involving the first metacarpal base. Usually these occur secondary to an axial load mechanism. In 1882 Edward Hallaran Bennett described the fracture dislocation that now carries his name. The Bennett fracture (*see Figure 6)* is an intra-articular fracture of the first metacarpal base in which there is dorsal displacement of the metacarpal at the carpometacarpal joint stemming from traction by the adductor pollicis brevis tendon. The proximal bony fragment remains connected to the trapezium. Similarly, a Rolando fracture is a comminuted, intra-articular fracture of the thumb metacarpal base with similar subluxation of the distal fragment. The fragments frequently resemble a "T" or "Y." While it occurs less frequently than the Bennett fracture, it has a worse prognosis. Post-traumatic arthritis is a common sequela of this injury even with optimal care. Both Bennett and Rolando fractures are generally considered unstable, with closed reduction either not possible or difficult to maintain without operative management. While these injuries may initially be treated with a thumb spica splint, given their instability and potential for disabling long-term consequences, urgent consultation with a hand specialist should be considered.[37-39]

**Metacarpal Fractures Exclusive of the Thumb.** Metacarpal fractures account for approximately one in three hand fractures.[39] The mechanism of injury for most metacarpal fractures is a direct impact or an axial load that occurs when a patient hits a hard surface with a closed fist. These injuries may be divided into fractures of the distally situated head, as well as the metacarpal neck, shaft, or base. Poor outcomes are associated with rotational malalignment, associated soft-tissue injuries, or malunion. Associated injuries include extensor tendon injuries, carpal injuries, CMC joint dislocations, or collateral ligament injuries.

Metacarpal head fractures are unusual injuries that are frequently intra-articular, with comminution being common. An associated avulsion of the collateral ligament may be present and distort the normal contour of the knuckles. This can be demonstrated radiographically using the Brewerton or skyline view or by CT. The former is a view taken with MCP joints flexed and allows better visualization of the metacarpal heads.

Bony neck fractures involving the fourth or fifth metacarpals are the most common fractures of the hand and are known as Boxer's fractures although, ironically, they rarely occur in professional boxing. (*See Figure 7.*) Neck fractures of second and third metacarpals are less frequent. These injuries typically occur just proximal to the metacarpal head and have a volar angulation. The fourth and fifth CMC joints have enough mobility in the sagittal plane to allow for compensation of a significant degree of angu-

**Figure 8. Pseudoclawing Deformity**

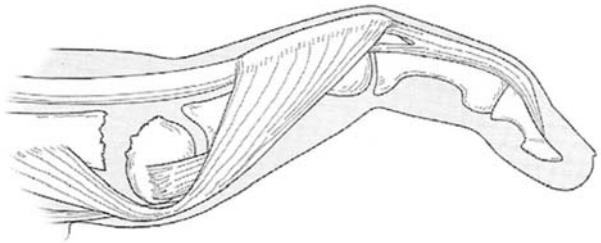

A metacarpal neck fracture that is not properly reduced will develop a compensatory MCP joint hyperextension and PIP joint flexion known as pseudoclawing.

Used with permission from Simon R, Sherman S, Koenigsknecht S. Hand. *Emergency Orthopedics—The Extremities*. 2007. McGraw Hill & Co. p. 146.

**Figure 9. Stener Lesion**

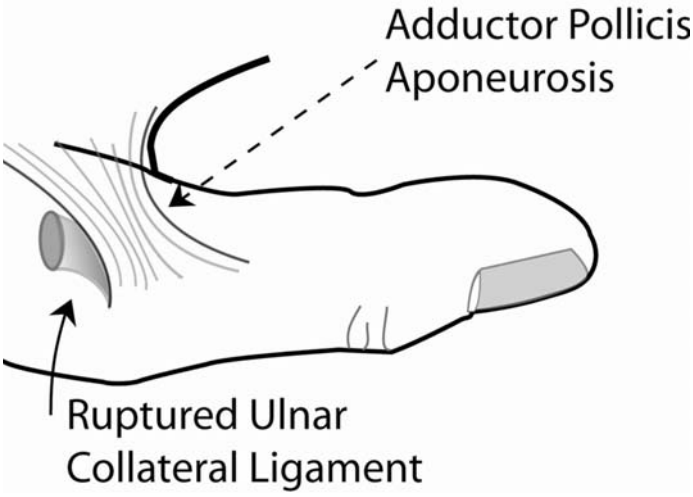


The ruptured proximal ulnar collateral ligament fails to reduce properly and remains superficial to the adductor pollicis aponeurosis. Illustration by Jennifer Rolfsema.

lation of a distal neck fracture. This is not true of the second and third CMC joints, where angulation beyond about 10-20 degrees should be reduced.[40]

How much angulation is acceptable in a fourth or fifth metacarpal fracture is controversial. It has been shown in one cadaver model that angulation greater than approximately 30 degrees is associated with potential weakness of flexion across the MCP joint due to a slackening of the flexor digiti minimi.[41] That said, in a study by Muller, in which no attempt at reduction was made for fractures with angulation less than 70 degrees, no significant differences in pain, range of motion, and overall satisfaction were noted between patients who were immobilized for three weeks in an ulnar gutter versus patients who were treated with a compression bandage and early range of motion. In that study the average angulation was 39 degrees.[42] Several standard emergency medical texts suggest reduction if the angulation of a fifth metacarpal neck fracture exceeds approximately 35-40 degrees.[38,43,44] The treatment of these injuries should be individualized, taking into consideration which metacarpal is involved, the degree of fracture angulation, and the age and occupation of the patient. One potential risk of not reducing a significantly angulated fracture is the development of a pseudoclawing deformity formed by hyperextension at the MCP and flexion at the PIP.[38] (*See Figure 8.*)

Reduction may be attempted in the ED using the Jahss maneuver. Following the establishment of satisfactory anesthesia using a hematoma block or an ulnar nerve block at the wrist, the physician has the patient flex the MCP and PIP joints to 90 degrees. Subsequently, dorsal pressure is applied to the PIP joint while volar pressure is applied over the proximal metacarpal. The hand is then splinted using an ulnar gutter with 30 degrees of extension at the wrist, 90 degrees of flexion at the MCP joints, and extension at the PIP joints.[38,40,45]

With any metacarpal fracture, a rotational deformity is unacceptable. On examination, one clue to rotation is misalignment of the involved finger during fist closure. Normally, all of the distal phalanges should point toward the scaphoid. With significant rotation, frank finger overlap ("scissoring") or divergence may occur. Acutely, it may be more useful to inspect the patient's nails. The nails should lie on roughly the same horizontal plane when sighted end on. It is notable, however, that in some individuals this trusted teaching is not true, thus stressing the importance of comparing the same digit on both hands.[46] The hand should be examined in flexion and extension to the best ability of the patient, as some rotational misalignments may be occult in extension.[45] To reduce a rotational deformity, the finger can be held in traction while twisting it back into normal position. It can then be buddy-taped to the adjacent finger to maintain reduction.

Metacarpal shaft fractures are typically described as transverse, oblique, or comminuted. Minimally displaced shaft fractures without rotational deformity may be treated with preliminary splinting and eventual casting. Spiral fractures frequently have a rotational component that must be reduced. Comminuted fractures and/or spiral fractures may be unstable and require surgical intervention.

Dislocations of the CMC joint or extensor tendon injuries may accompany fractures of the metacarpal bases. Additionally, fractures of the fourth or fifth metacarpal bases are sometimes associated with ulnar nerve injury. It is important to note that angulation that would be considered acceptable with a neck fracture may be unacceptable with a more proximal injury, since in the latter the effects of the angulation are more pronounced.[38]

**Thumb Ligamentous Injuries.** Forced abduction of the thumb may partially or completely tear the ulnar collateral ligament of the MCP joint. Traditionally, this injury has been referred to as a Gamekeeper's thumb after the injury was originally described in people who manually sacrificed small game by breaking the animal's neck. While working in this trade, game-

keepers frequently injured their thumbs. Today, these injuries are seen in a variety of situations, including contact sports and in skiing when the skier falls over a planted pole or falls onto the snow with the thumb abducted. These also occur in cycling or motor vehicle collisions when the thumb jams into a handlebar or steering wheel during a frontal impact. The ligamentous injury may occur alone or with an avulsion fracture of the proximal phalanx.

Patients will often complain of pain and swelling at the thumb MCP joint and tenderness may be noted over the ulnar collateral ligament. Plain films will often be negative. Complete tears may be diagnosed by clinical examination or radiographically using stress views of the joint. Some authors have advocated the use of MRI or ultrasonography as an adjunct to clinical examination.[47,48] Adequately stressing the joint requires infiltration of local anesthesia or block of the median and radial nerves at the wrist. Performing a stress examination carries a risk of causing a Stener lesion (see below) where one did not exist previously, or displacing an avulsion fracture, thus creating the need for an open procedure.[48,49] If undertaken in the ED, the joint should be stressed in maximum flexion, since this position isolates the ligament. Angulation of 35 degrees or more, or greater than a 15-degree difference than the uninjured side, constitutes a positive test and is suggestive of a complete tear. Instability in full extension implies additional injury to the volar plate.[49,50]

The Stener lesion (*see Figure 9*) occurs when the proximal end of the completely torn ligament is pulled out from its normal location deep to the abductor aponeurosis during the initial or subsequent valgus stress. It then fails to reduce itself properly and remains superficial to the aponeurosis. Thus, the proximal and distal portions of the ligament are separated by the intervening abductor aponeurosis, creating the need for surgical correction. A Stener lesion is present in perhaps 50% or more of patients with a complete ulnar collateral ligament tear.

Patients suspected of having this injury should be splinted using a thumb spica splint and have close consultation arranged. Delayed diagnosis and under-treatment can contribute to complications including chronic pain, weakness with pinching or frank first MCP joint instability.[49-52]

**Fractures of the Proximal and Middle Phalanges.** Fractures of the proximal and middle phalanges have similar mechanisms of injury, usually a direct blow, torquing force, or hyperextension. Obtaining a PA, lateral, and oblique radiographs will usually suffice in the ED.

As a result of the initial trauma, as well as the forces exerted by the tendinous insertions, these fractures may be angulated or displaced and irreducible, requiring early consultation with a hand surgeon. Other circumstances for which early consultation is warranted include: fractures that are intra-articular, especially if displaced or involving greater than 20% of the articular surface; any fracture that appears rotated radiographically or by examination (see above section on metacarpal fractures); patients with multiple or open fractures; and those associated with significant tissue loss.

Complications include associated tendon injuries, malunion or nonunion (especially with under-treatment), digital nerve injury, and tendinous adhesions of either the flexors or extensors forming during the healing phase. Rotational deformity can occur and should be reduced. Additionally, instability of the PIP joint may result from injury to any of its stabilizing ligaments.[38,40,53] The most common long-term problem is joint stiffness.[54]

These fractures may be described as intra-articular or extra-articular fractures. A blow that results in an oblique or spiral shaft fracture may often be associated with a rotational deformity. Displaced and angulated fractures are likely to be unstable, even following reduction. Comminuted fractures may appear deceptively stable but a more conservative approach is advisable. Patients with non–displaced, transverse shaft fractures may be treated using dynamic splinting (buddy taping). Indeed, overzealous treatment with prolonged immobilization can result in long-term stiffness. Alternatively, if the patient is in a significant degree of pain, a gutter splint may be used for the initial week of treatment. Intra-articular fractures involving either the bases or condyles of the bones should be considered to have a potential for instability and a subsequent need for eventual surgical intervention. Intra-articular fractures also may be associated with collateral ligament disruption and joint instability.[38-40,53,54]

Shaft fractures have a predilection for angulation and instability resulting from the constant tension of the extensors and flexors and their insertions on the middle phalanx. Shaft fractures of the middle and proximal phalanges are treated similarly. Intra-articular fractures are considered unstable if they involve more than 20% of the articular surface, or are displaced and may require surgical intervention. Stable fractures may be treated with dynamic splinting with close follow-up arranged for the patient.

Avulsion fractures of the base of the middle phalanx deserve special mention since they have important implications for PIP joint function. Many of these occur as a result of jamming or stubbing mechanisms or a dorsal impact from a ball on the extended finger during certain sports. The fracture may occur as a result of a volar PIP dislocation and may be associated with

**Figure 10. Boutonnière Deformity**

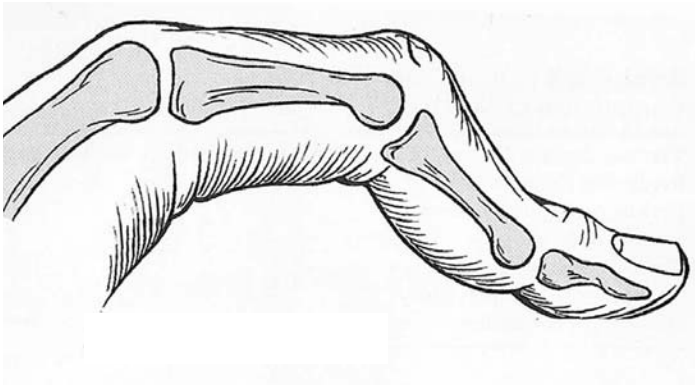

Reprinted with permission from: Muelleman RL, Wadman M. Injuries to the hand and digits. In: Tintinalli J, ed. *Emergency Medicine: A Comprehensive Study Guide*. 6th ed. 2004. McGraw Hill. p 1672.

**Figure 11. Mallet Deformity**

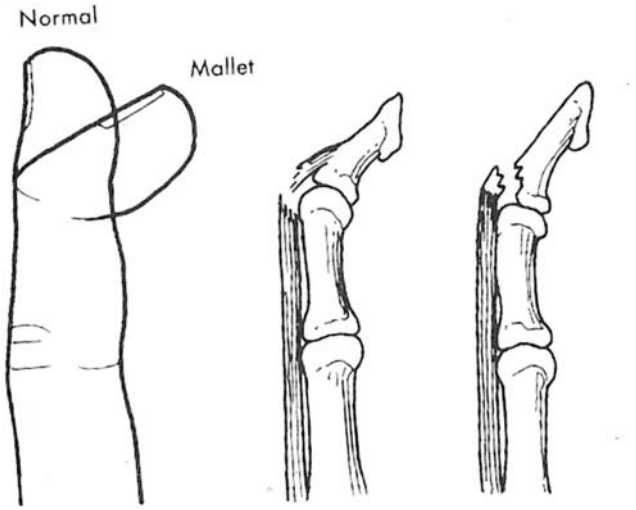


Reprinted with permission from: Antosia, R, Lynn E. The Hand. In: *Emergency Medicine. Concepts and Clinical Practice*. 4th ed. p. 655. 1998. Elsevier.

**Figure 12. Swan Neck Deformity**

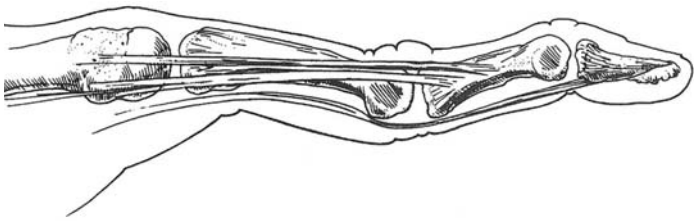

Reprinted with permission from: Simon R, Sherman S, Koenigsknecht S. Hand. In: *Emergency Orthopedics—The Extremities*. 2007. McGraw Hill & Co. p. 131.

other ligamentous instability of the PIP joint.

Although dorsal fractures may be small in size, they are potentially devastating injuries since the extensor's central insertion may be avulsed with the fragment, creating a potential for the development of a boutonnière deformity. (*See Figure 10.*) This deformity results when the lateral bands of the extensor mechanism, no longer tethered in their normal position by the dorsal insertion, slip toward the volar surface. As a result, they no longer serve to extend the PIP joint but rather hold it in flexion. Unfortunately, the injury is often under appreciated, since it may take weeks to develop. PIP hyperextension injuries or acute lateral strain may result in avulsions of the volar or lateral aspects of the intra-articular base of the middle phalanx, resulting in an unstable joint.[38,40,50,55]

**Fractures of the Distal Phalanx.** Fractures of the distal phalanx are the most common type of hand fracture and may involve the tuft, shaft, or the bone's intra-articular surface. Tuft fractures tend to be the result of a direct blow to the distal finger such as a misplaced strike while hammering a nail. In this situation, significant trauma to the nail and its supporting structures often results. If the fracture is a closed injury, there will likely be a subungual hematoma. The hematoma may cause the patient significant pain, in which case the nail may be trephinated in a sterile fashion. This may be done using any one of several tools including a heated paper clip, needle, or electrocautery.

A displaced fracture may be associated with significant soft-tissue injury to the nail bed or volar pulp space and may well be an open injury. With these open injuries, the maintaining fracture reduction and alignment is dependent upon the repair of the soft tissues to restore as much of the normal finger anatomy as possible. In fact, an intact nail will serve as a biologic splint for a tuft fracture. Thus, if the nail is avulsed off its matrix or out from the eponychium, it should be removed, the matrix should be sutured, and the nail should be replaced into the nail fold. A retention suture may then be used to anchor it into position. Open fractures require copious irrigation, prophylaxis for infection, and tetanus immunization. Tuft fractures may be splinted for patient comfort for about 1-2 weeks. The splint should leave the PIP free.

The approach to a patent with an intact nail with a significant subungual hematoma is more controversial. While some have advocated for nail removal and nail bed exploration, there is support for a less aggressive approach using trephination alone. Similarly controversial is whether or not to prescribe prophylactic antibiotics to a patient who has had a nail trephination.[40,53,56-58]

A jamming mechanism imposing sudden flexion forces on an extended DIP joint may result in a dorsal avulsion fracture. This is a common injury for players of ball sports, hence the term baseball finger. If the fragment is of significant size, the extensor mechanism may be avulsed with the fracture resulting in a mallet finger.[40,53,59] (*See Figure 11.*) This deformity stems from unopposed flexion at the DIP joint exerted by the flexor digitorum profundus tendon. An uncorrected mallet deformity may result in proximal migration of the extensor mechanism. This may result in an extension deformity at the PIP joint with a concomitant flexion deformity at the DIP joint, known as a swan neck deformity. (*See Figure 12.*) A fracture involving less than one-third the articular surface may be treated by splinting the DIP joint in slight extension leaving the PIP joint free.

If a closed treatment is opted for, the patient must be instructed that the joint must remain in full extension at all times for 8-10 weeks. Any flexion of the DIP joint prior to that time may once again recreate the original injury and negate any healing that has already occurred.[60] Fractures involving more than one-third of the articular surface or those individuals who fail conservative measures are candidates for surgical intervention.[38,53,59] Some individuals with relatively large articular surface involvement may still opt for treatment by closed means. While the cosmetics of the final outcome will likely be less than ideal, there may be no significant degree of pain or impediment to normal daily activities. Avulsion fractures may also occur off the palmar side of the distal phalanx at the DIP joint as the result of sudden

extension while the finger is actively flexed. In that situation the insertion of the long flexor tendon may be avulsed, manifested clinically by loss of DIP flexion.[61,62] This injury, known as a jersey finger, is discussed later in this article.

**Ligament and Joint Injuries.** The second through fifth carpometacarpal joints are relatively fixed within the palm and are uncommonly dislocated. Given their interlocking geometry with the carpus, fracture-dislocations are more common than pure dislocations. The fifth CMC joint is the most frequently dislocated.[63] Other associated injuries include trauma to the extensor tendons, ulnar or median nerves, or the deep palmar arch.[52] Clues on the PA film to a CMC dislocation include loss of the parallel "M's" or bony overlap.[64,65] An attempt at reduction may be made in the ED; however, soft tissue interposed between the articular surfaces may block success. Since surgical management is frequently needed, early consultation with a hand surgeon should be considered.

Similarly, MCP joint dislocations are infrequent occurrences and are unlikely to be lone injuries. Most often these are dorsal dislocations with potential concomitant volar plate injury. In the latter situation, interposition of the plate itself may prevent reduction. If closed reduction is attempted in the ED, excessive traction or hyperextension of the joint must be avoided since it may result in just such an interposition, thus mandating an open reduction.[52,63]

The PIP joint is the most commonly dislocated joint in the body.[51] This injury is a common sight on the sidelines of contact sporting events and is often reduced on the field earning it the name coach's finger. While the coach may treat this injury with complacency, unaware of its potential long-term complications, the emergency physician must treat the problem with greater respect. The volar plate and the two collateral ligaments are the primary stabilizers of the joint. For a dislocation to occur, two of these three structures must be breached. Dislocations are described as dorsal (most common), lateral, or volar. It is important to query the patient who presents with a previously reduced dislocation as to the exact appearance of the deformity, since the treatment differs for each type. These patients should be considered for imaging to rule out an associated fracture.

Most PIP joint dislocations can be successfully reduced and treated in the ED. The commonly encountered dorsal dislocation may be reduced by applying gentle traction on the digit while directing volar pressure on the middle phalanx. Mild initial hyperextension may facilitate reduction. The joint is then splinted at 20–30 degrees of flexion for several days up to a couple of weeks, as symptoms dictate. The patient is then asked to buddy tape the finger for a period of several weeks. If, however, the joint appears to hyperextend either on examination or stress testing under digital anesthesia, a complete rupture of the volar plate should be suspected and the joint should be splinted and the patient referred to a hand specialist.[50-52,63,66]

While volar dislocation is less common than the dorsal variety, the injury can cause a rupture of the central extensor slip, potentially initiating a boutonnière deformity. The mechanics of this injury have been previously discussed. It is noteworthy to add that if the physician wrongly concludes that the injury was the dorsal variant, splinting the joint in flexion may actually facilitate the development of exactly that complication.

Following reduction, volar dislocations are best splinted in slight extension and referred to a hand consultant. Unfortunately, these injuries are often misdiagnosed as the more benign dorsal dislocation with delays in appropriate treatment, which may contribute to poor outcomes. In one series such a delay was noted to be 11 weeks, with associated worsened outcomes.[52,63,67]

Lateral dislocations result from tearing of one collateral ligament plus injury to the volar plate potentially resulting in frank joint instability. To ascertain instability, the joint must be stressed to valgus or varus forces in complete extension. More than 20 degrees of forced angulation is suspicious for a complete tear of a collateral ligament and at least a partial volar plate injury. Reduction is usually straightforward, and early range of motion is instituted with buddy taping.[63,66] The most common long-term complication of PIP joint dislocations is persistent swelling and stiffness. This occurs as the fusiform swelling and edema of the injury are replaced by scar. This is best avoided by instituting dynamic splinting as soon as possible. Additionally, flexion contracture or a swan neck deformity may occur. Following PIP dislocation perhaps one in three patients will experience a sub-optimal outcome.[63,66,68]

Dislocations of the DIP joint are rare injuries usually resulting from hyperextension and are often open dislocations. If they are closed injuries, they may be reduced in the ED, splinted in slight flexion, and referred for follow-up. In some cases, reduction may not be possible as a result of interposed soft tissues.[63,69]

**Tendon Injuries.** Patients with isolated tendon injuries may not seek care immediately, may have no radiographic abnormalities, and may appear comfortable with minimal pain or swelling. All of these are potential sources of error for the clinician. For good long-term outcome, it is important to diagnose these injuries initially. The key to a correct diagnosis is an understanding that the examination findings may be subtle and/or delayed in their appearance.[70]

Following a jamming injury forcing the DIP joint into flexion, a rupture of the extensor tendon insertion at the distal phalanx may occur. While this may result in a frank mallet deformity (discussed above) the findings may be less impressive with the extensor lag not developing for days. Thus, all patients with a suspected extensor tendon avulsion or partial avulsion should be carefully examined. If a high index of suspicion remains, consider splinting with the DIP joint in slight extension and outpatient referral. The splint must be left on for 8 weeks, during which time the joint must not bend. The splint should be removed daily with the joint maintained in extension on a flat table for the skin to dry, since maceration beneath the splint may occur. Patients should be advised that the price to pay for non-compliance may be a swan neck deformity.[39,59,60-63,68,70]

Rupture of the flexor digitorum profundus may occur via a forced extension of the DIP while the tendon is taught. This may occur in contact sports when the patient's finger catches on another player's jersey, hence the name jersey finger. Due to ten-

don retraction, pain and swelling may occur anywhere along the flexor sheath—even as proximal as the palm. On examination the normal resting attitude of the hand may appear abnormal, the patient will be unable to flex the DIP joint, and may be unable to close a fist completely. The long-term complication with this injury is a flexion contracture of the finger stemming from adhesions within the flexor sheath. In the ED these patients should be splinted with the wrist in 30 degrees of flexion, the MCP at 70 degrees, and the IP joints in 30 degrees of flexion.[70] Early surgery is usually advised since the tendon may retract all the way into the palm, and the results are sub-optimal if it is delayed beyond about a week. Discussion with a hand surgeon to ensure follow-up is advisable.[39,51,70]

The extensor tendon central slip insertion may be avulsed from the middle phalangeal base with forced flexion of the PIP joint. It commonly results from a jamming injury during sports. If unrecognized, progression to a boutonnière deformity (discussed above) can be anticipated. While the deformity may develop acutely, more commonly it will take days to weeks. Without a deformity on examination, the diagnosis can be particularly elusive. Furthermore, the lateral bands initially may continue to be able to extend the PIP joint, obscuring the true nature of the injury.

A diagnostic maneuver that can aid in making a correct diagnosis is to have the patient flex the PIP joint over the edge of a table to 90 degrees while the DIP joint is kept straight. The patient is then asked to extend the PIP joint against a resistance placed on the middle phalanx. This position eliminates the effects of the lateral bands. Thus, any PIP joint extension is the result of intact central slip function. If a central slip injury is suspected, treatment includes splinting the PIP joint in full extension leaving the DIP and MCP joints free and referral to a hand specialist. Once a boutonnière deformity has become clinically apparent, the chance for a good long-term outcome is considerably less.[71-73]

Similar to the complications encountered with the aforementioned tendon injuries, lacerations involving the flexor or extensor tendons and their insertions may upset the intricate balance of flexion and extension at the IP joints, producing any of the deformities described above.

The evaluation and management of hand lacerations is beyond the scope of this article, but some fundamentals are considered here. A proper examination of the lacerated hand includes a thorough inspection with proper lighting, hemostasis, pain control, and a cooperative patient—all of which are not easily obtainable in the ED. Partial lacerations may not produce an abnormal motor examination and, thus, at times the wound must be visually inspected to make a diagnosis of a tendon injury. During exploration, the hand or finger should be put through a full range of motion to inspect any exposed tendon, since this maneuver may bring into view an injury that initially may not have been seen. Physicians should also bear in mind that a transected tendon may completely retract out of site. Partial tendon lacerations greater than approximately 50% of the tendon width have a propensity for delayed rupture, and primary repair is suggested. Additionally, the possibility of an open joint should be considered with any laceration near the MCP or IP joints.

The extensor tendons are very superficial along their course in the hand and are frequently involved with lacerations to the dorsal surface. Over the metacarpal, the communis tendons of the long, ring, and small fingers are interconnected by the juncture tendinum. Even a complete laceration initially may produce a deceptively normal examination. If, however, the patient is able to extend each finger individually while the other fingers are held flexed, that finger's communis tendon is intact. Conversely, a lack of ability to extend the MCP joint or weakness compared to the opposite side is a suspicious finding. Furthermore, the independent extension afforded by extensor indicis proprius and extensor digiti minimi to their respective digits may similarly mask a laceration in their communis tendons or vice versa. For lacerations near the MCP joint, a high index of suspicion should be maintained for a fight bite. Dorsal lacerations near the PIP joint may involve the central extensor insertion, resulting in a boutonnière deformity. Those located over the dorsal middle phalanx or DIP joint may result in a mallet finger deformity.[74,75]

While extensor tendon repair may be performed by the emergency physician, flexor tendon inspection and repair is more difficult since these tendons reside within fibrous sheaths and are enveloped by the flexor pulley system. Volar lacerations of the hand from the level of the distal palm to the superficialis tendon insertion at the middle phalanx (flexor zone 2) have an especially poor prognosis. In zone 2 both the superficial and deep tendons share one fibrous sheath, and some of the more important flexor pulleys are vulnerable at this location. Since primary repair of these tendons may require exploration within the flexor sheaths with potential for an iatrogenic injury to occur, only physicians with expertise in this area should attempt a primary flexor tendon repair. Complications of flexor tendon lacerations include long-term stiffness or triggering, flexion contractures, delayed tendon rupture, and bowstringing.[76,77]

## Compartment Syndromes

Compartment syndromes with long-term sequelae may occur following significant orthopedic trauma to the hand. There are 10 compartments within the hand: thenar, hypothenar, adductor pollicis, four dorsal, and three volar interosseous. Compartment syndromes are possible within each of these or in individual fingers since the fingers are also enveloped by a tough fascia. Additionally, the carpal tunnel may act as a "compartment." Swelling or bleeding within these compartments can directly affect venous pressure since the veins lack rigid walls. When the normal interstitial pressure increases beyond normal venous pressure, a reduction in perfusion pressure (the difference between arterial and venous pressure) occurs. With dropping perfusion pressure, tissue ischemia ensues with neuronal death and contracture of the muscles within the compartment.

Compartment syndromes have been reported in a variety of situations, including: crush injuries; the unconscious patient (the comatose drug overdose patient laying on their forearm); patients with coagulopathy (warfarin, hemophilia); burns; snake enveno-

mations; intravenous drug use; and bony fractures. Iatrogenic causes include soft- tissue infiltration of intravenous lines, complications of arterial punctures, malpositioning during surgical procedures, and casting or bandaging that is too tight.

On examination, while marked swelling on the dorsum of the hand is often present, loss of the normal palmar concavity with firmness to palpation of the volar palm should increase the level of concern. Additionally, taught swelling of the thenar or hypothenar eminences may be noted. The patient's hand may assume an "intrinsic minus" position—extension at the MCP joints and flexion of the IP joints. If the thenar compartment is involved the thumb may be held in palmar abduction.

While not specific, the most consistent sign of a compartment syndrome is pain. It is often severe and typically escalates over time. While it initially may be confused for the pain associated with the original injury, pain out of proportion to the sustained trauma should provide a clue to the diagnosis. The discomfort may worsen rather than improve with elevation, which decreases the arterial pressure head thus worsening ischemia. Pain worsened with passive range of motion is particularly worrisome, and diminished two-point discrimination or loss of vibratory sensation may be additional signs not to be missed early on. Loss of a palpable pulse is a late finding. The diagnosis in the mentally altered patient or the pre–verbal child can be especially challenging.[78-82]

Emergency management consists of the management of associated trauma to support the arterial pressure, reduction of any unreduced fracture, analgesia, and emergent consultation with a hand specialist. The measurement of intra-compartmental pressures is beyond the scope of this article.[83]

## Amputations and Avulsions

Amputations of the distal phalanx are the most commonly encountered upper extremity amputations and most frequently involve the thumb and middle finger.[84] These injuries involve varying degrees of tissue loss distal to the DIP joint and may be characterized according to Allen's classification of finger-tip injuries. Zone 1 is a distal finger-tip injury not involving the nail or nail-bed; zone 2 injuries involve the nail and/or nail-bed but without bony involvement; zone 3 injuries involve the bone distal to the lunula; and zone 4 are more proximal injuries. The goals of treatment are to preserve bony length and to provide a stable, sensate, pain-free fingertip, preserving as much of the pulp as possible while covering any exposed bone.

For zone 1 and smaller zone 2 injuries (less than 50% of the nail-bed involved), conservative treatment with occlusive dressings and referral to a hand specialist is indicated if the wound measures less than approximately 1 $cm^2$. Early mobility of the DIP joint should be encouraged to prevent stiffness. Larger zone 2 injuries and zone 3 injuries involving less than 50% of the nail-bed are best managed by primary closure if enough viable tissue remains or using a flap procedure. The most commonly used flap is a V-Y plasty, which works best with transverse or dorsal oblique amputations, with sufficient volar tissue remaining.

In situations with greater than 50% of the nail bed injured, preservation of normal nail anatomy is unlikely and shortening of the digit with nail bed excision is often required. If possible, the decision to shorten a digit should be made in consultation with a hand surgeon, or performed by the surgeon since other options that preserve bony length are more desirable. Patients with proximal amputations (zone 4) may be candidates for replantation, especially when the thumb or index finger is involved.[84-86] More proximal amputations involving the distal upper extremity are true surgical emergencies as the potential viability of the amputated part is reduced with each passing hour. Generally, if the time to surgery is greater than six hours, the chance for a good result is reduced. Even so, replantations have been successful with ischemia times of 12 hours or more. Patients arriving with amputated parts should have those parts rinsed with sterile saline, placed in saline wetted gauze, the gauze placed in a dry plastic bag, and the bag placed in ice. There should be no direct contact with ice to avoid freezing injury. The emergency physician should make sure this information is given to pre-hospital providers also. Severed parts or tissue arriving with the patient should never be discarded, since they maybe useful for grafting purposes.

The patient should be managed similar to any other open orthopedic emergency utilizing appropriate analgesia, emergent radiography, antimicrobial prophylaxis, and tetanus immunization where needed. Bleeding should be controlled with direct pressure and elevation, or as a last resort by tourniquet, but never by blind clamping. The patient should be made NPO on arrival to the ED, and a hand surgeon should be contacted. All patients initially should be considered replantation candidates until the treating surgeon opts for another course of management.

Indications for replantation include patients with thumb amputations, amputations of the wrist or forearm, pediatric patients, those with multiple digits involved, and some patients with distal phalanx amputations beyond the flexor profundus insertion (Allen zone 4). Relative contraindications include ischemia time greater than 6 hours, single digit involvement, crush mechanism, contamination, amputations in flexor zone 2 (proximal to the insertion of the superficialis tendon), and amputations occurring in patients with significant co-morbidities such as diabetes and peripheral vascular disease. Other considerations include predicted patient compliance, hand dominance, occupation, smoking, and hobbies. Partial amputations may derive some perfusion by bridging tissues, prolonging the window of opportunity. Additionally, a guillotine mechanism or clean cut portends a more favorable outcome than a jagged laceration or a crush.

In some cases replantation has a less favorable prognosis, and a shortened digit may retain more function than a stiff, poorly sensate replanted finger. Care must be individualized.[87-89]

## References


1. Rogers L, Hendrix R. The Wrist. In: *Radiology of Skeletal Trauma*. 2nd ed. New York: Churchill Livingstone; 1992:837-938.
2. Krasin E, Goldwirth M, Gold A, Goldwin DR. Review of the current methods in the diagnosis and treatment of scaphoid fractures. *PostgradMed J* 2001;77:235–237.
3. Ring D, Jupiter J, Herndon J. Acute fractures of the scaphoid. *J Am Acad*

*Orthop Surg* 200;8:225–231.
4. Ritchie J, Munter D. Emergency department evaluation and treatment of wrist injuries. *Emerg Med Clinics NA* 1999;17:823–842.
5. Goldfarb C, et al. Wrist fractures: What the clinician wants to know. *Radiology* 2001;219:11-28.
6. Steinmann S, Adams J. Scaphoid fractures and nonunions: Diagnosis and treatment. *J Ortho Sci* 2006;11:424–431.
7. Escarza R, Chin H. Wrist injuries. In: *Emergency and Primary Care of the Hand*. Dallas, TX: American College of Emergency Physicians; 2001: 139-160.
8. Simon R, Sherman S, Koenigsknecht S. Wrist. In: *Emergency Orthopedics—The Extremities.* New York: McGraw Hill; 2007:184-217.
9. Addey L, et al. Computed tomography of suspected scaphoid fractures. *J Hand Surg* 2007;32A:61–66.
10. Chakravarty D, Sloan J, Brenchley J. Risk reduction through skeletal scintigraphy as a suspected screening tool in suspected scaphoid fracture: a literature review. *Emerg Med J* 2002;19:507-509.
11. Foex B, Brody R. Magnetic resonance imaging or bone scintigraphy in the diagnosis of plain x-ray occult scaphoid fractures. *Emerg Med J* 2005;6: 434-435.
12. Timins M, et al. MR imaging of the major carpal stabilizing ligaments: Normal anatomy and clinical examples. *Radiographics* 1995;15:575–587
13. Ballas MT, Tytko J, Mannarino F. Commonly missed orthopedic problems. *Am Fam Physician* 1998;57:267–274.
14. Thorpe AP, Murray AD, Smith FW, Ferguson J. Clinically suspected scaphoid fracture: a comparison of magnetic resonance imaging and bone scintigraphy. *Br J Radiol* 1996;69:109-113.
15. Yin Z, Zang J, Kan S, Wang P. Treatment of acute scaphoid fractures–Systematic review and meta-analysis. *Clin Orthop Relat Res* 2007 E-Pub ahead of print Feb 15.
16. Barton NJ. The late consequences of scaphoid fractures. *J Bone Joint Surg* (Br) 2004;86-B:626-630.
17. Perron A, Brady W, Keats T, Hersh R. Orthopedic pitfalls in the ED: Scaphoid fractures. *Am J Emerg Med* 2001;19:310–316.
18. Mudgal CS, Jones WA. Scapho-lunate diastasis: A component of fractures of the distal radius. *J Hand Surg* (British volume) 1990; 15B:503–505.
19. Garcia–Elias M, Geissler W. Carpal Instability. In: *Green's Operative Hand Surgery*. 5th ed. Philadelphia: Elsevier, Churchill, Livingstone; 2005: 535-604.
20. Retting A. Athletic Injuries of the wrist and hand. Part 1: Traumatic injuries of the wrist. *Am J Sports Med* 2003;31:1038–1048.
21. Jones WA. Beware the sprained wrist. The incidence and diagnosis of scapholunate instability. *J Bone Joint Surg* (Br.) 1988;70–B:293–297.
22. Culp R, Lemel M, Taras J. Complications of common carpal injuries. *Hand Clinics* 1994;10:139–155.
23. Herzberg JJ, et al. Perilunate dislocations and fracture dislocations: A multicenter study. *J Hand Surg* 1993;18A:768–779.
24. Halikis M, Taleisnik J. Soft-tissue injuries of the wrist. *Clin Sports Med* 1996;15:235–259.
25. Hocker K, Menschik A. Chip fractures of the triquetrum. Mechanism, classification and results. *J Hand Surg* (British and European Volume) 1994;19B:(5):584–588
26. Levy M, et al. Chip fractures of the os triquetrum. The mechanism of injury. *J Bone Joint Surg Br* 1979;61-B (3):355–357.
27. Lacey J, Hodge J. Pisiform and Hamulus fractures: Easily missed wrist fractures diagnosed on a reverse oblique radiograph. *J Emerg Med* 1998;16: 445–452.
28. Muniz A. Unusual wrist pain. Pisiform fracture and dislocation. *Am J Emerg Med* 1999;17:78-79.
29. Amadio P, Moran S. Fractures of the carpal bones. In: *Green's Operative Hand Surgery.* 5th ed. Philadelphia: Elsevier, Churchill- Livingstone; 2005; 711-768.
30. Mabee J, Pritchard B. An unusual transcapitate fracture of the wrist. *Am J Emerg Med* 1997;15:584–586.
31. De Schrijver F, De Smet L. Isolated fracture of the capitate: the value of MRI in diagnosis and follow-up. *Acta Orthoped Belgica* 2002;68:311-315.
32. Yoshihara M, et al. Nonunion of the isolated capitate waist fracture. *J Orthop Sci* 2002;7:578–580.
33. Yaghoubian R, et al. Diagnosis and management of acute fracture dislocation of the carpus. *Ortho Clinics NA* 2001;32:295-305.
34. Hirano K, Inoue G. Classification and treatment of hamate fractures. *Hand Surgery* 2005;10:151–157.
35. Failla J, Amadia P. Recognition and treatment of uncommon carpal fractures. *Hand Clinics* 1988;4:469–476.
36. Laing A, Tansey C, O'Sullivan M. Trapezoid and Scaphotrapezial dislocation. *J Trauma* 2004;56:713–715.
37. Rogers L, Hendrix R. The Hand. In: *Radiology of Skeletal Trauma*. 2nd ed. New York: Churchill Livingstone; 1992: 939-989.
38. Simon R, Sherman S, Koenigsknecht S. Hand. In: *Emergency Orthopedics—The Extremities*. New York: McGraw Hill; 2007:123-183.
39. Peterson J, Bancroft L. Injuries of the fingers and thumb in the athlete. *Clin Sports Med* 2006;25:527–542.
40. Stern P. Fractures of the metacarpals and phalanges. In: *Green's Operative Hand Surgery*. 5th ed. Philadelphia: Elsevier, Churchill-Livingstone; 2005; 277-341.
41. Ali A, Hamman J, Mass D. The biomechanical effects of angulated boxers fractures. *J Hand Surg* 1999;24A:835–844.
42. Muller M, Poolman R, van Hoogsrtaten MJ, Steller E. Immediate mobilization gives good results in boxer's fractures with volar angulation up to 70 degrees: a prospective randomized trial comparing immediate mobilization with cast immobilization. *Arch Orthop Trauma Surg* 2003;123:534–537.
43. Antosia R, Lyn E. Hand. In: *Emergency Medicine: Concepts and Clinical Practice*. 2004. Mosby. 493–534.
44. Muelleman RL, Wadman M. Injuries to the hand and digits. In: Tintanalli J, ed. *Emergency Medicine: A Comprehensive Study Guide*. McGraw–Hill. 2004: 1665–1674.
45. Seiler J. [editor]. Fractures and dislocations of the metacarpals and phalanges. In: *Essentials of Hand Surgery*. Philadelphia: Lippincott, Williams and Wilkins: 99–113.
46. Bansal R, Craigen M. Rotational alignment of the fingernails in a normal population. *J Hand Surg* (European volume) 2007;32E:80–84.
47. Hinke D, et al. Ulnar collateral ligament of the thumb: MR findings in cadavers, volunteers, and patients with ligamentous injury (gamekeeper's thumb). *AJR Am J Roentgenol* 1994;163:1431–1434.
48. Schnur D, et al. Ultrasound: a powerful tool in the diagnosis of ulnar collateral ligament injuries of the thumb. *Ann Plastic Surg* 2002;49:19–23.
49. Richard R. Gamekeeper's thumb: Ulnar collateral ligament injury. *Am Fam Physician* 1996;53:1775–1781.
50. Lee S, Montgomery K. Athletic hand injuries. *Orthop Clin N Am* 2002;33: 547–554.

51. Leggit J, Meko C. Acute finger injuries: Part 2: Fractures, dislocations, and thumb injuries. *Am Fam Physician* 2006;73:827–834,839.
52. Proust A. Joint Injuries. In: *Emergency and Primary Care of the Hand*. Dallas, TX: American College of Emergency Physicians; 2001: 123–138.
53. Chaffin T. Phalangeal fractures. In: *Emergency and Primary Care of the Hand*. Dallas, TX: American College of Emergency Physicians; 2001: 111-122.
54. Hardy M. Principles of metacarpal and phalangeal fracture management: a review of rehabilitation concepts. *J Orthop Sports Phys Ther* 2004;34: 781–799.
55. Seno N, et al. Fractures of the base of the middle phalanx of the finger. Classification, management and long-term results. *J Bone Joint Surg* (Br) 1997; 79-B:758–763.
56. Roser S, Gellman H. Comparison of nail bed repair versus nail trephination for subungual hematomas in children. *J Hand Surg* 1999;24A:1166–1170.
57. Seaberg D, Angelos W, Paris P. Treatment of subungual hematomas with nail trephination: A prospective study. *Am J Emerg Med* 1991;9:209–210.
58. de Alwis W. Fingertip Injuries. *Emerg Med Australia* 2006;18:229–237.
59. Bendre A, Hartigan B, Kalainov D. Mallet finger. *J Am Acad Orthop Surg* 2005;13:336–344.
60. Lubahan J, Hood J. Fractures of the distal interphalangeal joint. *Clin Orthop Rel Res* 1996;327:12-20.
61. Kalainov D, et al. Nonsurgical treatment of closed mallet finger fractures. *J Hand Surg* 2005;30A:580–586.
62. Schneider L. Fractures of the distal phalanx. *Hand Clinics* 2004;4;537–547.
63. Glickel S, Baron A, Catalano L. Dislocations and ligament injuries in the digits. In: *Green's Operative Hand Surgery*. 5th ed. Philadelphia: Elsevier, Churchill-Livingstone; 2005;343–388.
64. Fisher M, Rogers L, Hendrix R. Systematic approach to identifying fourth and fifth carpometacarpal joint dislocations. *AJR* 1983;140:319–324.
65. Jebson P, Engber W, Lange R. Dislocation and fracture-dislocation of the carpometacarpal joints. *Orthop Review* 1994; Suppl:19-28.
66. Arnis F, et al Management of proximal interphalangeal joint injuries. *J Trauma* 1999;46:523–528.
67. Peimer C, Sullivan D, Wild D. Palmar dislocation of the proximal interphalangeal joint. *J Hand Surg* 1984; 9A:39-48.
68. Hong E. Hand injuries in sports medicine. *Prim Care Clin Office Pract* 2005;32:91-103.
69. Wang Q, Johnson B. Fingertip Injuries. *Am Fam Physician* 2001; 63:1961–1966.
70. Perron A, et al. Orthopedic pitfalls in the emergency department: Closed tendon injuries of the hand. *Am J Emerg Med* 2001;19:76–80.
71. Coons M, Green S. Boutonnière deformity. *Hand Clinics* 1995;11:387–402.
72. Elson RA. Rupture of the central slip of the extensor hood of the finger. *J Bone Joint Surg* (Br) 1986;68:229-231.
73. Froehlich J, Akelman E, Herndoin J. Extensor tendon injuries at the proximal interphalangeal joint. *Hand Clin* 1988;4:25–36.
74. Wolford R, White J. Extensor tendon injuries. In: *Emergency and Primary Care of the Hand*. Dallas, TX: American College of Emergency Physicians; 2001:175–190.
75. Newport ML. Extensor tendon injuries in the hand. *J Am Acad Orthop Surg* 1997;5:59–66.
76. Steinberg D. Acute flexor tendon injuries. *Orthop Clinics NA* 1992;23: 125–140.
77. Lilly S, Messer T. Complications after treatment of flexor tendon injuries. *J Am Acad Orthop Surg* 2006;14:387–396.
78. Naidu S, Heppenstall RB. Compartment syndrome of the forearm and hand. *Hand Clinics* 1994;10:13–27.
79. Ouellete E, Kelly R. Compartment syndromes of the hand. *J Bone Joint Surg* (Am) 1996;78-A:1515–1522.
80. Del Pinal F, et al. Acute hand compartment syndromes after closed crush: a reappraisal. *Plast Reconstr Surg* 2002;110:1232–1239.
81. Compartment Syndrome. In: *Essentials of Hand Surgery*. Philadelphia: Lippincott Williams and Wilkins; 2002:163-166.
82. Gulgonen A. Compartment Syndrome. In: *Green's Operative Hand Surgery*. 5th ed. Philadelphia: Elsevier, Churchill-Livingstone; 2005; 1985–2006.
83. Frankel N, Villarin CA. Compartment Syndromes. In: *Clinical Procedures in Emergency Medicine*. Elsevier; 2004: 1058–1072.
84. Martin C, Gonzalez del Pino J. Controversies in the treatment of fingertip amputations. Conservative versus surgical reconstruction. *Clin Orthop Rel Res* 1998;353:65–73.
85. Jackson E. The V-Y plasty in the treatment of fingertip amputations. *Am Fam Physician* 2001;64:455–458.
86. Chang J, Vernadakis A, McClellan WT. Fingertip injuries. *Clin Occup Environ Med* 2006;5:413–422.
87. Alfred B. Amputations. In: *Emergency and Primary Care of the Hand*. Dallas, TX: American College of Emergency Physicians; 2001: 211–218.
88. Dec W. A meta-analysis of success rates for digital replantation. *Tech Hand Up Extrem Surg* 2006;10:124–129.
89. Seiler J, [Editor]. Amputations. In: *Essentials of Hand Surgery*. Philadelphia: Lippincott Williams and Wilkins: 2002:216–219.

## Physician CME Questions

41. Which of the following carpal bones is most often fractured?
    A. Triquetrum
    B. Lunate
    C. Scaphoid
    D. Pisiform

42. Most patients with snuffbox tenderness and negative plain films:
    A. do not actually have a scaphoid fracture.
    B. will eventually develop avascular necrosis.
    C. will have a fracture diagnosed on CT or MRI.
    D. will develop a positive plain film by 10 days.

43. Scapholunate dissociation may result in:
    A. a spilled tea-cup sign.
    B. carpal instability.
    C. Kienboch's avascular necrosis.
    D. a Stenner lesion.

44. Upon striking out, a batter slams his bat down against the ground. The patient presents hours later with pain, swelling, and tenderness in the proximal hypothenar eminence Which of the following is likely to be rapidly helpful in the emergency department in making a diagnosis?
    A. MRI
    B. Carpal tunnel view
    C. Brewerton or skyline view
    D. Stress views

45. Which of the following is unacceptable?
    A. A fracture of the fifth metacarpal neck with 25 degrees of volar angulation
    B. A second metacarpal neck fracture with 10 degrees of volar angulation
    C. A mid-shaft proximal phalangeal fracture with a mild rotational deformity
    D. Closed management of intra-articular fractures

46. Which of the following is true of volar PIP dislocations?
    A. They are more common than dorsal dislocations.
    B. They may result in a mallet deformity.
    C. The boutonnière deformity may present in a delayed manner.
    D. Splinting should be done with slight flexion at the PIP joint.

47. A patient sustains trauma to the DIP joint during a basketball game when he "got jammed" by the ball. A mallet deformity is present. Which of the following is true?
    A. The injury will likely require surgery if associated with a large intra-articular fracture.
    B. A boutonnière deformity is likely to develop as well.
    C. Associated subungual hematomas are common.
    D. Splints should be removed after about a week and active motion of the joint encouraged.

48. Which of the following is true regarding gamekeeper's thumb injury?
    A. It is the result of hyperextension of the thumb injuring the radial collateral ligament.
    B. Tenderness is found on the ulnar aspect of the thumb IP joint.
    C. Stenner lesions will require surgical intervention.
    D. Rupture of the collateral ligament is protective for the volar plate.

49. The patient developing a compartment syndrome in the hand:
    A. loses pulses as an early manifestation of the problem.
    B. may have pain out of proportion to injury, even despite adequate dosing of analgesia, elevation, and splinting.
    C. will have reduced two-point discrimination.
    D. will show a high CPK.

50. Which of the following patients is most likely to be a candidate for digit replantation?
    A. A 74-year-old diabetic with a chain saw amputation of the index finger
    B. A person with an isolated amputation of the ring finger across the middle phalanx
    C. A 60-year-old smoker with a snow blower amputation of the small finger
    D. A healthy person with a clean thumb amputation

## CME Answer Key

41. C; 42. A; 43. B; 44. B; 45. C; 46. C; 47. A; 48. C; 49. B; 50. D

## *Emergency Medicine Reports*
## CME Objectives

*To help physicians:*

- quickly recognize or increase index of suspicion for specific conditions;
- understand the epidemiology, etiology, pathophysiology, and clinical features of the entity discussed;
- apply state-of-the-art diagnostic and therapeutic techniques (including the implications of pharmaceutical therapy discussed) to patients with the particular medical problems discussed;
- understand the differential diagnosis of the entity discussed;
- understand both likely and rare complications that may occur.

## CME Instructions

Physicians participate in this continuing medical education program by reading the article, using the provided references for further research, and studying the questions at the end of the article. Participants should select what they believe to be the correct answers, then refer to the list of correct answers to evaluate their knowledge. To clarify confusion surrounding any questions answered incorrectly, please consult the source material. *After completing this activity, you must complete the evaluation form that will be provided at the end of the semester and return it in the reply envelope provided to receive a certificate of completion.* When your evaluation is received, a certificate will be mailed to you.

Emergency Medicine Reports®
The Practical Journal for Emergency Physicians

# Traumatic Injuries of the Hand and Wrist

## Scaphoid Fracture

The scaphoid fat pad has been obliterated.

## The Terry Thomas Sign

The scapholunate space is markedly abnormal in this patient. Additionally, a signet ring sign is present owing to rotary subluxation.

## DISI and VISI Illustrated

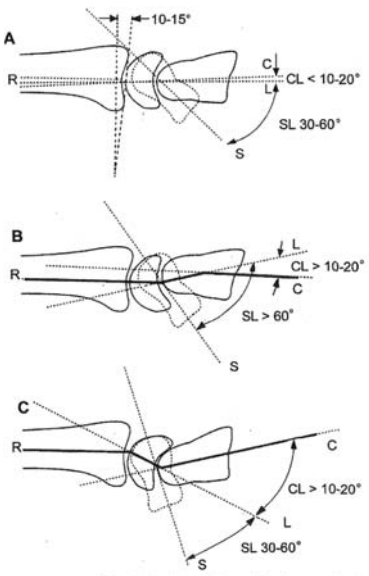


**A.** Normal wrist. (1) Axis of the radius, lunate, and capitate are collinear (three C's sign). (2) The capitolunate (CL) angle is less than 10 to 20 degrees. (3) The scapholunate (SL) angle is between 30 and 60 degrees. (4) The radial volar tilt is 10 to 15 degrees. **B.** Dorsal intercalated segment instability (DISI). The lunate tilts dorsal and slides palmar, increasing the capitolunate angle. The scaphoid tilts more palmar and increases the scapholunate angle. The axes of the radius, lunate, and capitate take on a zigzag pattern (dark line). **C.** Volar intercalated segment instability (VISI). The lunate tilts palmar and the capitolunate angle increases, but the scapholunate angle is maintained. The zigzag pattern is in the opposite direction.

Used with permission from Uehara D, Wolanyk D, Escarza R. Wrist Injuries. In: Tintinalli J, ed. *Emergency Medicine: A Comprehensive Study Guide*. 6th ed. 2004. McGraw Hill & Co.:1676.

## Lunate Dislocation

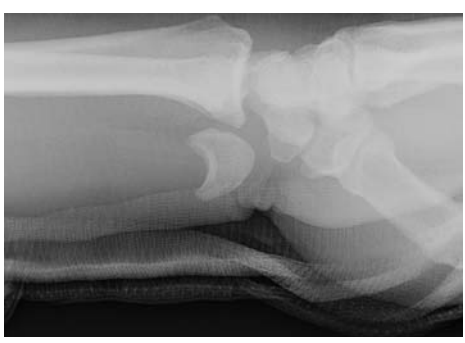

The lunate has dislocated from its radial articulation and the capitate now abuts the distal radius.

## Pseudoclawing Deformity

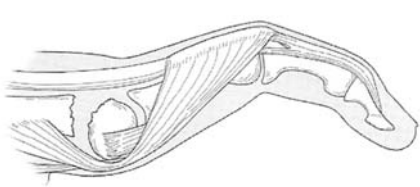

A metacarpal neck fracture that is not properly reduced will develop a compensatory MCP joint hyperextension and PIP joint flexion known as pseudoclawing.

Used with permission from Simon R, Sherman S, Koenigsknecht S. Hand. *Emergency Orthopedics—The Extremities*. 2007. McGraw Hill & Co. p. 146.

## Perilunate Dislocation

The articulation of the radius and lunate is preserved. The capitate is dorsally dislocated.

## A Bennett Fracture

There is an intra-articular fracture of the first metacarpal base with joint subluxation.

## A Boxer's Fracture

## Stener Lesion

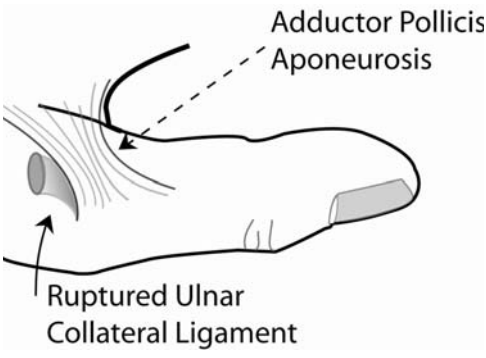


The ruptured proximal ulnar collateral ligament fails to reduce properly and remains superficial to the adductor pollicis aponeurosis. Illustration by Jennifer Rolfsema.

## Boutonnière Deformity

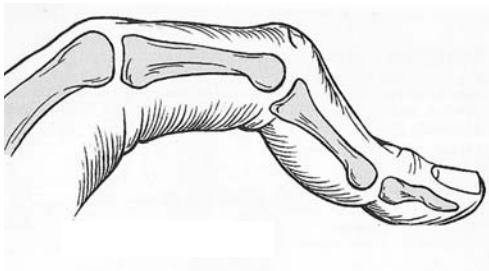

Reprinted with permission from: Muelleman RL, Wadman M. Injuries to the hand and digits. In: Tintinalli J, ed. *Emergency Medicine: A Comprehensive Study Guide*. 6th ed. 2004. McGraw Hill. p 1672.

## Mallet Deformity

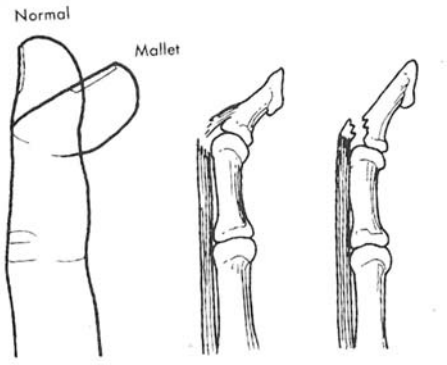


Reprinted with permission from: Antosia, R, Lynn E. The Hand. In: *Emergency Medicine. Concepts and Clinical Practice*. 4th ed. p. 655. 1998. Elsevier.

## Swan Neck Deformity

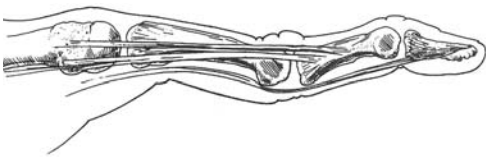

Reprinted with permission from: Simon R, Sherman S, Koenigsknecht S. Hand. In: *Emergency Orthopedics—The Extremities*. 2007. McGraw Hill & Co. p. 131.

Supplement to *Emergency Medicine Reports*, August 20, 2007.: "Traumatic Injuries of the Hand and Wrist. Part II." *Author:* **Thomas Germano, MD, FACEP**, Assistant Clinical Professor, Brown University Medical School, Attending Physician, Rhode Island Hospital, Providence, RI.