AHC Media LLC

Rapid Access Card Enclosed

Enclosed in this issue: Trauma Reports

PEDIATRIC Emergency Medicine Reports

The Practical Journal of Pediatric Emergency Medicine

Volume 12, Number 9 September 2007

Physical Abuse of Children: Identification, Evaluation, and Management in the Emergency Department Setting

Authors: **N. Ewen Wang, MD,** Assistant Professor of Surgery, Associate Director of Pediatric Emergency Medicine, Stanford University Hospital, Stanford, CA; and **Bronwyn Baz, MD,** Lucile Packard Children's Hospital, Stanford University Medical Center, Palo Alto, CA.

Peer reviewer: **Kristen Bechtel, MD,** Associate Professor of Pediatrics, Yale University School of Medicine, New Haven, CT.

Approximately one in five of children evaluated in EDs are physically abused, emergency physicians (EPs) have a responsibility to consider abuse in the differential of every injured child.[1] Although there is increasing awareness of the emergency physician's role in diagnosing abuse, EPs still frequently fail to diagnose child abuse.[1] This article reviews the identification, evaluation, and management of a child with possible physical abuse.

— *The Editor*

Background

Physical abuse has a number of manifestations, but is most simply defined as injury inflicted upon a child by a caregiver. Recognition of child abuse in the ED setting is essential for both timely treatment and prevention of further injury. The identification of child abuse requires the completion of a thorough medical and social evaluation, and should be followed by the notification of child protective services. This sensitive and often difficult situation presents a unique challenge for both the medical staff and the family, and requires thoughtful coordination and cooperation between such disciplines as ED personnel, social workers, child protective services, law enforcement personnel, and inpatient hospital staff if the child's injury is serious enough to warrant hospital admission.

This article focuses on the evaluation of physically injured children presenting to the ED. As physically abused children commonly present to an ED for treatment, emergency medicine practitioners must keep in mind that child abuse may be the cause of a child's injury, as this may be the first significant intervention to prevent future abusive injury.

Epidemiology

The incidence of child abuse in the United States is difficult to ascertain, but is believed to be much higher than reported. The

Statement of Financial Disclosure

In order to reveal any potential bias in this publication, and in accordance with Accreditation Council for Continuing Medical Education guidelines, we disclose that Dr. Dietrich, editor-in-chief, Dr. Skrainka (CME question reviewer), Drs. Wang (author), Baz (author), and Bechtel (peer reviewer) report no consultant, stockholder, speaker's bureau, research, or other financial relationships with companies having ties to this field of study.

National Incidence Study of Child Abuse and Neglect reports that maltreated children who are investigated by Child Protective Services (CPS) represent only the "tip of the iceberg."[2] Moreover, the findings of the Third National Incidence Study of Child Abuse and Neglect (NIS-3) show a substantial and significant increase in the incidence of children who are seriously harmed; this most likely indicates an increase in abuse incidence, rather than an increase in reporting.[2] Child abuse is believed to be the etiology of 10% of traumatic injuries in children younger than age 5.[3] Approximately 1,300 children die each year from inflicted injuries,[4,5] and nearly 45% of those children are younger than age 1.[4,6]

In 2003, approximately 2.9 million reports involving 5.5 million children were made to CPS agencies; of these, nearly 70% were categorized as needing further investigation. Approximately 906,000 children were found to have been abused and/or neglected; of these substantiated cases, 25% were due to physical abuse. The range of injuries, in order of frequency of occurrence, includes: bruises, skeletal fractures, CNS (central nervous system) injuries, and burns.[2,7,8]

Although reports of suspected abuse are more often made for minority than Caucasian children, race has not been found to be a significant factor in substantiated cases of abuse, according to NIS-2 and NIS-3 data.[4,6,9] Though gender also is not a statistically significant factor in substantiated cases of abuse, boys are more likely to incur serious injury.[2,7,10] Finally, according to data from the U.S. Department of Health and Human Services/Administration for Children and Families in 2004, the most largely victimized age group is the youngest (less than one year of age), with a rate of 16.1 per 1,000 children of the same age group. The oldest children (ages 12-17 years) were victimized the least frequently.[11]

The abused child is at risk for both the physical and the psychological ramifications that occur as a result of battering. It is estimated that 37% of children with maltreatment injuries develop future special medical needs, most often from disability, and particularly from CNS injuries and thermal burns. The incidence of disability caused by maltreatment is estimated to be 147 per 100,000 children.[7,10] Moreover, according to U.S. Department of Health and Human Service data, an estimated 1,490 children died in 2004 (compared to 1,460 children for 2003) from abuse or neglect, at a rate of 2.03 deaths per 100,000 children. Of note, 81% of those fatalities were in abused children younger than age 4. Most fatalities were associated with neglect only (35.5%), combinations of maltreatment types (30.2%), and physical abuse only (28.3%).[11]

Another unfortunate consequence of battering is the risk that the child himself will grow up to become a perpetrator, acting out the violence that was once modeled to him as normal problem-solving behavior.[4] These children also have a higher risk of developing psychological sequelae, including psychiatric disorders such as depression, suicidal impulses, and post-traumatic stress disorder (PTSD), as well as risk-taking behaviors such as an earlier age of sexual activity and drug and alcohol use.[12]

Scope of the Problem: Risks for Abuse

Factors that put children at risk for physical abuse involve characteristics of both the perpetrator and the child, and are commonly exacerbated by social and environmental stressors. Perpetrators, in order of frequency, are most commonly fathers, mothers' boyfriends, babysitters (female), and mothers.[13,14] Risk factors for the perpetrator include history of abuse or neglect as a child, lower level of education, young or single parenthood, and unstable social situations.[15] A caretaker also may be more likely to perpetrate abuse when suffering from a psychiatric illness, when under the influence of drugs or alcohol, or when inexperienced and unprepared for parenthood.[4,12,15,16]

Innate factors that put the child at greater risk for abuse include young age (67% of abused children are younger than age 1 and 80% are younger than age 3), chronic illness and disability, speech and language disorders, learning disability, conduct disorders (e.g., hyperactivity), and psychological illness.[4,17] Although the data is controversial, it is thought that medical conditions such as prematurity and low birth weight also may be independent risk factors of abuse later in life.[18,19] Most importantly, history of previous abuse is a significant risk factor for future abuse: a physically abused child has a 50% chance of suffering further abuse and a 10% chance of dying from the abuse if it is not identified and addressed at initial presentation.[1] Moreover, children whose mothers suffer from domestic violence are up to 15 times more likely to be abused. It has been recommend-

Pediatric Emergency Medicine Reports™ (ISSN 1082-3344) is published monthly by AHC Media LLC, 3525 Piedmont Road, N.E., Six Piedmont Center, Suite 400, Atlanta, GA 30305. Telephone: (800) 688-2421 or (404) 262-7436.

Vice President/Group Publisher: Brenda Mooney
Associate Publisher: Lee Landenberger
Senior Managing Editor: Suzanne Thatcher
Marketing Manager: Nan Webb
GST Registration No.: R128870672

Periodicals Postage Paid at Atlanta, GA 30304.

POSTMASTER: Send address changes to ***Pediatric Emergency Medicine Reports***, P.O. Box 740059, Atlanta, GA 30374.

Back issues: $65. Missing issues will be fulfilled by customer service free of charge when contacted within one month of the missing issue's date.

Accreditation

AHC Media LLC is accredited by the Accreditation Council for Continuing Medical Education to provide continuing medical education for physicians.

AHC Media LLC designates this educational activity for a maximum of 30 *AMA PRA Category 1 Credits™*. Physicians should only claim credit commensurate with the extent of their participation in the activity.

Approved by the American College of Emergency Physicians for 30 hours of ACEP Category 1 credit.

This continuing medical education activity has been reviewed by the American Academy of Pediatrics and is acceptable for up to 30 (2.5 per issue) AAP credits. These credits can be applied toward the AAP CME/CPD Award available to Fellows and Candidate Fellows of the American Academy of Pediatrics.

This CME activity is intended for emergency and pediatric physicians. It is in effect for 36 months from the date of the publication.

Subscriber Information

Customer Service: 1-800-688-2421
Customer Service E-Mail Address:
customerservice@ahcmedia.com
Editorial E-Mail Address: suzanne.thatcher@ahcmedia.com
World-Wide Web page: http://www.ahcmedia.com

Subscription Prices

1 year *with* 30 ACEP, AMA, or AAP Category 1 credits: $439;
1 year without credit: $389;
Add $9.95 for shipping & handling
Multiple copies:
Discounts available for group subscriptions. For pricing information, call Tria Kreutzer at (404) 262-5482.
One to nine additional copies: **$350 each;**
10 or more additional copies: **$311 each.**
Resident's Rate: **$194.50**
All prices U.S. only. U.S. possessions and Canada, add $30 postage plus applicable GST. Other international orders, add $30.

Questions & Comments

Please call **Suzanne Thatcher,** Senior Managing Editor, (404) 262-5514, or e-mail suzanne.thatcher@ahcmedia.com

AHC Media LLC

ed that screening and intervening on behalf of the battered parent may be an effective abuse prevention strategy.[20]

Environmental and social factors increasing a child's risk for abuse include acute and chronic problems such as financial and family stressors (divorce, separation, conflict), and illness, all of which may contribute to instability and violence in the home. Cultural factors may include social isolation, lack of support from extended family, and the modeling and acceptance of violence (such as corporal punishment and domestic violence) for resolving conflict.[4,16]

Types and Biomechanics of Injuries to Children

Abusive injuries to infants and children have unique characteristics due to their immature physiology, especially in regard to skeletal and CNS injuries. Orofacial injuries also are unique to children, and are found in up to one-half of physically abused children.[21]

Bruises. Bruises, including ecchymoses and hematomas, are the most commonly found injury in abusive trauma, accounting for up to 40% of injuries. Bruises result from direct blunt force to the skin with resulting rupture of capillaries and leakage of blood into subcutaneous tissue.[21,22] Discoloration may appear immediately, or hours to days after the injury is sustained.[23] As bruises heal, the discoloration progresses through a spectrum of colors as the hemoglobin from extravasated blood is broken down and removed.[10] Healing of bruises may take place over a period of one to three weeks, depending on factors that include the victim's gender, health, medications (aspirin, ibuprofen) he/she may be taking, skin tone, and environmental factors. All of these factors may alter the resolution and color sequence of bruises.[24]

Although bruises at different stages of healing have been described as characteristic of abusive injury, caution should be used when attempting to determine the age of bruises because of a wide variability in bruise development.[25] A study by Langlois and Gresham attempted the first analysis of how accurately the age of a bruise can be determined by its color. Data on color and age were analyzed in 89 photographs of bruises. Their conclusions suggested that the development of bruise color is variable, and although yellow is the color of a relatively older bruise, it may appear much earlier than forensic charts suggest.[26]

Although the age of a bruise cannot be accurately determined from its color, observations of location, size, and color of the bruise can be valuable in distinguishing between accidental and abusive trauma.[26] For this reason, it is reasonable for a clinician to estimate a range of time (days to weeks) rather than specific dates as to when the bruise developed, based on its clinical appearance. The estimated age of a bruise should never be the sole criteria for a diagnosis of child abuse, but rather one component of a comprehensive assessment.[25]

Distinguishing between normal traumatic bruises and inflicted injuries in children can be difficult, but recognizable geometric shapes from implements such as belts, whips, and hand prints are suggestive of abusive injury. Additionally, location and approximate ages of bruises can be helpful for determining if a bruise is due to abuse.[27] Accidental bruising most often occurs over bony prominences, such as joints (elbows, knees) or pretibial areas, the forehead, and the front of the body, as a result of play. Bruising to the back of the body, inner arms or thighs, trunk, genitalia, cheeks, ears, eyes, and neck are more suggestive of abusive injury.[28,29] Other important clues include bruising in non-ambulatory babies, which is rare in accidental trauma;[30] multiple and/or clustered bruises, especially bruises of different ages and healing stages, suggesting repeated inflicted injuries; and specific bruising patterns, as mentioned above.[10,29] *(See Figure 1.)*[31]

Finally, the features of bruises that are suggestive of child abuse are listed in Table 1 (also *see Figure 2)*.

Bite Marks. Bite marks are associated with both physical and sexual abuse of children.[4,33,34] They can appear as circular, elliptical, or arrow-shaped bruises or abrasions, and may have central clearing or associated erythema and petechiae. Human and animal bite marks may be differentiated by their depth. Human bites tend to be more superficial, do not always leave individual tooth marks, and lack the tearing and deep punctures of animal bites.[34] Further, adult bite marks may be differentiated from a child's by the adult tooth pattern and by the maxillary intercanine distance, which is at least 2.5-3 cm.[33,34]

Forensic investigation is an important component of bite evaluation and documentation. The pattern, size, contour, and color of a bite mark can be evaluated by a forensic odontologist or pathologist.[33] If neither is available, a physician or dentist who is knowledgeable in patterns of child abuse injuries can evaluate the bite-mark characteristics. Contact information for American Board of Forensic Odontology (ABFO)-certified odontologists can be obtained from the ABFO web site (www.abfo.org).

Blood-group substances and DNA (in epithelial cells) can be secreted in saliva and may be deposited in bites. Even if they have dried, they can be collected using the double-swab technique: 1) a sterile cotton swab moistened with distilled water is used to wipe the area in question, dried, and then placed in a specimen tube; 2) a second sterile, dry cotton swab is used to clean the same area and then is dried and placed in a specimen tube; 3) a third control sample should be obtained from an uninvolved area of the child's skin. (All samples should be sent to a certified forensic laboratory for prompt analysis. The chain of custody must be maintained on all samples submitted for forensic analysis.)[33]

Thorough documentation in the patient's chart of any suspicious bruise or bite mark is recommended, using written description, drawings, and careful photographic evidence with a color wheel and ruler.[26]

Fractures. Fractures are the second most common injury in physical abuse, and are detected in 30-55% of abused children.[29] Understanding the unique physiology of children's' skeletal injuries is crucial for correctly differentiating between injuries incurred from normal childhood trauma and those from abusive trauma in the emergency setting. A child's skeleton is more porous than an adult's, and is more prone to compression injuries that may result in green stick and buckle fractures. Further, the periosteum is more prone to separation from the bone in a child,

Figure 1. Abusive Bruises

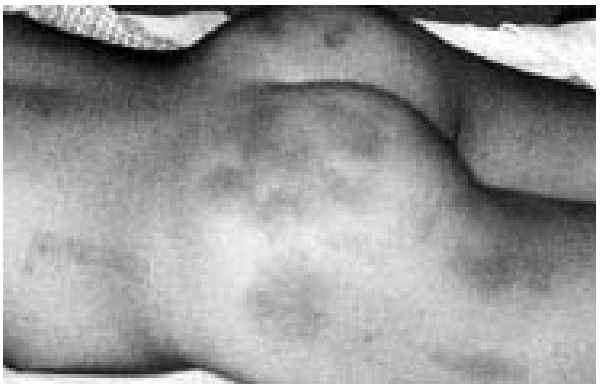

Photo used with permission from David M. Pressel, MD, PhD.

but their joint capsules and ligaments are known to be more resistant to mechanical stressors than bone and cartilage, making joint dislocations less likely in childhood. Finally, bone healing is more rapid in children than in adults.[10,36]

Dating of skeletal injuries is particularly important in the evaluation of physical abuse, as it may assist investigators in determining who had access to the child during the period of time that the skeletal injury is thought to have occurred. In general, fractures of long bones and ribs heal in relatively predictable stages: initial healing, soft callus, hard callus, and remodeling.[10,37] The timing of metaphyseal fractures are more difficult because of the relative lack of disruption in the periosteum at the time of the fracture. Skull fractures heal differently than long bones and ribs, making the dating of injury more difficult.[10]

Skeletal injuries that are suspicious for abusive trauma include diaphyseal fractures, which are the most commonly found fracture in abuse and often result from transverse forces applied perpendicularly to the long axis of the bone. Spiral fractures from rotational forces, such as twisting or torquing of the extremity, especially in non-ambulatory children, are considered by some to be pathognomonic for abuse.[38]

Metaphyseal fractures also are considered to be pathognomonic for abuse. These fractures are subtle findings on radiographs, often appearing as chips or fractures from the corner of the bone known as "bucket handle" fractures.[31] *(See Figure 3.)* This type of fracture is particularly important to detect, as injury to the metaphyseal plate may limit future growth if not adequately treated in a timely manner.[10]

Rib fractures account for up to 27% of all abusive skeletal injuries,[37] and occur as a result of direct blows as well as anteroposterior compression of the chest wall, such as occurs when holding and shaking an infant. Most abusive rib fractures are posterior and adjacent to the vertebral body, due to the levering of forces over the transverse process of the vertebra.[31] *(See Figure 4.)* To diagnose these difficult-to-detect fractures, skeletal surveys are recommended in children younger than age 2 in whom abuse is suspected. Radionuclide bone scanning also may detect new rib fractures and subtle long bone fractures not evident on skeletal survey.[1]

Table 1. Features of Bruises Suggestive of Abuse[10,32]

- The pattern of injuries corresponds to infliction with an instrument not found in play or the child's usual environment, such as linear bruises and petechiae on the buttocks and gluteal cleft from hitting, spanking, whipping, or paddling
- Linear bruising and/or petechiae of the pinna from blows to the skull ("tin ear syndrome" is comprised of bruising to the pinna, retinal bleeding, and acute traumatic head injury)
- Hand prints or oval marks on cheeks, neck, upper arms, trunk, or buttocks (from being punched, slapped, grabbed, shaken, or pinched)
- Belt marks (leaving long bands of ecchymosis, sometimes with a u-shape at the end or puncture wounds from the buckle)
- Loop marks from beating with a rope, wire, or electric cord (electric cords leave a characteristic "double-track mark")
- Ligature marks or circumferential rope burns seen on the neck, wrists, ankles, and gag marks at corners of the mouth
- Any history of injury inconsistent with the child's level of development or with the category and extent of the injury should raise suspicion for abusive trauma

A study reviewing the value of repeat skeletal surveys within two weeks after the original survey found that follow-up skeletal survey identified additional fractures or clarified tentative findings in children who were suspected victims of physical abuse.[39] The authors concluded that follow-up skeletal survey should be completed on all patients who have an initial skeletal survey performed for suspected physical child abuse and for whom child abuse is still a concern.[39]

Central Nervous System (CNS) Trauma

The EP frequently is required to differentiate between accidental household falls and abusive trauma as the cause of head injuries in infants and toddlers. The ability to distinguish between

Figure 2. Loop Marks

Photo used with permission from David M. Pressel, MD, PhD.

Figure 3. Metaphyseal Bucket Handle Fracture

Photo used with permission from David M. Pressel, MD, PhD.

Figure 4. Posterior Rib Fractures

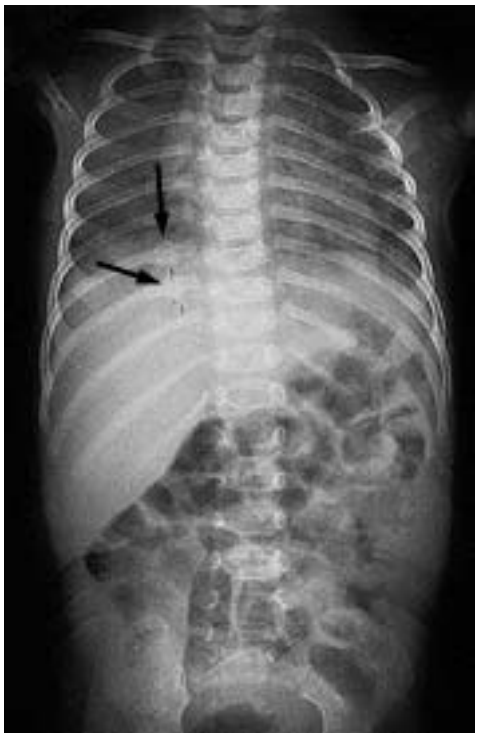

Photo used with permission from David M. Pressel, MD, PhD.

accidental and abusive head injury may be facilitated by an understanding of the biomechanics of brain injury. Sudden angular deceleration of the brain and cerebral vessels from violent shaking results in diffuse brain injury, such as subdural hemorrhage, which is a hallmark of inflicted craniocerebral trauma ("shaken-baby syndrome"), rather than specific contact forces applied to the surface of the head as seen in household falls.[13] Thus, this angular type of force is distinctly different from those generated in most cases of accidental traumas (household falls) in young children, which involve low-velocity translational forces.[13]

CNS trauma is found in up to one-quarter of abused children, and represents the most serious form of injury in physical abuse.[13]

Abusive head trauma is the most common cause of morbidity and mortality in physically abused infants;[13,14] in one case review study, 23% of children with inflicted head injuries died.[14] Further, the authors found that male victims accounted for 60.3% of the cases, although death rates for boys and girls did not vary significantly. They also noted that male caretakers and babysitters are at greater risk for abusing infants.[14]

Sequelae include intracranial hemorrhage (subdural and subarachnoid), as well as contusions and intraparenchymal bleeding. The classic presentation linking CNS trauma and abuse is "shaken baby syndrome," with the findings of subdural hematoma; retinal hemorrhages (65-95% of cases); and skeletal fractures, including metaphyseal and posterior rib fractures (30-70% of cases) caused when the child is shaken violently back and forth.[10] Significantly, although retinal hemorrhages, rib fractures, and subdural hemorrhage are the classic triad associated with head trauma, it should be emphasized that a minority of patients will have all three findings. Clinical deterioration from an acute SDH (subdural hematoma) occurs at the time of injury without a "lucid interval;" rapid onset of morbidity and mortality from traumatic brain injury in a previously healthy child is particularly suspicious for abusive trauma.[10]

Abusive head injury may present with a wide spectrum of symptoms and clinical findings.[33] Subsequently, children who have more mild forms of head trauma and less ominous symptoms, such as vomiting and irritability, may not be recognized until they present later with a more serious injury.[40] Thus, the EP's timely diagnosis of abusive head trauma is essential for preventing a child from suffering further brain injury and potentially more severe sequelae.

An analysis of missed cases of abusive head trauma (AHT) found that 31.2% of abused children with head injuries had been seen by health care personnel who had not recognized the AHT.[41] The average time to correct diagnosis for these children was seven days, and AHT was more likely to be unrecognized in very young Caucasian children from intact families and in patients without respiratory distress or seizures. Significantly, 27.8% were re-injured after the missed diagnosis, and 40.7% suffered medical complications related to the missed diagnosis. The misinterpretation of radiological studies contributed to delay in diagnosis of seven of the children with unrecognized AHT, and five deaths in the group with unrecognized AHT might have been prevented by earlier recognition of abuse.[41]

Consequently, it is crucial for EP's to consider inflicted head trauma in infants and young children presenting with nonspecific

clinical signs. Unfortunately, the diagnosis of AHT often is challenging for even the experienced EP, as caregivers rarely provide a history of trauma. A study by Duhaime and Partington, however, found that children presented with nonspecific symptoms such as vomiting or fussiness in 57% (8 of 14) of the patients with AHT. This suggests that these infants may be the ones at highest risk for missed head trauma.[42] Thus, infants presenting with the symptoms noted above deserve careful consideration and screening for AHT.

In addition to the above symptoms, retinal hemorrhage may serve as a useful sign in the EP's diagnosis of AHT. Retinal hemorrhages are seen more often in abusive head injury, are often bilateral, and tend to involve the pre-retinal layer.[43] Further, they found that children with abusive head injury were more likely to have retinal hemorrhages covering the macula and extending to the periphery of the retina.[31] *(See Figure 5.)* Importantly, unilateral retinal hemorrhages can be seen in children with accidental head injury. Other distinguishing characteristics between abusive and accidental head injury in children younger than age 2 included abnormal mental status and seizures in abused children, whereas scalp hematomas were more likely in children with accidental head injury.[43]

Burns

Burns, which are found in up to 20% of abused children, are frequently due to intentional injury.[22] Burns result from contact between heat energy and skin, and may be caused by liquids (causing scalding burns), chemicals, contact with hot and/or dry objects, flames (causing flash burns), and electricity. Three concentric zones of tissue damage are found in relation to the heat source: coagulation, stasis, and hyperemia. Skin closest to the heat source undergoes coagulation necrosis as cellular proteins denature; thus, no regeneration is possible. Stasis results from less direct heat exposure, and cellular repair may be possible. Hyperemia is the least direct injury to skin cells and has the greatest potential for repair.[10,44]

Specific burn patterns should raise suspicion for intentional injury, and include brands or contact burns (grill or grid patterns), cigarette burns, immersion burns[31] *(see Figure 6),* microwave oven burns, and stun gun burns. Patterned or brand burns from an intentional burn such as a cigarette, radiator grill, or curling iron are uniformly deep and leave clear outlines of the identifiable object on the skin, whereas unintentional burns are shallow and leave only part of an outline due to the withdrawal reflex.[4] Cigarette burns, for instance, usually leave a complete circle, 8-10 mm in diameter, often with an indurated margin, and are often painless due to deep, third-degree tissue damage. Microwave burns (inflicted by holding a child's extremity in an operating microwave) and stun gun burns cause partial to full-thickness burns; abusive stun-gun injuries are usually multiple, paired burns 0.5 cm in diameter and 5 cm apart.[4,45,46]

In detail, burn patterns consistent with abuse include: forced immersion burns resulting in sharp stocking and glove demarcations with sparing of flexural/protected areas such as antecubital or popliteal fossae and no splash or drip marks; bilateral or "mirror image" burns or localized burns to genitals, buttocks, and perineum not consistent with accidental trauma; and splash/spill-type burns attributed to a developmental level not consistent with the child's age and abilities. Finally, evidence of delay in seeking care for burns and presence of other injuries are highly suspicious, especially when the physical examination is incompatible with the provided history.[10,47]

Burns have been attributed to abuse, neglect, or unstable family factors in up to 8% of cases in pediatric burn units.[4,48] Social factors that are associated with abusive burns include children living in single-parent families and previous history of investigation for abuse. Medical factors associated with inflicted burns include increased requirement for intensive care or skin grafting and, most importantly, higher mortality rates. In two studies, mortality from abusive burns was found to be 5.6-9.6%, as opposed to 2.6-6% from accidental burns.[4,48]

Facial Injuries

Oral and facial injuries are common in physical abuse, occurring in up to one-half of cases.[21] Toddlers do frequently have injuries to the lips or maxillary frenulum due to accidental falls. However, these injuries in non-ambulatory children are suspicious for forced feeding, such as when the bottle is jammed forcefully into the child's mouth. Lip or frenulum injuries may also result from facial blows.[21]

Other types of orofacial injuries observed in abuse may include: facial fractures (e.g., the mandible or other facial bones); deviated septum or other damage to the nose from direct trauma or foreign body penetration; periorbital injuries ("raccoon eyes"); post-auricular ecchymosis or blood behind the tympanic membranes; bruising and scarring at the angles of the mouth, such as would occur when a gag is placed around the mouth; traumatic alopecia from hair pulling (patchy areas of missing hair without the scaling and inflammation seen in tinea capitis, occasionally associated with scalp bruising or subgaleal hematoma); and burns from forced

Figure 5. Retinal Hemorrhages

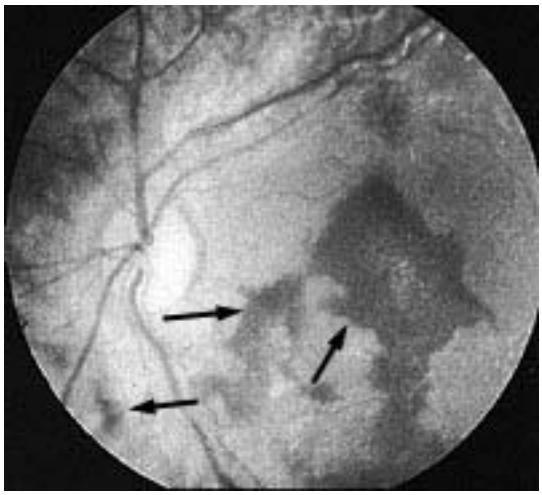

Photo used with permission from David M. Pressel, MD, PhD.

ingestion of scalding liquids or caustic materials, or dental fractures and tooth discoloration from repeated direct trauma.[4,33,49-51]

Forced Ingestion and Starvation

Forced ingestion may involve intentional poisoning of children with massive amounts of water, salt, pepper, or various drugs and overlaps with Munchausen syndrome by proxy.[4,52,53] Although not as commonly described,[54] the sequelae can be particularly grave. Excessive water ingestion may be used as a form of punishment, and presents with hyponatremic seizures, vomiting, coma, and/or death.[53] Signs of physical abuse also are often present and should be thoroughly assessed. Salt poisoning also overlaps with Munchausen syndrome by proxy and often presents as recurrent unexplained hypernatremia, with serum sodium levels greater than 200, in the first 6 months of life.[55] In this instance, urine sodium and chloride also may be elevated, and renal and endocrinological evaluations are normal.[4] Finally, starvation is a less common form of child abuse, but may have higher mortality rates; one case series reported up to 50% mortality.[56] Age appears to be a significant risk factor for death: the median age at which children suffer fatalities is 8 months, whereas children ages 8 or older usually survive their injuries. These children also may be at significantly greater risk for fatality from starvation due to their isolation from relatives and medical and school personnel.[56]

Evaluation for Abuse: History

The evaluation of the injured child requires a complete history of the circumstances and events leading up to the injury. Documentation should be meticulous and legible, as the EP might be called to court years from the actual examination.[10] Essential questions are similar to the usual information gathered in history-taking but require more specific data. *(See Table 2.)* Assessment of the developmental level of the child also is required in the determination of whether the story is compatible with the child's developmental abilities (for instance, a 2-month-old generally will not roll off the table and hit his head).

Figure 6. Immersion Burn

Photo used with permission from David M. Pressel, MD, PhD.

Classic red flags in the history for abusive trauma are listed in Table 3.

Clinical Evaluation: Physical Exam

Children with abusive injuries present with a wide spectrum of severity, from a child who is apneic and unresponsive due to abusive head trauma, to the child who is otherwise well appearing but who has multiple old fractures. For the child with acute severe trauma, the usual trauma evaluation should proceed, beginning with an assessment of the child's airway, breathing, and circulation. The physical examination should be comprehensive, looking for contemporaneous as well as prior injuries. Other physical signs consistent with physical abuse include multiple injuries and types of injuries, as well as injuries at different stages of healing, presence of pathognomonic injuries such as those seen in abusive head trauma (SDH, posterior rib fractures, and retinal hemorrhages), or patterned injuries such as cigarette burns or loop marks *(see Table 3)*.[10] Finally, evidence of malnourishment (weight less than third percentile) and neglect such as caries, poor hygiene, and lack of adequate clothing; and poor (harsh or aloof) interaction between caregiver and child are important clues for abuse.

Differential Diagnosis

The diagnosis of accidental versus abusive injuries is crucial for the child's proper medical and social management, and may be confounded by the presence of underlying medical conditions. Whereas the past medical history often will elucidate previously diagnosed conditions, the exploration of the differential diagnosis for physical abuse should be undertaken in those cases that are unclear or suggest an alternative etiology of injury. The workup should include laboratory data as is appropriate based on the child's presentation.[10] *(See Table 4.)* Often, the workup and consults will be completed once the child is admitted. Clinicians should always consider reasonable, alternative medical diagnoses before concluding that the child's injury is most likely from abuse.

Differential diagnoses for bruises are many, and most commonly include Mongolian or slate-gray spots. These are collections of melanocytes causing bluish discoloration in patches over the sacrum, back, and extremities present at birth in up to 80% of African-American children as well as in high percentages of Hispanic and Asian children.[57] Hemangiomas also are frequently found in infants, may be reddish to bluish in color, and may have deep as well as superficial components. They tend to be present at birth, evolve relatively rapidly over the first year of life, and then spontaneously regress. Several presentations that may be confused with abusive bruises as well, include: eczema, phytophotodermatitis (reddened areas and erosions from sun exposure), erythema multiforme (variable erythematous lesions from drug or sensitivity reactions), idiopathic thrombocytopenic purpura (ITP) and other bruising or petechiae from coagulopathy or malignancy, unusual genetic syndromes such as Ehlers-Danlos syndrome (loss of normal skin elasticity) or OI type I (discussed below in the skeletal injury differential), and folk healing prac-

Table 2. Documentation of Abuse

The medical record may be admitted as evidence in court.

- Accurate, detailed, legible records are essential (consider dictation).[10]

THE RECORD SHOULD INCLUDE:

❒ Date and time of injury
❒ When first noted
❒ Where the injury occurred
❒ Who was there and witnessed the injury
❒ What led up to the injury
❒ How the child and caretaker responded to the injury
❒ Lapse in time before seeking care for the injury?[10]

❒ **Child's interview and medical history (separate interview):**[1]
Child's name, medical record number, DOB

❒ **Caregiver statements (separate interview, optimally conducted by social work)**[10]
- ❒ Name, relationship to child
- ❒ Date, time statement made
- ❒ Exact wording with quotation marks and identification of speaker
- ❒ Behavior and mood of speaker
- ❒ Practitioner's questions, statements and actions
- ❒ Witnesses to interview (names & titles of those present)

❒ **Physical exam findings, evidence collection**
❒ Photographs of all findings with child's name, record number, ruler, color scale (often done by law enforcement)
❒ Serial photographs throughout healing process to document changes
❒ Supplement photographs with detailed drawings in chart for back-up records[10]

Note: Recent or fresh bite marks can be swabbed for saliva with a sterile cotton swab moistened in sterile saline, dried, and packaged in an envelope from an evidence kit for DNA processing.[33]
When there is a clear dental imprint, casts of the bite marks can be matched with an abuser by a forensic dentist or pathologist.[34,60]

Table 3. Red Flags for Abuse

Classic red flags for abusive trauma in the history include:

❒ Changing details with the caretaker's repetition of the story
❒ Details inconsistent with findings on physical exam:
- ❒ Findings of additional injuries or more severe injuries than described
- ❒ Injuries described as self-inflicted or inflicted by another child
- ❒ Injuries not compatible with developmental stage of the child

❒ Significant lapse in seeking care for injuries
❒ Seeking care at different health care facilities with each presentation[10]

Classic red flags for abusive trauma on physical exam include:

❒ Multiple injuries and multiple types of injuries at different stages of healing
❒ Multiplanar or unusual locations of injuries (neck, perineal area, upper arms)
❒ Poor hygiene or poor caretaker-child interaction
❒ Pathognomonic injuries: SDH, posterior rib fractures, spiral fractures (non- ambulatory children), metaphyseal fracture (bucket handle), scapular and spinous process fractures, sternal fractures[61]
❒ Patterned injuries: hand imprint, cigarette burns, grill marks, or loop marks

tices such as cupping (using a heated, usually glass, cup to apply vacuum suction to one's back), coining (applying heated coins to a child's skin, *see Figure 7)*,[58] or moxibustion (application of incense to skin believed to have healing power).[10]

Cigarette burns may be confused with nummular impetigo, phytophotodermatitis, or dermatitis herpetiformis (often associated with autoimmune diseases and characterized by blistering). Finally, as noted above, folk remedies such as cupping, coining, or moxibustion also may cause burns that are suspicious for abusive trauma, but represent an attempt to treat an illness rather than an intent to harm.[10] An accurate history taken with the aid of a medical interpreter, when necessary, is essential in discernment of the latter case.

For skeletal fractures, the differential diagnosis includes normal variants of bone structures (which may appear suspicious on radiographs), congenital syphilis (causing periosteal elevation on radiograph), Vitamin D-dependent rickets, and osteogenesis imperfecta (OI).[10]

With respect to OI, there are four types, of which Type IV is the most easily confused with abuse. Features include easy bruising, short stature, abnormal dentition (dentinogenesis imperfecta) bluish sclera (Types I and II) and varying degrees of osteopenia.[10] Abusive injury can be distinguished from OI Types I and II due to their characteristic blue sclerae.[59] Differentiation between abuse and OI types III and IV may be more difficult. Although rare, type III has normal sclerae but severely fragile bones with frequent fractures and progressive deformity of long bones. However, radiographs of children with mild cases of OI will demonstrate wormian bones in the skull and osteoporosis characteristics. Distinguishing abusive injury from OI Type IV may be more challenging, as the clinical characteristics may be less severe. It often can be identified with careful family history and evaluation for the radiographic findings of OI, such as the presence of wormian bones, osteoporosis, bony deformity, and demineralization.[38,59]

The differential for CNS injuries includes infections such as meningitis or encephalitis, febrile or idiopathic seizures, and ingestions.[10] Specifically, the evaluation for shaken baby syndrome includes the differential diagnosis for SDH and retinal hemorrhages, such as accidental trauma, coagulation disorders,

Table 4. Laboratory and Imaging Considerations[10]

Routine laboratory data and imaging: Evaluation of comorbidities and differential diagnoses as indicated

- ❒ Complete blood count with differential (infection, bruising, bleeding, inflammation)
- ❒ C-reactive protein (infection, inflammation)
- ❒ ESR (infection, inflammation, rheumatologic disorders)
- ❒ Coagulation panel (bruising, bleeding)
- ❒ Lumbar puncture for CSF studies (seizures, altered mental status, infection)
- ❒ Complete metabolic panel (seizures, dehydration)
- ❒ Tests for abdominal injury: LFTs, amylase, lipase, stool occult blood, urinalysis/urine dip for occult blood
- ❒ Urine (and serum) toxicology panels (seizures, altered mental status)

Imaging

- ❒ Skeletal survey (for children < age 2):
  - ❒ AP views of humeri, forearms, hands, femurs, lower legs and feet; chest; pelvis; lateral view axial skeleton (infants), and AP and lateral views of skull
- ❒ Radionuclide bone scanning for identification of new rib fractures and occult fractures
- ❒ Head CT for any child with suspected intracranial injury
  - ❒ If positive: Brain MRI (further assessing and dating the injury)
- ❒ Thorax/abdomen/pelvic FAST, US, CT, or MRI for further injury evaluation as indicated

vascular malformations, and rare amino acid metabolic disorders such as glutaric aciduria type I (associated with acute encephalopathy and SDH). Finally, the history should evaluate for the folk healing practice "caida di mollera," where a child with a sunken fontanelle is held upside by the ankles and shaken (in an effort to pop out the fontanelle).[10]

The differential diagnoses for retinal hemorrhages include vasculitis, vascular obstruction, and toxic febrile illness associated with serious infections.[10] The role of the EP is to rule out potentially grave diagnoses in the differential and to contact the pediatrics service for admission to protect the child while the remainder of the social and medical work-up is completed.

Clinical Evaluation: Ancillary Studies

If during the history and physical exam, a concern for abuse has developed, appropriate ancillary studies can be ordered. In cases where inflicted head trauma is suspected, in addition to those cases where a child presents with seizures, altered mental status, and focal neurological findings, a head CT should be obtained to evaluate for skull fractures, intracranial hemorrhage, or hydrocephalus.[10] During in-hospital evaluation, a brain MRI with contrast may be useful in dating CNS injuries, which may assist in the identification of the chronicity of the injury and when the child was exposed to a potential perpetrator.[10] *(See Table 4.)*

Due to the frequency of skeletal injury and difficulty in detection of fractures in younger children, a skeletal survey should be considered in the clinical evaluation of all children younger than age 2 in whom there is a concern for abuse. The skeletal survey consists of AP views of humeri, forearms, hands, femurs, lower legs, and feet; chest; pelvis; lateral view axial skeleton (infants); and AP and lateral views of the skull.[10] *(See Table 4.)* Finally, a skeletal survey should be performed during the evaluation of a child with suspected abusive head injury, as extracranial abnormalities may be detected in 30-70% of these children.[13]

Psychosocial Evaluation of Suspected Child Abuse in the ED

When abuse is suspected, and/or when a young child presents with a severe injury, the immediate involvement of a social worker, especially when they are specifically trained in the area of child abuse, can add invaluable information to the medical team's assessment of the social situation and the child's safety. Consultation with Child Protective Services (CPS) is crucial when abuse is suspected and may be especially helpful when it is uncertain: unusual aspects of the case may be discussed with CPS by phone 24 hours a day. The CPS worker will note the details of the case, including the assessment of the caretakers' background, abilities, environment, and potential risk to other children, and advise whether the case merits further investigation by CPS and potentially by local law enforcement agencies.[10]

In some cases, the child must be admitted to the hospital for protection while the social and medical evaluations are completed. The family's understanding and cooperation with the investigative process may be facilitated by a preliminary and diplomatic conversation with the child's family, communicating concern for abuse and the consequent necessity for discussion with CPS, additional studies such as the skeletal survey, and admission for the child's appropriate medical management and safety. It must be stressed that the EP's role is to ensure that there are no emergent health issues or injuries that require evaluation and management. While careful communication between the EP and admitting physician must ensure that a thorough history and work-up are done, often the appropriate locale of the thorough history and extensive testing will be during hospital admission.[10]

Medico-legal Considerations

The mandated reporting law, which exists in all states, requires that a physician make a report to CPS when there is a reasonable suspicion that a child's injury was caused by abuse. The physician should be familiar with the laws for reporting in their respective state. A reasonable suspicion for abuse is defined as when the information gathered by the physician leads to the conclusion that a child's injury or medical condition is most likely due to child abuse. Once a report is made (usually by calling the 24-hour emergency state or county hotline) and written documentation is provided, CPS workers evaluate the provided information, investigate the report if deemed appropriate, and provide support to the family per the state's established timeline.[10]

Finally, a physician making a report "in good faith" is able to

Figure 7. Coining

Photo used with permission from Preston Maxim, MD, San Francisco General Hospital.

claim immunity from liability if an angry caregiver and/or family files suit against that physician if it is determined that no maltreatment occurred. Additionally, a physician who fails to make a report of suspected abuse may be liable for prosecution for failure to report child abuse under the state's statutes. In cases of physical abuse, the EP may be subpoenaed to testify in court. Thus, the most effective way a physician can advocate for the child in question is to accurately and thoroughly document the medical evaluation performed in the ED.[10]

Conclusion

In summary, the physical abuse of children has potential for serious long-term sequelae, such as disability and death. While there is a vast spectrum in the presentation of physical abuse, ranging from mild bruising to acute intracranial hemorrhage, each child presenting to the ED for treatment of an injury must be carefully evaluated for the possibility of child abuse. Even mild injuries may be suggestive of more extensive and long-term battering, and a thorough history and physical exam might yield findings to pursue a complete laboratory, radiological, and psychosocial evaluation. The ED evaluation of child abuse requires cooperation and collaboration among many different disciplines, such as the ED providers, social workers, CPS investigators, and law enforcement personnel. Finally, meticulous documentation of the child's medical evaluation in the ED is the most effective way to advocate for the child and to protect the child from further abusive episodes.

References

1. Saade DN, Simon HK, Greenwald M. Abused children: missed opportunities for recognition in the ED. *Acad Emerg Med* 2002;9:524.
2. Sedlak AJ, Broadhurst DD. Third National Incidence Study of Child Abuse and Neglect, US Dept of Health and Human Services; 1996. Accessed on 8/13/07 at www.childwelfare.gov/pubs/statsinfo/nis3.cfm.
3. Kocher MS, Kasser JR. Orthopedic aspects of child abuse. *J Am Acad Orthop Surg* 2000;8:10-20.
4. Endom E. Epidemiology and clinical manifestations of child abuse. *UpToDate Patient Information* online.
5. United States Dept of Health and Human Services, Administration on Children, Youth, and Families. Child Maltreatment 2001. US Govt Printing Office, Washington DC, 2003. Accessed 8/13/07 at http://www.acf.hhs.gov/programs/cb/pubs/cm01
6. U.S. Department of Health and Human Services, Children's Bureau Administration on Children, Youth, and Families. Child welfare outcomes 2000: Annual report. Appendix C: Highlights of findings from Child Maltreatment 2000.
7. National Center on Child Abuse and Neglect: National Child Abuse and Neglect Data Service Component. Washington DC: Government Printing Office: 1993. Working Paper 2.
8. U.S. Department of Health and Human Services: Child Maltreatment 2003. In: Chapter Three: Victims. Accessed 8/13/07 at http://www.acf.hhs.gov/programs/cb/pubs/cm03
9. Lane WG, Rubin DM, Monteith R, et al. Racial differences in the evaluation of pediatric fractures for child abuse. *JAMA* 2002;288:1603-1609.
10. Giardino AP. Child Abuse and Neglect: Physical Abuse. Emedicine 2006 June 15th.Accessed Dec 10th, 2006. Available at: URL: http//www.emedicine.com/ped/topic2648.htm.
11. U.S. Department of Health and Human Services: Administration for Children and Families. Summary: Figures. Child Maltreatment 2004. Accessed 8/15/07 at http://www.acf.hhs.gov/programs/cb/pubs/cm04/sumfig.htm
12. Egami Y, Ford DE, Greenfield SF, et al. Psychiatric profile and sociodemographic characteristics of adults who report physically abusing or neglecting children. *Am J Psychiatry* 1996;153:921-928.
13. Duhaime AC, Christian CW, Rorke LB, et al. Nonaccidental head injury in infants—the "shaken baby syndrome". *N Engl J Med* 1998;338:1822-1829.
14. Starling SP, Holden JR, Jenny C. Abuse head trauma: the relationship of perpetrators to their victims. *Pediatrics* 1995;95:259-262.
15. Jain AM. Emergency department evaluation of child abuse. *Emerg Med Clin North Am* 1999;17:575-593.
16. Ludwig S. Child abuse. In: *Textbook of Pediatric Emergency Medicine.* Fleischer GR, Ludwig S, Henretig FM, eds. 5th ed. Philadelphia: Lippincott Williams and Wilkins; 2006:1761.
17. Kini N, Lazoritz S. Evaluation for possible physical or sexual abuse. *Pediatr Clin North Am* 1998;45:205-219.
18. Strathearn L, Gray PH, O'Callaghan FD, et al. Childhood neglect and cognitive development in extremely low birth weight infants: a prospective study. *Pediatrics* 2001;108:142-151.
19. Gessner BD, Moore M, Hamilton B, et al. The incidence of infant physical abuse in Alaska. *Child Abuse Negl* 2004;28:9-23.
20. Jenny C; Committee on Child Abuse and Neglect. Evaluating infants and young children with multiple fractures. *Pediatrics* 2006;118:1299-1303.
21. Naidoo S. A profile of the oro-facial injuries in child physical abuse at

a children's hospital. *Child Abuse Negl* 2000;24:521-534.
22. Wissow LS. The medical history and physical examination. In: *Child Advocacy for the Clinician: An Approach to Child Abuse and Neglect.* Baltimore: Williams and Wilkins; 1990:49.
23. Wilson EF. Estimation of the age of cutaneous contusions in child abuse. *Pediatrics* 1977;60:750-752.
24. Dailey JC, Bowers CM. Aging of bitemarks: a literature review. *J Forensic Sci* 1997;42:792-795.
25. Schwartz AJ, Ricci LR. How accurately can bruises be aged in abused children? *Pediatrics* 1996;97:254-257.
26. Langlois NE, Gresham GA. The ageing of bruises: a review and study of the colour changes with time. *Forensic Sci Int* 1991;50:227-238.
27. Dunstan FD, Guildea ZE, Kontos K, et al. A scoring system for bruise patterns: a tool for identifying abuse. *Arch Dis Child* 2002;86:330-333.
28. Carpenter RF. The prevalence and distribution of bruising in babies. *Arch Dis Child* 1999;80:363-366.
29. Maguire S, Mann MK, Sibert J, et al. Are there patterns of bruising in childhood which are diagnostic or suggestive of abuse? A systematic review. *Arch Dis Child* 2005;90:182-186.
30. Pressel DM. Evaluation of physical abuse in children. *Am Fam Physician* 2000;61:3057-3064.
31. Sugar NF, Taylor JA, Feldman KW. Bruises in infants and toddlers: those who don't cruise rarely bruise. Puget Sound Pediatric Research Network. *Arch Pediatr Adoles Med* 1999;153:399-403.
32. Committee on Child Abuse and Neglect. Academy of Pediatrics. When inflicted skin injuries constitute child abuse. *Pediatrics* 2002;110:644-645.
33. Kellogg N; American Academy of Pediatrics Committee on Child Abuse and Neglect. Oral and dental aspects of child abuse and neglect. *Pediatrics* 2005;116:1565-1568.
34. Jessee SA. Orofacial manifestations of child abuse and neglect. *Am Fam Physician* 1995;52:1829-1834.
35. Albert MJ, Drvaric DM. Injuries resulting from pathologic forces: child abuse. In: *Pediatric Fractures: A Practical Approach to Assessment and Treatment.* MacEwen GD, Kasser JR, Heinrich SD, eds. Baltimore: Williams and Wilkins; 1993:388.
36. Spivak BS. Biomechanics of nonaccidental trauma. In: Ludwig S, Kornberg AE, eds. *Child Abuse: Medical Reference*. 2nd ed. New York: Churchill Livingstone; 1992:61-78.
37. Kleinman PK. *Diagnostic Imaging of Child Abuse*. 2nd ed. St Louis: Mosby-Yearbook, Inc.; 1998.
38. Kleinman PK. The spectrum of non-accidental injury and its imitators in children. In: *Musculoskeletal Diseases: Diagnostic Imaging and Interventional Techniques.* Hodler J, Zollikofer, von Schulthess GK, Zollikofer CL, eds. Milan: Springer; 2005:169-174.
39. Zimmerman S, Makaroff K, Care M, et al. Utility of follow-up skeletal surveys in suspected child physical abuse evaluations. *Child Abuse Negl* 2005;29:1075-1083.
40. Bechtel K, Stoessel K, Leventhal JM, et al. Characteristics that distinguish accidental from abusive injury in hospitalized young children with head trauma. *Pediatrics* 2004;114:165-168.
41. Jenny C, Hymel KP, Ritzen A, et al. Analysis of missed cases of abusive head trauma. *JAMA* 1999;281:621-626.
42. Duhaime AC, Partington MD. Overview and clinical presentation of inflicted head injury in infants. *Neurosurg Clin N Am* 2002;13:149-154.
43. Bechtel K, Berger R. Inflicted traumatic brain injury: making the diagnosis in the emergency department. *Clin Pediatr Emerg Med* 2006;7:138-142.
44. Robson MC, Heggers JP. Pathophysiology of the burn wound. In: *Burns in Children: Pediatric Burn Management.* Carvajal HF, Parks D, eds. Chicago: Year Book; 1988:27-32.
45. Alexander RC, Surrell JA, Cohle SD. Microwave oven burns to children: an unusual manifestation of child abuse. *Pediatrics* 1987; 79:255-260.
46. Burdett-Smith P. Stun gun injury. *J Accid Emerg Med* 1997;14:402-404.
47. Hansbrough JF, Hansbrough W. Pediatric burns. *Pediatr Rev* 1999;20:17-23.
48. Andronicus M, Oates RK, Peat J, et al. Non-accidental burns in children. *Burns* 1998;24:552-558.
49. Wissow LS. Head and internal injuries. In: *Child Advocacy for the Clinician: An Approach to Child Abuse and Neglect.* Baltimore: Williams and Wilkins; 1990:67.
50. Crouse CD, Faust RA. Child abuse and the otolaryngologist: part II. *Otolaryngol Head Neck Surg* 2003;128:311-317.
51. Saraswat A. Child abuse and trichotillomania. *BMJ* 2005;330:83-84.
52. Friedman EM. Caustic ingestions and foreign body aspirations: an overlooked form of child abuse. *Ann Otol Rhinol Laryngol* 1987;96:709-712.
53. Arieff AI, Kronlund BA. Fatal child abuse by forced water intoxication. *Pediatrics* 1999;103:1292-1295.
54. Thomas JN. Child abuse and neglect. CHNMC Clinical Proceedings. 1984 May-August. Accessed 8/13/07 at http://www.dvinstitute.org/conferences/proceedings/1995/joyce.pdf
55. Meadow R. Non-accidental salt-poisoning. *Arch Dis Child* 1993; 68:448-452.

CME Objectives

The CME objectives for *Pediatric Emergency Medicine Reports* are to help physicians:

a.) Quickly recognize or increase index of suspicion for specific conditions;

b.) Describe the epidemiology, etiology, pathophysiology, historical and physical examination findings associated with the entity discussed;

c.) Correctly formulate a differential diagnosis and perform necessary diagnostic tests;

d.) Apply state-of-the-art therapeutic techniques (including the implications of pharmacologic therapy discussed) to patients with the particular medical problems discussed;

e.) Provide patients with any necessary discharge instructions.

CME Instructions

Physicians participate in this continuing medical education program by reading the article, using the provided references for further research, and studying the questions at the end of the article. Participants should select what they believe to be the correct answers, then refer to the list of correct answers to test their knowledge.

To clarify confusion surrounding any questions answered incorrectly, please consult the source material. After completing this activity, you must complete the evaluation form that will be provided at the end of the semester and return it in the reply envelope provided to receive a credit letter. When your evaluation is received, a credit letter will be mailed to you.

56. Kellogg ND, Lukefahr JL. Criminally prosecuted cases of child starvation. *Pediatrics* 2005;116:1309-1316.
57. Bittner S, Newberger E. Pediatric understanding of child abuse and neglect. *Pediatr in Review* 1981;2:197-207.
58. Maxim P. San Francisco General Hospital Emergency Department, UCSF, Continuing Education, Clinical Images website. Accessed on 8/15/07 at http://sfghed.ucsf.edu/Education/ClinicImages/Coining%20clin.jpg
59. Kleinman PK. Differentiation of child abuse and osteogenesis imperfecta: medical and legal implications. *AJR Am J Roentgenol* 1990;154:1047-1048.
60. Oral and dental aspects of child abuse and neglect. American Academy of Pediatrics. Committee on Child Abuse and Neglect. American Academy of Pediatric Dentistry. Ad Hoc Work Group on Child Abuse and Neglect. *Pediatrics* 1999;104(2 pt 1):348-350.
61. Potash AS. Pediatrics, Child Abuse. EMedicine. Accessed on 8/13/07 at http://www.emedicine.com/emerg/topic368.htm

CME Questions

81. What type of fracture is more often seen in abusive injuries?
    A. Diaphyseal fracture
    B. Skull fracture
    C. Metaphyseal corner fracture
    D. Rib fracture

82. Bruising on what part of the body is suggestive of abuse?
    A. Inner thighs and groin
    B. Bony prominences such as elbows and knees
    C. Ulnar aspect of forearms
    D. Calves or shins

83. What burn patterns are suggestive of abuse?
    A. Spill and splash burns
    B. Unilateral burns
    C. Sunburns
    D. Identifiable patterned burns

84. Perpetrators of abuse are *most* likely to be:
    A. Fathers
    B. Mothers
    C. Mother's boyfriend
    D. Babysitters

85. Which statement about mandated reporting is true?
    A. Physicians are liable to prosecution for reporting suspected abuse when it is determined that maltreatment has not occurred.
    B. The mandated reporting law in all states requires a physician to make a report when injury due to abuse is suspected.
    C. Physicians are always expected to testify as expert witnesses in abuse cases.
    D. Physicians are not held responsible for failing to make a report of suspected abuse.

86. Which statement about bite marks is true?
    A. It is not possible to distinguish between animal and human bites.
    B. It is not possible to distinguish between bite marks of adults and children.
    C. DNA swabs may be obtained from bite marks only when saliva has not dried.
    D. Forensic evidence for bite marks, including photo documentation, may help identify the perpetrator and should be routinely collected.

87. Which of the following statements about documentation is accurate?
    A. The medical record may be admitted as evidence in court.
    B. Photographs of injuries are only done by law enforcement officers.
    C. Detailed documentation of interviews with child and caregivers is not necessary.
    D. The physician should avoid making statements in the assessment and plan about whether abuse is suspected.

88. Orofacial injuries suspicious for abuse include:
    A. injuries to lips and maxillary frenulum in ambulatory children.
    B. bruising to the back of the body, inner arms or thighs, trunk, genitalia, cheeks, ears, eyes, and neck.
    C. isolated epistaxis.
    D. injuries to forehead in toddlers.

89. Aspects of the caregiver's history and physical examination of the child that may raise concern for abuse include:
    A. reproducible details with repetition of the story by caregiver.
    B. injuries consistent with the child's developmental level and abilities.
    C. details inconsistent with findings on physical exam.
    D. immediate presentation for care following injury.

90. What types of cutaneous findings are frequently confused with abuse?
    A. Bruises over shins
    B. Refractory eczema
    C. Impetigo
    D. Lesions from folk practices (e.g., cupping, coining, moxibustion)

Answers: 81. C; 82. A; 83. D; 84. A; 85. B; 86. D; 87. A; 88. B; 89. C; 90. D

PEDIATRIC Emergency Medicine Reports
The Practical Journal of Pediatric Emergency Medicine

Physical Abuse of Children

Abusive Bruises

Photo used with permission from David M. Pressel, MD, PhD.

Features of Bruises Suggestive of Abuse[10,32]

- The pattern of injuries corresponds to infliction with an instrument not found in play or the child's usual environment, such as linear bruises and petechiae on the buttocks and gluteal cleft from hitting, spanking, whipping, or paddling
- Linear bruising and/or petechiae of the pinna from blows to the skull ("tin ear syndrome" is comprised of bruising to the pinna, retinal bleeding, and acute traumatic head injury)
- Hand prints or oval marks on cheeks, neck, upper arms, trunk, or buttocks (from being punched, slapped, grabbed, shaken, or pinched)
- Belt marks (leaving long bands of ecchymosis, sometimes with a u-shape at the end or puncture wounds from the buckle)
- Loop marks from beating with a rope, wire, or electric cord (electric cords leave a characteristic "double-track mark")
- Ligature marks or circumferential rope burns seen on the neck, wrists, ankles, and gag marks at corners of the mouth
- Any history of injury inconsistent with the child's level of development or with the category and extent of the injury should raise suspicion for abusive trauma

Metaphyseal Bucket Handle Fracture

Photo used with permission from David M. Pressel, MD, PhD.

Loop Marks

Photo used with permission from David M. Pressel, MD, PhD.

Posterior Rib Fractures

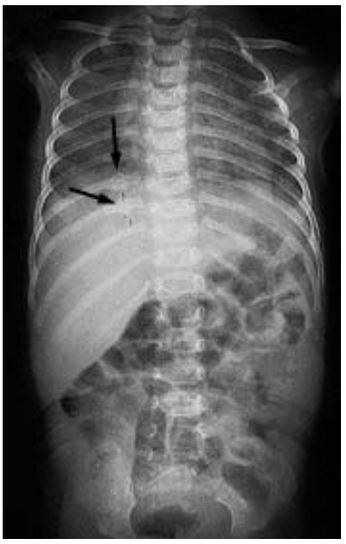

Photo used with permission from David M. Pressel, MD, PhD.

Retinal Hemorrhages

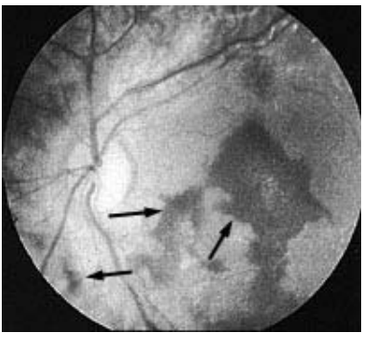

Photo used with permission from David M. Pressel, MD, PhD.

Immersion Burn

Photo used with permission from David M. Pressel, MD, PhD.

Red Flags for Abuse

Classic red flags for abusive trauma in the history include:

- ❒ Changing details with the caretaker's repetition of the story
- ❒ Details inconsistent with findings on physical exam:
  - ❒ Findings of additional injuries or more severe injuries than described
  - ❒ Injuries described as self-inflicted or inflicted by another child
  - ❒ Injuries not compatible with developmental stage of the child
- ❒ Significant lapse in seeking care for injuries
- ❒ Seeking care at different health care facilities with each presentation[10]

Classic red flags for abusive trauma on physical exam include:

- ❒ Multiple injuries and multiple types of injuries at different stages of healing
- ❒ Multiplanar or unusual locations of injuries (neck, perineal area, upper arms)
- ❒ Poor hygiene or poor caretaker-child interaction
- ❒ Pathognomonic injuries: SDH, posterior rib fractures, spiral fractures (non- ambulatory children), metaphyseal fracture (bucket handle), scapular and spinous process fractures, sternal fractures[61]
- ❒ Patterned injuries: hand imprint, cigarette burns, grill marks, or loop marks

Laboratory and Imaging Considerations[10]

Routine laboratory data and imaging: Evaluation of comorbidities and differential diagnoses as indicated

- ❒ Complete blood count with differential (infection, bruising, bleeding, inflammation)
- ❒ C-reactive protein (infection, inflammation)
- ❒ ESR (infection, inflammation, rheumatologic disorders)
- ❒ Coagulation panel (bruising, bleeding)
- ❒ Lumbar puncture for CSF studies (seizures, altered mental status, infection)
- ❒ Complete metabolic panel (seizures, dehydration)
- ❒ Tests for abdominal injury: LFTs, amylase, lipase, stool occult blood, urinalysis/urine dip for occult blood
- ❒ Urine (and serum) toxicology panels (seizures, altered mental status)

Imaging

- ❒ Skeletal survey (for children < age 2):
  - ❒ AP views of humeri, forearms, hands, femurs, lower legs and feet; chest; pelvis; lateral view axial skeleton (infants), and AP and lateral views of skull
- ❒ Radionuclide bone scanning for identification of new rib fractures and occult fractures
- ❒ Head CT for any child with suspected intracranial injury
  - ❒ If positive: Brain MRI (further assessing and dating the injury)
- ❒ Thorax/abdomen/pelvic FAST, US, CT, or MRI for further injury evaluation as indicated

Documentation of Abuse

The medical record may be admitted as evidence in court.

- Accurate, detailed, legible records are essential (consider dictation).[10]

THE RECORD SHOULD INCLUDE:

- ❒ Date and time of injury
- ❒ When first noted
- ❒ Where the injury occurred
- ❒ Who was there and witnessed the injury
- ❒ What led up to the injury
- ❒ How the child and caretaker responded to the injury
- ❒ Lapse in time before seeking care for the injury?[10]

- ❒ **Child's interview and medical history (separate interview):**[1]
  Child's name, medical record number, DOB
- ❒ **Caregiver statements (separate interview, optimally conducted by social work)**[10]
  - ❒ Name, relationship to child
  - ❒ Date, time statement made
  - ❒ Exact wording with quotation marks and identification of speaker
  - ❒ Behavior and mood of speaker
  - ❒ Practitioner's questions, statements and actions
  - ❒ Witnesses to interview (names & titles of those present)

- ❒ **Physical exam findings, evidence collection**
- ❒ Photographs of all findings with child's name, record number, ruler, color scale (often done by law enforcement)
- ❒ Serial photographs throughout healing process to document changes
- ❒ Supplement photographs with detailed drawings in chart for back-up records[10]

Note: Recent or fresh bite marks can be swabbed for saliva with a sterile cotton swab moistened in sterile saline, dried, and packaged in an envelope from an evidence kit for DNA processing.[33]
When there is a clear dental imprint, casts of the bite marks can be matched with an abuser by a forensic dentist or pathologist.[34,60]

Coining

Photo used with permission from Preston Maxim, MD, San Francisco General Hospital.

Supplement to *Pediatric Emergency Medicine Reports*, September 2007: "Physical Abuse of Children: Identification, Evaluation, and Management in the Emergency Department Setting." *Authors:* N. Ewen Wang, MD, Assistant Professor of Surgery, Associate Director of Pediatric Emergency Medicine, Stanford University Hospital, Stanford, CA; and Bronwyn Baz, MD, Lucile Packard Children's Hospital, Stanford University Medical Center, Palo Alto, CA. *Peer reviewer:* Kristen Bechtel, MD, Associate Professor of Pediatrics, Yale University School of Medicine, New Haven, CT. *Pediatric Emergency Medicine Reports' "Rapid Access Guidelines."* **Senior Vice President and Group Publisher:** Brenda Mooney. **Editor-in-Chief:** Ann Dietrich, MD, FAAP, FACEP. **Associate Publisher:** Lee Landenberger. For customer service, call: **1-800-688-2421.**

AHC Media LLC

Evidence-Based M ED

Trauma Reports

Enclosed in this issue: CME/CME Evaluation

Vol. 8, No. 5

Supplement to *Emergency Medicine Reports* and *Pediatric Emergency Medicine Reports*

September/October 2007

Abstract: Abdominal trauma is the most frequently initially missed fatal injury in pediatrics. A high degree of suspicion is critical and early diagnosis is essential to minimize the morbidity and mortality associated with these injuries. The clinician must understand the mechanisms of injury that place the child at risk and the subtle physical examination findings, and develop an algorithmic approach to the diagnosis. The authors review the unique features and injury patterns associated with pediatric abdominal trauma.

— *The Editor*

Pediatric Abdominal Trauma

Authors: **N. Ewen Wang, MD,** Assistant Professor, Division of Emergency Medicine, Stanford University School of Medicine, Palo Alto, CA; and **Rebecca L. Blankenburg, MD, MPH,** Clinical Instructor, General Pediatrics Hospitalist, Lucile Packard Children's Hospital, Stanford University Medical Center, Palo Alto, CA.

Peer reviewer: **Perry W. Stafford, MD, FACS, FAAP, FCCM,** Professor of Surgery, UMDNJ Robert Wood Johnson Medical School, New Brunswick, NJ.

Introduction

Trauma remains the number one cause of disability and death for children. Abdominal trauma is a major cause of severe injury in children and also is the most common cause of initially missed fatal injury.[1,2] This article will discuss the epidemiology of pediatric abdominal trauma, the differences between abdominal injury in adults and children, and the specific patterns of abdominal injury seen in children. Specific organ system injuries and their management will be systematically presented.

Background/ Epidemiology

Unintentional injury is the number one cause of death in the United States for children and adults ages 1-44. Use of the term "unintentional injury" as opposed to "accident" began two decades ago. Referring to something as an "accident" implies that the injury occurred without a cause. The term "unintentional injury" is now used to emphasize that many injuries can be prevented either by physical safety equipment, such as bicycle helmets and seat belts, or by regulations, such as slower speed limits. It is sobering to note that homicide and suicide, often carried out by traumatic mechanisms, remain the second and third most common causes of death in our society for young people ages 15-34.

Statement of Financial Disclosure

Dr. Dietrich (editor in chief), Drs. Wang and Blankenburg (authors), and Stafford (peer reviewer), Ms. Finerty (nurse reviewer), and Ms. Neff (nurse reviewer) report no relationships with companies related to this field of study.

While traumatic injury is common in children, the mechanism of injury depends upon the chronologic and developmental age of the child. Toddlers usually suffer from submersion injuries as well as falls. School age children more often experience pedestrian and bicycle injuries. Pedestrian injuries are the second most common cause of abdominal injury in children after motor vehicle collision (MVC). Morbidity in these cases is related to the degree of multiple injury, with the majority of deaths caused by head trauma.[3]

Adolescents incur injuries secondary to increased risk taking behavior, coupled with the ability to drive legally. Injuries in adolescents result from organized sports, firearms, recreational equipment, and motorized vehicles. Adolescents sustain the largest burden of injury mortality, with 48.5% of these deaths occurring between the ages of 15 and 19.[4] MVCs are the major cause of fatal injuries in adolescents, as well as the majority of serious injuries and death in the pediatric population. Although young adults ages 15-20 make up only 7% of licensed drivers, this group makes up 15% of all drivers killed in fatal crashes.[4] Per Loiselle, "the fatality per distance traveled is 4 times higher in this age group than all other ages combined."[4]

All terrain vehicles (ATVs) deserve special mention. Despite regulations developed in the 1980s mandating that children younger than age 16 cannot use ATVs without a helmet or adult supervision, there continue to be more than 20,000 injuries annually caused by ATVs, with more than 200 deaths per year.[5] Rollovers account for almost one-half of injuries, while falls and collisions account for the rest. Abdominal trauma accounts for 25% of injuries and 19% of deaths.[5,6]

Abuse is responsible for less than 4% of children with abdominal trauma cared for in urban EDs and accounts for less than 1% of children admitted to urban hospitals for abdominal trauma.[7,8] The children with abdominal trauma secondary to abuse are younger than a majority of trauma patients (mean age, 2-3 years) but they have more severe injuries than children who were injured by other mechanisms of abdominal trauma.[9] Up to 50% of mortality in abdominal trauma is due to delays in presentation (mean time to presentation, 13 hours) and extent of injuries.[7,8]

Abdominal injury in children is mainly due to blunt trauma, with more than 90% of pediatric injuries caused by blunt trauma such as MVCs.[10,11] Penetrating injuries such as gunshots and stab wounds account for only 1.5% of all trauma admissions nationwide; however, they account for 15% of children with abdominal trauma who are admitted to urban trauma centers.[9] These children are older and account for a disproportionate number of trauma-related deaths.

Differences Between Adult and Pediatric Abdominal Trauma: Children are not Small Adults

Unique developmental, anatomic, and physiologic factors in children compared to adults lead to differences in the type of injury and the management and outcome of abdominal trauma. In regard to overall injury management, since children often sustain head trauma or are unable to communicate accurately secondary to their level of development or fear, a history of the incident may be unavailable. Abdominal distention, which occurs from swallowing air when crying, can make the physical examination less reliable. A compliant rib cage may allow for internal injury without external evidence of these injuries.

Infants and young children are more prone to abdominal injury than adults. Since the solid abdominal organs are relatively larger, the abdominal musculature is less mature, the abdominal wall and internal organs have less fat than those in adults, and the internal organs are suspended by more elastic structures (especially the kidneys), the abdominal organs have an increased risk of direct injury and are more vulnerable to blunt injury.[12] The pediatric kidney retains fetal lobulations that might lead to easier separation and fracture.[12] In children, the splenic and hepatic capsules are tougher than those in adults, which is postulated to account for the ability to contain bleeding and manage injuries nonoperatively.[13,14] Because of a child's smaller size, a given force is applied over a relatively larger area, causing increased susceptibility to multi-organ injury.[12] In children, the compliant ribcage does not protect the liver and spleen from injury as it does in adults, and the bladder is an intraabdominal organ. Thus, the child's abdomen begins at the level of the nipples.

Physiologically, children can maintain normal vital signs even in the setting of significant blood loss. As much as one quarter of the blood volume can be lost prior to the onset of hypotension.[15,16] Clinical identification of hypovolemia is difficult. Heart rate varies with age, pain, temperature, and stress, and persistent tachycardia can be secondary either to these factors or to blood loss. Capillary

Trauma Reports™ (ISSN 1531-1082) is published bimonthly by AHC Media LLC, 3525 Piedmont Road, N.E., Six Piedmont Center, Suite 400, Atlanta, GA 30305. Telephone: (800) 688-2421 or (404) 262-7436.

Senior Vice President/Group Publisher: Brenda Mooney
Associate Publisher: Lee Landenberger
Managing Editor: Suzanne Thatcher

POSTMASTER: Send address changes to ***Trauma Reports***, P.O. Box 740059, Atlanta, GA 30374.

Accreditation

AHC Media LLC is accredited by the Accreditation Council for Continuing Medical Education to provide continuing medical education for physicians.

AHC Media LLC designates this educational activity for a maximum of 2.5 AMA *PRA Category 1 Credits™*. Physicians should only claim credit commensurate with the extent of their participation in the activity.

Approved by the American College of Emergency Physicians for 2.5 hours of ACEP Category 1 credit.

AHC Media LLC is accredited as a provider of continuing nursing education by the American Nurses Credentialing Center's Commission on Accreditation.

Provider approved by the California Board of Registered Nursing, Provider # 14749, for 1.5 Contact Hours.

This program has been approved by the American Association of Critical-Care Nurses (AACN) for 1.5 Contact Hours, Category A, file number 10852.

AHC Media LLC

Subscriber Information

Customer Service: 1-800-688-2421

Customer Service E-Mail: customerservice@ahcmedia.com
Editorial E-Mail: suzanne.thatcher@ahcmedia.com

World Wide Web page: http://www.ahcmedia.com

FREE to subscribers of *Emergency Medicine Reports* and *Pediatric Emergency Medicine Reports*

This is an educational publication designed to present scientific information and opinion to health professionals, to stimulate thought, and further investigation. It does not provide advice regarding medical diagnosis or treatment for any individual case. It is not intended for use by the layman. Opinions expressed are not necessarily those of this publication. Mention of products or services does not constitute endorsement. Clinical, legal, tax, and other comments are offered for general guidance only; professional counsel should be sought for specific situations.

This CME/CNE activity is intended for emergency, family, osteopathic, trauma, surgical, and general practice physicians and nurses who have contact with trauma patients.

It is in effect for 24 months from the date of publication.

For Customer Service,
Please call our customer service department at **(800) 688-2421.** For editorial questions or comments, please contact **Suzanne Thatcher**, Senior Managing Editor, at suzanne.thatcher@ahcmedia.com.

Table 1. Mechanisms and Patterns of Injury Suggesting Increased Risk of Intra-abdominal Injury*

FALL

- Major factors in injuries incurred as a result of a fall:
  - — Height of fall
  - — Body position on impact
  - — Nature of contact surface
  - — Body orientation on impact
  - — Body mass
  - — Victims age
- Children younger than age 3 have less serious injuries than older children who fall the same distance (increased fat and cartilage and less muscle mass help younger children dissipate energy from the fall).[40,41]
- Mortality increases with falls from > 6 meters.

MVC

- Position in vehicle and use of seatbelts have an effect on seriousness of MVC injuries.
- Compared with unrestrained occupants, restrained occupants of MVCs may be at comparable risk for solid-organ intra-abdominal injury and greater risk for hollow viscous injury.[42,43]
- MVC with restraints and steering wheel deformity have increased risk of small bowel injury and pancreatic injury.
- Injury of thoracic cage and rib fractures should heighten suspicion for hepatic and splenic injury.[44,45]

* Adapted from: Potoka DA, Saladino RA. Blunt abdominal trauma in the pediatric patient. *Clin Ped Emerg* Med 2005;6:23-31.

refill, which often is cited as a useful predictor of blood loss, is unreliable given inter-observer variation, fluctuations with environmental temperature, and variability in technique.[17-20] A larger relative surface area in children younger than age 2 can promote hypothermia and complicate shock. Given that the diaphragm is a major muscle of respiration, abdominal injury or distention can cause severe respiratory distress, exacerbating other injuries.

Patterns of Pediatric Abdominal Injury

Children with an abdominal injury often have other associated injuries, depending on the mechanism of injury. Falls usually cause head and extremity injuries with a very small percentage of significant abdominal trauma.[9,12,15,21] Pedestrian injuries in toddlers are usually caused by low-speed cars backing into children and result in crush injuries to the trunk and head.[22,23] Pedestrian injuries in school age children who are struck crossing the street often cause multiple injuries, including injuries to the head (44%) and extremities (32%) as well as abdominal injuries (10%).[3] Bicycle injuries usually cause extremity and neck fractures; abdominal injuries in this instance are less common and more difficult to diagnose.

Waddell's triad refers to the pattern of a lower limb injury, left sided abdominal or chest injury, and head injury occurring as a motor vehicle hits a child who is running across a street. The vehicle hits the lower extremity first. Then the child's left chest/abdomen is impacted by the front of the car. After the child is thrown over the car, the head strikes the pavement, causing a closed head injury.[12,24]

Children in MVCs using restraints tend to have less massive head, thoracic, solid organ, and extremity injury than those who do not use restraints. Although the incidence of abdominal trauma may be more common among those who use restraints, overall mortality and morbidity are significantly lower.[12,25,26]

Lap belt complex injuries typically occur` in young children who wear seat belts improperly positioned over immature iliac crests. The restraint migrates onto the abdomen during rapid deceleration of the car.[12,27] Abdominal injuries (small bowel contusions and lacerations) and lumbar injuries can occur. Chance fracture is a flexion injury of the lumbar spine with distraction of posterior elements and anterior compression fractures. Chance fracture results from rapid deceleration with hyperflexion around a poorly fitted lap seatbelt.[12,27]

The seatbelt sign, or contusion of the abdomen secondary to the lap belt, is known to be a possible harbinger of more serious abdominal injury. However, in one study, only 45% of children with visceral injury had abdominal wall ecchymoses;[28] therefore, lack of a seatbelt sign cannot be used to rule out serious injury.

With the advent of airbags in cars, children are at risk of airbag injury. Airbags can deploy at speeds of 150 mph, causing significant injury to children. Both infants in rear-facing car seats and children sitting inappropriately in a seat with airbags can suffer serious injury, including death, head injury, C-spine injury, abrasions, and burns from the airbag deployment mechanism.[29-35] The middle back seat is, thus, the safest for children.

Handlebar injuries are not uncommon in children riding bicycles.[36-38] After a sudden stop, the child falls over the front of the bicycle and the handlebars hit the child's abdomen. The trauma in this instance can be considered trivial and the symptoms may initially be mild. The mean delay before injury diagnosis is approximately 23 hours.[39] Traumatic pancreatitis is the most common injury (33%) in these cases. Other handlebar injuries include renal and splenic trauma (17%), duodenal hematoma (13%), and bowel perforation (10%).[39]

Initial Management

Initial management of the child with trauma always begins with attention to the ABC's (airway, breathing, and circulation). It is important to always remember that the main cause of cardiac arrest in children is respiratory arrest. Oxygenation and ventilation must be the first priorities in pediatric trauma management. When assessing circulatory status, heart rate and end organ perfusion are important. While tachycardia can have many etiologies in a trauma situation, it also is a child's earliest response to hypovolemia. Blood pressure is not a reliable indicator of circulatory status. In regard to abdominal injury, the most important factor indicating the need for laparotomy in a child with trauma is hemodynamic instability.

Diagnosis. Diagnosis depends on understanding the mechanism of the injury, thorough physical examination and appropri-

Figure 1. Algorithm for Abdominal Imaging in Pediatric Trauma

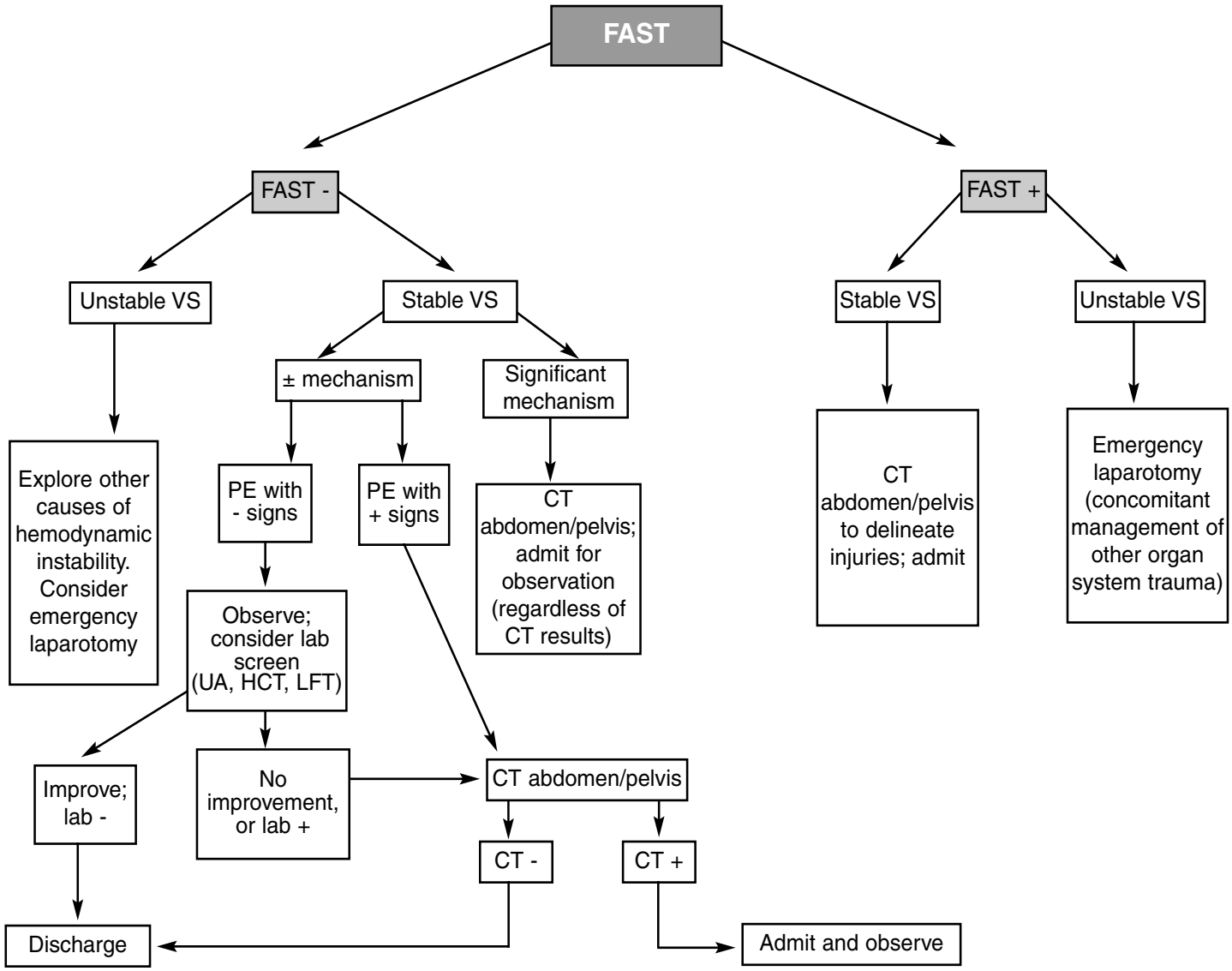

Key: VS = vital signs; UA = urinalysis; HCT = hematocrit; LFT = liver function test

ate laboratory and imaging tests. Table 1 lists mechanisms that suggest an increased risk of intraabdominal injury.

Physical Examination. Physical exam of the child's abdomen in trauma has been generally considered an unreliable and inaccurate indicator of injury and has led to missed injuries.[2,46] Stage of development and inability to communicate verbally can impede the physical exam. Also, children with severe trauma have an increased incidence of concomitant brain injury compared to adults, which decreases the sensitivity of the physical exam.[12] Since abdominal trauma also is the most common cause of initially unrecognized fatal injury in the pediatric population,[1,2] children with serious mechanisms of abdominal injury usually undergo some imaging modality to identify these injuries.

Diagnostic Modalities. *CT Scan.* CT scan has become a valuable tool in the evaluation of abdominal and pelvic injury.[47-51] However, concerns about increased risk of cancer from radiation exposure in children have raised questions about possible overuse of CT imaging.[52-55] Overall, children are more radiosensitive than adults. A child also receives a larger radiation dose than an adult for a given procedure, and the use of helical CT is increasing faster in children than in adults.[55] Frush and colleagues estimated a risk of developing a fatal cancer secondary to radiation to be approximately 1/1000 pediatric CT scan examinations.[56] The recent literature has shown that children with mild and moderate trauma undergo more abdominal imaging for similar injuries than adults,[57] and that 67-75% of pediatric abdominal CT scans obtained are normal.[48,51,58]

Table 2. Grading of Splenic Injury: American Association for the Surgery of Trauma (AAST) Splenic Injury Scale[10]

GRADE 1

Subcapsular hematoma < 10% of surface area or capsular tear < 1 cm in depth.

GRADE 2

Subcapsular hematoma of 10-50% of surface area, intraparenchymal hematoma of < 5 cm in diameter or laceration of 1-3 cm in depth and not involving trabecular vessels.

GRADE 3

Subcapsular hematoma > 50% of surface area or expanding and ruptured subcapsular or parenchymal hematoma, intraparenchymal hematoma of > 5 cm or expanding, or laceration > 3 cm in depth or involving trabecular vessels.

GRADE 4

Laceration involving segmental or hilar vessels with devascularization of > 25% of the spleen.

GRADE 5

Shattered spleen or hilar vascular injury.

Reproduced with permission from: Potoka DA, Saladino RA. Blunt abdominal trauma in the pediatric patient. *Clin Ped Emerg Med* 2005;6:23-31

Focused Abdominal Sonography for Trauma (FAST). FAST has gained popularity in the adult trauma patient as an initial screening tool for identifying patients who are in need of immediate laparotomy. FAST is portable, easy, quick, and non-invasive. The specificity of FAST in children is cited at 95-100% for hemoperitoneum.[59-63] However, in the hemodynamically stable pediatric patient with blunt abdominal trauma, the sensitivity of FAST is 42-88%.[62,63] Solid organ injuries without free intraperitoneal fluid, delayed bleeds, as well as intestinal injuries that do not cause a large accumulation of fluid would not be picked up by FAST. A consensus conference on ultrasound in trauma developed the following practice paradigm:[64] positive FAST in a hemodynamically unstable patient should indicate immediate laparotomy while negative FAST in the same patient would warrant examination for an extraabdominal source of bleeding. Positive FAST in a hemodynamically stable patient should be followed by abdominal CT scan to better define injury. Negative FAST in the same patient should be followed with serial exams for six hours and then follow-up FAST or CT scan, depending on the clinical scenario.

In children, the use of FAST is controversial. A positive FAST exam in a hemodynamically unstable child would indicate the need for an emergent laparotomy.[65,66] Rose suggests that FAST exam can offer information about the timing and urgency of head CT, abdominal CT, and laparotomy in children with concomitant head and abdominal trauma.[67] He also suggests that FAST exam may be sufficient to obviate a CT exam in a child who has a low likelihood of intraabdominal injury.[63,67] However, a FAST exam, whether positive or negative, does not provide the same information as a CT scan. It is argued that many pediatric patients with traumatic injury do not have free fluid, and CT imaging is necessary to stage and identify these injuries to appropriately manage these patients.[65,68,69] Other work suggests using ultrasound in conjunction with physical examination and laboratory values to determine the need for further imaging studies.[58,60,62] *(See Figure 1.)*

Diagnostic Peritoneal Lavage. Diagnostic peritoneal lavage (DPL) historically has been used to identify intraabdominal injury in patients, including children who are too unstable to go to the CT scanner. Since the advent of FAST, which serves a similar diagnostic role, with the advantages of being quicker and non-invasive, the use of DPL has decreased in trauma.

Laboratory Tests. Aside from urinalysis, routine "trauma panels" are not sensitive or specific for identifying intraabdominal injury in children.[70-72] However, children with equivocal physical exam and low mechanism of injury can be screened with laboratory tests. Serial hematocrits are standard to monitor possible bleeding. Several studies found that elevation of aspartate aminotransferase (AST) and alanine aminotransferase (ALT) are predictive of internal abdominal injury.[73-76]

Summary. In summary, the physical exam in pediatric abdominal trauma is not considered reliable. With high risk mechanisms of injury and abnormal physical exam, imaging is necessary to characterize injuries and develop a management plan. Although CT scan is very sensitive and specific, increasing awareness of the trade-off with radiation risks raises questions about appropriate imaging algorithms utilizing combination of physical exam, FAST, CT scan and laboratory tests. It also must be remembered that although helical CTs are increasing in quality, there are some injuries that can be missed by CT scan. Observation at a tertiary trauma center is the only intervention proven to decrease the risk of missed traumatic injury.[77]

Splenic Injuries

Pediatric splenic injuries are the most common intraabdominal organ injury following blunt trauma. *(See Figure 2.)* They should be suspected in any child with significant mechanism of injury, abdominal pain, abdominal tenderness on exam (particularly in the left upper quadrant), left upper quadrant abdominal ecchymoses or contusions, or left rib fractures.

Diagnosis. In hemodynamically stable patients, abdominal CT scan is the best method for diagnosing and grading splenic injuries. *(See Figure 3.)* If contrast blush is seen on CT scan, this indicates active bleeding and a greater likelihood that surgical intervention will be necessary. In hemodynamically unstable patients, diagnosis should be made at laparotomy.[10] *(See Table 2.)*

Management. The current standard of care in pediatric splenic injury is that the spleen should be preserved whenever possible. Nonoperative management and splenic preservation techniques, including partial splenectomy and splenorrhaphy, have become the mainstay of splenic injury management. The presence of hemodynamic instability in a child with an irreparably damaged spleen does remain an absolute indication for

Figure 2. Splenic Trauma

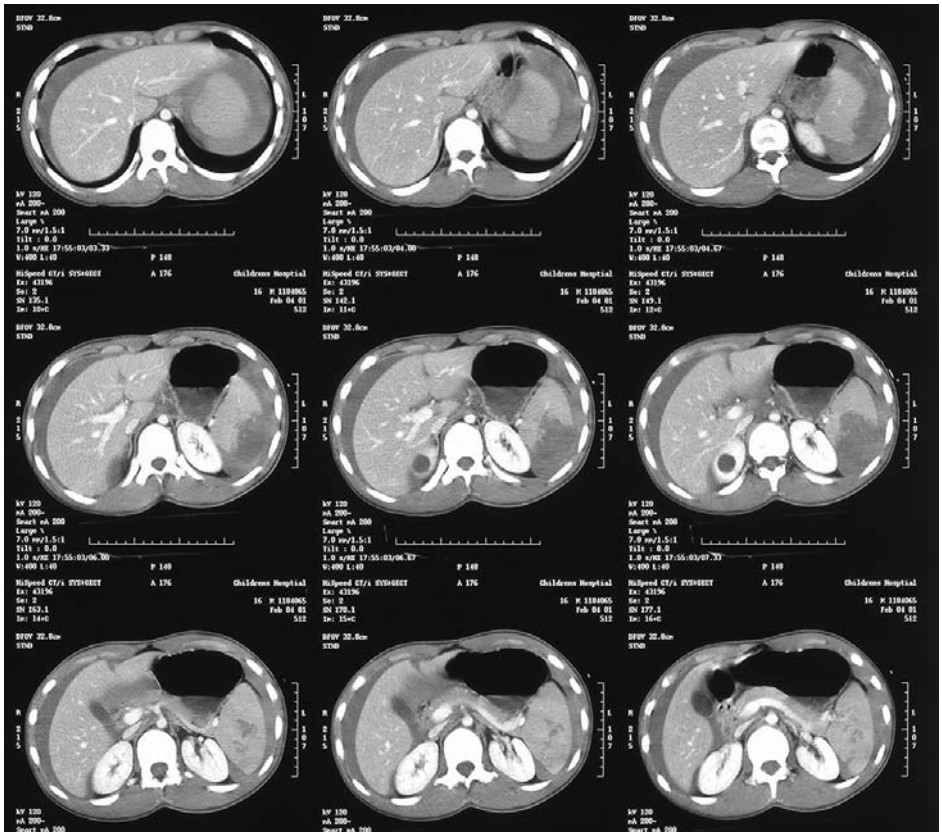

splenectomy. Hemodynamically stable patients may be followed with serial abdominal exams and serial hematocrits, and do not need repeat imaging studies unless they remain symptomatic.

Nonoperative management should be attempted in any hemodynamically stable child with blunt splenic injury, regardless of grade, unless another intraabdominal injury necessitates exploratory laparotomy. Nonoperative management of pediatric splenic injuries leads to full recovery in 90-98% of patients. Nonoperative management has been associated with a decreased number of blood transfusions compared to operative management, and no increased risk of missing other intraabdominal injuries.[78-83] Splenic preservation prevents overwhelming postsplenectomy infection; this may occur in 2-11% of children following post-traumatic splenectomy, with a mortality rate of up to 50%.[84] It also has been shown to result in longer quality-adjusted life expectancy.[85]

A recent retrospective study by Stylianos and colleagues comparing operative rates for 3,232 patients with blunt splenic trauma at both trauma and non-trauma centers found that patients treated at trauma centers had a significantly lower rate of operation than those at non-trauma centers (15.3% vs. 19.3%, $p < 0.001$, for multiply injured patients, and 9.2% vs. 18.5%, $p < 0.0001$, for isolated injury). But rates at both types of centers exceed published American Pediatric Surgical Association benchmarks for all children with spleen injury (5-11%) and the subset with isolated splenic injury (0-3%).[86] Thus, although trauma centers do a better job of having reduced operation rates for splenic injuries, they still have rates 1.5 to 3 times higher than those set by the American Pediatric Surgical Association.

Figure 3. Spleen Fracture

Hepatic Injuries

Pediatric liver injuries *(see Figure 4)* are the second most common intraabdominal organ injury following blunt trauma. They should be suspected in any child with significant mechanism of injury, abdominal pain, abdominal tenderness on exam, right upper quadrant abdominal ecchymoses or contusions, or right rib fractures.

Paddock and co-workers retrospectively reviewed a multi-institutional pediatric trauma registry and found that hepatic injuries represent a higher mortality risk (2.5%) than splenic injuries (0.7%), and though rare, hepatosplenic injuries have the highest risk of mortality (8.6%).[87]

Diagnosis. In hemodynamically stable patients, abdominal CT scan with IV contrast is the best method for diagnosing and grading liver injuries. In unstable patients, diagnosis should be made at laparotomy.

Several studies have shown that AST (aspartate aminotransferase) greater than 400 IU/L or ALT (alanine aminotransferase) greater than 250 IU/L is predictive of hepatic injury.[73-76] Cotton et al used multiple logistic regression analysis in a study of 353 children to show that increased ALT was the only laboratory finding predictive of intraabdominal injury; in fact, ALT of

Figure 4. Liver Laceration

greater than 131 IU/L and the presence of abdominal trauma were indicative of intraabdominal injury with 100% sensitivity.[88] Thus, in cases in which no clear indication exists for imaging following initial assessment, measurement of hepatic enzymes may provide additional information. *(See Table 3.)*

Management. The hemodynamic status of the child should guide management. Hemodynamically stable patients can be managed nonoperatively by following serial abdominal exams, serial hematocrits, and if abnormal, serial liver enzymes. If a child is hemodynamically unstable despite fluid resuscitation or requiring blood transfusion, then an exploratory laparotomy may be required.

The majority of children (85-90%) with blunt hepatic and splenic injuries have relatively low-grade (grade 1-3) injuries and can be managed nonoperatively. In the management of higher-grade solid organ injuries, angiographic embolization is gaining acceptance.[88] Asensio and colleagues reported a significant reduction in liver-related mortality in patients with grades 4 and 5 liver injuries when using angiography and embolization in the initial evaluation and management (from 40-80% down to 8-22%).[89]

Pancreatic Injuries

Compared with other solid organ injury, pancreatic injury is relatively uncommon, occurring in 3-12% of patients with abdominal trauma. It is almost always caused by blunt trauma, and often is caused by compression of the pancreas against the lumbar vertebral column.[10]

Of patients with pancreatic injury, children are more likely than adults to have isolated pancreatic injury. In one series of patients with pancreatic injury, 62.5% of children had isolated pancreatic injuries following blunt abdominal trauma, compared with 15.3% of adults.[90] Bicycle handlebar injuries are a particularly common mechanism of pancreatic injury.

Table 3. Grading of Hepatic Injury: American Association for the Surgery of Trauma (AAST) Liver Injury Scale

GRADE 1
Subcapsular hematoma < 1 cm in maximal thickness; capsular avulsion; superficial parenchymal laceration < 1 cm deep; and isolated periportal blood tracking.

GRADE 2
Parenchymal laceration 1-3 cm deep and parenchymal/subcapsular hematomas 1-3 cm thick.

GRADE 3
Parenchymal laceration > 3 cm deep and parenchymal or subcapsular hematoma > 3 cm in diameter.

GRADE 4
Parenchymal/subcapsular hematoma > 10 cm in diameter, lobar destruction, or devascularization.

GRADE 5
Global destruction or devascularization of liver.

GRADE 6
Hepatic avulsion (CT scan grade, not AAST grade).

Reproduced from: Moore EE, Cogbill TH, Jurkovich GJ, et al. Organ injury scaling: Spleen and liver (1994 revision). *J Trauma* 1995;38:323-324, with permission from Lippincott Williams & Wilkins.

Diagnosis. Pancreatic injuries may be difficult to diagnose due to the retroperitoneal location of the pancreas. Clinical signs and laboratory markers may be subtle and require time to evolve, as pancreatic secretions become activated and pancreatic and peripancreatic inflammation begins. Thus, it is prudent to be suspicious for possible pancreatic injury based on mechanism of injury and clinical signs.

Serum amylase and lipase are rarely helpful in the early post-injury period, but can be followed. Abdominal CT scans are the primary imaging modality, but 1) the sensitivity varies widely, ranging from 28 to 85%; 2) they tend to underestimate the severity of pancreatic injury; and 3) the sensitivity for pancreatic ductal injury is particularly low (42.9-54.5%).[91-96]

Management. Nonoperative management of pancreatic injury is being increasingly proposed, and several series have shown that nonoperative management of pancreatic injuries without ductal disruption can result in low morbidity.

However, compared to other solid organ injuries, pancreatic injury is the most likely to fail nonoperative management. Holmes and coworkers' retrospective study of 1818 pediatric patients with solid organ injury showed an overall nonoperative management failure rate of 5%.[97] The failure rates for isolated organ injuries were: kidney 3%, liver 3%, spleen 4%, and pancreas 18%. Of mechanisms of injury, only bicycle accidents demonstrated a significantly increased risk of failing nonoperative management. A summary Abbreviated Injury Scale (AIS) score of greater than 4, isolated pancreatic injury, and more than

one injured organ were significantly associated with nonoperative management failure.[97]

Intestinal Injuries

Small intestine and colon injuries occur less frequently in children than solid organ injuries, but their findings can be more subtle. They should be suspected in any child with significant mechanism of injury, abdominal pain, abdominal tenderness on exam, ecchymoses or contusions, and particularly in children involved in motor vehicle accidents who are found to have seat-belt signs. One should be highly suspicious if the initial exam demonstrates peritonitis or hemodynamic instability (due to mesenteric bleeding).

Three distinct mechanisms of injury have been described: 1) in burst injuries a compressive force ruptures a transiently distended segment of bowel; 2) shear injuries occur when the rapid deceleration of the bowel is resisted by a fixed point such as the ligament of Treitz or terminal ileum; and 3) crush injuries are seen when the bowel is compressed against the spine.

Diagnosis. These injuries are often subtle in their workup as well as in their initial presentation, and the lack of significant findings on routine trauma imaging and laboratory studies does not imply the absence of injury, particularly in the early post-injury period.

FAST scans have low sensitivity for intestinal injuries. Abdominal CT scan with IV contrast is preferred; specific CT scan findings that suggest surgical exploration include evidence of extraluminal air, extraluminal contrast material, or a moderate to large amount of free fluid without evidence of solid-organ injury (seen on 4 or more consecutive CT scan sections).[98]

Management. In hemodynamically stable patients with no clear signs of intestinal injury, diagnosis requires serial exams, serial laboratory tests, and repeat imaging studies. Any child with initial or evolving peritonitis or intestinal injuries on imaging should undergo an exploratory laparotomy.

Renal Injuries

If the posterior abdomen and retroperitoneum are included in the definition of blunt abdominal trauma, then the kidney is the most commonly injured solid organ in pediatrics.[99] Renal injuries should be suspected in any child with significant mechanism of injury, abdominal or flank pain, abdominal or flank tenderness on exam, back ecchymoses or contusions, or posterior rib fractures.

Diagnosis. Urinalyses are frequently obtained in children with abdominal trauma, and both gross and microscopic hematuria have been associated with intraabdominal injury in children. Gross hematuria is defined as being visible to the naked eye. Microscopic hematuria has been defined differently by different authors, as greater than 5 red blood cells per high power field (RBCs/hpf), more than 20 RBCs/hpf, or more than 50 RBCs/hpf.[72,74,99-101]

How well microscopic hematuria predicts renal injury and the amount of workup that is needed in patients with microscopic hematuria remains controversial (partly due to differing definitions of how many red blood cells per high power field constitute microscopic hematuria). In Stein and coworkers' retrospective study of abdominal CT scans in 412 children following abdominal trauma, it was found that all significant renal injuries presented with hematuria (48 had renal injuries documented by abdominal CT; 25 of which had significant injuries and 23 had insignificant renal injuries). Of those with significant renal injuries, 68% (17/25) had microscopic hematuria, and 32% (8/25) had gross hematuria.[102]

In Stalker and colleagues' retrospective chart review of 256 children with blunt abdominal trauma, they found that hematuria has a sensitivity of 33% (35/106) for predicting renal injury. However, they also noted that having a normal blood pressure and less than 50 RBCs/hpf had a negative predictive value of 100%.[101]

Santucci and associates retrospective review of 720 pediatric trauma patients with hematuria found that all patients with significant renal injuries had either gross hematuria, shock, or significant deceleration injury.[103]

Management. Hemodynamically stable children with gross hematuria or other concerning symptoms should undergo an abdominal CT scan with IV contrast to diagnose and grade kidney injuries. It remains controversial whether hemodynamically stable patients with asymptomatic microscopic hematuria need to undergo abdominal CT. In unstable patients, diagnosis should be made at laparotomy.

The standard of care is renal preservation. A recent retrospective study from a single institution's 25-years of experience reported a less than 1% nephrectomy rate.[104]

Conclusion

Abdominal injury in children is a major cause of severe injury and also is the most common cause of initially missed fatal injury in children.[1,2] It usually is caused by blunt injury due to MVC. An understanding of how abdominal injury presents in children as compared to adults, as well as a knowledge of the different patterns of injury can aid in diagnosing pediatric abdominal injury. Although management of many pediatric abdominal injuries is non-operative, use of appropriate imaging modalities to diagnose intraabdominal pathology is essential to the care of these patients.

References

1. Cantor RM, Leaming JM. Evaluation and management of pediatric major trauma. *Emerg Med Clin North Am* 1998;16(1):229-256.
2. Flood RG, Mooney DP. Rate and prediction of traumatic injuries detected by abdominal computed tomography scan in intubated children. *J Trauma* 2006;61(2):340-345.
3. Kong LB, Lekawa M, Navarro RA, et al. Pedestrian-motor vehicle trauma: an analysis of injury profiles by age. *J Am Coll Surg* 1996;182(1):17-23.
4. Loiselle J. The adolescent trauma patient. *Clin Pediatr Emerg Med* 2003;4(1):4-11.
5. Lynch JM, Gardner MJ, Worsey J. The continuing problem of all-terrain vehicle injuries in children. *J Pediatr Surg* 1998;33(2):329-332.
6. Hargarten SW. All-terrain vehicle mortality in Wisconsin: a case study in injury control. *Am J Emerg Med* 1991;9(2):149-152.
7. Cooper A, Floyd T, Barlow B, et al. Major blunt abdominal trauma due to child abuse. *J Trauma* 1988;28(10):1483-1487.

8. Sivit CJ, Taylor GA, Eichelberger MR. Visceral injury in battered children: a changing perspective. *Radiology* 1989;173(3):659-661.
9. Peclet MH, Newman KD, Eichelberger MR, et al. Patterns of injury in children. *J Pediatr Surg* 1990;25(1):85-90; discussion 90-81.
10. Potoka DA, Saladino RA. Blunt abdominal trauma in the pediatric patient. *Clin Pediatr Emerg Med* 2005;6(1):23-31.
11. Schafermeyer R. Pediatric trauma. *Emerg Med Clin North Am* 1993;11(1):187-205.
12. Rothrock SG, Green SM, Morgan R. Abdominal trauma in infants and children: prompt identification and early management of serious and life-threatening injuries. Part I: injury patterns and initial assessment. *Pediatr Emerg Care* 2000;16(2):106-115.
13. Haller JA Jr., Papa P, Drugas G, et al. Nonoperative management of solid organ injuries in children. Is it safe? *Ann Surg* 1994;219(6):625-628; discussion 628-631.
14. Wright MS. Update on pediatric trauma care. *Curr Opin Pediatr* 1995;7(3):292-296.
15. Rouse TM, Eichelberger MR. Trends in pediatric trauma management. *Surg Clin North Am* 1992;72(6):1347-1364.
16. Schwaitzberg SD, Bergman KS, Harris BH. A pediatric trauma model of continuous hemorrhage. *J Pediatr Surg* 1988;23(7):605-609.
17. Gorelick MH, Shaw KN, Baker MD. Effect of ambient temperature on capillary refill in healthy children. *Pediatrics* 1993;92(5):699-702.
18. Gorelick MH, Shaw KN, Murphy KO. Validity and reliability of clinical signs in the diagnosis of dehydration in children. *Pediatrics* 1997;99(5):E6.
19. Schriger DL, Baraff L. Defining normal capillary refill: variation with age, sex, and temperature. *Ann Emerg Med* 1988;17(9):932-935.
20. Schriger DL, Baraff LJ. Capillary refill—is it a useful predictor of hypovolemic states? *Ann Emerg Med* 1991;20(6):601-605.
21. Roshkow JE, Haller JO, Hotson GC, et al. Imaging evaluation of children after falls from a height: review of 45 cases. *Radiology* 1990;175(2):359-363.
22. Agran PF, Winn DG, Anderson CL. Differences in child pedestrian injury events by location. *Pediatrics* 1994;93(2):284-288.
23. Winn DG, Agran PF, Castillo DN. Pedestrian injuries to children younger than 5 years of age. *Pediatrics* 1991;88(4):776-782.
24. Lucid W, AB T. Abdominal Trauma. In: Strange GR, ed. *Pediatric Emergency Medicine: A Comprehensive Study Guide.* New York: McGraw Hill, Health Professionals Division; 1996:84-90.
25. Hoffman MA, Spence LJ, Wesson DE, et al. The pediatric passenger: trends in seatbelt use and injury patterns. *J Trauma* 1987;27(9):974-976.
26. Osberg JS, Di Scala C. Morbidity among pediatric motor vehicle crash victims: the effectiveness of seat belts. *Am J Public Health* 1992;82(3):422-425.
27. Agran PF, Dunkle DE, Winn DG. Injuries to a sample of seatbelted children evaluated and treated in a hospital emergency room. *J Trauma* 1987;27(1):58-64.
28. Tso EL, Beaver BL, Haller JA Jr. Abdominal injuries in restrained pediatric passengers. *J Pediatr Surg* 1993;28(7):915-919.
29. Giguere JF, St-Vil D, Turmel A, et al. Airbags and children: a spectrum of C-spine injuries. *J Pediatr Surg* 1998;33(6):811-816.
30. Grisoni ER, Pillai SB, Volsko TA, et al. Pediatric airbag injuries: the Ohio experience. *J Pediatr Surg* 2000;35(2):160-162; discussion 163.
31. Lapner PC, McKay M, Howard A, et al. Children in crashes: mechanisms of injury and restraint systems. *Can J Surg* 2001;44(6):445-449.
32. Marshall KW, Koch BL, Egelhoff JC. Air bag-related deaths and serious injuries in children: injury patterns and imaging findings. *AJNR Am J Neuroradiol* 1998;19(9):1599-1607.
33. Pudpud AA, Linares M, Raffaele R. Airbag-related lower extremity burns in a pediatric patient. *Am J Emerg Med* 1998;16(4):438-440.
34. Quinones-Hinojosa A, Jun P, Manley GT, et al. Airbag deployment and improperly restrained children: a lethal combination. *J Trauma* 2005;59(3):729-733.
35. Wittenberg E, Goldie SJ, Graham JD. Predictors of hazardous child seating behavior in fatal motor vehicle crashes: 1990 to 1998. *Pediatrics* 2001;108(2):438-442.
36. Nadler EP, Potoka DA, Shultz BL, et al. The high morbidity associated with handlebar injuries in children. *J Trauma* 2005;58(6):1171-1174.
37. Winston FK, Shaw KN, Kreshak AA, et al. Hidden spears: handlebars as injury hazards to children. *Pediatrics* 1998;102(3 Pt 1):596-601.
38. Winston FK, Weiss HB, Nance ML, et al. Estimates of the incidence and costs associated with handlebar-related injuries in children. *Arch Pediatr Adolesc Med* 2002;156(9):922-928.
39. Sparnon AL, Ford WD. Bicycle handlebar injuries in children. *J Pediatr Surg* 1986;21(2):118-119.
40. Barlow B, Niemirska M, Gandhi RP, et al. Ten years of experience with falls from a height in children. *J Pediatr Surg* 1983;18(4):509-511.
41. Lallier M, Bouchard S, St-Vil D, et al. Falls from heights among children: a retrospective review. *J Pediatr Surg* 1999;34(7):1060-1063.
42. Anderson PA, Rivara FP, Maier RV, et al. The epidemiology of seatbelt-associated injuries. *J Trauma* 1991;31(1):60-67.
43. Denis R, Allard M, Atlas H, et al. Changing trends with abdominal injury in seatbelt wearers. *J Trauma* 1983;23(11):1007-1008.
44. Shweiki E, Klena J, Wood GC, et al. Assessing the true risk of abdominal solid organ injury in hospitalized rib fracture patients. *J Trauma* 2001;50(4):684-688.
45. Ziegler DW, Agarwal NN. The morbidity and mortality of rib fractures. *J Trauma* 1994;37(6):975-979.
46. Jaffe D, Wesson D. Emergency management of blunt trauma in children. *N Engl J Med* 1991;324(21):1477-1482.
47. Haftel AJ, Lev R, Mahour GH, et al. Abdominal CT scanning in pediatric blunt trauma. *Ann Emerg Med* 1988;17(7):684-689.
48. Kane NM, Cronan JJ, Dorfman GS, et al. Pediatric abdominal trauma: evaluation by computed tomography. *Pediatrics* 1988;82(1):11-15.
49. Meyer DM, Thal ER, Coln D, et al. Computed tomography in the evaluation of children with blunt abdominal trauma. *Ann Surg* 1993;217(3):272-276.
50. Taylor GA, Fallat ME, Potter BM, et al. The role of computed tomography in blunt abdominal trauma in children. *J Trauma* 1988;28(12):1660-1664.
51. Taylor GA, Sivit CJ. Computed tomography imaging of abdominal trauma in children. *Semin Pediatr Surg* 1992;1(4):253-259.
52. Brenner D, Elliston C, Hall E, et al. Estimated risks of radiation-induced fatal cancer from pediatric CT. *AJR Am J Roentgenol* 2001;176(2):289-296.
53. Brenner DJ. Estimating cancer risks from pediatric CT: going from the qualitative to the quantitative. *Pediatr Radiol* 2002;32(4):228-223; discussion 242-224.

54. Brenner DJ, Elliston CD, Hall EJ, et al. Estimates of the cancer risks from pediatric CT radiation are not merely theoretical: comment on "point/counterpoint: in x-ray computed tomography, technique factors should be selected appropriate to patient size. against the proposition". *Med Phys* 2001;28(11):2387-2388.
55. Hall EJ. Lessons we have learned from our children: cancer risks from diagnostic radiology. *Pediatr Radiol* 2002;32(10):700-706.
56. Frush DP, Donnelly LF, Rosen NS. Computed tomography and radiation risks: what pediatric health care providers should know. *Pediatrics* 2003;112(4):951-957.
57. Jindal A, Velmahos GC, Rofougaran R. Computed tomography for evaluation of mild to moderate pediatric trauma: are we overusing it? *World J Surg* 2002;26(1):13-16.
58. Fenton SJ, Hansen KW, Meyers RL, et al. CT scan and the pediatric trauma patient—are we overdoing it? *J Pediatr Surg* 2004;39(12):1877-1881.
59. Ong AW, McKenney MG, McKenney KA, et al. Predicting the need for laparotomy in pediatric trauma patients on the basis of the ultrasound score. *J Trauma* 2003;54(3):503-508.
60. Patel JC, Tepas JJ 3rd. The efficacy of focused abdominal sonography for trauma (FAST) as a screening tool in the assessment of injured children. *J Pediatr Surg* 1999;34(1):44-47; discussion 52-44.
61. Soudack M, Epelman M, Maor R, et al. Experience with focused abdominal sonography for trauma (FAST) in 313 pediatric patients. *J Clin Ultrasound* 2004;32(2):53-61.
62. Suthers SE, Albrecht R, Foley D, et al. Surgeon-directed ultrasound for trauma is a predictor of intra-abdominal injury in children. *Am Surg* 2004;70(2):164-167; discussion 167-168.
63. Thourani VH, Pettitt BJ, Schmidt JA, et al. Validation of surgeon-performed emergency abdominal ultrasonography in pediatric trauma patients. *J Pediatr Surg* 1998;33(2):322-328.
64. Scalea TM, Rodriguez A, Chiu WC, et al. Focused Assessment with Sonography for Trauma (FAST): results from an international consensus conference. *J Trauma* 1999;46(3):466-472.
65. Coley BD, Mutabagani KH, Martin LC, et al. Focused abdominal sonography for trauma (FAST) in children with blunt abdominal trauma. *J Trauma* 2000;48(5):902-906.
66. Holmes JF, Brant WE, Bond WF, et al. Emergency department ultrasonography in the evaluation of hypotensive and normotensive children with blunt abdominal trauma. *J Pediatr Surg* 2001;36(7):968-973.
67. Rose JS. Ultrasound in abdominal trauma. *Emerg Med Clin North Am* 2004;22(3):581-599, vii.
68. Emery KH, McAneney CM, Racadio JM, et al. Absent peritoneal fluid on screening trauma ultrasonography in children: a prospective comparison with computed tomography. *J Pediatr Surg* 2001;36(4):565-569.
69. Mutabagani KH, Coley BD, Zumberge N, et al. Preliminary experience with focused abdominal sonography for trauma (FAST) in children: is it useful? *J Pediatr Surg* 1999;34(1):48-52; discussion 52-44.
70. Capraro AJ, Mooney D, Waltzman ML. The use of routine laboratory studies as screening tools in pediatric abdominal trauma. *Pediatr Emerg Care* 2006;22(7):480-484.
71. Keller MS, Coln CE, Trimble JA, et al. The utility of routine trauma laboratories in pediatric trauma resuscitations. *Am J Surg* 2004;188(6):671-678.
72. Isaacman DJ, Scarfone RJ, Kost SI, et al. Utility of routine laboratory testing for detecting intra-abdominal injury in the pediatric trauma patient. *Pediatrics* 1993;92(5):691-694.
73. Hennes HM, Smith DS, Schneider K, et al. Elevated liver transaminase levels in children with blunt abdominal trauma: a predictor of liver injury. *Pediatrics* 1990;86(1):87-90.
74. Holmes JF, Sokolove PE, Land C, et al. Identification of intra-abdominal injuries in children hospitalized following blunt torso trauma. *Acad Emerg Med* 1999;6(8):799-806.
75. Puranik SR, Hayes JS, Long J, et al. Liver enzymes as predictors of liver damage due to blunt abdominal trauma in children. *South Med J* 2002;95(2):203-206.
76. Wisner DH, Wold RL, Frey CF. Diagnosis and treatment of pancreatic injuries. An analysis of management principles. *Arch Surg* 1990;125(9):1109-1113.
77. Sikka R. Unsuspected internal organ traumatic injuries. *Emerg Med Clin North Am* 2004;22(4):1067-1080.
78. Bond SJ, Eichelberger MR, Gotschall CS, et al. Nonoperative management of blunt hepatic and splenic injury in children. *Ann Surg* 1996;223(3):286-289.
79. Morse MA, Garcia VF. Selective nonoperative management of pediatric blunt splenic trauma: risk for missed associated injuries. *J Pediatr Surg* 1994;29(1):23-27.
80. Partrick DA, Bensard DD, Moore EE, et al. Nonoperative management of solid organ injuries in children results in decreased blood utilization. *J Pediatr Surg* 1999;34(11):1695-1699.
81. Schwartz MZ, Kangah R. Splenic injury in children after blunt trauma: blood transfusion requirements and length of hospitalization for laparotomy versus observation. *J Pediatr Surg* 1994;29(5):596-598.
82. Stylianos S. Evidence-based guidelines for resource utilization in children with isolated spleen or liver injury. The APSA Trauma Committee. *J Pediatr Surg* 2000;35(2):164-167; discussion 167-169.
83. Stylianos S. Compliance with evidence-based guidelines in children with isolated spleen or liver injury: a prospective study. *J Pediatr Surg* 2002;37(3):453-456.
84. Bisharat N, Omari H, Lavi I, et al. Risk of infection and death among post-splenectomy patients. *J Infect* 2001;43(3):182-186.
85. Velanovich V, Tapper D. Decision analysis in children with blunt splenic trauma: the effects of observation, splenorrhaphy, or splenectomy on quality-adjusted life expectancy. *J Pediatr Surg* 1993;28(2):179-185.
86. Stylianos S, Egorova N, Guice KS, et al. Variation in treatment of pediatric spleen injury at trauma centers versus nontrauma centers: a call for dissemination of American Pediatric Surgical Association benchmarks and guidelines. *J Am Coll Surg* 2006;202(2):247-251.
87. Paddock HN, Tepas JJ 3rd, Ramenofsky ML, et al. Management of blunt pediatric hepatic and splenic injury: similar process, different outcome. *Am Surg* 2004;70(12):1068-1072.
88. Cotton BA, Beckert BW, Smith MK, et al. The utility of clinical and laboratory data for predicting intraabdominal injury among children. *J Trauma* 2004;56(5):1068-1074; discussion 1074-1065.
89. Asensio JA, Demetriades D, Chahwan S, et al. Approach to the management of complex hepatic injuries. *J Trauma* 2000;48(1):66-69.
90. Takishima T, Sugimoto K, Asari Y, et al. Characteristics of pancreat-

ic injury in children: a comparison with such injury in adults. *J Pediatr Surg* 1996;31(7):896-900.
91. Akhrass R, Kim K, Brandt C. Computed tomography: an unreliable indicator of pancreatic trauma. *Am Surg* 1996;62(8):647-651.
92. Akhrass R, Yaffe MB, Brandt CP, et al. Pancreatic trauma: a ten-year multi-institutional experience. *Am Surg* 1997;63(7):598-604.
93. Bradley EL, 3rd, Young PR Jr., Chang MC, et al. Diagnosis and initial management of blunt pancreatic trauma: guidelines from a multi-institutional review. *Ann Surg* 1998;227(6):861-869.
94. Ilahi O, Bochicchio GV, Scalea TM. Efficacy of computed tomography in the diagnosis of pancreatic injury in adult blunt trauma patients: a single-institutional study. *Am Surg* 2002;68(8):704-707; discussion 707-708.
95. Jeffrey RB Jr., Federle MP, Crass RA. Computed tomography of pancreatic trauma. *Radiology* 1983;147(2):491-494.
96. Kim HS, Lee DK, Kim IW, et al. The role of endoscopic retrograde pancreatography in the treatment of traumatic pancreatic duct injury. *Gastrointest Endosc* 2001;54(1):49-55.
97. Holmes JH 4th, Wiebe DJ, Tataria M, et al. The failure of nonoperative management in pediatric solid organ injury: a multi-institutional experience. *J Trauma* 2005;59(6):1309-1313.
98. Garcia VF, Brown RL. Pediatric trauma: beyond the brain. *Crit Care Clin* 2003;19(3):551-561, x.
99. Wegner S, Colletti JE, Van Wie D. Pediatric blunt abdominal trauma. *Pediatr Clin North Am* 2006;53(2):243-256.
100. Lieu TA, Fleisher GR, Mahboubi S, et al. Hematuria and clinical findings as indications for intravenous pyelography in pediatric blunt renal trauma. *Pediatrics* 1988;82(2):216-222.
101. Stalker HP, Kaufman RA, Stedje K. The significance of hematuria in children after blunt abdominal trauma. *AJR Am J Roentgenol* 1990;154(3):569-571.
102. Stein JP, Kaji DM, Eastham J, et al. Blunt renal trauma in the pediatric population: indications for radiographic evaluation. *Urology* 1994;44(3):406-410.
103. Santucci RA, Langenburg SE, Zachareas MJ. Traumatic hematuria in children can be evaluated as in adults. *J Urol* 2004;171(2 Pt 1):822-825.
104. Buckley JC, McAninch JW. Pediatric renal injuries: management guidelines from a 25-year experience. *J Urol* 2004;172(2):687-690; discussion 690.

CME/CNE Questions

1. Which of the following is true regarding pediatric abdominal trauma?
   A. Mainly due to penetrating trauma
   B. Children with abdominal trauma secondary to abuse are younger than the majority of trauma patients and have more severe injuries
   C. Only 5% of the mortality in abdominal trauma is due to delays in presentation
   D. Penetrating injuries account for 60% of all trauma admissions nationwide

2. Which of the following is true regarding pediatric anatomy?
   A. Pediatric solid abdominal organs are smaller
   B. A compliant rib cage may allow for underlying injury without external evidence of injury
   C. Abdominal wall and internal organs have more fat than adults
   D. The pediatric internal organs are suspended by less elastic structures than adults

3. A child presents with a seatbelt sign. Which of the following is true?
   A. The child may have serious internal injury
   B. The child may have a Chance fracture
   C. The child may have a small bowel injury
   D. All of the above

4. Which of the following is true regarding a child who has a handlebar mark to the abdomen?
   A. The trauma may be considered trivial and initially symptoms may be mild
   B. The mean delay before diagnosis is approximately 23 hours
   C. Traumatic pancreatitis is the most common injury
   D. All of the above

5. CT scan has become a valuable tool in the evaluation of abdominal and pelvic injuries.
   A. True
   B. False

6. Which of the following is *false* regarding the use of ultrasound in a pediatric trauma patient?
   A. FAST is easy, portable, quick, and noninvasive.

CNE/CME Instructions

Physicians and nurses participate in this continuing medical education/continuing education program by reading the article, using the provided references for further research, and studying the questions at the end of the article. Participants should select what they believe to be the correct answers, then refer to the list of correct answers to test their knowledge. To clarify confusion surrounding any questions answered incorrectly, please consult the source material. **After completing this activity, you must complete the evaluation form provided and return it in the reply envelope provided in order to receive a letter of credit.** When your evaluation is received, a letter of credit will be mailed to you.

CNE/CME Objectives

Upon completing this program, the participants will be able to:

a.) discuss conditions that should increase suspicion for traumatic injuries;
b.) describe the various modalities used to identify different traumatic conditions;
c.) cite methods of quickly stabilizing and managing patients; and
d.) identify possible complications that may occur with traumatic injuries.

B. The specificity of FAST for hemoperitoneum in children is 95-100%.
C. In the hemodynamically stable patient the sensitivity of FAST is 100%.
D. The FAST exam does not detect solid organ injuries without free intraperitoneal fluid.

7. The current standard of care for pediatric splenic injury is that the spleen should be preserved whenever possible.
   A. True
   B. False

8. Regarding hepatic injury, which of the following is true?
   A. Hepatic injury is the most common intraabdominal injury following blunt trauma.
   B. In hemodynamically unstable patients, CT scan is the imaging modality of choice.
   C. The majority of children with hepatic injury have low-grade injuries and can be managed nonoperatively.
   D. In unstable patients, CT scan should be performed immediately.

9. Which of the following is true regarding pancreatic injury?
   A. Pancreatic injury is common.
   B. It usually occurs following penetrating injury.
   C. Children are more likely than adults to have isolated pancreatic injury.
   D. Pancreatic injuries are easy to diagnose.

10. FAST scans have a high sensitivity for intestinal injuries.
   A. True
   B. False

Answers: 1. B; 2. B; 3. D; 4. D; 5. A; 6. C; 7. A; 8. C; 9. C; 10. B

In Future Issues:

Pitfalls in Trauma Management

AHC Media LLC

Dear Trauma Reports Subscriber:

This issue of your newsletter marks the start of a new continuing medical education (CME) or continuing nursing education (CNE) activity and provides us with an opportunity to review the procedures.

Trauma Reports, sponsored by AHC Media LLC, provides you with evidence-based information and best practices that help you make informed decisions concerning treatment options and physician office practices. Our intent is the same as yours - the best possible patient care.

Upon completing this program, the participants will be able to:

1. discuss conditions that should increase suspicion for traumatic injuries
2. describe the various modalities used to identify different traumatic conditions
3. cite methods of quickly stabilizing and managing patients
4. identify possible complications that may occur with traumatic injuries

Each issue of your newsletter contains questions relating to the information provided in that issue. After reading the issue, answer the questions at the end of the issue to the best of your ability. You can then compare your answers with the correct answers provided in an answer key in the newsletter. If any of your answers were incorrect, please refer back to the source material to clarify any misunderstanding.

At the end of each semester you will receive an evaluation form to complete and return in an envelope we will provide. Please make sure you sign the attestation verifying that you have completed the activity as designed. Once we have received your completed evaluation form we will mail you a letter of credit. This activity is valid 24 months from the date of publication. The target audience for this activity is emergency medicine physicians and nurses, trauma surgeons and nurses.

If you have any questions about the process, please call us at (800) 688-2421, or outside the U.S. at (404) 262-5476. You can also fax us at (800) 284-3291, or outside the U.S. at (404) 262-5560. You can also email us at: customerservice@ahcmedia.com.

On behalf of AHC Media, we thank you for your trust and look forward to a continuing education partnership.

Sincerely,



Brenda Mooney
Senior Vice-President/Group Publisher
AHC Media LLC

3525 Piedmont Road NE ■ Building Six, Suite 400 ■ Atlanta, Georgia 30305-1515 ■ Tel (404) 262-7436 ■ Fax (404) 262-7837 ■ www.ahcmedia.com