AHC Media LLC

Enclosed in this issue: CME/CME Evaluation

Evidence-Based M ED

Trauma Reports

Vol. 8, No. 6

Supplement to *Emergency Medicine Reports* and *Pediatric Emergency Medicine Reports*

Nov./Dec. 2007

Trauma patients frequently present to the emergency department for evaluation. Early identification of injuries, a thorough diagnostic evaluation, and timely management improve outcomes. Understandably, high-risk patients with the potential for decompensation on missed injuries mandate a thorough and comprehensive evaluation. This article identifies and reviews areas where diagnostic errors may occur.

— *The Editor*

Blunt Trauma Evaluation and Management: Pitfalls to Avoid

Author: **Lisa Freeman Grossheim, MD, FACEP,** Assistant Professor, Department of Emergency Medicine, University of Texas Medical School at Houston

Peer reviewer: **Mary Jo Bowman, MD, FAAP, FCP,** Associate Professor of Clinical Pediatrics, Ohio State University College of Medicine, PEM Fellowship Director, Attending Physician, Columbus Children's Hospital, Columbus, OH.

Overview

Major trauma is one of America's most pervasive and expensive health care concerns. In this environment of rising costs and diminishing resources, care must be delivered in the most cost-effective manner while also ensuring that significant injuries are not missed. Clinicians should recognize the limitations of, indications for, and contraindications to diagnostic testing. *(See Table 1.)* In addition, interpreting certain studies completed in the trauma setting should be done cautiously, with an awareness of limitations. This article will discuss the caveats in the evaluation and management of blunt trauma patients in both the community hospital and trauma center.

Don't Get Unnecessary Labs

Patients who warrant laboratory evaluation include those with decreased systolic blood pressure, altered mental status, or abnormal respiratory rate secondary to a higher-than-expected frequency of electrolyte abnormalities. Patients with significant co-morbid disease, such as renal failure, diabetes, or cardiac disease, or those patients on anticoagulant medications, warrant more extensive laboratory testing.

Protocol-driven evaluation of trauma patients is routine in most trauma centers and is a practice-guideline of the advanced trauma life support (ATLS) course. Protocol testing is variable but may include arterial blood gas, lactate, complete blood count, serum chemistries, blood type and screen, coagulation panel, urinalysis, blood alcohol level, and urine drug screen. Some institu-

Statement of Financial Disclosure

Dr. Dietrich (editor in chief), Dr. Grossheim (author), Dr. Bowman (peer reviewer), Ms. Finerty (nurse reviewer), and Ms. Neff (nurse reviewer) report no relationships with companies related to this field of study.

Table 1. Do's and Don'ts of Trauma Evaluation

- ❑ Don't get unnecessary labs.
- ❑ Don't miss occult trauma in high-risk patients.
- ❑ Don't overestimate the utility of plain films of the cervical spine.
- ❑ Don't ignore abnormal vital signs (tachycardia).
- ❑ Do beware of a "negative" CT scan of the abdomen.
- ❑ Don't worry about oral contrast.
- ❑ Don't overestimate reliability of FAST (focused abdominal sonography in trauma).
- ❑ Don't ignore the ventilator alarm.
- ❑ Do transfer patients appropriately.

tions may include liver enzymes. Routine trauma laboratory protocols are frequently costly and unnecessary and their utility is questionable, especially in patients with minor trauma.[1]

A prospective study by Namias and colleagues evaluated 500 admissions to a trauma service. Electrolytes, amylase, and coagulation parameters were obtained. No interventions were made for abnormalities in sodium, bicarbonate, BUN (blood urea nitrogen), or creatinine. One patient had potassium administered for hypokalemia. Hyperglycemia was seen in known diabetics and in patients with severe neurologic injuries.[2]

Tortella and coworkers found that routine chemistries only rarely revealed clinically significant abnormalities.[3] In the study by Namias et al, an intervention was made as a result of abnormal chemistry findings in only 5 of 1023 patients.[2] The bulk of the abnormalities found in these patients are clinically insignificant in the trauma resuscitation setting and do not lead to clinical interventions.[1]

Chu and colleagues prospectively evaluated 1155 patients who were tested based on protocol versus those who were given selected labs based on clinical need. They found no statistically significant change in the percentage of lab tests leading to interventions between the two groups (7% versus 8%). In the protocol group, the average lab charge was $748. In the group treated based on clinical need, the charge was reduced by 93%; this gave an estimated annual savings of $1.5 million. No adverse event was noted when selective laboratory evaluation was used.[4]

Hypokalemia is common in trauma patients (50-68%) and is likely due to catecholamine effect and/or acid base status. It is not a body depletion of potassium but rather a shift. In one study, hypokalemia was responsible for 92% of the lab abnormalities in trauma patients.[2] In a prospective study of 133 patients with blunt trauma, it was noted that hypokalemia occurred within one hour of trauma and returned to normal within 24 hours without significant potassium replacement.[5] Hypokalemia in trauma patients has been reported to correlate with the severity of the insult.[2,6-7] It is not clinically significant and typically corrects with resuscitation or benign neglect.[8]

Hyperglycemia also is very common. Some degree of hyperglycemia is expected as part of the physiologic response to trauma.[2] Treatment for a glucose level of less than 300 usually is unnecessary. However, if the patient is a known or suspected diabetic, electrolytes should be checked to ensure that the patient is not in diabetic ketoacidosis.

Mure et al[9] and Buecher et al[10] concluded that amylase and lipase lack the sensitivity and specificity and predictive value to be useful in the setting of blunt abdominal trauma. Elevated amylase was nondiagnostic and triggered no interventions in another study.[2] Liver transaminases may be elevated after blunt liver injury or they may be normal. The level of elevation does not correlate with the severity of injury. Transaminases have not been shown to be useful as a screening tool to exclude the need for a CT (computed tomography) scan of the abdomen.

Hemoglobin and blood type and cross match are indicated if there is evidence of significant bleeding. If the patient is on warfarin sodium, a coagulation panel is necessary. Alcohol and toxicology screens are not usually necessary. They are generally ordered on a delayed basis when other explanations for altered mental status cannot be identified.[4]

Severely injured patients are the exception to the rule of minimal laboratory utilization in trauma. Anemia, acidosis, and coagulopathy are very real concerns in these patients and should be aggressively identified. Abnormal coagulation parameters can be seen in conjunction with hypotension, respiratory depression, and altered mental status.

Don't Miss These Injuries: Occult Trauma in High-risk Populations

Several groups of patients are at increased risk for injury that may be occult or not apparent upon their initial presentation.

Trauma Reports™ (ISSN 1531-1082) is published bimonthly by AHC Media LLC, 3525 Piedmont Road, N.E., Six Piedmont Center, Suite 400, Atlanta, GA 30305. Telephone: (800) 688-2421 or (404) 262-7436.

Senior Vice President/Group Publisher: Brenda Mooney
Associate Publisher: Lee Landenberger
Managing Editor: Suzanne Thatcher

POSTMASTER: Send address changes to ***Trauma Reports***, P.O. Box 740059, Atlanta, GA 30374.

Accreditation

AHC Media LLC is accredited by the Accreditation Council for Continuing Medical Education to provide continuing medical education for physicians.

AHC Media LLC designates this educational activity for a maximum of 2.5 AMA *PRA Category 1 Credits™*. Physicians should only claim credit commensurate with the extent of their participation in the activity.

Approved by the American College of Emergency Physicians for 2.5 hours of ACEP Category 1 credit.

AHC Media LLC is accredited as a provider of continuing nursing education by the American Nurses Credentialing Center's Commission on Accreditation.

Provider approved by the California Board of Registered Nursing, Provider # 14749, for 1.5 Contact Hours.

This program has been approved by the American Association of Critical-Care Nurses (AACN) for 1.5 Contact Hours, Category A, file number 10852.

AHC Media LLC

Subscriber Information

Customer Service: 1-800-688-2421

Customer Service E-Mail: customerservice@ahcmedia.com
Editorial E-Mail: suzanne.thatcher@ahcmedia.com

World Wide Web page: http://www.ahcmedia.com

FREE to subscribers of *Emergency Medicine Reports* and *Pediatric Emergency Medicine Reports*

This is an educational publication designed to present scientific information and opinion to health professionals, to stimulate thought, and further investigation. It does not provide advice regarding medical diagnosis or treatment for any individual case. It is not intended for use by the layman. Opinions expressed are not necessarily those of this publication. Mention of products or services does not constitute endorsement. Clinical, legal, tax, and other comments are offered for general guidance only; professional counsel should be sought for specific situations.

This CME/CNE activity is intended for emergency, family, osteopathic, trauma, surgical, and general practice physicians and nurses who have contact with trauma patients.

It is in effect for 24 months from the date of publication.

For Customer Service,
Please call our customer service department at **(800) 688-2421.** For editorial questions or comments, please contact **Suzanne Thatcher**, Managing Editor, at suzanne.thatcher@ahcmedia.com.

Patients with head injuries, substance abusers, or those with distracting injuries are at highest risk for missed injuries.[11] Other high-risk categories of patients include the elderly; coagulopathic patients; those with neurological disease; patients who are rude, obnoxious, or uncooperative; and the mentally ill.[12] Patients who are coagulopathic are at risk for significant bleeding with even trivial trauma. Patients with alcoholism and the elderly tend to have cerebral atrophy that puts them at greater risk for subdural hematoma because of increasing tension on the cerebral bridging veins.[12]

Blunt Abdominal Trauma. Missed intra-abdominal injuries are common, with a reported incidence of missed injuries in the adult population as high as 65%.[11] A common error in this instance is under-appreciation for the mechanism of injury. Patients with trivial mechanisms of injury still may be at risk for major intra-abdominal pathology.[11]

Even in patients with a normal mental status, it may be difficult to elicit abdominal tenderness despite the presence of significant intra-abdominal pathology.[11] Lack of appreciation for a pertinent physical finding or false reassurance from a benign exam often contributes to this. For example, a seat belt abrasion on the abdomen is associated with significant bowel injury in 21% of cases.[13] In patients with intra-abdominal trauma, the sensitivity and specificity of abdominal pain or tenderness is estimated at 82% and 45%, respectively.[14] *Approximately 40% of patients with significant intra-abdominal pathology may have no signs and symptoms on initial presentation to the emergency department*.[15-17] The finding of a negative or equivocal exam is less reliable in patients who have an altered level of consciousness that is secondary to head injury, intoxication, or distracting injuries.

The presence of any rib fracture significantly increases the risk of a splenic or hepatic laceration.[18,19]

Solid Organ Injury. The spleen is the most commonly injured organ in blunt abdominal trauma. It can be injured from relatively minor mechanisms. In a retrospective study of 30 patients with splenic trauma, it was noted that just more than half of them did not have any abdominal pain.[20] *(See Figure 1.)* An injury involving the bare area of the liver may be clinically silent because the bare area lacks a peritoneal covering and may not produce peritoneal signs or abdominal pain.[19]

Renal injuries may be difficult to predict and may be silent on physical examination due to the retroperitoneal location of the kidneys. The kidneys are somewhat mobile; thus, they are susceptible to deceleration injury from a motor vehicle accident, fall, or from a direct blow. No accurate markers for renal injury exist. In all types of renal trauma, the degree of hematuria is not indicative of the severity or extent of injury.[21] Adult patients at risk of major renal lacerations will have either gross hematuria or microscopic hematuria with hypotension (less than 90 mmHg) in either the field or in the emergency department.[21,22] However, hematuria may be absent in renal pedicle injuries.[23] Children can sustain major renal injuries even with a normal urinalysis, so imaging based on the mechanism of injury is paramount. Intravenous contrast-enhanced CT scan is the study of choice to identify urologic injuries.[21,22]

Figure 1. CT Scan of a Splenic Injury

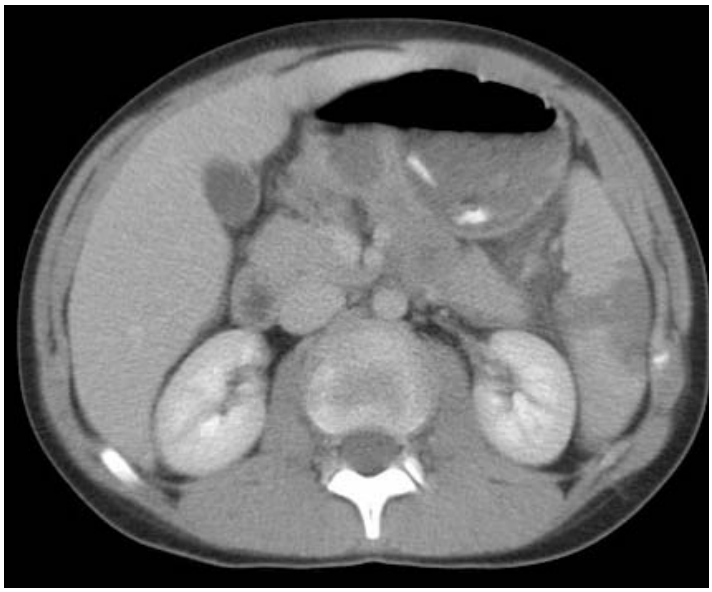

Elderly Patients

Trauma is the fifth leading cause of death in patients older than age 65.[24] The elderly sustain a disproportionate amount of fractures and serious injuries; they account for about 28% of all deaths due to trauma, while representing only 12% of the overall trauma population.[25,26] The elderly often have significant co-morbid conditions and take medications that may mask physiologic changes typically associated with injury, such as tachycardia.[25] Injuries to the brain, spine, and chest, as well as skeletal injuries, increase dramatically with age; however, injuries to the abdomen do not.[25] Elderly patients with low-level falls have an increased risk of cervical spine injury from the occiput to C2. A reasonable strategy is to obtain a CT scan of the cervical spine in all elderly patients who require CT scan of the head.[25] This issue will be discussed in detail in a subsequent section.

Elderly patients with rib fractures have nearly twice the mortality of younger patients with the same injury.[25]

The abdominal exam is less reliable in the elderly. This is demonstrated by the lack of sensitivity of abdominal findings for surgical disease in non-traumatic conditions.[27] Liberal use of CT scan is recommended.

Isolated hip fractures are common presentations in the elderly, and they are especially prevalent after a fall. A typically encountered clinical scenario is persistence of hip pain and negative radiographs. *(See Figure 2.)* One study found that about 5% of such patients had a hip fracture.[28] Hip fractures most commonly occur as a result of relatively minor trauma to an already weakened, osteoporotic bone.[12] The absence of a visible fracture on standard radiographs in an elderly patient with hip pain after a fall is not sufficient to exclude a fracture. Fractures of the acetabulum can be occult on plain films as well. Fractures may be missed initially due to an impacted fracture, nondisplaced fracture, or underlying osteoporosis.[12] MRI (magnetic resonance

Figure 2. Hip Film

A 68-year-old male complaining of pelvic pain after his legs "gave out"; plain radiograph of the pelvis shown here was read as normal by a radiologist.

imaging) is superior to CT scan for the detection of occult fractures, but CT scan is adequate in most patients. *(See Figure 3.)* A reasonable strategy is admission, bedrest, and further imaging such as bone scan, CT scan, or MRI.

Don't Overestimate the Utility of Plain Films of the Cervical Spine

The incidence of adult cervical spine injury in blunt trauma is 2-6%.[29-31] Pain, neurologic deficit, distracting injuries, altered consciousness, and high-risk mechanism of injury have been shown to be appropriate, highly sensitive clinical indications for spinal imaging.[32]

Evaluation of patients for cervical spine injury has significantly changed over the last 30 years. Before 1970, a single lateral view was considered adequate for cervical spine evaluation. In 1981, Shaffer and Doris noted that up to 10% of cervical spine injuries would be missed with only a lateral view.[33,34] They recommended adding AP (anteroposterior) and open-mouth views. In 1993, Woodring and Lee reported that 15% of blunt cervical spine fractures were missed when only the lateral view was obtained.[35] In 1996, Nunez and Quencer noted that 42% of injuries were missed when the lateral view was obtained as the sole film.[36] The American College of Radiology 2005 Appropriateness Criteria recommend a three-view study for cervical spine evaluation that should be supplemented by CT scan when necessary;[37] oblique views are not needed.

Standard three-view series of the cervical spine include lateral, open mouth, and anterior-posterior. A five-view series includes oblique views. A swimmer's view is sometimes added to visualize the cervicothoracic junction. Flexion/extension views add nothing to the initial screening series.[29,38]

What is the most efficient imaging method? There is considerable evidence in the radiology literature to show that CT scan is superior to plain radiography for detecting cervical spine fractures.[33,36,39-43] *(See Figures 4-6.)* The sensitivity of plain films ranges from 39% to 94%, with variable specificities.[44-51] There is wide disparity about the adequacy of the three-view film series in detecting cervical fractures. In a review of 3034 total patients in several studies, cervical spine injury was identified only 53% of the time with plain radiographs; however, CT scan was 98% sensitive.[33] Nguyen and coworkers found that plain radiography was 93% sensitive and CT scan was 100% sensitive for detecting fractures.[51] Other authors report sensitivities as low as 53% for plain films.[51-53]

Reasons for missed injuries include inadequate radiographs, associated injuries, inaccurate clinical examination, and patient co-morbidities.[36]

The sensitivity of CT scan for cervical fracture detection has been reported to be between 90% and 99%, with specificity between 72% and 89%. The limitations of plain films are especially prominent when they are used to evaluate the craniocervical and cervicothoracic junctions. Link and colleagues noted that 8 out of 9 occipital condyle fractures and 13 of 33 C1 and C2 fractures were not seen on plain films.[54,55] CT scan is faster and has improved sensitivity but is more expensive and is associated with more radiation — a 50% increase over plain radiographs.

Helical CT scan is the preferred initial screening test for detection of cervical spine fractures among moderate to high-risk patients in urban trauma centers. The incidence of paralysis resulting from false-negative imaging studies and institutional costs and subsequent litigation and settlement costs from missed fractures and paralysis is reduced by the use of CT scan.[46]

A CT scan is warranted if there is any doubt about an abnormality on a plain radiograph or if the patient has disproportionate

Figure 3. Hip CT Scan

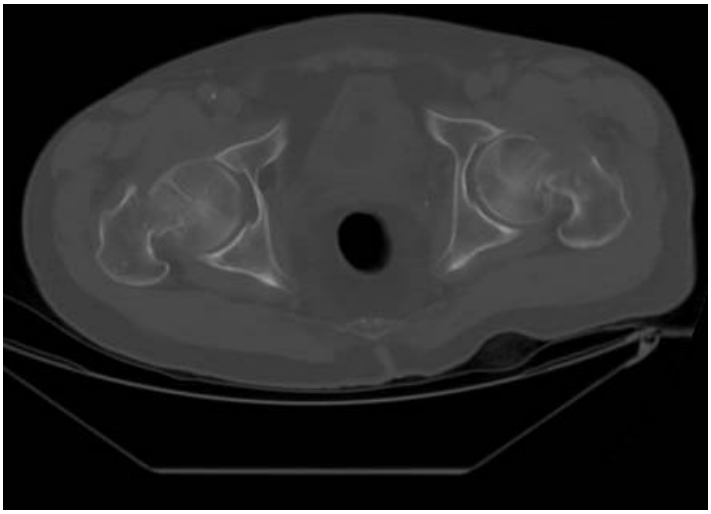

Bone windows of the abdomen and pelvis CT show bilateral femoral neck fractures in this same patient that were not seen in plain radiograph.

neck pain. Practitioners should be familiar with the available scanner. CT scan cuts need to be 3 mm or less to reliably detect occult fracture.[56] CT scan is not perfect, however. It can miss fractures at C2 because the fracture may be in the plane of the scan or can be obscured by artifacts from dental work.[33,39] Therefore, a single-view lateral film is indicated to evaluate C1 and C2 to complement CT scan. This is especially important in elderly patients who have a higher incidence of upper cervical spine fractures.[57]

Can CT scan detect unstable cervical ligamentous injuries? There are five cardinal findings that may be demonstrated on radiography and/or CT scan that indicate instability: displacement, wide interpedicle distance, wide interspinal (interlaminar) distance, widening of facet joints, and disruption of posterior vertebral body line.[33] CT scan should be adequate to determine the presence or absence of ligamentous injury in the majority of conscious patients; in comatose patients, limited MRI is recommended in the sagittal plane to look for ligamentous injury.[33,39]

Does everyone with cervical trauma need a CT scan? Low-risk patients (no head injury or neurologic deficit, low-energy trauma, normal clinical exam, no neck pain) have a low prevalence of injury. Plain radiographs are an effective tool in these patients.[51] Plain radiography does have limitations when used in the high-risk patient group, however. It is difficult to obtain adequate films in severely injured patients, especially in those who are intubated. High-risk patients would include those who have significant closed head injuries, neurologic deficits, high-energy trauma, unreliable examination secondary to intoxication, and neck pain that is out of proportion to plain film findings.[51] These patients need CT scan evaluations.

Figure 4. CT Scan: Axial View

CT scan, axial view, of cervical spine of a 25-year-old male in auto versus train; interpreted as normal.

Don't Ignore Abnormal Vital Signs — Tachycardia

There are many causes of tachycardia in a trauma patient. The most common etiologies include pain, anxiety, blood loss, hypoxia, and sympathomimetic drug abuse (cocaine, amphetamines). Once these potential causes have been excluded or treated, the clinician is left to wonder, "Why is this patient still tachycardic? What am I missing?"

Myocardial contusion is used as a general term encompassing the gamut of blunt cardiac injuries (BCI). There are no widely accepted diagnostic criteria for BCI. The incidence is uncertain as studies differ in diagnostic criteria.[58] BCI can include chamber rupture, contusion, laceration, papillary muscle rupture, and valve rupture.[59]

Outcomes vary from asymptomatic with electrocardiographic changes to cardiogenic shock and death.[58] Associated injuries are common and include rib fracture, sternal fracture, hemothorax, pulmonary contusion, pneumothorax, aortic or great vessel injury, and closed head injury.[60]

The most common complaint of a patient with BCI is chest pain. Examination may reveal hypotension, jugular venous distention, tachypnea, chest abrasion, crepitus, or other evidence of chest trauma.[58] The evaluation begins with a chest radiograph, mainly to exclude other injuries. The most common ECG finding is sinus tachycardia, followed by PACs (premature atrial contractions) or PVCs (premature ventricular contractions).[58]

An abnormal initial ECG (excluding sinus tachycardia) is the most significant independent predictor of a complication, defined as dysrhythmia requiring intervention, cardiogenic shock, valvu-

Figure 5. CT Scan: Odontoid View

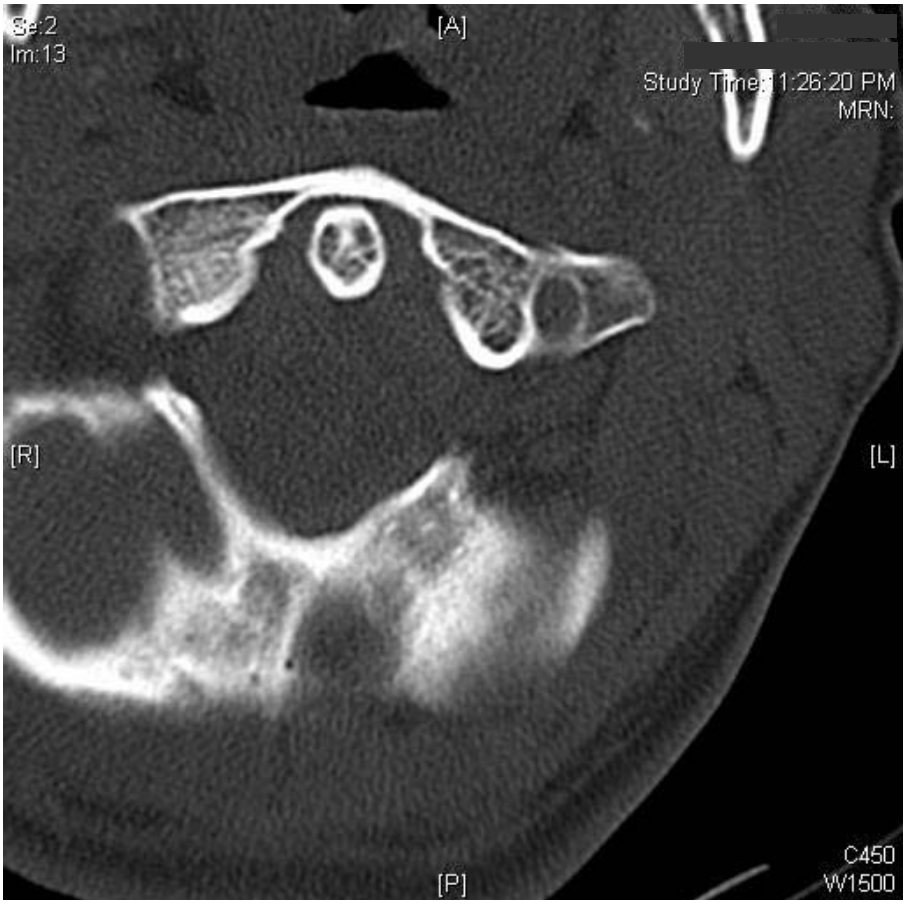

CT scan, odontoid view, of the same patient as seen in Figure 4.

lar rupture, or tamponade.[61]

Dysrhythmias are the most common complication associated with BCI.[62] Up to 70% of patients have a rhythm disturbance. Atrial dysrhythmias are the most common.

Cardiac failure may manifest as hypotension, tachycardia, tachypnea, jugular venous distension, rales, or a systolic murmur. Echocardiogram (ECHO) detects pericardial effusion, myocardial contusion, valvular disruption, and wall motion abnormalities. It may assist in defining injury severity and may alter management. Thirty percent of BCI patients have an abnormal ECHO.[63]

The pathophysiology of trauma-induced myocardial necrosis is poorly understood. Therefore, it is difficult to predict the pattern of myocyte enzymatic release and it remains unclear whether a role exists for its routine measurement.[58] Troponin I is only found in the cardiac myocyte. In BCI patients, elevated troponin I has a sensitivity of 23-100% and a specificity of 85-97% for injury.[64-66] By combining ECG and troponin I at eight hours, a negative predictive value of 100% was reached in a prospective study of 333 patients with blunt thoracic trauma. The authors noted that patients with a normal ECG and troponin I can be discharged.[67]

BCI should be suspected in patients with chest pain that is associated with rib or sternal fractures, pulmonary injury, or significant deceleration mechanism.[14,58] Delayed diagnosis can occur in the elderly; patients with pre-existing cardiac disease; those with multiple, severe chest wall injuries; or patients with unexplained hypotension.[61,68]

BCI can be excluded in the following patients if there is a normal initial ECG and a normal set of cardiac enzymes: hemodynamically stable patients without a history of cardiac disease, younger than age 55, and who do not require admission for another diagnosis.[58]

Patients with isolated ECG or enzyme abnormalities represent the largest and most benign subset of BCI patients. These patients should receive telemetry monitoring for 24 hours and may require ECHO, depending on the level of suspicion.

Do: Beware of "Negative" Abdominal CT Scan

In the past 5-10 years, more emphasis has been placed on non-operative management for certain blunt injuries, resulting in increased use of CT scan.[69] CT scan can be used as a screening tool to help identify patients who may be discharged without further evaluation.[70] CT scan is useful for detecting solid organ injuries, such as those to the liver, spleen, and kidney. CT scan does have limitations. It is less reliable for detecting injuries to the bowel and pancreas.

Bowel injury from blunt trauma varies from a minor hematoma to perforation. Hollow viscus injury is uncommon from blunt trauma, but the consequences of a delay in diagnosis or missing an injury are severe. *(See Table 2.)* Abdominal pain and peritoneal irritation may present early after major perforations or develop slowly because bowel contents are not enzymatically active and have low pH and bacterial counts.[24] Small perforations initially may be clinically unrecognized.[71] Physical examination of the abdomen often is unreliable due to head injury, distracting injuries, or intoxication.[72]

CT Scan Diagnostic Criteria for Bowel Injury. A normal CT scan can be seen in 10-17% of patients with perforated small bowel.[73-75] Direct visualization of bowel discontinuity and extraluminal oral contrast material are virtually diagnostic of bowel perforation but are relatively insensitive. The presence of enteric contrast extravasation is an uncommon finding as well. Extravasation of oral contrast in the absence of free air has been reported only once in a recent review of the literature.[76] Free intraperitoneal oral contrast material is 100% specific for bowel perforation unless IV contrast material from the genitourinary (GU) tract perforation is not a confounding factor. However, the sensitivity is 12% or less.[77-79]

When extraluminal air is present, bowel perforation is the most likely etiology; however, it is not diagnostic of bowel perforation.[80,81] The sensitivity of pneumoperitoneum is 44-55%.[77,79] Other causes may include barotrauma from mechanical ventilation, diagnostic peritoneal lavage, or bladder rupture.[82,83] Intra-

mural air presents as discrete bubbles in a thickened bowel wall.

Bowel wall thickening is present in 61% of small bowel mesenteric injury (SBMI) cases.[84] Contusions and lacerations of bowel and isolated mesenteric lacerations that result in ischemia because of disruption of the arterial supply or venous drainage may cause wall thickening. Both major and minor bowel injuries may have findings of bowel wall thickening and free fluid in common. Bowel wall thickening is more sensitive for bowel injury than extravasation of oral contrast or pneumoperitoneum.[77] Bowel wall enhancement is a subjective finding that is suggestive of bowel injury. The proposed mechanism for wall enhancement is reduced perfusion and interstitial leak of contrast material.[79,85]

Mesenteric stranding is defined as the presence of ill-defined, increased attenuation in the normally fatty mesenteric folds caused by perivascular hemorrhage and an inflammatory infiltrate.[86] This is associated with at least a mesenteric injury. If it is associated with bowel wall thickening, it is highly suggestive of bowel injury.[87-89]

Free intraperitoneal fluid is a common finding in patients with SBMI; it may be the most frequent finding.[89] This fluid may or may not be hemorrhagic. Free fluid is not diagnostic of SBMI; it may produce false positives as high as 67%. This is likely caused by the presence of fluid related to other injuries.[79,90]

Figure 6. CT Scan: Axial View

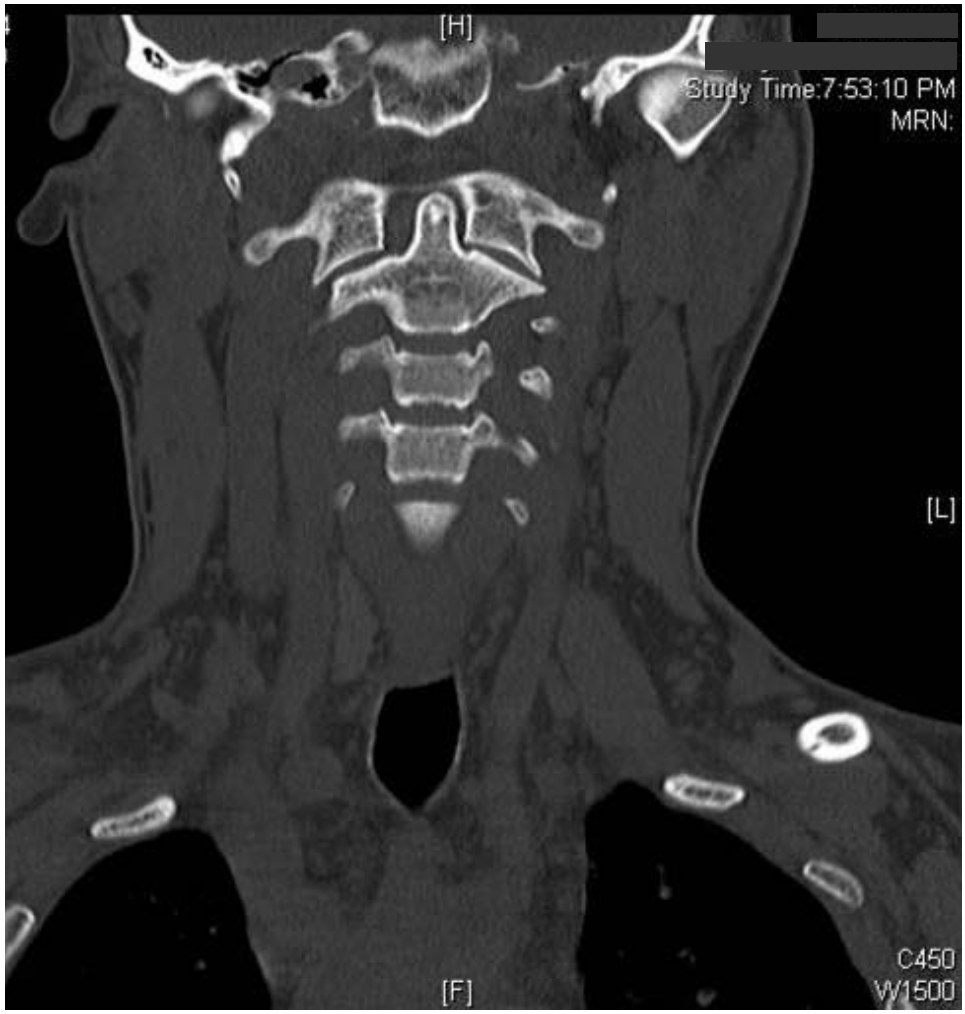

CT scan, axial view, of the same patient as in figures 4 and 5 four days later when he returned to the ED with continued neck pain; demonstrates lateral subluxation of C1 lateral mass on C2 suggesting ligamentous injury.

The location of the fluid is important. Fluid isolated to the mesentery is an unusual finding in liver or spleen injury and suggests underlying SBMI.[69] Retroperitoneal fluid can be caused by hemorrhage, renal injury, bowel perforation, or pancreatic or duodenal injury.[69] Hemoperitoneum in the absence of solid organ injury implies a bowel or mesenteric laceration as the bleeding source.[79]

Bowel injury may be overlooked when solid organ injury is diagnosed. Concomitant bowel injury is present in 5% of patients with liver lacerations and 4% of patients with splenic lacerations because free fluid is attributed to the solid organ injury.[79,91]

Pancreatic Injuries. Injury to the pancreas is rare in blunt trauma; it occurs in only 1-2% of patients. Handlebar injuries and motor vehicle accidents are the most common mechanisms of injury. Abdominal pain may be absent in 25% of patients with a pancreatic injury. The patient may complain of pain initially that resolves and then returns and worsens several hours after the injury.[11] The failure to develop consistent and localizing physical findings has been attributed to the retroperitoneal location of the pancreas and the inactivation of pancreatic enzymes immediately after injury.[92,93] A normal amylase or lipase is not sufficient to rule out pancreatic injury.[11] Helical CT scan is the indicated test, but it is only has sensitivity of 68%.[94]

Don't Worry About Oral Contrast

Most trauma centers use IV and oral contrast for abdomen/pelvis CT scan. The necessity of oral contrast (OC) is a topic of contention. Stafford and colleagues randomized 394 patients to OC or no OC.[95] The sensitivity for small bowel injury detection was 86% with OC and 100% without OC. The sensitivity for solid organ injury was 84% with OC and 89% without OC.[95] Limitations of this study included lack of optimal time for contrast enhancement and a small sample size. In another study, Clancy and coworkers reviewed the charts of 492 patients.[96] Only eight of those patients had oral contrast prior to CT scan. The overall sensitivity of CT scan without oral contrast was 98% with a specificity of 99.8%.[96]

A randomized, prospective trial of CT scan in blunt trauma demonstrated equivalent sensitivities for the diagnosis of small

Table 2. CT Scan Findings in Hollow Viscus Injury[79]

- ❑ Bowel discontinuity
- ❑ Extraluminal oral contrast
- ❑ Extraluminal air
- ❑ Bowel wall thickening
- ❑ Bowel wall enhancement
- ❑ Mesenteric stranding
- ❑ Free intraperitoneal fluid

bowel injuries in those undergoing CT scan with or without oral contrast.[97]

Although most of these studies are limited by small sample size and/or insufficient time for contrast to transverse the length of the bowel, it is typically not practical to wait for two hours or more to allow for opacification of the entire bowel and the addition of contrast should be reserved for patients with clinical scenarios where contrast would be beneficial.

Don't Overestimate the Reliability of FAST

Focused abdominal sonography in trauma (FAST) is designed to visualize hematoperitoneum in unstable blunt trauma patients. However, limitations exist; there is not free fluid associated with contained solid organ injury and hematomas may appear echogenic if clotted. If FAST is completed early after the traumatic event, it may fail to detect fluid in the setting of a significant injury.

The use of ultrasound as a screening modality may lead to false-negative results.[20] In hemodynamically stable patients with blunt abdominal trauma, FAST has a sensitivity of 42-100%.[98-101] Ultrasound may fail to detect grades 3 and 4 hepatic lacerations and grades 2 and 3 splenic lacerations, especially if the associated bleeding is not brisk.[101] Hahn and colleagues noted that 27% of patients in whom no free fluid was detected required laparotomy.[102] False positives may occur in patients with pre-existing ascites, peritoneal dialysis, or in females with small amounts of physiologic fluid.[103]

FAST doesn't detect bowel/mesenteric injuries, pancreatic or vascular injuries, diaphragm, or adrenal injuries. FAST should be used as a triage tool only, not as a definitive study.

Don't Ignore the Ventilator Alarm

Intubated patients are among the most seriously injured patients in the emergency department (ED), but once stabilized they may not be sufficiently monitored in a busy ED. Intubated patients awaiting admission, surgery, or transfer need to be physically and chemically restrained so they have less chance of dislodging the endotracheal tube. Sedation and paralysis is indicated for patient comfort as well as airway protection. Do not undersedate! Don't ignore the ventilator alarm. It may indicate that the patient is coughing or biting the tube, the tube is occluded with blood or a mucus plug, or that the tube has become dislodged or is kinked. Any of these events, if not promptly recognized and treated, can lead to hypoxia and potential brain injury. Verify the tube position, suction the patient, and provide adequate sedation and/or paralysis as needed to control ventilation.

Do: Transfer Patients Appropriately

If a decision is made to transfer a trauma patient to a higher level of care, attention to detail will make the process smoother and benefit the patient. Send copies of all of the patient's radiographs, especially his/her CT scans. If a radiologist has interpreted these films, send a copy of the written report as well. Radiology house staff may be reluctant and may not be permitted to reinterpret films that have already been evaluated by a board-certified radiologist. This is especially true if a change in interpretation is being considered. With regard to CT scan, send copies of all the images, including reconstructions if they have been done. If any studies are incomplete, they will likely be repeated, thus exposing the patient to more radiation and increased cost. Patients transferred from an outside hospital should be thoroughly evaluated and reports should be reviewed carefully. There should be a formal reinterpretation at the receiving facility or a repeat study to avoid missed injury.[104] This should be balanced with the risk of additional radiation and increased cost.

Initiate the transfer process early in obvious cases in which a higher level of care will be needed, such as possible intracranial hemorrhage. When in doubt, secure the airway prior to transfer. As is necessary, chest tubes should be placed and the patient should be transfused prior to transfer. Be certain that the patient has reliable IV access as well and treat pain adequately. If there will be a delay in transfer, repair lacerations to decrease the likelihood of infection. Place Foley catheters and nasogastric tubes as needed and splint fractures. Appropriate packaging of patients requiring transfer enhances patient care.

References

1. Jacobs IA, Kelly K, Valenziano C, et al. Cost savings associated with changes in routine lab tests ordered for victims of trauma. *Am Surg* 2000;66:579-584.
2. Namias N, McKenney MG, Martin LC. Utility of admission chemistry and coagulation profiles in trauma patients: a reappraisal of traditional practice. *J Trauma* 1996;41:21-25.
3. Tortella BJ, Lavery RF, Rekant M. Utility of routine admission serum chemistry panels in adult trauma patients. *Acad Emerg Med* 1995;2:190-194.
4. Chu UB, Clevenger FW, Imani ER, et al. The impact of selective laboratory evaluation on utilization of laboratory resources and patient care in a level 1 trauma center. *Am J Surg* 1996;172:558-563.
5. Vanek VW, Seballos RM, Chong D, et al. Serum potassium concentrations in trauma patients. *South Med J* 1994;87:41-46.
6. Morell V, Lundgren E, Gillott A. Predicting severity of trauma by admission white blood cell count, serum potassium level and arterial pH. *South Med J* 1993;86:658-659.
7. Smith JS Jr. Hypokalemia in resuscitation from multiple trauma. *Surg Gynecol Obstet* 1978;147:18-20.
8. Keller MS, Coln E, Trimble BS, et al. The utility of routine trauma laboratories in pediatric trauma resuscitations. *Am J Surg* 2004;188:671-678.
9. Mure AJ, Josloff R, Rothberg J, et al. Serum amylase determination and blunt abdominal trauma. *Am Surg* 1991;57:210-213.

10. Buechter KJ, Arnold M, Steele B, et al. The use of serum amylase and lipase in evaluating and managing blunt abdominal trauma. *Am Surg* 1990;56:204-208.
11. Sikka R. Unsuspected internal organ traumatic injuries. *Emerg Med Clin North Am* 2004;22:1067-1080.
12. Shoenberger JM, Houpt JC, Swadron SP. Occult trauma in high-risk populations. *Emerg Med Clin N Am* 2003;21:1145-1163.
13. Chandler CF, Lane JS, Waxman KS. Seatbelt sign following blunt trauma is associated with increased incidence of abdominal injury. *Am Surg* 1997;63:885-888.
14. Ferrera PC, Verdile VP, Bartfield JM, et al. Injuries distracting from intraabdominal injuries from blunt trauma. *Am J Emerg Med* 1998;16:145-150.
15. Davis JJ, Cohn I, Nance FC. Diagnosis and management of blunt abdominal trauma. *Ann Surg* 1976;183:672-677.
16. Olsen WR, Hildreth DH. Abdominal paracentesis and peritoneal lavage in blunt abdominal trauma. *J Trauma* 1971;11:824-829.
17. Rodriguez A, DuPriest RW, Shatney CH. Recognition of intra-abdominal injury in blunt trauma victims: a prospective study comparing physical examination with peritoneal lavage. *Am Surg* 1982;48:456-459.
18. Ziegler DW, Agarwal NN. The morbidity and mortality of rib fractures. *J Trauma* 1994;37:975-979.
19. Shweiki E, Klena J, Wood C, et al. Assessing the true risk of abdominal solid organ injury in hospitalized rib fracture patients. *J Trauma* 2001;50:684-888.
20. Cathey KL, Brady WJ, Butler K, et al. Blunt splenic trauma: characteristics of patients requiring urgent laparotomy. *Am Surg* 1998;64:450-454.
21. Marx JA, Isenhour J. Chapter 43: Abdominal Trauma. In: Marx JA, Hockberger RS, Walls RM, et al, eds. *Rosen's Emergency Medicine: Concepts and Clinical Practice,* 6th ed. Philadelphia: Mosby; 2006.
22. Mee SL, McAninch JW, Robinson AL, et al. Radiographic assessment of renal trauma: A ten-year prospective study of patient selection. *J Urol* 1989;141:1095-1098.
23. Alsikafi NF, Rosenstein DI. Staging, evaluation and nonoperative management of renal injuries. *Urol Clin North Am* 2006;33:13-19.
24. Nghiem HV, Jeffrey RB Jr, Mindelzun RE. CT of blunt trauma to the bowel and mesentery. *Semin Ultrasound CT MR* 1995;16:82-90.
25. Aschkenasy MT, Rothenhaus TC. Trauma and falls in the elderly. *Emerg Med Clin North Am* 2006;24:413-432.
26. Koval KJ, Meek R, Schemitsch E, et al. An AOA critical issue. Geriatric trauma: young ideas. *J Bone Joint Surg Am* 2003;85-A:1380-1388.
27. McMahon DJ, Schwab CW, Kauder D. Comorbidity and the elderly trauma patient. *World J Surg* 1996;20:1113-1120.
28. Dominguez S, Liu P, Roberts C, et al. Prevalence of traumatic hip and pelvic fractures in patients with suspected hip fracture and negative initial standard radiographs — a study of emergency department patients. *Acad Emerg Med* 2005;12:366-369.
29. Marion DW, Domeier R, Dunham CM, et al. Practice management guidelines for identifying cervical spine injuries following trauma. Eastern Association for the Surgery of Trauma (EAST). www.EAST.org/tpg/chap3.pdf. Accessed on 10/2/07.
30. Grossman MD, Reilly PM, Gillett T, et al. National survey of the incidence of cervical spine injury and approach to cervical spine clearance in the United States trauma center. *J Trauma* 1999;47:684-691.
31. Davis JW, Phreaner DL, Hoyt DB, et al. The etiology of missed cervical spine injuries. *J Trauma* 1993;34:342-346.
32. Bagley LJ. Imaging of spinal trauma. *Radiol Clin Nort Am* 2006;44:1-12.
33. Daffner RH, Deeb ZL, Goldberg AL, et al. The radiologic assessment of post-traumatic vertebral stability. *Skeletal Radiol* 1990:19:103-108.
34. Shaffer MA, Doris PE. Limitation of cross table lateral view in detecting cervical spine injuries: a retrospective analysis. *Ann Emerg Med* 1981;10:508-513.
35. Woodring JH, Lee C. Limitations of cervical radiography in the evaluation of acute cervical trauma. *J Trauma* 1993;34:32-39.
36. Nunez DB Jr, Quencer RM. The role of helical CT in the assessment of cervical spine injuries. *AJR Am J Roentgenol* 1988;171:951-957.
37. American College of Radiology (ACR) Expert Panel on Musculoskeletal Imaging. ACR Appropriateness Criteria: Suspected Cervical Spine Trauma. Reston, VA: ACR; 2002. (Revised 2005.)
38. Insko EK, Gracias VH, Gupta R, et al. Utility of flexion and extension radiographs of the cervical spine in the acute evaluation of blunt trauma. *J Trauma* 2002;53:426-429.
39. Daffner RH, Sciulli RL, Rodriguez A, et al. Imaging for evaluation of suspected cervical spine trauma: a 2-year analysis. *Injury* 2006;37:652-658.
40. Barba CA, Taggert J, Morgan AS, et al. A new cervical spine clearance protocol using CT. *J Trauma* 2001;51:652-657.
41. Berne JD, Velmanos GG, El-Tawil Q, et al. Value of complete cervical helical CT scanning in identifying cervical spine injury in the unevaluable blunt trauma patient with multiple injuries: a prospective study. *J Trauma* 1999;47:896-903.
42. Li AE, Fishman EK. Cervical spine trauma: evaluation by multidetector CT and three-dimensional volume rendering. *Emerg Radiol* 2003;10:34-39.
43. Ptak T, Kihczak D, Lawrason JN, et al. Screening for cervical spine trauma with helical CT: experience with 676 cases. *Emerg Radiol* 2001;8:315-319.
44. Widder S, Doig C, Burrows P, et al. Prospective evaluation of computed tomographic scanning for spinal clearance of obtunded trauma patients: preliminary results. *J Trauma* 2004;56:1179-1184.
45. Blackmore CC, Ramsey SD, Mann FA, et al. Cervical spine screening with CT in trauma patients: a cost effective analysis. *Radiology* 1999;212:117-125.
46. Grogan EL, Morris JA, Dittus RS, et al. Cervical spine evaluation in urban trauma centers: lowering institutional costs and complications through helical CT scan. *J Am Coll Surg* 2005;200:160-165.
47. Brandt MM, Wahl WL, Yoem K, et al. CT scanning reduces costs and time of complete spine evaluation. *J Trauma* 2004;56:1022-1028.
48. Tins BJ, Cessar-Pullicino VN. Imaging of acute cervical spine injuries: review and outlook. *Clin Radiol* 2004;59:865-880.
49. Blackmore CC, Mann FA, Wilson AJ. Helical CT in the primary

trauma evaluation of cervical spine: an evidence-based approach. *Skeletal Radiol* 2000;29:632-639.
50. Schenarts PJ, Diaz J, Kaiser C, et al. Prospective comparison of admission computed tomographic scan and plain films of the upper cervical spine in trauma patients with altered mental status. *J Trauma* 2001;51:663-668.
51. Nguyen GK, Clark R. Adequacy of plain radiography in the diagnosis of cervical spine injuries. *Emerg Radiol* 2005;11:158-161.
52. Cornelius RS. Imaging of acute cervical spine trauma. *Semin Ultrasound CT MR* 2001;22:108-124.
53. Fisher RP. Cervical radiographic evaluation of alert patients following blunt trauma. *Ann Emerg Med* 1984;13:905-907.
54. Link TM, Schuierer G, Hufendiek A et al. Substantial head trauma: value of routine CT examination of the cervicocranium. *Radiology* 1995;196:741-745.
55. Adelgais KM, Grossman DC, Langer SG, et al. Use of helical computed tomography for imaging the pediatric cervical spine. *Acad Emerg Med* 2004;11:228-236.
56. Grogan EL, Morris JA Jr, Dittus RS, et al. Cervical spine evaluation in urban trauma centers: lowering institutional costs and complications through helical CT scan. *J Am Coll Surg* 2005;200:160-165.
57. Lawarson JN, Novelline RA, Rhea JT, et al. Can CT eliminate the initial lateral cervical spine radiograph in the multiple trauma patient? A review of 200 cases. *Emerg Radiol* 2001;8:272-275.
58. Elie MC. Blunt cardiac injury. *Mt Sinai J Med* 2006;73:542-552.
59. Parmley LF, Manion WC, Mattingly TW. Nonpenetrating traumatic injury of the heart. *Circulation* 1958;18:371-396.
60. Shultz JM, Trunkey DD. Blunt cardiac injury. *Crit Care Clin* 2004;20:57-70.
61. Biffl WL, Moore FA, Moore EE, et al. Cardiac enzymes are irrelevant in the patient with suspected myocardial contusion. *Am J Surg* 1994;168:523-538.
62. Maenza RL, Seaberg D, D'Amico F. A meta-analysis of blunt cardiac trauma: ending myocardial confusion. *Am J Emerg Med* 1996;14:237-241.
63. Frazee RC, Mucha P Jr, Farnell MB, et al. Objective evaluation of blunt cardiac trauma. *J Trauma* 1986;26:510-520.
64. Salim A, Velmanas GC, Jindal A, et al. Clinically significant blunt cardiac trauma: role of serum troponin levels combined with electrocardiographic findings. *J Trauma* 2001;50:237-243.
65. Bertinchant JP, Polge A, Mohty D, et al. Evaluation of incidence, clinical significance and prognostic value of circulating cardiac troponin I and T elevation in hemodynamically stable patients with suspected myocardial contusion after blunt chest trauma. *J Trauma* 2000;48:924-931.
66. Adams III JE, Davilla-Roman VG, Bessey PQ, et al. Improved detection of cardiac contusion with cardiac troponin I. *Am Heart J* 1996;131:308-312.
67. Velmahos G, Karaiskakis M, Salim A, et al. Normal electrocardiography and serum troponin I levels preclude the presence of clinically significant blunt cardiac injury. *J Trauma* 2003;54:45-51.
68. Foil MB, Mackersie RC, Furst SR, et al. The asymptomatic patient with suspected myocardial contusion. *Am J Surg* 1990;160:638-643.
69. Hanks PW, Brody JM. Blunt injury to the mesentery and small bowel: CT evaluation. *Radiol Clin North Am* 2003;41:1171-1182.
70. Livingston DH, Lavery RF, Passannante MR, et al. Admission or observation is not necessary after a negative abdominal CT scan in patients with suspected blunt abdominal trauma: results of a prospective, multi-institutional trial. *J Trauma* 1998;44:273-282.
71. Wisner DH. Stomach and small bowel. In: Mattox KL, Feliciano DV, Moore EE, eds. *Trauma* 4th ed. New York: McGraw-Hill; 2000: 713-734.
72. Brownstein MR, Bunting T, Meyer AA, et al. Diagnosis and management of blunt small bowel injury: a survey of the membership of the American Association for the Surgery of Trauma. *J Trauma* 2000;48:402-407.
73. Fakhry S, Watts D, Luchette FA for the EAST Multi-Institutional Hollow Viscous Injury Research Group. Current diagnostic approaches lack sensitivity in the diagnosis of perforated small bowel injury: analysis from 275,557 trauma admissions from the EAST Multi-Institutional HVI Trial. *J Trauma* 2003;54:295-306.
74. Sharma OP, Oswanski MF, Singer D, et al. The role of CT in diagnosis of blunt intestinal and mesenteric trauma (BIMT). *J Emerg Med* 2004;27:55-67.
75. Fang JF, Chen RJ, Lin BC, et al. Small bowel perforation: is urgent surgery necessary? *J Trauma* 1999;47:515-520.
76. Tsang BD, Panacek EA, Brant WE, et al. Effect of oral contrast administration for abdominal CT in the evaluation of acute blunt trauma. *Ann Emerg Med* 1997;30:7-13.
77. Levine CD, Gonzales RN, Wachsberg RH. CT findings of bowel and mesenteric injury. *J Comput Assist Tomogr* 1997;21:974-979.
78. Tsang BD, Panacek EA, Brant WE, et al. Effect of oral contrast administration for abdominal computed tomography in the evaluation of acute blunt trauma. *Ann Emerg Med* 1997;30:7-13.
79. Brody JM, Leighton DB, Murphy BL, et al. CT of blunt trauma bowel and mesenteric injury: typical findings and pitfalls in diagnosis. *Radiographics* 2000;20:1525-1536.
80. Kane NW, Francis IR, Burney RE, et al. Traumatic pneumoperitoneum: implications of CT diagnosis. *Invest Radiol* 1991;26:574-578.
81. Cook DE, Walsh JW, Vick CW, et al. Upper abdominal trauma: pitfalls in CT diagnosis. *Radiology* 1986;159:65-69.
82. Kane NM, Francis IR, Burney RE, et al. Traumatic pneumoperitoneum: implications of CT diagnosis. *Invest Radiol* 1991;26:574-578.
83. Cook DE, Walsh JW, Vick CW, et al. Upper abdominal trauma: pitfalls in CT diagnosis. *Radiology* 1986;159:65-69.
84. Rizzo MJ, Federle MP, Griffiths BG. Bowel and mesenteric injury following blunt trauma: evaluation with CT. *Radiology* 1989;173:143-148.
85. Mirvis SE, Shanmuganathan K, Erd R. Diffuse small bowel ischemia in hypotensive adults after blunt trauma (shock bowel): CT findings and clinical significance. *AJR Am J Roentgenol* 1994;163:1375-1379.
86. Hagiwara A, Yukioka T, Satou M, et al. Early diagnosis of small intestine rupture from blunt abdominal trauma using CT: significance of the streaky density within the mesentery. *J Trauma* 1995;38:630-633.
87. Strouse PJ, Close BJ, Marshall KW, et al. CT of the bowel and mesenteric trauma in children. *Radiol Graphics* 1999;19:1237-1250.

88. Dowe MF, Shanmuganathan K, Mirvis SE, et al. CT findings of mesenteric injury after blunt trauma: implications for surgical intervention. *AJR Am J Roentgenol* 1997;168:425-428.
89. Halvorsen A, McKenney K. Blunt trauma to the GI tract: CT findings with small bowel and colon injuries. *Emerg Radiol* 2002;9:141-145.
90. Miller LA, Shanmuganathan K. Multidetector CT evaluation of abdominal trauma. *Radiol Clin North Am* 2005;43:1079-1095.
91. Buckman Jr RF, Piano G, Dunham CM, et al. Major bowel and diaphragmatic injuries associated with blunt spleen or liver rupture. *J Trauma* 1988;28:1317-1321.
92. Northrup WF 3rd, Simmons RL. Pancreatic trauma: a review. *Surgery* 1972;71:27-43.
93. Lucas CE. Diagnosis and treatment of pancreatic and duodenal injury. *Surg Clin North Am* 1977;57:49-64.
94. Ilahi O, Bochicchio GV, Scalea TM. Efficacy of CT in the diagnosis of pancreatitic injury in adult blunt trauma patients: a single-institutional study. *Am Surg* 2002;68:704-707.
95. Stafford RE, McGonigal MD, Weigelt JA, et al. Oral contrast solution and computed tomography for blunt abdominal trauma. *Arch Surg* 1999;134:622-627.
96. Clancy TV, Ragozzino MW, Ramshaw D, et al. Oral contrast is not necessary in the evaluation of blunt abdominal trauma by CT. *Am J Surg* 1993;166:680-685.
97. Stafford RE, McGonigal MD, Weigelt JA, et al. Oral contrast solution and CT for blunt abdominal trauma: a randomized study. *Arch Surg* 1999;134:622-626.
98. Goletti O, Ghiselli G, Lippolis PV, et al. The role of ultrasonography in blunt abdominal trauma: results in 250 consecutive cases. *J Trauma* 1994;36:178-181.
99. Rozycki GS, Ochsner MG, Schmidt JA, et al. A prospective study of surgeon-performed ultrasound as the primary adjunctive modality for injured patient assessment. *J Trauma* 1995;39:492-500.
100. McKenney MG, Martin L, Lentz K, et al. 1000 consecutive ultrasounds for blunt abdominal trauma. *J Trauma* 1996;40:607-612.
101. Miller MT, Pasquale MD, Bromberg WJ, et al. Not so fast. *J Trauma* 2003;54:52-60.
102. Hahn DD, Offerman SR, Homes JF. Clinical importance of intraperitoneal fluid in patients with blunt intra-abdominal injury. *Am J Emerg Med* 2002;20:595-600.
103. McGahan JP, Richards J, Fogata MLC. Emergency ultrasound in trauma patients. *Radiol Clin North Am* 2004;42:417-425.
104. Robertson R, Mattox R, Collins T, et al. Missed injuries in a rural area trauma center. *Am J Surg* 1996;172:564-578.

CME/CNE Objectives

Upon completing this program, the participants will be able to:

a.) discuss conditions that should increase suspicion for traumatic injuries;
b.) describe the various modalities used to identify different traumatic conditions;
c.) cite methods of quickly stabilizing and managing patients; and
d.) identify possible complications that may occur with traumatic injuries.

CME/CNE Questions

1. In a previously healthy trauma patient, which electrolyte abnormality requires treatment?
   A. Glucose of 210
   B. Potassium of 3.0
   C. Bicarbonate of 24
   D. None of the above requires treatment

2. In blunt trauma, which of the following statements is true?
   A. Hematuria is a reliable marker of renal injury.
   B. Hypokalemia correlates with the severity of the injury.
   C. Hypokalemia routinely requires correction.
   D. Amylase and lipase are reliably elevated in blunt pancreatic injury.
   E. Elevated liver transaminases are a reliable marker of liver injury.

3. Which statement is *false* regarding trauma in the elderly?
   A. Abdominal pain or tenderness in intra-abdominal injury is present in more than 80% of patients on initial presentation.
   B. The elderly sustain a disproportionate amount of fractures and serious injury from trauma.
   C. The abdominal examination in the elderly is not as reliable as it is in younger patients.
   D. Rib fractures in the elderly are a significant cause of morbidity.
   E. All of above are true

4. Which statement is *not* true regarding imaging of the cervical spine in blunt trauma?
   A. A single lateral view is indicated to evaluate C1 and C2 and to complement CT.
   B. Fractures at C2 may be missed by CT.
   C. Plain films have prominent limitations at the cervicocranial and cervicothoracic junctions.
   D. Helical CT is the preferred initial screening test for detecting cervical spine fractures in high-risk trauma patients.

CNE/CME Instructions

Physicians and nurses participate in this continuing medical education/continuing education program by reading the article, using the provided references for further research, and studying the questions at the end of the article. Participants should select what they believe to be the correct answers, then refer to the list of correct answers to test their knowledge. To clarify confusion surrounding any questions answered incorrectly, please consult the source material. **After completing this activity, you must complete the evaluation form provided and return it in the reply envelope provided in order to receive a letter of credit.** When your evaluation is received, a letter of credit will be mailed to you.

E. The American College of Radiology 2005 guidelines recommend a five-view cervical spine series for routine imaging of the cervical spine in blunt trauma.

5. Which of the following is *not* a characteristic finding on CT of cervical ligamentous injury?
   A. Displacement
   B. Wide interpedicle distance
   C. Widening of facet joints
   D. Disruption of posterior vertebral body line
   E. All of the above are characteristic of cervical ligamentous injury

6. CT scan as an initial imaging modality is indicated in all of the following patients with blunt cervical trauma *except*?
   A. A 36-year-old female with shoulder pain after a 25 mph rear-end collision
   B. An 18-year-old intubated male with a severe closed head injury after being ejected from a vehicle
   C. A 79-year-old female with neck pain after a fall
   D. A 47-year-old intoxicated male with no complaints after a high-speed rollover

7. Which statement is *false* regarding blunt cardiac injury?
   A. The most common complaint is chest pain.
   B. Associated injuries such as pneumothorax and pulmonary contusion are common.
   C. The most common ECG finding is atrial fibrillation.
   D. Dysrhythmias are the most common complication associated with blunt cardiac injury (BCI).
   E. An abnormal EKG coupled with suspicion of BCI mandates at least a 24-hour admission.

8. Which of the following is an *uncommon* finding on CT in the setting of bowel injury following blunt trauma?
   A. Mesenteric stranding
   B. Free intraperitoneal fluid
   C. Extraluminal air
   D. Bowel discontinuity
   E. Bowel wall thickening

9. Which of the following injuries would *not* be identified with a FAST scan?
   A. Contained solid organ injury
   B. Pancreatic injury
   C. Bowel injury
   D. Diaphragmatic injury
   E. None of the above injuries would be identified by FAST

10. Which of the following is a reliable marker of solid organ injury?
   A. Amylase
   B. Lipase
   C. Liver transaminases
   D. Creatinine
   E. None of the above are reliable markers for solid organ injury

Answers: 1. D; 2. B; 3. A; 4. E; 5. E; 6. A; 7. C; 8. D; 9. E; 10. E

In Future Issues:

Geriatric Trauma